

Contents lists available at ScienceDirect

International Journal of Infectious Diseases

journal homepage: www.elsevier.com/locate/ijid

Case Report

Mycobacterium sherrisii visceral disseminated infection in an African HIV-infected adolescent



Francesco Santoro^{a,*}, Giulia Santoro^b, Annalisa Del Giudice^b, Rossella Perna^b,
Francesco Iannelli^a, Maria Immacolata Spagnuolo^c, Eugenia Bruzzese^c,
Andrea Lo Vecchio^{c,*}

^a Laboratory of Molecular Microbiology and Biotechnology (LAMMB), Department of Medical Biotechnologies, University of Siena, Siena, Italy

^b UOC Microbiology and Virology, Ospedali dei Colli – AO V. Monaldi, Naples, Italy

^c Section of Paediatrics, Department of Translational Medical Science, University of Naples Federico II, Naples, Italy

ARTICLE INFO

Article history:

Received 27 November 2015

Received in revised form 11 January 2016

Accepted 13 February 2016

Corresponding Editor: Eskild Petersen,
Aarhus, Denmark.

Keywords:

Mycobacterium sherrisii

Non-tuberculous mycobacteria

HIV

Abscess

Children

gyrB

SUMMARY

A case of visceral disseminated infection by *Mycobacterium sherrisii* in an African HIV-infected adolescent with multiple abdominal abscesses is reported. Despite multiple drug resistance to first-line antibiotics in vitro, long-term treatment with clarithromycin, moxifloxacin, and clindamycin, together with appropriate antiretroviral treatment, resulted in clinical and radiological cure after 19 months of therapy and follow-up.

© 2016 The Authors. Published by Elsevier Ltd on behalf of International Society for Infectious Diseases. This is an open access article under the CC BY-NC-ND license (<http://creativecommons.org/licenses/by-nc-nd/4.0/>).

1. Introduction

Mycobacterium sherrisii is an opportunistic pathogen mainly associated with HIV infection.¹ It has recently been recognized as a species phylogenetically related to *Mycobacterium simiae*.² A few cases of disseminated³ or localized⁴ infection have been reported in the literature, some of them in non-HIV patients.⁵

2. Case report

A 17-year-old, HIV-infected, severely malnourished Eritrean female was hospitalized in January 2014 for a clinical evaluation in the Paediatrics Department of the University of Naples Federico II. The girl had been diagnosed with HIV in Eritrea and had been started on antiretroviral therapy (ART) in 2011. In 2013 she was admitted to a local hospital in Eritrea with chronic diarrhoea,

abdominal discomfort, vomiting, haematemesis, and a low-grade fever. She was diagnosed with pulmonary tuberculosis (TB) on the basis of positive acid-fast smears and was started on a three-drug anti-TB regimen lasting 3 months, followed by rifabutin for another 4 months.

Upon arrival in Italy, the girl was severely malnourished with a weight of 23.78 kg (Z-score −13.3), height of 132 cm (Z-score −4.78), body mass index (BMI) of 13.6 kg/m² (BMI-for-age below the first percentile), and pubertal retardation (Tanner stage B1, G1, PH1). Despite good compliance with ART and an HIV load of <40 HIV RNA copies/ml, her CD4+ cell count was 261/μl (12% of total lymphocytes), defining AIDS (stage C3 according to the US Centers for Disease Control and Prevention paediatric classification⁶).

A physical examination revealed reduced lung basal ventilation, increased respiratory frequency (36 breaths/min), and decreased thoracic excursion. The abdomen was tense and there was pain on palpation of the left side. The presence of high C-reactive protein (CRP; 88 mg/dl), hyperfibrinogenemia (644 mg/dl), normocytic anaemia (haemoglobin 11.3 g/dl), and the persistent low-grade evening fever (37.8 °C) suggested a chronic systemic inflammatory process.

* Corresponding authors.

E-mail addresses: santorof@unisi.it (F. Santoro), andrea.lovecchio@unina.it (A. Lo Vecchio).

<http://dx.doi.org/10.1016/j.ijid.2016.02.011>

1201-9712/© 2016 The Authors. Published by Elsevier Ltd on behalf of International Society for Infectious Diseases. This is an open access article under the CC BY-NC-ND license (<http://creativecommons.org/licenses/by-nc-nd/4.0/>).

At admission, the patient's ART, consisting of lamivudine (4 mg/kg twice daily), abacavir (8 mg/kg twice daily), and lopinavir/ritonavir (12 mg/kg twice daily of lopinavir), was reviewed and adjusted according to weight variation and age.

High-resolution computed tomography (CT) of the thorax revealed a parenchymal consolidation in the upper lobe of the left lung. Because of the persistent haematemesis, an upper endoscopy was performed to rule out gastrointestinal bleeding. Although the girl had no cough (hence no haemoptysis), she reported frequent swallowing of mucus, mainly at night, strengthening the suspicion of a respiratory aetiology of the bleeding. In order to rule out TB, three consecutive gastric aspirations and three sputum samples were sent to the mycobacteriology laboratory. An interferon-gamma release assay was 'non-reactive', presumably due to the low lymphocyte count. As clinical and anamnestic data suggested a relapse of the previous TB infection, treatment was started immediately with isoniazid (10 mg/kg/day), ethambutol (20 mg/kg/day), pyrazinamide (35 mg/kg/day), and rifabutin (10 mg/kg/day) in accordance with recent guidelines.⁷

Abdominal ultrasound and subsequent magnetic resonance imaging of the abdomen revealed the presence of encapsulated abscesses of about 20 × 30 mm located in the para-aortic and mesenteric lymph nodes and a large abscess (82 × 30 mm) in the left psoas muscle. The capsules of the abscesses showed significant contrast enhancement (Figure 1). Considering the previous ineffective anti-TB treatment and the persistence of symptoms and general inflammation after the onset of treatment, the psoas abscess was drained percutaneously and the material was sent to the microbiology laboratory for further analysis.

Acid-fast stains were performed on all specimens. Specimens were inoculated onto both solid (Lowenstein–Jensen) and liquid media (BACTEC MGIT 960). Smears made from gastric aspiration were negative, while the smear from the abscess drainage material was positive for acid-fast bacilli (>10 bacilli/field). Two out of three gastric aspiration specimens yielded growth in the liquid medium after 6 and 7 days, while the abscess drainage material grew on solid medium after 30 days of incubation. Both isolates were identified as *M. simiae* by GenoType Mycobacterium AS (Hain Lifescience, GmbH, Nehren, Germany). Therapy was thus modified by the addition of oral clarithromycin and the discontinuation of both isoniazid and pyrazinamide.

During the first 7 days of this therapy, the patient experienced an initial improvement (CRP 25 mg/dl, fever 37 °C); however, she then began to have high fevers and an increase in inflammatory markers. Ultrasound of the left psoas showed an increase in the size of the abscesses and therefore a permanent drain was positioned.

In order to confirm the aetiological diagnosis, PCR amplification and sequencing of an internal fragment (964 bp) of the 16S rDNA was performed on the two gastric aspirate isolates. BLAST sequence analysis (<http://blast.ncbi.nlm.nih.gov/Blast.cgi>) with the 16S ribosomal RNA sequence database showed 100% identity with the sequence of *M. sherrisii* ATCC BAA-832 (GenBank [AY353699](#)). Furthermore, a 1282-bp fragment of the gyrase subunit B (*gyrB*) gene was amplified and sequenced with primers IF882 (5'-CAYGCSGGCGGCAAGTTCG-3') and IF883 (5'-GCCATCARSACGATCTTG-3'). The sequence showed 92% identity with the *gyrB* gene from *M. simiae* strain KPM 1403 (GenBank [AB014182](#)) and was deposited at GenBank (accession number [KT182936](#)). This confirmed the 16S sequencing species identification.

Antibiotic therapy was again modified, switching from oral to intravenous clarithromycin and adding amikacin (30 mg/kg/day),³ and successively moxifloxacin (10 mg/kg/day) and co-trimoxazole (15 mg/kg/day). During the first 10 days of this multidrug therapy, the patient experienced a general improvement, with resolution of the fever and a reduction in the inflammatory markers. However, the patient developed pancytopenia and severe hypoacusis (with auditory brainstem response threshold shifts), thus both co-trimoxazole and amikacin were discontinued.

In accordance with the recommendations for the treatment of multidrug-resistant mycobacterial infections,⁷ empiric treatment with linezolid (20 mg/kg/day) was added and there was an initial clinical improvement in the fever and pain. However, due to the limited response with regard to inflammation and to the relapse of symptoms, linezolid was discontinued after 18 days of treatment. Despite the relapsing–remitting pattern, the patient still complained of abdominal pain, fever, and rare episodes of haematemesis.

In April 2014, after 3 months of hospitalization and despite the persistence of the low-grade fever, abdominal pain, and low grade inflammation (CRP 10.7 mg/l), the patient returned to Eritrea on

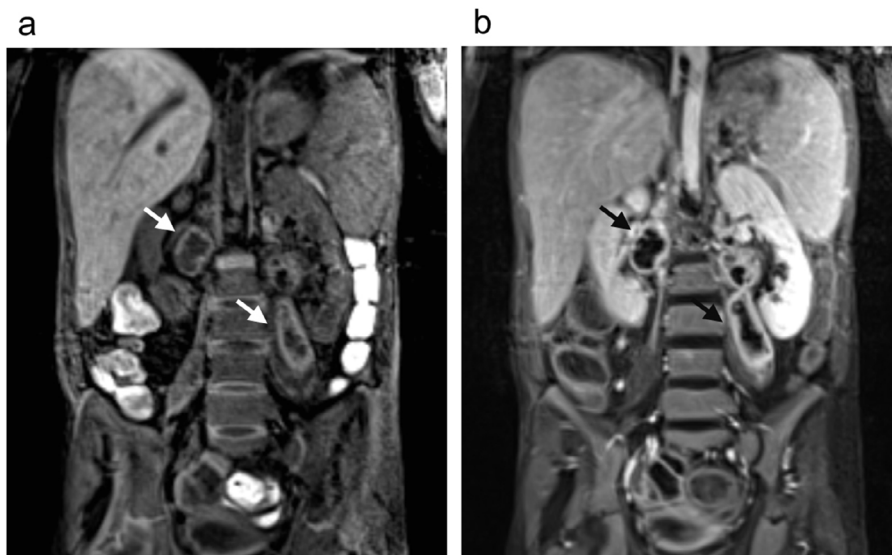


Figure 1. Magnetic resonance imaging of the abdomen before (a) and after (b) intravenous gadolinium contrast injection. The larger abscess formations are indicated with arrows.

Table 1
In vitro antimicrobial susceptibility of the *Mycobacterium sherrisii* isolate^a

Antibiotic	MIC (μg/ml)	Interpretative category
Isoniazid	4	-
Streptomycin	32	-
Ethambutol	16	R
Rifampicin	4	R
Amikacin	16	S
Clarithromycin	4	S
Ciprofloxacin	16	R
Linezolid	32	R
Moxifloxacin	2	S

MIC, minimum inhibitory concentration; R, resistant; S, susceptible.

^a MIC values were interpreted according to the Clinical and Laboratory Standards Institute (CLSI) criteria. There are no CLSI interpretative criteria for isoniazid and streptomycin.

ART (lamivudine, abacavir, and lopinavir/r). A tailored antibiotic therapy was planned consisting of oral clindamycin, moxifloxacin, and clarithromycin (switched to oral after intravenous administration), considering (1) the in vitro antimicrobial susceptibility profile (Table 1), (2) the side effects shown during hospitalization, and (3) the availability of drugs in the country of origin. The progression of the HIV infection was checked with viro-immunological markers, while the mycobacterial infection was monitored by periodic blood sampling and CT of the abdomen.

A slow and progressive improvement was registered after the patient's return from Eritrea, with clinical amelioration, improvements in the abdominal distension and pain, and resolution of the vomiting, haematemesis, and fever within 2 months of discharge. An abdominal CT scan performed after 1 year of treatment demonstrated complete resolution of the psoas abscess and a significant reduction in the other abdominal lesions. As of November 2015, the girl was in good overall clinical condition, had gained 12 kg in weight (weight 36 kg, Z-score -4.3) and 13 cm in height (height 145 cm, Z-score -2.7), and was having regular menstrual cycles.

3. Discussion

The diagnosis of non-tuberculous mycobacterial infections is routinely performed with commercial kits, such as GenoType Mycobacterium AS or INNO LiPA (Innogenetics, Ghent, Belgium); however, in the case presented here, the diagnosis of *M. sherrisii* infection required 16S rDNA sequencing. The antimicrobial susceptibility pattern showed resistance to multiple first-line antibiotics, including most of those used for the empirical treatment of non-tuberculous mycobacterial infections (i.e., isoniazid, ethambutol, ciprofloxacin, and linezolid). After numerous antibiotic modifications, a long-term antibiotic regimen including clindamycin, clarithromycin, and moxifloxacin was able to control, and appears to have cured, the infection. This was evidenced by the significant weight gain and pubertal development. Effective control of the HIV infection (HIV RNA copies <40/ml and CD4+ 18%, 435 cells/μl) was also likely to have been an important factor in the favourable outcome.

Ethical approval: Not required. Informed consent to report the clinical data anonymously was provided by the caregivers.

Conflict of interest: The authors report no conflict of interest.

References

- Loulergue P, Lamontagne F, Vincent V, Rossier A, Pialoux G. *Mycobacterium sherrisii*: a new opportunistic agent in HIV infection? *AIDS* 2007;**21**:893–4.
- van Ingen J, Tortoli E, Selvarangan R, Coyle MB, Crump JA, Morrissey AB, et al. *Mycobacterium sherrisii* sp. nov., a slow-growing non-chromogenic species. *Int J Syst Evol Microbiol* 2011;**61**(Pt 6):1293–8.
- Tortoli E, Galli L, Andebirhan T, Baruzzo S, Chiappini E, de Martino M, et al. The first case of *Mycobacterium sherrisii* disseminated infection in a child with AIDS. *AIDS* 2007;**21**:1496–8.
- Gamperli A, Bosshard PP, Sigrist T, Brandli O, Wildermuth S, Weber R, et al. Pulmonary *Mycobacterium sherrisii* infection in a human immunodeficiency virus type 1-infected patient. *J Clin Microbiol* 2005;**43**:4283–5.
- Tortoli E, Mariottini A, Mazzarelli G. *Mycobacterium sherrisii* isolation from a patient with pulmonary disease. *Diagn Microbiol Infect Dis* 2007;**57**:221–3.
- US Centers for Disease Control and Prevention. Revised classification system for human immunodeficiency virus infection in children less than 13 years of age. *MMWR Recomm Rep* 1994;**43**(RR12):1–10.
- World Health Organization. Guidance for national tuberculosis programmes on the management of tuberculosis in children, 2nd edition, Geneva: WHO; 2014.