



This is a repository copy of *Effect of Pulp Protection Technique on the Clinical Performance of Amalgam Restorations: Three-Year Results* .

White Rose Research Online URL for this paper:  
<http://eprints.whiterose.ac.uk/405/>

---

**Article:**

Baratieri, L.N., Machado, A., van Noort, R. et al. (2 more authors) (2002) Effect of Pulp Protection Technique on the Clinical Performance of Amalgam Restorations: Three-Year Results. *Operative Dentistry*, 27 (4). pp. 319-324. ISSN 0361-7734

---

**Reuse**

Unless indicated otherwise, fulltext items are protected by copyright with all rights reserved. The copyright exception in section 29 of the Copyright, Designs and Patents Act 1988 allows the making of a single copy solely for the purpose of non-commercial research or private study within the limits of fair dealing. The publisher or other rights-holder may allow further reproduction and re-use of this version - refer to the White Rose Research Online record for this item. Where records identify the publisher as the copyright holder, users can verify any specific terms of use on the publisher's website.

**Takedown**

If you consider content in White Rose Research Online to be in breach of UK law, please notify us by emailing [eprints@whiterose.ac.uk](mailto:eprints@whiterose.ac.uk) including the URL of the record and the reason for the withdrawal request.



[eprints@whiterose.ac.uk](mailto:eprints@whiterose.ac.uk)  
<https://eprints.whiterose.ac.uk/>

# Effect of Pulp Protection Technique on the Clinical Performance of Amalgam Restorations: Three-Year Results

LN Baratieri • A Machado • R Van Noort  
AV Ritter • NMM Baratieri

## Clinical Relevance

Results of this study indicate that pulp protection may not be necessary under amalgam restorations made with a high copper, dispersed phase alloy. A longer evaluation is necessary to confirm/reject that observation.

## SUMMARY

**This study evaluated the influence of the pulp protection technique on clinical performance of amalgam restorations after three years, with**

\*Luiz Narciso Baratieri, DDS, MS, PhD, professor and head, Department of Operative Dentistry, Universidade Federal de Santa Catarina, Florianópolis, SC–Brazil

Adriana Machado, DDS, MS, private practice, Porto Alegre, RS – Brazil

Richard Van Noort, BSc, DPhil, professor, Operative Dentistry Department, Sheffield University, Sheffield–UK

André V Ritter, DDS, MS, assistant professor, Department of Operative Dentistry, University of North Carolina at Chapel Hill, Chapel Hill, NC; auxiliary professor, Department of Operative Dentistry, Universidade Federal de Santa Catarina, Florianópolis, SC–Brazil

Naira Maria Mascarenhas Baratieri, DDS, MS, PhD, professor, Department of Radiology, Universidade Federal de Santa Catarina, Florianópolis, SC–Brazil

\*Reprint request: Rua Presidente Coutinho, 311 – Salas 1001-1004, Florianópolis SC 88015-230–Brazil; e-mail: lbaratieri@hotmail.com

**particular reference to post-operative sensitivity and secondary caries. One hundred and twenty (120) Class II amalgam restorations (68 premolars, 52 molars; 78 MOD, 42 OD/MO) were placed in 30 participants (four restorations per participant). The restorations were divided into four groups according to the pulp protection technique used: copal varnish; 2% neutral sodium fluoride; adhesive resin and no pulp protection. The parameters evaluated were post-operative sensitivity, staining of the dental structure, tooth vitality, partial or total loss of the restoration and secondary caries. One hundred and eight (108) restorations were available for evaluation after three years. No partial or total loss of restorations had occurred; all teeth were vital, no tooth structure staining or secondary caries was detected in any of the restored teeth. Post-operative sensitivity was observed only in two restorations at baseline and at seven-days. The three-year clinical performance of teeth restored with a high copper dispersed phase amalgam was not**

## affected by the choice of pulp protection technique.

### INTRODUCTION

One of the main goals of a restoration is to prevent microleakage at the tooth-restoration interface. Clinically, marginal leakage can be related to signs and symptoms including sensitivity, marginal staining and recurrent decay and can lead to the failure of the restoration. For amalgam restorations, copal varnish has been widely recommended to avoid migration of metallic ions from the amalgam to the tooth structure, preventing staining, reducing marginal leakage and its consequences, post-operative sensitivity and secondary caries (Fitchie & others, 1990; McComb, Ben Amar & Brown, 1990; Murray, Yates & Williams, 1983). Copal varnish is considered an important dentin sealant in the period between placement of the restoration and formation of amalgam corrosion by-products, which are capable of sealing the tooth-restoration interface.

The kinetics of the initial seal attributed to the varnish and subsequent sealing by the amalgam itself has never been thoroughly elucidated (Newman, 1984). Some reports have demonstrated that cavity varnishes do not produce any benefit to the marginal seal of restorations (Marchiori & others, 1998; Manders, García-Godoy & Barnwell, 1990; Mazer, Rehfeld & Leinfelder, 1988), in both conventional and high-copper amalgam (Andrada, 1982). Furthermore, cavity varnishes have been criticized for providing an uneven film, poor insulation, lack of biologic properties, lack of adhesion between tooth and amalgam and high solubility (Mazer & others, 1988).

Other pulp protection techniques and materials have also been suggested, such as calcium hydroxide cements, zinc oxide and eugenol bases, zinc-phosphate bases, and more. More recently, adhesives have been recommended to seal the tooth preparation, providing pulp protection (Gwinnett & others, 1994; Staninec & Holt, 1988). Amalgam can also be bonded to the tooth preparation, generating secondary retention to the restoration (Staninec, 1989). The medium- and long-term effects of these pulp protection techniques on the clinical performance of amalgam restorations has not been fully investigated.

This study assessed the influence of three different pulp protection techniques on the clinical performance of Class II amalgam restorations over time. The three-year findings are presented.

### METHODS AND MATERIALS

#### Sample Description

Thirty adult patients, ranging in age from 16 to 36 years, were selected for this study. Participants were selected from an original pool of 142 patients from the

Federal University of Santa Catarina School of Dentistry, Florianópolis, Brazil. Participants qualified for the study if they required replacement of four defective typical Class II amalgam restorations of moderate size (bucco-lingual isthmus not to exceed 2/3 of the distance between the cusp tips) on vital teeth. In addition, the teeth to be restored needed to have proximal and occlusal contacts in the restoration. The sample for the study consisted of 120 vital teeth (68 premolars and 52 molars) with 78 MOD and 42 OD/MO restorations. Reasons for restoration replacement were secondary caries, marginal failure, bulk fracture, marginal ridge fracture and/or lack of contour (missing proximal contacts).

#### Restorative Procedures—Experimental Groups

All the preparations were accomplished at water-cooled high-speed with #330 carbide burs. Manual instruments were used to refine the preparations. A caries-detector solution (Caries Detector—Kuraray Company, Ltd, Osaka, Japan) was used to aid in the identification of the carious tissue, whenever necessary. All restorations had proximally contacting surfaces, and the gingival margins were located in enamel. In addition, all the restorations presented occlusal contacts. The remaining dentin thickness (RDT) after tooth preparation/ restoration was determined to be moderately deep. Even though the RDT was not quantitatively determined, all tooth preparations had pulpal and axial walls at least 0.5 mm inside the dentin-enamel junction.

Each of the four preparations in the same participant was protected with a different pulp protection technique prior to placing the amalgam, which consisted of (1) copal varnish, (2) 2% neutral sodium fluoride, (3) a resin adhesive or (4) no pulp protection. The four different pulp protection techniques applied were:

Group 1: All the preparation walls were coated with two layers of copal varnish (Copalite, Cooley & Cooley, Houston, TX 77041, USA);

Group 2: 2% neutral sodium fluoride (DFL, Rio de Janeiro, 22713-0001 Brazil) was applied to all the preparation walls for four minutes, then dried with a blast of air;

Group 3: The resin adhesive system All-Bond 2 (BISCO Inc, Schaumburg, IL 60193, USA) was applied on all enamel and dentin walls according with the manufacturer's instructions and

Group 4: No pulp protection was used, the amalgam was condensed directly onto the freshly-cut enamel and dentin.

All 120 preparations were cut and restored under rubber dam isolation by the same operator (AM) with the same amalgam type (Dispersalloy, Dentsply/Caulk, Milford, DE 19963, USA). After the pulp protection

application (Groups 1–3), the amalgam was inserted and carved, the rubber dam was removed and the occlusion adjusted.

### Follow-Up Examinations

Evaluations were done at baseline, at seven days and at the end of every subsequent year until the third year after placement of the restorations. Forty-eight hours after placement, all the restored teeth were tested for vitality with tetrafluorethan (–20, Roeko, Langenan, 1150 D-89129, Germany). This appointment represented the baseline for the assessment of post-operative sensitivity. At this same appointment, the restorations were finished and polished. After polishing, the restorations were photographed from the occlusal aspect with X2 magnification. Figures 1a, 2a, 3a and 4a depict representative examples of restorations at the baseline appointment.

Black and white prints were obtained from the color slides and cropped to leave only the occlusal surface of the restoration visible. The photographic documentation allowed for (1) the generation of a photographic archive, (2) the prospective evaluation of the restorations, (3) side-by-side comparison of the baseline vs three-year old restoration, (4) inter-evaluators discussion without the participant being present and (5) more precise statistical analysis.

Bitewing radiographs were obtained for all the teeth, which were used to detect proximal overhangs.

Evaluation of the restorations on every follow-up visit involved visual examination with the aid of a dental explorer and intra-oral mirror. Two independent examiners carried out the clinical examination. Inter-examiner reliability was determined using a statistical method described by Cohen (1969).

At the end of the first, second and third year, respectively 120, 112 and 108 restorations were evaluated by the same examiners. All the teeth were tested for vitality and evaluated clinically at each time point, with attention to marginal integrity, presence/absence of post-operative sensitivity, staining of the dental structure, partial or total loss of the restoration and secondary caries.

At the end of the third year, the photographic records of the restorations were used to evaluate the marginal degradation over that period, using the sequential method proposed (Osborne & others, 1976; Osborne, Binon & Gale, 1980a, Osborne & others, 1980b). Figures 1b, 2b, 3b and 4b show the restorations depicted in Figures 1a, 2a, 3a and 4a, respectively, at the three year recall visit.

As a calibration exercise, prior to the study, the examiners were given a series of photographs of archived amalgam restorations (n=186) that they ranked from best to worst based on the appearance of the restoration margins. The results of the photographic rankings were submitted to a Kruskal-Wallis test that showed no significant difference between the two examiners. The same two examiners then ranked the pictures from the main study from best to worst, and the same statistical analysis was used to determine difference among the four groups.

## RESULTS

### Baseline

At baseline, all the teeth were vital. Two teeth from Group 3 (adhesive) presented with subtle sensitivity upon biting. Occlusal interference was detected for these restorations, which was removed.

### Seven Days

At seven days, all the teeth responded positively to the vitality test and none presented spontaneous pain although two teeth in the adhesive resin group presented sensitivity to cold liquids. Participants in the adhesive resin group reported that the sensitivity was decreasing but it was bearable.

### One Year

At the end of the first year, all 120 restorations were reassessed clinically with the aid of photographic images. Not a single fracture was detected, no secondary caries and no stain in the dental structure was present. None of the teeth presented spontaneous pain or pain to cold liquids. All the teeth gave a positive response to the vitality test.

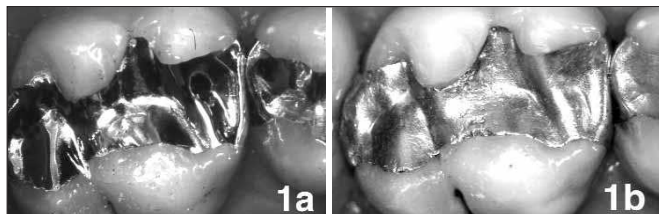


Figure 1. Representative clinical example of a restoration from Group 1 (cavity varnish) at baseline (a) and at the 3-year recall (b).

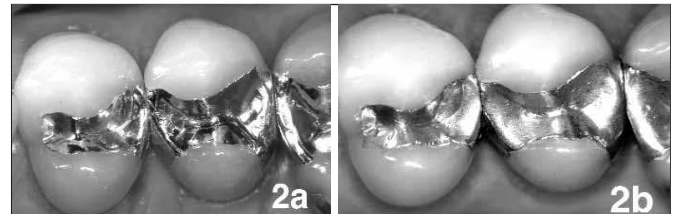


Figure 2. Representative clinical examples of restorations from Groups 2 (fluoride, #12) and 4 (control, #13) at baseline (a) and at the 3-year recall (b).

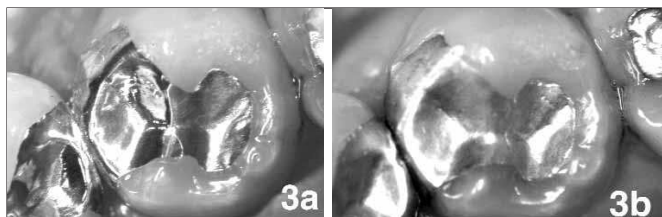


Figure 3. Representative clinical example of a restoration from Group 3 (adhesive resin) at baseline (a) and at the 3-year recall (b).

### Two Years

At the end of the second year, 112 restorations were re-evaluated clinically and the results were identical to those observed at the end of the first year. All the teeth responded positively to the vitality test. Two participants (eight restorations) missed this evaluation.

### Three Years

At the end of the third year, the results from the clinical examination of 108 restorations (three participants did not participate in the third-year evaluation) were identical to those observed at the end of the first and second years. None of the teeth presented spontaneous pain or pain to cold liquids and they all presented a positive response to the vitality test.

Examination of the restorations at three years revealed no statistically significant differences among the four groups regarding marginal integrity, staining of the dental structure, partial or total loss of the restoration and secondary caries regardless of the type of pulp protection technique used.

Inter-examiner reliability tests produced a Kappa score of 0.86, which showed excellent agreement (Cohen, 1969).

## DISCUSSION

The use of liners and bases under amalgam restorations has been common practice for many years and continues to be promoted in operative dentistry textbooks (Schwartz & Hilton, 2000; Bayne, Thompson & Taylor, 2001). Bases and liners are believed to provide protection against marginal leakage, affording the tooth pulp protection and post-operative comfort. Nevertheless, current concepts related to the use of liners and bases have been challenged (Hilton, 1996; Leinfelder, 1994; Weiner, Weiner & Kugel, 1996). As knowledge and understanding of the tooth and of dental biomaterials evolves, our approach to the clinical practice should be constantly revisited.

The results of this study indicate that the amalgam-tooth interface seals over time, resulting in low levels of post-operative sensitivity even without the use of a pulp-protecting material. These results agree with other studies (Osborne & others, 1980a; Piperno & others, 1982). Twenty years ago, both Osborne & others,

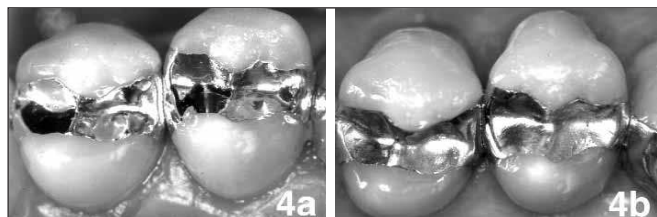


Figure 4. Representative clinical examples of restorations from Groups 3 (adhesive resin #12 and 4 (control #13) at baseline (a) and at the 3-year recall (b).

1980a and Piperno & others had already demonstrated in *in vivo* studies that using bases under amalgam restorations does not contribute to decreased post-operative sensitivity. They hypothesized that amalgams with greater plasticity can be more appropriately condensed and consequently better adapted to the walls and internal angles of the preparation, resulting in tighter margins when compared to regular amalgam alloys.

Previous studies have critically analyzed the use of liners under restorations (Owens, 1996; Pereira & others, 1990). These authors have demonstrated that materials such as calcium hydroxide have a short anti-bacterial effect. In addition, with time, the oral fluids can penetrate through a non-sealed tooth-restoration interface, dissolving partially or totally this pulp-protecting material. This would result in an increased gap at the tooth-restoration interface, increasing the risk of sensitivity and marginal leakage.

Irrespective of the type of pulp protection technique used, not one predisposed the restorations to a poor clinical performance with regard to recurrent caries. The relevance of this finding relates to the fact that recurrent (or secondary) caries is still regarded as the main reason for failure and replacement of amalgam restorations (Mjör & Toffenetti, 2000). Since the factors responsible for primary caries are also responsible for secondary caries, it is inappropriate to solely blame a material or any specific technique for the incidence of recurrent or secondary caries. Even though it was not under the scope of this study to establish the participants' caries risk, the overall caries risk of the sample in this study was considered moderate. It is well known that participants in clinical studies tend to improve their hygiene habits during the evaluation periods of the study. This might have influenced the zero incidences of secondary caries found at the three-year evaluation. Longer evaluation times for this sample may reveal different tendencies or significant differences among the experimental groups.

Poor marginal integrity is another frequently cited reason to replace restorations (Mjör, 1986; Mjör & Toffenetti, 2000). However, Barbakow & others (1988) have shown that 100% of amalgam restoration mar-

gins are defective six months after they are placed and therefore poor marginal integrity does not necessarily justify replacement of the restoration. Either periodic recall to monitor the restoration and/or the patient's caries risk or the repair of the margin is preferable to total replacement. The marginal defects that appear in the tooth-restoration interface are mechanically and ecologically similar to occlusal pit and fissure defects. Although occlusal pits and fissures are plaque accumulation sites (Mjör, 1986; Owens, 1996), it is possible to maintain these areas free of caries. The same should be true for ditched amalgam margins. Plaque control is as caries preventive in occlusal pits as it is in ditched margins, provided that these margins are accessible for cleaning (Cardoso, Baratieri & Ritter, 1999). In this study, the photographic evaluation was unable to find differences among the four groups as it relates to marginal degradation, regardless of the inherent marginal breakdown present in all restorations.

The potential advantages for using resin adhesives to bond amalgam to the dental structure are reduced microleakage, reduced incidence of postoperative sensitivity (Staninec & Holt, 1988), reduced marginal fracture (Tarim & others, 1996), increased fracture resistance of the prepared tooth (Eakle, Staninec & Lacy, 1992) and improved retention of the restorations with the potential for preservation of tooth structure during tooth preparation (Staninec, 1989). Although these advantages have obvious merits, their validity still requires confirmation in the clinical setting. A number of concerns have been expressed regarding using adhesive systems in association with amalgam restorations. Recent *in vitro* reports (Boston, 1997; Charlton, Murchison & Moore, 1991; Mahler & Bryant, 1999) indicate that microleakage can be significantly reduced when an adhesive system is used under amalgam restoration in lieu of varnish or no liner. Yet, the same behavior cannot be duplicated *in vivo* when the gingival walls of the proximal box are located on enamel. It is possible that *in vitro* marginal leakage tests are not good predictors of clinical activity (Meiers & Turner, 1998).

This study demonstrated that in a three-year period the use of an adhesive system cannot be justified under typical tooth preparations for amalgam. No significant differences were observed among the restorations that did not receive any type of pulp protection technique and those that were bonded to the dental structure. Similar results were recently reported for another adhesive system (Mahler & Engle, 2000).

Some authors have suggested topical fluoride application under amalgam restorations to minimize the incidence of secondary caries (Alexander, McDonald & Stookey, 1969; Cooley & Barkmeier, 1979; Nixon, Hembree & McKnight, 1978; Peterzen & others, 1990;

Stufflebeam & others, 1997). An *in vitro* study (Marchiori & others, 1998) verified that fluoride significantly decreased the performance of amalgam restorations with respect to marginal leakage. In the topical fluoride group, 50% of enamel margins and 100% of dentin margins had maximum leakage scores. This study, however, did not reveal any negative aspects of the use of fluorides, neither was it capable of showing any superiority of that procedure.

Several clinical studies have indicated that the clinical behavior of amalgam restorations observed in the first year of activity is a good predictor of long-term results (Letzel & Vrijhoef, 1984a, 1984b; Mahler & Marantz, 1980; Mjör, 1986; Osborne & others, 1980a, 1980b). This study's results suggest that there are no advantages in the use any pulp protection technique under typical amalgam restorations. It must be emphasized, however, that all the restorations included in this study were replacements of old, failed amalgam restorations. The clinical significance derived from these results might differ from a situation where primary caries is being restored, particularly when related to the physiological condition of the dentin substrates. Dentin can undergo a number of structural changes under restorations, including occlusion of the dentinal tubules, formation of reparative dentin, and more. All these changes can influence the response of the pulp-dentin complex to external stimuli. Hence, when restoring primary caries lesions, the influence of the type of pulp protection technique under amalgam restorations remains to be investigated.

## CONCLUSIONS

Based on the results of this study, it can be concluded that the type of pulp protection technique (cavity varnish, adhesive resin or fluoride application) might not influence the clinical performance of teeth restored with moderate sized replacement amalgam restorations after three years of clinical service.

(Received 16 October 2001)

## References

- Alexander WE, McDonald RE & Stookey GK (1969) Effectiveness of a stable 30 percent stannous fluoride solution in the prevention of recurrent dental caries *Journal Indiana Dental Association* **48** 175-179.
- Andrada MAC (1982) Estudo comparativo da infiltração marginal em ligas para amálgama enriquecidas ou não com cobre *Odontólogo Moderno* **9** 16-21.
- Barbakow F, Geberthuel T, Lutz F & Schupbach (1988) Maintenance of amalgam restorations *Quintessence International* **19** 861-870.
- Bayne SC, Thompson JY & Taylor DF (2001) Dental materials in Roberson TM, Heymann HO, Swift Jr EJ (ed), *Sturdevant's*

- Art and Science of Operative Dentistry, Fourth Edition*, Mosby St Louis 133-234.
- Boston DW (1997) Adhesive liner incorporation in dental amalgam restorations *Quintessence International* **28** 49-55.
- Cardoso M, Baratieri LN & Ritter AV (1999) The effect of finishing and polishing on the decision to replace existing amalgam restorations *Quintessence International* **30** 413-418.
- Charlton DG, Murchison DF & Moore BK (1991) Incorporation of adhesive liners in amalgam: Effect on compressive strength and creep *American Journal of Dentistry* **4** 184-188.
- Cohen J (1969) A coefficient of agreement for nominal scales *Education Psychology Measurement* **20** 37-46.
- Cooley RL & Barkmeier WW (1979) Reducing recurrent caries with topical stannous fluoride treatment of cavity preparations *General Dentistry* **27** 30-33.
- Eakle WS, Staninec M & Lacy AM (1992) Effect of bonded amalgam on the fracture resistance of teeth *Journal of Prosthetic Dentistry* **68** 257-260.
- Fitchie JG, Reeves GW, Scarbrough AR & Hembree JH (1990) Microleakage of a new cavity varnish with a high-copper spherical amalgam alloy *Operative Dentistry* **15** 136-140.
- Gwinnett AJ, Baratieri LN, Monteiro S Jr & Ritter AV (1994) Adhesive restorations with amalgam: Guidelines for the clinician *Quintessence International* **25** 687-695.
- Hilton TJ (1996) Cavity sealers, liners, and bases: Current philosophies and indications for use *Operative Dentistry* **21** 134-146.
- Leinfelder KF (1994) Changing restorative traditions: The use of bases and liners *Journal of the American Dental Association* **125** 65-67.
- Letzel H & Vrijhoef MM (1984a) Long-term influences on marginal fracture of amalgam restorations *Journal Oral Rehabilitation* **11** 95-101.
- Letzel H & Vrijhoef MM (1984b) The influence of polishing on the marginal integrity of amalgam restorations *Journal of Oral Rehabilitation* **11** 89-94.
- Mahler DB & Bryant R (1999) Amalgam bonding agents in tensile-shear mode *Journal of Dental Research* **78** Abstract #3410, pg 532.
- Mahler DB & Marantz RL (1980) Clinical assessments of dental amalgam restorations *International Dental Journal* **30** 327-334.
- Mahler DB & Engle JH (2000) Clinical evaluation of amalgam bonding in class I and II restorations *Journal of the American Dental Association* **131** 43-49.
- Manders CA, García-Godoy F & Barnwell GM (1990) Effect of a copal varnish, ZOE or glass ionomer cement bases on microleakage of amalgam restorations *American Journal of Dentistry* **3** 63-66.
- Marchiori S, Baratieri LN, de Andrada MA, Monteiro S Jr & Ritter AV (1998) The use of liners under amalgam restorations: An *in vitro* study on marginal leakage *Quintessence International* **29** 637-642.
- Mazer RB, Rehfeld R & Leinfelder KF (1988) Effect of cavity varnishes on microleakage of amalgam restorations *American Journal of Dentistry* **1** 205-208.
- McComb D, Ben-Amar A & Brown J (1990) Sealing efficacy of therapeutic varnishes used with silver amalgam restorations *Operative Dentistry* **15** 122-128.
- Meiers JC & Turner EW (1998) Microleakage of dentin/amalgam alloy bonding agents: Results after 1 year *Operative Dentistry* **23** 30-35.
- Mjör IA & Toffenetti F (2000) Secondary caries: A literature review with case reports *Quintessence International* **31** 165-179.
- Mjör IA (1986) Buonocore Memorial Lecture. Clinical assessments of amalgam restorations *Operative Dentistry* **11** 55-62.
- Murray GA, Yates JL & Williams JI (1983) Effect of four cavity varnishes and a fluoride solution on microleakage of dental amalgam restorations *Operative Dentistry* **8** 148-151.
- Newman SM (1984) Microleakage of A copal resin cavity varnish *Journal of Prosthetic Dentistry* **51** 499-502.
- Nixon RM, Hembree JH Jr & McKnight JP (1978) *In vitro* effectiveness of topical fluoride under amalgam restorations *Journal of Pedodontics* **2** 107-113.
- Osborne JW, Binon PP & Gale EN (1980a) Dental amalgam: Clinical behavior up to eight years *Operative Dentistry* **5** 24-28.
- Osborne JW, Leinfelder KF, Gale EN & Sluder TB (1980b) Two independent evaluations of ten amalgam alloys *Journal of Prosthetic Dentistry* **43** 622-626.
- Osborne JW, Phillips RW, Gale EN & Binon PP (1976) Three-year clinical comparison of three amalgam alloy types emphasizing an appraisal of evaluation methods used *Journal of the American Dental Association* **93** 784-789.
- Owens BN (1996) Initial placement and replacement of amalgam restoration: A respective review *Journal of the Tennessee Dental Association* **76** 37-39.
- Pereira JC, Manfio AP, Franco EB & Lopes ES (1990) Clinical evaluation of Dycal under amalgam restorations *American Journal of Dentistry* **3** 67-70.
- Peterzen RM, Shaner JW, Stoffers KW & Legan JJ (1990) Effect of stannous fluoride cavity wash on postoperative thermal sensitivity *General Dentistry* **38** 347-349.
- Piperno S, Barouch E, Hirsch SM & Kaim JM (1982) Thermal discomfort of teeth related of presence or absence of cement bases under amalgam restorations *Operative Dentistry* **7** 92-96.
- Schwartz RS & Hilton TJ (2000) Caries Management and Pulpal Considerations in Schwartz RS, Summit JB, Robbins WR (eds) *Fundamentals of Operative Dentistry. A Contemporary Approach 2<sup>nd</sup> ed* Quintessence Books Chicago 51-66.
- Staninec M (1989) Retention of amalgam restorations: Undercuts versus bonding *Quintessence International* **20** 347-351.
- Staninec MA & Holt M (1988) Bonding of amalgam to tooth structure: Tensile adhesion and microleakage test *Journal of Prosthetic Dentistry* **59** 397-402.
- Stufflebeam M, Donly KJ & García-Godoy F (1997) Topical fluoride caries inhibition before and after restoration placement *Journal of Dental Research* **76** Abstract #647 pg 94.
- Tarim B, Suzuki S, Suzuki S & Cox CF (1996) Marginal integrity of bonded amalgam restorations *American Journal of Dentistry* **9** 72-76.
- Weiner RS, Weiner LK & Kugel G (1996) Teaching the use of bases and liners. A survey of North American dental schools *Journal of the American Dental Association* **127** 1640-1645.