



Title	Measurement of Carotid Stenosis Using Duplex Ultrasonography with a Microconvex Array Transducer: A Validation with Cerebral Angiography
Author(s)	Tateishi, Yohei; Tsujino, Akira; Hamabe, Jumpei; Tasaki, Osamu; Morikawa, Minoru; Horie, Nobutaka; Hayashi, Kentaro; Nagata, Izumi
Citation	Journal of Stroke and Cerebrovascular Diseases, 22(8), pp.e360-e365; 2013
Issue Date	2013-11
URL	<a href="http://hdl.handle.net/10069/34341">http://hdl.handle.net/10069/34341</a>
Right	© 2013 Elsevier B.V. All rights reserved.; NOTICE: this is the author ' s version of a work that was accepted for publication in Journal of Stroke and Cerebrovascular Diseases. Changes resulting from the publishing process, such as peer review, editing, corrections, structural formatting, and other quality control mechanisms may not be reflected in this document. Changes may have been made to this work since it was submitted for publication. A definitive version was subsequently published in Journal of Stroke and Cerebrovascular Diseases, 22, 8, (2013)

This document is downloaded at: 2017-12-22T08:36:43Z

Measurement of Carotid Stenosis Using Duplex Ultrasonography with a  
Microconvex Array Transducer: A Validation with Cerebral Angiography

Yohei Tateishi, M.D.<sup>1</sup>, Akira Tsujino, M.D.<sup>1</sup>, Jumpei Hamabe, M.D.<sup>1</sup>, Osamu  
Tasaki, M.D.<sup>2</sup>, Minoru Morikawa, M.D.<sup>3</sup>, Nobutaka Horie, M.D.<sup>4</sup>, Kentaro  
Hayashi, M.D.<sup>4</sup>, Izumi Nagata, M.D.<sup>4</sup>

Cerebrovascular Center<sup>1</sup>, Emergency Medical Center<sup>2</sup>, Department of  
Radiology<sup>3</sup>, and Department of Neurosurgery<sup>4</sup>  
Nagasaki University Hospital

1-7-1 Sakamoto, Nagasaki City, Nagasaki, Japan 852-8501

Tel: (+81)95-819-7265, Fax: (+81)95-819-7265

Corresponding author: Yohei Tateishi

E-mail: ytate.com@gmail.com

There is no grant support.

**Short title:**

Measurement of carotid stenosis using duplex ultrasonography

Word count: 2269 words

## **Abstract**

**Background:** We aimed to evaluate the validity of duplex ultrasonography using a microconvex array transducer with enhanced flow imaging for visualization of the distal internal carotid artery and the accurate assessment of internal carotid artery stenosis.

**Methods:** Patients who underwent both duplex ultrasonography and digital subtraction angiography were registered for this study. Duplex ultrasonography was performed by using a linear array transducer and a microconvex array transducer with enhanced flow imaging. The visibility of the internal carotid artery was compared between the two transducers. Internal carotid artery stenosis was evaluated by the NASCET method on duplex ultrasonography, and the peak systolic flow velocity using a microconvex array transducer. These results were compared with digital subtraction angiography.

**Results:** In 238 internal carotid arteries, the average length of visualized internal carotid artery was longer for duplex ultrasonography using a microconvex array transducer than a linear array transducer ( $38.7 \pm 11.7$  mm versus  $25.8 \pm 9.8$  mm,  $p < 0.0001$ ). In 68 stenotic internal carotid arteries, the degree of internal carotid artery stenosis detected by the NASCET method on duplex ultrasonography was correlated to that on digital subtraction angiography ( $p < 0.0001$ ,  $r = 0.969$  and adjusted  $r^2 = 0.938$ ). Peak systolic flow velocity also correlated to NASCET method on digital subtraction angiography ( $p < 0.0001$ ,  $r = 0.804$ , and adjusted  $r^2 = 0.640$ ).

**Conclusions:** Duplex ultrasonography using a microconvex array transducer with enhanced flow imaging technology could reveal more extended distal views

of the internal carotid artery and was strongly correlated with NASCET method on digital subtraction angiography.

## **Introduction**

Internal carotid artery (ICA) stenosis is one of the most common causes of ischemic stroke. The NASCET has proven the benefit of carotid endarterectomy in patients with 70-99% symptomatic ICA stenosis.<sup>1, 2</sup> The degree of ICA stenosis, as assessed by the NASCET method, is based on digital subtraction angiography (DSA), which is one of methods to select patients for carotid endarterectomy. However, DSA is an invasive, risky, and expensive procedure.<sup>3-5</sup> New asymptomatic ischemic lesions were frequently documented on diffusion-weighted imaging in acute stroke patients after DSA.<sup>6</sup> The rate of permanent neurological complications was from 0 to 0.5%, and the rate of transient neurological complications was between 0.4% and 0.9%.<sup>7-10</sup> Furthermore, DSA has a potential to develop non-neurological complications, such as hematoma at groin site, sheath-related complication and contrast reaction.<sup>10</sup> Duplex ultrasonography (DUS) is a non-invasive and easy screening procedure for the evaluation of ICA stenosis and is widely used to select patients for DSA. Although elevation of the ICA peak systolic flow velocity (PSV) is preferred when the necessity of carotid endarterectomy must be predicted, there are various cut-off values to identify 70% stenosis with the NASCET method.<sup>11-18</sup> A conventional linear array transducer (LAT) has a flat head with a high ultrasound frequency (> 7 MHz) and an ability to clearly and closely visualize detailed findings, such as hypoechoic plaques and plaque ulcerations in the carotid artery, from the broad surface of the neck. However, this approach sometimes has difficulty to achieve an appropriate ultrasonic view of the distal ICA, which is a denominator used in the NASCET measurement, especially in

patients with high carotid artery bifurcation and a very short neck.<sup>19</sup> Therefore, to evaluate carotid stenosis accurately, further improvement of DUS technology is desirable.

A microconvex array transducer (MAT) with a small and rounded head, and a relatively high ultrasound frequency would be suitable to clearly visualize deep structures through various angles on the small surface of the neck.<sup>20</sup> Furthermore, the enhanced flow imaging (EFI) utilized in the present study is a novel technology developed by Aloka Co. Ltd. (Tokyo, Japan) for the imaging of blood flow dynamics. Unlike traditional color Doppler methods, it provides high spatial and temporal resolution by applying a composite pulse emission technique (allowing a shorter pulse length) to better illustrate capillary perfusion and blood flow continuity.<sup>21</sup>

The aim of this study was to validate the utility of DUS using a MAT with EFI technology for the accurate assessment of ICA stenosis by the NASCET method.

## **Method**

Between May 1, 2009 and April 30, 2011, we performed DUS in 126 patients within 48 hours before or after DSA. Patients were excluded from this study in the following cases: (1) ICA occlusion was observed, or (2) ICA stenosis was unobservable due to acoustic shadow from a massive hyperechoic plaque.

### *Clinical background*

The following information about patient history and medication were obtained: gender and age; vascular risk factors (hypertension, diabetes mellitus,

hyperlipidemia, and smoking); and, atrial fibrillation. Vascular risk factors were identified as follows: (1) hypertension: use of antihypertensive agents, systolic blood pressure of  $\geq 140$  mmHg or diastolic blood pressure of  $\geq 90$  mmHg; (2) diabetes mellitus: use of oral hypoglycemic agents, insulin, or glycosylated hemoglobin of  $\geq 6.5\%$ ; (3) hyperlipidemia: use of antihyperlipidemic agents or serum cholesterol levels of  $> 220$  mg/dL; and, (4) currently smoking or any past history of cigarette use. DSA was performed on patients with ICA stenosis, cerebral artery aneurysms, brain tumors, obstructive lesions of intra- or extra-cranial cerebral arteries, arterial-venous fistulas, and spontaneous occlusion of the circle of Willis (Moyamoya disease).

#### *Ultrasound*

We performed DUS using an ultrasound unit (ProSound  $\alpha 10$ , ALOKA, Tokyo, Japan) with a multifrequency MAT (4-10 MHz) and a LAT (4-13 MHz). The pulse repetition frequency was adjusted to 4.34 KHz, and the cut-off of the wall filter was 88.97 Hz. All sonographic examinations were performed while patients were lying in the supine position, with the head turned away from the evaluation side and the neck extended. The color gain was adequately adjusted to avoid artifacts. All images were obtained by two experienced sonographers, who were blinded to the results of DSA. One sonographer performed ultrasonographic scan of the ICA using a LAT with EFI. Then, the other sonographer, who was blinded to the results obtained with a LAT, used the MAT to visualize the ICA. The lengths of the ICA between the region of origin of ICA and its distal limit of visualization were measured and compared between the DUS method using a LAT and the DUS method using a MAT. A 3.5-mm range-gated and pulsed

Doppler sample size was set with an appropriate angle (< 60 degree) between the Doppler beam and the ICA. If ICA stenosis existed, we measured short axis diameters of the stenotic lesion seeking the view which the most stenotic lesion could be identified with multi-angle insonation, and those of the healthy distal ICA by using a MAT. We also evaluated the intrastenotic PSV. These measurements were obtained on DUS, which detected the blood flow by EFI, and we adjusted the measurements to be free from artifacts. We calculated the NASCET-style stenosis measurements using the results of DUS (NASCET-DUS).

#### *Digital subtraction angiography*

An experienced neuroradiologist (M.M.) performed all angiographic procedures using DSA equipment (SIEMENS, AXIOM Artis dBA, Munich, Germany). Informed consent was obtained from each patient or his/her family. The right transfemoral or transbrachial approach was selected in accordance with the Seldinger method. Standard four-vessel studies, including the bilateral carotid and vertebral arteries, were performed. The neuroradiologist, who was unaware of the result of the DUS, calculated the degree of stenosis using the NASCET method (NASCET-DSA).

#### *Analysis*

The longitudinal length of the ICA and the intrastenotic PSV were expressed as the mean  $\pm$  standard deviation (SD). Pearson's correlation coefficient was used to prove linear correlations between the NASCET-DUS or PSV and NASCET-DSA. When we evaluated the relationship between NASCET-DSA and intrastenotic PSV in the ICA, we excluded ICAs with slow flow related to near-



occlusion. To obtain threshold values for predicting ICA stenosis greater than 70%, we conducted a sensitivity-specificity analysis on NASCET-DUS and PSV. We also calculated the positive predictive value (PPV), negative predictive value (NPV), and determined the accuracy when we used threshold values of NASCET-DUS and PSV in order to diagnose ICA stenosis. Statistical significance was assumed at  $p < 0.05$ .

### **Results**

One hundred and twenty-six patients underwent DUS and DSA. Fourteen ICAs, including 13 occluded and one undetectable ICA due to a massive hyperechoic plaque, were excluded and the remaining 238 ICAs from 126 patients (84 men and 42 women, mean age of  $62 \pm 7$  years) were analyzed. Table shows the backgrounds of the patients in the present study and includes gender, age, vascular risk factors, and past illnesses. The main diagnoses from the DSA studies were ICA stenosis ( $n=62$ , 49%), aneurysms ( $n=24$ , 19%), brain tumors ( $n=12$ , 10%), arterial-venous malformations ( $n=7$ , 6%), middle cerebral artery lesions ( $n=7$ , 6%), arterial-venous fistulas ( $n=5$ , 4%), Moyamoya disease ( $n=5$ , 4%), vertebral artery lesions ( $n=3$ , 2%), ICA occlusion ( $n=1$ , 1%), and common carotid artery occlusion ( $n=1$ , 1%).

For the 238 ICAs that we were able to observe without hindrance, we evaluated the validity of the MAT combined with EFI technology. As shown in Figure 1, which depicts one patient with severe stenosis, DUS using a MAT combined with EFI clearly visualized both the distal and the stenotic portions in the vessel lumen of the ICA. In terms of visibility of the ICA, the average lengths

between the distal limit and the origin of the visualized ICA were longer on DUS using a MAT than on DUS using a LAT ( $38.7 \pm 11.7$  mm versus  $25.8 \pm 9.8$  mm,  $p < 0.0001$ ) (Figure 2).

For 68 stenotic ICAs from 238 ICAs total, the intrastenotic PSV in the ICA and the NASCET-DUS were obtained. Figures 3 and 4 show a Bland-Altman plot and a regression equation between the NASCET-DSA and NASCET-DUS. There was a significant correlation between NASCET-DSA and NASCET-DUS ( $p < 0.0001$ ,  $r = 0.969$ , and adjusted  $r^2 = 0.938$ ). Angle correction between ultrasound insonation and the flow direction of the ICA was  $54 \pm 7$  degrees. The correlation coefficient between NASCET-DSA and intrastenotic PSV was analyzed except for three ICAs with slow flow velocity in combination with near-occlusion (Figure 5). The findings from DSA included narrowing of the distal lumen of the ICA and delayed internal carotid filling as compared with external carotid branch filling. PSVs were determined to be 16 cm/sec, 36 cm/sec, and 38 cm/sec. There was a significant correlation between NASCET-DSA and intrastenotic PSV ( $p < 0.0001$ ,  $r = 0.804$ , and adjusted  $r^2 = 0.640$ ).

In the sensitivity-specificity analysis, optimal threshold values of NASCET-DUS and intrastenotic PSV for predicting ICA stenosis greater than 70%, as detected by NASCET-DSA, were 68% and 290 cm/sec, respectively. NASCET-DUS had a sensitivity of 88%, specificity of 91%, PPV of 81%, NPV of 91%, and an accuracy of 90%. Intrastenotic PSV had a sensitivity of 80%, specificity of 72%, PPV of 63%, NPV of 63%, and an accuracy of 74%.

## ***Discussion***

The present study demonstrated that using DUS with a MAT could achieve improved visualization of the distal ICA compared with using a conventional LAT. The evaluation of ICA stenosis by the NASCET method on DUS using a MAT was significantly comparable to that of NASCET-DSA.

NASCET-DUS with EFI was a useful method for the assessment of ICA stenosis. DUS with a LAT, may overestimate for the denominator of the NASCET measurement when the distal artery measurement is taken within the carotid bulb or post-stenotic dilatation.<sup>22</sup> Utilization of a MAT could sufficiently visualize the distal ICA to calculate the NASCET measurement. Visualization of the distal ICA is improved by using a 3.5 MHz convex array transducer because of prominent characteristics, such as a powerful ultrasound emission and a rounded surface.<sup>23</sup> However, the 3.5 MHz convex array transducer is not suitable for detailed evaluation of the common carotid artery, the bifurcation, and the ICA because of coarse imaging resulting from its lower ultrasonic frequency. In contrast, DUS using a 7.5 MHz LAT provides detailed and precise imaging of said vessels due to the high resolution.<sup>24, 25</sup> The 4-10 MHz MAT has a rounded surface, which is one characteristic of a convex array transducer, and a relatively high ultrasonic frequency, which is comparable to the LAT used routinely in clinical practice. Therefore, we considered that the 4-10 MHz MAT was also suitable for the evaluation of the ICA. Clevert et al. reported that B-flow, which is quite similar technology to the EFI utilized in the present study, provided better ultrasonographic diagnosis of ICA stenosis as compared with color Doppler flow imaging and power Doppler imaging as a result of negligible pulsation and blooming artifacts.<sup>26</sup> Some studies have demonstrated a good

correlation between the NASCET measurement by B-flow and by DSA.<sup>27, 28</sup> Similar to B-flow, EFI is able to visualize blood flow with improved spatial and temporal resolution by applying a composite pulse emission technique.

In the present study, excluding three patients with near-occlusion of ICAs, the correlation coefficient between NASCET-DSA and intrastenotic PSV was 0.804 ( $p < 0.0001$ ). A significant correlation between intrastenotic PSV and NASCET-DSA has been reported.<sup>11-14</sup> Koga et al. reported that the correlation coefficient between the NASCET-DSA and intrastenotic PSV was 0.84 ( $p < 0.0001$ ).<sup>11</sup> The result of our study is in accordance with this report. The cut-off PSV for ICA stenosis greater than 70%, as determined by NASCET-DSA, was 290 cm/sec in this study. The Society of Radiologists in Ultrasound has recommended a cut-off PSV for the ICA of  $\geq 125$  cm/sec and  $\geq 230$  cm/sec to predict angiographic ( $> 50\%$  and  $> 70\%$ ) ICA stenosis, respectively.<sup>16</sup> However, numerous optimal threshold values of velocity criteria for diagnosis of ICA stenosis greater than 70% have been published.<sup>11-15, 17, 18</sup> One reason for such discrepancy may be related to the variability between studies, laboratories, and operators.<sup>16, 29-31</sup> Moreover, Schreuder et al demonstrated an age-dependent decline in blood flow velocities in the carotid arteries.<sup>32</sup> This may result in an underestimation of the degree of ICA stenosis in elderly. Using the European Carotid Surgery Trial (ECST) method, the optimal PSV cut-off values for the diagnosis of ICA stenosis greater than 80% differed substantially (210 and 320 cm/s) between the two considered angle ranges (0-49 degrees and 50-62 degrees).<sup>33</sup> In our study, the angle correction was relatively high. Therefore, the optimal PSV cutoff value may be higher than that in previous studies.

Near-occlusion, which was identified on DSA as having a delayed internal carotid filling compared with external carotid artery branch filling and a reduced distal lumen and/or intracranial collateral vessels, was tentatively fixed at 95% carotid stenosis.<sup>34</sup> In this study, the neuroradiologist was unaware of the findings of DUS examination before DSA, and the sonographers were blinded to the result of DSA. Although near-occlusion could be easily identified by DSA, it could not be confirmed on DUS. Therefore, we included patients who had near-occlusion when we compared NASCET measurements between DUS and DSA.

We encountered some limitations. The diameter of the severe stenotic lesion can be established by means of various ultrasound method considering different position and special anatomical situation, such as a short neck and high position of the carotid bifurcation. Consequently, it depends on skills of the investigator. We were unable to visualize the vascular lumen of one patient due to the massive hyperechoic plaque.

### ***Conclusions***

DUS using a MAT improved the visualization of the distal ICA compared with a LAT. Using a MAT, the measurement of ICA stenosis by NASCET-DUS was comparable to NASCET-DSA measurements. Consequently, the NASCET-DUS method including a MAT may serve as a substitute for NASCET-DSA measurements if patients have contraindications for other appraisal methods.

- 1 Barnett HJ, Taylor DW, Eliasziw M, et al. Benefit of carotid endarterectomy in patients with symptomatic moderate or severe stenosis. North American Symptomatic Carotid Endarterectomy Trial Collaborators. *N Engl J Med.* 1998;339:1415-25.
- 2 Randomised trial of endarterectomy for recently symptomatic carotid stenosis: final results of the MRC European Carotid Surgery Trial (ECST). *Lancet.* 1998;351:1379-87.
- 3 Davies KN, Humphrey PR. Complications of cerebral angiography in patients with symptomatic carotid territory ischaemia screened by carotid ultrasound. *J Neurol Neurosurg Psychiatry.* 1993;56:967-72.
- 4 Heiserman JE, Dean BL, Hodak JA, et al. Neurologic complications of cerebral angiography. *AJNR Am J Neuroradiol.* 1994;15:1401-7; discussion 8-11.
- 5 Cloft HJ, Lynn MJ, Feldmann E, et al. Risk of cerebral angiography in patients with symptomatic intracranial atherosclerotic stenosis. *Cerebrovasc Dis.* 2011;31:588-91.
- 6 Shibazaki K, Iguchi Y, Kimura K, et al. New asymptomatic ischemic lesions on diffusion-weighted imaging after cerebral angiography. *J Neurol Sci.* 2008;266:150-5.
- 7 Willinsky RA, Taylor SM, TerBrugge K, et al. Neurologic complications of cerebral angiography: prospective analysis of 2,899 procedures and review of the literature. *Radiology.* 2003;227:522-8.
- 8 Johnston DC, Chapman KM, Goldstein LB. Low rate of complications of cerebral angiography in routine clinical practice. *Neurology.* 2001;57:2012-4.

- 9 Berczi V, Randall M, Balamurugan R, et al. Safety of arch aortography for assessment of carotid arteries. *Eur J Vasc Endovasc Surg.* 2006;31:3-7.
- 10 Thiex R, Norbash AM, Frerichs KU. The safety of dedicated-team catheter-based diagnostic cerebral angiography in the era of advanced noninvasive imaging. *AJNR Am J Neuroradiol.* 2010;31:230-4.
- 11 Koga M, Kimura K, Minematsu K, et al. Diagnosis of internal carotid artery stenosis greater than 70% with power Doppler duplex sonography. *AJNR Am J Neuroradiol.* 2001;22:413-7.
- 12 Hood DB, Mattos MA, Mansour A, et al. Prospective evaluation of new duplex criteria to identify 70% internal carotid artery stenosis. *J Vasc Surg.* 1996;23:254-61; discussion 61-2.
- 13 Moneta GL, Edwards JM, Chitwood RW, et al. Correlation of North American Symptomatic Carotid Endarterectomy Trial (NASCET) angiographic definition of 70% to 99% internal carotid artery stenosis with duplex scanning. *J Vasc Surg.* 1993;17:152-7; discussion 7-9.
- 14 Neale ML, Chambers JL, Kelly AT, et al. Reappraisal of duplex criteria to assess significant carotid stenosis with special reference to reports from the North American Symptomatic Carotid Endarterectomy Trial and the European Carotid Surgery Trial. *J Vasc Surg.* 1994;20:642-9.
- 15 Shaalan WE, Wahlgren CM, Desai T, et al. Reappraisal of velocity criteria for carotid bulb/internal carotid artery stenosis utilizing high-resolution B-mode ultrasound validated with computed tomography angiography. *J Vasc Surg.* 2008;48:104-12; discussion 12-3.

- 16 Grant EG, Benson CB, Moneta GL, et al. Carotid artery stenosis: gray-scale and Doppler US diagnosis--Society of Radiologists in Ultrasound Consensus Conference. *Radiology*. 2003;229:340-6.
- 17 AbuRahma AF, Robinson PA, Strickler DL, et al. Proposed new duplex classification for threshold stenoses used in various symptomatic and asymptomatic carotid endarterectomy trials. *Ann Vasc Surg*. 1998;12:349-58.
- 18 Jahromi AS, Cina CS, Liu Y, et al. Sensitivity and specificity of color duplex ultrasound measurement in the estimation of internal carotid artery stenosis: a systematic review and meta-analysis. *J Vasc Surg*. 2005;41:962-72.
- 19 Tegeler CH. Ultrasound and cerebral vascular disease In. In: Toole JF, ed. *Cerebrovascular disorder*. Philadelphia, Pa: Lippincott Williams & Wilkins; 1999:83-128.
- 20 von Sarnowski B, Khaw AV, Kessler C, et al. Evaluation of a microconvex array transducer for the ultrasonographic examination of the intrathoracic segments of the supraaortic arteries. *J Neuroimaging*. 2010;20:246-50.
- 21 Dong FQ, Zhang YH, Li ZA, et al. Evaluation of normal fetal pulmonary veins from the early second trimester by enhanced-flow (e-flow) echocardiography. *Ultrasound Obstet Gynecol*. 2011.
- 22 Rotstein AH, Gibson RN, King PM. Direct B-mode NASCET-style stenosis measurement and Doppler ultrasound as parameters for assessment of internal carotid artery stenosis. *Australas Radiol*. 2002;46:52-6.
- 23 Todo K, Watanabe M, Fukunaga R, et al. Imaging of distal internal carotid artery by ultrasonography with a 3.5-MHz convex probe. *Stroke*. 2002;33:1792-4.



- 24 Gaul JJ, Marks SJ, Weinberger J. Visual disturbance and carotid artery disease. 500 symptomatic patients studied by non-invasive carotid artery testing including B-mode ultrasonography. *Stroke*. 1986;17:393-8.
- 25 Pignoli P, Tremoli E, Poli A, et al. Intimal plus medial thickness of the arterial wall: a direct measurement with ultrasound imaging. *Circulation*. 1986;74:1399-406.
- 26 Clevert DA, Johnson T, Jung EM, et al. Color Doppler, power Doppler and B-flow ultrasound in the assessment of ICA stenosis: Comparison with 64-MD-CT angiography. *Eur Radiol*. 2007;17:2149-59.
- 27 Yurdakul M, Tola M, Cumhuri T. B-flow imaging of internal carotid artery stenosis: Comparison with power Doppler imaging and digital subtraction angiography. *J Clin Ultrasound*. 2004;32:243-8.
- 28 Yurdakul M, Tola M, Cumhuri T. B-flow imaging for assessment of 70% to 99% internal carotid artery stenosis based on residual lumen diameter. *J Ultrasound Med*. 2006;25:211-5.
- 29 Kuntz KM, Polak JF, Whittemore AD, et al. Duplex ultrasound criteria for the identification of carotid stenosis should be laboratory specific. *Stroke*. 1997;28:597-602.
- 30 Mead GE, Lewis SC, Wardlaw JM. Variability in Doppler ultrasound influences referral of patients for carotid surgery. *Eur J Ultrasound*. 2000;12:137-43.
- 31 Corriveau MM, Johnston KW. Interobserver variability of carotid Doppler peak velocity measurements among technologists in an ICAVL-accredited vascular laboratory. *J Vasc Surg*. 2004;39:735-41.

- 32 Schreuder FH, Mess WH, Hoeks AP. Ageing affects the accuracy of duplex ultrasonography in grading carotid artery stenosis. *Cerebrovasc Dis.* 2009;27:75-83.
- 33 Jogestrand T, Lindqvist M, Nowak J. Diagnostic performance of duplex ultrasonography in the detection of high grade internal carotid artery stenosis. *Eur J Vasc Endovasc Surg.* 2002;23:510-8.
- 34 Eliasziw M, Smith RF, Singh N, et al. Further comments on the measurement of carotid stenosis from angiograms. North American Symptomatic Carotid Endarterectomy Trial (NASCET) Group. *Stroke.* 1994;25:2445-9.

Table: Characteristics

		n = 126	
Age	mean (SD)	62	(7)
Male	n (%)	84	(67)
Risk factors	n (%)		
Hypertension		65	(52)
Diabetes mellitus		20	(16)
Hyperlipidemia		38	(30)
Atrial fibrillation		2	(2)
Smoking		31	(25)
Diagnosis	n (%)		
Internal carotid artery stenosis		62	(49)
Aneurysm		24	(19)
Brain tumor		12	(10)
Arterial venous malformation		7	(6)
Middle cerebral artery lesion		7	(6)
Arterial venous fistura		5	(4)
Moyamoya disease		5	(4)
Vertebral artery lesion		3	(2)
Internal carotid artery occlusion		1	(1)
Common carotid artery occlusion		1	(1)

Figure 1: A representative case of internal carotid artery stenosis in a 59-year-old man. (A) Common carotid arteriography shows 80% stenosis in the proximal portion of the internal carotid artery as determined by the NASCET method. (B) and (C) presents duplex ultrasonography using a microconvex array transducer. The degree of stenosis according to the NASCET method is 76%.

Figure 2: Scattergrams. The lengths of visualized internal carotid arteries are  $25.8 \pm 9.8$  mm on duplex ultrasonography using a linear array transducer and  $38.7 \pm 11.7$  mm on duplex ultrasonography using a microconvex array transducer ( $p < 0.0001$ ).

Figure 3: NASCET-DUS and NASCET-DSA compared in a Bland-Altman plot. The mean difference is 2.4% within the limit of agreement at +11.0 and -8.6%.

Figure 4: Scatter plot of the correlation between NASCET-DUS and NASCET-DSA ( $p < 0.0001$ ,  $r = 0.969$ , and adjusted  $r^2 = 0.938$ ).

Figure 5: Scatter plot of the correlation between PSV and NASCET-DSA. Three outliers are excluded because of slow flow velocity due to near-occlusion ( $p < 0.0001$ ,  $r = 0.804$ , and adjusted  $r^2 = 0.640$ ).

Figure 1

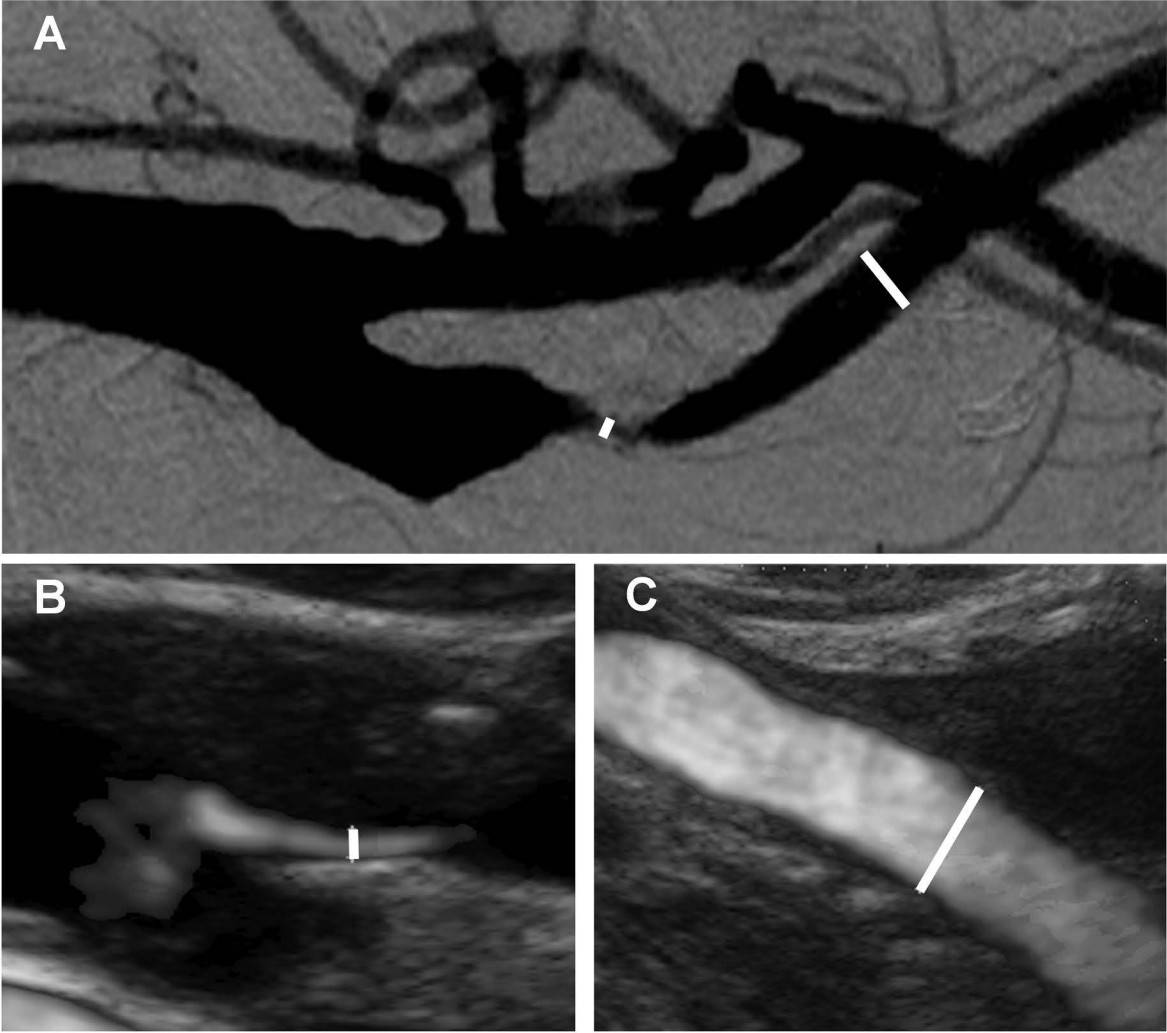


Figure 2

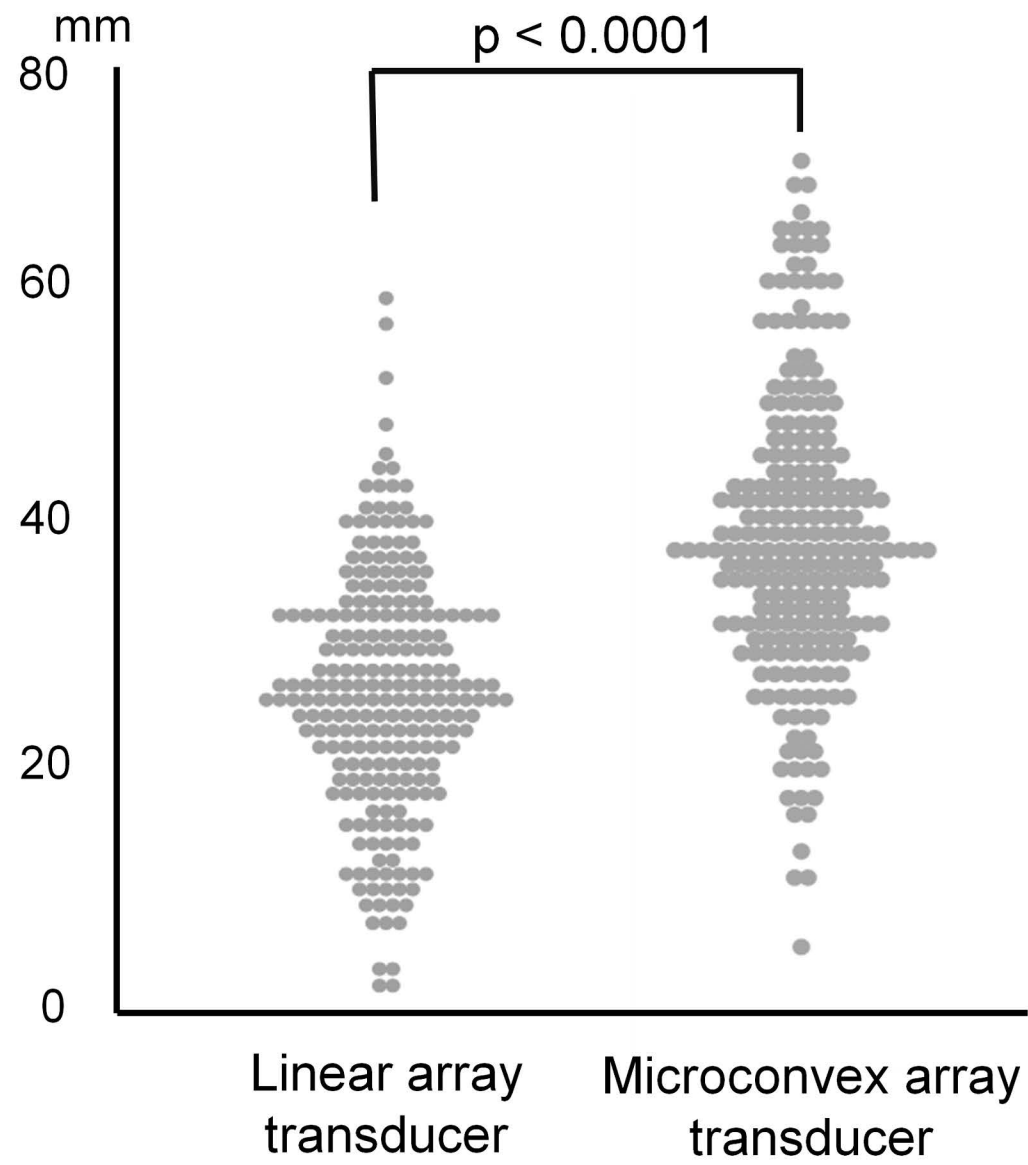


Figure 3

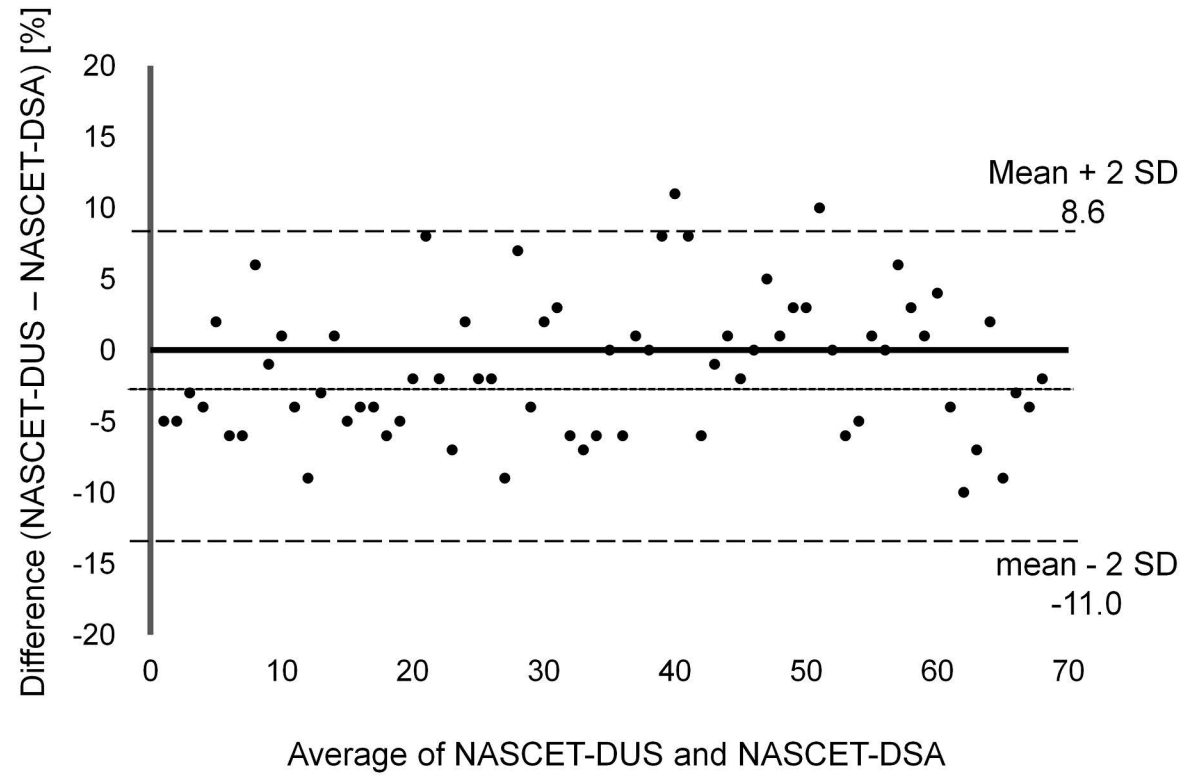


Figure 4

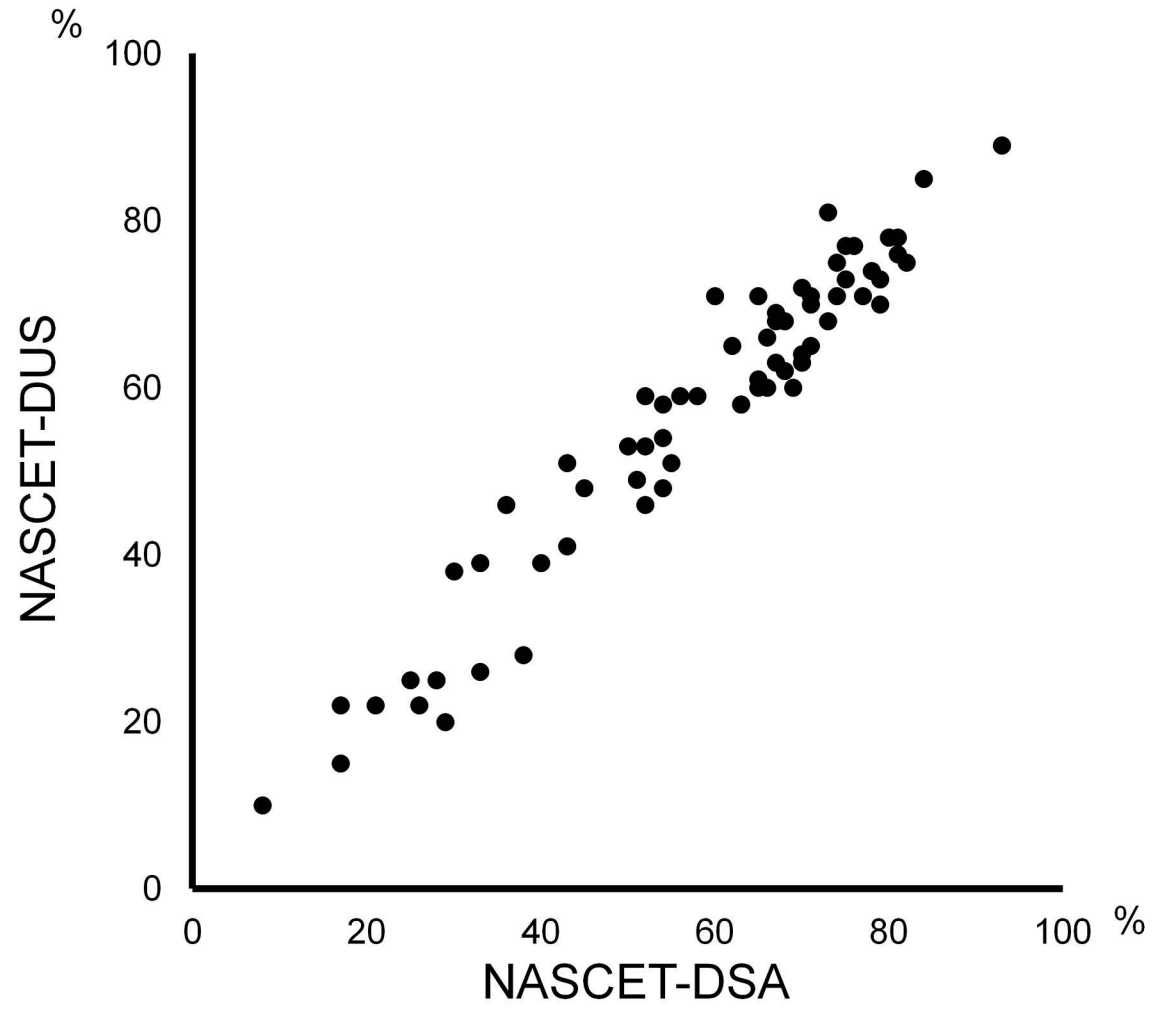




Figure 5

