

## Intravenous itraconazole for treating invasive pulmonary aspergillosis in neutropenic patients with acute lymphoblastic leukemia

**Aspergillus infection is associated with a high mortality rate in immunocompromised hosts; more effective drugs for this infection are needed. Oral itraconazole has been studied in neutropenic fungus-infected patients. Using a novel formulation (intravenous) of itraconazole, we successfully treated severe necrotizing pneumonias due to Aspergillus species occurring during a post-chemotherapy prolonged aplastic phase in two patients with acute lymphoblastic leukemia.**

Haematologica 2007; 88:(1):e8-e9

Invasive pulmonary aspergillosis is an emerging complication in patients with acute leukemia. Its increasing incidence has been dramatically documented in the last decade, in both ante- and post-mortem studies.<sup>1,2</sup> The overall response rates to conventional amphotericin B (cAMB) is unsatisfactory, ranging between 35% and 45%; long-term therapy is badly tolerated owing to nephro- and infusion-related toxicity.<sup>3</sup> More effective and less toxic drugs for this infection are needed. We report the use of i.v. itraconazole for the treatment of invasive pulmonary aspergillosis in two patients who had undergone intensive chemotherapy for acute lymphoblastic leukemia (ALL) and were subsequently included in an international phase IV study (Protocol ITR-INT-92; Sporanox IV, Janssen Pharmaceutica, Beerse, Belgium).

### Case report #1

Ph-positive ALL-L2 was diagnosed in a 39-year old woman in November 1999. She proved to be resistant to 2 induction courses, and no bone marrow donor was available. In June 2000, she received additional chemotherapy (cytarabine 11 gr daily for 4 days and idarubicin 22 mg daily for 3 days). Antimicrobial prophylaxis with ciprofloxacin and fluconazole was given. After 10 days of severe neutropenia, she started having high fever followed by chest pain, cough, dyspnea, and moderate hypoxia, and received broad-spectrum antibiotics. A week later the persistence of symptoms and the appearance of pulmonary infiltrates (Figure 1A) led to antifungal treatment with i.v. cAMB 1.5 mg/Kg/day and G-CSF 5 µg/Kg/day. After 10 days, cAMB was stopped because of persisting symptoms and onset of refractory severe hypokalemia. Intravenous itraconazole was started at 400 mg daily on the first 2 days, followed by 200 mg daily for 12 days. The clinical course rapidly improved with symptom regression, although recovery from neutropenia occurred 2 weeks later. A second course of i.v. itraconazole (compassionate use) was given (same dosage and duration), for persisting pulmonary infiltrates (Figure 1B). In September 2000, the patient was discharged in complete hematological and cytogenetic remission from ALL; itraconazole was continued orally (5 mg/Kg twice a day). A month later, she underwent surgical curettage of a peripheral residual nodule: pathologic examination and culture of the surgical section documented *Aspergillus fumigatus* infection. In January 2001 a course of consolidation chemotherapy was given, but the patient died of leukemia relapse resistant to salvage chemotherapy in June 2001; neither signs nor symptoms of pulmonary infection recurred after consolidation and salvage treatments.

### Case report #2

In July 2000 a 43-year-old woman with ALL-L1 was admitted for induction chemotherapy including L-asparaginase, vincristine, daunorubicin and prednisone (GIMEMA 0496 Protocol). Standard antimicrobial prophylaxis was given. After 10 days of moderate neutropenia, she started having high fever followed by chest pain, cough, dyspnea and moderate hypoxia, and received meropenem 3 gr daily, amikacin 1 gr daily and teicoplanin 400 mg daily. A week later, the persistence of symptoms and the appearance of pulmonary infiltrates (Figure 1C) prompted antifungal treatment (i.v. itraconazole 400 mg daily for 2 days, followed by 200 mg daily for 12 days). After starting itraconazole the clinical course rapidly improved with symptom regression. No pathogens were found in the culture of bronchoalveolar lavage. Two weeks later recovery from neutropenia occurred and the patient was discharged. Itraconazole was continued orally (5 mg/Kg twice a day) for persisting pulmonary infiltrates, likely due to *Aspergillus* species (Figure 1D). A few months later a CT-scan found no pulmonary infiltrates. She underwent consolidation and maintenance chemotherapy; neither signs nor symptoms of pulmonary infection recurred. The patient is in continuous complete hematological remission from ALL and off-therapy.

Only a few drugs are effective for treating invasive pulmonary aspergillosis, including conventional and lipid-based AMB, itraconazole, and, more recently, voriconazole and caspofungin.<sup>4,5</sup> Few data are available on the use of i.v. itraconazole for invasive pulmonary aspergillosis in immunocompromised hosts.<sup>6</sup> Our patients had a proven (case #1) or possible (case #2) invasive pulmonary aspergillosis;<sup>7,8</sup> within the frame of a trial on the use of i.v. itraconazole in invasive fungal infec-

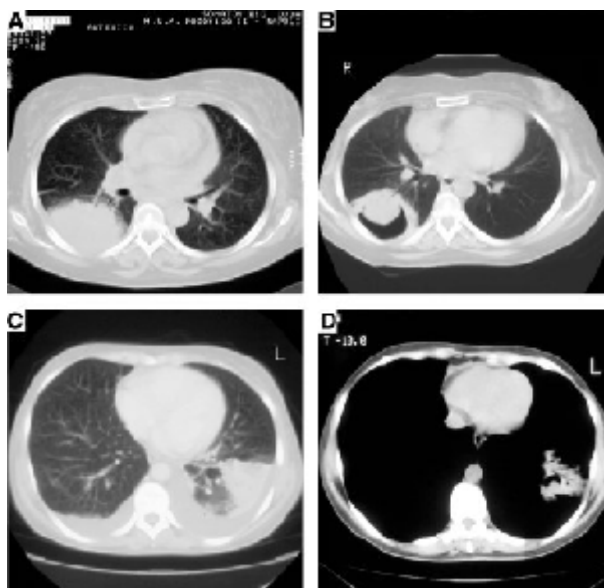


Figure 1. Changing characteristics of invasive pulmonary aspergillosis on computed tomography scans. (A) Subpleural large parenchymal masses with a surrounding halo of ground-glass attenuation (halo sign), in the right lung; a small nodular lesion in the left lung. (B) Two weeks later, a fungus ball inside the right lesion. (C) Large triangular infiltrate in the left lung, and bilateral pleural effusion. (D) Two weeks later, cavitation described as the air-crescent sign inside the parenchymal lesion.

tions, this drug was introduced after informed consent as first-line treatment in case 2 and after failure of cAMB in case #1. During the following 2 weeks, even in the absence of neutrophil recovery, infectious symptoms completely disappeared in both cases. Complete disappearance of the pulmonary infection was achieved after switching to high-dose oral itraconazole (Sporanox Oral Solution),<sup>9</sup> combined with surgical curettage in one case. At the dose used, i.v. itraconazole did not show any side-effect or hematological toxicity. In conclusion, this drug proved to be effective and well tolerated for the management of life-threatening invasive pulmonary aspergillosis. These observations warrant further investigations of i.v. itraconazole use in neutropenic patients with acute leukemia and Aspergillus infection.

*M. Picardi, A. Camera, L. Luciano, R. Ciancia, B. Rotoli  
Division of Hematology, Federico II University Medical School,  
Naples, Italy*

*Supported in part from the Associazione Italiana contro le Leucemie  
(A.I.L.) Salerno, Italy. We wish to thank the Janssen Research  
Foundation for allowing compassionate use of intravenous itraconazole.*

*Correspondence: Prof. Bruno Rotoli, Divisione di Ematologia, Nuovo  
Policlinico, Via S. Pansini 5, 80131, Naples, Italy  
Tel. +390817462068 - Fax +390817462165*

## References

1. Pagano L, Girmenia C, Mele L, Ricci P, Tosti ME, Nosari A, et al. Infections caused by filamentous fungi in patients with hematologic malignancies. A report of 391 cases by GIMEMA Infection Program. *Haematologica* 2001; 86: 862-70.
2. Groll AH, Shah PM, Mentzel C, Schneider M, Just-Nuebling G, Huebner K. Trends in the post-mortem epidemiology of invasive fungal infections at a University Hospital. *J Infect* 1996; 33: 23-32.
3. Lin SJ, Schranz J, Teutsch SM. Aspergillosis case-fatality rate: systematic review of the literature. *Clin Infect Dis* 2001; 32: 358-66.
4. Herbrecht R, Denning DW, Patterson TF, Bennett JE, Greene RE, Oestmann JW, et al. Voriconazole versus amphotericin B for primary therapy of invasive aspergillosis. *N Engl J Med* 2002; 347: 408-15.
5. Groll AH, Walsh TJ. Caspofungin: pharmacology, safety and therapeutic potential in superficial and invasive fungal infections. *Expert Opin Investig Drugs* 2001; 10: 1545-58.
6. Caillot D, Bassaris H, Mc Geer A, Arthur C, Prentice HG, Seifert W, et al. Intravenous itraconazole followed by oral itraconazole in the treatment of invasive pulmonary aspergillosis in patients with hematologic malignancies, chronic granulomatous disease, or AIDS. *Clin Infect Dis* 2001; 33: 83-90.
7. Ascioglu S, Rex JH, de Pauw B, Bennett JE, Bille J, Crokaert F, et al. Defining opportunistic invasive fungal infections in immunocompromised patients with cancer and hematopoietic stem cell transplant: an international consensus. *Clin Infect Dis* 2002; 34:7-14.
8. Caillot D, Covaillier JF, Bernard A, Casanovas O, Denning DW, Mannone L, et al. Increasing volume and changing characteristics of invasive pulmonary aspergillosis on sequential thoracic computed tomography scans in patients with neutropenia. *J Clin Oncol* 2001; 19: 253-9.
9. Boogaerts M, Maertens J. Clinical experience with itraconazole in systemic fungal infections. *Drugs* 2001; 61: 39-47.x