

Surgical Approach to the Stylohyoid Process in Eagle's Syndrome

Umberto Buono, MD,* Giuseppe Michele Mangone, MD,† Ambra Michelotti, DDS,‡
Francesco Longo, MD, PhD,§ and Luigi Califano, MD||

Elongation or mineralization of the stylohyoid process causes Eagle's syndrome, which is characterized by facial and pharyngeal pain, odynophagia, and dysphagia.¹ A case of ossification of the stylohyoid ligament was reported by Marchetti in 1652.² In 1872, Weinlechner described the first case of painful elongation of the styloid process treated surgically.³ Its etiology is still debated. In 1937, Eagle first described a case of pain associated to elongation of the styloid process.⁴ Eagle primarily described 2 syndromes:

- 1) Classic styloid syndrome after tonsillectomy;
- 2) Stylocarotid syndrome not related to tonsillectomy.⁵

Treatment of choice, which is surgical excision of the styloid complex, may be performed with an intraoral or extraoral approach.

There are also alternative nonsurgical treatments such as transpharyngeal infiltration of lidocaine or steroids and manual transpharyngeal fracture of the styloid process.^{6,7}

The aim of this report is to propose a new surgical technique for the treatment of Eagle's syndrome.

Materials and Methods

Five patients affected by Eagle's syndrome have been treated at the Department of Maxillofacial Sur-

gery of the University of Naples "Federico II," Italy. A panoramic radiograph and axial and coronal computed tomography scans without contrast iodine medium were used for diagnosis. The same radiologic exams were performed postoperatively.^{8,9}

The surgical approach was extraoral in all cases.

Technique

The classic surgical approach to the stylohyoid complex is an external incision at the upper two thirds of the anterior margin of the sternocleidomastoid muscle of approximately 10 cm. After identification and incision of the platysma muscle and the superficial cervical fascia, using sharp and blunt dissections, the sternocleidomastoid muscle is retracted to reach the posterior belly of the digastric muscle and the vascular-nervous bundle of the neck where the stylohyoid process can be easily palpated. The fascia covering the process can now be incised to dissect the muscles and ligaments and to remodel the stylohyoid process.

To avoid scarring, we modified the conventional incision used to approach the stylohyoid complex. We adopted the surgical incision described by Appiani and Delfino¹⁰ to approach the parotid region that we further modified to avoid the temporal extension of the incision line (Figs 1-4).

This incision starts from the radix of the helix of the ear, continuing in the internal aspect of the tragus up to the lobulus auriculæ, then continues posteriorly in the auricular sulcus for approximately 2 cm and makes a curve with upper convexity up to the hair line which ends after a short tract.

After incision, the cutaneous flap is dissected up to the anterior margin of the sternocleidomastoid muscle, after which the traditional surgical procedure may continue.

This incision provides a wide surgical approach, sparing the greater auricular nerve and giving a very good cosmetic result because most of the scar is masked by the tragus and hair. Additionally, this incision preserves sensory innervation of the lower ear and the parotid region.

*Resident, Maxillofacial Surgery Department "Federico II" University of Naples, Italy.

†Assistant Maxillofacial Surgery Department "Federico II" University of Naples, Italy.

‡Professor, Odontostomatology Department "Federico II" University of Naples, Italy.

§Consultant, Maxillofacial Surgeon Department of Head & Neck Surgery Istituto Nazionale Tumori-Napoli, Italy.

||Professor, Maxillofacial Surgery Department "Federico II" University of Naples, Italy.

Address correspondence and reprint requests to Prof. Califano: Via Palizzi 9, 80127-Naples, Italy.

© 2005 American Association of Oral and Maxillofacial Surgeons

0278-2391/05/6305-0009\$30.00/0

doi:10.1016/j.joms.2004.10.013

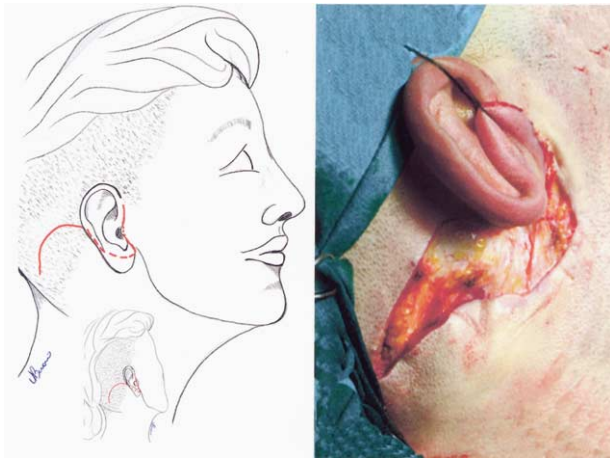


FIGURE 1. Skin incision.

Buono et al. The Stylohyoid Process in Eagle's Syndrome. J Oral Maxillofac Surg 2005.

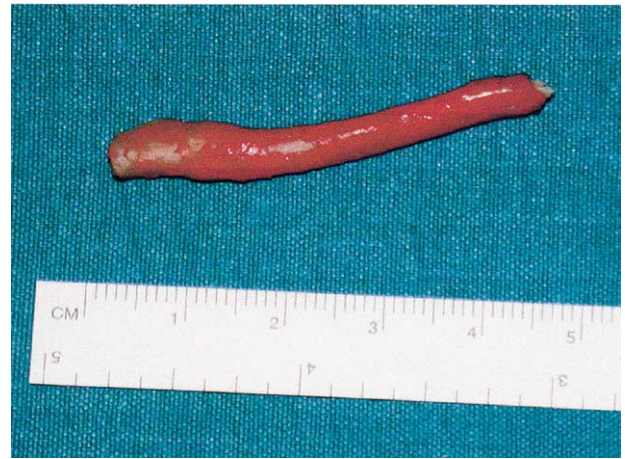

FIGURE 3. Surgically excised segment.

Buono et al. The Stylohyoid Process in Eagle's Syndrome. J Oral Maxillofac Surg 2005.

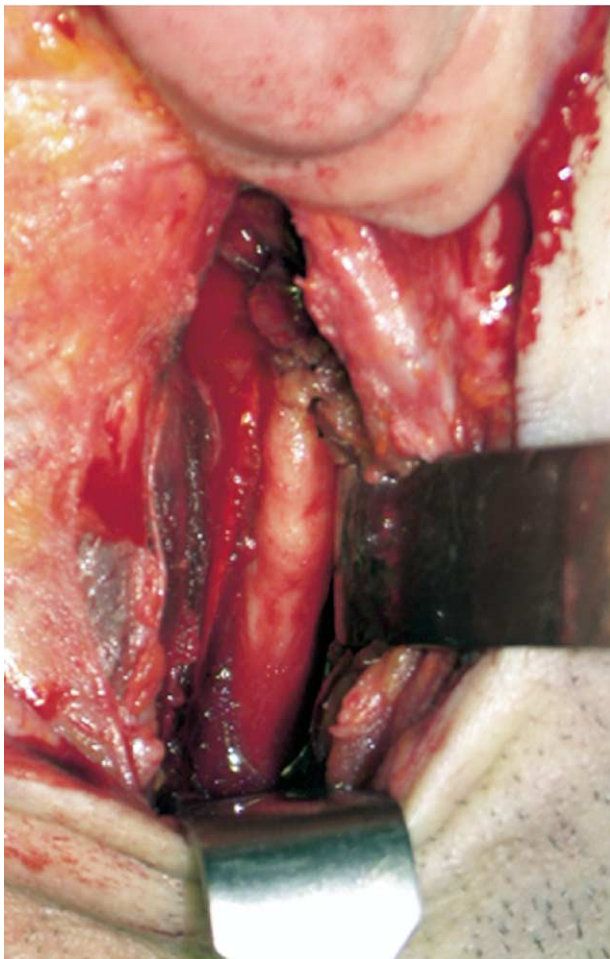


FIGURE 2. Intraoperative view.

Buono et al. The Stylohyoid Process in Eagle's Syndrome. J Oral Maxillofac Surg 2005.

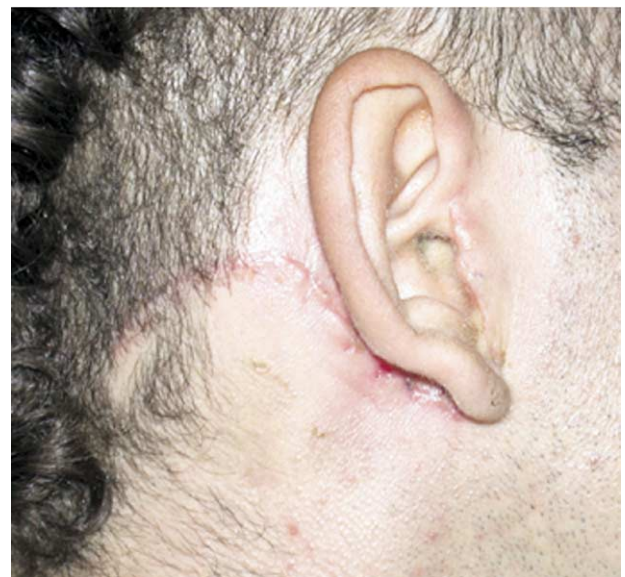

FIGURE 4. Postoperative results.

Buono et al. The Stylohyoid Process in Eagle's Syndrome. J Oral Maxillofac Surg 2005.

Results

Age ranged from 28 to 55 years; 3 patients were women and 2 were men. The greater auricular nerve was spared in all cases. The postoperative course was uneventful and the patients were discharged 1 or 2 days after surgery and followed-up for at least 1 year.

Discussion

The stylohyoid complex includes the stylohyoid process, stylohyoid, stylopharyngeal and styloglossal muscles, and the stylohyoid and stylomandibular lig-

aments. It may vary in shape, position, or size because of the many factors that determine changes in its structure and the painful symptoms characteristic of Eagle's syndrome.

Although nonsurgical procedures have been proposed in the treatment of the Eagles' syndrome, the only effective treatment is its surgical management.

An intraoral approach is also possible but it is rather dangerous because of the restricted operative field and the possibility of an incomplete control over many important vascular and nervous structures. The external surgical approach circumvents these limitations, but results in unsightly scars. Our experience in the treatment of parotid lesions led us to use a modified Appiani's incision to approach the parotid region. We have modified the Appiani's approach to avoid the temporal extension of the incision in the treatment of the Eagles' syndrome.

Our surgical approach overcomes the limits of the external approach, providing a wide surgical field and complete control of all vascular and nervous struc-

tures, granting excellent functional and cosmetic results.

References

1. Friz M: Elongated styloid process: Cause of obscure throat symptoms. *Arch Otolaryngol* 31:911, 1940
2. Marchetti P: *Anatomia. Patavii.* 1652, p 205
3. Weinlechner, cited by Kalvin, MM: Elongated Styloid processes: Their formation and clinical significance. *Laryngoscope* 40:907, 1930.
4. Eagle WW: Elongated styloid processes: Report of two cases. *Arch Otolaryngol* 25:584, 1937
5. Fini G, Gasparini G, Filippini F, et al: The long styloid process syndrome or Eagle's syndrome. *J Craniomaxillofac Surg* 28:123, 2000
6. Chase DC, Zarmen A, Bigelow WC, et al: Eagle's syndrome: A comparison of intraoral versus extraoral surgical approaches. *Oral Surg* 62:625, 1986
7. Diamond LH, Cottrell DA, Hunter MJ, et al: Eagle's syndrome: A report of 4 patients treated using a modified extraoral approach. *J Oral Maxillofac Surg* 59:1420, 2001
8. Kaufman SM, Elzay RP, Irish EF: Styloid process variation: Radiological and clinical study. *Arch Otolaryngol* 91:460, 1970
9. Prasad KC, Kamath MP, Reddy KJM, et al: Elongated styloid process (Eagle's syndrome): A clinical study. *J Oral Maxillofac Surg* 60:171, 2002
10. Appiani E, Delfino MC: Plastic incisions for facial and neck tumours. *Ann Plast Surg* 13:335, 1984