

CASE REPORT

A fatal case of airway obstruction by an organic one-way valve

F Bresci¹, M Di Paolo¹, M Martelli², L De Simone², F Giunta² and N Ambrosino³

¹Department of Neurosciences, Institute of Legal Medicine, University of Pisa, Pisa, Italy; ²Intensive Care Unit, Department of Surgery, University Hospital, Pisa, Italy; and ³Pulmonary Unit, Cardio-Thoracic Department, University Hospital, Pisa, Italy

We report a fatal case of airway obstruction. A tracheostomized, spontaneously breathing 39-year-old man developed dyspnea, cardiac, and respiratory arrest after tracheal cannula replacement. Inspection of the cannula showed a blood clot obstructing the tube. Autopsy showed pink foam in the trachea, pulmonary hyperinflation, and congested lung parenchyma. Histological examination showed acute pulmonary emphysema without any sign of blood inhalation. The probable pathophysiological mechanism is a clot creating a one-way valve allowing inspiration but not expiration, resulting in dyspnea and pulmonary hyperinflation. *Chronic Respiratory Disease* 2009; 6: 47–48

Key words: tracheal blood clot; tracheal cannula obstruction; tracheostomy; ventilator assisted individuals

Introduction

Many retrospective studies have estimated a 5–40% prevalence of complications of tracheostomy (mean 15%). The most frequent long-term complications are hemorrhage (3.7%), tube obstruction (2.7%), and tube displacement (1.5%).¹ Tube obstruction by a blood clot forming a one-way valve is a rare but often fatal complication.^{2–7} We report a fatal case of airway obstruction by a “ball-valve” blood clot.

Case report

A tracheostomized, spontaneously breathing 39-year-old man living in a chronic assisted ventilatory care (CAVC) unit after post-anoxic coma, underwent replacement of the capped tracheal cannula (6 mm diameter, fixed flange tube, without any removable inner cannula). Twelve hours later, the nurse in charge noticed dry blood on the skin around and inside the tracheal cannula of the patient who was still breathing regularly. One hour later, the patient suffered from slight dyspnea, whereas arterial oxygen saturation was 97%. Following to progressive deteri-

orating respiratory observations, the nurse unsuccessfully attempted aspiration of the airways. The patient developed cardiac and respiratory arrest and cardiopulmonary resuscitation was performed. The tracheal cannula was removed, a new tracheal tube was inserted, and resuscitation was continued without success until the patient's death.

Inspection of the tracheal cannula showed a blood clot obstructing approximately 75% of the tube cross section at the distal end (Figure 1). Autopsy showed pink foam in the trachea, pulmonary hyperinflation, and congested lung parenchyma. Histological examination showed acute pulmonary emphysema without signs of inhalation of blood (Figure 2).

Discussion

The cause of death was acute respiratory failure because of a blood clot obstructing the tracheal tube caused by slight bleeding of the mucosa around the tracheostomy over a period of 12 h. The complete absence of blood in lung microscopic slides (Figure 2) indicated that the clot was caused by slight bleeding. The clot formed a valve that permitted inspiration but not expiration, leading to dyspnea, hyperinflation, respiratory failure, and hemodynamic impairment.

Correspondence to: N Ambrosino, Pulmonary Unit, Cardio-Thoracic Department, University Hospital, Pisa, Italy.
Email: n.ambrosino@ao-pisa.toscana.it

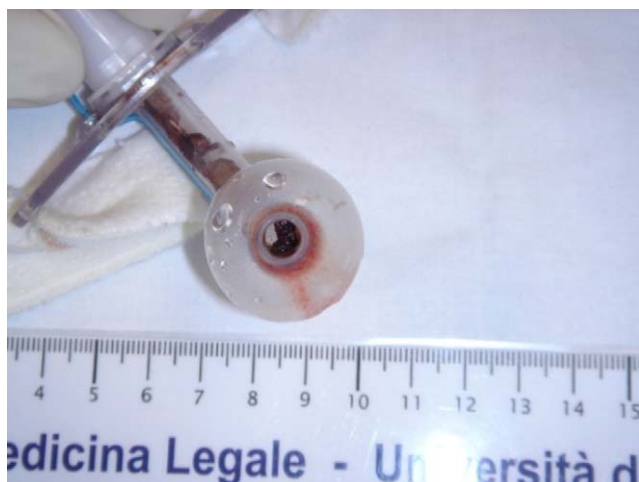

Figure 1 Cannula obstruction because of the blood clot.

Tube obstruction by a blood clot forming a one-way valve is a rare but often fatal complication. Airway obstruction is described in the literature²⁻⁷ together with management procedures to remove clots.^{6,7} A ball-valve clot obstructing the upper respiratory tract is a life-threatening emergency. Prompt intervention is necessary to restore respiration.

The number of ventilator-assisted individuals is increasing world wide and the problems to be faced by care givers (either at home or in other facilities like a CAVC unit is relevant).⁸ Tube change is a major critical point and requires an experienced care giver, especially in unconscious patients. Furthermore, this maneuver is often performed at home or in locations without the monitoring facilities and nurse supervision normally available in a hospital setting. As a consequence, the care giver performing such maneuver should be aware that complications may occur even after some hours and prolong supervision accordingly. This clearly poses organization and resource problems. Furthermore, in the present case, the tube used had no removable inner cannula. Many tubes for home use do have an inner cannula allowing them to be changed and cleaned by all grades of care giver to avoid obstruction. The lesson of the case study is that the first choice for home care should be a tracheostomy tube with a removable inner cannula. The management of a clinically

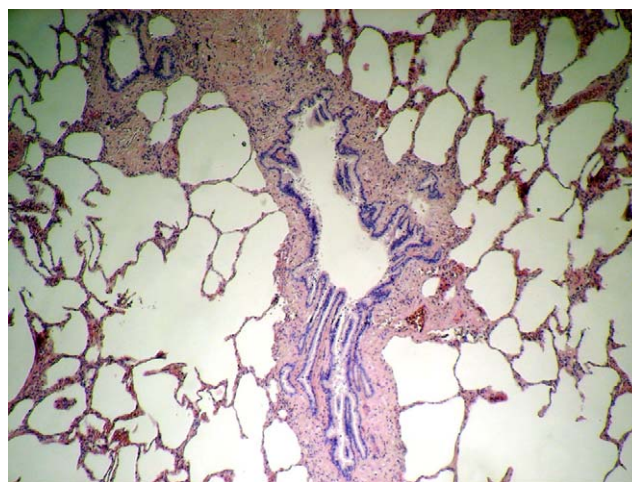


Figure 2 Lung tissue destruction because of acute hyperinflation, without any sign of blood inhalation.

stable ventilator-dependent individual is a challenge. Patients who are managed outside an intensive care unit require a safe location, expert care givers, and appropriate choice of equipment.

References

1. Goldenberg, D, Ari, EG, Golz, A, Danino, J, Netzer, A, Joachims, HZ. Tracheotomy complications: a retrospective study of 1130 cases. *Otolaryngol Head Neck Surg* 2000; **123**: 495-500.
2. Brennan, FJ, Parker, JO. Check valve airway obstruction by blood clot. *Can Med Assoc J* 1970; **102**: 630-631.
3. Kruczek, ME, Hoff, BH, Keszler, BR, Smith, RB. Blood clot resulting in ball-valve obstruction in the airway. *Crit Care Med* 1982; **10**: 122-123.
4. Popovich Jr, J, Babcock, R. Intraluminal blood clot casts causing obstructive emphysema and recurrent pneumothorax. *Crit Care Med* 1982; **10**: 482-483.
5. Foucher, P, Merati, M, Baudouin, N, Reybet-Degat, O, Camus, P, Jeannin, L. Fatal ball-valve airway obstruction by an extensive blood clot during mechanical ventilation. *Eur Respir J* 1996; **9**: 2181-2182.
6. Arney, KL, Judson, MA, Sahn, SA. Airway obstruction arising from blood clot: three reports and a review of the literature. *Chest* 1999; **115**: 293-300.
7. Dongelmans, DA, Jonkers, RE, Schultz, MJ. Case report: a ball valve blood clot in the airways - life-saving whole tube suction. *Crit Care* 2004; **8**: R289-R290.
8. Avendano, M, Hurtado, C, Goldstein, RS. Clinical experience in a CAVC unit. In: Ambrosino, N, Goldstein, RS, (eds), *Ventilator support for chronic respiratory failure*. New York: Informa Health Care; 2008, pp. 197-210.