

Development of sexual organs and fecundity in *Octopus vulgaris* Cuvier, 1797 from the Sardinian waters (Mediterranean Sea)

D. CUCCU, M. MEREU, C. PORCU, M.C. FOLLESA, AL. CAU and A. CAU

Dipartimento di Scienze della Vita e dell'Ambiente, Università di Cagliari.
Via Tommaso Fiorelli 1, 09126 Cagliari, Italy

Corresponding author: cuccu@unica.it

Handling Editor: Stelios Katsanevakis

Received: 5 September 2011; Accepted: 26 March 2013; Published on line: 29 April 2013

Abstract

In this paper we report information about the sexual maturity process of 245 *Octopus vulgaris* specimens (75 females and 170 males) from the Mediterranean Sea. For both sexes, six stages of sexual maturity (immature, developing, maturing, mature, spawning, and spent) are identified on the basis of macroscopic and microscopic observations of the reproductive system and linked with some reproductive indices. A good correspondence between gonad appearance and its histological structure is observed, highlighting, in females, how oviducal gland morphology plays a crucial role in the macroscopic evaluation of maturity. The Gonadosomatic and Hayashi indices, in the two genders, and the Oviducal Gland index in females alone do not allow distinguishing all the stages in an irrefutable way. Data on the potential fecundity, oocyte and spermatophore size are reported and compared with literature. In addition, spermatophore components are also computed. The results reported in this paper lead to easy identification of the different phases of sexual maturation of *O. vulgaris* and could constitute an important tool for defining assessment models in view of sound management of this species.

Keywords: *Octopus vulgaris*, sexual maturity process, gametogenesis, Mediterranean Sea.

Introduction

The knowledge of the reproductive process of a marine species is based on the study of its life cycle. This aspect is more relevant with reference to a commercial species, such as the common octopus *Octopus vulgaris* Cuvier, 1797, for which the reproductive pattern represents a key factor for management aims (González *et al.*, 2011).

The reproductive biology of this species has been studied in the Mediterranean and some differences in the spawning season and the size at maturity have emerged in the different areas investigated (e.g. Mangold-Wirz, 1963; Guerra, 1978; Mangold, 1983, 1989; Sanchez & Obarti, 1993; Quetglas *et al.*, 1998; Tirado-Narvaez *et al.*, 2003; González *et al.*, 2011; Cuccu *et al.*, 2013).

The available sexual maturity scales used for *O. vulgaris* are more or less detailed and criteria adopted to divide the different stages depend, in some cases, on the morphologic status of the gonads and/or on other features such as the dimensions of the sexual products (e.g. Mangold-Wirz, 1963; Guerra, 1975; Dia, 1988; Gonçalves, 1993; Perales-Raya, 2001).

The development of a reliable maturity scale should involve the establishment of a precise and logical correspondence between the macroscopic changes occurring in the gonads (reflecting the development of the gametes during maturation, observed by microscopic investigation) and their gross morphology (Sauer & Lipiński, 1990; Gonçalves *et al.*, 2002).

To the authors' best knowledge, the gametogenesis of *Octopus vulgaris* has been studied (e.g. Khallahi, 2001; Gonçalves *et al.*, 2002; Rodriguez-Rua *et al.*, 2005) and validation of the macroscopic maturity scale by a histological approach has been reported only for the Atlantic stock (Gonçalves *et al.*, 2002; Khallahi & Inejih, 2002).

The aim of this paper is to propose, for both sexes of *O. vulgaris* from the Mediterranean Sea, a sexual maturity scale obtained on the basis of macroscopic and microscopic analysis. We also report some gravimetric indices at the different stages of the maturity process and potential fecundity.

Materials and Methods

Among 245 *O. vulgaris* sampled in the central western Sardinian waters, 230 were collected during monthly

samplings carried out by trawl surveys from 2008 to 2009 at a depth of 25-60 m using a bottom otter trawl with a 20 mm cod-end mesh size. The rest, 15 specimens, were collected by scuba diving from artificial octopus dens (experimentally used for a local management purpose) at a depth of 35-40 m.

On each fresh specimen dorsal mantle length (ML), ventral mantle length (VML) (to the nearest mm) and total weight (TW, to the nearest 0.1 g) were recorded and the sex determined. The weight of the reproductive system (GW), and in particular the weight of the testis (TEW) and spermatophoric complex (SCW) in males and of the ovary (OVW) and oviducal complex (OCW) in females, were taken to the nearest 0.01 g. The diameter of the oviducal gland (OGD) was also registered in females to the nearest 0.1 mm.

Macroscopic maturity stages were established, on the basis of colour, and structure of the reproductive system, according to the information given by Guerra (1975), Hatanaka (1979) and Dia (1988).

For both sexes, 5 fresh specimens at each maturity stage were sampled for the histological analysis. A piece of testis, ovary, oviducal gland (the stretch from the proximal oviduct to the central cavity), proximal oviduct, and smooth oocytes free in the *coelom* (only in the spawning and spent stages) were preserved in 5% formalin buffered in 0.1 M phosphate (pH 7.4). Transverse sections of 3.5 μm (glycol-methacrylate method) were stained with Harris hematoxylin and counterstained with eosin.

Oocytes and testicular germ cells at different development levels were identified using an optic microscope through which oocytes were also measured along the major axis. The different types of cells were described in accordance with our microscopic observations, taking into account also the previous histological studies made by Khallahi (2001), Golçalves *et al.* (2002), Khallahi & Inejih (2002), Rodriguez-Rua *et al.* (2005) and Idrissi *et al.* (2006).

The gonadosomatic ($\text{GSI} = [\text{GW}/\text{TW}] * 100$) (Gabr *et al.*, 1998) and the Hayashi indices following Guerra (1975) ($\text{HI} = \text{SCW}/[\text{SCW} + \text{TEW}]$; $\text{HI} = \text{OCW}/[\text{OCW} + \text{OVW}]$) for both sexes and the oviducal gland index (Fernández-Núñez *et al.*, 1996; $\text{OGI} = \text{OGD}/\text{VML}$) for females, were calculated at each maturity stage and compared using the Kruskal–Wallis test. Gonads of 75 males (45 mature and 30 spawning) and 75 females (15 immature, 15 developing, 15 maturing, 15 mature, 5 spawning and 10 spent) were fixed in 4% saline formalin for the fecundity analysis. In males, all spermatophores inside the Needham's Sacs were measured (to the nearest 0.1 mm) and counted to establish potential fecundity (PF) and the spermatophore length index was also computed (*see* Voss *et al.*, 1998 p. 295; $\text{SpLI} = \text{SpL} * 100/\text{ML}$). On a sample of 450 spermatophores (10 for each individual)

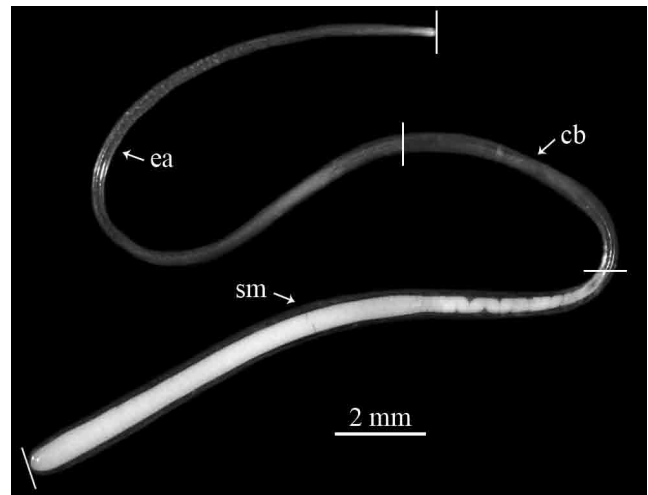


Fig. 1: *Octopus vulgaris*: spermatophore; (ea) ejaculatory apparatus, (cb) cement body, (sm) sperm mass.

the lengths of the sperm mass, cement body and ejaculatory apparatus were also recorded (Fig. 1).

In females, PF was gravimetrically estimated, based on 5 sub-samples (of 0.10 g in immature, developing and maturing specimens, and of 0.25 g in mature individuals) taken throughout the whole ovarian volume. In each sub-sample all oocytes larger than 0.1 mm were counted and measured along the major axis (to the nearest 0.1 mm).

Results

Macroscopic and histological analysis of the reproductive systems

The macroscopic (M) and histological analysis (H) of the changes of the reproductive apparatus during the sexual maturity process in both sexes of *O. vulgaris* led us to identify six stages (1: immature, 2: developing, 3: maturing, 4: mature, 5: spawning and 6: spent), which are described in Tables 1 and 2 and shown in Figures 2 and 3. The reproductive apparatus gradually changes its immature appearance characterized by small gonads and accessory organs reaching a full maturity status through two distinct phases here called developing and maturing stages. After they release the sexual products (spawning stage) they regress (spent stage).

At each stage, from a histological point of view, it is possible to observe cells at different development levels, a result of the oogenesis and spermatogenesis processes.

Reproductive indices

In both sexes the evolution of GSI showed an increase from immature to mature (0.15-7.08% and 0.12-1.65% respectively in females and males); it remained similar at the spawning stage (females: 6.90%; males: 1.34%) and decreased at the spent stage (females: 0.31%; males: 0.52%) (Table 3). Significant differences in the GSI val-

ues within each sex were found at all maturity stages ($P < 0.01$) except for immature-spent and mature-spawning females, and for maturing-mature/spawning and mature-spawning males. HI mean value varied from 0.05 to 0.26 and from 0.36 to 0.52 in females and males respectively (Table 3). In females, HI decreased gradually from the immature to the mature condition and then increased after the spawning stage reaching the maximum value in the spent phase. On the contrary, in males HI showed a gradual increase from the immature to the spawning-spent stages. Significant differences in the HI values of females were found in all the maturity stages ($P < 0.01$) except for the immature-spent, maturing-mature/spawning and mature-spawning females. In males significant

differences in the HI values ($P < 0.05$) occurred between the immature-mature/spawning/spent specimens and the developing-mature/spawning/spent ones.

Regarding the OGI, the mean values varied from 0.036 to 0.117 showing an increase from the immature to the spawning stage and a decrease at the spent one (Table 3). Significant differences in the OGI values ($P < 0.01$) were observed at all maturity stages except between mature and spawning females.

Sexual products

In females, an increase in the number of oocytes was observed from stage 1 (immature) to stage 4 (mature),

Table 1. *Octopus vulgaris*: macroscopic (M) and histological (H) description of the female gonad at different maturity stages.

Stage	Description
Immature 1	M: small and translucent reproductive apparatus. Oocytes hardly visible in the ovary. Oviducts meander not visible and small oviducal gland (OG) (\emptyset : 0.36-3.80 mm) (Fig. 2A).
	H: oogonia (OO: 7.0-16.8 μm) and early primary oocytes (EPO: 23.8-85.2 μm) in the germinal epithelium. EPO associated with one or several follicular cells, oval in shape located on the connective tissue (Fig. 2G). In OG the spermathecae (SP) are empty and show simple ciliated epithelium (Fig. 3A).
Developing 2	M: whitish-creamy ovary not reaching the posterior half of the mantle cavity. Small oocytes (≤ 2.80 mm) clearly visible. Oviducts meander visible. Developing and creamy OG (\emptyset : 4.20-6.89 mm), could show a thin white denticulate apical region (Fig. 2B).
	H: OO, EPO, and late primary oocytes (LPO: 140.2-220.4 μm) surrounded by a layer of flat follicle cells and with some lipid inclusions (LI). Previtellogenic oocytes, (PVO: 190.4-648.0 μm) with a double layer of follicular cells; in some cases the follicle forms a syncytium (F) (Fig. 2H). In OG, two glandular compartments (outer strongly eosinophilic, OR and inner, weakly eosinophilic IR) separated by a thin basal lamina are visible. SP with few spermatozoa (SPZ) (Fig. 3B).
Maturing 3	M: yellowish ovary, occupying the whole posterior half of mantle cavity, containing reticulated oocytes at different sizes (≤ 3.40 mm). Oviducts fully developed but empty. Creamy OG (\emptyset : 6.93-9.80 mm) displaying the white denticulate apical region followed by a light brown ring (Fig. 2C).
	H: abundant vitellogenic oocytes (VO, 876.5-1396.3 μm). The follicular epithelium active in vitellogenesis and in the formation of a chorion. PVO, LPO, OO are also present (Fig. 2I). In OG the two glandular regions (OR and IR) are separated by a thick basal lamina (BL). SP full of SPZ with their heads within the mucosa (Fig. 3C, D).
Mature 4	M: yellow ovary, occupying the whole posterior half of mantle cavity, containing oocytes at different sizes (≤ 4.0 mm) with a high percentage of large reticulate (3.0-4.0 mm) ones. Oviducts fully developed but empty. Creamy OG (\emptyset : 9.80-16.31 mm) with enlarged white denticulate apical region and brown ring (Fig. 2D).
	H: abundant advanced vitellogenic oocytes (AVO, 879-3980 μm) surrounded by a well developed chorion and with yolk granules (Y) in the cytoplasm (Fig. 2J). All types of oocytes are present. OG as before (Fig. 3E, F).
Spawning 5	M: yellow ovary containing oocytes at different sizes (≤ 4.0 mm) with large reticulate oocytes (3.0-4.0 mm). Some smooth oocytes (4.0 mm) free in the <i>coelom</i> . Thick oviducts with smooth oocytes inside. Creamy OG (\emptyset : 11.90-14.45 mm) as before but with the brown ring slightly darker (Fig. 2E).
	H: abundant AVO and presence of other types of oocytes in the ovary. Ripe oocytes (RO: 2884-3998 μm) free in the <i>coelom</i> and in the proximal part of the oviducts. RO issued by the preovulatory follicle with the cytoplasm filled by yolk granules and the folds completely reabsorbed, involved and protected by the chorion; they have a peduncle (P) (Fig. 2K). OG as before (Fig. 3G, H).
Post spawning 6	M: brownish ovary. Few smooth oocytes could be present in the <i>coelom</i> . Enlarged oviducts with few smooth oocytes or empty. Shrunken OG (\emptyset : 2.83-4.80 mm) darker in colour (Fig. 2F).
	H: ovarian tissue with post-ovulatory follicles (POF) and atretic oocytes (AO). In AO, disorganized follicular epithelium and chorion fragments (Fig. 2L). Occasionally RO free in the <i>coelom</i> . In OG, the glandular components less compact with a wide lumen. SP almost empty, with residual SPZ (Fig. 3I, L).

OG, oviducal gland; OO, oogonium; EPO, early primary oocyte; SP, spermathecae; LPO, late primary oocyte; LI, lipid inclusion; PVO, previtellogenic oocyte; F, syncytium; OR, outer region; IR, inner region; SPZ, spermatozoa; VO, vitellogenic oocyte; BL, basal lamina; AVO, advanced vitellogenic oocyte; Y, yolk granules; RO, ripe oocyte; P, peduncle; POF, post-ovulatory follicles; AO, atretic oocyte.

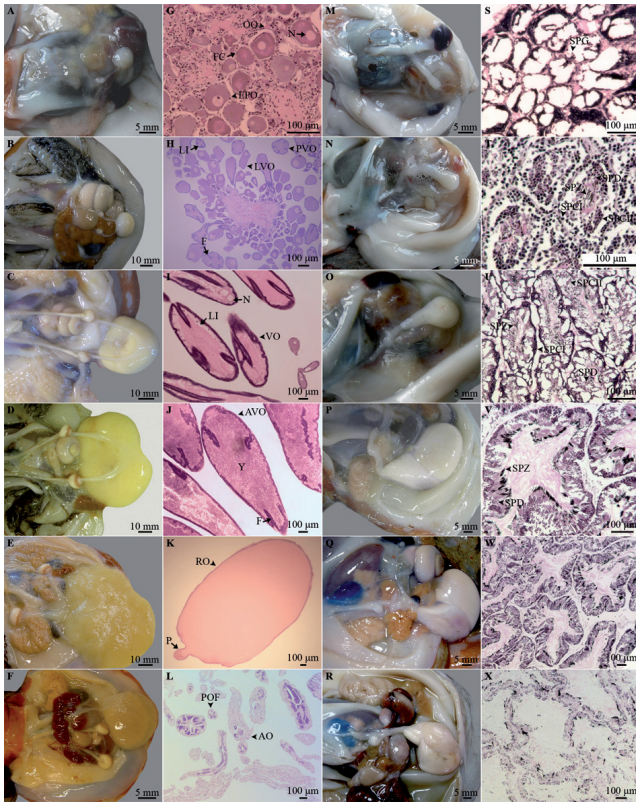


Fig. 2: *Octopus vulgaris*: macroscopic (females: A, B, C, D, E, F; males: M, N, O, P, Q, R) and microscopic photos at six maturity stages (females: G, H, I, J, K, L; males: S, T, U, V, W, X). A, G, M, S: stage 1; B, H, N, T: stage 2; C, I, O, U: stage 3; D, J, P, V: stage 4; E, K, Q, W: stage 5; F, L, R, X: stage 6. OO, Oogonium; EPO, early primary oocyte; LPO, late primary oocyte; PVO, previtellogenic oocyte; VO, vitellogenic oocyte; AVO, advanced vitellogenic oocyte; RO, ripe oocyte; POF post-ovulatory follicle; AO, atretic oocytes; F, fold; FC, follicular cells; LI, lipid inclusion; N, nucleoli; P, peduncle; Y, yolk granules; SPG, spermatogonium; SPD, spermatid; SPCI, primary spermatocyte; SPCII, secondary spermatocyte; SPZ, spermatozoa.

while not counting the very small oocytes (<0.1 mm) at the first two stages (Table 3). At the maturity stage, PF ranged between 202518 (110.0 mm ML and 410.0 g TW) and 546662 (165.0 mm ML and 2830 g TW) oocytes with a size of 0.1 - 4.0 mm (Table 3). The specific length of oocytes and their frequency distribution, for each maturity stage, are shown in Table 3 and Table 4, respectively.

In the Needham's Sacs of mature males between 30 (125.0 mm ML; 1089.0 g TW) and 246 (137.0 mm ML; 1297.0 g TW) spermatophores (mean: 150±66) were counted (Table 3). SpL varied from 30.01 to 62.87 mm (mean: 45.00±8.10 mm) and the SpLI ranged between 25.1% and 42.6% (35.7%±4.2%). Sperm mass (33.49-38.89 %), cement body (16.09-22.29 %) and ejaculatory apparatus (42.12-47.19 %) constituted 35.64%, 19.20%, and 45.16% of the total spermatophore length, respectively.

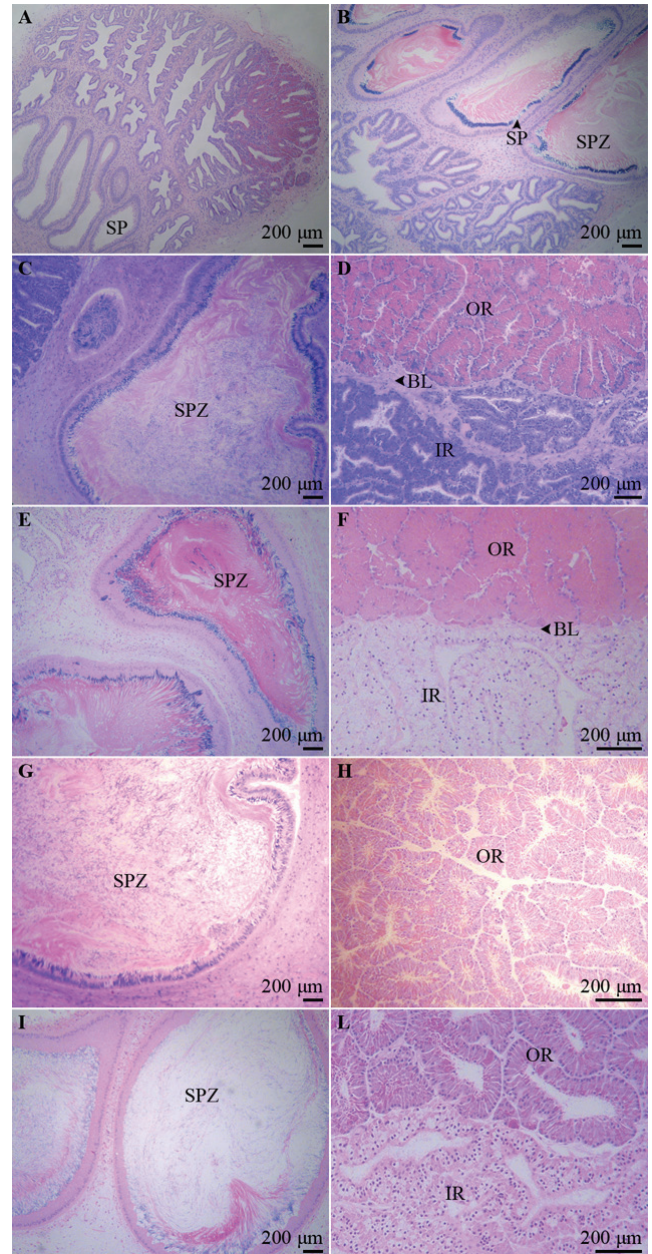


Fig. 3: *Octopus vulgaris*: histological transverse sections of the oviducal gland (OG) at different maturity stages. (A) OG of an immature female with empty spermathecae (SP). (B) OG of a developing female showing the spermathecae (SP) with few spermatozoa (SPZ). (C) OG of a maturing female showing the spermathecae full of spermatozoa (SPZ) with their heads within the mucosa and (D) the two glandular regions (IR, inner region and OR, outer region) of the OG separated by the basal lamina (BL). (E, F) OG of a mature female. (G, H) OG of a spawning female. (I) OG of a spent female showing spermathecae with residual spermatozoa and (L) the two less compact regions.

Discussion

Recently, particular attention has been given to the necessity to adopt suitable scales to establish the maturity state of cephalopod specimens, and this was also discussed at the last workshop on this subject (ICES, 2010).

Table 2. *Octopus vulgaris*: macroscopic (M) and histological (H) description of the male gonad at different maturity stages.

Stage	Description
Immature 1	M: Small and translucent reproductive apparatus. Thin and flat testis (TE) and spermatophoric complex (SC). Vas deferens (VD) and Needham's Sac (SS) not visible (Fig. 2M).
	H: Seminiferous tubules small, but well defined. Only spermatogonia (SPG) are present (Fig. 2S).
Developing 2	M: Ivory TE and semitransparent SC with VD and SS visible and empty (Fig. 2N).
	H: Inside the seminiferous tubules, bigger than those from the previous stage, the spermatogenesis is active: SPG, numerous primary and secondary spermatocytes (SPCI and SPCII), spermatids (SPD) and few spermatozoa (SPZ) (not in all tubules) (Fig. 2T).
Maturing 3	M: Ivory and spherical TE. White VD and SS with few tentative spermatophores inside (Fig. 2O).
	H: Seminiferous tubules clearly defined with all germ cells. SPZ more evident and visible in all tubules; they are grouped around the lumen of the tubules with the flagella towards the centre (Fig. 2U).
Mature 4	M: Creamy-white large TE and VD. Spermatophores packed in SS (Fig. 2P).
	H: Seminiferous tubules large and well distinct without empty spaces between cells. Presence of all types of cells; abundant SPZ in the central lumen (Fig. 2V).
Spawning 5	M: Greyish TE. SS with reddish areas and packed spermatophores inside (Fig. 2Q).
	H: Seminiferous tubules large and well defined. Presence of all types of cells with some empty spaces between them. Abundant SPZ in the central lumen (Fig. 2W).
Post spawning 6	M: Flaccid greyish TE. SS empty or with some residual spermatophores (Fig. 2R).
	H: Wide spaces inside the tubules. Only few SPCI, SPCII and SPD. SPZ dispersed throughout the seminiferous tubules (Fig. 2X).

TE, testis; SC, spermatophoric complex; VD, vas deferens; SS, Needham's Sac; SPG, spermatogonium; SPCI, primary spermatocyte; SPCII, secondary spermatocyte; SPD, spermatid; SPZ, spermatozoa.

Table 3. *Octopus vulgaris*: measurements, computed indices and fecundity data from samples at different maturity stages.

	N°	ML (mm)	TW (g)	GSI (%)	HI	OGI	PF	Oocytes/ spermatophores length (mm)
Immature Stage 1	♀ 15	25.0–90.0 [62.4±11.2]	35.1–379.0 [123.6±73.2]	0.04–0.35 [0.15±0.07]	0.15–0.48 [0.25±0.08]	0.009–0.049 [0.036±0.007]	12160–45000* [26580±12061]	0.10–1.00
	♂ 30	14.0–77.6 [59.1±7.8]	20.0–141.7 [96.2±25.3]	0.03–0.25 [0.12±0.07]	0.25–0.47 [0.36±0.06]			
Developing Stage 2	♀ 15	80.0–135.0 [106.5±13.5]	485.0–1258.0 [563.3±203.5]	0.39–1.25 [0.84±0.28]	0.09–0.21 [0.16±0.04]	0.056–0.077 [0.067±0.008]	37430–72140* [42150±8605]	0.10–2.80
	♂ 30	47.4–85.0 [61.2±8.9]	63.1–244.0 [127.2±44.8]	0.17–0.56 [0.35±0.12]	0.27–0.47 [0.39±0.06]			
Maturing Stage 3	♀ 15	105.0–238.9 [137.5±35.5]	327.0–4661.0 [1238.6±1108.2]	1.43–4.66 [2.92±1.21]	0.05–0.12 [0.08±0.03]	0.080–0.093 [0.085±0.005]	165047–315224 [181393±111337]	0.10–3.40
	♂ 30	63.0–115.0 [86.7±21.1]	81.9–794.0 [314.6±252.7]	0.78–1.82 [1.34±0.42]	0.32–0.59 [0.43±0.11]			
Mature Stage 4	♀ 15	110.0–165.0 [138.2±15.9]	410.0–2830.0 [1169.6±558.1]	4.22–12.34 [7.08±2.43]	0.03–0.06 [0.05±0.01]	0.097–0.131 [0.109±0.009]	202518–546662 [313785±111807]	0.10–4.00
	♂ 45	45.0–190.0 [115.0±25.0]	195.3–3522.0 [1025.6±674.7]	0.87–1.97 [1.65±0.29]	0.34–0.74 [0.48±0.10]		30–246 [150±66]	30.01–62.87 [45.0±8.1]
Spawning Stage 5	♀ 5	125.2–170.0 [152.0±19.8]	730.0–1684.0 [1080.0±150.0]	6.70–7.00 [6.90±0.12]	0.06–0.10 [0.09±0.03]	0.105–0.126 [0.117±0.008]		0.10–4.00
	♂ 30	71.0–250.0 [125.0±30.4]	203.3–5850.0 [1152.4±837.8]	0.44–1.80 [1.34±0.30]	0.34–0.77 [0.52±0.08]		28–148 [109±40]	31.10–58.08 [42.9±7.4]
Spent Stage 6	♀ 10	95.0–120.0 [108.4±10.0]	343.0–912.0 [636.6±320.7]	0.16–0.45 [0.31±0.15]	0.22–0.33 [0.26±0.05]	0.045–0.058 [0.051±0.009]		3.00–4.00
	♂ 5	121.0–150.0 [135.5±20.5]	980.0–1320.0 [1150.0±240.4]	0.48–0.56 [0.52±0.06]	0.48–0.50 [0.49±0.01]			

ML, Dorsal Mantle Length; TW, Total Weight; GSI, gonadosomatic index; HI, Hayashi index; OGI, oviducal gland index; PF, potential fecundity; *, uncounted oocytes (< 0.10 mm). Mean values ± standard deviations are in brackets.

Table 4. *Octopus vulgaris*: oocytes length frequency distributions in ovaries at different maturity stages.

Oocytes size (mm)	Immature Stage 1	Developing Stage 2	Maturing Stage 3	Mature Stage 4	Spawning Stage 5
0.5	61.2 %	35.0 %	22.3 %	14.0 %	11.2 %
1.0	38.8 %	25.0 %	10.0 %	5.2 %	4.3 %
1.5		18.4 %	14.9 %	6.2 %	5.6 %
2.0		13.5 %	17.3 %	8.0 %	6.4 %
2.5		6.0 %	17.6 %	14.1 %	15.1 %
3.0		2.1 %	15.4 %	20.5 %	22.7 %
3.5			2.5 %	23.4 %	25.6 %
4.0				8.6 %	9.1 %

According to Juanicó (1983), a maturity scale can be defined as a “sequence of observable sets of primary and secondary sexual characteristics that are synchronous in time and which the organism in question passes through in sequence, during its sexual maturation”.

Basically, the creation of a maturity scale is not easy and it is often complicated to decide how many steps should be included; this, obviously, depends on the use of the scale and the aims of the research.

Arkhipkin (1992) showed that sexual maturity in cephalopods can be divided into physiological and functional maturity in accordance with the biological processes that occur in the gonads. He suggested that the evaluation of both histological and morphological characteristics is the best way to define all the development phases.

In fact, in this way it is possible to establish the relationship between the maturation process and the morphological appearance of the gonad (Gonçalves *et al.*, 2002). With this aim, the six stage macroscopic scale proposed in this paper for *Octopus vulgaris* from the Mediterranean, represents the first scale in which each stage has been validated by microscopic analysis and linked with some reproductive indices.

The GSI and HI, in the two genders, from the immature to the mature condition, showed a development of the reproductive system with higher indices in females than in males and with different mean values at the six stages. However, these reproductive indices alone do not allow us to distinguish all the analysed stages in an irrefutable way, as also observed for squid by Lipiński & Underhill (1995). In females, the OGI's characterize each stage well except for the mature and spawning ones which show similar values.

During physiological maturation (stages 1-3) and maturity (stage 4) the oviducal glands play a crucial role as the main morphological indicator of maturity together with the changes of the ovary (size and colour). From a histological point of view, the white denticulate apical region that macroscopically appears during the maturation process in the glands is correlated to the presence of spermatozoa stored inside the spermathecae. This region

is observable to the naked eye starting from the developing females (stage 2). The presence of spermatozoa in the histological sections of the glands at this stage confirms that they have already mated. Mating in immature females of *O. vulgaris* has been noticed and it appears that spermatozoa, before egg fertilization, stay alive inside the glands waiting for the functional maturity of the females (e.g. Mangold, 1983; Gonçalves *et al.*, 2002). For our sample, this period could last about 86 days if we take into account the mean age of maturing and mature females, estimated in the same geographical area by Cuccu *et al.* (2013).

In mature females (stage 4), the light brown ring under the apical region becomes dark and enlarged during full vitellogenesis. Considering the different staining properties of the two glandular regions, we are in agreement with the two-fold role played by the oviducal glands in secreting substances which harden into an egg shell and store the sperm (Wells, 1978; Di Cosmo *et al.*, 2001).

At the spawning stage, the presence of free smooth oocytes in the *coelom* and inside the proximal part of the oviducts indicates the achievement of functional maturation-maturity (*sensu* Arkhipkin, 1992). This has been confirmed histological by the individuation of ripe oocytes bearing a peduncle, not visible to the naked eye. It is known that this peduncle is necessary during spawning when the eggs are interwoven to form the strings (Mangold, 1983) that attach to the shelters by means of secretions (Frösh & Marthy, 1975). In fact, the spawning females were collected from dens as were the spent specimens (stage 6) in which the ovaries contained post ovulatory follicles and atretic cells as a result of the ovulation process.

Potential Fecundity estimated in mature females (stage 4) is in agreement with previous studies for Mediterranean and Atlantic specimens (e.g. Mangold, 1989; Silva *et al.*, 2002; Otero *et al.*, 2007), even if we have never analyzed specimens as large as the Atlantic samples (up to 6000 g).

The maximum size of the oocytes (4 mm) in mature females is bigger than those reported by several authors (e.g. Mangold-Wirz, 1963: 2.7 mm; Guerra, 1975: 2.4 mm; Roper *et al.*, 1984: 2 mm) and smaller than those reported by Otero *et al.* (2007) (5 mm). These differences could probably be related to the methodology used to preserve the samples before the analysis (e.g. fixative, temperature, duration of the preservation, etc.).

The range size of oocytes and their frequency, recorded at all stages, as well as the presence of oocytes at various stages of development in the histological sections, reflect an asynchronous oocyte development as already proposed by Gonçalves *et al.* (2002) for the same species.

Regarding the males, the morphological aspect of the reproductive system, as regards size and colour, is correlated with the development of seminiferous tubules and the presence of the different spermatid cells, according to the spermatogenesis described by Gonçalves *et al.* (2002). Starting from stage 3, the presence of spermatozoa in all seminiferous tubules and their peculiar orientation, highlight the beginning of functional maturation-maturity (*sensu* Arkhipkin, 1992) which is characterized by the movement and location of the mature sexual cells in the different parts of the reproductive system. This is macroscopically correlated with the presence of white vas deferens and tentative spermatophores inside the Needham's Sac.

In mature (stage 4) and spawning (stage 5) males, spermatophores are packed in the Needham's Sacs; in appearance these two stages differ only by a reddish stain on the sacs at the spawning stage. Histologically, the only difference is the presence of some spaces between all kinds of germ cells inside the seminiferous tubules of the spawning males.

The flaccid appearance of the testis in the spent specimens (stage 6) corresponds to the wide spaces inside the tubules due to the small number of germinal cells. This senility condition is reached about one year after hatching (Cuccu *et al.*, 2012).

In mature males, the maximum number of spermatophores is higher than those reported for other Mediterranean areas (Mangold-Wirz, 1963; Guerra, 1975), similar to that found by Silva *et al.* (2002) in the Gulf of Cádiz, and markedly lower than that given by Otero *et al.* (2007) for the Galician waters. Moreover, their lengths are in agreement with Mediterranean literature (Mangold-Wirz, 1963; Mangold, 1983, 1989) and lower than those for the Atlantic (Silva *et al.*, 2002; Otero *et al.*, 2007).

Overall, the scales proposed in this study allow easy identification of the different phases of sexual maturation for the two genders of *O. vulgaris* and could be an important tool to define assessment models for sound management of the species, considering also that environmental variability seems to have an effect on stock fluctuation

(e.g. Faure *et al.*, 2000; Ezzeddine & El Abed, 2004; González *et al.*, 2011).

Acknowledgements

We wish to thank the referees deeply for their constructive criticism and useful comments and suggestions, which greatly improved the quality of this document.

References

- Arkhipkin, A.I., 1992. Reproductive System Structure, Development and Function in Cephalopods with a New General Scale for Maturity Stages. *Journal of Northwest Atlantic Fishery Science*, 12: 63-74.
- Cuccu, D., Mereu, M., Cau, A.I., Pesci, P., Cau, A., 2013. Reproductive development versus estimated age and size in a wild Mediterranean population of *Octopus vulgaris* (Cephalopoda: Octopodidae). *Journal of the Marine Biological Association of the United Kingdom*, 93(3): 843-849. (DOI: 10.1017/S0025315412000203).
- Dia, M.A., 1988. *Biologie et exploitation du poulpe Octopus vulgaris (Cuvier, 1797) des côtes mauritaniennes*. PhD Thesis. University of West Brittany, France, 164 pp.
- Di Cosmo, A., Di Cristo, C., Paolucci, M., 2001. Sex steroid hormone fluctuations and morphological changes of the reproductive system of the female of *Octopus vulgaris* throughout the annual cycle. *Journal of Experimental Zoology*, 289 (1), 33-47.
- Ezzeddine, S., ElAbed, A., 2004. Potential biological and environmental influences on the *Octopus vulgaris* population of the Gulf of Gabès (south-eastern Tunisian coast). *MedSudMed Technical documents No2*, 42-49.
- Faure, V., Inejih, C.A., Demarq, H., Cury, P., 2000. The importance of retention processes in upwelling areas for recruitment of *Octopus vulgaris*: the example of the Arguin Bank (Mauritania). *Fisheries Oceanography*, 9, 343-355.
- Fernández-Núñez, M.M., Hernández-González, C.L., Raya, C.P., Balguerías, E., 1996. Reproductive biology of *Octopus vulgaris* Cuvier, 1797, from North Western African Coast (218N-268N). ICES Document CM 1996/K, 15, 19 pp.
- Frösch, D., Marthy, H.J., 1975. The structure and function of the oviducal gland in octopods (Cephalopoda). *Proceedings of the Royal Society of London, Series B*, 188, 95-107.
- Gabr, H.R., Hanlon, R.T., Hanafy, M.H., El-Etreby, S.G., 1998. Maturation, fecundity and seasonality of reproduction of two commercially valuable cuttlefish, *Sepia pharaonis* and *S. dollfusi*, in the Suez Canal. *Fisheries Research*, 36: 99-115.
- Gonçalves, J.M., 1993. *Octopus vulgaris Cuvier, 1797 (polvo-comum): Sinopse da biologia e exploração*. PhD Thesis. Universidade dos Açores, Portugal, 470 pp.
- Gonçalves, I., Sendão, J., Borges, T.C., 2002. *Octopus vulgaris* (Cephalopoda: Octopodidae) Gametogenesis: a Histological Approach to the Verification of the Macroscopic Maturity Scales. *Abhandlungen der Geologischen Bundesanstalt*, 57, 79-88.
- González, M., Barcala, E., Pérez-Gil, J.L., Carrasco, M.N., García-Martínez, M.C., 2011. Fisheries and reproductive biology of *Octopus vulgaris* (Mollusca: Cephalopoda) in the Gulf of Alicante (Northwestern Mediterranean). *Mediterranean Marine Science*, 12 (2), 369-389.

- Guerra, A., 1975. Determinación de las diferentes fases del desarrollo sexual de *Octopus vulgaris* Lamarck, mediante un índice de madurez. *Investigación Pesquera*, 39: 397-416.
- Guerra, A., 1978. Sobre la alimentación y el comportamiento alimentario de *Octopus vulgaris*. *Investigación Pesquera*, 42 (2), 351-364.
- Hatanaka, H., 1979. Studies on the fisheries biology of common octopus off the northwest coast of Africa. *Bulletin of the Far Seas Fisheries Research Laboratory*, 17: 13-124.
- ICES, 2010. Report of the Workshop on Sexual Maturity Staging of Cephalopods, 8-11 November 2010, Livorno, Italy. ICES CM 2010/ACOM, 49, 97 pp.
- Idrissi, F.H., Koueta, N., Idhalla, M., Belghyti, D., Bencherifi, S., 2006. Les modalités du cycle sexuel du poulpe *Octopus vulgaris* du Sud marocain (Tantan, Boujdour). *Comptes Rendus Biologies*, 329: 902-911.
- Juanicó, M., 1983. Squid maturity scales for population analysis. p. 341-348. In: *Advances in assessment of world Cephalopod resources – FAO Fisheries Technical Papers*, n° 231. J.F. Caddy (Ed). FAO, Rome.
- Khallah, O.M.F., 2001. Etude de la gamétogenèse chez le poulpe *Octopus vulgaris* (Cuvier, 1797). *Bulletin Scientifique IMROP*, 28, 44-52.
- Khallahi, O.M.F., Inejih, C.A., 2002. Proposition d'une échelle macroscopique de maturité sexuelle des femelles de poulpe *Octopus vulgaris* (Cuvier, 1797). *Bulletin Scientifique IMROP*, 29, 51-57.
- Lipiński, M.R., Underhill, L.G., 1995. Sexual maturation in squid: quantum or continuum? *South African Journal of Marine Science*, 15 (1), 207-223.
- Mangold-Wirz, K., 1963. Biologie des céphalopodes benthiques et nectoniques de la mer catalane. *Vie et Milieu*, 13 (Suppl.), 1-285.
- Mangold, K., 1983. *Octopus vulgaris*. p. 335-364. In: *Cephalopod Life Cycles*, vol. I. P.R. Boyle (Ed). Academic Press, London.
- Mangold, K., 1989. *Traité de Zoologie: Cephalopoda. Anatomie, Systématique, Biologie. Tome V, fascicule 4*. K. Mangold & Grassé P.P. (Eds). Masson, Paris, 804 pp.
- Otero, J., González, A.F., Pilar-Sieiro, M., Guerra, A., 2007. Reproductive cycle and energy allocation of *Octopus vulgaris* in Galician waters, NE Atlantic. *Fisheries Research*, 85, 122-129.
- Perales-Raya, C., 2001. *Determinación de la edad y estudio del crecimiento del choco (Sepia hierredda), el calamar (Loligo vulgaris) y el pulpo (Octopus vulgaris) de la costa noroccidental africana*. PhD Thesis. Universidad de La Laguna, Spain, 192 pp.
- Quetglas, A., Alemany, F., Carbonell, A., Merella, P., Sanchez, P., 1998. Biology and fishery of *Octopus vulgaris* Cuvier, 1797, caught by trawlers in Mallorca (Balearic Sea, western Mediterranean). *Fisheries Research*, 36, 237-249.
- Rodríguez-Rúa, A., Pozuelo, I., Prado, M.A., Gómez, M.J., Bruzón, M.A., 2005. The gametogenic cycle of *Octopus vulgaris* (Mollusca: Cephalopoda) as observed on the Atlantic coast of Andalusia (south of Spain). *Marine Biology*, 147: 927-933.
- Roper, C.F.E., Sweeney, M.J., Nauen, C.E., 1984. Fao species catalogue, vol. 3. Cephalopods of the world. An annotated and illustrated catalogue of the species of interest to fishery. *Fao Fishery Synopsis*, 3 (125), 1-247.
- Sauer, W.H.H., Lipiński, M.R., 1990. Histological validation of morphological stages of sexual maturity in chokker squid *Loligo vulgaris reynaudii* D'Orb (Cephalopoda: Loliginidae). *South African Journal of Marine Science*, 9, 189-200.
- Sánchez, P., Obarti, R., 1993. The biology and fishery of *Octopus vulgaris* caught with clay pots on the Spanish Mediterranean coast. p. 477-487. In: *Recent Advances in Cephalopod Fisheries Biology*. T. Okutani, R.K. O'Dor & Kubodera, T. (Eds). Tokai University Press, Tokyo.
- Silva, L., Sobrino, I., Ramos, F., 2002. Reproductive biology of the common octopus *Octopus vulgaris* Cuvier, 1797 (Cephalopoda: Octopodidae) in the Gulf of Cádiz (SW Spain). *Bulletin of Marine Science*, 71, 837-850.
- Tirado Narváez, C., Rodríguez de la Rúa, F.A., Bruzón Gallego, M., López Linares, J., Salas Casanova, C. et al., 2003. La reproducción del pulpo (*Octopus vulgaris*) y el choco (*Sepia officinalis*) en la costa andaluza. *Consejería de Agricultura y Pesca. Mairena de Aljarafe, Sevilla*, 18 pp.
- Voss, N.A., Nesis, K.N., Rodhouse, P.G., 1998. The cephalopod family Histioteuthidae (Oegopsida): Systematics, biology and biogeography. p. 293-372. In: *Systematics and Biogeography of Cephalopods (Vol. II)*. Smithsonian Contributions to Zoology, number 586. Voss, N.A., Vecchione, M., Toll, R.B., Sweeney, M.J. (Eds). Smithsonian Institution Press, Washington.
- Wells, M.J., 1978. *Octopus: Physiology and Behaviour of an advanced invertebrate*. Chapman and Hall, London, 417 pp.