

## Original Research Article

# Assessment of functional outcome of operative management of displaced acetabular fractures and complications

Jawed A. Bhat<sup>1\*</sup>, Tabasum Akbar<sup>2</sup>, Abdul Hanan Javaid<sup>3</sup>, Faizan Javaid<sup>1</sup>,  
Faesal Mir<sup>1</sup>, Nasir Mir<sup>1</sup>

<sup>1</sup>Department of Orthopaedics, SKIMS Medical College, Bemina, Srinagar, Jammu and Kashmir, India

<sup>2</sup>Department of Pharmacology, Govt. Medical, College Baramulla, Jammu and Kashmir, India

<sup>3</sup>Acharya Shri Chander College of Medical Sciences, Sidhra, Jammu and Kashmir, India

**Received:** 27 July 2021

**Accepted:** 02 September 2021

### \*Correspondence:

Dr. Jawed A. Bhat,

E-mail: [bhatjawed@gmail.com](mailto:bhatjawed@gmail.com)

**Copyright:** © the author(s), publisher and licensee Medip Academy. This is an open-access article distributed under the terms of the Creative Commons Attribution Non-Commercial License, which permits unrestricted non-commercial use, distribution, and reproduction in any medium, provided the original work is properly cited.

## ABSTRACT

**Background:** Aim of the study was to assess the functional outcome of operative management of displaced acetabular fractures and complications.

**Methods:** The study included sixty patients presenting within 2 weeks with displaced fractures of more than 2 mm. Elderly patients with osteoporotic bones and co-morbid conditions were excluded.

**Results:** A total of sixty patients were operated on. Union was achieved in anatomical position in 51 patients (85%) and in malposition in 9 (15%) patients. Excellent results were obtained in 15 (25%) patients, good results in 32 (53%), fair results in 7 (11.6%) and poor results in 6 (10%) patients. Post operative complications included infection in 2 (3%), sciatic nerve injury in 2 (3%) and avascular necrosis (AVN) in 3 (5%) patients.

**Conclusions:** In the present study, majority of the patients were operated within two weeks. The Harris hip score averaged 58.

**Keywords:** Displaced acetabular fractures, Anatomical reduction, AVN

## INTRODUCTION

Most acetabular fractures occur primarily because of significant high velocity trauma secondary to road traffic accidents or fall from height. The anatomic location of the acetabulum, as well as the three-dimensional structure of the bone, makes the treatment of these injuries extremely challenging. The severity of these injuries is demonstrated by the fact that early descriptions of acetabular fractures are the result of autopsy findings of patients who had sustained significant trauma.<sup>1</sup>

In 1961, Rowe and Lowell published their landmark article entitled 'prognosis of fractures of the acetabulum'.<sup>2</sup> This was a retrospective study of 93 acetabular fractures in 90 patients, all with a minimum follow-up of one year. In Judet et al published their classic article entitled 'fractures

of the acetabulum, classification and surgical approaches for open reduction'.<sup>3</sup> This manuscript described AP and 45° oblique views of the pelvis to evaluate the acetabular fractures. This article represented a substantial step forward in the understanding of acetabular anatomy and fracture classifications. In Matta published two articles that helped establish the guidelines for those acetabular fractures, which could be managed non-operatively. Using the AP and the 45° oblique views of the pelvis, Matta developed the concept of a 'roof arc measurement'.<sup>4</sup>

The classification (anatomical and radiological) plays an important role and acts as a predominant factor in decision making for mode of treatment.<sup>5</sup>

Associated injuries, which are of life-threatening nature are also very important as 50% often have polytrauma

injuries and are often missed.<sup>6</sup> Fracture of extremities, head injury, chest, abdominal and pelvic injuries are most commonly associated ones.<sup>7</sup>

The incidence of acetabular fractures is on rise due to increased incidence of automobile and occupational injuries. Among different treatment options, operative treatment for these fractures is a safe and acceptable method of treatment.

Currently, surgical treatment has evolved to be treatment of choice as restoration of joint congruity is of paramount importance to reduce the incidence of post traumatic osteoarthritis in hip joint.<sup>8</sup>

The aim of surgical management is to achieve a congruent joint and early mobilisation thus avoiding complications.

The long-term results of operative treatment are influenced by numerous factors including fracture type and or dislocation, femoral head status, intraarticular osteochondral fragments, injury duration, reduction quality, age of the patient, associated comorbidity and musculoskeletal injury and surgical approach.<sup>9,10</sup>

Fractures of the acetabula occur at all ages. Low energy fractures occur in the elderly patients with osteopenia while high energy acetabular fractures are more common in middle age groups. Rehabilitative programme is dependent on type of surgery, age of patient and associated injuries. These patients have profound functional deficit compared with normal population. Anatomical reduction alone is not sufficient to restore function.<sup>11</sup>

The objective of this study was to assess the functional outcome of operative management of displaced acetabular fractures and complications occurring during the procedure.

## METHODS

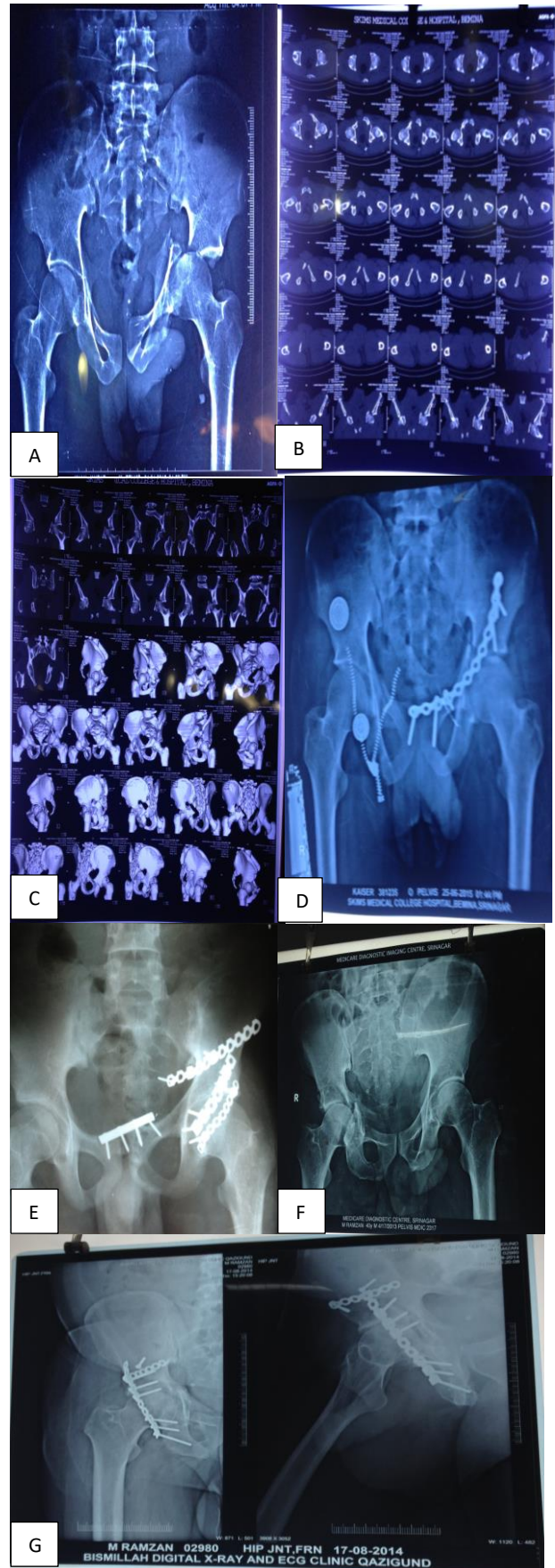
The study was done in postgraduate department of orthopaedics of skims medical college from September 2006 to September 2019.

Patients included in the study were all those who presented with closed displaced fractures of more than 2 mm diagnosed radiologically within three weeks of the injury (Figure 1).

Elderly patients with osteoporotic bones, compound fractures and co- morbid conditions were excluded.

Clinical and radiological assessment as well as postoperative complications were recorded in a proforma especially prepared for this.

Preoperative and post operative x-rays were done in all patients undergoing acetabular surgery. CT scan was done with 3 D reconstruction (Figure 1).

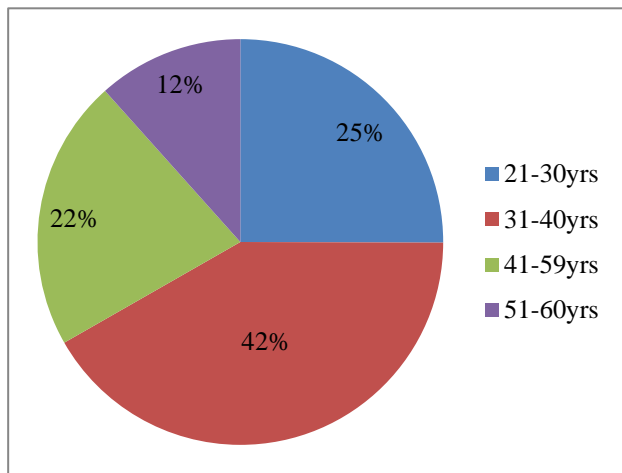


**Figure 1 (A-G): Pre-operative radiograph, CT scan and post-operative radiographs of patients.**

Patients were followed up for 3-6 months postoperatively. At each visit the patients were examined clinically and radiologically. Clinical examinations included checking range of movement at hip joint, status of ambulation and adequate muscle strength especially quadriceps, hamstrings and gluteus. The radiological examination was done at different intervals to look for adequacy of fixation and any complication. Patients were discharged from hospital after 7 days with instruction for ROM and muscle strengthening exercises. Weight bearing was restricted till 12 weeks. Fractures of posterior lip, posterior column, transverse fractures and T fractures were approached through Kocher-langenbeck approach (Figure 1) and fracture involving the anterior column were approached through ilioinguinal or Stoppa approach. No case was treated with extensile approach. The implants used were recon plates and cortical screws (Figure 1).

**RESULTS**

A total of sixty patients were operated on. Mean age of the patients was (36.3 years) with a gender distribution of males 46 (76.6%) and females 14 (23.3%).



**Figure 2: Age distribution.**

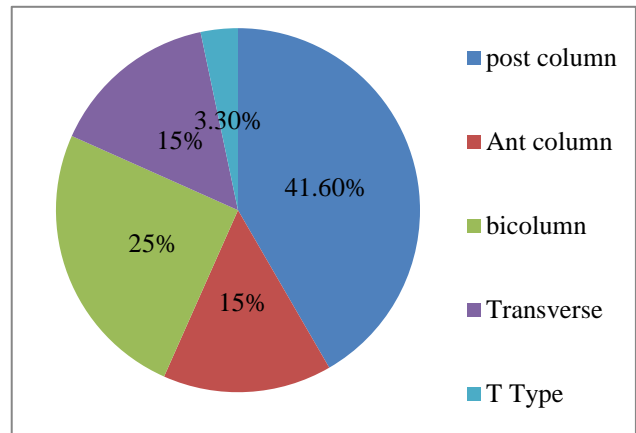
Mode of the injury in majority of the cases was road traffic accidents in 36 (60%) and 24 (40%) had fall from height.

The 50 (83.3%) presented within first 24 hours, 5 (8.3%) patients presented within first week and 5 (8.3%) after 14 days.

Most common fracture pattern was post column seen in 25 (41.6%) patients, anterior column in 9 (15%), bi-column in 15 (25%), transverse in 9 (15%) and T type in 2 (3.3%). Of all the patients, 48 (80%) were operated through Kocker-Langenbeck approach, 2 (3.3%) patients operated through both Kocker-Lagenbeck and ilioinguinal approach and 10 patients operated through ilioinguinal/Stoppa approach.

The mean duration of the surgery was 146 (125-190) minutes with mean blood loss 750 (600-1500) ml. The

mean hospital stay was 7 (5-12 days) and minimum follow-up up to 3 months. In all patients the fracture was united. Union was achieved in anatomical position in 50 (83.3%) and malposition in 10 (16.6%) patients.



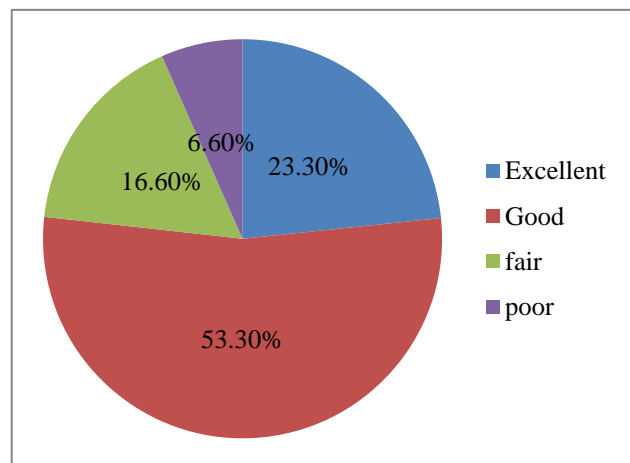
**Figure 3: Fracture pattern.**

Excellent reduction was obtained in 14 (23.3%) of patients, good results in 32 (53.3%), fair results in 10 (16.6%) and poor results in 4 (6.6%) patients.

**Table 1: Functional outcome with respect to age groups.**

Age groups (Years)	N	Excellent, (n=14)	Good, (n=32)	Fair, (n=10)	Poor, (n=4)
21-30	15	6	10	3	4
31-40	25	4	15	4	2
41-50	13	3	5	1	0
51-60	7	1	2	2	1

Further functional outcome was assessed after dividing the sixty patients enrolled in four age groups: 21-30, 31-40, 41-50 and 51-60 years. Quantitative and qualitative analysis was based on new acetabular fracture score system.<sup>12</sup>



**Figure 4: Functional outcome.**

Excellent results were attributed to less severe trauma, anatomical reduction and stable internal fixation after operation and adequate postoperative care and rehabilitation programme.

Post-operative infection in our series was seen in 2 cases, sciatic injury in 3 and AVN in 3 cases.

**DISCUSSION**

Acetabular fractures are complex, high-energy injuries and have potential for a poor outcome regardless of treatment method. The contributing factors may include an imperfect reduction, osteochondral defects in either the acetabulum or the femur at the time of injury, osteoarthritis (OA), AVN of femoral head, heterotopic ossification (HO), nerve injury and infection.<sup>13</sup> Although the incidence of infection has been reduced due to modern theatre facilities and aseptic measures, in developing countries its prevalence is still high and this may lead to increased antibiotic use, prolonged hospital stay, repeated debridement, change of infected implant, prolonged rehabilitation, morbidity and mortality.<sup>14</sup> The fracture pattern, marginal impaction, and residual displacement of more than 2 mm are known to be associated with development of arthritis.

According to Gupta et al following surgical fixation of fracture of the acetabulum, excellent results/union was achieved in 74.6% of the cases using the ilioinguinal approach which was comparable to the results of international studies, while in the remainder of the cases complications were recorded.<sup>15</sup>

The use of the extended iliofemoral or tri-radiate approaches presented with the greatest risk of heterotopic ossification (significant bone formation) while the ilioinguinal approach carries with it the least risk. Those reported with higher incidence were series where the extensile approach was used.<sup>16</sup>

Over the past forty years, the management of displaced acetabular fractures has changed from conservative to operative. A meta-analysis to evaluate the classification, the incidence of complications and the functional outcome of patients who had undergone operative treatment of such injuries was undertaken in which the authors analysed a total of 3670 fractures of acetabulum fixed surgically. The meta-analysis demonstrated an overall incidence of post traumatic nerve palsies associated with acetabular fractures of 16.4%, which is comparable with the findings of Letournel and Jude.<sup>17</sup> The incidence of avascular necrosis of the femoral head (AVN) was noted in 18 studies with 2010 patients with an overall incidence of 5.6%.<sup>18</sup>

In the present study, sixty patients were included and majority of our patients were males. This explains that most of these fractures result from high velocity trauma

(RTA), again an answer for predominant male incidence in our settings.<sup>19</sup>

**Table 2: Comparison of present study to a previous study.**

Parameters	Present study (%)	Meta-analysis (%) <sup>18</sup>
<b>Mean age (Years)</b>	36.3	38.6±4.6
<b>Gender</b>		
Male	76.6	69.4
Female	23.3	30.6
<b>Mechanism of injury</b>		
RTA	60	80.5
Fall	24	19.5
<b>Classification</b>		
Post wall	41.6	23.9
Both column	25	21.7
Ant wall	15	
<b>Post operative complication</b>		
Local infection	3.3	4.4
Nerve palsy	5	8
AVN	5	26.6
<b>Functional out come</b>		
Excellent	23.3	43.9
Good	53.3	29.5
Fair	16.6	11.5
Poor	6.6	15.3

In our series we didn't come across any case of heterotopic ossification, though HO is a common problem in acetabular injury. Formation of large amounts of heterotopic bone occurs unpredictably.<sup>20</sup> Theories that seek to explain ectopic bone formation implicate excessive stripping of gluteal musculature from external iliac fossa, multiple operative procedures, large sized patient, and increased trauma to the abduction mechanism especially in extensile approach (which was not used in our series). Methods for prevention of HO were not employed in this series but in literature various methods are described such as administration of bisphosphonates, indomethacin and low dose radiation.<sup>21,22</sup>

In the current series, post-operative nerve injury occurred in three patients (5%) and this was without somatosensory potential monitoring.<sup>23</sup>

The main strengths of this study were that the study was done in one institution under supervision of one surgeon with long follow up but limitations were that sample size was smaller.

**CONCLUSION**

In the present study, majority of the patients were operated within two weeks. The Harris hip score averaged 58.

Fractures of the acetabulum are increasing in frequency due to an increase in automobile accidents. These fractures

involve major weight bearing joints of the lower limb; hence they must be restored to as much normal as possible and this satisfactory reduction is only possible with open operation and correct approach.

Open reduction and internal fixation markedly reduced hospital stay and was consistent with better clinical results.

*Funding: No funding sources*

*Conflict of interest: None declared*

*Ethical approval: The study was approved by the institutional ethics committee*

## REFERENCES

- Schroeder WE. Fracture of the acetabulum with displacement of the femoral head into the pelvic cavity (central dislocation of femur). Bull North-Western Med school. 1909;11(1):9-42.
- Rowe CR, Lowell JD. Prognosis of fractures of the acetabulum. J Bone Joint Surg Am. 1961;43:30-62.
- Judet R, Judet J, Letournel E. Fractures of the acetabulum: classification and surgical approaches for open reduction. J Bone Joint Surg. 1964;46:1615-46.
- Matta J, Anderson L, Epstein H, Hendricks P. Fractures of the acetabulum. A retrospective analysis. Clin Orthop Relat Res. 1986;205:230-40.
- Anizar-Faizi A, Hisam A, Sudhagar KP, Moganadass M, Suresh C. outcome of surgical treatment for displaced acetabular fractures. Malays orthop J. 2014;8(3):1-6.
- Porter SE, Schroeder AC, Dzugan SS, Graves ML, Zhang L, Russell GV. Acetabular fracture patterns and their associated injuries. J orthop Trauma. 2008;22(3):165-70.
- Milenkovic S, Saveski J, Radenkovic M, Vidic G, Trajkovska N. Surgical treatment of displaced acetabular fractures. Srp Ar celok Lek. 2011;139(7-8):496-500.
- Estrems-Diaz V, Hernandez-ferrando L, Balaguer-Andres J, Bru-pomer A. Acetabular fractures short term results. Rev ES p Cir Ortop Traumatol. 2012;56(1):17-23.
- Magu NK, Gogna P, Singh A, Singla R, Rohilla R, Batra A et al. Long term results after surgical management of posterior wall acetabula fractures. J orthop traumatol. 2014;15(3):173-9.
- Meena UK, Tripathy SK, Sen RK, Aggarwal S, Behera P. Predictors of postoperative outcome for acetabular fractures. Orthop traumatol Surg Res. 2013;99(8):929-35.
- Anjum P, Qayyum N. Experience of fixation of pelvic fractures in mass disaster-a study of 23 cases of sacroiliac joint dislocation. J Pak ortho Assoc. 2008;20(1):88-93.
- Kebaish AS, Roy A, Rennie W. Displaced Acetabular fractures: Long-term follow-up. J trauma. 1991;31(11):1539-42.
- Briffa N, Pearce R, Hill AM, Bircher M. Outcomes of acetabular fracture fixation with ten years follow-up. J bone Joint Surg Br. 2011;93(2):229-36.
- Hickok NJ, Shapiro IM. Immobilised antibiotics to prevent orthopaedic implant infections. Adv drug deliv rev. 2012;64(12):1165-76.
- Gupta RK, Singh H, Dev B, Kansay R, Gupta P, Garg S. Results of operative treatment of acetabular fractures from the third world-how local factors affect the outcome. Int orhop. 2009;33(2):347-52.
- Biokhuis TJ, Frolke JP. Is radiation superior to indomethacin to prevent heterotopic ossification in acetabular fractures: a systemic review. Clin orthop relat Res. 2009;467(2):526-30.
- Haidukewych GJ, Scaduto J, Herscovici D Jr, Sanders RW, Dipasquale T. Iatrogenic nerve injury in acetabular fracture surgery: a comparison of monitored and un monitored procedures. J orthop Trauma. 2002;16(5):297-301.
- Giannoudis PV, Grotz MR, Papakostidis C, Dinopoulos H. Operative treatment of displaced fractures of the acetabulum. A meta-analysis. J Bone Joint Surg Br. 2005;87(1):2-9.
- Khan SH, Ara I, Raza S, Sipra S. Functional outcome of surgery in patients with acetabular fractures. J Ayub Med coll Abbottabad. 2013;25(1-2):60-3.
- Firoozabadi R, O'Mara TJ, Swenson A, Agel J, Beck JD, Routt M. Risk factors for the development of heterotopic ossification after acetabular fracture fixation. Clin orthop relat Res. 2014;472(11):3383-8.
- Popovic M, Agarwal A, Zhang L, Yip C, Kreder HJ, Nousianen MT et al. Radiotherapy for the prophylaxis of heterotopic ossification: a systematic review and meta-analysis of published data. Radiother oncol. 2014;113(1):10-7.
- Nauth A, Giles E, Potter BK, Nesti LJ, O'bien FP, Bosse MJ et al. Heterotopic ossification in orthopaedic trauma. 2012;26(12):684-8.
- Dunbar RP Jr, Gardner MJ, Cunningham B, Rout ML Jr. Sciatic nerve entrapment in associated both column acetabular fractures: a report of 2 cases and review of the literature. J orthop trauma. 2009;23(1):80-3.

**Cite this article as:** Bhat JA, Akbar T, Javaid AH, Javaid F, Mir F, Mir N. Assessment of functional outcome of operative management of displaced acetabular fractures and complications. Int J Res Orthop 2021;7:1145-9.