

## **VERSATILITY OF AN 810 NM DIODE LASER IN PEDIATRIC DENTISTRY**

***Paolo Maturo\**, *Cesare Perugia*, and *Raffaella Docimo***

<sup>1</sup>Pediatric Dentistry, Department of Experimental Medicine and Surgery,  
Tor Vergata University of Rome, Italy

### **ABSTRACT**

**Purpose:** During the last few years, the use of laser techniques has dominated the dentistry world as an alternative to different traditional methods or in combination with these. Diode laser is the most frequently used in dentistry due to its reliability, versatility and convenience, together with its handiness and simple setting-up. The aim of this paper is to review the use of diode laser (810 nm) in pediatric dentistry.

**Methods:** We illustrate, according to the recent literature review, the clinical approach in deciduous teeth endodontics (like pulpotomy and root canal therapy) and in soft tissues surgery with description of techniques used in labial and lingual fraenectomy, operculectomy for tooth retention and hypertrophic lesions removal.

**Results:** 810 nm diode laser has been used in all these different therapies at 0,8 to 3 W power either in continuous or pulsed mode. Diode laser has one of the most versatile ranges of wavelengths available due to the number of different therapies that can be performed in several tissues.

### **CLINICAL SIGNIFICANCE**

Diode laser has shown to be able to supply an exhaustive therapeutic efficacy in the different clinical situations in which it has been employed, together with a precise and fast performance, speeding restorative tissue processes, reducing pain and postoperative edema.

### **INTRODUCTION**

The use of laser as a dentistry tool on a daily basis is becoming a more and more popular practice, in any of the domains that characterize this field.

The Diode Laser can be used for a multitude of dental procedures which are predominantly soft tissue surgery, periodontal pocket therapy, peri-implantitis, but can also be

---

\* Corresponding Author: Dr. Paolo Maturo, Viale Oxford 81, 00131, Rome Italy, Tel +390620900265, Fax +390620900286, email: paolo.maturo@uniroma2.it.

used in endodontics for root canal disinfection, and in laser-assisted tooth whitening [1, 2].

During the last few years, the use of laser techniques has dominated the operative dentistry world as an alternative to different traditional methods or in combination with these [3, 4].

In the dentistry field, different kinds of lasers with different wavelengths are used: carbon dioxide laser (CO<sub>2</sub>), erbium Yag laser (Er:Yag), erbium chrome YSGG (Er-Cr:YSGG), neodymium Yag (Nd: Yag), Argon and KPT laser and diode laser (Ga-As-Al) (4). The latter is the most frequently used in dentistry due to its reliability, versatility and convenience, together with its handiness and simple setting-up. These characteristics make it a useful and complete device and, in some domains, it has shown to be a positive alternative to conventional dentistry therapies.

The field in which its potential is better expressed is predominantly that of soft tissue surgery, but it is also useful and advantageous in endodontics, periodontology and esthetic dentistry [4].

The aim of this paper is to show the use of diode laser (810 nm) in pediatric dentistry.

## **THE DIODE LASER**

Diode laser was introduced in dentistry in the mid nineties and its potential in different surgical procedures has been well documented [1, 2], particularly in the case of pediatric patients, laser surgery allows to benefit from different highlights [6].

The diode laser uses as an active medium a solid semiconductor of aluminum gallium arsenide operating in the near-infrared spectral region, between 808 and 980 nm. The diode laser wavelength is highly absorbed by pigmented tissues containing hemoglobin, melanin and collagen chromospheres, and shows little absorption by hard dental tissue. Thus, this wavelength allows a selective action and is indicated for cutting, vaporization, blood coagulation, curettage, hemostasis and oral soft tissue operations in areas around dental structures [7-9].

Power normally used in dentistry are set from a few mW (antalgic action and biostimulation) to 10 W. Radiation emission can be continuous or pulsed (pulse duration goes from 0,1 ms to continuous, with programmable frequencies at 1000Hz) and the beam transmission system is done through an optical flexible fiber ranging from 200 to 600  $\mu$ m [2, 4].

From a clinical point of view, the Diode Laser has shown to be particularly useful thanks to different characteristics [3, 4, 8, 9]:

- Complete sterilization of the energy source
- It extremely diminishes the need of anesthesia.
- Excellent control of hemostasis due, mainly, to its high absorption in hemoglobin.
- May not generally require sutures.
- Reduced damage of surrounding tissue during procedures resulting in a better recovery and a better post surgery symptomatology.

## Applications in Pediatric Dentistry

In the present article, different clinical situations in which diode laser can be used in pediatric dentistry are analyzed, as, both, a tool needed to reach a therapeutic result and a helping device to complete conventional therapy.

### PULPOTOMY

Accidental pulp exposure is quite frequent in conservative therapy in children. In these situations, the approach to be used, even in these days, remains still coronal pulpotomy, preserving a vital root pulp. The traditional protocol foresees, once the pulp chamber has been opened, removal of the pulp at the root canal with a blade, an excavator, a milling cutter or an electric scalpel, then, after hemostasis, to apply on the pulp stumps a material that may be different according to the chosen technique (Calcium hydroxide, Zinc oxide eugenol, ~~iron~~ ferric sulfate, MTA) [10-12]. In the laser aided pulpotomy, the pulp amputation is performed from the root canals access with an 810 nm diode laser at a power of 2 watt, continuous wave, using a fiber of 320-400  $\mu\text{m}$ . After having proceeded with cutting, immediate hemostasis is controlled, and then, a Calcium hydroxide or a glass ionomer cement lining is applied. Removing the pulp by using the laser results to be efficient when we need to cut pulp tissue in a hemostasis condition or in a sterilized manner. We can see, in the treated area, the formation of amorphous connective tissue, which substitutes the removed pulp with minimal damage of the root pulp and, thus, resulting in less inflammation. Its haemostatic effect allows to rapidly place the dental restorative material without any hematic contamination (Figure 1) [4, 10].

### ROOT CANAL THERAPY

In case of primary teeth with a diseased pulp after deep caries or pulp necrosis, the laser aided endodontic operative protocol foresees to proceed with conventional treatment of cleaning and shaping the canal till 2 mm from the radiological apex followed by a decontamination procedure with diode laser. This decontamination of the canal smear layer and of the intra and inter-tubular organic component is obtained thanks to a combined action of the laser and the sodium hypochlorite, used as a canal irrigating solution (sodium hypochlorite acts as a protective barrier from the laser energy and evaporating penetrates easily in the dentinal tubules). Diode laser is set to 2-2.5 watt in pulse mode (10 ms pulse and 10 ms pause) using a fiber of 200 $\mu\text{m}$ , with circular 5 seconds movements in an apical to coronal direction. After laser decontamination, the canal needs to be cleaned of potential product traces by using physiological solution or EDTA at 17% (6, 13, 14). The root canal can consequently be dried with paper points and filled with resorbable material like calcium hydroxide; the crown restoration with composite will ensure the coronal sealing and the occlusal function (Figure 2).

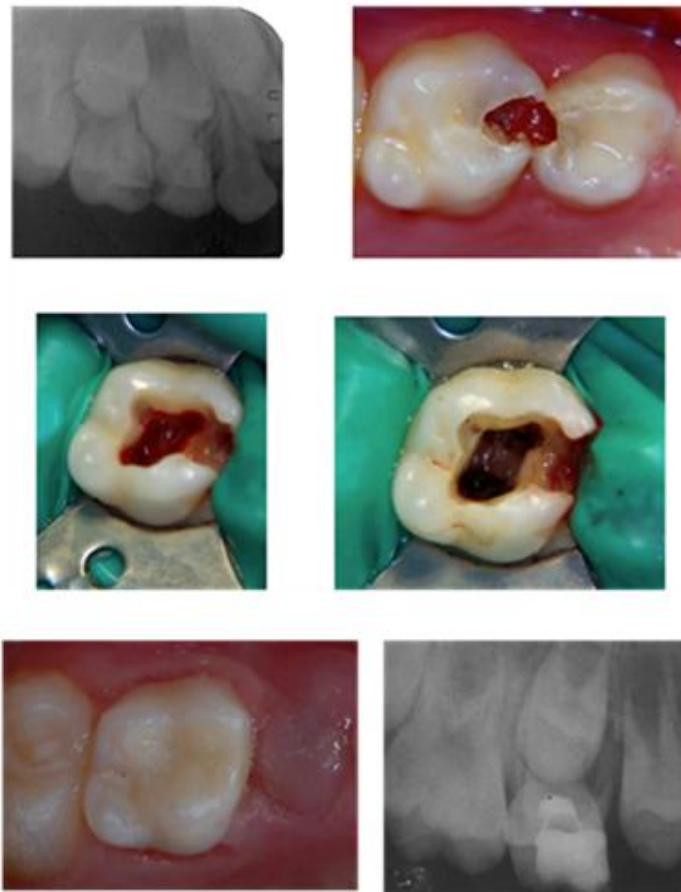

Figure 1. Maxillary second left primary molar pulpotomy. 810 nm diode laser cut of the pulp at root canal level at a power of 2 watt continuous wave, 320  $\mu$ m fiber, control at 6 month post op.

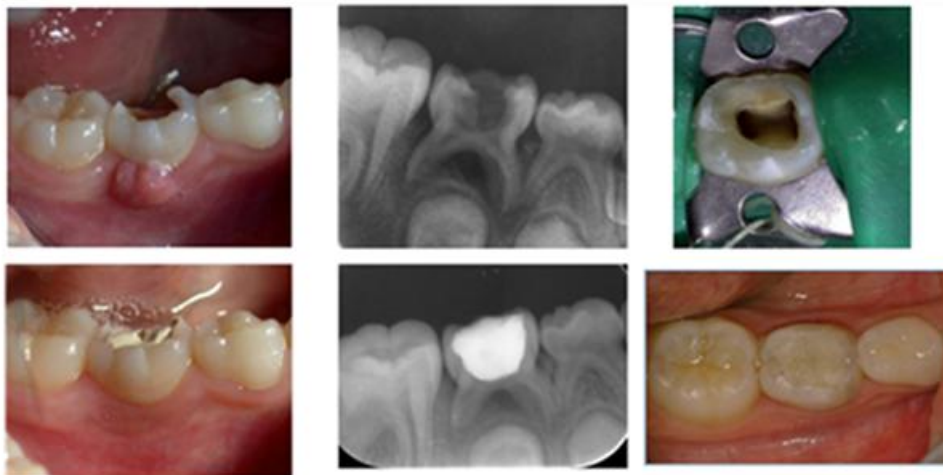


Figure 2. Pulpectomy at 2mm from the apex, 810nm diode laser at 2 watt in pulse mode (10 ms pulse and 10 ms pause) 200  $\mu$ m fiber with circular 5 seconds movements. Calcium oxide root canal filling and composite crown restoration. Rx and clinical control at 6 months post-op.

## SOFT TISSUES SURGERY

Thanks to the use of laser, it is possible to perform different kinds of interventions on oral soft tissues in pediatric patients with efficient and fast techniques, minimizing, at the same time, intra and postoperative discomforts [6, 10]. The advantages of the laser are its great precision, its reliability and visual access of the area operated, the hemostasis control is definitely very high without the tissue suffering any harm due to uncontrollable spread of heat [8]. The laser tip needs to be used in movement so as to prevent an increase of direct source energy. Next to delicate areas, as for example the periodontal area, it is advisable to operate the pulse mode. In this case, its efficacy is slightly slowed down, but tissue recovery is much faster [15]. The hemostasis of the 810 nm laser is a consequence of its precision radiation absorption by hemoglobin and not to the typical electronic scalpel cauterizing action. The tissue injury is almost null and recovery is fast with reduced edema, inflammation and pain. Laser aided interventions on oral soft tissue can be frequently performed without needing local anesthesia, but it is generally enough to use topical anesthesia, especially if laser energy is operated using the pulse mode [6].

Treatment with diode laser is recommended in pediatric dentistry in all procedures of soft tissue surgery, as labial and lingual frenum, infections incisions, cheek or lip fibromas, flap opening of retained elements, gingival hypertrophy.

## LABIAL FRAENUM

The upper labial frenum usually goes from the upper or lower labial vestibules till the incisal area next to the interdental area between the two central incisors next to the mucogingival junction. The hypertrophy of the labial frenum looks like a thick tissue that anchors the the upper lip mucosa to the end of the alveolar bone and the interdental papilla between the two central incisors and, in some cases, to the adherent palatal gum [16, 17].

Complications associated to the hypertrophy of the upper labial frenum can be orthodontic, such as interdental diastema, a periodontal, with predisposition to develop gingival recession or functional recession, dealing with a bad oral hygiene.

The labial frenectomy procedure is recommended whenever a pathologic interdental diastema or/and a periodontal risk of losing mucogingival tissue is present [18].

The aim of this surgical procedure is that of repositioning the frenum apically to the mucogingival line eliminating the interdental fibrous membrane. Frenectomy is performed with 810 nm diode laser with a power of 1.6-2.5 W in continuous mode using a fiber of 320/400  $\mu\text{m}$ . The technique foresees the removal of the frenum starting from the interdental insertion moving towards the apex direction, parallel to the tooth axis. Afterwards, the interdental papilla is incised till the periosteum is reached. Thanks to the hemostasis condition caused by the diode laser, suture is not needed, and thus, recovery is awaited as per second intention. Complete healing takes place after about two weeks from surgery [19]. Compared to traditional surgery, which also foresees healing by second intention of the bone portion of the surgery injury, after frenectomy with diode laser, patients generally report little discomforts during the healing time.

The lower labial frenum attaches, from the inner part of the lower lip to the interdental papilla or apically of it.

When the insertion of this frenum is in a coronal position compared to the mucogingival line it can predispose to the development of periodontal complications, particularly in case it is associated to a thin layer of keratinized gingival [18, 19]. When gingival recession has been observed, the frenum seems to be a worsening factor. The laser aided surgery technique for lower labial frenum foresees the same steps as for the upper frenum.

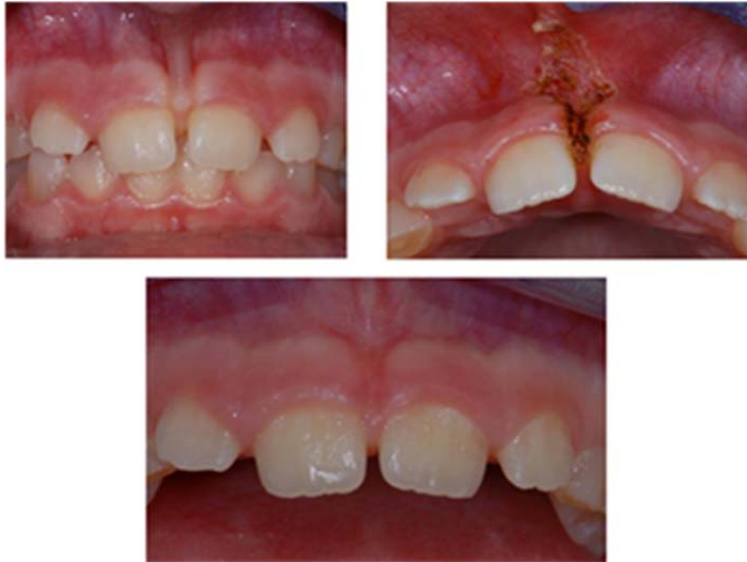

Figure 3. Upper lip frenum. 810 nm diode laser 2.5 W power in continuous mode, 320  $\mu$ m fiber. Control at 3 months post-op.

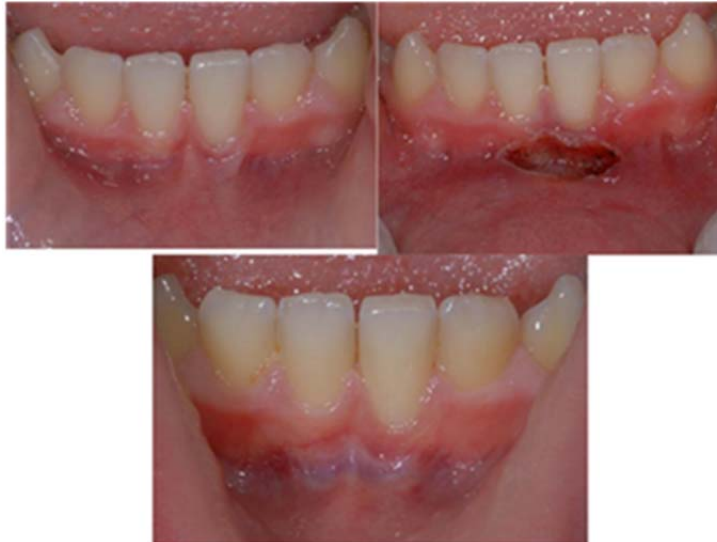

Figure 4. Lower lip frenum. 810 nm diode laser 2 W power in continuous mode, 320  $\mu$ m fiber. Control at 3 months post-op.

According to some authors experience [6, 7, 19], to perform labial frenectomy with diode laser in pediatric patients, after topical anesthesia, it is necessary to infiltrate about 0.5 ml of anesthesia without vasoconstrictor at the level of the vestibule so as to reduce to the minimum pain sensibility that can develop, particularly during recession of the deep connective fibers at the level of the periosteum. It is not advisable to supply anesthesia directly on the frenum area, so as not to alter its shape and dimension. It is not recommended to use vasoconstrictors in order to avoid a condition of ischemia that would render less efficient the interaction between wavelength of the diode laser radiation (810 nm) and tissue (Figures 3-4).

## LINGUAL FRAENUM

The lingual frenum is a fold of mucous membrane extending from the ventral surface of the tongue to the floor of the mouth. The situation in which the lingual frenum is short and hypertrophic is called ankyloglossia. Ankyloglossia can condition normal suction, swallowing and phonetics in children, influencing, thus, during time, the development of the jawbone and dental position, for both the atypical contemporary swallowing to come and for the traction strength to follow. This condition can, this way, predispose to the development of orthodontic and phonetic problems [11].

The technique of lingual frenum removal with 810 nm diode laser is performed with a fiber of 320-400  $\mu\text{m}$  and a power of 1.8-3W in continuous mode, through mobilization of the lingual corpse and rhomboidal cutting following anatomic levels [3, 6, 20], generally without infiltration of anesthesia and with only topical administration, recovery is reached by second intention and without any surgical suture. Immediately after the operation, the mobility of the tongue acquires physiological characteristics during the recovery period that lasts about two weeks. Patients will need to do exercises of the mobility of the tongue to prevent relapse and then start, eventually, logopedic rehabilitation (Figure 5).

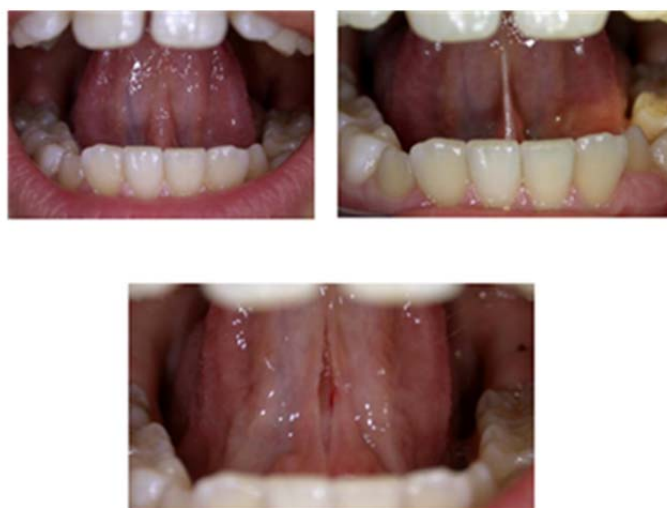

Figure 5. Lingual frenum. 810 nm diode laser 2 W power in continuous mode, 320  $\mu\text{m}$  fiber.

## GINGIVAL HYPERTROPHY

Gingival hypertrophy is represented by an increase in the size of the gingiva linked to an increased number of cells that can be due to different causes, as irritation (iatrogenic or associated to bad habits), hormonal influences or side effects during drug therapies. Hereditary or idiopathic forms are also generalized or locally identified in only some sites [21]. In many cases, tissue hypertrophy does not remit spontaneously after resolution of the causing agent, and thus, it is needed to surgically address the clearing of hypertrophic tissue in order to solve esthetic issues or, in some cases, orthodontic ones.

Gingivectomy with 810 nm diode laser shows different advantages compared to traditional surgery, limiting anesthesia to the topical administration. The postoperative period has shown to present no discomfort for patients. Cutting within a hemostasis environment renders the operation easy and precise in what the definition of gingival contour regards, especially in an esthetic area, and most of all, it guarantees a safe treatment in terms of potential iatrogenic damages. These issues, which are frequent after electrical scalpel, are caused by tissue retraction during postoperative healing.

This treatment is performed with 810 nm diode laser on continuous mode at a power of 1-2,5 watt using a fiber of 320-400  $\mu\text{m}$  (Figure 6).

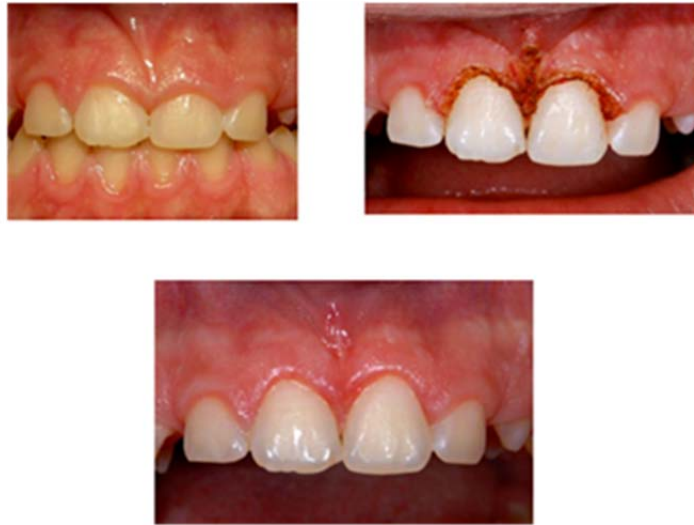

Figure 6. Gingivectomy. 810 nm diode laser 2,5 W power in continuous mode, 320  $\mu\text{m}$  fiber. Control at 3 weeks post-op.

## TOOTH RETENTION

The operculectomy or surgical excision of the mucosa over an unerupted tooth with a laser light presents undoubtful practical advantages. In traditional surgery, the operculum opening that is to allow the dental element to show up is performed after local anesthesia and scalpel or electronic scalpel cutting, according to the site, depth and mucosa thickness. Hemostasis control may be problematic and surgical suture is often needed [11].



With diode laser the intervention is far more comfortable, less invasive and traumatic. The most vascularized areas are surgically easy to treat due to the high visibility of the operating area which normally does not bleed.

The operation is performed with a 810 nm diode laser with a fiber of 320-400  $\mu\text{m}$  and at a power of 1,6-3 W in continuous mode (Figure 7).

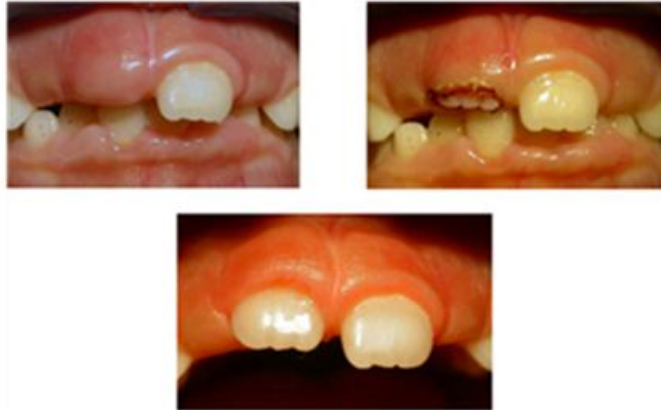

Figure 7. Tooth retention. 810 nm diode laser 3 W power in continuous mode, 320  $\mu\text{m}$  fiber. Control at 2 months post-op.

### HYPERTROPHIC LESIONS

Diode laser has shown to be, since its introduction, particularly recommended in oral soft tissues surgery, specifically regarding benign lesions. Oral soft tissue benign new formations in children are generally mucous cysts at a labial level or connective fibromas, normally sited at the buccal mucosa. These are due to proliferation of fibroblasts after repeated bite trauma or lesions due to orthodontic devices [4, 7].

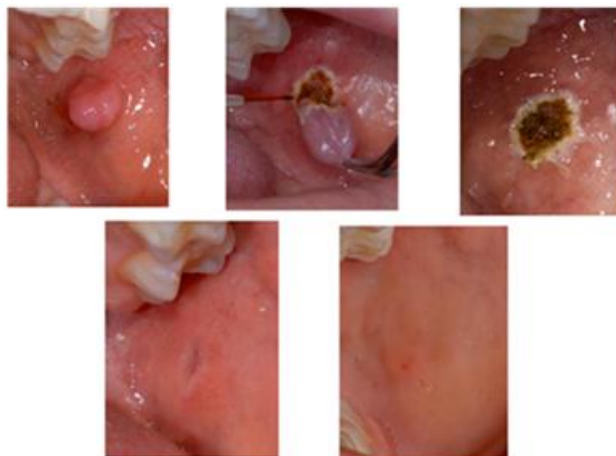


Figure 8. Hypertrophic fibroma. 810 nm diode laser 320  $\mu\text{m}$  fiber, 2,75 W power in continuous mode. Control at 2 weeks and 2 months post-op.

The use of a diode laser allows you to remove the new formation, whether it presents a sessile or peduncle form, without needing surgical suture and without scar resulting from healing. In some cases, besides topical anesthesia a mild infiltration of anesthesia can be applied with no vasoconstriction at the lesion base, especially when is situated in sensible areas [22].

The treatment is performed with a 810 nm diode laser with a fiber of 320-400  $\mu\text{m}$  and at 2,5-4 W power in continuous mode. After removal of the new formation, the surgical wound area, normally not bleeding, heals by second intention and patients are controlled for follow-up at 1 and 2 weeks or, in any case, till complete tissue recovery. During the healing process the patient discomfort in the scar tissue area is usually very acceptable in comparison to conventional surgery techniques (Figure 8).

## DISCUSSION

Different authors claim [2-4, 23] that the conduction of laser aided procedures on soft and hard tissue is more comfortable and better accepted by pediatric patients and their parents, making the child management easier, reducing psychological trauma during and after dentistry therapy, in favor of a better dentist/infant patient relationship and with a better compliance of the latter [11, 23].

The main characteristic of the diode laser is the laser wavelength. Many studies has shown that NIR (Near Infrared) zone, which is the laser light around 810 nm, is one of the most versatile ranges of wavelengths available due to the number of different therapies that can be performed in several tissues. [2, 3]

Most frequent laser applications in pediatric dentistry are gingivectomy, frenectomy, excision of mucocutaneous lesions, and remodeling of gingival tissues associated to mucogingival surgery [2, 3, 24].

Rossmann and Cobb [25] summarized the advantages of lasers in soft tissue as follows:

- The laser cut is more precise than that of a scalpel.
- The cut is more visible initially because the laser seals off blood and lymphatic vessels, leaving a clear dry field.
- The laser sterilizes as it cuts, reducing the risk of blood-borne transmission of disease.
- Minimal postoperative pain and swelling.
- Less postoperative infection because the wound is sealed with a biological dressing during surgery.
- Less damage occurs to adjacent tissues.
- Minimum anesthesia is required.

These qualities result in a shorter operative time, faster postoperative recuperation and a better compliance of infant patients [11, 23]. The risks, on the other side, are:

- Environment contamination danger due to vaporization of target tissue.
- Optical radiation danger not coming from laser emissions.

- Accidental exposure of the eyes of both, the operator and the patient, to laser radiation (protective glasses).

## CONCLUSION

Diode laser has shown to be able to supply an exhaustive therapeutic efficacy in the different clinical situations in which it has been employed, together with a precise and fast performance, speeding restorative tissue processes, reducing pain and postoperative edema.

These peculiar characteristics make the diode laser a user-friendly tool of undoubtedly help in different pediatric dentistry settings.

## REFERENCES

- [1] Pick RM, Powell GL. Lasers in dentistry: Soft-tissue procedures. *Dent. Clin. North Am.* 1993; 31: 281-297.
- [2] Gutknecht N. *Proceedings of the 1st International Workshop of Evidence Based Dentistry on Lasers in Dentistry*. UK: Quintessence Publishing, 2007.
- [3] Crippa R, Barone M, Benedicenti S. *Laser a diodi in odontoiatria*. Italy: Edi-Ermes, 2008.
- [4] Maggioni M, Attanasio T, Scarpelli F. *I Laser in Odontoiatria*. Italy: Piccin, 2009.
- [5] Coluzzi DJ. An overview of laser wavelengths used in dentistry. *Dent. Clin. North Am.* 2000; 44: 753-765.
- [6] Kotlow LA. Lasers in pediatric dentistry. *Dent. Clin. North Am.* 2004; 48: 889-922.
- [7] Stabholz A, Zeltser R, Sela M, Peretz B, Moshonov J, Ziskind D, Stabholz A. The use of lasers in dentistry: principles of operation and clinical applications. *Compen. Contin. Educ. Dent.* 2004; 24: 935-948.
- [8] Nelson JS, Berns MW. Basic laser physics and tissue interactions. *Contemp. Dermatol* 1998; 2: 3-10.
- [9] Goharkhay K, Moritz A, Wilder-Smith P, Schoop U, Kluger W, Jakolitsch S, Sperr W. Effects on oral soft tissue produced by a diode laser in vitro. *Lasers Surg. Med.* 1999; 25: 401-406.
- [10] Saltzman B, Sigal M, Clokie C, Rukavina J, Titley K, Kulkarni GV. Assessment of a novel alternative to conventional formocresol-zinc oxide eugenol pulpotomy for the treatment of pulpally involved human primary teeth: diode laser-mineral trioxide aggregate pulpotomy. *Int. J. Paediatr. Dent.* 2005; 15: 437-447.
- [11] Koch G, Poulsen S. *Pediatric dentistry. A clinical approach*. 2nd ed. Oxford: Wiley-Blackwell, 2009.
- [12] Maturo P, Costacurta M, Bartolino M, Docimo R. MTA applications in pediatric dentistry. *Oral. and Implantology* 2009; 2: 37-44.
- [13] Gutknecht N, Alt T., Slaus G, Bottenbergd P, Rosseel P, Lauwers S, Lampert F. A Clinical Comparison of the Bactericidal Effect of the Diode Laser and 5% Sodium Hypochlorite in Necrotic Root Canals. *J. Oral. Laser Applications* 2002; 2: 151-157.

- 
- [14] Moritz A, Gutknecht N, Schoop U, Goharkhay K, Doertbudak O, Sperr W. Irradiation of infected root canals with a diode laser in vivo: results of microbiological examinations. *Lasers Surg. Med.* 1997; 21: 221-226.
- [15] Kreisler M. Clinical efficacy of semiconductor laser application as an adjunct to conventional scaling and root planning. *Laser Surg. Med.* 2005; 37: 350-355.
- [16] Zegarelli EV, Kutscher AH, Hyman G A. Anomalies and malformations. In: Zegarelli EV, Kutscher AH, Hyman GA. *Diagnosis of Diseases of the Mouth and Jaws*. Philadelphia: Lea and Febiger, 1978; 512-513.
- [17] Matsumoto K, Hossain M. Frenectomy with the Nd: YAG laser: A clinical study. *J. Oral Laser Appl.* 2002; 2: 25-30.
- [18] Koerner KR, Tilt LV, Johnson KR. Management of the abnormal frenum. In: *Color Atlas of Minor Oral Surgery*. London: Mosby-Wolfe, 1994; 173-198.
- [19] Gontijo I, Navarro RS, Haypek P, Ciamponi AL, Haddad AE. The Applications of Diode and Er: YAG Lasers in Labial Frenectomy in Infant Patients. *J. Dent. Child* 2005; 72: 10-15.
- [20] Fernando C. *Tongue-tie from confusion to clarity. A guide to the diagnosis and treatment of ankyloglossia*. Sydney: Tandem Publications, 1998.
- [21] Bimstein E, Needleman H. *Periodontal and gingival health and diseases: children, adolescents, and young adults*. London: Martin Dunitz, 2001.
- [22] Olivi G, Costacurta M, Maturo P, Docimo R. Removal of fibrous epulis with Er,Cr:YSGG laser: case report. *Eur. J. Paediatr. Dent.* 2007; 8: 149-152.
- [23] Docimo R, Barlattani A Jr., Maturo P, Costacurta M, Perugia C. L'impiego del laser Er:YAG in odontoiatria infantile. *Dental Cadmos* 2003; 2: 75-81.
- [24] Pirnat S. Versatility of an 810 nm Diode Laser in Dentistry: An Overview. *J. Laser Health Acad.* 2007; 4: 1-9.
- [25] Rossman JA, Cobb CM. Lasers in periodontal therapy. *Periodontology 2000* 1995; 9: 150-164.
- [26] Scardina GA. Critical reading of a scientific article: Scientific validity. *Int. J. Clin. Dent.* 2009;2(4):205-206.