

Thin-plate spline analysis of mandibular morphological changes induced by early class III treatment: a long-term evaluation

Lorenzo Franchi^{*,**}, Chiara Pavoni^{***}, Silvia Cerroni^{***} and Paola Cozza^{***}

^{*}Department of Surgery and Translational Medicine—Orthodontics, University of Florence, Florence, Italy, ^{**}Department of Orthodontics and Pediatric Dentistry, University of Michigan, Ann Arbor, USA, ^{***}Department of Orthodontics, The University of Rome 'Tor Vergata', Rome, Italy

Correspondence to: Lorenzo Franchi, Department of Surgery and Translational Medicine—Orthodontics, Via del Ponte di Mezzo, 46-48, Firenze 50127, Italy. E-mail: lorenzo.franchi@unifi.it

SUMMARY

OBJECTIVE: To evaluate the long-term mandibular morphological changes induced by early treatment of class III malocclusion with rapid maxillary expansion (RME) and facial mask (FM).

MATERIALS AND METHODS: Twenty-five subjects [10 boys, 15 girls; mean age at T1 (start of treatment) 9.3 ± 1.6 years] with class III disharmony were treated with RME and FM therapy followed by fixed appliances. The patients were re-evaluated at the end of growth (T2), about 8.5 years after the end of the treatment (mean age, 18.6 ± 2.0 years). Sixteen subjects with untreated class III malocclusion comprised the control group. Mandibular shape changes were analysed on the lateral cephalograms of the subjects of both groups by means of thin-plate spline (TPS) analysis. Procrustes average mandibular configurations were subjected to TPS analysis by means of both cross-sectional between-group comparisons at T1 and at T2 and longitudinal within-group comparisons. Statistical analysis of shape differences was performed using a generalized Goodall F test.

RESULTS: In the long term, the treated group exhibited a significant upward and forward direction of condylar growth. On the contrary, untreated class III subjects showed an upward and backward direction of condylar growth associated with a downward and forward deformation of the mandibular symphysis.

LIMITATIONS: Limitations are related to the small sample size of both treated and control groups and to the retrospective nature of the study.

CONCLUSIONS: Early treatment of class III malocclusion with RME and FM is able to produce significant and favourable long-term mandibular shape changes characterized by an anterior morphogenetic rotation.

Introduction

Treatment of class III malocclusion in growing patients is one of the most challenging orthodontic endeavours, due mostly to the uncertainty of a stable outcome at the end of the active growth period. A series of treatment approaches has been proposed in the literature regarding orthopaedic and orthodontic treatment in class III malocclusion (Toffol *et al.*, 2008). However, the mechanism of action of the different treatment protocols on both the maxilla and the mandible still needs to be elucidated, especially when referred to long-term effects. Owing to the lack of adequate control groups consisting of children with untreated class III malocclusions, little definitive information is available on the long-term mandibular skeletal changes induced by early treatment of class III malocclusion in human beings (Toffol *et al.*, 2008; Cozza *et al.*, 2010). Recently, Masucci *et al.* (2011) investigated into the long-term effects produced by rapid maxillary expansion (RME) and facial mask (FM) by using untreated class III subjects as controls. The authors found that favourable skeletal changes were mainly due to significant improvements in the sagittal position of the mandible. However, the mechanisms that can account for the

long-term favourable mandibular skeletal changes still need to be elucidated.

Thin-plate spline (TPS) analysis has been proposed by Bookstein (1991) as a morphometric tool for the comparison of configuration landmarks in two or more specimens. It is a descriptive method of shape and shape changes that has been developed and implemented as major improvement when compared with conventional cephalometrics (Moyers and Bookstein, 1979). TPS analysis enables the construction of transformation grids that capture the differences in shape independently from size and are available for visual interpretation. In recent times TPS analysis has become increasingly important in orthodontics as a means of investigating modifications in shape related to both facial growth and treatment (Singh *et al.*, 1997; Franchi *et al.*, 2007). Baccetti *et al.* (1999) used TPS analysis to analyse the short-term craniofacial changes in class III patients treated with RME and FM versus untreated class III controls. They found that significant treatment-induced short-term changes involved both the maxilla and the mandible. Alarcòn *et al.* (2011) elucidated the short-term treatment response mechanisms of the mandible after early chin cup treatment with

TPS analysis. Their findings support the claim that early chin cup treatment widely modifies the mandibular shape in prognathic children in a way that improves class III malocclusion in the short term. Chang *et al.* (2005) investigated the short-term effects induced by maxillary protraction combined with chin cup therapy by using TPS analysis. Major skeletal effects consisted of forward advancement of the maxillary complex with negligible rotation of the palatal plane and a forward direction of growth of the mandibular condyle associated with a restriction in sagittal advancement of the chin.

No data are available in the literature with regard to the long-term changes produced by early orthopaedic treatment of class III malocclusion and assessed with a morphometric analysis. Since it has been shown that significant long-term modifications following early class III treatment are located mainly in the mandibular region (Masucci *et al.*, 2011) the aim of present study was to evaluate, by means of TPS analysis, the long-term mandibular morphological changes induced by early treatment of class III malocclusion with RME and FM.

Subjects and methods

Subjects

The treated group consisted of 25 class III patients (10 males, 15 females), who were consecutively treated at the University of Florence and the University of Rome 'Tor Vergata'. The success of therapy at the end of the observation period was not a determining factor for the selection of patients.

All patients had the following dentoskeletal features before therapy (T1, mean age 9.3 ± 1.6 years) when the pre-treatment lateral cephalogram was taken: anterior crossbite or edge-to-edge incisor relationship, class III molar relationship, Wits appraisal of -2.0 mm or less, no discrepancy between centric occlusion and centric relation (indicating pseudo-class III malocclusion), and prepubertal skeletal maturation (CS1–CS3; Baccetti *et al.*, 2005). The stages of cervical vertebral maturation were determined by an operator (L.F.) calibrated in this method. No permanent teeth were congenitally missing or extracted before or during treatment.

All patients were re-evaluated at a follow-up observation (T2, 18.6 ± 2.0 years, CS6) with a set of lateral cephalograms at an average time after T1 of 9.3 ± 2.0 years.

Sixteen subjects (11 males, 5 females) with untreated class III malocclusion were selected from the files of the University of Florence and from the American Association of Orthodontists Foundation Craniofacial Growth Legacy Collection (<http://www.aeoflegacycollection.org>, Bolton–Brush Growth Study, Michigan Growth Study, Denver Growth Study, Oregon Growth Study, and Burlington Growth Study) to comprise the control group. Mean age at T1 was 8.9 ± 1.7 years, mean age at T2 was 18.2 ± 1.7 years,

and mean T1–T2 interval was 9.3 ± 2.2 years. The control sample matched the treated group as to type of dentoskeletal disharmony, chronologic age at T1 and T2, duration observation interval, skeletal maturation at T1 and T2, and gender distribution (chi-square with Yates correction = 2.179, $P = 0.140$).

Treatment protocol

Treatment consisted of a first phase of RME either with a bonded or banded maxillary expander. The activation rate of the expander was 1–2 times per day until the desired transverse width was achieved. RME was followed immediately by the application of FM with the elastics stretched from the soldered hooks on the expander to the support bar of the FM in a downward and forward direction (30 degrees to the occlusal plane). The extraoral elastics developed orthopaedic forces of 400–500 g per side. Patients were instructed to wear the facemask for a minimum of 14 hours per day. All patients were treated at least to a positive dental overjet before discontinuing treatment; most patients were overcorrected toward a class II occlusal relationship. Average duration of RME and FM treatment was 1.1 years \pm 5 months.

Twenty-two out of 25 subjects (88 per cent of the cases) underwent a second phase of preadjusted edgewise therapy after an interim period, during which a removable mandibular retractor (Tollaro *et al.*, 1995) typically was worn, or in a few instances immediately following the rapid maxillary expansion and protraction treatment. On average, fixed appliance therapy lasted 18 months. After removal of fixed appliances the patients wore a standard Hawley retainer at night for about 2 years, and thereafter they wore no retention appliances.

TPS analysis

The following homologous anatomical mandibular landmarks were digitized on the lateral films of all subjects at T1 and T2: point B (B), pogonion (Pg), gnathion (Gn), menton (Me), antegonial notch (An, the deepest point of the concavity of the antegonial notch), gonion (Go), posterior border of the ramus (Pb, the deepest point of the concavity of the posterior border of the mandibular ramus), articulare (Ar), condylion (Co), and articulare anterior (Ara; Figure 1).

Based on lateral films, cephalograms of all the subjects were hand traced on a 0.03-inch thick-frosted acetate paper by a single investigator (C.P.) and checked by another investigator (L.F.). Landmarks for the description of the mandibular region were digitized by means of appropriate software (Viewbox 3.1, dHAL Software, Kifissia, Greece) and a digitizing table (Numonics, Lansdale, Pennsylvania, USA). In this study a TPS software (tpsRegr, version 1.38, Ecology & Evolution, SUNY, Stonybrook, New York, USA) computed the orthogonal least squares Procrustes average configuration of mandibular landmarks in both treated and control groups by using the generalized orthogonal least squares

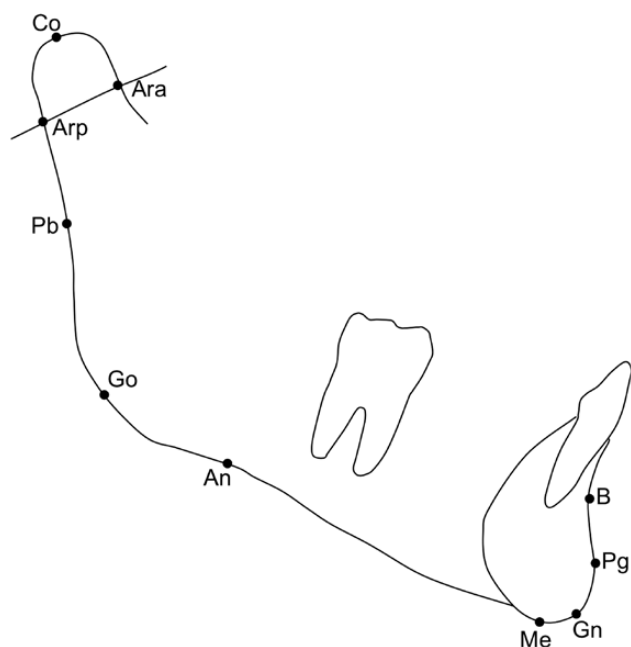


Figure 1 Cephalometric mandibular anatomical landmarks. B, point B; Pg, pogonion; Gn, gnathion; Me, menton; An, antegonial notch; Go, gonion; Pb, posterior border of the ramus; Ar, articulare; Co, condylion; Ara, articulare anterior.

procedure described by Rohlf and Slice (1990). Procrustes average configurations were subjected to TPS analysis by means of both cross-sectional comparisons of the treated group versus the control group at T1 and T2 and longitudinal T1–T2 comparisons within the treated and control groups.

Statistical analysis of shape differences was performed by calculating residuals from Procrustes analysis and by comparing these residuals using a generalized Goodall F test (tpsRegr, version 1.38, Ecology & Evolution, SUNY, Stonybrook, New York, USA).

Centroid size was used as the measure of the geometric size of mandibular region and it was calculated as the square root of the sum of the squared distances from each landmark to centroid of each specimen's configuration of landmarks (Bookstein, 1991).

For those comparisons showing significant shape differences, a test for allometry (Hotelling's *T*-square test) checking for shape depending on size was carried out (tpsRegr, version 1.38, Ecology & Evolution, SUNY, Stonybrook, NY).

To analyse the combined error of landmark location, tracing, and digitization error of the method, 20 randomly selected cephalograms were re-traced and re-digitized by the same operator (L.F.) to evaluate method error. Method of moments' estimator (Springate, 2012) was used to calculate the method error as a combination of location of landmarks, tracing, and digitization for the X and Y co-ordinates of every cephalometric landmark. The method error ranged from a minimum of 0.20 mm (Y co-ordinate of point Co) to a maximum 0.54 mm (Y co-ordinate of point Go).

Results

TPS analysis allowed the analysis of both cross-sectional and longitudinal shape changes in the mandibular configurations of both treated and control subjects.

As for the cross-sectional comparisons, no statistically significant mandibular shape changes ($P = 0.3233$) were found when comparing the treated and the control groups at T1 (Table 1 and Figure 2).

When comparing the treated and control samples at T2 (Table 1 and Figure 3), statistically significant ($P < 0.001$) mandibular shape changes were found with the greatest deformation located in the mandibular posterior region. This deformation could be described as a vertical extension and horizontal compression in the region of the mandibular condyle associated mainly with an upward and forward dislocation of point Co in the treated group versus the control group. The vertical extension in the gonial region was due mostly to a downward dislocation of point Go. In the anterior region the treated group showed a vertical extension and horizontal compression due to an upward and backward dislocation of points B, Pg, and Gn.

The longitudinal T1–T2 comparison in the treated group revealed statistically significant ($P < 0.001$) mandibular shape changes (Table 1 and Figure 3) that were similar to those of the cross-sectional comparison between treated and control samples at T2 (Figure 3). This deformation could be described as a vertical extension and horizontal compression in the region of the mandibular condyle associated mainly with an upward and forward dislocation of point Co. The vertical extension in the gonial region was due to a downward dislocation of both points Go and An. In the anterior region the treated group at T2 showed a vertical extension and horizontal compression due mainly to a backward and upward dislocation of point B.

Figure 4 reports the longitudinal T1–T2 mandibular shape changes in the control group. The control group showed statistically significant ($P < 0.001$; Table 1) mandibular shape differences that were in the opposite direction with respect to the longitudinal mandibular shape changes in the treated group. In the condylar region shape changes were characterized by a horizontal extension associated mainly with a backward dislocation of point Co. The vertical extension in

Table 1 Sum of residuals, *F*-values, and probability of statistical equivalence between mean mandibular configurations for the treatment group (TG) and control group (CG) groups as determined by Procrustes analysis (T1, start of treatment; T2, long-term observation).

Group	Sum of residuals	<i>F</i> -value	<i>P</i> -value
TG versus CG at T1	0.063226	0.981	0.476
TG versus CG at T2	0.090909	3.700	0.000
TG at T1 versus TG at T2	0.094551	7.314	0.000
CG at T1 versus CG at T2	0.059554	2.799	0.000

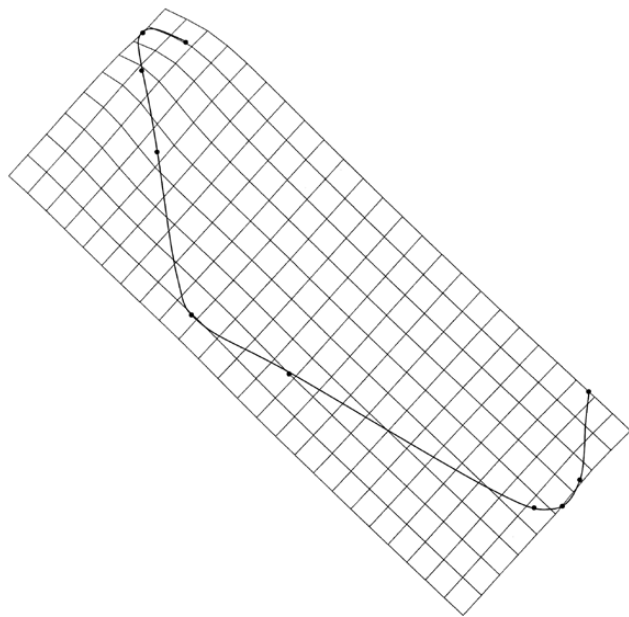


Figure 2 Thin-plate spline (TPS) graphical display of cross-sectional mandibular shape changes between the control group and the treated group at T1 (magnification factor $\times 4$).

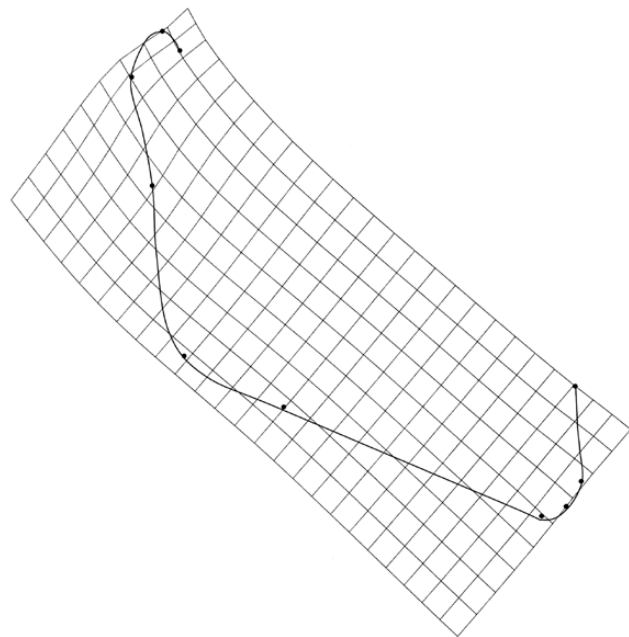


Figure 3 Thin-plate spline (TPS) graphical display of cross-sectional mandibular shape changes between the control group and the treated group at T2 (magnification factor $\times 4$).

the gonial region was due mostly to a downward dislocation of point An. In the anterior region there was a horizontal extension of the symphyseal region with a forward dislocation of point Pg and Gn associated with a horizontal compression of the alveolar region due to a backward dislocation of point B.

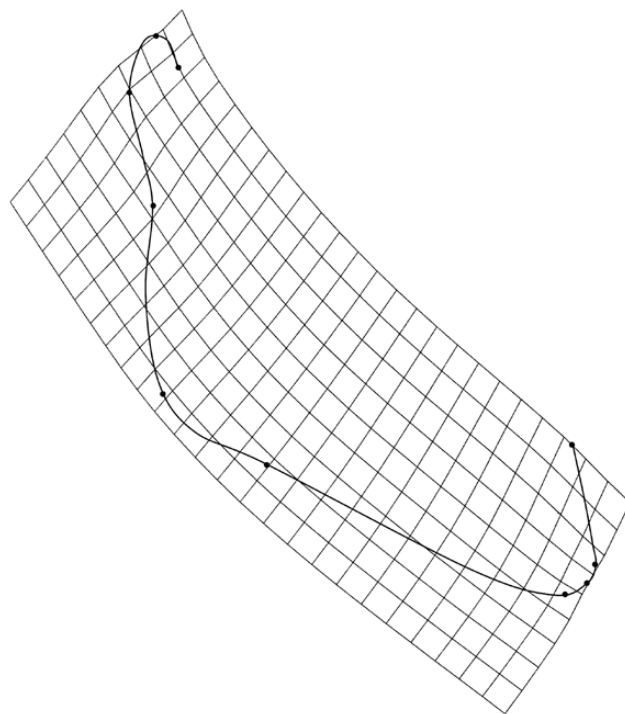


Figure 4 Thin-plate spline (TPS) graphical display of longitudinal T1–T2 mandibular shape changes in the treated group (magnification factor $\times 4$).

The test for allometry showed that the significant mandibular shape changes were not significantly dependent on size differences either in the cross-sectional comparison between the treated and control samples at T2 (Hotelling's T -square test: 0.415; $P = 0.500$) or in the longitudinal T1–T2 comparison in the treated group (Hotelling's T -square test: 0.871; $P = 0.928$) or in the longitudinal T1–T2 comparison in the control group (Hotelling's T -square test: 0.443; $P = 0.732$).

Discussion

The aim of this study was to analyse the mandibular long-term changes produced by RME and FM therapy in growing class III patients with respect to an untreated class III sample by means of TPS analysis. Major advantages of TPS analysis applied to cephalometric landmark configurations with respect to conventional cephalometrics include optimal superimposition of landmarks for analysis of shape changes independently of size changes in complex skeletal configurations without the use of any conventional reference line and visual interpretation of craniofacial shape differences with the use of transformation grids (Bookstein, 1991).

Skeletal effects of nonsurgical therapy of class III malocclusions in growing subjects still represent a controversial topic in orthodontics. A recent long-term controlled study (Masucci *et al.*, 2011) on the effects of RME and FM showed favourable modifications recorded in the mandible while no significant changes were found in the maxilla. Mandibular

skeletal changes consisted of a reduction of mandibular length (though not statistically significant), significant improvements in the sagittal position, and no tendency to an increase in the vertical skeletal relationships. The current investigation, therefore, was aimed at elucidating the mechanisms that could account for the favourable mandibular skeletal changes by means of a morphometric analysis.

TPS analysis showed that significant mandibular shape changes could be recorded in the cross-sectional comparison between the treated and the control samples at T2 and in the longitudinal T1–T2 comparisons within the treated group and the control group. Comparable shape changes were found in the cross-sectional comparison between the treated and the control samples at T2 and in the longitudinal T1–T2 comparisons within the treated group (Figures 3 and 4). These significant deformations involved mainly the mandibular condyle that exhibited an upward-forward direction of growth. In the longitudinal T1–T2 comparison within the treated sample a backward and upward dislocation of point B was also evident, most probably as a result of dentoalveolar compensation with lingual inclination of the lower incisors. The upward-forward direction of condylar growth can be interpreted as a sign of an anterior morphogenetic rotation of the mandible (Lavergne and Gasson, 1977) that is characterized by an anterior rotation of the mandibular body associated with an upward-forward direction of condylar growth. According to Lavergne and Gasson (1977) this biological mechanism is effective in ‘dissipating’ excessive growth of the mandible relative to the maxilla and therefore it appears to be particularly favourable in controlling mandibular growth in class III patients. In other words, the mandible tends to ‘shrink’ along the direction of total mandibular length (Co–Gn) as illustrated in Figures 3 and 4.

Anterior morphogenetic rotation of the mandible with an upward and forward direction of condylar growth has been described with cephalometric superimpositions as a major treatment effects in children with class III malocclusion treated with other orthopaedic devices (Mitani and Sakamoto, 1984; Ferro *et al.*, 2003) and with functional appliances (Tollaro *et al.*, 1995; Saleh *et al.*, 2013). Mandibular anterior morphogenetic rotation was also revealed to occur as a short-term effect associated with early treatment of class III malocclusion with either RME and FM (Baccetti *et al.*, 1999) or maxillary protraction combined with chin cup (Chang *et al.*, 2005). These authors showed that the effects of therapy on the mandible could be described as a forward direction of condylar growth associated with a restriction in sagittal advancement of the symphysis. Recently, Alarcón *et al.* (2011) by using TPS analysis demonstrated that also early chincup treatment is able to induce mandibular anterior morphogenetic rotation in the short term. Chincup treatment altered mandibular shape, with a change in the orientation of the mandibular condyle from backward and upward before treatment to forward and upward after treatment. The gonial area was also compressed, thereby closing the gonial angle. The current study showed that the anterior morphogenetic

rotation of the mandible can be assessed also in the long term as a result of RME and FM therapy.

The present study also elucidated some interesting aspects of mandibular growth in subjects with untreated class III malocclusion in the long term. Untreated class III subjects (Figure 5) showed mandibular shape changes that were in an opposite direction with respect to treated patients (Figure 4). An upward and backward direction of condylar growth was associated with a downward and forward deformation of the mandibular symphysis and backward and upward dislocation of point B, most probably as a result of dentoalveolar compensation. These changes depict a tendency to a posterior morphogenetic rotation of the mandible, a mechanism that appears to be unfavourable in class III malocclusion since it produces a mandibular ‘stretching’ along the direction of total mandibular length (Co–Gn; Figure 5). This result corroborates previous findings by Baccetti *et al.* (2007) who found that untreated class III disharmony in Caucasian subjects worsens along with growth and that the need of appropriate orthopaedic intervention in growing class III individuals is, therefore, demanded. The results of the current investigation, though interesting, need to be corroborated by similar studies conducted on larger samples of treated and control subjects possibly with a randomized controlled trial design.

Conclusions

Early treatment of class III malocclusion with RME and FM is able to produce significant and favourable long-term mandibular shape changes characterized by an anterior morphogenetic rotation, with the condyle showing an upward and

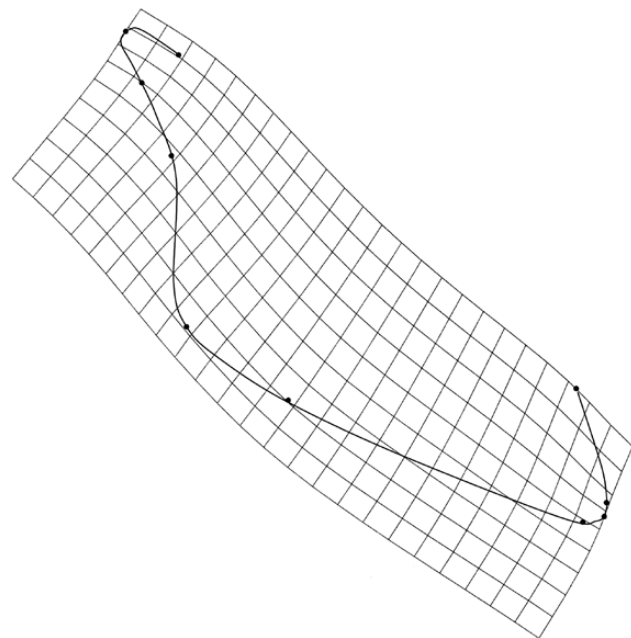


Figure 5 Thin-plate spline (TPS) graphical display of longitudinal T1–T2 mandibular shape changes in the control group (magnification factor $\times 4$).

forward growth direction. On the contrary, if left untreated, class III malocclusion shows significant and unfavourable long-term mandibular shape changes characterized by a posterior morphogenetic rotation, with the condyle exhibiting an upward and backward growth direction and the mandibular symphysis showing a deformation in an forward direction.

References

- Alarcón J A, Bastir M, Rosas A, Molero J 2011 Chincup treatment modifies the mandibular shape in children with prognathism. *American Journal of Orthodontics and Dentofacial Orthopedics* 140: 38–43
- Baccetti T, Franchi L, McNamara J A Jr 2007 Growth in the untreated class III subject. *Seminars in Orthodontics* 13: 130–142
- Baccetti T, Franchi L, McNamara J A Jr 2005 The cervical vertebral maturation (CVM) method for the assessment of optimal treatment timing in dentofacial orthopedics. *Seminars in Orthodontics* 11: 119–129
- Baccetti T, Franchi L, McNamara J A Jr 1999 Thin-plate spline analysis of treatment effects of rapid maxillary expansion and face mask therapy in early class III malocclusions. *European Journal of Orthodontics* 21: 275–281
- Bookstein F L 1991 *Morphometric Tools for Landmark Data*. Cambridge University Press, New York
- Chang H P, Lin H C, Liu P H, Chang C H 2005 Geometric morphometric assessment of treatment effects of maxillary protraction combined with chin cup appliance on the maxillofacial complex. *Journal of Oral Rehabilitation* 32: 720–728
- Cozza P, Baccetti T, Mucedero M, Pavoni C, Franchi L 2010 Treatment and posttreatment effects of a facial mask combined with a bite-block appliance in class III malocclusion. *American Journal of Orthodontics and Dentofacial Orthopedics* 138: 300–310
- Toffol L D, Pavoni C, Baccetti T, Franchi L, Cozza P 2008 Orthopedic treatment outcomes in class III malocclusion. A systematic review. *The Angle orthodontist* 78: 561–573
- Ferro A, Nucci L P, Ferro F, Gallo C 2003 Long-term stability of skeletal class III patients treated with splints, class III elastics, and chincup. *American Journal of Orthodontics and Dentofacial Orthopedics* 123: 423–434
- Franchi L, Baccetti T, Stahl F, McNamara J A Jr 2007 Thin-plate spline analysis of craniofacial growth in class I and class II subjects. *The Angle orthodontist* 77: 595–601
- Lavergne J, Gasson N 1977 Operational definitions of mandibular morphogenetic and positional rotations. *Scandinavian Journal of Dental Research* 85: 185–192
- Masucci C, Franchi L, Defraia E, Mucedero M, Cozza P, Baccetti T 2011 Stability of rapid maxillary expansion and facemask therapy: a long-term controlled study. *American Journal of Orthodontics and Dentofacial Orthopedics* 140: 493–500
- Mitani H, Sakamoto T 1984 Chin cap force to a growing mandible. Long-term clinical reports. *The Angle orthodontist* 54: 93–122
- Moyers R E, Bookstein F L 1979 The inappropriateness of conventional cephalometrics. *American Journal of Orthodontics* 75: 599–617
- Rohlf F J, Slice D E 1990 Extensions of the procrustes method for the optimal superimposition of landmarks. *Systematic Zoology* 39: 40–59
- Saleh M, Hajeer M Y, Al-Jundi A 2013 Short-term soft- and hard-tissue changes following class III treatment using a removable mandibular retractor: a randomized controlled trial. *Orthodontics & craniofacial research* 16: 75–86
- Singh G D, McNamara J A Jr, Lozanoff S 1997 Thin-plate spline analysis of the cranial base in subjects with class III malocclusion. *European Journal of Orthodontics* 19: 341–353
- Springate S D 2012 The effect of sample size and bias on the reliability of estimates of error: a comparative study of Dahlberg's formula. *European Journal of Orthodontics* 34: 158–163
- Tollaro I, Baccetti T, Franchi L 1995 Mandibular skeletal changes induced by early functional treatment of class III malocclusion: a superimposition study. *American Journal of Orthodontics and Dentofacial Orthopedics* 108: 525–532