

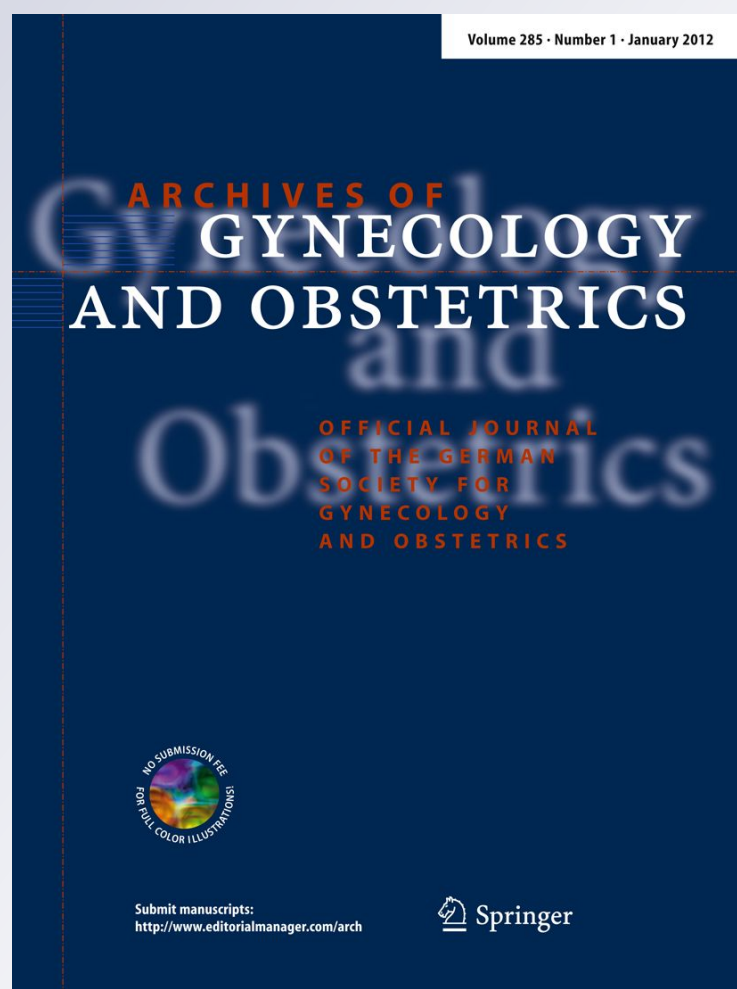
*Multiple ectopic leiomyomas of the abdominal rectus muscles after gasless laparoscopic uterine myomectomy*

**Francesco Sesti, Chiara Di Pietro,  
Antonio Capece & Emilio Piccione**

**Archives of Gynecology and  
Obstetrics**

ISSN 0932-0067  
Volume 285  
Number 3

Arch Gynecol Obstet (2012)  
285:883-885  
DOI 10.1007/s00404-011-2125-1



**Your article is protected by copyright and all rights are held exclusively by Springer-Verlag. This e-offprint is for personal use only and shall not be self-archived in electronic repositories. If you wish to self-archive your work, please use the accepted author's version for posting to your own website or your institution's repository. You may further deposit the accepted author's version on a funder's repository at a funder's request, provided it is not made publicly available until 12 months after publication.**

## Multiple ectopic leiomyomas of the abdominal rectus muscles after gasless laparoscopic uterine myomectomy

Francesco Sesti · Chiara Di Pietro ·  
Antonio Capece · Emilio Piccione

Received: 5 September 2011 / Accepted: 17 October 2011 / Published online: 2 November 2011  
© Springer-Verlag 2011

### Abstract

**Purpose** To describe and analyze the first case of multiple ectopic leiomyomas of the abdominal rectus muscles in a patient who had undergone gasless laparoscopic uterine myomectomy (GLM) 10 years before.

**Methods** A 41-year-old woman, who had undergone GLM 10 years before, having presented multiple palpable masses of the abdominal wall, underwent minilaparotomic excision of six abdominal masses.

**Results** Six round well-circumscribed masses of the abdominal rectus muscles, measuring, respectively,  $3.8 \times 1.7$ ,  $2.9 \times 0.9$ ,  $0.8 \times 0.5$ ,  $0.7 \times 0.3$ ,  $10 \times 0.8$  and  $0.5 \times 0.4$  cm, were excised. The major lesion was situated close to the right trocar site of the previous GLM, the other smaller tumors were located in the umbilical area and left abdominal region. On histopathologic examination, the abdominal lumps were categorized as leiomyoma.

**Conclusions** Ectopic leiomyomatosis is an uncommon complication after GLM, and does not justify follow-up in all asymptomatic cases. However, the gynecologists should bear this unusual condition in mind, and inform the patients that leiomyoma fragments can grow in ectopic sites.

**Keywords** Ectopic leiomyomas · Post-myomectomy leiomyomas · Gasless laparoscopic myomectomy · Uterine leiomyomas

Gasless laparoscopic myomectomy (GLM) was proposed as alternative to CO<sub>2</sub> laparoscopic myomectomy (LM) and classic laparotomy in the management of uterine leiomyomas [1]. GLM offers several advantages over LM. As the peritoneal cavity does not need to be sealed airtight, conventional laparotomy instruments can be used facilitating several steps of the procedure. The operating times are shorter, and closure of the uterine defect is more rapid [2].

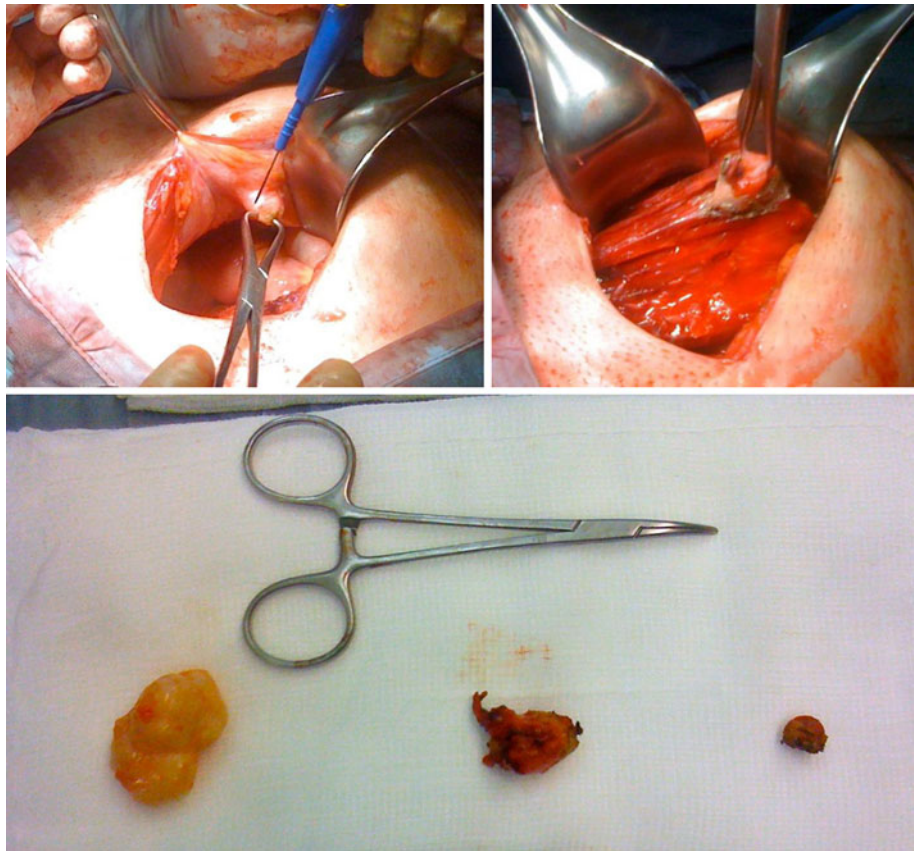
Concerns have been expressed about the risk of incomplete extraction of myoma fragments during LM or laparoscopically assisted myomectomy with subsequent iatrogenic growth of myomas at the ectopic site [3–5]. Others reported cases of disseminated peritoneal leiomyomatosis [6] after LM [7], or laparoscopic supracervical hysterectomy [8].

To our knowledge, no case of aberrant leiomyoma following GLM was described in the literature. A 41-year-old woman presented multiple palpable nonpainful abdominal masses. Transabdominal ultrasound revealed six round well-circumscribed nodules of the abdominal rectus muscles, with diameter measuring between 3.8 and 0.5 cm. Ten years before, the patient had undergone multiple GLM. At that time, five uterine myomas were entirely removed and extracted from the abdominal cavity through the ancillary right port by conversion into thin strips of tissue using conventional scissors and scalpel. In 2006, the patient had a baby by elective cesarean section. The patient underwent, using a suprapubic transverse minilaparotomic access, excision of the six abdominal masses that appeared as solid, round, encapsulated, whitish lesions (Fig. 1). On histopathologic examination, the abdominal lumps were categorized as leiomyoma.

The present case is the first report that multiple fragments of myoma can implant and grow at more ectopic sites many years after GLM. Even though the

F. Sesti (✉) · C. Di Pietro · A. Capece · E. Piccione  
Section of Gynecology and Obstetrics,  
Department of Surgical Sciences, School of Medicine,  
Tor Vergata University Hospital, Viale Oxford,  
81-00133 Rome, Italy  
e-mail: Francesco.Sesti@uniroma2.it

**Fig. 1** Three major leiomyomas of the abdominal rectus muscles



fragmentation of the myoma nodules had moderate compared with power morcellation that is utilized in LM, where it produces smaller fragments so to be extracted through a small abdominal incision, a disseminated ectopic growth of leiomyomas is occurred. Because we did not use any cannula into the accessory ports, this could have facilitated the dissemination and implant of myoma fragments into subfascial tissue. Like residual particles of endometriotic lesions after their surgical removal can grow and cause iatrogenic localizations at various sites, retained myoma fragments can implant and produce ectopic myomas also after many years since the uterine myomectomy.

It is not clear why the ectopic growth of myomas occurs in a low number of patients considering that the surgical technique was always the same in all cases. We have registered only one such case out of our all GLMs. Because there are reports on myomas that have spontaneously lost their connections to the uterus and parasitized other blood supplies [9], also this possible cause for ectopic myomas cannot be excluded, even if our case is plausibly iatrogenic.

When enucleated myomas are extracted, it is important to avoid touching any healthy tissues using wound retractors for removing the myoma fragments. In addition, after intraperitoneal washing in a reverse Trendelenburg position, it is necessary to scrupulously examine the surgical field, and any remaining tissue removed.

In conclusion, ectopic leiomyomatosis is an uncommon complication after GLM, and does not justify follow-up in all asymptomatic cases. Gynecologists should bear this unusual condition in mind, and inform the patients that leiomyoma fragments can grow in ectopic sites.

**Conflict of interest** None.

## References

1. Damiani A, Melgrati L, Marziali M, Sesti F (2003) Gasless laparoscopic myomectomy. Indications, surgical technique and advantages of a new procedure for removing uterine leiomyomas. *J Reprod Med* 48:792–798
2. Damiani A, Melgrati L, Franzoni G, Stepanyan M, Bonifacio S, Sesti F (2006) Isobaric gasless laparoscopic myomectomy for removal of large uterine leiomyomas. *Surg Endosc* 20:1406–1409
3. Moon HS, Koo JS, Park SH, Park GS, Choi JG, Kim SG (2008) Parasitic leiomyoma in the abdominal wall after laparoscopic myomectomy. *Fertil Steril* 90:1201.e1–e2
4. Ostrzenski A (1997) Uterine leiomyoma particle growing in an abdominal-wall incision after laparoscopic retrieval. *Obstet Gynecol* 89:853–854
5. Wada-Hiraike O, Yamamoto N, Osuga Y, Yano T, Kozuma S, Taketani Y (2009) Aberrant implantation and growth of uterine leiomyoma in the abdominal wall after laparoscopically assisted myomectomy. *Fertil Steril* 92:1747.e13–5
6. Kumar S, Sharma JB, Verma D, Gupta P, Roy KK, Malhotra N (2008) Disseminated peritoneal leiomyomatosis: an unusual

- complication of laparoscopic myomectomy. Arch Gynecol Obstet 278:93–95
7. Paul PG, Koshy AK (2006) Multiple peritoneal parasitic myomas after laparoscopic myomectomy and morcellation. Fertil Steril 85:492–493
  8. Sinha R, Sundaram M, Mahajan C, Sambhus A (2007) Multiple leiomyomas after laparoscopic hysterectomy: report of two cases. J Minim Invasive Gynecol 14:123–127
  9. Lurie S, Gorbacz S, Caspi P, Borenstein R (1991) Parasitic leiomyoma: a case report. Clin Exp Obstet Gynecol 18:7–8