

CASE REPORT

Palatal-Implant Anchorage in an Adult Class II Patient

ALDO GIANCOTTI, DDS, MS
MARIO GRECO, DDS
GIANLUCA MAMPIERI, DDS
CLAUDIO ARCURI, DDS, MS

Class II nonextraction treatment can be particularly challenging in adult patients. Although many appliances have been proposed for maxillary molar distalization in such cases,^{1,2} they generally require some degree of patient compliance, and their design causes anchorage loss due to the incorporation of occlusal rests or bands on the premolars.

The introduction of skeletal anchorage has radically changed orthodontists' approach to Class II treatment.^{3,4} Still, there are a few cases in which buccal mini-

screws cannot be inserted because of a lack of interradicular space or an extended maxillary sinus.⁵ At first, only available edentulous spaces could be used for implant insertion,⁶ but the midpalate was subsequently confirmed as a potential site for skeletal orthodontic anchorage in the maxilla.⁷⁻¹⁶

This article shows the use of a modified Hilgers Pendulum¹⁷ appliance, supported by an osseointegrated palatal mini-implant, to gain space in the maxillary arch of an adult patient.

Diagnosis and Treatment Plan

A 25-year-old female presented with moderate crowding in both arches (Fig. 1, Table 1). Clinical examination revealed Class II skeletal and dental relationships, a balanced profile, and a pleasant facial appearance.

Three treatment options were discussed with the patient: extraction of the upper first and lower second premolars to correct the Class II malocclusion; extraction of the upper first premolars



Dr. Giancotti



Dr. Greco



Dr. Mampieri



Dr. Arcuri

Drs. Giancotti and Mampieri are Assistant Professors and Dr. Greco is a postgraduate student, Department of Orthodontics, and Dr. Arcuri is Professor and Chief, Department of Periodontology, University of Rome "Tor Vergata", Rome, Italy. Contact Dr. Giancotti at Viale Gorizia 24/c, 00198 Rome, Italy; e-mail: giancott@uniroma2.it.

Palatal-Implant Anchorage in an Adult Class II Patient

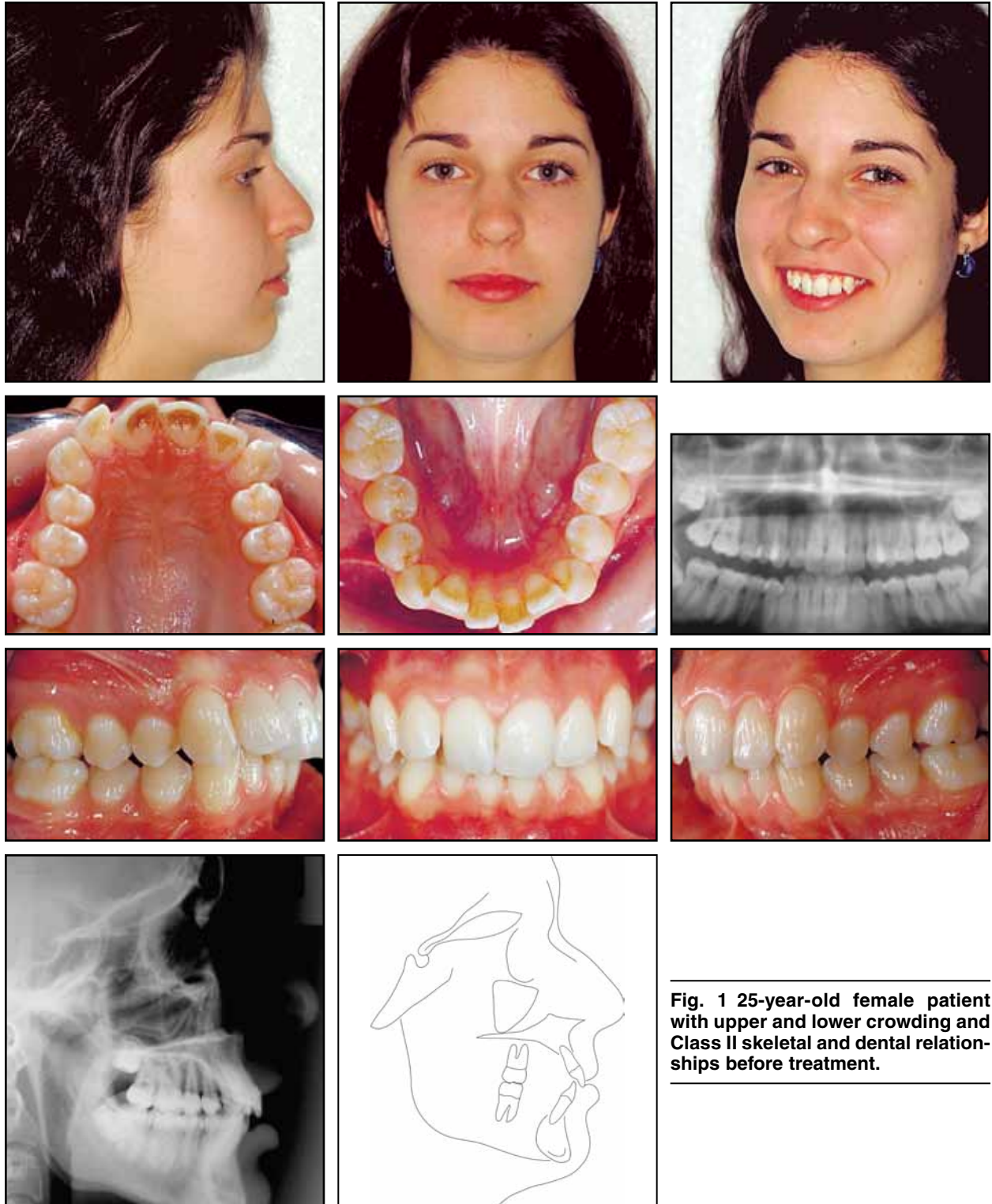


Fig. 1 25-year-old female patient with upper and lower crowding and Class II skeletal and dental relationships before treatment.

TABLE 1
CEPHALOMETRIC DATA

	Norm ± S.D.	Pretreatment	Post-Treatment
SNA	82° ± 3.5	85°	85°
SNPg	80° ± 3.5	80°	80°
ANPg	2° ± 2.5	5°	5°
SN/ANS-PNS	8° ± 3.0	8°	8°
SN/Go-Gn	33° ± 2.5	26°	26°
ANS-PNS/Go-Gn	25° ± 6.0	18°	18°
U1/ANS-PNS	110° ± 6.0	118°	100°
L1/Go-Gn	94° ± 7.0	110°	106°
L1/A-Pg	2.0mm ± 2.0	6mm	3mm
Overjet	3.5mm ± 2.5	4mm	2mm
Overbite	2.0mm ± 2.5	4mm	2mm
Interincisal angle	132° ± 6.0	112°	133°

to compensate for the malocclusion; and nonextraction treatment involving distalization of the maxillary molars. When the patient declined extractions, the third option was chosen. The treatment plan involved anchorage from a temporary midpalatal implant.

Treatment Progress

After some interproximal reduction to reduce crowding, the

lower arch was bonded. A self-threading Orthosystem mini-implant* (6mm × 3mm) was inserted at an angle of about 60° to the occlusal plane, and a healing cap was placed.⁹ After 12 weeks, a polyvinyl siloxane impression of the maxillary arch was taken, using a transfer analog connected to the implant to reproduce the exact position of the implant on the cast.

The distalizing device was

a modified version of the Hilgers Pendulum,^{8,17} which has the advantages of flexibility and ease of activation due to its removable springs. Two arms ending in lingual sheaths were soldered to a stainless steel octagonal cap designed to fit over the mini-implant. Distalizing springs were fabricated from .032" TMA** wire, and the mesially oriented loops were inserted into the lingual sheaths (Fig. 2).

Following Hilgers's recommended procedure for bodily distal movement of the maxillary molars, the two distalizing springs were initially activated at 60° to the horizontal plane, producing 200g of distalizing force. A second activation was performed 12 weeks later to correct the root inclination by bending the two spring ends at 30° to the sagittal plane¹⁷ (Fig. 3).

The distalization phase was

*Registered trademark of Institut Straumann, Waldenburg, Switzerland; www.straumann.com.

**Registered trademark of Ormco, Orange, CA; www.ormco.com.

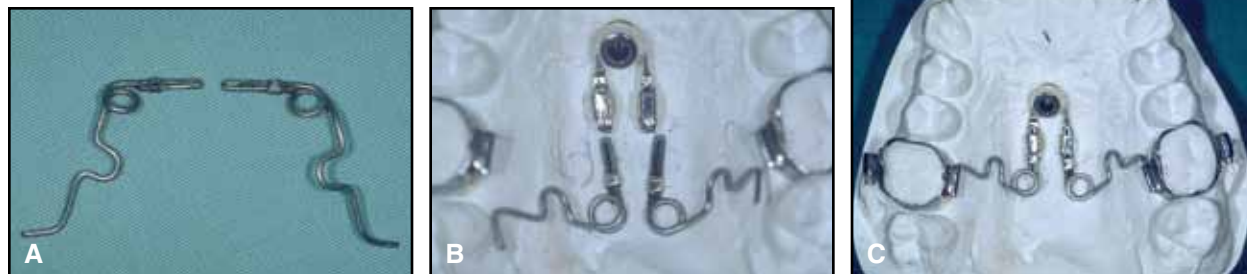

Fig. 2 A. Modified Hilgers Pendulum arms prepared for insertion into palatal-implant sheaths. B. Lingual sheaths soldered to palatal implant, and Pendulum arms activated. C. Completed appliance ready for placement.

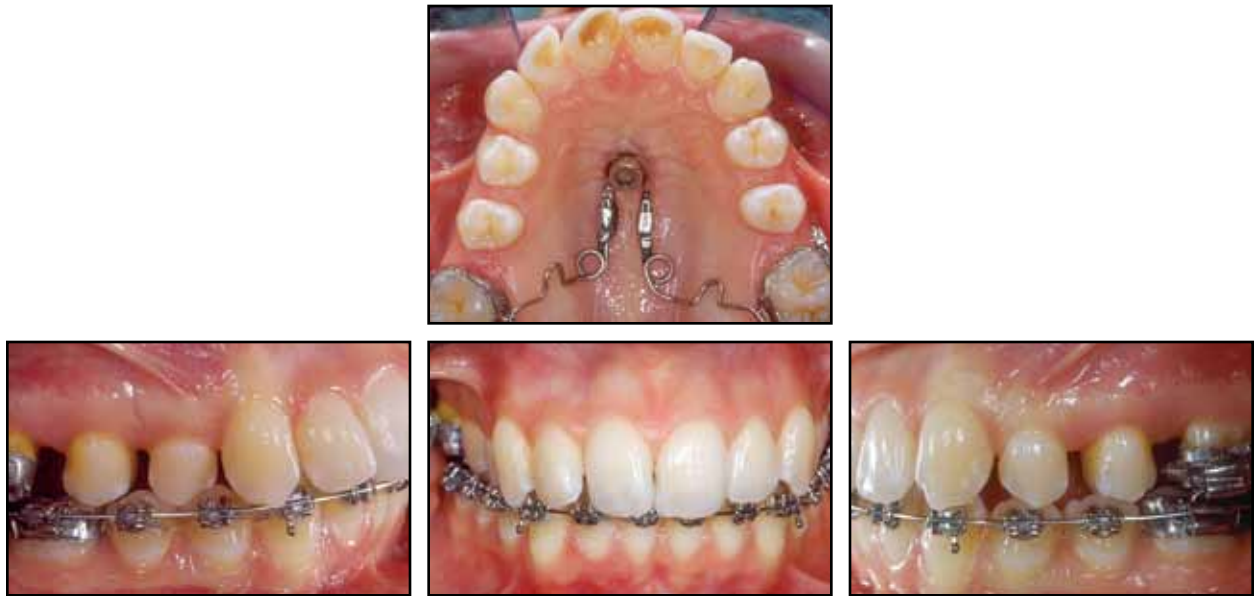

Fig. 3 Second activation of Pendulum springs, after 12 weeks of molar distalization.

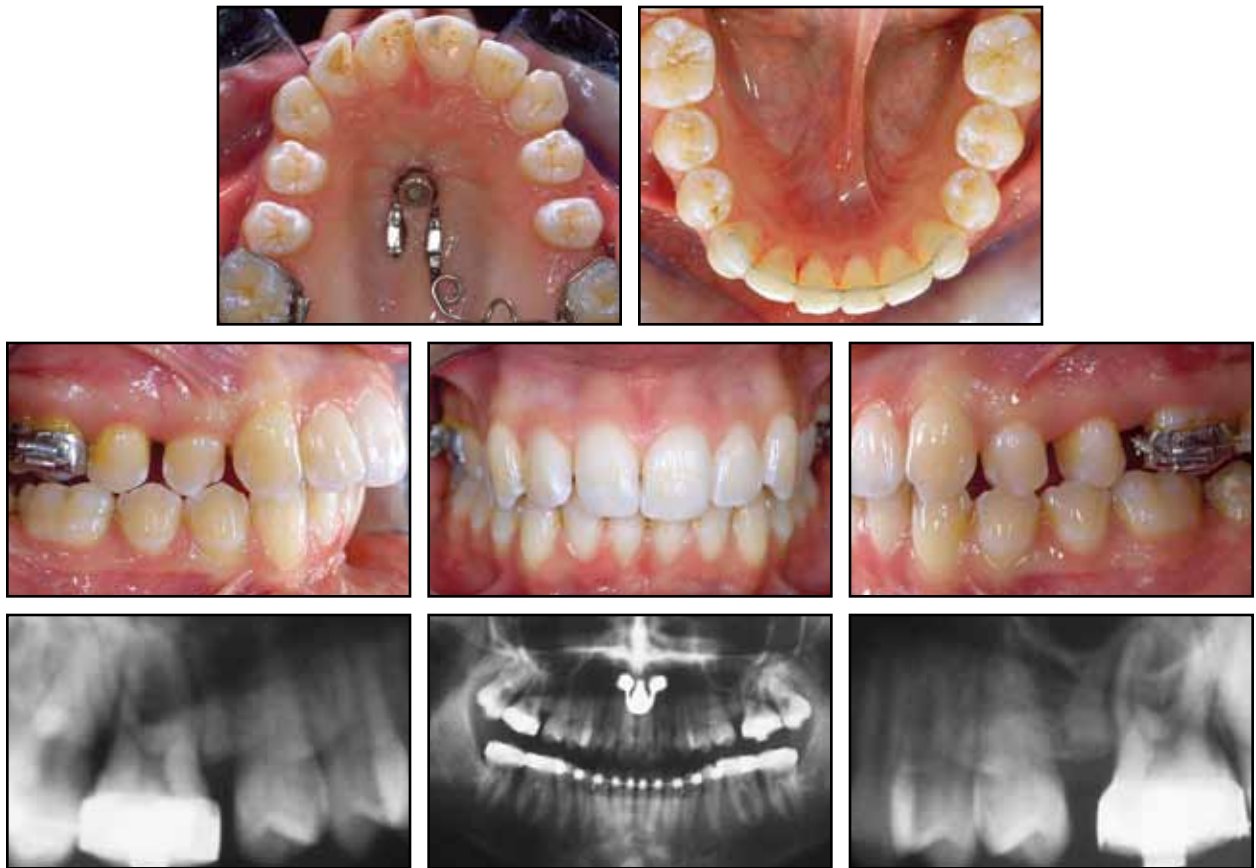

Fig. 4 After six months of maxillary molar distalization, lower brackets removed and lingual retainer bonded. (Radiographs taken before removal of lower brackets.)

completed in six months, with the right side reaching a Class I position first (Fig. 4). A rigid .051" transpalatal bar was then connected to the palatal mini-implant

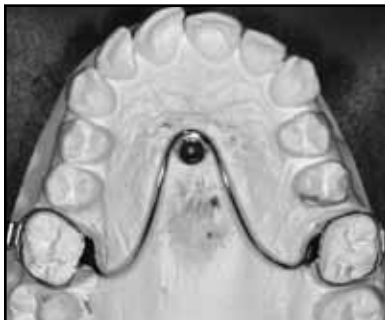

Fig. 5 Palatal bar connected to palatal implant for maintenance of molar positions.

to maintain the molar positions (Fig. 5). The lower brackets were debonded, and a lingual 4-4 retainer was bonded.

As expected, the upper premolars drifted distally over the next five months of this molar-retention phase (Fig. 6). Additional space closure and alignment were carried out in the upper arch using the Bidimensional technique¹⁸ with an .018" × .022" stainless steel archwire. Nickel titanium closed-coil springs (300g) were attached to crimped hooks distal to the lateral incisor brackets for anterior retraction (Fig. 7).

The lower canines through first molars were rebonded for the

finishing phase. An .018" Australian wire^{***} was placed in the upper arch from second premolar to second premolar, and an .018" Australian overlay archwire with an asymmetrical intrusion loop was inserted in the first-molar tubes to align the gingival margins (Fig. 8). The palatal mini-implant was removed after 22 months of treatment.

Treatment Results

Post-treatment evaluation showed Class I molar and canine

***Registered trademark of A.J. Wilcock Pty. Ltd., Whittlesea, Victoria, Australia; distributed in North America by G&H Wire Company, Franklin, IN; www.ghwire.com.

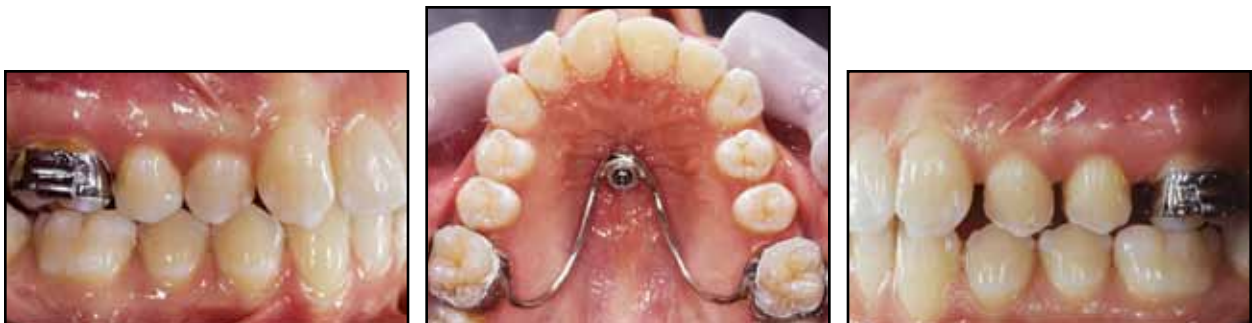

Fig. 6 Distal drifting of premolars after molar distalization.

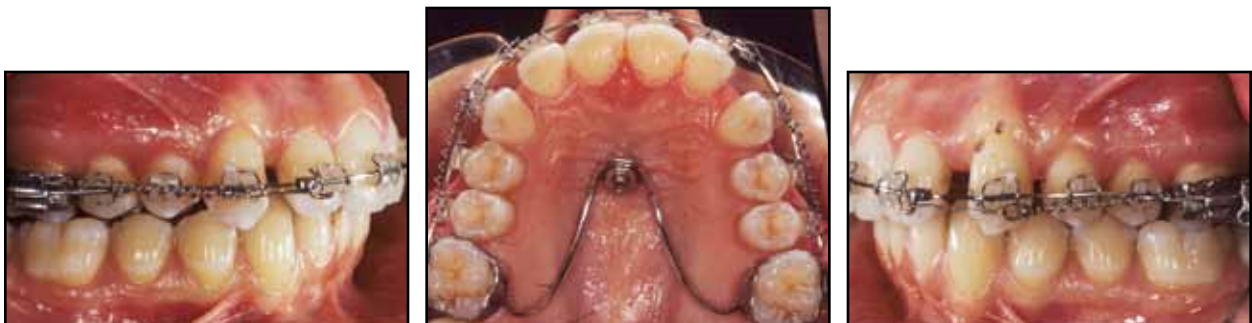

Fig. 7 Bidimensional technique used in upper arch for remaining space closure; hooks crimped on archwire distal to lateral incisors for anterior retraction with 300g nickel titanium closed-coil springs.

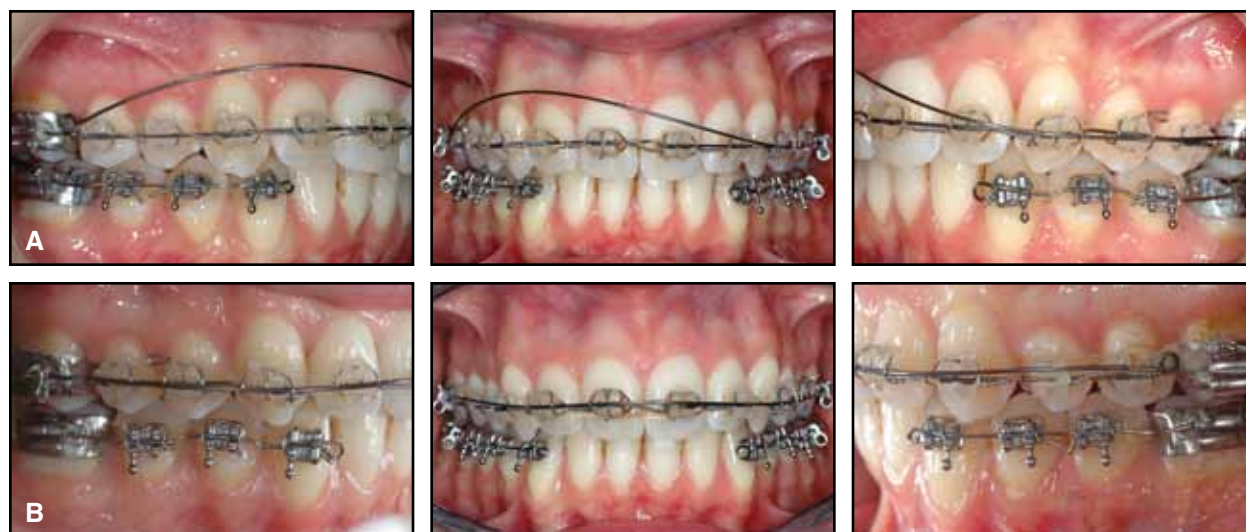


Fig. 8 A. Lower brackets bonded from canines to first molars for finishing; upper overlay wire placed for asymmetrical intrusion to align anterior gingival margin. **B.** After activation of overlay intrusion wire.

relationships with proper overbite and overjet (Fig. 9, Table 1). Cephalometric data and superimpositions indicated no change in the skeletal pattern, except for some important variations in incisor inclination. The upper incisors were retruded 18° , compatible with the amount of space opening during molar distalization. The 4° improvement in lower incisor inclination was attributable to the interproximal stripping for relief of crowding and to the avoidance of Class II elastics, made possible by the use of implant anchorage.

Discussion

In this case, once the patient refused extraction treatment, skeletal anchorage was needed to support the molar-distalization mechanics. Radiographs of the upper arch showed inadequate spac-

es between the second-premolar and first-molar roots for miniscrew placement. Moving the insertion site more gingivally would have placed the screws in the unattached gingiva, increasing the risks of screw failure and sinus penetration.^{4,5} Furthermore, when buccal miniscrews are used as anchorage for maxillary space opening, they must generally be removed and replaced by screws in different locations for the retraction phase.¹² Such a series of insertions, removals, and reinsertions would be no less invasive for an adult patient than the insertion and removal of a single palatal implant would be.

Conclusion

The implant-supported modified Pendulum appliance shown here is an effective option

for Class II nonextraction treatment of adult patients, offering the following advantages:

- A constant force is applied to the molars by the removable distalizing springs, while the reaction force is dissipated through the osseointegrated implant to the palatal bone.
- All phases of treatment can be managed without any risk of anchorage loss or the need for miniscrew repositioning.
- Patient cooperation with removable appliances is not required.
- The system is well accepted by the patient because it is intraoral, fairly inconspicuous, and relatively comfortable to wear.

ACKNOWLEDGMENTS: The authors wish to thank Mr. Stefano Della Vecchia and his staff at Orthosystem Roma for their technical support in fabrication of the appliance.

(continued on p. 634)

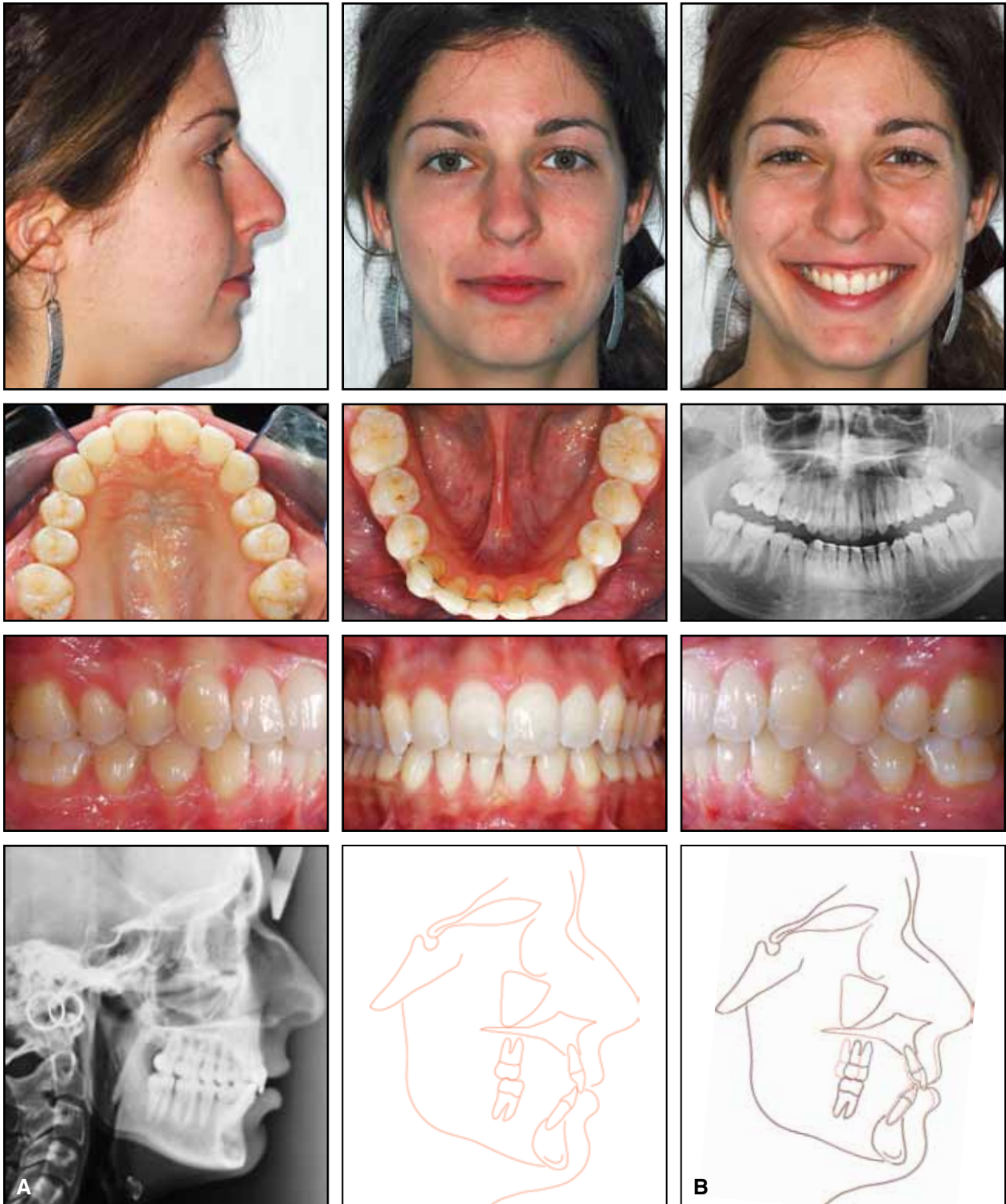


Fig. 9 A. Patient after 22 months of treatment. B. Superimposition of pre- and post-treatment cephalometric tracings.

REFERENCES

1. Antonarakis, G.S. and Kiliaridis, S.: Maxillary molar distalization with non-compliance intramaxillary appliances in Class II malocclusion: A systematic review, *Angle Orthod.* 78:1133-1140, 2008.
2. Kinzinger, G.S.M.; Eren, M.; and Diedrich, P.R.: Treatment effects of intraoral appliances with conventional anchorage designs for non-compliance maxillary molar distalization: A literature review, *Eur. J. Orthod.* 30:558-571, 2008.
3. Block, M.S. and Hoffman, D.R.: A new device for absolute anchorage for orthodontics, *Am. J. Orthod.* 107:251-258, 1995.
4. Carano, A.; Velo, S.; Incorvati, C.; and Poggio, P.: Clinical applications of the Mini-Screw-Anchorage-System in the maxillary alveolar bone, *Prog. Orthod.* 5:212-235, 2004.
5. Kravitz, N.D. and Kusnoto, B.: Risks and complications of orthodontic mini-screws, *Am. J. Orthod.* 131(4 suppl.): S43-51, 2007.
6. Roberts, W.E.; Helm, F.R.; Marshall, K.J.; and Gongloff, R.K.: Rigid endosseous implants for orthodontic and orthopedic anchorage, *Angle Orthod.* 59:247-256, 1989.
7. Bondemark, L.; Feldmann, I.; and Feldmann, H.: Distal molar movement with an intra-arch device provided with the Onplant System for absolute anchorage, *World J. Orthod.* 3:117-124, 2002.
8. Giancotti, A.; Muzzi, F.; Greco, M.; and Arcuri, C.: Palatal implant-supported distalizing devices: Clinical application of the Straumann Orthosystem, *World J. Orthod.* 3:135-139, 2002.
9. Giancotti, A.; Muzzi, F.; Santini, F.; and Arcuri, C.: Straumann Orthosystem method for orthodontic anchorage: Step by step procedure, *World J. Orthod.* 3:140-146, 2002.
10. Giancotti, A.; Greco, M.; Docimo, R.; and Arcuri, C.: Extraction treatment using a palatal implant for anchorage, *Austral. Orthod. J.* 19:87-90, 2003.
11. Giancotti, A.; Greco, M.; Mampieri, G.; and Arcuri, C.: Clinical management in extraction cases using palatal implant for anchorage, *J. Orthod.* 31:288-294, 2004.
12. Giancotti, A.; Greco, M.; Mampieri, G.; and Arcuri, C.: Treatment of ectopic maxillary canines using a palatal implant for anchorage, *J. Clin. Orthod.* 39:607-611, 2005.
13. Maino, B.G.; Mura, P.; and Gianelly, A.A.: A retrievable palatal implant for absolute anchorage in orthodontics, *World J. Orthod.* 3:125-134, 2002.
14. Maino, G.B.; Gianelly, A.A.; Bednar, J.; Mura, P.; and Maino, G.: MGBM system: New protocol for Class II non extraction treatment without cooperation, *Prog. Orthod.* 8:130-143, 2007.
15. Triaca, A.; Antonini, M.; and Wintermantel, E.: Ein neues Titan-Flachschrauben-Implantat zur orthodontischen Verankerung am anterioren Gaumen, *Inf. Orthod. Kieferorthop.* 24:251-257, 1992.
16. Wehrbein, H.; Feifel, H.; and Diedrich, P.: Palatal implant anchorage reinforcement of posterior teeth: A prospective study, *Am. J. Orthod.* 116:678-686, 1999.
17. Hilgers, J.J.: The Pendulum appliance for Class II non-compliance therapy, *J. Clin. Orthod.* 26:706-714, 1992.
18. Gianelly, A.A.: *Bidimensional Technique: Theory and Practice*, GAC International, Central Islip, NY, 2000.