

## References

- Poovorawan Y, Chongsrisawat V, Boudville I, Bock HL. Dengue virus infection: a major cause of acute hepatic liver failure in Thai children. *Ann Trop Paediatr*. 2006;26:17–23. <http://dx.doi.org/10.1179/146532806X90565>
- Deepak NA, Patel ND. Differential diagnosis of acute liver failure in India. *Ann Hepatol*. 2006;5:150–6.
- Carvalho de Macedo F, Nicol AF, Cooper LD, Yearslev M, Pires AR, Nuovo GJ. Histologic, viral and molecular correlates of dengue fever infection of the liver using highly sensitive immunohistochemistry. *Diagn Mol Pathol*. 2006;15:223–8. <http://dx.doi.org/10.1097/01.pdm.0000213462.60645.cd>
- Huerre MR, Lan NT, Marianneau P, Hue NB, Khun H, Hung NT, et al. Liver histopathology and biological correlates in five cases of fatal dengue fever in Vietnamese children. *Virchows Arch*. 2001;438:107–15.
- Deasy NP, Wendon J, Meire HB, Sidhu PS. The value of serial Doppler ultrasound as a predictor of clinical outcome and the need for transplantation in fulminant and severe acute liver failure. *Br J Radiol*. 1999;72:134–43.
- Wachsberg RH, Bahramipour P, Sofocleous CT, Barone A. Hepatofugal flow in the portal venous system: pathophysiology, imaging findings, and diagnostic pitfalls. *Radiographics*. 2002;22:123–40.
- Khongphatthanayothin A, Lertsapcharoen P, Supachokchaiwattana P, Satupan P, Thongchaiprasit K, Poovorawan Y, et al. Hepatosplanchnic circulatory dysfunction in acute hepatic infection: the case of dengue hemorrhagic fever. *Shock*. 2005;24:407–11. <http://dx.doi.org/10.1097/01.shk.0000180981.70870.8c>
- Moriyasu F, Nishida O, Ban N, Nakamura T, Sakai M, Miyake T, et al. “Congestion index” of the portal vein. *AJR Am J Roentgenol*. 1986;146:735–9. <http://dx.doi.org/10.2214/ajr.146.4.735>
- Sahaphong S, Riengrojpitak S, Bhamarapravati N, Chirachariyavej T. Electron microscopic study of the vascular endothelial cell in dengue hemorrhagic fever. *Southeast Asian J Trop Med Public Health*. 1980;11:194–204.
- Helmy A. Review article: updates in the pathogenesis and therapy of hepatic sinusoidal obstruction syndrome. *Aliment Pharmacol Ther*. 2006;23:11–25. <http://dx.doi.org/10.1111/j.1365-2036.2006.02742.x>

Chulalongkorn University, 1873 Rama IV Rd., Pratumwan, Bangkok 10330, Thailand; email: [yong.p@chula.ac.th](mailto:yong.p@chula.ac.th)

## Spotted Fever Group Rickettsiae in Questing Ticks, Central Spain

**To the Editor:** The number of spotted fever group (SFG) rickettsiae that cause diseases in humans is rapidly increasing (1,2); infections have been described in ticks and humans in Spain (3,4). However, in Castilla-La Mancha, central Spain, where recreational parks and hunting estates are abundant and humans may be exposed to infected ticks, information on such infections is not available. Therefore, it is worthwhile to characterize *Rickettsia* spp. found in this area for epidemiologic studies and proper diagnosis of possible rickettsial diseases.

In this study, we obtained 148 questing adult ticks, representing the most abundant species in the area: 12 *Dermacentor marginatus*, 26 *Rhipicephalus bursa*, 41 *Rh. sanguineus*, 15 *Rh. turanicus*, 8 *Rh. pusillus*, 2 *Haemaphysalis punctata*, 11 *Hyalomma lusitanicum*, and 33 *Hyalomma marginatum* (5). The ticks were collected from the vegetation at natural sites surveyed in Castilla-La Mancha by blanket dragging with a cotton flannel during fall 2009 and spring–summer 2010 (Figure, panel A) and classified (5).

Total DNA was extracted from dissected tick internal organs by using the DNeasy Blood & Tissue Kit (QIAGEN, Düsseldorf, Germany) and used to analyze *Rickettsia* spp. DNA by PCR, cloning, and sequence analysis of the amplicons. At least 3 clones were sequenced for each amplicon.

Genes targeted by PCR included fragments of adenosine triphosphate synthase  $\alpha$  subunit (*atpA*), heat-shock protein 70 (*dnaK*), outer membrane protein A (*ompA*), outer membrane protein B (*ompB*), citrate synthase (*gltA*), 16S rRNA, *recA*, and initiator protein of DNA replication (*dnaA*) (6,7). To characterize *Rickettsia* spp., we compared nucleotide sequence identity to reference strains and carried out multilocus analysis using *ompA-ompB* sequences and in silico *PstI* and *RsaI* restriction analysis of *ompA* sequences (7).

Ticks were first screened by 16S rRNA PCR, and positive samples were analyzed for all targeted genes. The results showed that 27 (18.2%) of the 148 ticks analyzed were positive for *Rickettsia* spp. Of these, 11 were confirmed as *R. massiliae* in *Rh. sanguineus*, *Rh. turanicus*, and *Rh. pusillus*, 3 as *R. raoultii* in *D. marginatus*, 2 as *R. slovacica* in *D. marginatus*, and 2 as *R. sibirica* subsp. *mongolitimonae* in *H. marginatum* and *Rh. pusillus* (Figure, panel B). These species had >99% pairwise nucleotide sequence identity to reference strains *R. massiliae* MTU5 (GenBank accession no. NC\_009900), *R. slovacica* 13-B (accession no. NC\_016639), and *R. sibirica* subsp. *mongolitimonae* HA-91 (accession no. AHZB00000000) genome sequences for all genes analyzed, and the only *R. raoultii* reported sequences (accession nos. JQ792107, JQ792166, JQ792134, and NR\_043755 for *ompB*, *ompA*, *gltA*, and 16S rRNA, respectively). The sequences obtained in this study were deposited in the GenBank under accession nos. KC427998–KC428040.

Multilocus sequence analysis of *ompA-ompB* sequences (Figure, panel B) and in silico *PstI* and *RsaI* restriction analysis of *ompA* sequences also confirmed the identity of the *Rickettsia* spp. identified in this study. As previously shown (7,8), multilocus analysis with *ompA-ompB* sequences was highly informative about the

Address for correspondence: Yong Poovorawan, Department of Pediatrics, Faculty of Medicine,

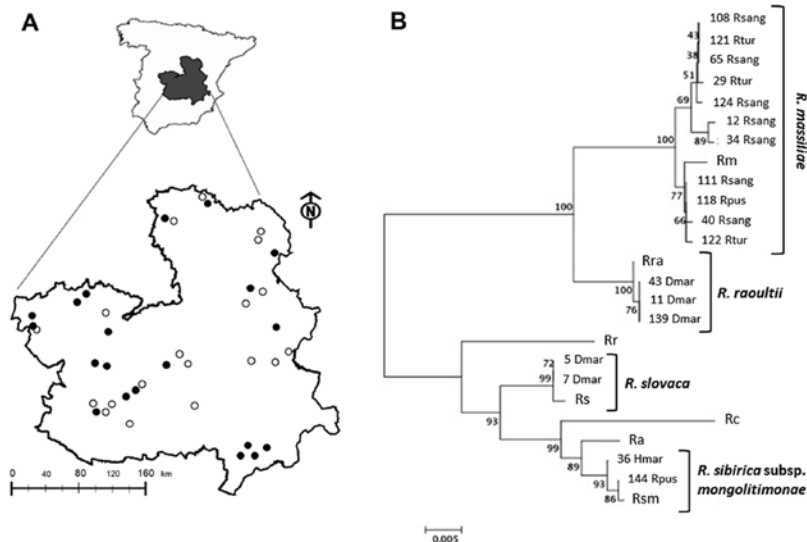


Figure. *Rickettsia* species in questing ticks collected in central Spain. A) Study area with 20 collection sites where ticks were found (black dots) of the 39 sites surveyed (white and black dots). B) Multilocus sequence analysis of *Rickettsia* spp. The evolutionary history was inferred by using the neighbor-joining method of *ompA-ompB* concatenated sequences (total length = 1,189 nt). The optimal tree with the sum of branch length = 0.15227017 is shown. The percentage of replicate trees in which the associated taxa clustered together in the bootstrap test (1,000 replicates) is shown next to the branches. The tree is drawn to scale, with branch lengths in the same units as those of the evolutionary distances used to infer the phylogenetic relationship. The evolutionary distances were computed using the Maximum Composite Likelihood method and are in the units of the number of base substitutions per site. Codon positions included were 1st+2nd+3rd+noncoding. All ambiguous positions were removed for each sequence pair. Evolutionary analyses were conducted in MEGA5 ([www.megasoftware.net](http://www.megasoftware.net)). The number of the *Rickettsia* spp. recognized in this study is shown next to the tick spp. Identified with them. Clusters of identified *Rickettsia* spp. are shown. Rc, *Rickettsia conorii* strain Malish 7; Ra, *R. africana* strain ESF-5; Rr, *R. rickettsii* strain Iowa; Rs, *R. slovaca* strain 13-B; Rm, *R. massilliae* strain MTU5; Rsm, *R. sibirica* subsp. *mongolitimona* strain HA-91; *R. raoultii* isolate XG86; Rhsang, *Rhipicephalus sanguineus*; Rtur, *Rh. turanicus*; Rpus, *Rh. pusillus*; Dmar, *Dermacentor marginatus*; Hmar, *Hyalomma marginatum*. Scale bar indicates number of nucleotide changes per site.

phylogenetic relationship between *Rickettsia* spp. (Figure, panel B), with similar results for maximum likelihood, maximum parsimony, and neighbor-joining methods (data not shown). Furthermore, the results suggested the tick vectors for these *Rickettsia* spp. in the study area (Figure, panel B) match those reported or suspected previously for these *Rickettsia* spp. (1–4), but for the first time, *R. sibirica* subsp. *mongolitimona* was identified in *Hyalomma* and *Rhipicephalus* spp. ticks in Spain (4).

These tick species are frequently found in the same area feeding on Eurasian wild boar (*Sus scrofa*) and red

deer (*Cervus elaphus*), which may act as hosts for these pathogens (5,9). To test this hypothesis, we determined the seroprevalence for SFG rickettsiae in these host species in Castilla-La Mancha. Serum samples from 235 red deer and 206 wild boar were analyzed for the presence of anti-SFG *Rickettsia* antibodies by ELISA (Spotted Fever Rickettsia IgG EIA Antibody Kit, Fuller Laboratories, Fullerton, CA, USA). The ELISA was adapted to test ungulate serum specimens by substituting antihuman IgG-horseradish by protein G-horseradish peroxidase (Sigma-Aldrich, Madrid, Spain). Specific SFG-*Rickettsia* antibodies were

detected in 146 (70.9%) of 206 wild boar and 174 (74.0%) of 235 red deer, indicating a high seroprevalence in these species and thus the possibility that they can serve as hosts for these pathogens.

These tick species also infest humans, thus posing a risk for transmission of rickettsiae that are pathogenic in humans (1). In fact, Castilla-La Mancha is one of the regions in Spain where a high number of SFG rickettsioses are reported ([10]; <http://pagina.jccm.es/sanidad/salud/epidemiologia/3507.pdf>).

In conclusion, these results demonstrate that SFG rickettsiae with public health relevance are found in ticks in central Spain as in other regions in Spain. In central Spain, the widespread distribution of tick vectors and possible wildlife hosts, the presence of persons in tick-infested recreational and hunting areas, and the transstadial and transovarial transmission of the pathogen in ticks may favor transmission to humans.

#### Acknowledgments

We thank M. Durán-Martínez and R. Sobrino for help with tick surveys.

F. R.-F. and I.G.F.M. are supported by a Juan de la Cierva contract from the Spanish Ministry for Economy and Competitiveness. Research supported by POII09-0141-8176 and European Union FP7 ANTIGONE (Anticipating the Global Onset of Novel Epidemics) project number 278976.

**Isabel G. Fernández de Mera,  
Francisco Ruiz-Fons,  
Gabriela de la Fuente,  
Atilio J. Mangold,  
Christian Gortázar,  
and José de la Fuente**

Author affiliations: Instituto de Investigación en Recursos Cinegéticos (IREC)—CSIC-UCLM-JCCM, Ciudad Real, Spain (I.G. Fernández de Mera, F. Ruiz-Fons, G. de la Fuente, C. Gortázar, J. de la Fuente); Universidad Complutense de Madrid, Madrid,

Spain (I.G. Fernández de Mera); Instituto Nacional de Tecnología Agropecuaria, Santa Fe, Argentina (A.J. Mangold); and Oklahoma State University, Stillwater, Oklahoma, USA (J. de la Fuente).

DOI: <http://dx.doi.org/10.3201/eid1907.130005>

## References

1. Raoult D, Roux V. Rickettsioses as paradigms of new or emerging infectious diseases. *Clin Microbiol Rev*. 1997; 10:694–719.
2. Uchiyama T. Tropism and pathogenicity of rickettsiae. *Front Microbiol*. 2012;3:230. <http://dx.doi.org/10.3389/fmicb.2012.00230>
3. Márquez FJ. Spotted fever group *Rickettsia* in ticks from southeastern Spain natural parks. *Exp Appl Acarol*. 2008;45:185–94. <http://dx.doi.org/10.1007/s10493-008-9181-7>
4. Aguirrebengoa K, Portillo A, Santibáñez S, Marín JJ, Montejo M, Oteo JA. Human *Rickettsia sibirica mongolitimonae* infection, Spain. *Emerg Infect Dis*. 2008;14:528–9. <http://dx.doi.org/10.3201/eid1403.070987>
5. Ruiz-Fons F, Fernández de Mera IG, Acevedo P, Höfle U, Vicente J, de la Fuente J, et al. Ticks (Acari: Ixodidae) parasitizing Iberian red deer (*Cervus elaphus hispanicus*) and European wild boar (*Sus scrofa*) from Spain: geographical and temporal distribution. *Vet Parasitol*. 2006;140:133–42. <http://dx.doi.org/10.1016/j.vetpar.2006.03.033>
6. Fernández de Mera IG, Zivkovic Z, Bolaños M, Carranza C, Pérez-Arellano JL, Gutiérrez C, et al. *Rickettsia massiliae* in the Canary Islands. *Emerg Infect Dis*. 2009;15:1869–70. <http://dx.doi.org/10.3201/eid1511.090681>
7. Torina A, Fernández de Mera IG, Alongi A, Mangold AJ, Blanda V, Scarlata F, et al. *Rickettsia conorii* Indian tick typhus strain and *R. slovaca* in humans, Sicily. *Emerg Infect Dis*. 2012;18:1008–10.
8. Zhu Y, Fournier PE, Eremeeva M, Raoult D. Proposal to create subspecies of *Rickettsia conorii* based on multi-locus sequence typing and an emended description of *Rickettsia conorii*. *BMC Microbiol*. 2005;5:11. <http://dx.doi.org/10.1186/1471-2180-5-11>
9. de la Fuente J, Naranjo V, Ruiz-Fons F, Vicente J, Estrada-Peña A, Almazán C, et al. Prevalence of tick-borne pathogens in ixodid ticks (Acari: Ixodidae) collected from European wild boar (*Sus scrofa*) and Iberian red deer (*Cervus elaphus hispanicus*) in central Spain. *Eur J Wildl Res*. 2004;50:187–96. <http://dx.doi.org/10.1007/s10344-004-0060-1>
10. Bartolomé J, Lorente S, Hernández-Pérez N, Martínez-Alfaro E, Marín-Orsa A, Crespo MD. Estudio clínico-epidemiológico de las rickettsiosis del grupo de las fiebres exantemáticas en Albacete. *Enferm Infecc Microbiol Clin*. 2005;23:194–6. <http://dx.doi.org/10.1157/13073143>

Address for correspondence: José de la Fuente, Instituto de Investigación en Recursos Cinegéticos (IREC-CSIC-UCLM-JCCM), Ronda de Toledo s/n, 13005 Ciudad Real, Spain; email: [jose\\_delafuente@yahoo.com](mailto:jose_delafuente@yahoo.com)

## Neonatal *Granulicatella* *elegans* Bacteremia, London, UK

**To the Editor:** *Granulicatella elegans*, a bacterium found in normal human oral flora, is generally associated with infective endocarditis. We discuss the identification and possible source of neonatal *G. elegans* bacteremia.

A 29-year-old woman sought care at Northwick Park Hospital (London, UK) at 41 weeks' gestation (first pregnancy) for spontaneous rupture of membranes and discharge of clear liquor. She had fever (37.6°C) and a heart rate of 98 beats/min; there was no evidence of fetal distress. The woman was released from the hospital.

Twelve hours later, she returned because of discharge of meconium-stained liquor. Her white cell count was  $18 \times 10^9/L$  (reference 3–10  $\times 10^9/L$ ), and her C-reactive protein level was 277 mg/L (reference <5 mg/L). Emergency cesarean section was performed after a diagnosis of fetal distress. A large amount of foul-smelling meconium was observed. A live male infant (3.05 kg) was delivered; Apgar score was normal. Blood samples were cultured for suspected sepsis, and the neonate was empirically

administered intravenous benzylpenicillin and amikacin (6 days). He made a full clinical recovery.

The mother remained generally well, although she had persistent tachycardia (120 beats/min) and fever (37.6°C). She was intravenously administered amoxicillin/clavulanic acid and amikacin; over the next 2 days, her white cell count became normal, but her C-reactive protein level remained >400 mg/L. By postdelivery day 10, her temperature and heart rate were normal. Antimicrobial drug treatment was stopped, and she was released without further treatment. We interviewed the mother 8 months later and established that she had no dental procedures/infection or endocarditis before, during, or after pregnancy.

Placental swab samples were cultured on Columbia horse blood agar (CBA) and chocolate CBA (both incubated aerobically with 5% CO<sub>2</sub> at 37°C for 24 hours), cysteine lactose electrolyte deficient agar (incubated in air at 37°C for 24 hours), and fastidious anaerobic agar with and without neomycin (incubated anaerobically at 37°C for 48 hours); all agar was from Thermo Fisher, Basingstoke, UK. On all media, the placental swab sample yielded moderate growth of tiny colonies, which Gram staining indicated were gram-positive coccobacilli.

Culture of the neonate's blood sample (BacTAlert 3D; Becton Dickinson, Oxford, UK) grew small, gram-variable bacilli after 17 hours of aerobic incubation. A subculture incubated aerobically on CBA or chocolate CBA showed no bacterial growth; however, tiny colonies were seen on fastidious anaerobic agar with and without neomycin. Gram staining of the colonies showed gram-positive bacilli that were morphologically similar to those isolated from placenta. We suspected lactobacilli or streptococci, but testing (API Strep and Coryne strips; bioMérieux UK Ltd, Hampshire, UK) did not confirm this. Nutritionally variant streptococci were not suspected.