

University of Groningen

Evaluation of Crohn's disease activity

Maccioni, Francesca

IMPORTANT NOTE: You are advised to consult the publisher's version (publisher's PDF) if you wish to cite from it. Please check the document version below.

Document Version

Publisher's PDF, also known as Version of record

Publication date:

2013

[Link to publication in University of Groningen/UMCG research database](#)

Citation for published version (APA):

Maccioni, F. (2013). *Evaluation of Crohn's disease activity: an integrated imaging approach*. [Thesis fully internal (DIV), University of Groningen]. [s.n.].

Copyright

Other than for strictly personal use, it is not permitted to download or to forward/distribute the text or part of it without the consent of the author(s) and/or copyright holder(s), unless the work is under an open content license (like Creative Commons).

The publication may also be distributed here under the terms of Article 25fa of the Dutch Copyright Act, indicated by the "Taverne" license. More information can be found on the University of Groningen website: <https://www.rug.nl/library/open-access/self-archiving-pure/taverne-amendment>.

Take-down policy

If you believe that this document breaches copyright please contact us providing details, and we will remove access to the work immediately and investigate your claim.

Downloaded from the University of Groningen/UMCG research database (Pure): <http://www.rug.nl/research/portal>. For technical reasons the number of authors shown on this cover page is limited to 10 maximum.

Evaluation of Crohn's Disease activity: an integrated imaging approach



Francesca Maccioni

Most of the clinical and scientific work presented in this thesis has been performed at the Department of Radiological Sciences of the "Sapienza" University of Rome. Part of the scientific work has been made in cooperation with the Groningen University Medical Center.

Cover picture by: Beatrice Bozzao 2011

A. Sunset from house dining room window: "different points of view".
(Zooming slow exposure effect).

The same subject, with different lights, is photographed in pictures B-M

© Francesca Maccioni

RIJKSUNIVERSITEIT GRONINGEN

**Evaluation of Crohn's Disease activity:
an integrated imaging approach**

Proefschrift

ter verkrijging van het doctoraat in de
Medische Wetenschappen
Aan de Rijksuniversiteit Groningen
op gezag van de
Rector Magnificus, dr. E. Sterken,
In het openbaar te verdedigen op
Maandag 13 mei 2013
om 11:00 uur

door

Francesca Maccioni

geboren op 11 februari 1963
te Roma, Italië

Promotores:

Prof. dr. A. Signore

Prof. dr. R.A. Dierckx

Beoordelingscommissie:

Prof. dr. M. Oudkerk

Prof. dr. C. van de Wiele

Prof. dr. S. Cucchiara

To my mother Lea

Index of chapters

1. Introduction	- 9
2. <i>Evaluation of Crohn disease activity with magnetic resonance imaging.</i> Abdom Imaging. 2000;25 (3):219-228.	- 17
3. <i>MR imaging in patients with Crohn disease: value of T2- versus T1-weighted gadolinium-enhanced MR sequences with use of an oral superparamagnetic contrast agent.</i> Radiology. 2006; 238 (2): 517-530.	- 38
4. <i>Double-contrast magnetic resonance imaging of the small and large bowel: effectiveness in the evaluation of inflammatory bowel disease.</i> Abdom Imaging.2010;35(1):31-40.	- 66
5. <i>Inflammatory bowel diseases: clinical update of practical guidelines.</i> Nucl Med Commun. 2005;26(7):649-655.	- 84
6. <i>Use of a 99mTc labeled anti-TNFα monoclonal antibody in Crohn's disease: in vitro and in vivo studies.</i> Q J Nucl Med Mol Imaging.2007;51(4):334-342.	- 98
7. <i>Imaging of cell trafficking in Crohn's Disease.</i> J Cell Physiol.2010;223:562–571.	- 113
8. <i>Differences in the location and activity of intestinal Crohn's disease lesions between adult and paediatric patients detected with MRI.</i> Eur Radiol. 2012; 22 (11): 2465-77.	- 144
9. <i>New frontiers of MRI in Crohn's disease: motility imaging, diffusion-weighted imaging, perfusion MRI, MR spectroscopy, molecular imaging, and hybrid imaging (PET/MRI).</i> AbdomImaging.2012;37(6):974-82.	- 167
10. Summary	- 185
11. Conclusions	- 190
12. Curriculum vitae.	- 193
13. Acknowledgments	- 197



Picture by Francesca Maccioni 2011
Sunset from the dining room window (B)

Chapter 1

Introduction

Epidemiology

Crohn's disease (CD) is a chronic inflammatory disorder of the alimentary tract of unknown etiology, more common in Northern Europe, North America and Japan. CD may involve any portion of the GI tract, from mouth to anus, although it usually affects the small or the large bowel or both, and almost invariably the terminal ileum. It has a typical segmental "patchy" spreading and a chronic relapsing-remitting course. The disease has an early onset, around the second- third decade of life, being not rare in pediatric age; a second peak of incidence is observed in older age group. An increased incidence at childhood age has been observed in the last two decades. Virtually, it can present at any age and lasts for patient's life, with a typical relapsing-remitting course.

Although the pathogenesis of CD still remains unknown, there is an emerging consensus that results from the complex interaction of multiple factors between genetic, immunologic and environmental factors. It starts as a breach of the mucosal barrier by a specific infectious agent or an environmental toxin, causing inflammation, perpetuated by exposure of luminal micro flora to the mucosal immune system and it becomes chronic as a result of a genetically determined failure of immunologic down-regulation.

The small bowel is affected in approximately 80% of cases, particularly the distal ileum, either alone (in 25-35% of cases) or associated with a colonic localization (in about 30-55% of cases). In 15 to 25% of patients the colon is involved alone, frequently at multiple sites. CD lesions are usually patchy and segmental, alternated to intestinal segments spared by the inflammatory process. Perianal disease it is not uncommon, but usually associated with rectal involvement.

Microscopically, CD is characterized by a transmural inflammation, with leukocyte infiltrates involving all wall layers, from the mucosa to the muscularis propria and serosa, frequently extending outside of the wall and involving adjacent structures. Typical features include deep mucosal ulcerations, mural and transmural fissures and sinus tracts extending outside of the wall.

This complex inflammatory process leads to a marked wall thickening, which usually exceeds 4 mm and may reach 15-20 mm in severe cases. Other macroscopic findings of CD include

the marked wall thickening related to the transmural inflammatory process, the serosal and mesenteric involvement, the characteristic fibrofatty proliferation of the perivisceral fat, an increased number and size of inflamed lymph nodes and, frequently, adhesions, perivisceral abscesses and entero-enteric fistulas, or fistulas between intestinal loops and muscles or other abdominal organs and structures.

Although unpredictable, three main CD phenotypes (or courses) have been recently identified, according to the Vienna Classification of CD (International Working Party for the World Congress of Gastroenterology 1998): the inflammatory (non fibrostenosing-non perforating), the perforating and the fibrostenosing phenotype, being the perforating phenotype more aggressive and frequently associated with severe complications.

Typically, CD is characterized by remission phases alternated to flares and exacerbations, with onset of complications requiring surgical interventions. At least one surgical intervention is needed throughout CD patient' lifetime, due to obstructing or inflammatory complications.

The treatment of CD is complex and based on the association of antiinflammatory, immunosuppressant and antibiotic drugs. Recently, biological agents, namely monoclonal antibodies directed against the specific inflammatory cytokines, have been successfully developed, and introduced in the clinical practice, such as the infliximab, the tumour necrosis alpha-factor antibody. Unfortunately, although temporarily effective, symptoms tend to recur during pharmacological treatment. Surgery may be frequently needed to treat severe or complicated CD, but it cannot be considered a resolutive treatment, since recurrences invariably occur in 3-24 months after surgery.

For several decades ileocolonoscopy and small bowel follow through have been considered the gold standard imaging techniques for the diagnosis of CD. The final diagnosis of CD is usually more difficult to achieve than UC. In fact, endoscopy and biopsy specimens alone cannot completely assess CD since most of small bowel lesions sited above the terminal ileum are endoscopically unreachable. ES and biopsy specimens alone cannot completely assess CD since small bowel lesions, transmural extent of inflammation, main complications such as abscesses or fistulas could be under-detected or completely missed. Moreover, in detectable lesions, the transmural extent of inflammation and most of main complications, including abscesses and fistulas, can be under-detected or completely missed by endoscopy. The recent introduction of the capsule endoscopy (CE) technology has been a significant improvement in the evaluation of the bowel, mostly due its completeness and lack of invasiveness. However, it has several contraindications, particularly in Crohn's disease, since

inflammatory or fibrotic strictures may impede the progression of the capsule, causing capsule retention.

Since the majority of patients need a long-term follow-up, it would be ideal to rely on non-invasive radiation-free techniques. For this purpose, ultrasound and magnetic resonance imaging (MRI) are more and more applied for diagnostic and follow-up purposes. In the last few years the diagnostic efficacy of MRI has been extensively investigated for all these different aspects of Crohn's Disease (Crohn's disease activity, lesions detection, complications) with excellent results, so that it is widely considered a valuable diagnostic tool in the overall assessment of the disease. MRI has the capability to assess the extent and complications of CD without radiation exposure and invasiveness. Furthermore, it is particularly effective to detect and quantify wall inflammation in CD, the so called "CD activity".

Therefore, current guide lines for the diagnosis and periodic evaluation of IBD are in favor of the association of US, MRI, nuclear medicine and endoscopy (ES) integrated by histology, whereas the use of CT and barium studies should be considered in selected cases only.

MRI

In recent years MRI has definitely emerged in the evaluation of the small bowel like no other diagnostic modality. The clinical and scientific interest is continuously increasing, with over 600 papers published in Medline on this subject (MRI, Small bowel) during the last 10 years. In the last two decades the overall quality of MRI has significantly increased, either in terms of spatial and temporal resolution. The possibility to evaluate the gastrointestinal tract with MRI is quite recent and directly related to relevant technical hardware and software advances. Before the years 1990-95, the MRI evaluation of the bowel was not accurate for several reasons. The long acquisition time caused blurred images of the bowel and motion artifacts, related to the bowel peristalsis and respiratory movements. Moreover, the spatial resolution was inadequate to detect intestinal wall abnormalities.

During the last decade, thanks to highly performing gradients and new software, rapid acquisition sequences have been continuously introduced and improved, with significant reduction of the motion artifacts related to intestinal peristalsis. Nowadays, breath-hold and breath-hold free abdominal MR imaging is easily available in newer equipments. Furthermore, the introduction of phased array coils has provided a relevant increase in the spatial resolution, which is crucial to detect subtle intestinal wall changes. At the same time, the multi-channel technology allowed the possibility of wider fields of view, to cover the entire

abdomen. Intestinal contrast agents have been extensively tested for homogenising the intestinal content and increasing the visualization of the bowel. Moreover, the possibility to selectively modulate the MRI signal (for example, selective fat tissue signal suppression) has improved the evidence of both T2-signal and gadolinium-enhancement on T1-weighted images, thus highlighting pathologic tissues, particularly inflammatory diseases. New imaging parameters, particularly Diffusion-Weighted Imaging (DWI), recently introduced, seem to be promising in the analysis of neoplastic and inflammatory bowel diseases.

Such recent technological advances, together with the intrinsic capability of a multiplanar acquisition and the possibility of using different imaging parameters (T1-T2 weighted, DWI), the inherent high soft tissue contrast and the lack of ionizing radiation, currently make MRI a primary imaging modality for the evaluation of the small and large bowel.

Specific advantages of MRI over other imaging modalities include the possibility of evaluating small bowel diseases with different tissue parameters (T1 and T2-weighted, Diffusion Weighted), with variable imaging planes and fields of view, variable spatial and temporal resolution, thus offering specific information with regard to bowel peristalsis, caliber, distribution, morphology vascularization, molecular structure, presence of oedema or fibrosis, mobility of tissue water molecules, etc. On the other hand, this wide availability of multiple sequences and different contrast agents allows many different choices. In order to obtain satisfactory results with MRI, and particularly in the evaluation of the bowel, it is mandatory to optimize the association of the proper contrast agent with a specific sequence, as well as the association of the proper intravenous and intestinal contrast agent and sequence. The availability of breath hold free sequences has improved the image quality in less cooperative patients, particularly pediatric ones.

Nuclear medicine

Nuclear medicine imaging is characterized by the use of radiopharmaceuticals which administered in pico- and nanomolar amounts take part in biochemical and physiological processes and in this way allow assessment and visualisation of these processes in vivo. The radiopharmaceutical mostly consists of a targeting compound labelled with a radionuclide. Depending on the radionuclides used, positron emitters or single photon emitters, the tomographic equipment specifically designed according to the intrinsic physical characteristics of these radionuclides is classified as positron emission tomography (PET) or single photon emission computed tomography (SPECT) respectively.

PET radionuclides are mostly produced by irradiation of target material with highly accelerated protons or deuterons using a cyclotron. Commonly used radionuclides in PET imaging are carbon-11, nitrogen-13, oxygen-15 and fluorine-18 with relatively short half-lives varying from 2 to 110 minutes. As these radionuclides resemble building blocks of biological life, they may be incorporated into relevant molecules using radiochemical methods. Radioactive decay takes place through emission of a positron. Following administration to a patient, the positron interacts after a short distance with an electron from tissue resulting in annihilation^{1,2}. PET shows a higher spatial resolution (4-5 mm) as compared to conventional gamma cameras with a resolution of approximately 8-15 mm. So-called micro-PET cameras used for small animal imaging reach a resolution of 1-2 mm^{3,4}. After injection of the radiopharmaceutical, the distribution can be followed in time in a part of the body (dynamic scan) or by moving the bed into several positions (static whole-body scan)¹. A general approach to dynamic PET imaging consists of independently reconstructing tomographic data with each dynamic frame.

Molecular imaging agents coupled with advanced data analysis methods support the application of PET for the assessment of normal biological processes, the assessment of changes in biological processes associated with disease formation and progression, and the ability to monitor the response of healthy and diseased tissue to therapeutic intervention. PET imaging is also utilized in the drug discovery process to provide information about novel drug distribution, drug occupancy at specific biological targets and biological responses to drug exposure⁴.

SPECT is similar to PET in its use of radioactive tracer material and detection of gamma rays. Unlike PET, however, the tracer used in SPECT emits gamma radiation that is measured directly. Also the levels of energy of the emitters used in SPECT are lower than those used in PET. SPECT radionuclides are single photon emitters with a half-life in the order of magnitude of several hours. Technetium-99m with a half-life of 6 hours is the most commonly used single photon emitter and is available as the product of a generator.

SPECT imaging is performed using a gamma camera to acquire multiple 2D images from multiple angles. To acquire SPECT images the gamma camera is rotated around the patient and projections are acquired at defined points during the rotations³.

Hybrid approaches have become popular in biomedical imaging since they provide complementary synergistic information, with the patient being in the same position.

In addition to simple visual alignment or the use of stereotactic frames that are undesirable or inconvenient in a diagnostic setting, sophisticated image fusion software was developed from

the eighties onwards. For relatively rigid objects, such as the brain, software can successfully align images from MRI, CT and PET, whereas in more flexible environments such as the rest of the body, accurate alignment is more difficult because of the large number of the possible degree of freedom. Software fusion is also dependent on matching common features that are extracted from the image or from markers placed on the patient. Functional imaging modalities such as PET and SPECT often lack reliable anatomic correlation and have coarser spatial resolution and greater noise levels than CT or MRI⁵.

The advantages and disadvantages of SPECT-CT parallel those of PET-CT in many ways. Using a combined system, one can now sequentially acquire both anatomic and functional information that is accurately fused in a single examination. For imaging infection early reports indicate that SPECT-CT increases specificity and may significantly affect disease management. Unfortunately, a potential disadvantage is that there is a sequential acquisition of CT data and SPECT data; therefore misregistration can occur with patient movement, leading to an artefact on the corrected scintigraphic images. This not only affects anatomic localization but also produces an incorrect attenuation map, causing defects on the attenuation corrected images. Furthermore, movement can result from respiratory and cardiac motion or sagging of the emission table⁶.

The two main forms of inflammatory bowel diseases (IBDs) are Ulcerative colitis (UC) and Crohn's disease (CD), that have both been widely investigated by nuclear medicine techniques. A labeled leukocyte scan should be considered as a second-line examination for the detection of abdominal abscesses when radiological studies and/or endoscopic techniques are inconclusive. In the case of stenosis, labeled leukocytes scan helps to differentiate between inflammation and fibrosis driving medical treatment or surgery, respectively; although, a labeled leukocytes scan has no indication for the diagnosis and characterization of fistulae. The different uptake pattern of CD and UC may provide a differential diagnosis between these two entities (i.e., in CD: uptake in the ileo-coecal area, uptake in the small bowel, patchy distribution of radioactivity; in UC: leukocyte uptake in the left colon up to the rectum or diffuse uptake in the whole colon), but in the case of colon uptake alone, a differential diagnosis is not certain. From data analysis of a recently published metaanalysis, it appears that ¹¹¹In oxine or ^{99m}Tc-HMPAO labeled autologous leukocytes demonstrated a high diagnostic accuracy and can be used for different aspects of the study of IBD.

As far as alternative nuclear medicine techniques (other than labeled leukocytes scans) are concern, radiolabeled monoclonal antibodies showed specific diagnosis in several

inflammatory/infectious disease patients. This kind of scintigraphy also holds the promise for therapy decision making and disease follow-up, with a view to assessing whether the therapeutic target receptor/molecule is present in the lesion, before using the same unlabeled monoclonal antibody for therapeutic purposes.

In conclusion, the high sensitivity for inflammatory processes of both NM and MRI make these modalities somehow similar and complementary for detecting Crohn's disease changes. Characterization of the disease is the challenge of imaging for the next years. Both NM and MRI have several potentials that could progress independently or integrated. Integration (fusion imaging) and focalization (molecular imaging) in both technologies is likely the challenge of the future of the research in CD.

References

1. Neels, O.C. Tracer development for detection and characterization of neuroendocrine tumors with PET. Ph.D. thesis, Rijksuniversiteit Groningen, Groningen, The Netherlands, 2008.
2. Lecomte R. Novel detector technology for clinical PET. *Eur J Nucl Med Mol Imaging*. 2009 Mar;36 Suppl 1:S69-85.
3. Eshuis, S.A. Radiotracer imaging in PD. Ph.D. thesis, Rijksuniversiteit Groningen, Groningen, The Netherlands, 2009.
4. Hutchins GD, Miller MA, Soon VC, Receveur T. Small animal PET imaging. *ILAR J*. 2008;49(1):54-65.
5. Townsend DW. Positron emission tomography/computed tomography. *Semin Nucl Med*. 2008 May;38(3):152-66.
6. Bybel B, Brunken RC, DiFilippo FP, Neumann DR, Wu G, Cerqueira MD. SPECT/CT imaging: clinical utility of an emerging technology. *Radiographics*. 2008 Jul-Aug;28(4):1097-113.



Picture by Beatrice Bozzao 2011
Sunset from the dining room window (C)

Chapter 2

Evaluation of Crohn disease activity with magnetic resonance imaging

F. Maccioni¹, A. Viscido², L. Broglia¹, M. Marrollo², R. Masciangelo³, R. Caprilli², P. Rossi¹

Abdom Imaging. 2000;25(3):219-228.

¹Department of Radiology, Policlinico Umberto I, Università "La Sapienza", Viale Regina Elena 324, 00161, Rome, Italy

²Department of Gastroenterology, Policlinico Umberto I, Università "La Sapienza", Viale Regina Elena 324, 00161, Rome, Italy

³Department of Medical Statistics, Policlinico Umberto I, Università "La Sapienza", Viale Regina Elena 324, 00161, Rome, Italy

Abstract

Background: The purpose of this study was to assess the accuracy of magnetic resonance imaging (MRI) in evaluating Crohn disease (CD) activity. The intestinal inflammatory activity is usually present in patients under pharmacologic treatment, despite their clinical remission.

Methods: Twenty patients with CD, all under pharmacologic treatment, were prospectively studied by MRI at 1.5 T as a periodic control. Positivity of three acute-phase reactants was considered an index of biologic activity (BA). T2-weighted, T2-weighted fat-suppressed turbo spin-echo, and breath-hold T1-weighted turbo field-echo sequences, before and after gadolinium intravenous injection, were obtained. A negative superparamagnetic contrast agent was orally administered. The following MRI parameters were qualitatively evaluated by three radiologists at the level of the affected bowel and compared with clinical data: wall thickness (WT), wall T2-weighted signal (T2W), wall contrast enhancement (WE), amount of fibrofatty proliferation (FP), and T2-weighted signal of fibrofatty proliferation on fat-suppressed images (T2FP). The coefficient of agreement was calculated. The Spearman rank correlation was used for the analysis of clinical and radiologic data.

Results: Nineteen of 20 patients were in clinical remission Crohn Disease Activity Index, 150). On the basis of laboratory tests, nine of 20 patients had biologically active disease. An excellent correlation was found between BA and WE, T2W, and T2FP (0.9, 0.927 and 0.961, respectively; $p < 0.0001$), and a lower correlation was found between BA and WT and between BA and FP (0.78 and 0.62). Excellent statistical correlation was also found between WE and T2W and between WE and T2FP (0.876 and 0.892).

Conclusions: An excellent statistical correlation was found between biologically "active" disease and the following MRI parameters: wall gadolinium enhancement, wall hyperintensity on T2-weighted fat-suppressed images, and hyperintensity of fibrofatty proliferation on T2-weighted fat-suppressed images. Therefore, MRI can be valuable in assessing CD activity.

Key words: Magnetic resonance imaging—Crohn disease— Crohn disease activity.

Introduction

Crohn disease (CD) is a chronic disorder of the alimentary tract that usually occurs in younger patients and lasts throughout the patient's lifetime; it requires continual medical therapy and, often, surgery. The disease is characterized by an inflammatory process extending through all the layers of the bowel wall that leads to fistulas, abscesses, and strictures.

Periodic assessment of the inflammatory activity at the level of the affected bowel is important to monitor drug effects and to plan the proper surgical therapy [1–4]. The presence of local inflammation may change the indications for surgery or affect the outcome of the intervention and the patient's prognosis. A recent publication has classified CD into two subgroups, fibrostenosing and inflammatory perforating disease, reflecting the need of both gastroenterologists and gastrointestinal surgeons to distinguish the different groups on the basis of local inflammatory activity [5].

Assessment of inflammatory activity is also vital in monitoring drug effects. To date, a resolutive pharmacologic therapy does not exist, and each patient should be specifically studied and monitored to assess which among the various drug associations achieves the desired effect. Moreover, new drugs are continually introduced into clinical research, and the results of their action need to be monitored from several points of view and with an adequate imaging modality.

Several clinical indices and diagnostic tests have been proposed to assess the inflammatory activity of the disease, but there has been no absolute reference method. Evaluation of the inflammation is currently based on a combination of clinical symptoms, physical findings, laboratory parameters, endoscopy, and conventional radiology [1–7]. The positivity of at least three acute-phase reactants, or biologic activity (BA), is considered one of the most sensitive methods to assess the inflammatory activity [2]. Results of laboratory analyses, however, must be supported by findings obtained from diagnostic imaging modalities or endoscopy [6–21].

Thus far, magnetic resonance imaging (MRI) has been used mainly to evaluate anal and perianal CD abnormalities because motion artifacts have limited its accuracy in investigating the disorders of the small and large intestines [22–24]. Recent technologic improvements (respiratory compensation, breath-hold acquisition, fat suppression, orally administered contrast agents) have allowed the physician to obtain high-quality MR images throughout the entire abdomen.

The aim of the present study was to evaluate the potential role of MRI in the assessment of CD inflammatory activity, in active and inactive disease, by investigating the main wall abnormalities on T1-weighted gadolinium-enhanced and T2-weighted images.

Gadolinium intravenous injection should produce marked contrast enhancement at the level of the inflamed bowel wall, as reported in several studies [25–31]. Similarly, the T2 signal should be increased at the level of the inflamed wall. However, in the detection of bowel wall inflammation, T2-weighted turbo spin-echo images are affected by low-contrast resolution because the high signal of the inflamed wall cannot be easily distinguished from the high signal of the intraluminal fluid or the perivisceral fat tissue.

In the present study, to improve the evidence of the wall signal on T2-weighted images, a superparamagnetic contrast agent (iron oxide particles) was orally administered, and fat-suppressed and non-fat-suppressed sequences were obtained [32, 33]. Suppression of the signal of the perivisceral fat tissue increases the evidence of the signal at the level of the inflamed wall. Oral administration of a superparamagnetic agent reduces the high signal of the bowel content on T2-weighted images, thus producing a negative contrast effect [33]. As a result of this association (fat suppression and oral superparamagnetic contrast agent), the evidence of the wall signal on T2-weighted images, if present, should be maximally improved.

Patients and methods

Patients

The study protocol was approved by our Institutional Review Board, and written informed consent was obtained from all patients. A consecutive series of 20 patients (12 male, eight female; mean age = 36.6±5.4 years) with a proven diagnosis of CD prospectively underwent MRI study during a periodic clinical assessment. All patients were under pharmacologic treatment with oral corticosteroids, azathioprine, mesalazine, or antibiotics and were periodically followed up at the gastroenterology unit. At the time of the study, 19 of 20 patients were in clinical remission, and one patient had had a recent exacerbation of symptoms.

Clinical evaluation

Diagnosis of CD was made in all patients by standard criteria [34]. Patient assessment included clinical evaluation, laboratory tests, colon ileoscopy, and/or barium studies. Localization, length, and severity of the lesions were documented by colon ileoscopy and/or barium studies.

The Crohn Disease Activity Index (CDAI) according to the criteria proposed by Best et al. [35, 36], the Harvey–Bradshaw Simple Index (SI), and the Oxford Index (OI) were used to evaluate all patients; these indices assign a specific score to different clinical signs and symptoms (e.g., length of symptoms, diarrhea, temperature, abdominal pain, etc.). Patients were also classified according to surgical history, predominant clinical “behavior,” and the results of endoscopy and barium studies into three main groups: (a) the obstructive/fibrostenotic clinical course, when the inflammatory activity is usually absent or low; (b) the inflammatory course; and (c) the perforating course, when complications, such as fistulas or abscesses, are present and the inflammatory activity is usually very high [5]. Laboratory assessment included white blood count, erythrocyte sedimentation rate, C-reactive protein, and orosomucoids. The positivity of these laboratory findings indicated the presence of sustained inflammatory events not confined to the intestinal wall.

In our study, the positivity of acute-phase reactants was considered the main index of BA and the “gold standard” to assess intestinal inflammatory activity; patients were considered to have active disease if at least three of these tests were abnormal. The clinical indices and the clinical courses also were correlated to MRI findings but were not considered a “gold standard”.

MRI technique

All patients were studied 1 h after oral administration of 900 mL superparamagnetic contrast agent (iron oxide; Lumirem, Laboratoires Guerbet, Paris, France). The passage was extremely rapid, approximately less than 1 h in patients with CD, to obtain a homogeneous distribution at the level of the small and large bowel.

The distribution of oral contrast on T2-weighted images was usually homogeneous throughout the bowel, although, at the level of active disease, the marked edema of the bowel wall and the higher intraluminal secretion prevented us from obtaining a negative intraluminal effect at the level of the lesion. However, in these cases, the noninflamed adjacent loops were always adequately filled with the negative contrast, thus providing good evidence of the active lesion on T2 weighted images (Fig. 3).

MRI was performed with a 1.5-T system (Philips NT) using a body coil for signal acquisition and reception. The following axial sequences were performed in all patients: turbo spin-echo (TSE) T2-weighted images (TR/TE = 3000/120 ms, matrix 256 x 256, nex = 6, turbo factor = 23, acquisition time = 3 min 54 s); fat-suppressed spectral presaturation with inversion recovery (SPIR) TSE T2-weighted images (TR/TE = 2500/120 ms, matrix 256 x 256, nex = 6, turbo factor = 16, acquisition time = 4 min 30 s); breath-hold turbo field-echo (TFE) T1-

weighted images (TR/TE = 10/5 ms, angle = 25°, nex = 3, matrix 256 x 256, acquisition time = 1 min 30–22 s, breath hold = 26 s x 4 slices). T1-weighted images were acquired before and after intravenous injection of a mean dose of 15–20 mL (0.25 mL/kg) gadolinium-DTPA (Magnevist, Schering, Germany). The delay from intravenous injection to image acquisition was 20 s.

Additional coronal T2-weighted TSE and T1 weighted TFE postgadolinium images were acquired when more than one loop was affected, in particular when the colon was involved, to obtain a more panoramic evaluation of the entire abdomen.

Data analysis

Radiologic evaluation of the following MRI signs was performed, at the level of the pathological bowel loops: wall thickness (WT), wall signal on T2-weighted fat-suppressed images (T2W), wall enhancement (WE), fibrofatty proliferation (FP), and signal of the perivisceral fat on T2-weighted fat suppressed images (T2FP). Images were qualitatively analyzed on films by three radiologists using a score system (0 = absent, 1 = mild, 2 = high) for each of the five parameters considered. MR images were evaluated blind, without knowledge of endoscopic findings or the BA. WT was considered mild if the score was equal or less than 4 mm and high if the score was equal or greater than 5 mm. Interobserver agreement in each category of findings was assessed using the kappa correlation coefficient. Statistical analysis of clinical and radiologic data was performed using nonparametric statistical analysis (Spearman rank correlation).

When more than one bowel segment showed alterations, all the involved segments were evaluated and scored; if fibrostenotic disease and active inflammatory disease were present in the same patient at different levels, only the active segment was considered for statistical analysis.

Results

Clinical evaluation

The time interval from the initial diagnosis of CD was between 1 and 17 years (mean 5.7 ± 6.5). At the time of the study, all the patients had an ileal disease, and seven also had colonic involvement. Nine patients had undergone ileocolonic resection.

Evaluation of clinical activity by means of CDAI, SI, and OI showed that all but one patient were in clinical remission. One patient had a CDAI score greater than 150, a SI score greater than 7, and an OI score greater than 3.

When using the subgroup classification, 11 patients had obstructive/fibrotic disease, six had inflammatory disease, and three had perforating disease. Laboratory tests showed nine patients with a positive acute-phase response (BA), all of whom belonging to the inflammatory or perforating subgroup. No patients with obstructive/fibrotic disease showed abnormal laboratory values.

Colon ileoscopy and barium studies showed that all patients with an acute-phase response had severe, large, deep ulcerations or fistulas. All clinical results are shown in Table 1.

MRI findings

WT was mild in four patients, marked in eight, and absent in eight. T2W was mild in three patients, high in seven, and absent in 10. WE was mild in five patients, high in five, and absent in 10. FP was mild in nine patients, marked in four, and absent in seven. T2FP was mild in three patients, high in six, and absent in 11 (Tables 1, 2).

In patients with inactive disease and fibrotic lesions ($n = 11$) we observed lack of WT in most of the cases (8/11). However, one patient (1/11) had marked WT (at this level, the endoscopy showed a normal mucosa), and two (2/11) had moderate WT (Table 1). Interestingly, the WT observed in these patients did not show enhancement or signal on T2 images.

In the group of patients with inactive disease and fibrotic lesions, we also observed lack of WE in 10 of 11 patients, lack of T2W in 10, and lack T2FP in 11. FP was absent seven of 11 patients, moderate in three, and marked in one; whenever present in this group of patients, FP did not show a signal in T2-weighted images.

Conversely, in patients with active disease ($n = 9$), all having inflammatory or fibrotic lesions, we observed, in the majority of the cases, a marked WT (7/9), a high T2W (7/9), a high (5/9) or moderate (4/9) WE, a mild (6/9) or moderate (3/9) FP, and a high (6/9) or mild (3/9) T2FP. In none of these patients did we observe lack of WT, T2W, WE, FP, or T2FP (Table 2).

Statistical results

The interobserver agreement was considered statistically significant for all the parameters evaluated, with a kappa coefficient of agreement ranging from 0.54 to approximately 1. The highest agreement was obtained in the evaluation of T2W and T2FP, and the lowest agreement was obtained in the assessment of WT (Table 3).

No statistically significant results were obtained by correlating the indices of clinical activity (CDAI, SI, OI) with the MRI parameters considered ($p < 0.01$).

Statistically significant results ($p < 0.01$) were obtained by correlating the BA with all the MRI findings considered. Spearman rank correlation coefficient values were excellent between BA and T2W (0.927; $p < 0.0001$), between BA and WE (0.900; $p < 0.0001$), and between BA and T2FP (0.961; $p < 0.00001$). A good correlation was obtained between BA and WT (0.786; $p < 0.0006$) and between BA and FP (0.620; $p < 0.006$). The same significance was obtained by correlating the inflammatory and perforating clinical course with each of the five MRI parameters.

A statistical correlation was found between the following MR parameters: T2W, T2FP, WT, and WE ($p < 0.0001$, 0.8767, 0.892, and 0.816). No correlation was found between WE and FP (0.531, $p < 0.02$). Spearman rank correlation overall results are reported in Table 4.

Discussion

The frequent and periodic evaluation of CD intestinal inflammation is vital in planning the proper therapy, surgical or pharmacologic, monitoring drug effects, and detecting postoperative recurrence. A persistent inflammatory activity at the site of the affected bowel is frequently observed in patients under pharmacologic treatment, despite their clinical remission. Thus far, an absolute reference method to assess disease activity does not exist, and many parameters are used by the physicians.

The CDAI (Crohn Disease Activity Index) and OI (Oxford Index) are well established clinical indices specifically created by gastroenterologists [35, 36]. However, by taking into account clinical signs and symptoms only (e.g., diarrhea, temperature, abdominal pain, etc.), the indices are often influenced by subjective factors and have a low overall sensitivity, particularly in detecting complications or recurrences [1, 36]. The evaluation of inflammation is currently based on a combination of clinical symptoms, physical findings, laboratory parameters, endoscopy, and barium studies [2–11]. Positivity of acute-phase reactants, or BA, is widely considered an important indicator of the inflammatory activity [1, 2, 4]. Results of laboratory analyses should, however, be supported by the findings obtained by diagnostic imaging modalities or endoscopy.

Endoscopy and conventional radiology can assess the longitudinal extension of the mucosal disease, but they are unable to evaluate the activity and extension of the inflammatory process through and beyond the intestinal mucosa [6–12]. In the last few years, several imaging modalities such as computed tomography (CT), ultrasound (US), color Doppler US, Doppler sonography of the superior mesenteric artery, and nuclear medicine have been

proposed, with variable results, but none of them has a firmly established role in the assessment of disease activity [8, 13–21].

For several years, the role of MRI in CD has been limited to the assessment of anal and perianal abnormalities because motion artifacts do not allow evaluation of the remaining bowel. Recent advances such as respiratory compensation, breath-hold acquisition, fat suppression, and orally administered contrast agents allow the physician to obtain high-quality MR images throughout the entire abdomen.

The main purpose of the present study was to evaluate the potential role of MRI in the assessment of the inflammatory activity of CD lesions by analyzing both T1-weighted gadolinium-enhanced and T2-weighted images. For this reason, five of the most frequent findings of CD were qualitatively evaluated on MR images and correlated with clinical signs of activity. Three of these parameters were related to wall abnormalities (enhancement, thickening, T2 signal), and the other two were related to perivisceral abnormalities (amount and T2 signal of FP).

The accuracy of contrast-enhanced MRI in the evaluation of CD has been recently investigated [8, 25–32],

whereas T2 signal values in CD have not been extensively examined [33, 37–39]. However, the T2 signal is a wellknown indicator of inflammation in human tissues, and it should be a good indicator of the inflammatory activity in CD as well.

The lack of studies on T2 signal values in CD is probably related to the low-contrast resolution of plain T2-weighted TSE sequences. It is difficult to distinguish among the high signals of the inflamed wall, the bowel content, and the perivisceral fat tissue (which is particularly elevated on T2-weighted TSE sequences). In our study, we overcame this problem by suppressing the signal of the bowel content through oral administration of a superparamagnetic contrast agent (iron oxide) and by suppressing the perivisceral fat tissue signal with a SPIR TSE T2 weighted sequence. In this way, the T2 signal of the inflamed wall, if present, is enhanced to the utmost. In other words, the signal of the fat tissue and of the luminal content are “subtracted” from the image; what remains is the signal of the inflamed bowel wall (Figs. 1C,E, 3B). To assess T2 signal values in CD, we then considered fatsuppressed images (T2FS) rather than plain ones and used negative rather than positive oral contrast agents.

One consequence of using T2FS sequences, however, is the loss of morphologic details because of the darkness of the image. For a complete assessment of CD, we suggest using both T2 TSE and T2FS TSE sequences. The former are extremely valuable in the

morphologic study of the entire abdomen on both axial and coronal planes (Figs. 1A,B, 2A,E, 3A), and the latter are extremely sensitive in investigating bowel wall inflammation.

As expected, we found a direct statistical correlation between active disease and high T2 wall signal (T2W) ($p < 0.0001$; $r = 0.927$). In all the patients with biochemical signs of active inflammation, we observed a marked wall hyperintensity on T2FS images. In those cases with nonactive disease, the T2 wall signal was low or absent at the level of the affected loop. Our results are in complete agreement with those of two other studies that reported high T2 values of the bowel wall in active CD [38, 39].

Wall enhancement (WE) is a characteristic finding of active CD; it was first described on contrast enhanced CT and recently on MRI [8, 13–15, 25–31]. In our experience, a marked wall gadolinium enhancement was observed at the level of the pathologic bowel loop in all the cases with an active disease ($p < 0.001$, $r = 0.9$), thus allowing an easy differentiation of inflamed loops from noninflamed loops (Figs. 1E, 3C). We also found a direct statistical correlation between WE and T2W because high-contrast enhancement was usually associated with a high T2 signal and vice versa.

Bowel wall thickening (WT) is a common morphologic change of CD that is not necessarily correlated with active disease. In our series, the bowel wall was moderately or significantly thickened in the majority of patients with active disease, whereas there was usually no significant wall thickening in patients with nonactive disease. However, we also observed marked wall thickening in a few patients with nonactive disease, but in these cases the thickened wall did not show a significant gadolinium enhancement or T2 signal (Fig. 2). The correlation between the wall thickening and the BA was statistically significant but lower when compared with the correlation values of the other parameters ($p < 0.006$, $r = 0.786$).

Fibrofatty proliferation is another typical finding of CD. Two different aspects were considered in our study: the amount of fibrofatty tissue (FP) and its signal on T2FS images (T2FP). Interestingly, in all cases of biologically active CD, a high T2 signal at the level of the FP was noted, probably related to a local "mesenteritis" (edema and dilatation of local vessels), previously described on CT images [40] (Figs. 1C, 3B). A marked FP in nonactive disease was also observed, but in this case the T2 signal on fat-suppressed images was low or completely absent (Fig. 2B). The statistical correlation between the T2 fat hyperintensity and BA ($p < 0.0001$, $r = 0.967$) was highly significant. No previous study, to our knowledge, has assessed the T2 value of FP.

Assessment of image quality was not the major focus of this study. T1-weighted breath-hold and T2 TSE images, however, showed the highest morphologic detail. The anatomic detail

was very low in T2FS images, but these were extremely sensitive in detecting bowel wall inflammation.

In our series, breath-hold acquisition of T1-weighted TFE images significantly reduced the presence of motion artifacts, thus improving the image quality. The use of fat-suppression with T1-weighted TFE images was avoided because it decreases the contrast between the bowel wall, the vessels, the lymph nodes, and the mesenteric fat, with consequent reduction of the morphologic detail of the image, according to the experience of others [31]. Furthermore, on gadolinium-enhanced T1-weighted TFE images, the wall signal intensity was much higher than the fat signal intensity, thereby permitting an easy differentiation between the inflamed wall and the adjacent tissue.

A direct correlation between MRI findings and findings obtained by other imaging modalities or endoscopy was not among the purposes of this study. This correlation can be an object of further investigations. However, the results of barium studies and endoscopy allowed us (with other clinical information) to group the patients into three clinical subgroups (fibrostenosing and inflammatory-perforating disease), which were subsequently correlated with the MRI findings (Table 2).

In summary, a marked WE and an elevated T2W and T2FP were always found in those patients with BA. All these cases belonged to the inflammatory perforating subgroup (Figs. 1C,E, 3B,C). No patients with obstructive/ fibrostenotic disease showed abnormal laboratory values, WE, or wall hyperintensity on T2-weighted images.

The lack of statistical correlation between MRI features and clinical indices of activity (CDAI, OI, SI) noted in our study is not surprising, and it is probably related to the very low sensitivity of these indices. Several investigators have reported a lack of correlation between CT or MRI findings and clinical indexes [14, 27, 28].

On the basis of our results, we believe that MRI can play a larger role in the clinical assessment of CD activity. MRI could be the diagnostic modality used to answer most of the questions of gastroenterologists and surgeons by offering information on both morphologic changes and degree and of inflammatory activity. Its main advantages as compared with other imaging modalities and in particular with CT include (a) lack of radiation exposure, (b) the possibility of using different parameters to evaluate inflammatory activity (gadolinium enhancement and T2 signal), (c) the possibility of obtaining high-quality coronal images to correlate with barium studies (particularly useful, in our experience, in visualizing the ileocecal region), (d) the possibility of evaluating the small intestine by using a negative oral contrast agent (in CT negative contrast agents for the small bowel can be administered

through a jejunal tube only), and (e) a higher contrast enhancement produced by gadolinium versus iodinated contrast agents. Disadvantages are related to the higher costs of MRI and its longer examination time, especially when compared with spiral CT.

In our experience MRI has shown good accuracy in detecting the main inflammatory changes of CD and in differentiating nonactive from active disease. A significant statistical correlation was found between the main MRI signs of inflammation (WE, T2 wall signal, T2 fibrofatty signal) and active disease; in nonactive lesions, these signs were not found.

Acknowledgments. We thank Maria Teresa Barbieri for her contribution to the completion of this article and Salvatore Genna for the photographic material.

References

1. Hanaouer SB. Measurements of disease activity. In: Targan SR, Shanani F, eds. *Inflammatory bowel disease: from bench to bedside*. Baltimore: Williams & Wilkins, 1994:429–444
2. Beck IT. Laboratory assessment of inflammatory bowel disease. *Dig Dis Sci* 1987;32:26S–41S
3. Singleton JW. Clinical activity assessment in inflammatory bowel disease. *Dig Dis Sci* 1987;32:42S–45S
4. Cellier C, Sahmoud T, Froguel E, et al. Correlations between clinical activity, endoscopic severity, and biological parameters in colonic or ileocolonic Crohn's disease. A prospective multicentric study of 121 cases. *Gut* 1994;35:231–235
5. Sachar DB, Andrews HA, Farmer RG, et al. Proposed classification of patients subgroups in Crohn's disease. *Gastroenterol Int* 1992; 5:141–154
6. Quinn PG, Binion DG, Connors PJ. The role of endoscopy in inflammatory bowel disease. *Med Clin North Am* 1994;78:1331–1352
7. Mary JR, Modigliani R. Development and validation of an endoscopic index of the severity for Crohn's disease: a prospective multicentric study. *Gut* 1989;30:983–989
8. Wills JS, Lobis IF, Denstman FJ. Crohn disease: state of the art. *Radiology* 1997;202:597–610
9. Herlinger H. Barium examination. In: Gore RM, Levine MS, Laufer I, eds. *Textbook of gastrointestinal radiology*. Philadelphia: WB Saunders, 1994:767–788
10. Maglante DDT, Chernish SM, Kelvin FM, et al. Crohn disease of the small intestine: accuracy and relevance of enteroclysis. *Radiology* 1992;184:541–545

11. Dijkstra J, Reeders JWA, Tytgat GNJ. Idiopathic inflammatory bowel disease: endoscopic–radiologic correlation. *Radiology* 1995;197:369–375
12. Halligan S, Saunders B, Williams, et al. Adult Crohn disease: can ileoscopy replace small bowel radiology? *Abdom Imaging* 1998;23:117–121
13. Nahakawa S, Takahashi M, Takagi K, et al. The role of computed tomography in management of patients with Crohn disease. *Clin Imaging* 1993;17:193–198
14. Tomei E, Diacinti D, Marini M, et al. Computed tomography of bowel wall in patients with Crohn's disease: relationships of inflammatory activity to biological indexes. *It J Gastroenterol* 1996; 28:487–492
15. Gore RM, Balthazar EJ, Ghahremani GG, et al. CT features of ulcerative colitis and Crohn's disease. *AJR* 1996;167:3–15
16. Sarrazin J, Wilson SR. Manifestations of Crohn disease at US. *Radiographics* 1996;16:499–520
17. Sheridan MB, Nicholson DA, Martin DF. Transabdominal ultrasonography as the primary investigation in patients with suspected Crohn disease or recurrence: a prospective study. *Clin Radiol* 1993; 48:402–404
18. von Oostayen JA, Wasser MNJM, von Hogezaand RA, et al. Activity of Crohn disease assessed by measurement of superior mesenteric artery flow with Doppler US. *Radiology* 1994;193:551–554
19. Giovagnorio F, Diacinti D, Vernia P. Doppler sonography of the superior mesenteric artery in Crohn disease. *AJR* 1998;170:123–126
20. Arndt JW, Grootsholten MI, van Hogezaand RA, et al. Inflammatory bowel disease activity; assessment using technetium-99-HMPAO leucocytes. *Dig Dis Sci* 1997;42(2)
21. Giaffer MH. Labelled leukocyte scintigraphy in inflammatory bowel disease: clinical applications. *Gut* 1996;38:1–5
22. Rafai RB, Nichols JN, Cennerazzo WJ, et al. MRI for evaluation of perianal inflammation. *Abdom Imaging* 1995;20:248–252
23. Myhr GE, Myrvoid HE, Nilsen G, et al. Perianal fistulas: use of MR imaging for diagnosis. *Radiology* 1994;191:545–549
24. O'Donovan A N, Somers S, Farrow R, et al. MR Imaging of ano-rectal Crohn disease: a pictorial essay. *Radiographics* 1997;17:101–107
25. Semelka RC, Shoenuit RP, Silverman R, et al. Bowel disease: prospective comparison of CT and 1.5 T pre- and post-contrast MR imaging with T1 weighted fat-suppressed and breath-hold FLASH sequences. *J Magn Res Imaging* 1991;1:625–632

26. Shoenut JP, Semelka RC, Silverman R, et al. Magnetic resonance imaging in inflammatory bowel disease. *J Clin Gastroenterol* 1993; 17:73–78
27. Shoenut JP, Semelka RC, Magro CM, et al. Comparison of magnetic resonance imaging and endoscopy in distinguishing the type and severity of inflammatory bowel disease. *J Clin Gastroenterol* 1994;19:31–35
28. Kettritz U, Isaaks K, Warshauer DM, et al. Crohn disease. Pilot study comparing MRI of the abdomen with clinical evaluation. *J Clin Gastroenterol* 1995;21:249–253
29. Rollandi GA, Martinoli C, Conzi R, et al. Magnetic resonance imaging of the small intestine and colon in Crohn's disease. *Radiol Med* 1996;91:81–85
30. Rieber A, Wruk D, Nussle K, et al. MRI of the abdomen combined with enteroclysis in Crohn disease using oral and intravenous Gd-DTPA. *Radiologe* 1998;38:23–28
31. Ernst O, Asselah T, Cablan X, et al. Breath-hold fast spin-echo MR imaging of Crohn's disease. *AJR* 1998;170:127–128
32. Hann PF, Stark DD, Lewis JM, et al. First clinical trial of a new superparamagnetic iron oxide for use as an oral gastrointestinal contrast agent in MR imaging. *Radiology* 1990;175:695–700
33. Holzknecht N, Helmberger T, von Ritter C, et al. MRI of the small intestine with rapid MRI sequences in Crohn disease after enteroclysis with oral iron particles. *Radiologe* 1998;38:29–36
34. Malchow H, Ewe K, Brandes JV, et al. European Cooperative Crohn's Disease Study (ECCDS): results of drug treatment. *Gastroenterology* 1984;86:246–266
35. Best WR, Bectel JM, Singleton JW, et al. Development of a Crohn's Disease Activity Index: National Cooperative Crohn's Disease Study. *Gastroenterology* 1976;70:439–444
36. Best WR, Bectel JM, Singleton JW, et al. Rederived values of the eight coefficients of the Crohn's Disease Activity Index (CDAI). *Gastroenterology* 1979;77:843–846
37. Lee JK, Semelka RC. MR imaging of the small bowel using the HASTE sequence. *AJR* 1998;170:1457–1463
38. Madsen SM, Thomsen HS, Munkholm P, et al. Active Crohn's disease and ulcerative colitis evaluated by low-field magnetic resonance imaging. *Scand J Gastroenterol* 1998;33:1193–1200
39. Madsen SM, Thomsen HS, Schlichting P, et al. Evaluation of treatment response in active Crohn's disease by low-field magnetic resonance imaging. *Abdom Imaging* 1999;24:232–239

40. Meyers MA, McGuire PV. Spiral CT demonstration of hypervascularity in Crohn disease: "vascular jejunization of the ileum" or the "comb sign." *Abdom Imaging* 1995;20:327–332

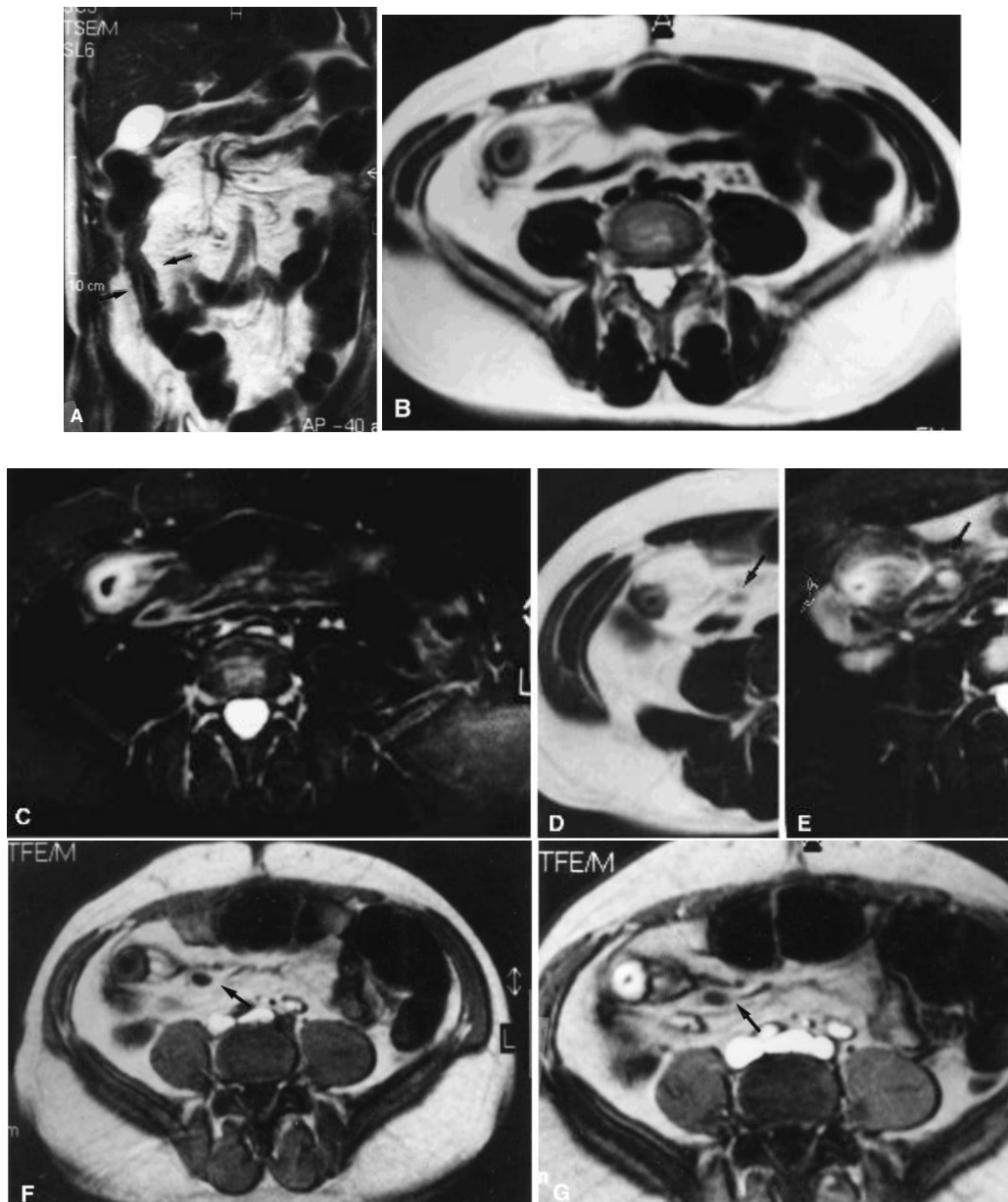


Fig. 1. Recurrence of Crohn disease (CD) in a 52-year-old male with previous resection of the terminal ileum and ascending colon. **A** Coronal T2-weighted TSE image: recurrence of CD at the level of the anastomotic ileal loop is clearly evident (*arrows*). The affected loop has thickened walls and a reduced, irregular lumen more than approximately 10 cm long. **B** Axial T2-weighted TSE image shows thickening and hyperintensity of the wall of the anastomotic loop, inhomogeneity of the perivisceral fat tissue, and dilation of the afferent vessels. **C** On the axial fat-suppressed T2-weighted TSE image obtained at the same level, the visibility of wall hyperintensity is greatly improved, as is hyperintensity of the perivisceral fat tissue. Initial signs of wall inflammation are also evident in an adjacent ileal loop. Axial T2-weighted TSE (**D**) and fat-suppressed T2-weighted TSE (**E**) images obtained at a higher level. The perivisceral fat hyperintensity is more evident, as is a regional enlarged lymph node (*arrows*), which shows a high signal after fat suppression due to inflammation. **F** On the breath-hold T1-weighted TFE image acquired at the same level, vascular dilation and prominence of the vasa recta are clearly visible, as is a local enlarged lymph node (*arrow*). **G** Breath-hold T1 weighted TFE image obtained after intravenous injection of gadolinium shows marked wall thickening and mural enhancement (*arrow*), indicating active mural disease

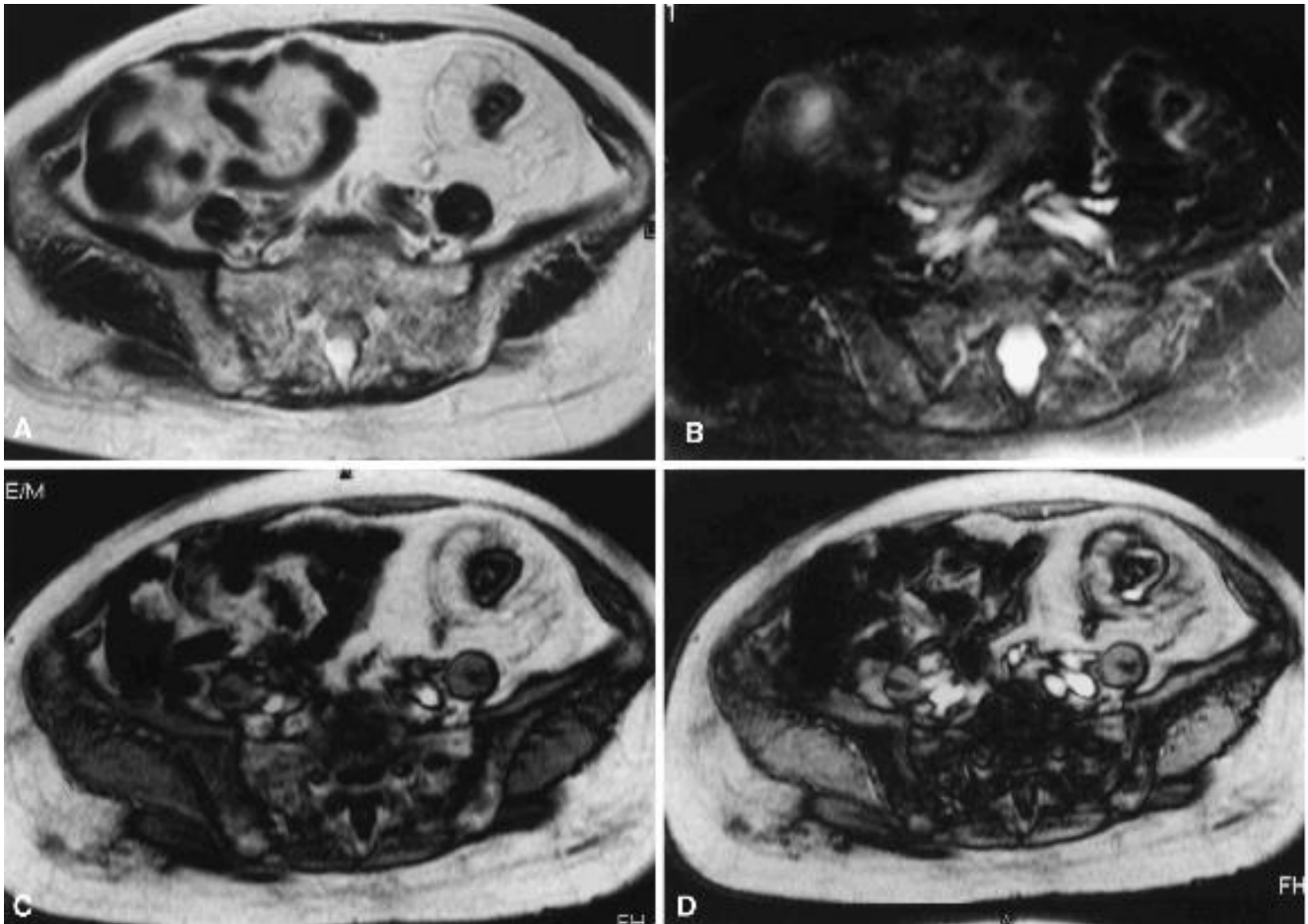


Fig. 2. An 81-year-old female patient, with a long history of Crohn disease, treated with corticosteroids. **A** The axial T2-weighted TSE image shows wall thickening at the level of the sigmoid colon, with marked fibrofatty proliferation displacing the adjacent ileal loops. **B** Axial fat-suppressed T2-weighted TSE image demonstrates lack of wall signal at the level of the sigmoid wall, except for a focal area at the mesenteric side; no significant signal is evident in the fibrofatty tissue. **C** Axial breath-hold T1-weighted TFE image shows wall thickening and fibrofatty proliferation. **D** Axial breath-hold T1-weighted TFE image obtained after gadolinium injection demonstrates low or absent enhancement, except for a focal area in the sigmoid wall. Colonoscopy showed normal mucosa at the level of the sigmoid colon.

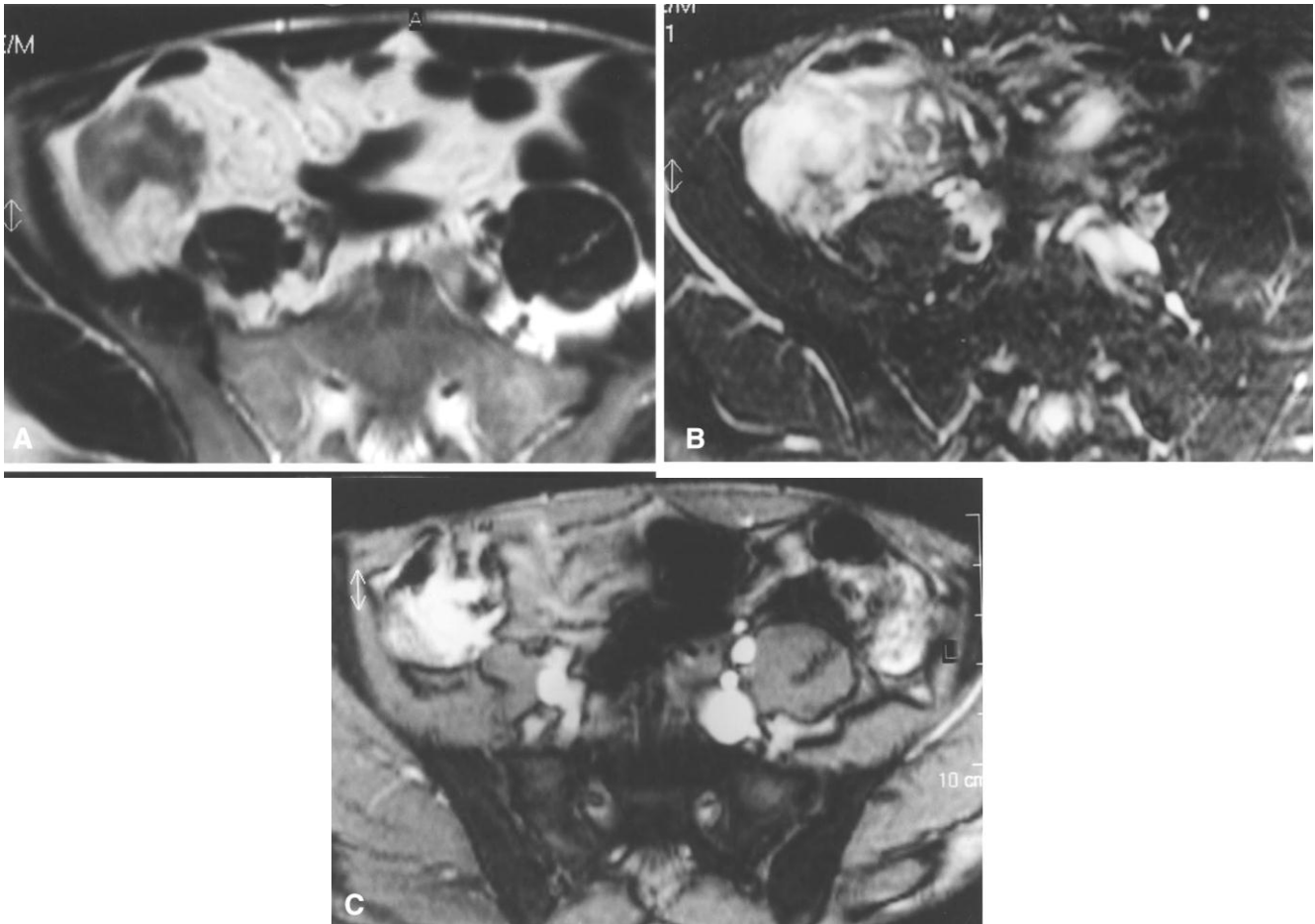


Fig. 3. A 36-year-old male with ileocolic CD and clinical signs of activity (erythrocyte sedimentation rate 55, white blood cell count 9000/mm³). **A** Axial T2-weighted TSE image demonstrates wall thickening of the cecum and last ileal loop. **B** Axial T2-weighted fat suppressed TSE image shows marked hyperintensity of the bowel wall and adjacent fat tissue, indicating active disease. **C** Axial breath-hold T1-weighted TFE image obtained after intravenous injection of gadolinium shows marked mural enhancement of the cecum and ileocecal valve.

Table 1. Overall MRI and clinical results

Patient	Sex	AGE	WT	WE	T2W	FP	T2FP	ESR	WBC	CRP	Or	OI	BA
1	F	22	2	2	2	1	2	52	8.3	+	+	5	1
2	M	28	1	1	1	1	1	21	7	+	+	1	1
3	M	28	2	1	2	2	2	24	8	++	++	0	1
4	F	31	0	0	1	0	0	13	7	-	-	0	0
5	M	34	0	0	0	0	0	11	6.5	-	-	3	0
6	M	35	0	0	0	0	0	11	7	-	-	2	0
7	M	35	0	0	0	0	0	10	7	-	-	3	0
8	M	27	2	2	2	1	1	18	4.7	+	+	1	1
9	F	81	2	0	0	2	0	15	6.3	-	-	0	0
10	F	51	1	1	2	1	2	18	6	+	+	2	1
11	M	36	0	0	0	0	0	4	8	-	-	0	0
12	M	36	0	0	0	0	0	6	4.5	-	-	0	0
13	M	52	2	2	2	2	2	21	10	++	+	0	1
14	F	28	2	2	2	2	2	41	9.7	++	+	2	1
15	M	36	2	2	2	1	2	51	9.9	++	+	1	1
16	F	29	2	1	1	1	1	15	9	+	+	0	1
17	M	33	1	0	0	1	0	11	4	-	-	0	0
18	F	27	0	0	0	1	0	9	4.5	-	-	0	0
19	M	34	0	0	0	1	0	6	5.2	-	-	0	0
20	F	30	1	1	0	0	0	15	7	-	-	1	0

WT, wall thickness;

WE, wall enhancement;

T2W, signal of the affected wall on T2 weighted fat-suppressed images;

FP, fibrofatty proliferation;

T2FP, signal of fibrofatty proliferation on T2-weighted fat-suppressed images;

score of MRI findings: 0 5 absent, 1 5 mild, 2 5 high;

ESR, erythro sedimentation rate (mm/h);

WBC, white blood count 3 1000/mm³;

CRP, C reactive protein;

Or, orosomucoids;

OI, Oxford Index;

BA, biological activity; score: 1 5 present, 0 5 absent

Table 2. Correlation between MRI parameters and active or nonactive disease

	Nonactive disease ^a	Active disease ^b
WT		
Marked	1	7
Mild	2	2
Absent	8	0
T2W		
High	0	7
Mild	1	2
Absent	10	0
WE		
High	0	5
Mild	1	4
Absent	10	0
FP		
Marked	1	3
Mild	3	6
Absent	7	0
T2FP		
High	0	6
Mild	0	3
Absent	11	0

a. Fibrostenosing lesions, $n = 11$

b. Inflammatory perforating lesions, $n = 9$

WT, wall thickness; WE, wall enhancement; T2W, signal of the affected wall on T2-weighted fat-suppressed images; FP, fibrofatty proliferation; T2FP, signal of fibrofatty proliferation on T2-weighted fat-suppressed images

Table 3. Interobserver agreement

	WT	WE	T2W	FP	T2FP
R1 vs. R2					
κ	0.923	0.796	0.762	0.54	0.833
SE	0.027	0.026	0.028	0.027	0.027
R1 vs. R3					
κ	0.571	0.704	1	0.766	1
SE	0.020	0.023	0.027	0.028	0.03
R2 vs. R3					
κ	0.634	0.627	0.839	0.615	0.833
SE	0.022	0.025	0.029	0.027	0.027

WT, wall thickness; WE, wall enhancement; T2W, signal of the affected wall on T2-weighted fat-suppressed images; FP, fibrofatty proliferation; T2FP, signal of fibrofatty proliferation on T2-weighted fat-suppressed images; R1-3, observers 1-3; κ, coefficient of agreement: >0.050 = moderate, >0.60 = good, >0.70 = considerable, >0.80 = excellent, <=1 = perfect; SE, standard error

Table 4. Spearman rank correlations

	WT	WE	T2W	FP	T2FP	ESR	OI	SI	BA
WT	1	0.816	0.733	0.773	0.772	0.786	0.122	0.112	0.786
<i>p</i> *	1	0.0004	0.001	0.0007	0.0008	0.0006	0.59	0.62	0.0006
WE	0.816	1	0.876	0.531	0.892	0.900	0.051	0.284	0.900
<i>p</i> *	0.0004	1	0.0001	0.020	0.0001	0.0001	0.0822	0.815	0.0001
T2W	0.733	0.876	1	0.573	0.946	0.927	0.093	0.363	0.927
<i>p</i> *	0.001	0.0001	1	0.012	0.0000	0.0001	0.683	0.113	0.0001
FP	0.773	0.531	0.573	1	0.649	0.620	0.173	0.047	0.620
<i>p</i> *	0.0007	0.02	0.012	1	0.004	0.006	0.449	0.837	0.006
T2FP	0.772	0.892	0.946	0.649	1	0.961	0.158	0.466	0.961
<i>p</i> *	0.0008	0.0001	0.0000	0.0047	1	0.0000	0.496	0.0422	0.0000

WT, wall thickness;

WE, wall enhancement;

T2W, signal of the affected wall on T2-weighted fat-suppressed images;

FP, fibrofatty proliferation;

T2FP, signal of fibrofatty proliferation on T2-weighted fat-suppressed images;

ESR, erythrocyte sedimentation rate (mm/h);


OI, Oxford Index;

SI, Simple

Index;

BA, Biological activity

**p*<0.01 was considered significant



Picture by Francesca Maccioni 2012
Sunset from the dining room window (D)

Chapter 3

MR imaging in patients with Crohn Disease: value of T2- versus T1-weighted Gadolinium-enhanced MR sequences with use of an oral superparamagnetic contrast agent

F. Maccioni¹, A. Bruni¹, A. Viscido², M.C. Colaiacomo¹, A. Cocco², C. Montesani³, R. Caprilli², M. Marini¹

Radiology. 2006;238(2):517-530.

¹Departments of Radiological Sciences, ²Clinical Sciences, Gastroenterology Unit, and ³Surgical Sciences, University of Rome La Sapienza, Via Regina Elena 324, 00161 Rome, Italy.

Abstract

Purpose: To prospectively compare oral contrast-enhanced T2-weighted half-Fourier rapid acquisition with relaxation enhancement (RARE) magnetic resonance (MR) imaging with T1-weighted gadolinium-enhanced fast low-angle shot (FLASH) MR and standard examinations in the evaluation of Crohn disease. *Materials and Methods:* Institutional review board approval and informed consent were obtained. Fifty-nine patients with Crohn disease underwent MR imaging after oral administration of a superparamagnetic contrast agent; RARE plain and fat-suppressed sequences and FLASH sequences were performed before and after intravenous injection of gadolinium chelate. References were endoscopic, small-bowel barium, computed tomographic, ultrasonographic, and clinical-biochemical scoring of disease activity. Two radiologists analyzed MR images for presence and extent of Crohn disease lesions, presence of strictures or other complications, and degree of local inflammation. MR findings were correlated with endoscopic, radiologic, and clinical data (*K* statistic and Spearman rank correlation test). *Results:* T2-weighted MR was 95% accurate, 98% sensitive, and 78% specific for detection of ileal lesions. Agreement between T1- and T2-weighted images ranged from 0.77 for ileal lesions to 1.00 for colic lesions. T2-weighted MR enabled detection of 26 of 29 severe strictures, 17 of 24 enteroenteric fistulas, and all adhesions and abscesses; T1-weighted MR enabled detection of 20 of 29 severe strictures, 16 of 24 enteroenteric fistulas, and all adhesions and abscesses. Complications leading to surgery were found in 12 (20%) patients; these were assessed correctly with either T1- or T2-weighted images. T2-weighted signal intensities of the wall and mesentery correlated with biologic activity ($P < .001$, r of 0.774 and 0.712, respectively). Interobserver agreement was 0.642–1.00 for T2-weighted and 0.711–1.00 for T1-weighted images. *Conclusion:* T2-weighted MR can depict Crohn disease lesions and help assess mural and transmural inflammation with the same accuracy as gadolinium-enhanced T1-weighted MR. Combination of gadolinium-enhanced T1- and T2-weighted sequences is useful in the assessment of Crohn disease.

Introduction

Crohn disease is a chronic disorder of the entire alimentary tract that is characterized by an inflammatory process that extends through all the layers of the bowel wall and frequently leads to strictures, fistulas, and/or abscesses. Because this condition is treated with anti-inflammatory drugs for long periods of time, a routine assessment of the inflammatory activity (ie, Crohn disease activity) is required to monitor the effects of medical therapy (1–4). At the same time, periodic evaluation of disease extent throughout the small and large bowels and detection of possible complications, such as strictures or fistulas, are also needed to determine the course and severity of the disease or to plan any changes in therapy (5).

According to several reports, magnetic resonance (MR) imaging is a valuable tool in the detection of main intestinal abnormalities in patients with Crohn disease and in the evaluation of disease activity (6–14). In addition, MR imaging has several advantages compared with other imaging modalities, particularly computed tomography (CT), which plays a major role in the evaluation of patients with Crohn disease. First, MR imaging lacks ionizing radiation, which is extremely important, considering these patients are frequently young and will require numerous imaging studies during their lives to enable assessment of the evolution of their chronic disease. Second, it is widely accepted that the higher intrinsic contrast of MR imaging allows easier detection of inflammatory changes in human tissues. Third, since different MR imaging parameters can be used to evaluate any disease, MR imaging could offer additional information on Crohn disease with respect to CT. For example, T1- and T2-weighted MR sequences can be used, or the signal intensity can be modulated by selectively suppressing the fat signal intensity on T1- and T2-weighted images.

To our knowledge, there is still no agreement, however, regarding the MR imaging technique to be used, the choice of intestinal contrast agent (ie, positive, biphasic, or negative contrast agents) (15–24), or the type of contrast agent administration (ie, oral administration, administration through a nasojejunal tube, or MR enteroclysis) (9,18,19,22,25,26). Several studies on the detection of Crohn disease lesions have shown a higher diagnostic value of T1-weighted gadolinium-enhanced images compared with that of T2-weighted images (11,12). All of these studies were, however, based on the use of biphasic oral contrast agents (producing a dark lumen on T1-weighted images and a bright lumen on T2-weighted images), which are more valuable for T1-weighted sequences than for T2-weighted sequences.

T2-weighted sequences are widely considered to be extremely sensitive in the study of inflammatory human tissues (eg, musculoskeletal or nervous tissues), but their value is likely

underestimated in inflammatory bowel diseases. Superparamagnetic agents (ie, iron oxide particles) reduce the high signal intensity of intestinal fluids on both T2- and T1-weighted MR images, thus producing a homogeneous negative contrast effect (10,17,20,23,24,26). To increase the depiction of the intestinal wall on T2-weighted images, fat-suppressed sequences can be used, as shown in previous studies (10,19). Thus, the purpose of our study was to prospectively determine the accuracy of T2-weighted half-Fourier rapid acquisition with relaxation enhancement (RARE) sequences after oral administration of a negative oral contrast agent in the evaluation of Crohn disease lesions compared with the accuracies of T1-weighted gadolinium-enhanced fast low-angle shot (FLASH) sequences and reference-standard examinations, which included clinical and laboratory tests, ileocolic endoscopic examination, radiologic barium study of the small and large bowel, and surgical assessment.

Materials and Methods

Patient population

The study protocol was approved by our institutional review board, and written informed consent was obtained from all the patients.

Between January and December 2002, 70 consecutive patients with a proved diagnosis of Crohn disease were prospectively selected for MR imaging studies during a periodic clinical and diagnostic assessment. All patients who had already undergone radiographic examination of the bowel in the previous 12 months were previously excluded from the study for radiation protection reasons. Two patients refused to undergo the examination because they were claustrophobic, while nine were excluded because they had already undergone MR imaging.

A total of 59 patients (30 men, 29 women) with a mean age of 46.3 years (age range, 18–76 years) were included in this study. The mean age of women was 46.7 years (age range, 18–70 years), and the mean age of men was 46.0 years (age range, 23–76 years). No statistical differences in age were found between women and men ($P > .05$). Researchers periodically followed up patients in the gastroenterology unit of our hospital (University of Rome La

Sapienza, Rome, Italy), whereas imaging examinations were performed in the department of radiology at the same institution. MR imaging was included in the follow up of patients with Crohn disease, in association with ultrasonography (US), ileocolic endoscopic examination, barium enema study, clinical evaluation, and laboratory testing. The diagnosis of Crohn disease was always based on standard criteria (27) by associating findings of radiologic barium studies, endoscopies, and histologic evaluations of biopsy specimens. All patients were undergoing pharmacologic treatment with oral corticosteroids or other drugs (ie, azathioprine, infliximab, mesalazine, or antibiotics).

Patient examination

Examination of patients included clinical evaluations, laboratory tests, ileocolic endoscopic examinations, and barium studies, all of which were performed either before or after MR imaging and within a maximum interval of 15 days.

Barium studies of the small bowel were performed in all the patients as a follow-through procedure or with enteroclysis, in accordance with standard techniques, by five experienced gastrointestinal radiologists (all of whom had more than 10 years of experience and were blinded to the results of MR imaging). The enteroclysis technique was based on the association of methylcellulose and barium sulfate as intestinal contrast agents, which were administered through a nasojejunal tube. Barium enema study of the colon was also performed whenever colonoscopy was not feasible or findings were incomplete, with use of the double-contrast technique.

Endoscopy of the colon and terminal ileum was planned for all patients within 15 days of MR imaging and was always performed by endoscopists with more than 8 years of experience who were blinded to the results of MR imaging and worked in the gastroenterology unit of our university hospital.

Location and length of the disease at the level of the small and large bowels (from jejunum to rectum), number and degree of strictures, and presence of fistulas were documented at ileocolic endoscopic examination and barium study; these tests were considered the reference examinations (5,28).

To assess other Crohn disease complications, such as abscesses, phlegmons and nonenteroenteric fistulas, each patient also underwent abdominal and pelvic US, which was performed by three experienced radiologists within 15 days of MR imaging. These radiologists were blinded to the results of MR imaging, and they used both 3.5- and 7.5- MHz probes. If a severe complication was found at US or strongly suspected at clinical

examination, CT examination of the abdomen and pelvis was performed with a multi-detector row CT scanner (Somatom Plus 4 Volume Zoom; Siemens, Erlangen, Germany) and a standard technique for examination of the abdomen and pelvis.

Patients with severe complications of Crohn disease underwent surgery, which was considered to be the reference standard whenever it was performed.

The Crohn disease activity index (CDAI), according to the criteria proposed by Best et al (29,30), was evaluated in all patients within 1 week of MR imaging by an experienced gastroenterologist (A.V., with 10 years of experience) and a gastroenterology resident (A.C.). This index was used to assign a specific score to the different clinical signs and symptoms (eg, duration of symptoms, diarrhea, body temperature, abdominal pain). A CDAI score lower than 150 was considered inactive (scored as 0), a score between 150 and 350 was considered mildly to moderately active (scored as 1), and a score higher than 350 was considered severe (scored as 2).

Laboratory tests were performed within 1 week before or after MR imaging; white blood cell (WBC) count, erythrocyte sedimentation rate (ESR), C-reactive protein (CRP) level, orosomucoids level, and a 1-acid-glycoprotein level were assessed. ESR was considered negative if it was less than or equal to 7 mm per minute (score of 0), positive and moderate if it was between 8 and 15 mm per minute (score of 1), and positive and high if it was greater than 15 mm per minute (score of 2). CRP was considered positive (score of 1) if CRP levels were higher than 5 mg/L and negative if CRP levels were lower than 5 mg/L (score of 0). A positive result from three of five laboratory tests indicated the presence of sustained inflammatory events or biologic activity, which was then scored as 1. If results of four or five tests were positive, biologic activity was considered high (scored as 2), whereas it was considered absent or not relevant (scored as 0) if results of two or fewer tests were positive. In our study, the positivity of acute-phase reactants was considered the main index of biologic activity and served as the reference standard in the assessment of intestinal inflammatory activity. CDAI scores were compared with MR imaging findings but were not considered as a reference standard.

Patients underwent laboratory evaluation in different clinics; we excluded data based on reference values that were different from those used by us, as well as biochemical examinations dated 10 days before or after the date of the MR examination.

MR Imaging Technique

All patients were examined 1 hour after oral administration of 600–900 mL of the superparamagnetic contrast agent ferumoxsil (Lumirem; Laboratoires Guerbet, Paris, France), which is a suspension of silicone-coated iron oxide particles. The total volume of oral contrast material administered varied according to patient acceptance and intestinal length (in patients who had undergone previous surgical resection). Approximately 1 hour was needed for homogeneous distribution of the contrast material through the small and large bowel.

MR imaging examinations were performed with a 1.5-T system (Magnetom Vision Plus; Siemens) equipped with a phased-array coil. A standard MR imaging study for assessment of Crohn disease included T2-weighted RARE sequences, which were performed in the transverse and coronal planes to cover the entire upper and lower abdomen, with the following parameters: repetition time msec/echo time msec, 4.4/90; 150° flip angle; 160 x 256 matrix; 20-second breath hold; 20 sections acquired; 7-mm section thickness; 15% gap for transverse acquisitions; and no gap for coronal acquisitions. T2-weighted RARE sequences were performed after fat-suppression with a presaturation technique in only the transverse plane. Usually, two or three breath holds were required for imaging of the abdomen and pelvis, whereas one breath hold was sufficient for imaging of the coronal plane.

T1-weighted FLASH sequences were performed with the following parameters: 160/5.7, 20-second breath hold for 20 sections, 70°-90° flip angle, 160 x 256 matrix, 6-mm section thickness, 15% gap for the transverse plane, and no gap for the coronal plane. T1-weighted FLASH sequences were performed only in the transverse plane and without fat suppression before injection of gadolinium-based contrast material, whereas they were performed in the transverse and coronal planes after injection of gadolinium-based contrast material, with the addition of fat suppression. Intravenous injection of gadopentetate dimeglumine (Magnevist; Schering, Berlin, Germany) was performed with a power injector at a flow rate of 2 mL/sec and with a mean dose of 15 mL per patient (with a concentration of 0.18 mmol per kilogram of body weight) and followed by injection of 20 mL of saline; image acquisition was started 60 seconds after the beginning of the injection. After injection, transverse sequences through the abdomen and pelvis were performed first and followed by coronal sequences; all gadolinium-enhanced sequences required three or four breath holds. The median examination time was 30 minutes (range, 20-40 minutes).

Analysis of MR Images

Images were evaluated on film hard copies by an experienced gastrointestinal radiologist (F.M., with 8 years of experience in MR imaging of the gastrointestinal tract) and a diagnostic radiology resident (M.C.C.). Reviewers worked independently and were blinded to the results of clinical and endoscopic examinations and barium studies.

For each patient, T2- and T1- weighted images (groups A and B, respectively) were evaluated and scored in a randomized fashion in different sessions. In additional sessions, T1- and T2-weighted images were analyzed and scored together (group C).

The bowel was divided into seven different intestinal segments, as follows: jejunum, ileum, ascending colon, transverse colon, descending colon, sigmoid colon, and rectum, for a total of 413 segments.

Once the Crohn disease lesions were identified in one or more intestinal segments, the following parameters were assessed quantitatively or qualitatively:

In group A (ie, T2-weighted images obtained with and without fat suppression), we assessed the following parameters: (a) lesion site, (b) lesion extent (measured in centimeters), (c) number of strictures and their degree (based on the degree of prestenotic dilatation), (d) maximum bowel wall thickness (measured in millimeters), (e) bowel wall signal intensity, (f) signal intensity of fibrofatty proliferation on fat-suppressed images, and (g) local complications (eg, local free fluid, phlegmons, abscesses, or fistulas).

In group B (ie, T1-weighted images obtained before and after administration of gadolinium-based contrast agents), we assessed the following parameters: (a) lesion site, (b) lesion extent (measured in centimeters), (c) number of strictures and their degree (based on the degree of prestenotic dilatation), (d) maximum bowel wall thickness (measured in millimeters), (e) gadolinium enhancement of the bowel wall, (f) enhancement of fibrofatty proliferation, and (g) local complications (eg, local free fluid, phlegmons, abscesses, or fistulas).

In group C (ie, T1- and T2-weighted images together), we assessed the following parameters: (a) lesion site, (b) lesion extent (measured in centimeters), (c) number of strictures and their degree (based on the degree of prestenotic dilatation), (d) maximum bowel wall thickness (measured in millimeters), (e) degree of bowel wall inflammation (gadolinium enhancement and T2-weighted signal intensity) (f) signs of mesenteric inflammation, and (g) local complications (eg, local free fluid, phlegmons, abscesses, or fistulas).

Lesion site (parameter *a*) was classified with letters indicating one or more of the seven different previously mentioned intestinal segments. Lesion extent (parameter *b*) was measured in centimeters. Number of strictures (parameter *c*) was quantified as a given number or as zero. The degree of the strictures was considered mild when the lumen diameter above the stricture was slightly higher than the normal value, and it was considered moderate to severe when it was at least more than twice the normal value. Bowel wall thickness (parameter *d*) was qualitatively evaluated and considered normal (score of 0) when thickness was 4 mm or less, moderate (score of 1) when thickness was 4–7 mm, and marked (score of 2) when thickness was more than 7 mm.

In group A, signal intensity of the bowel wall on T2-weighted fat-suppressed images (parameter *e*) was considered abnormal if it was greater than that of the liver or spleen, absent or minimal (score of 0) if it was lower than that of the liver or spleen, mild (score of 1) if it was greater than that of the spleen but lower than that of the renal cortex, and marked (score of 2) if it was equal to that of the renal cortex or cerebrospinal fluid.

In group B, gadolinium enhancement of the bowel wall (parameter *e*) was considered abnormal if the degree of enhancement at visual inspection was greater than that of the splenic parenchyma. Gadolinium enhancement of the bowel wall was absent (score of 0) if no enhancement was observed, mild (score of 1) if enhancement of the bowel wall was greater than enhancement of the spleen but lower than enhancement of the renal cortex, and marked (score of 2) if enhancement of the bowel wall was equal to enhancement of the renal cortex or the intravascular signal, according to previous studies (11,12). In group C, both criteria were considered.

Increased perivisceral fat signal intensity on gadolinium-enhanced or T2-weighted fat-suppressed MR images (parameter *f*) was considered a sign of transmural inflammation and scored as 0 if it was absent (ie, normal fat tissue), as 1 if it was lower than that of the inflamed bowel wall, and as 2 if it was similar to hyperintensity of the bowel wall.

Morphologic and activity-related MR imaging parameters

All MR imaging parameters of groups A, B, and C were divided into morphologic and activity-related groups. In groups A, B, and C, parameters *a*, *b*, *c*, and *g* (ie, lesion site, lesion extent, number of strictures and their degree, and local complications, respectively) were considered morphologic parameters and evaluated quantitatively, whereas parameters related to mural and extramural inflammation (activity-related parameters) were assessed qualitatively. The images were analyzed quantitatively and qualitatively on film hard copies for groups A, B, C.

The reference standards for morphologic parameters were endoscopy and barium study. Reference standards for parameter *g* (ie, local complications) were CT, US, and surgery for abscesses and phlegmons that were treated surgically; CT for phlegmons that were treated conservatively; and barium enema for fistulas.

The reference standard for parameters *d*, *e*, and *f* of all activity-related groups was the biologic activity considered on a per-patient basis. The results were also compared with biologic tests and with the CDAI. If more than one bowel segment was involved, only the site of maximum MR activity was considered for statistical correlation with the reference examination.

Statistical analysis

Statistical differences in age between men and women were calculated with the Kolmogorov-Smirnov test. A *P* value of less than .05 indicated a statistically significant difference. Interobserver agreement on MR imaging parameters was calculated with the *k* statistic. The general linear model test has been used to compare lengths of diseased segments (pairwise comparison).

MR imaging parameters of groups A, B, and C were compared with the reference biologic activity by using nonparametric statistical analysis (Spearman rank correlation); *P* values less than .05 were considered to indicate a statistically significant difference. Correlation between different T1- and T2- weighted parameters was performed by using the *k* statistic. The statistical software used was SPSS for Windows (release 10.0.0; SPSS, Chicago, Ill).

Sensitivity, specificity, positive and negative predictive values, and accuracy were assessed with standard formulas. Although we report the interobserver agreement between an experienced gastrointestinal radiologist and a 4th-year resident for lesion detection at any level of the gastrointestinal tract, we considered only those results that were obtained from the experienced radiologist (reader 1) for analysis of sensitivity and specificity.

Results

Patient evaluation

Small-bowel barium studies were performed in all patients (ie, small-bowel follow-through studies in 30 patients and enteroclyses in 29) (Tables 1–3). Colonoscopy was considered complete in 45 of 59 patients, with the last 10 cm of the ileum also assessed. In 11 patients, colonoscopy was incomplete or could not be performed because of the severity of the

disease, and three patients refused the examination. In these 14 patients, the colon was evaluated with a barium enema study.

Ileocolic endoscopic examinations and barium studies revealed that 50 (85%) of 59 patients had ileal lesions alone or in association with colonic or jejunal lesions; in particular, other disease locations (found alone or more frequently associated with ileal lesions) included the jejunum in nine (15%) patients, the right colon in nine (15%), the transverse colon in seven (12%), the descending colon in nine (15%), and the sigmoid colon in 12 (20%). The overall mean disease length was 36.3 cm per patient (range, 5–130 cm), and the average number of affected segments was 1.48 per patient; the association of ileal and colonic disease was the most common finding, occurring in 12 (20%) of 59 patients.

A total of 47 strictures were found at the level of the small and large bowel in 22 patients who underwent barium studies or ileocolic endoscopic examinations. On the basis of the degree of prestenotic dilation, 29 strictures were judged to be severe or moderate and 18 were judged to be mild; three strictures required surgery.

Enteroenteric fistulas were found in nine patients; one patient with complex enteroenteric and cutaneous fistulas underwent surgery. Results of radiologic barium studies and endoscopy regarding location and length of the disease at the level of the small and large bowel (from the jejunum to the rectum), number and degree of the strictures, and presence of fistulas are reported in Tables 1–3.

Clinical activity was evaluated with the CDAI, which showed that Crohn disease was active in 50 patients (CDAI score > 150) and in clinical remission in nine. Among the 50 patients with active Crohn disease, 32 had a CDAI value of 150–350, whereas 18 had more severe symptoms and a CDAI of more than 350.

Laboratory tests showed that 45 of 59 patients had a positive CRP level and 56 of 59 patients had an ESR higher than 7 mm per minute; ESR ranged from 8 to 15 mm per minute in 26 of 59 patients and was higher than 15 mm per minute in 30 patients. By considering all the positive acute-phase reactants, the biologic activity was found to be very high (four or five positive reactants) in 27 patients, moderate (three positive reactants) in 22 patients, and absent (only two or fewer positive reactants) in 10 patients.

Eight patients underwent surgery to treat an abscess or phlegmon ($n = 5$) or a complex fistulous tract involving the psoas muscle ($n = 1$), the urinary bladder ($n = 1$), or the ovaries ($n = 1$). Three patients underwent surgery to treat severe intestinal strictures, and one patient underwent surgery to treat complex enteroenteric cutaneous fistulas.

In total, 12 (20%) of 59 patients underwent surgery to treat complicated Crohn disease 5–30 days after MR examination.

Morphologic assessment of Crohn Disease with MR imaging

Identification of lesion site. In the detection and localization of Crohn disease lesions from the jejunum to the rectum, T2-weighted RARE images showed an accuracy of 93%–95%, with a mean value of 95% (Tables 4–6). In the depiction of ileal lesions, they showed 98% sensitivity, 78% specificity, 96% positive predictive value, and 88% negative predictive value (Figs 1a, 1b, 2a, 2c–2e).

T1-weighted RARE images were used to locate Crohn disease lesions from the jejunum to the rectum with an accuracy of 90%–97% (mean, 93%) (Figs 1c, 2b, 2c, 2f).

For the detection of Crohn disease lesions at any level of the gastrointestinal tract, good statistical agreement was present between T1-weighted gadolinium-enhanced and T2-weighted MR images (Figs 1b, 1c), with r values of 0.77 for ileal lesions and 1.00 for colic lesions (Table 6).

Detection of disease extent. In the assessment of disease extent, a statistical difference between T2-weighted sequences and the reference standard was not found ($P > .05$) (Table 1). The mean disease length was 35.5 cm (median length, 35 cm; standard deviation, 21.2 cm) for MR imaging examinations and 36.3 cm (median length, 36 cm; standard deviation, 19.2 cm) for reference examinations (Fig 2a–2c).

Detection of strictures and other complications. MR imaging enabled detection of 39 (83%) of 47 strictures in 20 patients, with underestimation of low-grade (13 of 18 were detected) rather than high-grade strictures (26 of 29 were detected) (Table 3).

T2-weighted RARE sequences were used to detect 39 of 47 strictures in 20 patients. The accuracy of T1-weighted gadolinium-enhanced sequences was slightly lower, enabling detection of 31 of 47 strictures in 16 patients (Fig 2a–2c). The overall sensitivity, specificity, and accuracy of T2-weighted sequences in the detection of strictures were 83%, 100%, and 91%, respectively, whereas the overall sensitivity, specificity, and accuracy of T1-weighted gadolinium-enhanced sequences were 66%, 100%, and 81%, respectively.

At reference examinations, 24 enteroenteric fistulas were found in nine patients. T2- and T1-weighted sequences enabled detection of 17 (71%) of 24 and 16 (66%) of 24 enteroenteric fistulas, respectively (Fig 3); the association of T1- with T2-weighted images increased the overall detection rate to 75% (18 of 24 enteroenteric fistulas); in two (22%) of nine patients,

fistulas were misinterpreted as tight adhesions. The overall sensitivity, specificity, and accuracy of T2-weighted sequences in the detection of enteric fistulas were 71%, 100%, and 91%, respectively, whereas overall sensitivity, specificity, and accuracy of T1-weighted gadolinium-enhanced sequences were 67%, 100%, and 89%, respectively.

MR imaging was used to detect other types of nonenteric fistulas (ie, enterovesical, entero-ovarian, and enteropsoas) in three patients. All of these fistulas were considered severe complications. None of these nonenteric fistulas was detected at reference examinations (ie, barium enema studies), but they were all confirmed at surgery.

Enteric fistulas were missed at MR imaging in two patients, but complex nonenteroenteric fistulous tracts were diagnosed with MR imaging in three patients. A large number of adhesions (48 adhesions in 20 patients), all of which were underestimated with reference examinations, were detected with MR imaging.

MR imaging revealed four abscesses in four patients (Fig 4); all abscesses were confirmed at surgery but were undetected at barium study or colonoscopy. MR imaging also depicted three phlegmons. One phlegmon was treated with surgical resection, and the other two were treated with pharmacologic therapy and confirmed with other imaging modalities (US and CT). All abscesses and phlegmons were diagnosed with both T1- and T2-weighted images (Fig 4a, 4b).

Assessment of Disease Activity with MR imaging

Correlation between MR imaging data and disease activity (both biologic and clinical activity) was calculated in 30 of 59 patients, since biochemical data were not available for all patients at the time of examination (Table 7). When biochemical data were dated more than 10 days before or after the examination date, they were excluded from the correlation.

A statistically significant correlation ($P < 0.001$) was found between the T2-weighted signal intensity of the wall (parameter *e*, group A) and the ESR ($r = 0.761$), CRP ($r = 0.678$), and biologic activity ($r = 0.774$) (Fig 1a, 1b). A similar but slightly lower correlation was observed between T2-weighted signal intensity of the mesenteric fat (parameter *f*, group A) and the same biologic parameters of inflammation (correlation with ESR, $r = 0.755$; correlation with CRP, $r = 0.563$; correlation with biologic activity, $r = 0.712$) (Figs 1b, 2e, 4b). A correlation was found between gadolinium enhancement (parameter *e*, group B) of the wall and biologic activity ($r = 0.751$), CRP level ($r = 0.681$), and ESR ($r = 0.841$). No statistical correlation was found between parameter *f* in group B (ie, gadolinium enhancement of mesenteric fat) and

biologic activity (Figs 1c, 2f, 4a). Wall thickening (parameter *d*) was also statistically correlated with biologic signs of activity (Figs 1, 2).

T2-related parameters (parameters *e* and *f*, group A) were related to T1- weighted bowel wall gadolinium enhancement (parameter *e*, group B): T2- weighted bowel wall and fat signal intensities showed correlation values of 0.919 and 0.852, respectively, with wall gadolinium enhancement ($P < .001$) (Fig 1). Weak correlations were obtained by correlating the CDAI with the MR imaging parameters (Table 7).

Interobserver agreement

Interobserver agreement was considered statistically significant for all parameters evaluated (Tables 8, 9). In the detection of lesions located between the jejunum and the rectum, a high level of agreement was observed on T1- and T2- weighted images (Table 7), with *k* coefficient values ranging from 0.642 to more than 0.999. The highest agreement was obtained in the evaluation of lesions located in the right side of the body and the descending colon on T2- weighted images ($k = 0.924$ and 0.914 , respectively). In the assessment of activity-related MR parameters, the overall agreement was very good, with *k* values ranging from 0.797 to 0.865 (Table 8). The Spearman rank correlation overall results are reported in Table 6.

Discussion

MR imaging is widely considered to be a sensitive imaging modality in the detection of inflammation in human tissues, and it is expected to be a reliable technique in the depiction of signs of inflammation in patients with Crohn disease. In several studies, researchers have investigated the diagnostic value of T1-weighted gadolinium-enhanced MR imaging in the assessment of inflammatory activity (12) and abnormalities of Crohn disease (11). Concentric bowel wall thickening with increased gadolinium enhancement is widely considered to be a striking finding of Crohn disease and related to the degree of wall inflammation (11–16,18,19,22,31).

On the other hand, the value of T2-weighted sequences in the evaluation of Crohn disease is still controversial, although the T2 weighted signal intensity is expected to be increased at the level of the inflamed bowel wall (10,13,14, 16,21,32). Preliminary studies found an increase in T2-weighted signal intensity at the level of the inflamed wall and perivisceral fat tissue in patients with active Crohn disease (10,19), whereas other studies (11,12) found an overall

lower diagnostic value of T2-weighted sequences in comparison with T1-weighted sequences, either in the evaluation of morphologic changes of Crohn disease or in the assessment of disease activity.

To highlight the T2-weighted signal intensity of the inflamed bowel wall, we chose a negative superparamagnetic oral contrast agent (ie, iron oxide particles) rather than a positive or biphasic one for several reasons: The diagnostic value of T2-weighted MR images significantly improves after administration of a negative contrast agent (20,23). On T2-weighted images, in fact, the signal intensity of the bowel content is markedly inhomogeneous, owing to the brightness of intestinal fluids, the darkness of air, and the intermediate signal intensity of stool. After administration of the negative intestinal contrast agent, a homogeneous low signal intensity, similar to that of intestinal air, is obtained throughout the bowel. Such homogeneous signal intensity cannot be obtained with an intestinal contrast agent producing high signal intensity on T2-weighted images because of the residual low signal intensity of air. Furthermore, if combined with fat suppression, the low signal intensity of the lumen allows the T2-weighted signal intensity of the inflamed wall and minimal amounts of perivisceral fluid or edema of the mesenteric fat to be seen; these are hardly ever seen, otherwise (Fig 1a, 1b). The superparamagnetic intestinal contrast agent also improves the quality of T1-weighted gadolinium-enhanced images by homogeneously decreasing the signal intensity of the lumen, thus highlighting wall enhancement (Fig 1c) (10–16).

Moreover, we chose oral administration of contrast material instead of enteroclysis for specific reasons. First, patient acceptance of oral contrast material is better, and the examination is relatively simple, lasting a total of 30–40 minutes. The placement of a nasojejunal tube requires more time and radiation exposure, and it causes patient discomfort. Second, oral administration allows evaluation of the entire small and large bowel, from the duodenum to the sigmoid colon. With enteroclysis, disease confined to the duodenum or proximal jejunum can be missed. Moreover, distending the small bowel to its maximum can reduce the evidence of large-bowel disease because the colon is compressed by the distended small-bowel loops. Similarly, mesenteric or peritoneal disease (ie, adhesions) can be underestimated with marked bowel dilatation. Finally, assessment of bowel wall and mesenteric signal intensity, which is crucial in the evaluation of transmural inflammatory bowel disease, is better performed with moderate rather than marked lumen dilatation.

A possible disadvantage of oral contrast agent administration is the possibility of suboptimal intestinal filling in case of low patient compliance; however, this was rarely observed in our series. Poor intestinal distention may cause underestimation of low-grade strictures.

To validate this MR imaging technique and to assess the accuracy of T2- weighted MR sequences in patients with Crohn disease, we considered several MR imaging parameters related to the disease. We assessed T1- and T2- weighted images, both separately and together; 413 intestinal segments were evaluated in 59 patients, and we adopted a per-segment rather than a per-patient approach. This can be considered a limitation of our study because we have performed multiple observations in each patient, with potential interdependency. In a disease that affects multiple bowel segments, however, the per-segment analysis allowed us to consider several different parameters.

Some parameters were classified as “morphologic” (ie, lesion site and length and presence of strictures, fistulas, and other complications) and compared with endoscopic and radiologic results. Others were related to disease activity and classified as “activity-related” parameters and compared with clinical/biochemical data.

In the detection and localization of Crohn disease in both the small and the large bowel, accuracy of T2-weighted images was high, ranging from 93% to 95% from the jejunum to the rectum; this was comparable with the accuracy of T1-weighted gadolinium-enhanced MR imaging.

In the assessment of disease length, no significant difference was found between T2- and T1-weighted MR sequences and the reference standard.

In the diagnosis of strictures, T2- weighted MR sequences showed higher sensitivity and accuracy than did T1-weighted MR sequences (sensitivity, 83% vs 66%; accuracy, 91% vs 81%). This can be explained by the poor wall enhancement that is frequently observed in patients with fibrostenosing disease and can produce an unclear bowel profile on coronal T1-weighted contrast material-enhanced images. Conversely, if intestinal contrast material filling is adequate, coronal T2- weighted MR images always offer an excellent anatomic display in patients with either inflammatory or fibrostenosing disease (Fig 2a).

Regarding the diagnosis of enteroenteric fistulas, no differences were found between T1- and T2-weighted sequences (89% vs 91% respectively), although their association moderately increased the overall detection rate from between 66% and 71% to 75%. The diagnosis of fistulas remains one of the major limitations of MR imaging in the assessment of Crohn disease, in part because it is difficult to obtain direct evidence of the fistulous enteroenteric tract; however, several indirect signs, such as marked adhesions of different bowel loops or

marked and sharp angulations and convergence of several loops toward a central point (Figs 3a, 3b), indicate the presence of fistulas. In our experience, approximately 25% of fistulas were missed when compared with findings of barium enema studies. However, complex nonenteroenteric fistulas, such as enterourinary fistulas or fistulas into retroperitoneal structures (ie, in the psoas muscle), were easily diagnosed with MR imaging but underestimated with barium studies. Such complex fistulas, more so than enteroenteric fistulas, represent severe complications of Crohn disease and usually require surgical treatment. Moreover, MR imaging showed high sensitivity in the detection of enteroenteric adhesions, which are widely considered to be precursors of fistula lesions.

Other severe complications that require surgery, such as abscesses or phlegmons, were found in 20% of patients, and all complications were assessed correctly either on T1- or T2-weighted images. These results confirm the clinical value of MR imaging, which could potentially replace CT in the diagnosis of all severe complications of Crohn disease. Thus, in our experience MR imaging was used to correctly assess most of the main morphologic abnormalities of Crohn disease, with the performance of T2-weighted imaging being slightly better.

Regarding MR imaging parameters related to local inflammation, both T1- and T2-weighted imaging parameters were correlated with biologic signs of inflammation or biologic activity ($P < .001$), whereas a lower correlation ($P = .02$) was found with the CDAI. When active intestinal inflammation develops in patients with Crohn disease, large amounts of cytokines and other proinflammatory mediators are produced. This induces an increased serum concentration of acute phase reactants (or biologic activity) that is in correlation to the severity of intestinal lesions (1,5,27). On the other hand, the CDAI has a lower specificity since it is based on subjective symptoms, such as abdominal pain and severity of diarrhea (29,30). Presently, to our knowledge, no absolute clinical criteria are available to define and quantify inflammatory activity of Crohn disease lesions.

A significant correlation between T2-weighted wall hyperintensity, gadolinium-enhanced bowel wall enhancement, and biologic activity has been demonstrated in previous studies (10). Our study results confirm these findings and show an intercorrelation between T2-weighted wall signal intensity and gadolinium enhancement at the level of the affected bowel ($r = 0.919$).

However, despite such a strong correlation between the T2-weighted wall signal intensity and T1-weighted wall enhancement obtained after gadolinium-based contrast material intravenous injection, some intrinsic differences should be noted. The increased gadolinium

enhancement observed at the level of the inflamed wall is, in fact, likely related to wall hypervascularity and/or increased vascular permeability, whereas the T2-weighted wall hyperintensity is determined on the basis of an increased amount of edema and fluid components within the inflamed wall. Hypervascularity and edema represent different features of inflammation, and they frequently, but not necessarily, overlap.

The T2-weighted hyperintensity of the mesenteric fat tissue, which was frequently observed on fat-suppressed images outside the affected bowel wall, is another characteristic finding of active Crohn disease. It is an expression of the typical Crohn disease transmural and extramural inflammatory processes and likely related to mesenteric edema or minimal amounts of perivisceral free fluid, which cannot be detected on gadolinium-enhanced images (Fig 1b, 1c).

Therefore, T2-weighted fat-suppressed images offer additional information on mural and transmural Crohn disease inflammation. These images are either complementary or dissimilar to gadolinium-enhanced images.

An intrinsic limitation of T2-weighted fat-suppressed images is the poor anatomic detail (Figs 1b, 2e), which is due to the diffuse low signal intensity of suppressed images. For this reason, these images should always be acquired in association with and related to T2-weighted unsuppressed images.

Other limitations of this study included the relatively small sample size and, above all, the heterogeneity of tests used as reference standards. Such heterogeneity is, however, necessarily related to the complexity of Crohn disease. Complete examination of patients with Crohn disease requires the association of several different imaging, clinical, and instrumental examinations. The disease, in fact, discontinuously affects the small and large bowel, thus requiring both endoscopic and radiologic examinations to diagnose lesion site and extent. At the same time, it produces transmural inflammation and complications that are undetectable at endoscopy or conventional radiography but can be detected easily with cross-sectional imaging. Moreover, to our knowledge, a reference examination to assess disease activity does not exist, although laboratory and clinical tests are widely used for this purpose.

Results of our study differ from those of previous studies (11,12), where T2-weighted sequences showed a lower accuracy than gadolinium-enhanced sequences, both in the depiction of pathologic segments (sensitivity, 51% vs 85%) and in the evaluation of disease severity (sensitivity, 43% vs 93%). A possible bias of these previous studies (11,12) showing a superiority of gadolinium-enhanced images versus T2-weighted images may be attributed

to the use of biphasic oral contrast agents (ie, water or diluted barium), which produce a negative effect on T1-weighted sequences and a positive effect on T2-weighted sequences, thus optimizing only T1-weighted gadolinium-enhanced sequences.

In conclusion, T2-weighted MR images, in association with a negative oral contrast agent, can be used to accurately evaluate Crohn disease lesions; furthermore, these images provide information on Crohn disease abnormalities and disease activity that is similar to that provided by T1-weighted gadolinium-enhanced images. T2-weighted sequences, which are able to replace T1-weighted gadolinium-enhanced sequences for all parameters considered, could also be used alone in the evaluation of Crohn disease (eg, in follow-up studies, with reduction of costs and invasiveness of the MR examination). The association of T2- and T1-weighted gadolinium-enhanced sequences provides the highest diagnostic accuracy, thus making MR imaging a powerful diagnostic tool in the complete examination of patients with Crohn disease.

Acknowledgments: We thank Raffale Masciangelo (statistical revision), University of Rome La Sapienza, Rome, Italy; Giancarlo Prossamariti (MR imaging technician), Department of Radiological Sciences, University of Rome La Sapienza, and Maria Teresa Barbieri (revision of the manuscript).

References

1. Sandborn WJ, Feagan BG, Hanauer SB, et al. A review of activity indices and efficacy endpoints for clinical trials of medical therapy in adults with Crohn's disease. *Gastroenterology* 2002;122:512–530.
2. Brignola C, Lanfranchi GA, Campieri M, et al. Importance of laboratory parameters in the evaluation of Crohn's disease activity. *J Clin Gastroenterol* 1986;8:245–248.
3. Singleton JW. Clinical activity assessment in inflammatory bowel disease. *Dig Dis Sci* 1987;32(12 suppl):42S–45S.
4. Cellier C, Sahnoud T, Froguel E, et al; for the Groupe d'Etudes Therapeutiques des Affections
5. Inflammatoires Digestives. Correlations between clinical activity, endoscopic severity, and biological parameters in colonic or ileocolonic Crohn's disease: a prospective multicentric study of 121 cases.
6. *Gut* 1994;35:231–235.
7. Wills JS, Lobis IF, Denstman FJ. Crohn disease: state of the art. *Radiology* 1997;202:597–610.

8. Shoenut JP, Semelka RC, Magro CM, et al. Comparison of magnetic resonance imaging and endoscopy in distinguishing the type and severity of inflammatory bowel disease. *J Clin Gastroenterol* 1994;19:31–35.
9. Kettritz U, Isaaks K, Warshauer DM, et al. Crohn disease: pilot study comparing MRI of the abdomen with clinical evaluation. *J Clin Gastroenterol* 1995;21:249–253.
10. Rollandi GA, Martinoli C, Conzi R, et al. Magnetic resonance imaging of the small intestine and colon in Crohn's disease. *Radiol Med (Torino)* 1996;91:81–85.
11. Rieber A, Wruk D, Nussle K, et al. MRI of the abdomen combined with enteroclysis in Crohn disease using oral and intravenous Gd-DTPA. *Radiologe* 1998;38:23–28.
12. Maccioni F, Viscido A, Broglia L, et al. Evaluation of Crohn's disease activity with MRI. *Abdom Imaging* 2000;25:219–228.
13. Low RN, Sebrechts CP, Politoske DA, et al. Crohn disease with endoscopic correlation: single shot fast spin-echo and gadoliniumenhanced fat-suppressed spoiled gradientecho MR imaging. *Radiology* 2002;222:652–660.
14. Koh DM, Miao Y, Chinn RJ, et al. MR imaging evaluation of the activity of Crohn's disease. *AJR Am J Roentgenol* 2001;177:1325–1332.
15. Schunk K. Small bowel magnetic resonance imaging for inflammatory bowel disease. *Top Magn Reson Imaging* 2002;13:409–425.
16. Laghi A, Borrelli O, Paolantonio P, et al. Contrast enhanced magnetic resonance imaging of the terminal ileum in children with Crohn's disease. *Gut* 2003;52:393–397.
17. Maglante DD, Gourtsoyiannis N, Rex D, et al. Classification of small bowel Crohn's subtypes based on multimodality imaging. *Radiol Clin North Am* 2003;41:285–303.
18. Ernst O, Asselah T, Cablan X, et al. Breathhold fast spin-echo MR imaging of Crohn's disease. *AJR Am J Roentgenol* 1998;170:127–128.
19. Madsen SM, Thomsen HS, Schlichting P, et al. Evaluation of treatment response in active Crohn's disease by low-field magnetic resonance imaging. *Abdom Imaging* 1999;24:232–239.
20. Prassopoulos P, Papanikolaou N, Grammatikakis J, et al. MR enteroclysis imaging of Crohn disease. *RadioGraphics* 2001;21:S161–S172.
21. Maccioni F, Viscido A, Marini M, Caprilli R. MRI evaluation of Crohn's disease of the small and large bowel with the use of negative superparamagnetic oral contrast agents. *Abdom Imaging* 2002;27:384–393.
22. Giovagnoni A, Fabbri A, Maccioni F. Oral contrast agents in MRI of the gastrointestinal tract. *Abdom Imaging* 2002;27:367–375.
23. Madsen SM, Thomsen HS, Munkholm P, et al. Inflammatory bowel disease evaluated by low-field magnetic resonance imaging: comparison with endoscopy, ^{99m}Tc-HMPAO leucocyte scintigraphy, conventional radiography and surgery. *Scand J Gastroenterol* 2002;37:307–316.

24. Gourtsoyiannis N, Papanikolaou N, Grammatikakis J, Prassopoulos P. MR enteroclysis: technical considerations and clinical applications. *Eur Radiol* 2002;12:2651–2658.
25. Hahn PF, Stark DD, Lewis JM, et al. First clinical trial of a new superparamagnetic iron oxide for use as an oral gastrointestinal contrast agent in MR imaging. *Radiology* 1990;175:695–700.
26. Holzknrecht N, Helmberger T, von Ritter C, et al. MRI of the small intestine with rapid MRI sequences in Crohn disease after enteroclysis with oral iron particles. *Radiologe* 1998;38:29–36.
27. Born C, Nagel B, Leinsinger G, Reiser M. MRI with oral filling in patients with chronic inflammatory bowel diseases. *Radiologe* 2003;43:34–42.
28. Holzknrecht N, Helmberger T, Herrmann K, et al. MRI in Crohn's disease after transduodenal contrast administration using negative oral MRI contrast media. *Radiologe* 2003;43:43–50.
29. Gauldie J, Richards C. Systemic symptoms/acute phase response. In: Targen SP, Shanahan F, eds. *Inflammatory bowel disease: from bench to bedside*. Baltimore, Md: Williams & Wilkins, 1994; 230–238.
30. Quinn PG, Binion DG, Connors PJ. The role of endoscopy in inflammatory bowel disease. *Med Clin North Am* 1994;78:1331–1352.
31. Best WR, Beckett JM, Singleton JW, et al. Development of a Crohn's disease activity index: national cooperative Crohn's disease study. *Gastroenterology* 1976;70:439–444.
32. Best WR, Beckett JM, Singleton JW. Rederived values of the eight coefficients of the Crohn's disease activity index (CDAI). *Gastroenterology* 1979;77:843–846.
33. Meyers MA, McGuire PV. Spiral CT demonstration of hypervascularity in Crohn disease: "vascular jejunitization of the ileum" or the "comb sign". *Abdom Imaging* 1995;20:327–332.
34. Lee JK, Marcos HB, Semelka RC. MR imaging of the small bowel using the RARE sequence. *AJR Am J Roentgenol* 1998;170:1457–1463.

Table 1

Results: mean length of CD lesions in the small and large bowel

Site of CD lesions	RE	MRI	T1-w sequences	T2-w sequences
J - Mean length (cm)	18.2 cm	15.7 cm	15.3 cm	16.2 cm
I - Mean length (cm)	25 cm	27.2 cm	26.6 cm	27.1 cm
AC - Mean length (cm)	17 cm	15.6 cm	15.1 cm	16 cm
TC - Mean length (cm)	27.8 cm	25.8 cm	25.7 cm	25.8 cm
DC - Mean length (cm)	18.2 cm	15.6 cm	15 cm	16.1 cm
SC - Mean length (cm)	17 cm	15.7 cm	16 cm	15.9 cm
R - Mean length (cm)	7 cm	5 cm	5 cm	5 cm

The mean values of CD lesions length at the level of each diseased bowel segment -from jejunum to rectum- are reported, as observed at reference examinations (RE) (association of colon-ileoscopy and small bowel barium studies) MRI (T1-+ T2-w sequences) and T1- and T2-w sequences, separately.

J (Jejunum), I (Ileum), AC (Ascending Colon), TC (Transverse Colon), DC (Descending Colon), SC (Sigmoid Colon), R (rectum).

Table 2

Overall mean CD length

	RE	MRI	T1-w sequences	T2-w sequences
Mean disease length	36.3 cm	35.5 cm	35.05 cm	35.6 cm
Median	36 cm	35 cm		
Standard Deviation	19.2	21.2		
Range	5-130 cm	5-120 cm	5-100 cm	5-130 cm
Affected segments Per-patient (mean)	1.48	1.56	1.57	1.57

The mean and median values of the total CD extent in the small and large bowel are reported, either for reference examinations (RE) (association of colon-ileoscopy and small bowel barium studies), MRI (T1-+ T2-w sequences) and T1- and T2-w sequences, separately.

J (Jejunum), I (Ileum), AC (Ascending Colon), TC (Transverse Colon), DC (Descending Colon), SC (Sigmoid Colon), R (rectum).

Table 3

Results: MRI detection of CD complications

Complications	RE	MRI	T1-weighted	T2-weighted
Pts with strictures	22 pts	20 pts	16 pts	20 pts
Total # of strictures	47	39 (83%)	31 (66%)	39 (83%)
Degree: severe	29	26 (89%)	20 (69%)	26 (89%)
Mild	18	13 (72%)	11 (61%)	13 (72%)
Pts with adhesions	-----	20 pts	17 pts	20 pts
Total adhesions #	-----	48	38	48
Pts with EEF	9 pts	7 pts	7 pts	7 pts
EEF #	24	18 (75%)	16 (66%)	17 (71%)
Pts with NEEF (*)	-----	3 pts	2 pts	3 pts
NEEF#		6	4	6
Abscesses	4 (surg)	4	4	4
Phlegmons	4 (surg)	4	4	3

MRI vs reference examinations in detection of strictures, adhesions, fistulas, abscesses, and phlegmons

Note: Reference examinations (RE) included CT, US and surgical confirmation for abscesses and phlegmons surgically treated, CT for phlegmons treated conservatively, barium studies for fistulas, barium studies and colonoscopy for strictures and adhesions

EEF : entero-enteric fistulas.

NEEF: non entero-enteric fistulas

(*) **NEEF** included: two entero-ovarian fistulas in one patient, three fistulas in the psoas muscle in one case, and one entero-vesical fistula in one patient, all undetected at barium studies.

Table 4

Diagnostic accuracy of T1- and T2-weighted sequences in detecting CD lesions at the level of each one of the different segments of the small and large bowel

	Jejunum		Ileum		Ascending colon	
	T1-w	T2-w	T1-w	T2-w	T1-w	T2-w
Total # of pts	59	59	59	59	59	59
True positive	6	6	47	49	8	8
False positive	3	3	2	2	1	0
True negative	47	50	7	7	46	47
False negative	3	0	3	1	4	4
Accuracy	90%	95%	92%	95%	92%	93%
Sensitivity	67%	100%	94%	98%	67%	67%
Specificity	94%	94%	78%	78%	98%	100%
PPV	67%	67%	96%	96%	89%	100%
NPV	94%	100%	70%	88%	92%	92%

	Transverse colon		Descending colon		Sigmoid colon	
	T1-w	T2-w	T1-w	T2-w	T1-w	T2-w
Total # of pts	59	59	59	59	59	59
True positive	7	7	6	6	10	10
False positive	1	2	1	1	3	1
True negative	50	49	49	49	44	46
False negative	1	1	3	3	2	2
Accuracy	97%	95%	93%	93%	92%	95%
Sensitivity	88%	88%	67%	67%	83%	83%
Specificity	98%	96%	98%	98%	94%	98%
PPV	88%	78%	86%	86%	77%	91%
NPV	98%	98%	94%	94%	92%	96%

Table 5

Overall diagnostic accuracy of T1- and T2-weighted sequences in detecting CD lesions

	T1-w	T2-w
Total segments	413	413
True positive	85	87
False positive	11	6
True negative	299	304
False negative	18	16
Accuracy	93%	95%
Sensitivity	83%	84%
Specificity	96%	98%
PPV	89%	94%
NPV	94%	95%

Table 6Agreement between T1- and T2-weighted sequences in detecting CD lesions (*k*-statistic)

T1/T2 agreement	Kappa value*	Asymp. Std. Error
Jejunum	0.772	0.123
Ileum	0.869	0.090
Ascending colon	0.931	0.68
Transverse colon	0.931	0.68
Descending colon	1.000	0.000
Sigmoid colon	0.896	0.72
Rectum	1.000	0.00

*all comparison: $p < 0.001$ **Table 7**

Results: correlation between activity-related MR parameters and BA

	CDAI	BA	ESR	Wall thickness (parameter 4)	Wall Gd-enhanc. (parameter 5B)	Wall T2-signal (parameter 5A)	Fat T2-signal (parameter 6A)
CDAI		r .299 p .035	r .299 p .109	r .470 p .009	r .371 p .043	r .403 p .027	r .299 p .109
BA	r .299 p .035		r .737 p <0.001	r .724 p <0.001	r .751 p <0.001	r .774 p <0.001	r .712 p <0.001
ESR	r .299 p .109	r .737 p <0.001		r .671 p <0.001	r .841 p <0.001	r .761 p <0.001	r .755 p <0.001
Wall thickness	r .470 p .043	r .724 p <0.001	r .671 p <0.001		r .816 p <0.001	r .878 p <0.001	r .807 p <0.001
Wall Gd-enhanc.	r .371 p .043	r .751 p <0.001	r .841 p <0.001	r .816 p <0.001		r .919 p <0.001	r .852 p <0.001
Wall T2-signal	r .403 p .027	r .774 p <0.001	r .761 p <0.001	r .878 p <0.001	r .919 p <0.001		r .875 p <0.001
Fat T2-signal	r .299 p .109	r .712 p <0.001	r .755 p <0.001	R .807 p <0.001	r .852 p <0.001	r .875 p <0.001	

A significant Spearman rank correlation was obtained between BA (Biological Activity), ESR (Erythrocytes Sedimentation Rate) and MRI parameters, respectively wall thickening (parameter 4), wall-enhancement (parameter 5B), T2 wall (parameter 5A) and fat signals (parameter 6A). Weak correlation was found between MRI parameters and CDAI (Crohn disease activity index). Results available for 30/59 patients.

Table 8

Inter-observer agreement for lesions' detection in the different bowel segments on T1- and T2-weighted images

	T1-weighted	T2-weighted
Jejunum	k .772	k .642
Ileum	k .731	k .714
Ascending Colon	k .711	k .924
Descending Colon	k .914	k .914
Sigmoid	k .783	k .896
Rectum	k 1	k 1

Table 9. Inter-observer agreement for MRI assessment of the disease activity

MRI parameters	k-values
Wall thickening	.797
Wall Gd-enhancement	.857
T2 wall signal	.817
T2 fat signal	.865

Figure 1

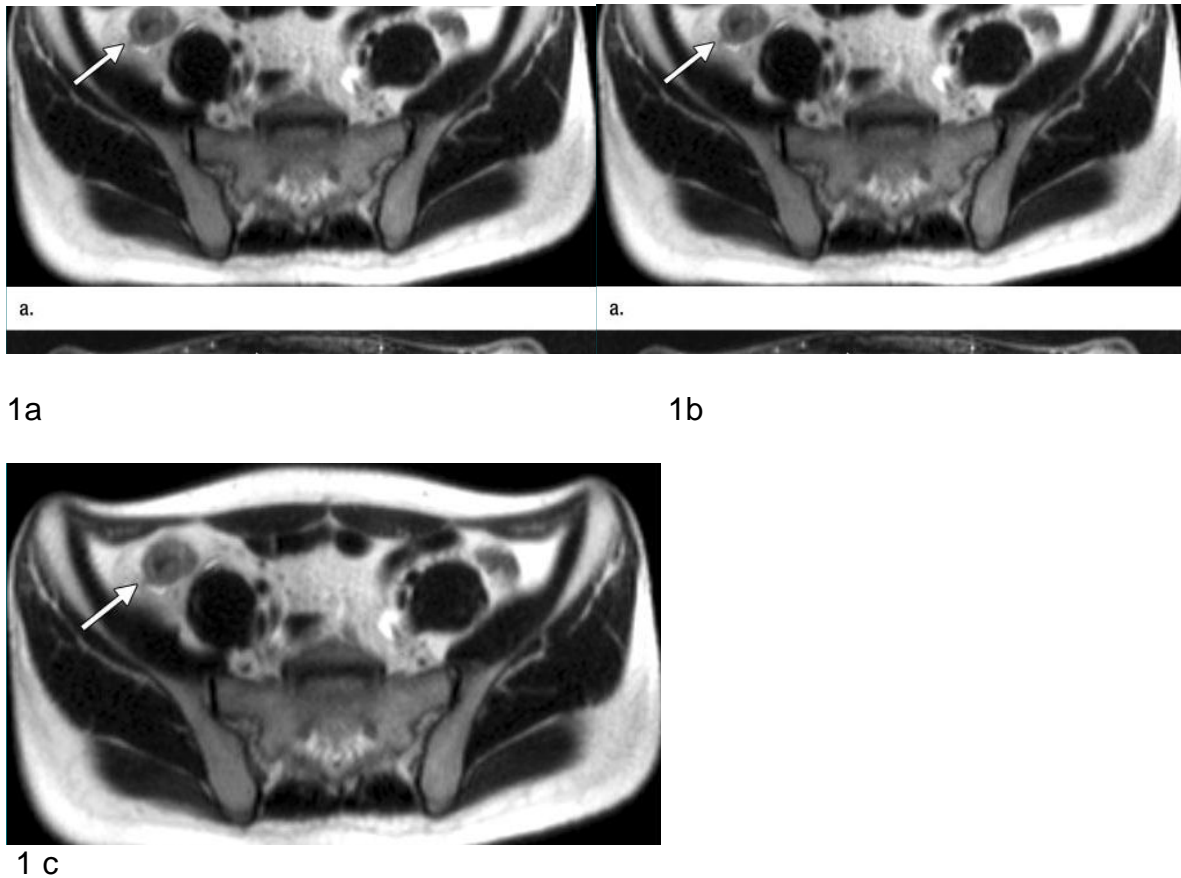


Figure 1: MR images in a 28-year-old man with known Crohn disease and high biologic activity (positive ESR, CRP level, and WBC count) and positive clinical indexes of activity (CDAI \square 150). (a, b) T2-weighted RARE transverse images obtained (a) without and (b) with fat suppression after oral administration of a negative contrast agent show marked diffuse wall thickening (arrow) at level of the terminal ileum, with minimal perivisceral free fluid; this can be seen better on b (arrowhead). After suppression, T2-weighted signal intensity of the wall is extremely high, suggesting diffuse wall edema and active disease. Adjacent bowel loops do not show wall or luminal abnormalities; they are clearly depicted because of low signal intensity of intestinal contrast agent. (c) Gadolinium-enhanced FLASH T1-weighted transverse MR image obtained with fat suppression show marked diffuse wall thickening and marked wall enhancement at level of the distal ileum (arrow) and dilatation of local mesenteric vessels (ie, "comb sign") (arrowheads) (31). These findings are concordant with those observed on T2-weighted images and are suggestive of active Crohn disease.

Figure 2

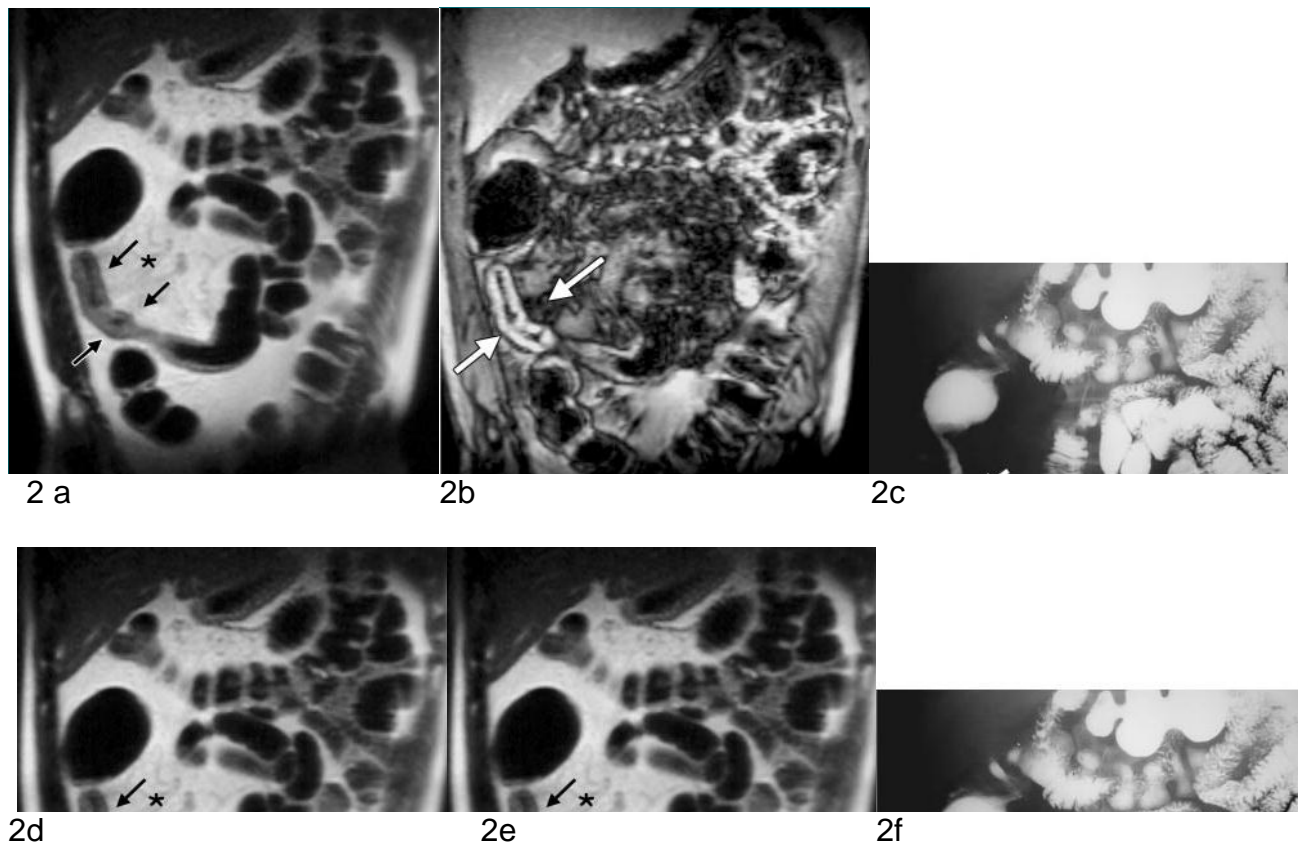
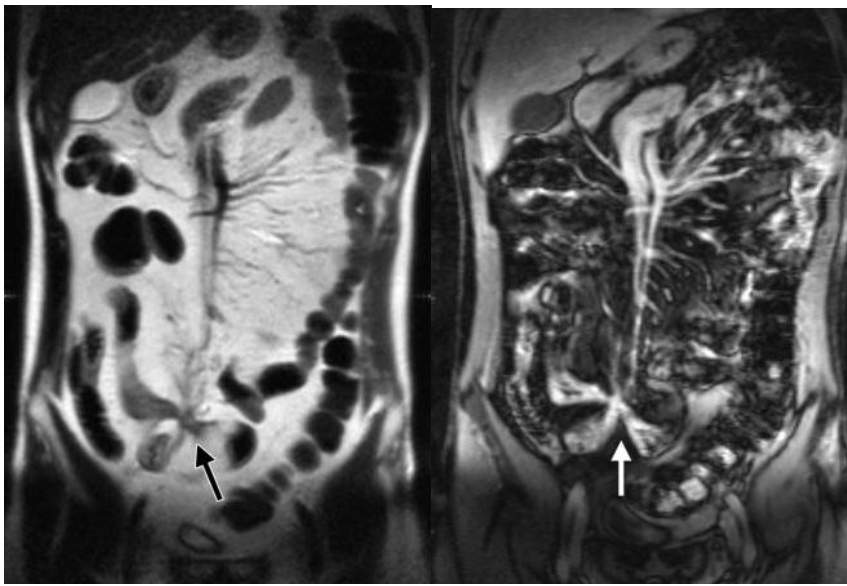


Figure 2: MR Images show recurrence of Crohn disease in a 52-years old man who underwent resection of the terminal ileum and descending colon 12 years earlier; this patient had a low level of biologic disease activity (negative ESR, CRP level, and WBC count) but positive clinical indexes of activity (ie, CDAI \square 150). (a) Coronal T2-weighted RARE image obtained after oral administration of a negative contrast agent. Recurrent Crohn disease at the level of the anastomotic ileal loop is clearly evident (arrows); the affected bowel loop shows thickened walls, reduced and irregular lumen over approximately 20 cm, and mild bowel dilatation above the stricture. Marked mesenteric fibrofatty proliferation (\square) is also evident, separating the affected bowel segment from the adjacent normal ileal and jejunal loops. (b) Coronal FLASH T1-weighted MR image obtained after intravenous injection of gadolinium-based contrast material. Diffuse wall thickening, increased wall enhancement, and lumen stenosis were observed at the level of the ileal anastomotic loop, suggesting recurrent Crohn disease (arrows). Bowel dilatation above the stricture is, however, less evident on this image than on the corresponding T2-weighted image. (c) Image obtained at follow-through barium examination shows a long inflammatory stricture (arrows) at the level of the anastomotic ileal loop. Marked fibrofatty proliferation is possible owing to separation of the affected bowel segment from the normal ileal and jejunal loops. (d) Transverse T2-weighted RARE image shows wall thickening at the level of the anastomotic loop (arrow) and inhomogeneity and increased volume of the peri-visceral fat tissue, which separates the affected loop from the other ileal loops. (e) Transverse fat-suppressed T2-weighted fast spin-echo image obtained at the same level. The T2-weighted signal intensity of the wall (arrow) is moderate; no signal intensity is evident at the level of the fibrofatty proliferation; this finding suggests the presence of chronic moderately active disease. (f) Transverse fat-suppressed T1-weighted FLASH image obtained at the same level. Layered wall enhancement (arrow) is evident, as is dilatation of the mesenteric vessels. These findings are suggestive of chronic moderately active disease.

Figure 3

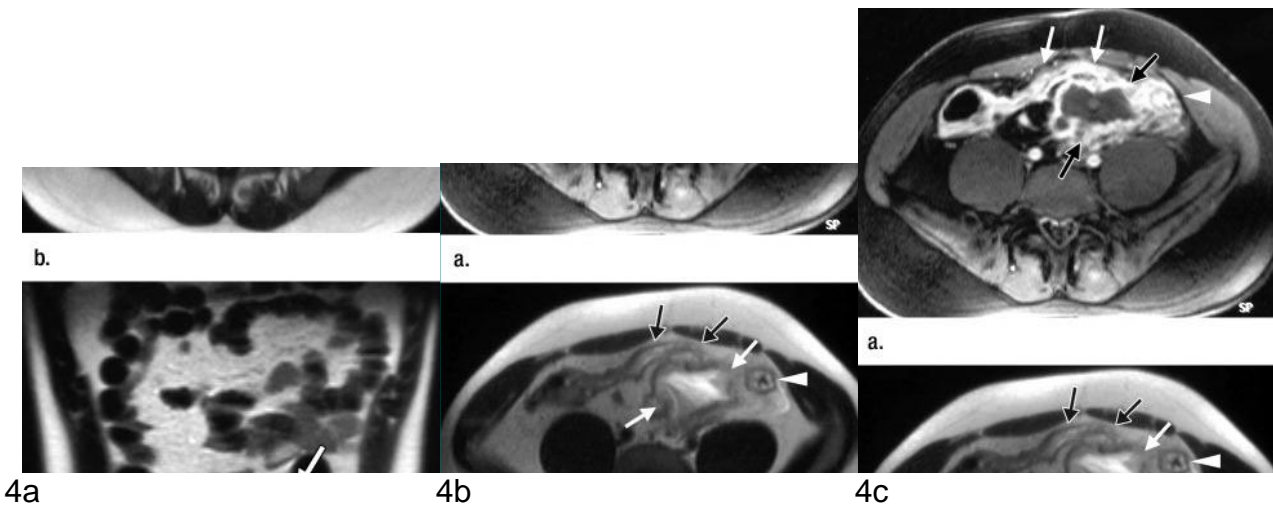


3a

3b

Figure 3: MR images obtained in a 41-year-old man with a 20-year history of Crohn disease. (a) T2- weighted RARE coronal image obtained after oral administration of a negative contrast agent. In the pelvis, slightly to the right of the midline, an ileal loop is angulated, and it converges (arrow) with other ileal loops; this suggests the presence of enteroenteric fistulas. (b) T1-weighted FLASH coronal image, obtained after intravenous injection of gadolinium-based contrast material. In the pelvis, slightly to the right of the midline, an ileal loop sharply converges (arrow) with other ileal loops; this finding is suggestive of enteroenteric fistulas. All the involved bowel loops show increased bowel wall enhancement

Figure 4



4a

4b

4c

Figure 4: MR images obtained in a 21-year-old man with known Crohn disease of the distal ileum that was treated with corticosteroids. Patient history included recent mild worsening of symptoms and lower abdominal pain in association with increased ESR, CRP level, and WBC count without fever. Patient underwent MR imaging and, 24 hours later, surgery. At surgery, a large abscess arising from the distal ileum that required ileocecal resection was found; no resection of the descending colon was needed. (a) Transverse fat-suppressed T1-weighted FLASH image obtained after injection of gadolinium chelates. A large fluid collection surrounded by contrast-enhanced inflammatory tissue (black arrows) anteriorly displaces the distal ileum (white arrows) adjacent to the descending colon. Both the wall of the distal ileum (white arrows) and the descending colon (white arrowhead) are characterized by marked gadolinium enhancement. (b) T2-weighted RARE transverse image. Note the descending colon (white arrowhead), the distal ileal loop (black arrows), and the large fluid collection (white arrows), which is characterized by high signal intensity and likely arises from the posterior mesenteric border of the ileal loop. (c) T2-weighted RARE coronal image. Note the large fluid collection (white arrows) between the distal ileal loop (black arrows) and the descending colon (white arrowhead). The high-signal-intensity fluid collection can be easily distinguished from the adjacent normal bowel loops, all of which have a low-signal-intensity lumen after the administration of a negative oral contrast agent.



Picture by Francesca Maccioni 2012
Sunset from the dining room window (E)

Chapter 4

Double-contrast magnetic resonance imaging of the small and large bowel: effectiveness in the evaluation of inflammatory bowel disease

Francesca Maccioni

Abdom Imaging. 2010;35(1):31-40.

Department of Radiological Sciences, University of Rome "Sapienza", Policlinico Umberto I, Viale Regina Elena 324, 00161 Rome, Italy

Abstract

Double-contrast magnetic resonance imaging (DC-MRI) is a technique for imaging the intestine, which has shown to be very effective in assessing inflammatory bowel disease (IBD), and particularly Crohn's disease (CD). The expression derives from the association of two different contrast agents, a superparamagnetic intestinal and a paramagnetic intravenous contrast agent. This specific contrast media combination provides optimization of the tissue contrast, both on T1- and T2-weighted images, thus allowing an effective display of small and large bowel loops in normal and pathologic conditions.

Therefore, main CD complications (strictures, fistulas, and abscesses), as well as disease activity, may be valuably assessed. The term DC-MRI may also be referred to the typical "double contrast" effect that is produced by this technique at the level of the inflamed bowel wall, both on T1- and T2-weighted images, directly related to the degree of wall inflammation (disease activity).

Key words: Double-contrast MRI—MRI in Crohn's disease—Crohn's disease activity—MRI in IBD—MRI of the bowel—Superparamagnetic negative intestinal contrast agent

Introduction

The expression “double-contrast magnetic resonance imaging” (DC-MRI) describes an MRI technique focused on the evaluation of the intestine, particularly effective for inflammatory bowel disease (IBD) [1].

The first meaning of “double-contrast” is due to the simultaneous use of two different contrast agents: a negative superparamagnetic oral contrast agent and a positive intravenous (i.v.) paramagnetic contrast medium. However, this technique also generates a sort of “black-and-white” or “double-contrast effect,” by producing a maximum wall-to-lumen contrast at the level of the inflamed bowel wall, on both T1- and T2-weighted images. In particular, this method highlights the intrinsic bowel wall contrast on T2-weighted imaging, thus allowing a direct depiction of the wall edema, which cannot otherwise be obtained. At the same time, the wall enhancement produced by i.v. injection of a gadolinium (Gd)-chelate contrast is evident to a maximal degree, thanks to the black lumen effect.

Another possible term to define this method could be “negative MR-enterography”, due to the black lumen effect produced on both T1- and T2-weighted images by the superparamagnetic oral contrast agent.

To explain how this technique works, the different possibilities currently offered by MRI in the evaluation of the bowel, and particularly of the intestinal wall, should be analyzed first.

Intestinal contrast agents for the evaluation of the bowel

In the last few years, several contrast agents and different MRI sequences have been introduced to evaluate the bowel, thus widening the range of MRI techniques [1–12]. Nowadays, MRI may produce several different T1- or T2-weighted fast sequences [among them: halfacquisition turbo spin-echo (HASTE) or turbo spin-echo (TSE), volume interpolated breath-hold examination (VIBE), fast low-angle shot (FLASH), spoiled gradient recalled echo (SPGR), etc.], as well as balanced T1-/T2- weighted ones [fast imaging employing steady state acquisition (FIESTA) or fast imaging with steady-state precession (True-FISP) or balanced fast field-echo (FFE)]. Moreover, each sequence may be further modulated by adding a selective suppression of the fat tissue signal. Furthermore, the intestinal lumen contrast, markedly inhomogeneous, may be rendered homogeneously dark or bright on T1- or on T2-weighted sequences, or on both, by administering the proper intestinal contrast agent, selected among positive, negative, or biphasic media. Finally, to assess the small bowel, the

contrast may be orally administered (MR-enterography) or introduced by a naso-jejunal tube (MR-enteroclysis).

Many different MRI procedures are therefore currently available for the evaluation of the bowel, based on the association of one or more sequences with a given intestinal contrast agent, in any way whatsoever administered, thus generating a large amount of heterogeneous scientific data.

By reviewing the scientific literature available and by analyzing the effects produced by the different combinations of imaging sequences and the use of different intestinal contrast agents, it however appears evident that biphasic and negative superparamagnetic oral contrast agents are the two intestinal media more widely used [1–9, 12–14]. Both contrast agents, in fact, improve MRI assessment of IBD in the large and small bowel, either with oral administration or by enteroclysis or enema.

Biphasic contrast agents, like simple water or nonabsorbable iso-osmolar solutions [polyethylene glycol (PEG) or mannitol solutions], to be administered either orally or by enteroclysis [5, 6, 8, 14], produce a bright lumen effect on T2-weighted sequences and a dark (gray) lumen effect on T1-weighted sequences.

On T1-weighted images, the dark lumen effect allows the detection of an increased Gd-enhancement of the wall at the level of the intestine and, therefore, an easier identification of wall inflammation in IBDs. On T2-weighted images, the bright lumen may induce artefacts due to the low signal of intestinal gas and the high signal of the inflamed wall and/or the mesenteric fat. To reduce these artefacts, a bright lumen effect is usually obtained by using a True-FISP (or FIESTA or balanced-FFE) sequence, a balanced T1/T2-weighted sequence, rather than a real T2-weighted sequence. However, the intrinsic T2-weighted signal of the intestinal wall and the mesenteric tissue this way cannot be analysed.

Negative intestinal contrast agents, on the other hand, produce a dark (negative) lumen effect with both T1- and T2-weighted sequences [1, 4, 7, 9, 10, 12]. These are superparamagnetic nonabsorbable solutions of iron oxide particles, silicon-coated (Ferumoxsil, commercial name: Lumirem, Laboratoires Guerbet, Paris, France), usually administered orally at the dose of approximately 900–1000 cc.

On T1-weighted images, superparamagnetic intestinal contrast agents produce a “black lumen” effect (darker than the one obtained with biphasic contrasts) which permits the detection of the peculiar increase of Gd-enhancement of the bowel wall in IBDs, similarly to biphasic contrast agents.

On T2-weighted images, differently from biphasic agents, the negative contrast produces a black lumen effect, thus making the intestinal contrast very dark and homogeneous (Fig. 1A–H). The residual intestinal gas that causes artefacts with biphasic contrast agents, in fact, virtually “disappears” from the bowel, since the gas and the superparamagnetic contrast share the same dark effect. For this reason, on T2-weighted images, normal and abnormal small and large bowel loops can be better identified and evaluated by using a negative rather than a biphasic water-like intestinal contrast agent. An advantage of the negative lumen effect on T2-weighted images is, therefore, a valuable morphologic display of the entire bowel, particularly the small intestine.

Similarly, the bright inflamed wall, a typical finding of Crohn's disease (CD), can be better assessed on T2-weighted images by using a negative rather than a positive lumen effect, at the level of both the small and the large bowel, because of the higher wall-to-lumen contrast. Pathologic bowel segments in IBDs can therefore be reliably identified.

Probably, to display small and large bowels, many radiologists might still instinctively prefer the bright lumen produced by a biphasic water-like contrast on T2-weighted images, which resembles the bright effect of barium studies, rather than the negative lumen effect. By inverting the image contrast, a bright lumen effect can however be easily obtained with negative contrast agents as well, thus producing a follow-through-like effect. In this way, the homogeneity of the negative intestinal contrast can be fully appreciated (Figs. 1I–J, 3B–C).

Furthermore, T2-weighted axial fat-suppressed images offer additional and important information on the inflammatory activity of IBDs. In case of an active wall inflammation, in fact, a double-contrast effect, related to the wall edema, is obtained on T2-weighted images as well, similarly to Gd-enhanced sequences. Following fatsuppression, the high T2-weighted signal (brightness) of the inflamed wall, as well the brightness of the perivisceral signal related to the mesenteric inflammation, can be clearly detected (see Figs. 1D–F, 2A–B) [1, 5, 10, 12].

On the other hand, the signs related to the edema of the intestinal wall and the mesenteric fat are hardly detected on T2-weighted images using biphasic contrast agents.

By analyzing the effects produced by a negative contrast agent on T2-weighted imaging, it is clearly evident that a larger amount of information can be obtained, there including a well defined morphological evaluation of the small and large bowel and a detailed analysis of the mesenteric and the bowel wall inflammation in IBDs.

In conclusion, the main advantage of using a negative superparamagnetic contrast agent instead of a biphasic one for the bowel evaluation, particularly in IBDs, consists in the

optimization of T2-weighted imaging. On T1- weighted Gd-enhanced images, both biphasic and negative oral contrast agents show a similar diagnostic efficacy. DC-MRI, therefore, is currently the most accurate and simple technique able to optimize both T1- and T2- weighted imaging in the evaluation of the bowel.

DC-MRI in CD: results obtained on T1- and T2 weighted images. “Double-contrast” effect and correlation with disease activity

Crohn's disease is a chronic IBD of the small and large bowel. The small bowel is discontinuously affected in over 80% of patients, alone or in association with the large bowel, which is involved in approximately 50% of cases.

The disease's hallmark is the transmural inflammation of the bowel wall affecting all the wall layers and extending outside, thus involving the serosa, the mesenteric fat and then the adjacent structures, such as contiguous bowel loops, genito-urinary structures, etc.

In the imaging evaluation of CD, therefore, the analysis of a mural and a transmural extent of the mesenteric inflammation is a major issue. The possibility of combining the simultaneous evaluation of both the small and the large bowel in a single step plays then a pivotal role.

DC-MRI (or negative MR-enterography) is able to provide a complete evaluation of overt CD lesions of the small or the large bowel (as well as intestinal complications) by depicting the signs of the mural/transmural intestinal inflammation on both Gd-enhanced T1- and T2-weighted images [1].

On T1-weighted Gd-enhanced images, if fat suppression is added, the black lumen effect provides a clear identification of the inflamed intestinal segments on both axial and coronal planes. Whenever a wall inflammation is present, the enhancing wall (bright), the inner black lumen and the outside dark fat produce, in fact, a real “double-contrast effect” (Fig. 3). The increased wall enhancement is determined by the increased wall vascularization and permeability recorded in active CD lesions. The correlation between these findings and the disease activity has been proven by several authors [1–3, 5, 6, 13–19]. The well known signs produced by active CD lesions at the level of the small or large intestine can

be easily detected by Gd-enhanced images, including concentric wall thickening (usually ranging between 4 and 10 mm), increased wall enhancement, increased local mesenteric vascularization or “comb sign” (Figs. 1–3), local lymph nodes enhancement, and fistulas or abscesses enhancement. Furthermore, a detailed study of the pattern of mural Gd-enhancement can be carried out, by distinguishing a homogenous pattern from a layered or a

markedly layered pattern, although a definitive correlation between enhancing patterns and the type of wall inflammation has not been established as yet. Other authors [15, 17] have proposed to assess the CD activity by analyzing wash-in and wash-out curves at the level of the enhancing bowel wall following Gd injection.

Coronal T1-weighted Gd-enhanced fat-suppressed images offer a panoramic assessment of the small and the large bowel, thus allowing the localization of the lesions from the jejunum to the rectum, as well as the evaluation of the degree of stenosis (Figs. 1–3).

According to published data [1], sensitivity, specificity and accuracy of DC-MRI T1-weighted Gd-enhanced sequences in detecting strictures was reported to be 66, 100 and 81% respectively, and for enteric fistulas 67, 100 and 89% respectively. T1-weighted Gd-enhanced sequences showed a sensitivity of 67% for jejunal lesions, 92% for ileal lesions, and sensitivity values ranging from 67% to 97% for colonic lesions [1].

The main findings of CD can be accurately identified on T2-weighted images as well. The use of a negative intestinal contrast agent permits an effective differentiation between normal and abnormal small and large bowel loops on T2-weighted images, as well as a detailed analysis of mural and transmural inflammation, thus offering complementary information as compared with T1-weighted Gd-enhanced imaging. The darkening of the bowel lumen is of help in identifying bowel loops from fluid collections or abscesses, otherwise missed or misdiagnosed. In general, the dark lumen effect, by providing a higher contrast between the wall, the lumen and the outside fat tissue, allows a better identification of the thickened pathologic intestinal wall. For this reason, diseased segments, strictures and dilations, perivisceral fibrofatty proliferation, and other findings usually associated with CD transmural inflammation (like entero-enteric adhesions and fistulas or abscesses) can be more reliably assessed. Recently published data [1], reported for DC-MRI T2-weighted sequences a sensitivity, specificity, and accuracy of 83%, 100%, and 91%, respectively, in detecting strictures, and 71%, 100%, and 91% in detecting enteric fistulas, similarly to T1-weighted Gd-enhanced sequences. Furthermore, T2-weighted sequences showed a sensitivity of 100% for jejunal lesions, 95% for ileal lesions, and sensitivity values ranging from 67% to 93% for colonic lesions [1]. Local inflamed lymph nodes and mesenteric hypervascularities may be occasionally underestimated on plain T2-weighted images.

As an additional specific advantage, the negative lumen effect allows a detailed evaluation of CD mural and transmural inflammation on T2-weighted fat-suppressed images [1, 10, 12]. The dark lumen enhances the evidence of edema and inflammatory changes at the level of the affected intestinal wall, typical features of an active CD. By adding fat-suppression to T2-

weighted images, the higher T2-weighted signal (brightness) of the inflamed wall, as well the brightness of the perivisceral signal related to the mesenteric inflammation, can be clearly detected (Figs. 1F and 2B). In case of an active wall inflammation, therefore, a double contrast effect is obtained on T2-weighted fat-suppressed images as well, similarly to Gd enhanced ones.

Wall edema and mesenteric inflammation are typical findings of an active CD and direct expressions of its typical transmural inflammation which involves all wall layers, the serosa and the fat immediately outside the intestinal wall. These signs are hardly detected on T2-weighted images using biphasic contrast agents. In previous studies, a direct correlation between these findings and an active CD was already reported [1, 10] (Table 1). In the majority of patients with an active CD, Gd-enhancement and T2-weighted images brightness at the level of the involved intestinal wall overlap almost completely on fat-suppressed images (see Figs. 1–3).

In other words, in active CD, the increased mural Gd-enhancement and the increased mural T2 signal can be observed simultaneously at the level of diseased intestinal segments. Moreover, an increased T2 signal is frequently observed at the level of the adjacent mesenteric tissue, suggesting serositis and/or mesenteric inflammation and edema. All these three findings have been successfully correlated with clinical or biochemical signs of CD activity in previous studies [1, 10]. It is important, however, to outline that the doublecontrast effects observed on both T1- and T2-weighted images in active CD lesions are expressions of different pathologic features. A wall enhancement on T1-weighted Gd-images means wall hypervascularity and increased capillary permeability. On the other hand, a hyperintensity of the wall signal on T2-weighted images is the direct finding of a submucosal edema. These features usually coexist in active IBDs, but they are not necessarily linked. Future studies are warranted to explain the behavior of T2 wall signal and Gd enhancement in CD, and to correlate it with pathologic and biochemical signs of activity.

The typical findings of ulcerative colitis (UC) may be similarly detected by DC-MRI [20]. A moderate to severe concentric and continuous wall thickening can be detected at the level of the rectum, the sigmoid colon and, sometimes, throughout the colon, up to the cecum, on both T1- and T2-weighted images. An increased wall enhancement and a local hypervascularity can be observed in active colitis, although usually to a lower degree than in CD colitis. Similarly, in active UC, an increased brightness of the colonic wall can be detected on T2-weighted fat-suppressed sequences. Finally, gross pathologic abnormalities of UC,

including loss of haustration and lumen tubulization or stricturing, can be satisfactorily diagnosed on coronal T2-weighted images.

DC-MRI in the evaluation of other intestinal or peritoneal diseases

According to a few preliminary experiences, this technique should be a valid tool also in the evaluation of less common IBDs. In graft-versus-host disease, for example, the bowel involvement may show MRI signs similar to

those of CD [21]. Infectious enteritis and colitis may be assessed with this technique as well. In cystic fibrosis, inflammatory changes at the level of the large and small intestine can be detected in a similar way [22].

Pseudomyxomas, ascites, and fluid collections are all easily depicted on T2-weighted axial and coronal images by using a negative oral contrast agent and fat-suppression. Fluid collections may in fact frequently be underestimated on T1-weighted images, whereas on plain T2-weighted images the signal of the fluid can be hardly differentiated from that of the mesenteric fat or the intestinal fluid. On T2-weighted fat-suppressed images, fluid collections may instead be depicted at their best, particularly if the signal of the intestinal fluid is simultaneously darkened.

Finally, DC-MRI has proven to be extremely effective in the evaluation of abdominal endometriosis, because of its capability to detect small peritoneal implants, particularly on T1-weighted fat-suppressed images [23]. On the other hand, this technique cannot be considered specific for the depiction of neoplastic lesions or polyps of the small or large bowel, which could be underdetected.

Furthermore, negative MR-enterography is not recommended in acute bowel obstructions, since air-fluid levels can be underestimated or completely missed, due to the homogenous darkening of the lumen content.

Finally, this method is not useful when a detailed analysis of the intestinal folds is required, such as in celiac diseases. In these patients, in fact, the biphasic contrast produces a more adequate lumen effect than the negative contrast [24].

DC-MRI in IBDs: technical aspects

Approximately 45–60 min before the examination, 900– 1000 cc of silicon-coated, superparamagnetic iron oxide (SPIO) intestinal contrast agent are orally administered, diluted in a nonabsorbable suspension (Ferumoxsil, Lumirem, Laboratories Guerbet, Paris, France).

The patient is asked to rapidly ingest the first 500–600 cc of contrast in 15–20 min, whereas the last 300–400 cc are administered slowly, up to the beginning of the exam. In this way, a dark lumen effect can be observed throughout the small bowel and, in most of the cases, at the level of the large bowel as well. Usually, the amount of negative contrast that reaches the large bowel is sufficient to reduce the artefacts due to residual feces, if present.

Large amounts of feces may in fact produce signal inhomogeneity and artefacts, particularly on T1-weighted post-Gd images, since their bright signal overlaps the bright signal of the enhancing wall. Bowel preparation with laxative drugs is however usually avoided if an enteritis or a colitis, related to a CD or a rectal UC, are present; in active IBDs, in which diarrhea is one of the main symptoms, poor amounts of solid feces are usually present in the colon consequently the oral contrast is generally sufficient to homogeneously darken the lumen.

Before Gd-enhancement, on basal T1-weighted images, the negative SPIO intestinal contrast may produce susceptibility artefacts, particularly evident with gradient-echo sequences, where a sort of “bowel dilation” artefacts can be produced (Fig. 1C). Nevertheless, T1 weighted gradient-echo plain sequences should be included in the examination, since they can be extremely useful to assess mesenteric lymph nodes, frequently underestimated on T2-weighted images and on T1-weighted fat-suppressed Gd-enhanced images as well.

On post-Gd T1-weighted images, however, susceptibility artefacts produced by superparamagnetic contrast agents at the level of the bowel lumen are significantly reduced or disappear completely, thanks to the increased signal intensity of mural Gd-enhancement (Fig. 1D).

Both three-dimensional VIBE or bi-dimensional gradient-echo breath-hold sequences are used as T1-weighted sequences; in addition, motion artefacts are possible events with any breath-hold T1-weighted fast sequence. Usually, by adding fat-suppression to Gd-enhanced T1-weighted imaging, the best results are achieved in terms of normal and pathologic wall assessment. In this way, in fact, a high contrast is produced between the bright intestinal wall, the dark perivisceral fat and the black lumen, the T1-weighted (Figs. 1A–D, 2C–D).

Similar findings may be obtained on T2-weighted images, by using the double-contrast technique. HASTE or fast TSE breath-hold T2-weighted sequences are currently used. Nowadays “breath-hold free” HASTE sequences are available too, so fast that do not require breath holding for acquisition, particularly useful for pediatric patients. To completely evaluate both the small and the large bowel, plain axial T2-weighted HASTE images should be acquired from the diaphragm to the pelvic floor. On plain axial T2-weighted images, the

typical concentric wall thickening of IBD, and particularly of CD, can be assessed better than with any other sequence.

The same axial T2-weighted image planes should be acquired before and after fat-suppression, and compared between them, similarly to pre- and post-Gd T1-weighted images. Coronal plain T2-weighted sequences are mandatory to correctly assess CD lesions site, from the jejunum to the rectum. In our experience, the morphologic changes produced by CD lesions at the level of the small and large bowel, such as adhesions, fistulas, dilations, etc., are assessed by plain coronal T2-weighted sequences better than by any other sequence (see Figs. 1–3).

The sequence planes and related findings of DC-MRI are shown in Table 2.

Conclusions

Radiologists certainly tend to assess IBDs by Gd-enhanced T1-weighted images rather than by T2-weighted ones. This is clearly evident since in the majority of published papers on CD, T1-weighted images are considered mostly effective in evaluating bowel signs of inflammation [2, 3, 5–9, 13–19]. T1-weighted Gd-enhanced imaging, however, has a diagnostic efficacy similar to contrast-enhanced computed tomography, although enriched by the intrinsic higher MRI contrast.

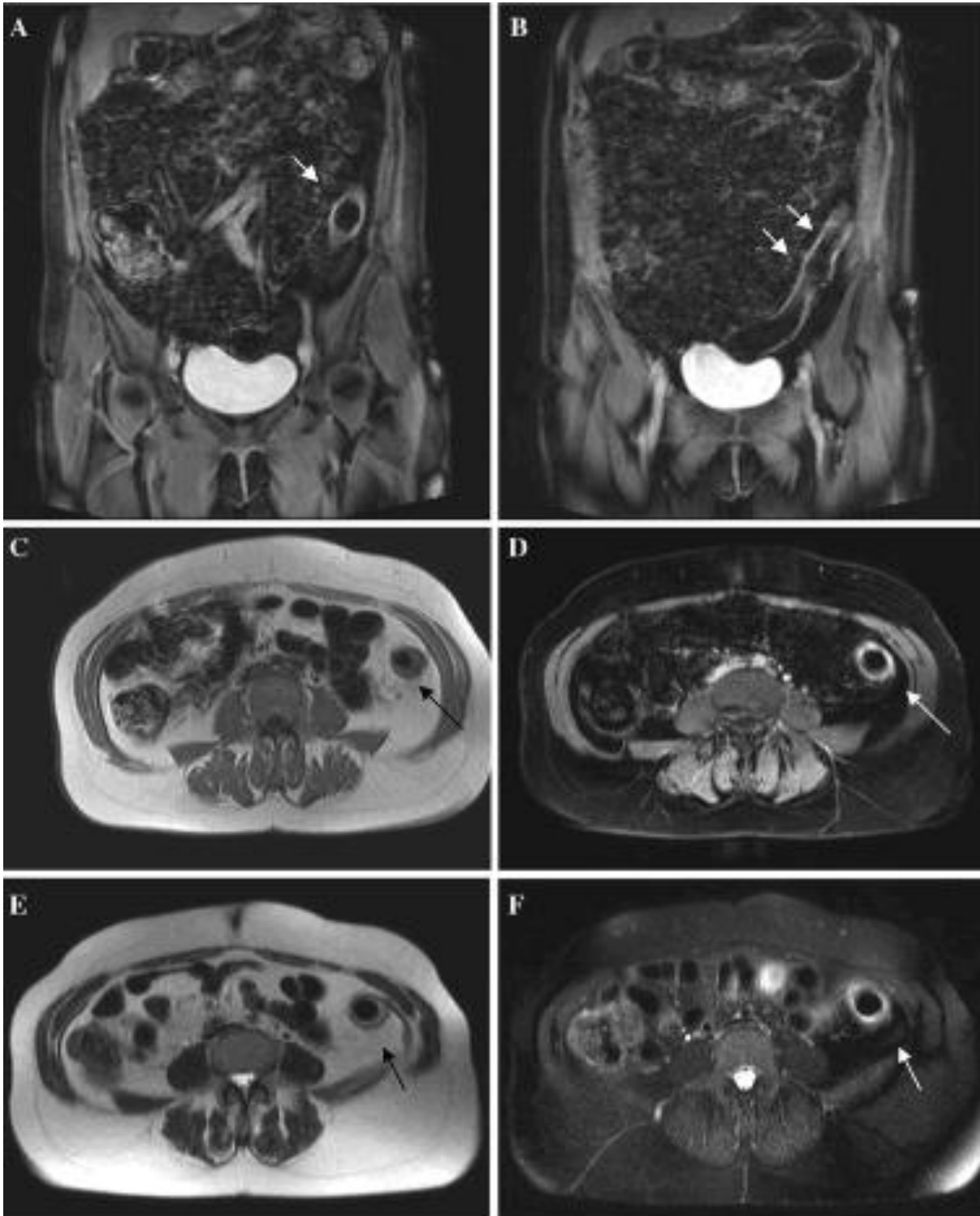
On the other hand, T2-weighted imaging is a primary and unique imaging modality and one of the main diagnostic advantages of MRI, since it highlights the tissue fluid-content like no other imaging technique. T2-weighted imaging should be optimized, rather than underestimated, since it may contain more information than T1-weighted Gd-enhanced imaging in the evaluation of IBDs (Table 3).

DC-MRI, in addition to its intrinsic meaning (combination of two different contrast agents), has the peculiar characteristic of increasing the tissue contrast on both T1- and T2-weighted sequences. Optimization of tissue contrast—due to the proper association of sequences, the negative intestinal contrast agents, the fat suppression, the use of i.v. contrast agents—allows an effective identification and characterization of IBD lesions throughout the small and large intestine. At the same time, the main signs of mural and transmural inflammation of CD can be highlighted on both T1- and T2-weighted images, providing a valuable assessment of disease activity.

References

1. Maccioni F, Bruni A, Viscido A, et al. (2006) MR imaging in patients with Crohn disease: value of T2- versus T1-weighted gadolinium- enhanced MR sequences with use of an oral superparamagnetic contrast agent. *Radiology* 238:517–530
2. Koh DM, Miao Y, Chinn RJ, Amin Z, et al. (2001) MR imaging evaluation of the activity of Crohn's disease. *Am J Roentgenol* 177(6):1325–1332
3. Low RN, Sebrechts CP, Politoske DA, et al. (2002) Crohn disease with endoscopic and gadolinium-enhanced fat-suppressed spoiled gradient-echo MR imaging. *Radiology* 222:652–660
4. Madsen SM, Thomsen HS, Munkholm P, et al. (2002) Inflammatory bowel disease evaluated by low-field magnetic resonance imaging. Comparison with endoscopy, ^{99m}Tc HMPAO leucocyte scintigraphy, conventional radiography and surgery. *Scand J Gastroenterol* 37(3):307–316
5. Gourtsoyiannis N, Papanikolaou N, Grammatikakis J, Prassopoulos P (2002) MR enteroclysis: technical considerations, clinical applications. *Eur Radiol* 12(11):2651–2658
6. Laghi A, Borrelli O, Paolantonio P, et al. (2003) Contrast-enhanced magnetic resonance imaging of the terminal ileum in children with Crohn's disease. *Gut* 52(2):393–397
7. Holzknacht N, Helmberger T, Von Ritter C, et al. (1998) MRI of the small intestine with rapid MRI sequences in Crohn's disease after enteroclysis with oral iron particles. *Radiology* 38(1):28–36
8. Masselli G, Casciani E, Poletti E, et al. (2006) Assessment of Crohn's disease in the small bowel: prospective comparison of magnetic resonance enteroclysis with conventional enteroclysis. *Eur Radiol* 16(12):2817–2827
9. Umschaden HW, Szolar D, Gasser J, Umschaden M, Haselbach H (2000) Small-bowel disease: comparison of MR enteroclysis images with conventional enteroclysis and surgical findings. *Radiology* 215(3):639–641
10. Maccioni F, Viscido A, Marini M, Caprilli R (2002) MRI evaluation of Crohn's disease of the small and large bowel with the use of negative superparamagnetic oral contrast agents. *Abdom Imaging* 27(4):367–375
11. Charles N, Bernstein MD, Greenberg H, et al. (2005) A prospective comparison study of MRI versus small bowel follow-through in recurrent Crohn's Disease. *Am J Gastroenterol* 100:2493–2502

12. Maccioni F, Viscido A, Broglia L, et al. (2000) Evaluation of Crohn's disease activity with MRI. *Abdom Imaging* 25:219–228
13. Albert JG, Martiny F, Krummenerl A, et al. (2006) Diagnosis of small bowel Crohn's disease: a prospective comparison of capsule endoscopy with magnetic resonance imaging and fluoroscopic enteroclysis. *Gut* 55(6):903
14. Borthne AS, Abdelnoor M, Rugtveit J, et al. (2006) Bowel magnetic resonance imaging of pediatric patients with oral mannitol MRI compared to endoscopy and intestinal ultrasound. *Eur Radiol* 16(8):1870
15. Florie J, Wasser MNJ, Arts-Cieslik K, et al. (2006) Dynamic contrast-enhanced MRI of the bowel wall for assessment of disease activity in Crohn's disease. *AJR Am J Roentgenol* 186:1384–1392
16. Ajaj WM, Lauenstein TC, Pelster G, et al. (2005) Magnetic resonance colonography for the detection of inflammatory diseases of the large bowel: quantifying the inflammatory activity. *Gut* 54(2):257–263
17. Sempere GAJ, Sanjuan VM, Chulia EM, et al. (2005) MRI evaluation of inflammatory activity in CD. *AJR* 184:1829–1835
18. Florie J, Wasser MNJM, Arts-Geslik K, et al. (2006) Dynamic contrast-enhanced MRI of the bowel wall for assessment of disease activity in Crohn's disease. *Am J Radiol* 186:1384–1392
19. Rottgen R, Herzog H, Lopez-Hainin E, Felix R (2006) Bowel wall enhancement in magnetic resonance colonography for assessing activity in Crohn's Disease. *J Clin Imaging* 30(1):27–31
20. Maccioni F, Colaiacomo MC, Parlanti S (2005) Ulcerative colitis: value of MR imaging. *Abdom Imaging* 30(5):584–92
21. Mentzel HJ, Kentiuche K, Kosmehl H (2002) US and MRI of gastrointestinal graft-versus-host disease. *Pediatr Radiol* 32(3):195–198
22. Alamberger M, Iannicelli E, Antonelli M (2001) The role of MRI in the intestinal complications of cystic fibrosis. *Clin Imaging* 25(5):344–48
23. Kinkel K, Frei KA, Balleyguier C, Chapron C (2006) Diagnosis of endometriosis with imaging: a review. *Eur Radiol* 16(2):285–298
24. Paolantonio P, Tomei E, Rengo M (2007) Adult coeliac disease: MRI findings. *Abdom Imaging* 32(4):433–440.



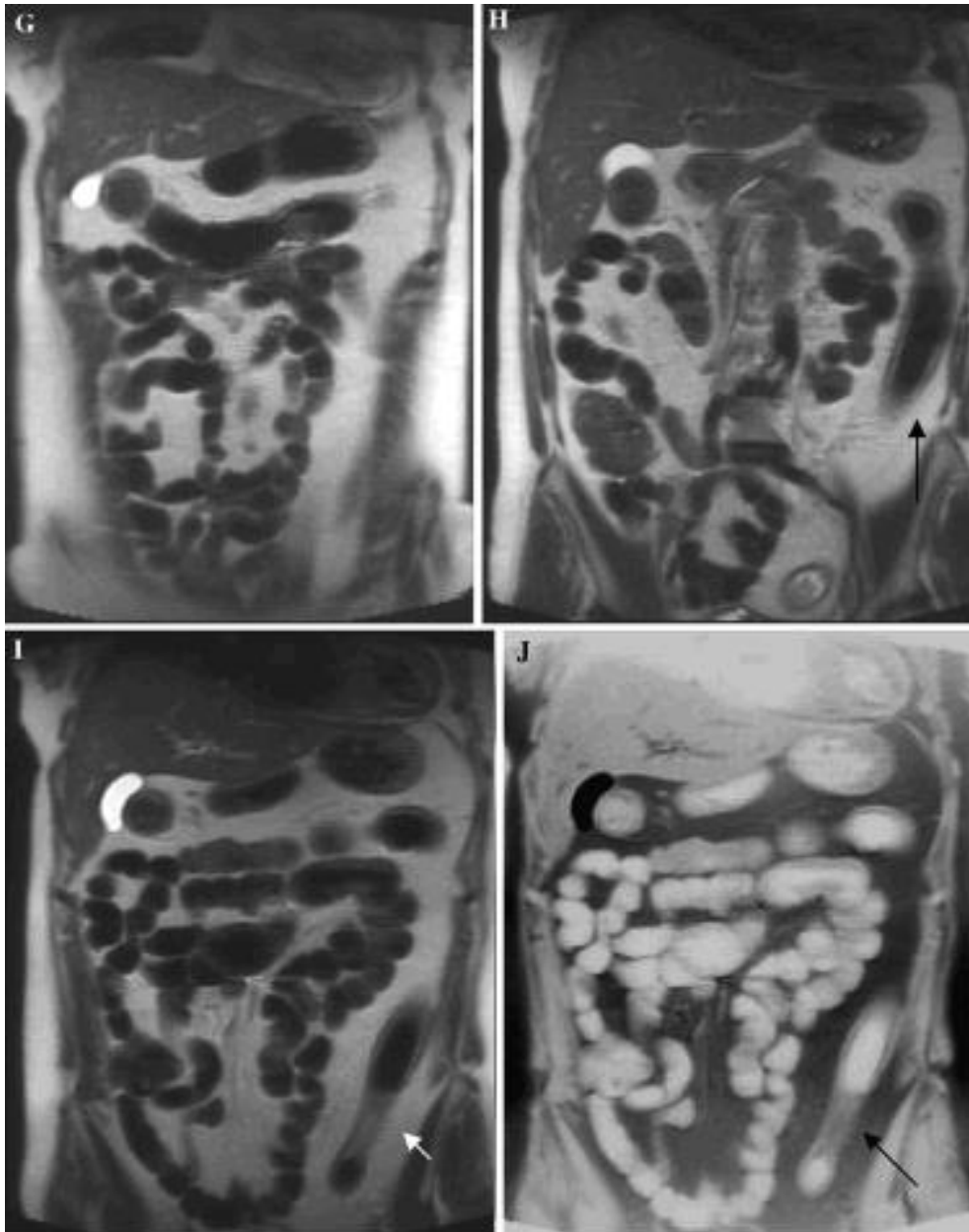


Fig. 1. A 55-year-old man, with colonic CD and clinical instrumental signs of high disease activity (endoscopic signs of colonic active disease, increased serum signs of activity, CDAI > 150). Double contrast MRI was obtained after oral administration of 1000 cc of oral SPIO contrast agent. A, B T1-weighted coronal fat-suppressed VIBE images, following Gd-injection: increased wall thickening and marked wall enhancement at the level of the descending-sigmoid colon (arrows). Mild enhancement of the right colon-distal ileum. Normal small bowel. C, D T1-weighted axial FLASH plain image (left), showing wall thickening and fibrofatty proliferation at the level of the descending colon. Susceptibility artefacts at the level of the bowel loops. On the right side, axial VIBE T1-weighted image, following Gd-injection, at the same level: a marked wall thickening and Gd-enhancement ("double-contrast" effect) is clearly evident, due to darkening of the bowel lumen (white arrow). E, F T2-weighted HASTE plain image (left), and fat-suppressed image (right), both showing wall thickening and fibrofatty proliferation at the level of the descending colon (black arrow). On the left image the diffuse wall brightness ("double contrast" effect) suggests marked wall edema (white arrow). G, H Coronal T2-weighted images. The bowel is diffusely and homogeneously darkened due to the negative contrast agent. Inflammatory involvement of the transverse colon and, more severely, of the descending colon (arrow) can be diagnosed, on the basis of diffuse wall thickening, lost of haustration and fibrofatty proliferation. I, J Coronal T2-weighted image (left): The bowel is diffusely and homogeneously darkened due to the negative contrast agent. Inflammatory involvement of the descending colon is clearly evident (arrow). On the right side, the same inverted coronal plane: the homogeneity of the intestinal contrast can be well appreciated on the right side.

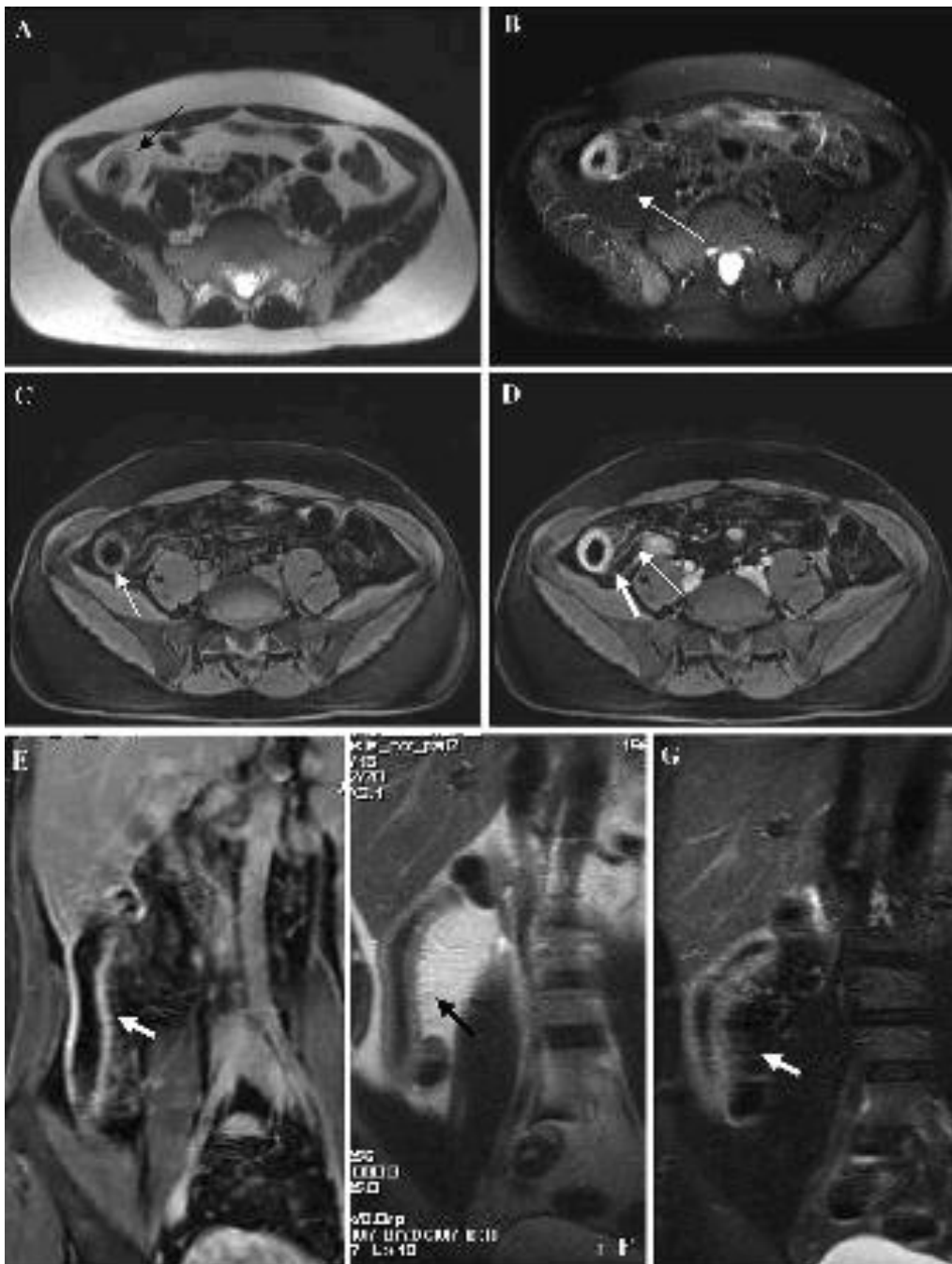

Fig. 2. Recurrent ileal CD after ileocecal resection in a patient with clinical and biochemical signs of active inflammation. A, B Axial HASTE T2-weighted plain (left) and fat-suppressed (right) image: a marked wall thickening and bright wall signal is evident at the level of the anastomotic ileal loop (black arrow); on the fat-suppressed image a “double contrast effect” is clearly evident (white arrow) at the level of the inflamed wall, due to the brightness of wall edema. C, D Axial VIBE T1-weighted plain (left) and Gd-enhanced (right) image: a marked wall thickening and bright wall signal is evident at the level of the anastomotic ileal loop; on the contrast-enhanced fat-suppressed image a “double contrast effect” is clearly evident at the level of the inflamed wall, due to hypervascularity (large arrow). Local increased mesenteric vascularity is evident as well (thin arrow). Notice that (B) and (D) are almost overlapping, although one is T1-weighted and the other one T2-weighted: both of them express active wall inflammation (Crohn's disease activity). E--G Coronal T1- weighted Gd-enhanced image (left) and coronal T2-weighted HASTE plain (mid) and fat-suppressed image (right). A marked and diffuse wall thickening is evident at the level of the ileal anastomotic loop (arrow), characterized by marked wall Gd-enhancement (2e) and bright wall signal on the T2- weighted fat-suppressed image (G).

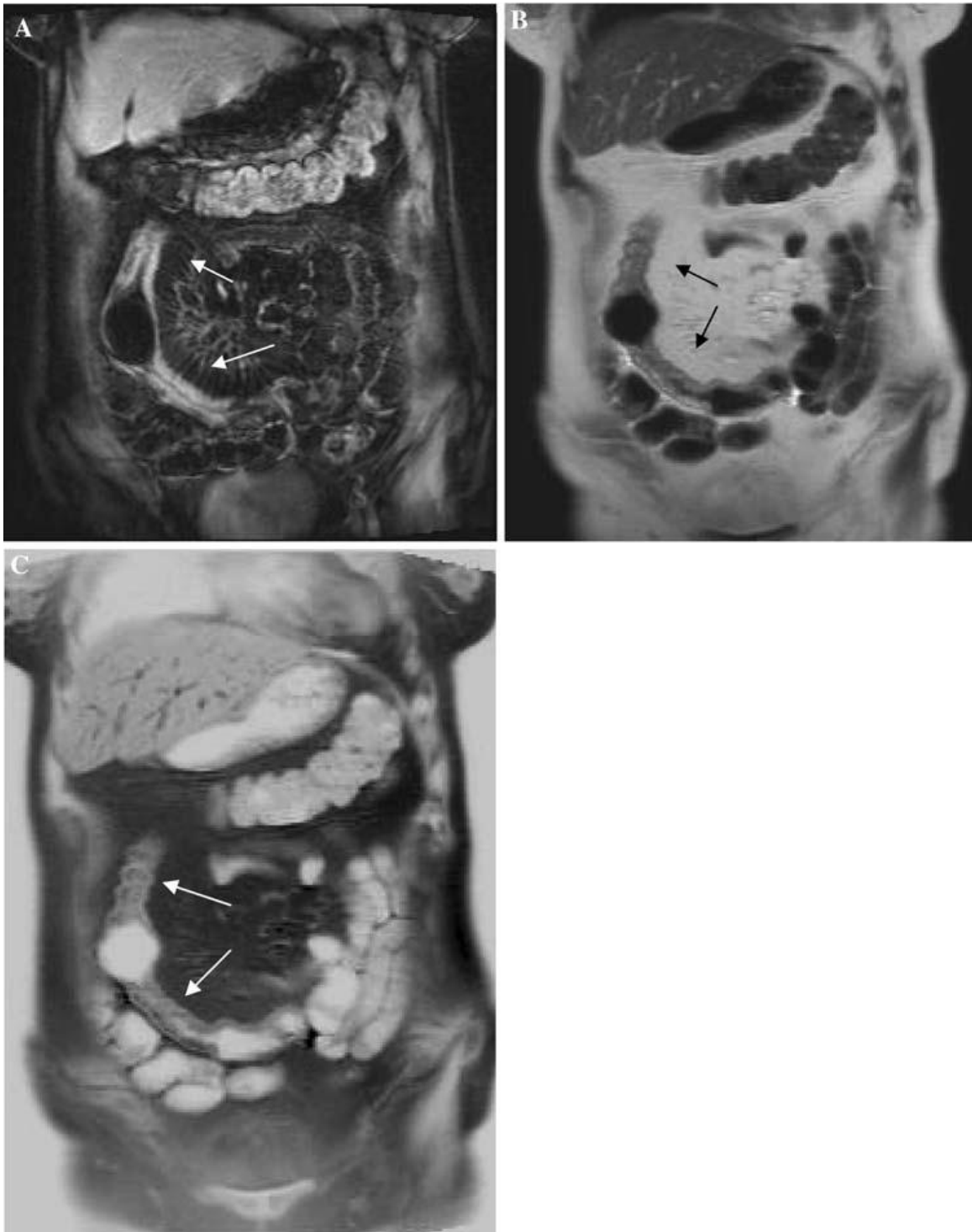


Fig. 3. A 60-year-old woman, with fibrostenotic CD of the mid-distal ileum. A, B. Short strictures alternate with brief prestenotic dilations, typical findings of fibrostenosing CD. On the left (A) coronal T1-weighted VIBE Gd-enhanced image: two short enhancing stenotic ileal segments are clearly evident (white arrows), with a short dilation in between. Local increased mesenteric vascularity is present. On the right (B) coronal T2-weighted HASTE image: the two short enhancing stenotic ileal segments are clearly evident (arrows), similarly the Gd-enhanced image, with a short dilation in between. Coronal T2-weighted HASTE “inverted” image (C): probably, the bright lumen effect better shows the alternating strictures (arrows) and dilations; however, information is exactly the same of image (B).

Table 1. T1- and T2-weighted MRI parameters correlated with clinical and/or endoscopic and/or biochemical signs of CD activity

Author/Journal/Year	MR finding to correlate with CD activity	T weighting
Shoenut et al. <i>J. Clin. Gastroenterol.</i> , 1994	Wall thickening and wall Gd-enhancement	T1
Low, <i>Radiology</i> , 2002	Increased mesenteric vascularity (comb sign*) Wall thickening Gd-enhancement	T1
Gourtsoyiannis et al., <i>Eur. Radiol.</i> , 2002	Increased mesenteric vascularity (comb sign*) Wall thickening Gd-enhancement Lymph nodes enhancement	T1
Sempere et al., <i>Radiology</i> , 2005	Wall enhancement Curves of Gd-wall enhancement	T1
Maccioni et al., <i>Abdom. Imaging</i> , 2000; <i>Radiology</i> 2006	Wall Gd-enhancement Wall thickening (> 4 mm) Increased wall signal ^a Increased mesenteric fat signal	T1 w T1 and T2 T2

^aMeyers et al., *Abdom. Imaging*, 1995

Table 2. Double contrast MRI (negative MR-enterography): technical aspects

Sequence-weighting	Diagnostic value	Acquisition time
T2-weighted HASTE on axial and coronal planes	– Morphologic evaluation of the small and large bowel – Detection of intestinal wall thickening – Detection of complications	5–8 min (breath-hold or breath-hold free acquisition)
T2-weighted HASTE fat suppressed on axial plane	– Assessment of CD activity (wall oedema and mesenteric oedema)	3 min
T1-weighted FLASH on axial plane	– Lymph nodes wall thickening	5 min
T1-weighted FLASH 2D or VIBE 3D fat-suppressed after Gd injection at 0.15 mmol/kg (= > 60 s delay) on axial and coronal planes	– Assessment of CD activity (wall enhancement, mesenteric hypervascularity) – Morphologic evaluation	6–15 min

In this table all the main sequences usually included in the examination are reported. Crohn's disease findings detectable with a given sequence are described

Table 3. MRI accuracy in the detection/localization of distal ileal CD lesions: biphasic vs. negative intestinal contrast agent

Author/journal/year	Number of pts	Intestinal contrast	Sensitivity (%)	Specificity (%)	PPV/NPV (%)	Accuracy (%)
Koh et al., <i>AJR</i> , 2001	30	Biphasic c.a.	89	67		
Low et al., <i>Radiology</i> , 2002	28	Biphasic c.a.	85–89	94–96		91–94
Maccioni et al., <i>Radiology</i> , 2006	59	Negative SPIO c.a	91	95	89/96	94

Chapter 5

Inflammatory bowel diseases: clinical update of practical guidelines

A. Viscido¹, A. Aratari¹, F. Maccioni², A. Signore³, R. Caprilli¹

Nuclear Medicine Communications 2005;26(7):649-655.

¹Gastroenterology Unit, ²Department of Radiological Sciences, ³Nuclear Medicine Unit, Department of Clinical Sciences, University "La Sapienza", Rome, Italy.

Abstract

Idiopathic inflammatory bowel disease (IBD) includes a collection of disorders of the gastrointestinal tract of unknown aetiology, characterized by intestinal inflammation and a chronic relapsing course associated with local and systemic complications. Traditionally, IBD comprises two prototype entities, ulcerative colitis (UC) and Crohn's disease (CD) and an intermediate variant of these diseases, indeterminate colitis which shows overlapping features of the two major forms. Over the last few years, considerable progress has been made in our knowledge of the pathogenesis of IBD, which is complex and derives from genetic, environmental and immunological interactions. The aetiology remains unclear, but it is well established that the lesions and symptoms are associated with over-production of pro-inflammatory cytokines. In this paper we briefly review the pathophysiology and the new therapeutic approaches to IBD, since from these, new achievement depends the appropriate diagnostic exams to be performed and diagnostic flow charts.

Keywords: inflammatory bowel disease, Crohn's disease, ulcerative colitis

Introduction

Idiopathic inflammatory bowel disease (IBD) includes a collection of disorders of the gastrointestinal tract of unknown aetiology, characterized by intestinal inflammation and a chronic relapsing course associated with local and systemic complications. Traditionally, IBD comprises two prototype entities, ulcerative colitis (UC) and Crohn's disease (CD) and an intermediate variant of these diseases, indeterminate colitis which shows overlapping features of the two major forms. Over the last few years, considerable progress has been made in our knowledge of the pathogenesis of IBD, which is complex and derives from genetic, environmental and immunological interactions.

The aetiology remains unclear, but it is well established that the lesions and symptoms are associated with over-production of pro-inflammatory cytokines. In this paper we briefly review the pathophysiology and the new therapeutic approaches to IBD, since from these, new achievement depends the appropriate diagnostic exams to be performed and diagnostic flow charts.

Pathophysiology of inflammatory bowel disease

In normal circumstances, the gastrointestinal mucosa is constantly exposed to substantial and potentially harmful antigenic challenges of the gut lumen (i.e., foods, toxins, chemicals, and resident microbial flora) that generate protective responses to combat possible injurious effects.

As a consequence, a low-grade chronic mucosal inflammation ensues, which is known as 'physiological' or 'controlled' inflammation. The term 'physiological' expresses the concept of inflammation as a favourable situation, whereas the term 'controlled' implies the involvement of powerful control mechanisms. A breakdown in control, either by antigenic overload or disordered immunoregulation causing inappropriate immune activation, results in 'pathological' or 'uncontrolled' inflammation that manifests as a quantitative increase in the immune and inflammatory cells and mediators usually present in controlled inflammation. In other words, even if the distinction between the two conditions is not well defined, the state of controlled inflammation corresponds to health, whereas the state of uncontrolled inflammation corresponds to disease [1]. A commonly held view is that the chronic inflammation is primarily the consequence of a dysregulated adaptive

immune system leading to an immunological imbalance with excess of pro-inflammatory cytokines [2]. There is evidence indicating that intestinal epithelial cells, in inflammatory bowel disease (IBD), process antigens abnormally. Instead of activating T-suppressor cells that may decrease an inflammatory response (so called induction of 'oral tolerance'), the intestinal epithelial cells actually activate T-helper cells, leading to an enhancement of immune reactivity. The associated increase in cytokine production leads, in turn, to the activation of a number of local cells (including neutrophils) with increased production and release of proinflammatory mediators that are ultimately responsible for pathological inflammation and tissue injury. If the loss of tolerance is temporary, cellular and epithelial repair promptly ensues with complete tissue healing (acute inflammation). When the loss of tolerance continues, immune activation becomes inappropriately persistent (chronic inflammation). This latter condition is present in IBD and is responsible for the chronic course. Based on this scheme, the degree and frequency of loss of tolerance over time may determine the relapsing course of the disease, with sustained, chronic inflammation [3].

Therefore, highly activated T-helper cells lacking of effective down-regulation are responsible for the continuous release of pro-inflammatory mediators determining mucosal injury. In addition, there is continuous recruitment of circulating immune cells towards the inflamed intestinal site. This mechanism participates in the perpetuation of the inflammatory process and interferes negatively with the repairing mechanisms. Immunological responses are regulated and directed by specific cytokines that are small glycoprotein mediators involved in the communication between cells. The simultaneous action of different cytokines and their interactions are of extreme importance for host defence.

A wide range of mediators and receptors are responsible for chronicization of inflammation and injury. Over the last few years considerable attention has been paid to tumour necrosis factor-alpha (TNF α), a highly proinflammatory molecule which plays a key role in the pathogenesis of Crohn's disease (CD) [4]. Increased concentrations of TNF α were seen both in normal and inflamed mucosa of patients with CD suggesting that TNF α plays an early, pivotal role in the cytokine cascade of the inflammatory process [5]. Transgenic animal models, which over-express TNF α genes, develop terminal ileitis with granuloma and arthritis; in addition, blockade of TNF determines healing of CD-like enteritis in a spontaneous animal model [6].

Adaptive immune responses start with the binding of antigen to antigen receptors on lymphocytes. The number and the activity of these cells, cross-reacting with the antigen, is greatly expanded by clonal proliferation and differentiation [7]. Furthermore, the triggering of inflammation will lead the mucosal cells to synthesize a variety of molecules, including cytokines. TNF α is released into the intestinal mucosal by activated T-cells and macrophages and circulates locally and systemically as a trimmer able to bind to transmembrane TNF α receptors. This results in intracellular signalling and nuclear factor (NF) κ B activation, which, in turn, stimulates the production of other potent pro-inflammatory cytokines, including TNF α itself. These cytokines enhance the immune response and activate other inflammatory pathways, such as those mediated by arachidonic acid metabolites (leukotrienes, prostaglandins, tromboxanes, platelet activating factor), superoxides, nitric oxide and growth factors [8]. TNF α also recruits circulating inflammatory cells at the site of inflammation by up-regulation of adhesion molecules and enhancing neovascularization, plays an active part in granuloma formation, induces oedema and activates coagulation. It also influences apoptosis of target cells through legation of specific receptor TNFR1 [9,10].

TNF α also exerts a number of systemic actions responsible for signs and symptoms of the acute phase response (e.g., fever, leukocytosis, neutrophilia, anaemia, liver responses, bone re-absorption) [11]. Recruitment of inflammatory cells from systemic circulation into the site of inflammation is of crucial importance in determining gut injury. This cell's trafficking, mostly controlled by TNF α , is due to a series of interactions of the circulating cells and the endothelium through the adhesion molecules, finally leading to cell transmigration. TNF α promotes the expression of a number of adhesion molecules such as intercellular adhesion molecule-1 (ICAM-1), selectins, integrins, vascular-cell adhesion molecule-1 (VCAM-1), and mucosal-addressin cellular madhesion molecule (Mad-CAM-1). Integrins are heterodimeric glycoproteins that are widely expressed on leukocytes, mostly lymphocytes, and are thought to be important mediators of leukocyte adhesion to vascular endothelium [12].

A number of observations showed that pro-inflammatory cytokine production is regulated by several nuclear transcription factors, activated by different intracellular and extracellular signals. NF κ B is a transcription factor that plays a key role in the activation of genes involved in immune and acute phase responses, increasing the expression of many cytokines (IL-1, TNF α , IL-2, IL-6, IL-8, and IL-12), enzymes (inducible nitric oxide

synthase (iNOS)), growth factors, adhesion molecules (e.g., ICAM-1, selectins, VCAM-1), T-cell receptor and MHC class II molecules [13]. Newly produced proinflammatory cytokines lead to a positive, auto-regulatory and self-amplifying loop of NFκB activation [14]. It is of interest that all these inflammatory mediators (cytokines, growth factors, adhesion molecules and receptors) could be used as radiolabelled peptides to visualize inflammation by using nuclear medicine techniques. NFκB is also able to function in concert with other transcription factors, such as activator protein-1 (AP-1). The activation of AP-1 is mediated by mitogen-activated protein kinases (MAP-kinases) pathways [15]. AP-1, similarly to NFκB, acts by enhancing the production of pro-inflammatory molecules. In the last few years, another nuclear transcriptional factor, the nuclear factor of activated T-cells (NFATc) has received much attention [7]. NFATc can produce both immunogenic and tolerogenic signals, depending on the kind of stimulus (pro-inflammatory or anti-inflammatory) [16]. The balance of immunogenic and tolerogenic signals is necessary to maintain an adequate immune system response. Ideal targets of new biological therapies could be addressed to stimulate tolerogenic pathways other than to block immunogenic ones. Recently, an explosion of interest came from the identification of the association between NOD2 gene mutations on chromosome 16 and increased susceptibility to CD [17,18]. NOD2 is an intracellular protein and its expression is highly restricted to monocytes/macrophages. NOD2 might serve as intracellular receptor for bacterial lipopolysaccharides and/or other bacterial products transducing signals in the monocyte/macrophage that lead to activation of NFκB and transcription of regulatory genes [19]. Three mutations of this gene have been identified in about 25% of the patients with CD. They probably determine an incomplete innate immune response and altered inflammatory response by adaptive immune system, but other mechanisms are involved [20]. It is commonly accepted that intestinal bacterial antigens play a key role in the pathogenesis of CD, but little is known on the mechanisms that link bacteria to the transcription of pro-inflammatory genes. The discovery of these mutations opens a new way to understand the linkage between the innate immune system, genetic factors and enteric bacteria in the pathogenesis of CD.

Nevertheless, the pathophysiological mechanisms induced by variations of the NOD2 gene in intestinal mucosa need further investigation.

Management of patients with inflammatory bowel disease

Management of IBD is aimed at reducing inflammation. Current conventional therapies with aminosalicylates, antibiotics, corticosteroids, and immunosuppressive agents are still far from satisfactory as most IBD patients need surgery at some time for failure of medical treatment or complications of the disease [21,22]. However, the progress made over the last few years in our knowledge of basic mechanisms of the diseases allowed the identification of new targets for therapy. Recent advances in biotechnology have led to the development of many new therapeutic agents, the so-called biological agents that selectively target single key processes involved in the pathogenesis of the disease. These agents include native biological preparations, recombinant peptides or proteins, monoclonal antibodies against cytokines (or other molecules), nucleotide based therapies, and cell and gene therapies [23].

A growing number of biological agents are under investigation in randomized controlled trials and uncontrolled studies. To date, biological agents have shown unequivocal advances in the treatment of CD and represent the new challenge in the management of IBD. However, considering the results of all the published randomized controlled trials, it may be seen that even if a treatment usually appeared more effective than placebo, a response rate clearly exceeding 50% was observed only after administration of the monoclonal antibody anti-TNF α (infliximab). Infliximab is able to induce and maintain remission, promote healing of gut mucosa, both endoscopically and histologically, and dramatically induce closure and healing of fistulae.

Furthermore, patients responding to treatment experience a rapid reduction of symptoms, but the effect of therapy is time limited as well as striking improvement extra-intestinal manifestations and quality of life. The effect of therapy is, however, limited to the period of treatment [24,25]. Recently, it has been demonstrated that maintenance treatment with repeated infusions of infliximab is able to maintain remission in a 1 year follow up [26,27].

Disease assessment

Treatment of IBD depends on the site and extension of the disease, severity of inflammation, and presence of complications (both intestinal and systemic). Response to previous treatments has also to be considered. Inflammation, obstruction, abscess and

fistulae need different treatments and therefore have to be distinguished by appropriate examinations. Thus, clinical and laboratory investigations have a key role, but instrumental evaluations are also necessary.

Plain abdominal radiography is still essential if intestinal obstruction, megacolon, or perforation are suspected, both in UC and CD. Overt toxic megacolon is diagnosed in the presence of a transverse colonic dilatation exceeding 6 cm. The gaseous distension of the small bowel is generally considered an alarm sign of impending megacolon. Overt perforation is diagnosed when free intra-peritoneal gas is present, but small sealed perforations will be missed on plain film. Computerized tomography (CT) is more sensitive than plain films for detecting sealed perforation or pneumatosis. Obstruction is simply detected on plain abdominal radiography, but the problem is to understand whether occlusion depends on fibrotic or inflammatory lesions, as the two conditions require different treatment.

For the study of the small intestine, the small bowel barium follow-through or the small bowel enema are performed. The barium follow-through is the 'gold standard' as, with respect to the small bowel enema, is more comfortable for the patient, more accurate for proximal disease, and safer. Fluoroscopy permits the detection of the earliest change of the small bowel, either mucosal granularity, aphthoid ulceration, or diffuse fold thickening, whereas cobblestones, linear or fissuring ulceration, fistula, narrowing, pre-stenotic dilatation are signs of more advanced disease.

Considering that more than half of patients with CD have disease in the distal ileum, colonoscopy with ileoscopy, is performed routinely. Endoscopy is preferred to radiological examinations as it allows a direct visual appreciation of mucosal lesions and the collection of biopsy samples. It helps to differentiate between CD and UC, to assess the extent and severity of the mucosal lesions, to monitoring the therapeutic efficacy in the healing of mucosal lesions and is important in the post-operative follow-up (recurrence of CD at the site of anastomosis or development of pouchitis in UC). Moreover, colonoscopy may have a role in surveillance programmes to detect dysplasia in longstanding diseases [28] especially using chromoendoscopy. Nowadays, the introduction in clinical practice of the endoscopic videocapsula allows the early detection of small lesions in the small bowel. When intestinal stenosis are suspected the patency capsula can be previously used to test the intestinal calibre and to avoid occlusion/ sub-occlusion situations [29].

In the last few years, new techniques to assess the site of disease, inflammatory activity and presence of complications have been used. These include scanning with radiolabelled leucocytes or peptides, and the use of ultrasound, computed tomography and magnetic resonance imaging.

Scanning with radiolabelled leukocytes identifies the sites and activity of intestinal inflammation and intraabdominal abscesses non-invasively. In the last few years, scintigraphic scanning with cytokines or monoclonal antibody anti-inflammatory molecules has been used [30]. So far, scanning with interleukin-2 [31] or with monoclonal antibody anti-cellular adhesion molecules such as E-selectin [32] have been tested successfully.

Scanning with interleukin-2 has been demonstrated to have a predictive value for clinical relapse [33]. These techniques allow therapeutic biological agents to be applied when detecting inflammation by using imaging techniques. They also give an important contribution to the understanding of the pathogenesis of IBD.

Transabdominal ultrasound for the assessment of wall abnormalities, presence of abscess and fistula is becoming widespread. The main abnormality is wall thickening of >3–4 mm. The presence of stratification of the bowel wall is suggestive of acute inflammation, whereas its loss is indicative of chronic inflammation with fibrosis (the wall has to have a uniform low reflectivity). Furthermore, the use of colour Doppler allows a better detection of changes in mucosal and superior mesenteric arterial blood flow indicating active or quiescent CD lesions [34]. The non-invasive nature and lack of radiation exposure make ultrasound an appealing investigative technique, particularly as a first-line examination and in the follow-up, but results are dependent on operator skill and equipment quality. Recently, it has been proposed that the use of an oral contrast agent (polyethylene glycol) strikingly enhances the accuracy of ultrasonography for the study of the small bowel (small intestine contrast ultrasonography (SICUS)) [35].

Abdominal computed tomography now has a major role in the diagnosis of abscess, fistula, and perianal and parastomal complications of CD. It offers imaging of transmural inflammation: fibro-fatty proliferation, mesenteric adenopathy and vascular changes in the mesentery. Furthermore, the introduction of oral contrast agents, with or without enteroclysis, permits better evaluation of the intestinal wall and the relative inflammation. However, the use of magnetic resonance imaging for the assessment of CD is evolving. The lack of radiation exposure, use of oral and intravenous contrast agents and different

acquisition sequences, make this technique very promising. It allows the intestinal wall thickness to be determined, and the images enhanced, as well as the detection of transmural inflammation and abdominal complications. Additionally, it is becoming even more valuable in assessing inflammatory activity [36].

Diagnosis of patients with suspected inflammatory bowel disease

It is important for the appropriate management of the patients to diagnose the presence of IBD and to distinguish CD from UC.

In normal circumstances the presence of IBD is suspected on the basis of clinical and laboratory data. Infectious diseases should be excluded on the basis of stool and blood examination.

Abdominal ultrasonography represents the first-line instrumental examination that can allow the visualization of a thickened bowel wall, abscess or other abdominal findings. Other imaging examinations such as a white blood cell scan and magnetic resonance imaging could be more accurate than ultrasonography in the detection of intestinal inflammation. However, their application as a first-line examination is limited by the low availability in hospitals and outpatients clinics. Ultrasound scanners are easily available in all centres and therefore ultrasonography is often used as a first-line instrumental examination. However, a combination of endoscopy with biopsies and X-ray barium studies is essential for the diagnosis of CD and UC.

Once the diagnosis is made it is important to investigate the presence of complications and extra-intestinal manifestations in order that the appropriate treatment can be given. This kind of investigation is based on imaging techniques such as scanning with radiolabelled leukocytes, magnetic resonance imaging or computer tomography (Fig. 1).

In paediatric patients imaging techniques (white blood cell scans, magnetic resonance imaging and computed tomography) are sometimes performed before the endoscopic examination as they are a more comfortable investigation. Considering, however, that differential diagnosis includes various malignancies, the presence of a histological examination of intestinal biopsies, showing characteristic findings of CD or UC is essential.

Follow-up of patients with inflammatory bowel disease

Whereas the same examinations are performed for the diagnoses of both CD and UC, patients undergo different examinations during the follow-up for CD and UC.

In UC patients, regular follow-up with biopsies is sufficient to monitor disease activity and to exclude the development of carcinoma. In CD patients, the follow-up is more difficult compared to that of UC patients due to the different clinical course. Due to the absence of a relationship between lesions and symptoms, patients in clinical remission need regular follow-up (Table 1). As far as the post-operative course is concerned, most physicians consider that the symptoms are the target for therapy and therefore patients are followed up in a similar way to those who have not undergone surgery. Other authors consider lesions as the target for therapy, as the kind of lesion (aphtae, ulcers or narrowing) are the most powerful predictive factors of the future course of the disease. In these conditions only endoscopy or barium examinations studies are able to make distinction between the different kind of lesions.

Considering that CD affects young adults and that there is no definitive cure, patients need many instrumental during their lives. That is why X-ray examinations are preferred. Nowadays, abdominal ultrasound, magnetic resonance imaging and white blood cell scans are becoming even more important. These techniques show good accuracy with respect to radiological examinations and can be repeated frequently. In the case of flare-up or when intestinal complications are suspected endoscopy and other radiological examinations, as illustrated in the previous paragraphs, are required (Fig. 2).

Conclusions

Meticulous specialist management can ameliorate the prognosis of patients with IBD. In the last few years considerable progress has been made in the knowledge of the pathogenic mechanisms of the diseases. As a result of the concomitant advances in biotechnology this progress has allowed the development of new therapeutic agents, the so-called biological agents, that selectively target single key processes involved in the pathogenesis of the disease.

Recently, new techniques for clarifying the site of disease, activity and complications have been used. These include scanning with radiolabelled leukocytes and peptides, ultrasound, computed tomography, and magnetic resonance imaging.

Further amelioration of management of patients with IBD could derive from the use of more accurate diagnostic procedures. The use of techniques that visualize inflammation is of crucial importance as the management of IBD is aimed at reducing inflammation. Scintigraphic scanning could allow the use, in the diagnostic setting, of the same biological agents used for therapy. These techniques could provide important contributions for visualizing inflammation and understanding the pathogenesis of IBD.

References

1. Kirsner JB. Nonspecific inflammatory bowel disease (ulcerative colitis and Crohn's disease) after 100 years – what next? *Ital J Gastroenterol Hepatol* 1999; 31:651–658.
2. Fiocchi C. Inflammatory bowel disease: etiology and pathogenesis. *Gastroenterology* 1998; 115:182–205.
3. Caprilli R, Viscido A. Evolving concepts on inflammatory bowel disease. Are we happy with the present nosology? *Ital J Gastroenterol Hepatol* 1999; 31:893–897.
4. Papadakis KA, Targan SR. Tumor necrosis factor: biology and therapeutic inhibitors. *Gastroenterology* 2000; 119:1148–1157.
5. Reimund JM, Wittersheim C, Dumont S, Muller CD, Kenney JS, Baumann R, et al. Increased production of tumor necrosis factor-alpha, interleukin-1-beta, and interleukin-6 by morphologically normal intestinal biopsies from patients with Crohn's disease. *Gut* 1996; 39:684–689.
6. Cominelli F. Tumor necrosis factor modulation: from bench to bedside. *Inflam Bowel Dis* 2000; 6:S21–S22.
7. Goodnow C. Pathways for self-tolerance and the treatment of autoimmune diseases. *Lancet* 2001; 357:2115–2121.
8. Eigler A, Sinha B, Hartman G, Endres S. Taming TNF: strategies to restrain this proinflammatory cytokine. *Immunol Today* 1997; 18:487–492.
9. Luger A, Schmidt M, Luger N, Paules HG, Domschke W, Kucharzik T. Infliximab induces apoptosis in monocytes from patients with chronic active Crohn's disease by using a caspase-dependent pathway. *Gastroenterology* 2001; 121:1145–1157.

10. Van Deventer SJ. Transmembrane TNF-alpha, induction of apoptosis, and the efficacy of TNF-targeting therapies in Crohn's disease. *Gastroenterology* 2001; 121:1242–1246.
11. Sandborn WJ, Hanauer SB. Antitumor necrosis factor therapy for inflammatory disease: a review of agents, pharmacology, clinical results, and safety. *Inflam Bowel Dis* 1999; 5:119–133.
12. Westermann B, Engelhardt B, Hoffmann JC. Migration of T-cells in vivo: molecular mechanisms and clinical implications. *Ann Intern Med* 2001; 135:279–295.
13. Tak PP, Firestein GS. NF-kB: a key role in inflammatory diseases. *J Clin Invest* 2001; 107:7–11.
14. Mercurio F, Zhu H, Murray BW, Shevchenko A, et al. Cytokine-activated IKB kinases essential for NFkB activation. *Science* 1997; 278:860–866.
15. Karin M. The regulation of AP-1 activity by mitogen-activated protein kinases. *Am Soc Biochem Mol Biol* 1995; 270:16483–16486.
16. Healy JI, Goodnow CC. Positive versus negative signalling by lymphocyte antigen receptors. *Annu Rev Immunol* 1998; 16:645–670.
17. Hugot JP, Chamaillard M, Zouali H, Lesage S, Cezard JP, Belaiche J, et al. Association of NOD2 leucine-rich repeat variants with susceptibility to Crohn's disease. *Nature* 2001; 411:599–603.
18. Ogura Y, Bonen DK, Inohara N, Nicolae DL, Chen FF, Ramos R, et al. A frameshift mutation in NOD2 associated with susceptibility to Crohn's disease. *Nature* 2001; 411:603–606.
19. Ogura Y, Inohara N, Benito A, Chen FF, Yamaoka S, Nunez G. Nod2, a Nod17APAF-1 family member that is restricted to monocytes and activates NF-kB. *J Biol Chem* 2001; 276:4812–4818.
20. Cho H. The Nod2 gene in Crohn's disease: implications for future research into the genetics and immunology of Crohn's disease. *Inflam Bowel Dis* 2001; 7:271–275.
21. Farrell RJ, Peppercorn MA. Ulcerative colitis. *Lancet* 2002; 359:331–340.
22. Shanahan F. Crohn's disease. *Lancet* 2002; 359:62–69.
23. Sands BE. Biologic therapy for inflammatory bowel disease. *Inflam Bowel Dis* 1997; 3:95–113.
24. D'Haens G, Van Deventer S, Van Hogezaand R, Chalmers D, Kothe C, Baert F, et al. Endoscopic and histological healing with Infliximab anti-tumor necrosis factor antibodies in Crohn's disease: a European Multicenter Trial. *Gastroenterology* 1999; 116:1029–1034.

25. D'Haens G. Infliximab (Remicade): is it the magic bullet for Crohn's disease?. *Dig Liver Dis* 2000; 32:653–656.
26. Hanauer SB, Feagan BG, Lichtenstein GR, Mayer LF, Schreiber S, Colombel JF, et al. Maintenance infliximab for Crohn's disease: the ACCENT I randomised trial. *Lancet* 2002; 359:1541–1549.
27. Sands BE, Anderson FH, Bernstein CN, Chey WY, Feagan BG, Fedorak RN, et al. Infliximab maintenance therapy for fistulizing Crohn's disease. *N Engl J Med* 2004; 350:876–885.
28. Rampton DS. Management of Crohn's disease. *BMJ* 1999; 319:1480–1485.
29. Kornbluth A, Legnani P, Lewis BS. Video capsule endoscopy in inflammatory bowel diseases: past, present, and future. *Inflam Bowel Dis* 2004; 10:278–285.
30. Signore A, Annovazzi A, Chianelli M, Corsetti F, Van de Wiele C, Watherhouse RN. Peptide radiopharmaceuticals for diagnosis and therapy. *Eur J Nucl Med* 2001; 28:1555–1565.
31. Signore A, Chianelli M, Annovazzi A, Bonanno E, Spagnoli LG, Pozzilli P, et al. ¹²³I-interleukin-2 scintigraphy for in vivo assessment of intestinal mononuclear cell infiltration in Crohn's disease. *J Nucl Med* 2000; 41:242–249.
32. Annovazzi A, Biancone L, Caviglia R. ^{99m}Tc-interleukin-2 and (⁹⁹Tc)- HMPAO granulocyte scintigraphy in patients with inactive Crohn's disease. *Eur J Nucl Med Mol Imaging* 2003; 30:374–382.
33. Bhatti M, Chapman P, Peters M, Haskard D, Hodgson HJ. Visualising E-selectin in the detection and evaluation of inflammatory bowel disease. *Gut* 1998; 43:40–47.
34. Rapaccini GL, Pompili M, Orefice R, Covino M, Riccardi L, Cedrone A, et al. Contrast-enhanced power doppler of intestinal wall in the evaluation of patients with Crohn's disease. *Scand J Gastroenterol* 2004; 39:188–194.
35. Pallotta N, Baccini F, Corazziari E. Small intestine contrast ultrasonography (SICUS) in the diagnosis of small intestine lesions. *Ultrasound Med Biol* 2001; 27:335–341.
36. Maccioni F, Viscido A, Broglia L, Marrollo M, Masciangelo R, Caprilli R, et al. Evaluation of Crohn disease activity with magnetic resonance imaging. *Abdom Imaging* 2000; 25:219–228.

Table 1
Follow-up examinations in patients with inflammatory bowel disease

Remission	Flare-up
Ultrasonography Magnetic resonance imaging White blood cell scan	White blood cell scan Magnetic resonance imaging Endoscopy Barium studies Computed tomography scan

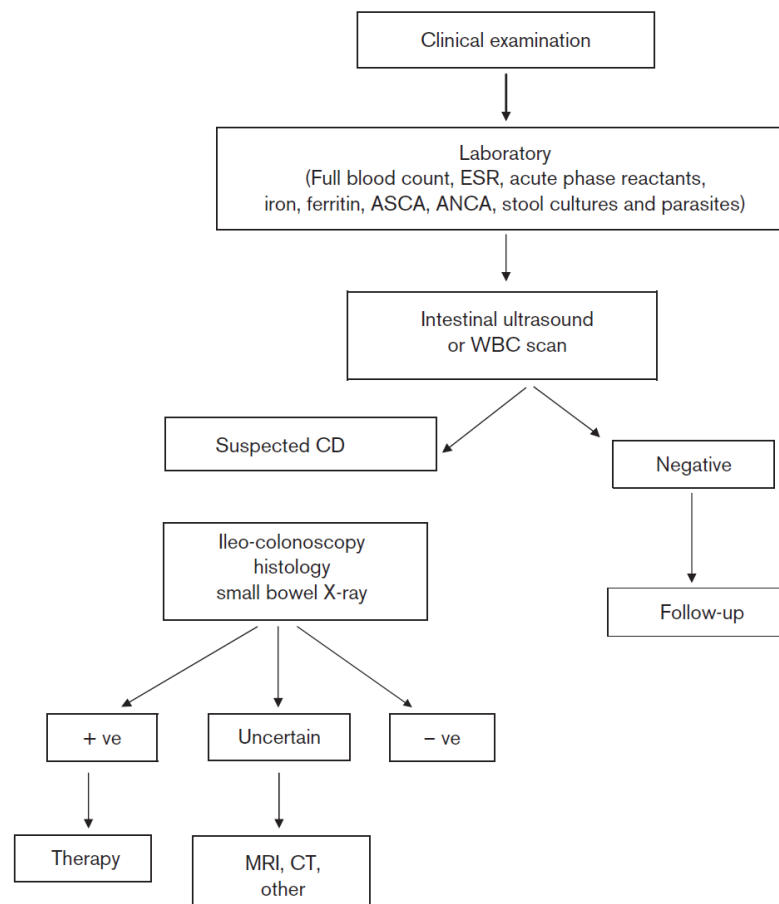


Figure 1: Diagnostic flow-chart for differential diagnosis of inflammatory bowel disease (IBD) in patients with clinical symptoms and suspected IBD. Intestinal ultrasound is often performed as a first test because it is non-invasive, cheap and easily available, despite its low sensitivity and specificity with respect to other diagnostic tests. We also suggest using a white blood cell scan as the first imaging modality because of its high sensitivity.

Chapter 6

Use of a ^{99m}Tc -technetium labeled anti-TNF α monoclonal antibody in Crohn's disease: in vitro and in vivo studies

C. D'Alessandria¹, G. Malviya², A. Annovazzi², A. Viscido³, A. Aratari³, F. Maccioni⁴, A. Amato⁵, F. Scopinaro¹, R. Caprilli³, A. Signore^{1,2}

Q J Nucl Med Mol Imaging. 2007;51(4):334-342.

¹ Nuclear Medicine Unit, II Faculty of Medicine, University "La Sapienza", Rome, Italy

² Department of Nuclear Medicine and Molecular Imaging, University Medical Center Groningen, University of Groningen, The Netherlands

³ Gastroenterology Unit, Department of Clinical Sciences, University "La Sapienza", Rome, Italy

⁴ Department of Radiological Sciences, University "La Sapienza", Rome, Italy

⁵ Department of Surgery, II Faculty of Medicine, University "La Sapienza", Rome, Italy

Key words: Crohn's disease, TNF α , Infliximab, molecular imaging

Abstract

Crohn's Disease is a chronic inflammatory bowel disease characterized by a cellular-mediated immune response driven by cytokines secreted mainly by T helper 1 cells (Th1). In active phases of the disease, an increased production and release of TNF α by macrophages and monocytes of the lamina propria has been described. In order to visualise the presence of TNF α within the gut mucosa in patients with active CD candidate for immunotherapy with a chimeric human/mouse monoclonal antibody anti-TNF α (Infliximab, Remicade®), the same antibody has been labelled with ^{99m}Tc . A product with high labelling efficiency (>95%) and stability has been obtained. In vitro tests with stimulated T-cells expressing TNF α indicated that ^{99m}Tc -Infliximab retains its binding activity to cell bound TNF α as compared to unlabelled Infliximab. We have studied 7 patients with active CD and candidate for immunotherapy with Infliximab. Images of the abdomen were acquired at 6 to 20 hrs after i.v. injection of about 10 mCi of ^{99m}Tc -Infliximab and a week later, all patients were also studied with ^{99m}Tc -HMPAO-labelled autologous white blood cells (WBC). The degree of ^{99m}Tc -Infliximab uptake by the inflamed bowel evaluated at 20 hrs post injection was less than that seen with labelled WBC and with a different distribution. In conclusion, bowel uptake of ^{99m}Tc -Infliximab in patients with active CD was very low indicating little presence of TNF α in inflamed gut. This finding does not supports the hypothesis that the therapeutic effect of Infliximab, or other similar biological drugs, in CD is mainly due to specific blocking of TNF α in inflamed tissue and more studies are necessary to clarify the mechanism of action of these new biological drugs.

Introduction

Ulcerative colitis (UC) and Crohn's disease (CD) are the two main types of inflammatory bowel diseases (IBD). In the network of IBD there is a sequence of events, which are not usually synchronous in all part of the bowel, so that different stages of the disease can be observed in different areas of the bowel. In Crohn's disease several pro-inflammatory cytokines are involved in response to inflammation, infection and injury. Increased levels of production and release of soluble and membrane bound $\text{TNF}\alpha$ in the bowel mucosa of patients with active Crohn's disease has been found (Baert FJ et al. 1999 (1)). The Tumour necrosis factor α ($\text{TNF}\alpha$) is a potent pro-inflammatory cytokine produced by many cell types, including macrophages, monocytes, lymphocytes, keratinocytes and fibroblasts in response to inflammation. $\text{TNF}\alpha$ exerts its inflammatory effects both directly on multiple tissue targets and also inducing other pro-inflammatory cytokines (Julià Panes, 1999 (2)). Several lines of evidence suggest the central role of $\text{TNF}\alpha$ in the pathogenesis of mucosal inflammation in Crohn's disease and it is indicated like the apex of the inflammatory cascade (Papadakis KA et al, 2000 (3)). The effects of $\text{TNF}\alpha$ in the intestine include disruption of the epithelial barrier, induction of apoptosis of villous epithelial cells, and secretion of chemokines from intestinal epithelial cells (Guy-Grand D et al, 1998; Yang SK et al, 1997 (4, 5)). The pivotal role of this cytokine in Crohn's disease led to development of specific immunotherapies based on the administration of monoclonal antibodies or soluble receptors which bind and inactivate the cytokine and promotes the $\text{TNF}\alpha$ as a prognostic factor for the disease outcome (Shanahan et al. 2001 (6)). Infliximab (also called cA2) is a chimeric monoclonal antibody showing binding site for $\text{TNF}\alpha$ of mouse origin and the remaining 75% of the antibody deriving from a human IgG1 antibody sequence. Infliximab neutralises the biological effects of $\text{TNF}\alpha$ by binding with high affinity and specificity to a soluble forms of $\text{TNF}\alpha$ inhibiting binding of the cytokine with its receptors and clearing $\text{TNF}\alpha$ from the circulation (Knight et al. 1993 (7)). Clinical improvement of approximately two third of patients with active Crohn's disease treated with a single infusion of Infliximab has been reported (Targan S et al, 1997 (8)). Disease localization and quantification are crucial for prognostic purposes and therapy management. From a diagnostic point of view, it is possible to evaluate the presence of the disease by standard radiological techniques without quantification of the disease activity. Endoscopic studies can be used to image the large bowel and the last small bowel loop, but sometimes inflammation could limit the instrument progression. $^{99\text{m}}\text{Tc}$ and ^{111}In labelled

leukocyte scans (WBC) have a well established clinical role in the diagnosis and follow-up of CD (Annovazzi A et al, 2005 (9, 10), however the complex leukocyte labelling technique involves manipulation of patient's blood ex-vivo prior to re-injection. In addition this technique allows to visualise only areas of the bowel characterised by acute inflammation, while chronic inflammation, usually localises in different bowel areas and can be detected only by using specific radiopharmaceuticals like ^{99m}Tc -Interleukin-2 (Annovazzi A et al, 2003, Signore et al, 2000 (11, 12).

Aim of the present work was to label the Infliximab with Technetium-99m and to evaluate its ability to in vivo detect soluble and lymphocyte-bound $\text{TNF}\alpha$ in patients with CD. We also aimed to compare the distribution and uptake of ^{99m}Tc -Infliximab to the extent of leucocytes infiltrating the gut mucosa as evaluated by WBC scans in the same patients. Finally, we correlated the ^{99m}Tc -Infliximab uptake in the gut with therapy response to unlabelled Infliximab as to define if ^{99m}Tc -Infliximab could be a useful radiopharmaceutical for identification of CD patients responsive to biological therapies aimed to interfere with $\text{TNF}\alpha$ activity.

Materials and methods

Labelling of Infliximab and quality controls

The anti- $\text{TNF}\alpha$ antibody (Infliximab, Remicade®) was labelled using the 2-Mercapthoethanol method as described by Mather and Ellison (Mather and Ellison 1990 (13). To a solution of Infliximab at a concentration of 10 mg/mL in 0.01 M phosphate buffer saline (PBS), pH 7.4, an appropriate volume of 2-Me was added to obtain a reaction mixture with molar ratio for 2-Me/Infliximab of 2000:1. The reaction mixture was kept for 30 min at room temperature. Then, the reduced antibody was purified using a PD10 column (Sephadex G25, Pharmacia) to eliminate the excess of 2-ME using nitrogen-purged phosphate buffer saline (PBS) at pH 7.4 as mobile phase. The reduced antibody was aliquoted and stored in liquid nitrogen for future use. For labelling 7 ml of a bone scan kit (containing 25mg of methylene diphosphonic acid, MDP, 0,8 mg of SnF_2 and 0,2 mg of 2,5-dihydroxy-1,4-benzenedisulphonic acid, dipotassium salt) was added to 200 ml of reduced Infliximab (approximately 150mg). Then, 0.5–1.0 mL of ^{99m}Tc -pertechnetate eluate (15-20 mCi) was added to the solution and allowed to stand for 10 min at room temperature. All preparations were analyzed using Instant Thin Layer Chromatography (ITLC-SG) chromatographic strips (Pall Corporation) with saline for

determination of the labelling efficiency (LE). The strips were spotted with 2.5 μl of sample and eluted with saline for approximately 9 cm and cut into two parts. All parts were counted in a γ -counter to quantify the amount of protein bound, non-protein bound ($^{99\text{m}}\text{Tc-MDP}$) and free $^{99\text{m}}\text{Tc}$ activity. The characterisation of the labelled antibody was assessed by High Performance Liquid Chromatography (HPLC) using a gel-filtration column (TSK-GEL Tosohaas, Stuttgart Germany) by simultaneously monitoring of UV absorbance (at 280 nm) and radioactivity. Specific activity was evaluated by purification in PD10 column (Sephadex G25, Pharmacia) using nitrogen-purged phosphate buffer saline (PBS) at pH 7.4 as mobile phase to eliminate the excess of free $^{99\text{m}}\text{Tc-MDP}$ and free $^{99\text{m}}\text{Tc}$.

The stability of the labelled Infliximab was evaluated in human serum and saline at 37°C for 24 hours. To this purpose, 0.1 ml of $^{99\text{m}}\text{Tc-Infliximab}$ (200 μg) was incubated at 37° C with 0.9 ml of fresh human serum and of saline. The amount of antibody labelled activity was tested at different time points (1h, 2h, 4h, 8h and 24h) by ITLC using saline as mobile phase. The integrity of reduced and labelled antibody was tested by mean of sodium-dodecyl-sulfate polyacrilamide gel electrophoresis (SDS-PAGE) under non-reducing conditions. The gel was revealed by Coomassie blue dye and the activity associated to the antibody was assessed by autoradiography.

In vitro binding assay

To test the ability of $^{99\text{m}}\text{Tc}$ -labelled Infliximab to bind to lymphocyte-bound TNF α in vitro, a competitive binding assay was performed on human lymphocytes purified from peripheral blood. Induction of membrane TNF α expression was achieved by incubating lymphocytes for three days in complete RPMI medium with phytoemagglutinin (PHA) 5 $\mu\text{g/ml}$. For binding experiments 30 μl of $^{99\text{m}}\text{Tc-Infliximab}$ at increasing concentrations (from 5×10^{-12} to 1×10^{-8} M) were incubated in triplicate with 4×10^5 lymphocytes (50 μl) alone or in presence of a molar excess of the unlabelled antibody (20 μl , 10^{-6} M) to saturate specific binding sites. The specific bound curve was calculated as the difference between total bound and non-specific bound curve. Binding affinity constant (Kd) was calculated using a specific software (Graph Pad prism).

Biodistribution in mice

50 μCi of $^{99\text{m}}\text{Tc-Infliximab}$ (0.6 μg protein) was intravenously injected in 9 normal NMRI mice. Groups of 3 mice were sacrificed at different time points after antibody injection (1, 4 and 24h). Major organs and tissues were removed and counted for radioactivity (blood, lungs,

heart, liver, spleen, stomach, kidneys, muscle, small and large bowel). Samples were weighted and counted in a γ -counter and organ activity was expressed as % of injected activity (%ID) per gram of tissue.

Studies in CD patients

Ten patients affected by active Crohn's diseases of the small bowel (mainly terminal ileum) and candidates for therapy with unlabelled Infliximab have been studied. Complete blood counts, routine biochemistry and C-reactive protein (CRP) as marker of inflammation have been measured. After the scintigraphic studies immunotherapy with unlabelled Infliximab was performed in 3 patients independently by the results of ^{99m}Tc -Infliximab scintigraphy. Three patients did not perform the immunotherapy for the presence of stenosis treated surgically by intestinal resection, 4 patients were instead treated with steroids. In order to test the best time for scintigraphic imaging, planar anterior images of the abdomen were acquired in the first two patients at 1hr, 3hrs, 6hrs and 20hrs after i.v. injection of 10-12 mCi of ^{99m}Tc -Infliximab (135-165 μg of protein). All other patients were imaged only at 6 hrs and 20 hrs because of the results obtained in the first 2 patients. All patients also performed a scintigraphy with ^{99m}Tc -HMPAO-labelled WBC, as gold standard technique (9), within 1 week from Infliximab scintigraphy. All patients gave their written informed consent for participating to the study. The study was approved by the local ethical committee.

Results

Labelling of Infliximab and quality controls

The modifications occurred on the antibody during reduction using 2-ME were assessed by High Performance Liquid Chromatography (HPLC). The HPLC chromatogram showed a single peak with retention time between 7.117-7.207 min both before and after 2-ME reduction (Figure 1, A and B). A molar ratio of 2000:1 (2-ME/MoAb) was chosen as the minimum reducing condition tested to provide a labelling efficiency higher than 97%, thus avoiding the need for antibody purification from unbound ^{99m}Tc -Technetium. Using this reducing ratio, a reproducible LE of $98.2 \pm 0.8\%$ and a specific activity of $75 \pm 15 \mu\text{Ci}/\mu\text{g}$ Ab has been obtained. Radiochemical purity was assessed by ITLC-SG using saline as mobile phase. Radioactivity bound to antibody remained at the origin, whereas free pertechnetate and ^{99m}Tc -MDP migrated with the solvent front because the different Rf. ^{99m}Tc -Infliximab Rf = 0.0, ^{99m}Tc -MDP Rf = 0.9-1.0 and free $^{99m}\text{TcO}_4^-$ Rf = 0.9-1.0.

HPLC profile of ^{99m}Tc -Infliximab showed one peak with 7.262 as retention time and the higher peak of radioactivity on radiogram profile corresponding to the radiolabelled antibody with retention time of 7.262 and the lower peak associated to the ^{99m}Tc -MDP with retention time of 10.383 (Figure 1, C). The labelled Infliximab remained substantially stable for the first 8 hours after preparation both in human serum and in saline at 37°C, as measured by ITLC chromatography (Figure 2). After this time point the percentage of radioactivity associated with Infliximab still remained over 95%.

In vitro binding assay

Results of competitive binding studies showed that ^{99m}Tc -Infliximab was able to bind $\text{TNF}\alpha$ receptors expressed on PHA-activated T-lymphocytes with a K_d of 4.67×10^{-10} M, similar to that of the native antibody (Figure 3).

Biodistribution in mice

The study of the biodistribution and clearance of the ^{99m}Tc -Infliximab performed in 9 normal NMRI mice revealed for ^{99m}Tc -Infliximab a mixed hepatic/renal metabolism and a slow blood clearance like for other monoclonal antibodies (Figure 4) and negligible accumulation leveling the gut over a period of 24 hrs.

Studies in CD patients

No adverse reactions have been observed in all patients studied with ^{99m}Tc -Infliximab. Images obtained immediately following injection of ^{99m}Tc -Infliximab showed activity in the vascular compartment and early renal activity. Best imaging times showing the lowest blood pool activity were obtained at 6h and 20h after injection of ^{99m}Tc -Infliximab (Figure 5). Overall a detectable ^{99m}Tc -Infliximab bowel uptake was found in 6 out of 10 patients, as shown in table 1. An non-specific accumulation of ^{99m}Tc -Infliximab in the right colon has been observed in one patient at 20 hrs, possibly related to antibody bowel excretion. The remaining 5 positive patients showed uptake of ^{99m}Tc -Infliximab in the terminal ileum or in other ileal loops.

On the contrary, 8 out of 10 patients were positive at WBC scan and mainly in correspondence of terminal ileum. It is interesting to notice that only 4 patients were positive to both scans but only 3 were positive in the same area (concordant) and 1 was positive in different bowel regions to different scans (discordant).

In all cases the positivity to ^{99m}Tc -Infliximab scan was much weaker than the positivity to ^{99m}Tc -WBC scan (Figures 6, 7, 8).

The 3 patients that received immunotherapy with Infliximab were 2 negatives to ^{99m}Tc -Infliximab scan but positive to ^{99m}Tc -WBC and 1 positive to both scans. All these 3 patients had clinical benefit from therapy (2 complete remission, 1 partial remission), (table 1).

Discussion

Results of this study suggest that Infliximab can be easily labeled with ^{99m}Tc , by a controlled reduction with 2-ME, with high labelling efficiency (>95%) and high specific activity (75 $\mu\text{Ci}/\mu\text{g}$) obtaining a stable product, as showed by HPLC investigation. Labelled antibody showed to retain high stability in serum and saline at 37° C during the following 24 hours. The reduction and radio-labelling of Infliximab showed no influence to its binding properties for TNF α as documented by in vitro binding receptor assay on PHA-activated lymphocytes and as confirmed by the SDS-PAGE analysis with any modification in the structure of the antibody. The biodistribution of ^{99m}Tc -Infliximab, reflects those of other labelled monoclonal antibody (14), with a slow blood clearance and a significant uptake in the liver and kidneys. In one patient, a significant radiopharmaceutical uptake in the colon at 20h and not present in early acquisitions have been documented. This pattern is possibly due to non-specific bowel excretion of the radiopharmaceutical as demonstrated for other labelled antibodies. Nevertheless, the possibility of a specific ^{99m}Tc -Infliximab targeting can not be ruled out, also considering that no significant colonic accumulation has been observed in biodistribution studies in mice. In vivo targeting studies in patients affected by active Crohn's disease have been performed to evaluate the presence of TNF α expression in the small bowel of patient selected for immunotherapy with unlabelled Infliximab. Despite the disease activity documented by endoscopy and elevated CDAI values, a significant ileal ^{99m}Tc -Infliximab accumulation was observed only in 5 patients, whereas a significant uptake of radiolabelled WBC was detected 8 out 10 patients. Very few patients show concordant positivity to both scans and, out of the 3 patients treated with unlabelled Infliximab, only one had a positive ^{99m}Tc -Infliximab scan, despite all of them had a clinical benefit from therapy. Another consideration that must be made is that the degree of ^{99m}Tc -Infliximab uptake in the bowel was always very weak and very low if compared to that observed in joints from patients affected by Rheumatoid Arthritis (15, 16). Different argumentations could be postulated to explain this aspect. A very low TNF α level in inflamed gut or limited sensitivity of ^{99m}Tc -

Infliximab to detect TNF α in the bowel due to a low antibody extravasation, as described for labelled anti-granulocyte antibodies (17). Assuming this possibility, a potential difficulty to reach the target should be considered also for the unlabelled antibody, although the higher amount used for therapeutic purpose as compared to those used for scintigraphy (100 mg vs 200 mg) can limit this phenomenon. On the other hand, the low uptake of labelled Infliximab in this set of patients could be caused by the previous use of steroids and/or other immunosuppressant therapies, that although without significant clinical effects, could potentially led to a down-regulation of TNF α bowel expression. Nevertheless, therapy with cold Infliximab in all patients that received it resulted in clinical remission. Another important information obtained from the study is that ^{99m}Tc -HMPAO-WBC can not be proposed for patient selection, since areas infiltrated by granulocytes are not necessarily those characterized by high TNF α levels. Our results suggest that caution should be used in selecting patients with CD for therapy by ^{99m}Tc -Infliximab scintigraphy and more studies are necessary to clarify the mechanism of action of anti-TNF α monoclonal antibodies, whose efficacy on symptoms relief can be related to a peripheral blocking of TNF α rather than to TNF α down-regulation in the bowel.

References

1. Baert FJ, D'Haens GR, Peeters M, Hiele MI, Schaible TF, Shealy D, et al. Tumour necrosis factor alpha antibody (infliximab) therapy profoundly down-regulates the inflammation in Crohn's ileocolitis. *Gastroenterology* 1999; 116:22-8.
2. Panes J. Adhesion molecules: their role in physiopathology and treatment of inflammatory bowel disease. *Gastroenterol Hepatol*. 1999; 22:514-524.
3. Papadakis KA, Targan SR. Role of cytokines in the pathogenesis of inflammatory bowel disease. *Annu RevMed* 2000; 51:289-298.
4. Guy-Grand D, Di Santo JP, Hencholz P, Malassis-Seris M, Vassalli P. Small bowel enteropathy: role of intraepithelial lymphocytes and of cytokines (IL-12, IFN γ , TNF α) in the induction of epithelial cell death and renewal. *Eur J Immunol* 1998; 28:730-744.
5. Yang SK, Eckemann L, Panja A, Kagnoff MF. Differential and regulated expression of C-X-C, C-C, and C-chemokines by human colon epithelial cells. *Gastroenterology* 1997; 113:1214-1223.
6. Shanahan F. Crohn's disease. *Lancet* 2002; 359:62-69.

7. Knight DM, Trinh H, Le J, Siegel S, Shealy D, McDonough M, Scallon B, et al.: Construction and initial characterization of a mouse-human chimeric anti-TNF antibody. *Molec Immunol* 1993; 30:1443-1453.
8. Targan S, Hanauer S, van Deventer SJH, Mayer L, Present DH, Braakman T, et al. A short-term study of chimeric monoclonal antibody cA2 to tumor necrosis factor- α for Crohn's disease. Crohn's disease cA2 Study Group. *N Engl J Med* 1997; 337:1029-1035.
9. Annovazzi A, Bagni B, Burrioni L, D'Alessandria C, Signore A. Nuclear medicine imaging of inflammatory/infective disorders of the abdomen. *Nucl Med Commun* 2005; 26:657-664
10. Signore A, Chianelli M, D'Alessandria C, Annovazzi A. Receptor targeting agents for imaging inflammation/infection: where are we now? *Q J Nucl Med Mol Imaging*. 2006; 50:236-242.
11. Annovazzi A, Biancone L, Caviglia R, Chianelli M, Capriotti G, Mather SJ, et al. ^{99m}Tc -interleukin-2 and ^{99m}Tc -HMPAO granulocyte scintigraphy in patients with inactive Crohn's disease. *Eur J Nucl Med Mol Imaging* 2003; 30:374-382.
12. Signore A, Chianelli M, Annovazzi A, Bonanno E, Spagnoli L, Pozzilli P, et al. ^{123}I -Interleukin-2 scintigraphy for the in vivo assessment of intestinal mononuclear cell infiltration in Chron's disease. *J Nucl Med* 2000; 41:242-249.
13. Mather S.J. and Ellison D. Reduction mediated technetium-99m labeling of monoclonal antibody. *J Nucl Med* 1990; 31:692-697.
14. Chianelli M, Parisella MG, D'Alessandria C, Corsetti F, Scopinaro F, Signore A. The developing role of peptide radiopharmaceuticals in the study of chronic inflammation: new techniques for novel therapeutic options. *Q J Nucl Med*. 2003; 47:256-269.
15. Conti F, Priori R, Chimenti MS, Coari G, Annovazzi A, Valesini G, Signore A. Successful treatment with intraarticular Infliximab for resistant knee monoarthritis in a patient with spondylarthropathy. *Arthritis & Rheumatism* 2005; 52:1224-1226.
16. Chianelli M, D'Alessandria C, Conti F, Priori R, Valesini G, Annovazzi A, Signore A. New radiopharmaceuticals for imaging rheumatoid arthritis. *Q J Nucl Med Mol Imaging*. 2006; 50:217-225.
17. Kerry JE, Marshall C, Griffith PA, James MW, Scott BB. Comparison between Tc-HMPAO labelled white cells and Tc LeukoScan in the investigation of inflammatory bowel disease. *Nucl Med Commun* 2005; 26:245-251.

Figure 1: HPLC profile of the antibody before and after reduction using 2-ME (graph A and B respectively), and after labelling (graph C). The graph C also shows the radiogram presenting two peaks for ^{99m}Tc -Infliximab (retention time=7.262) and ^{99m}Tc -MDP (retention time=10.383). respectively.

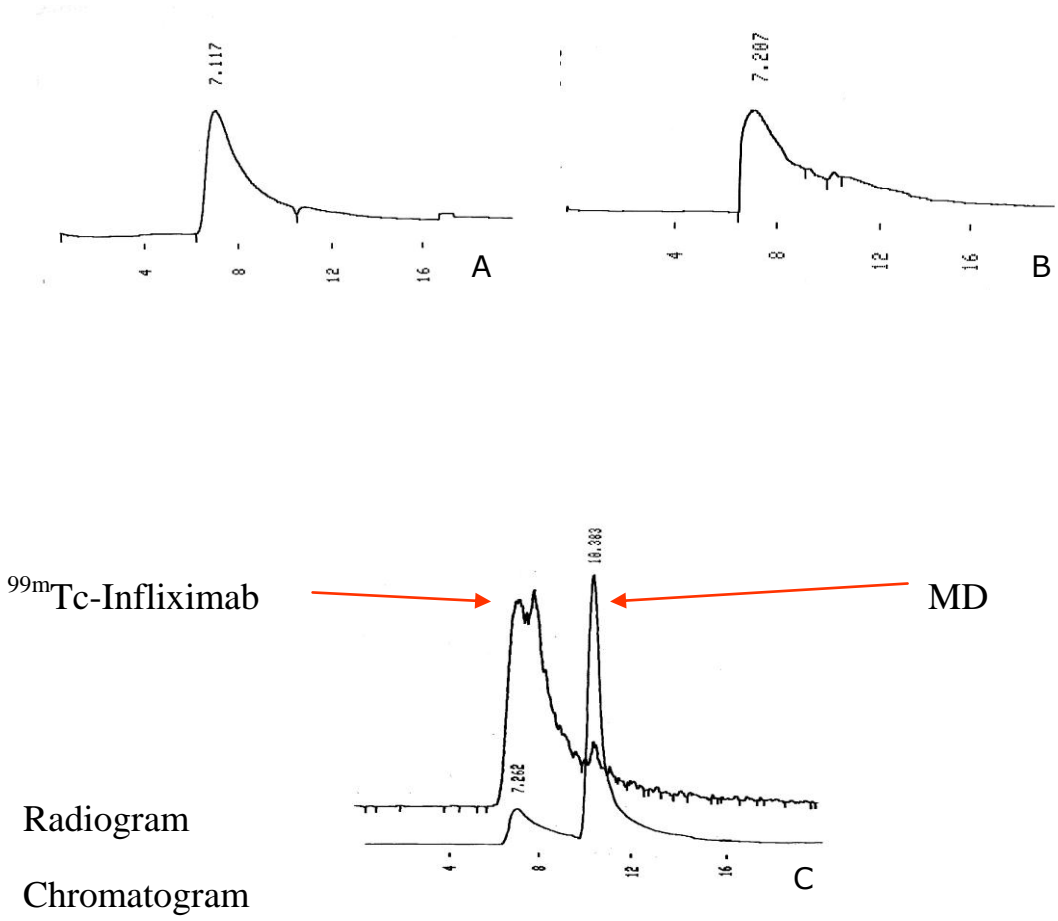


Figure 2: Stability of ^{99m}Tc -Infliximab at different time-points. The percentage of radioactivity associated with ^{99m}Tc -Infliximab slightly decreased from 98% to 87% at 24 hour.

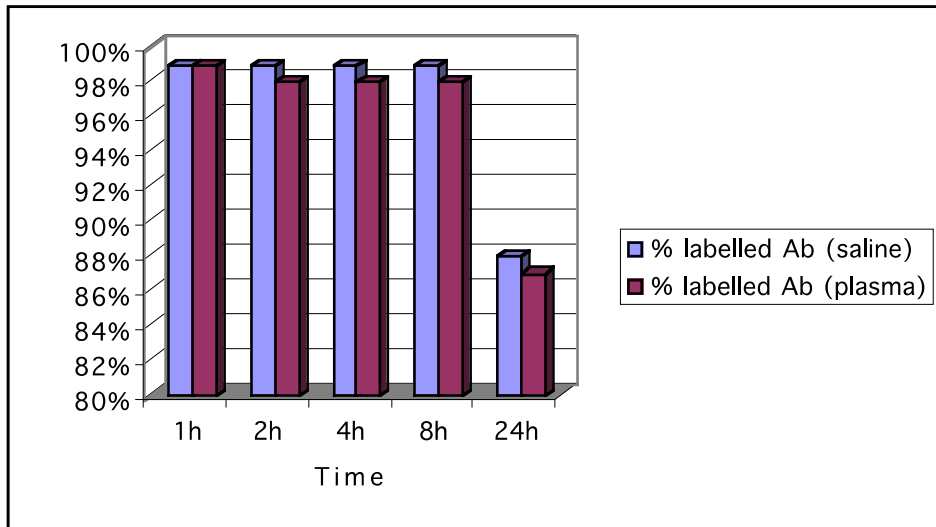


Figure 3: Competitive dose-dependent inhibition of the specific binding of ^{99m}Tc -Infliximab to PHA stimulated lymphocytes by unlabelled Infliximab.

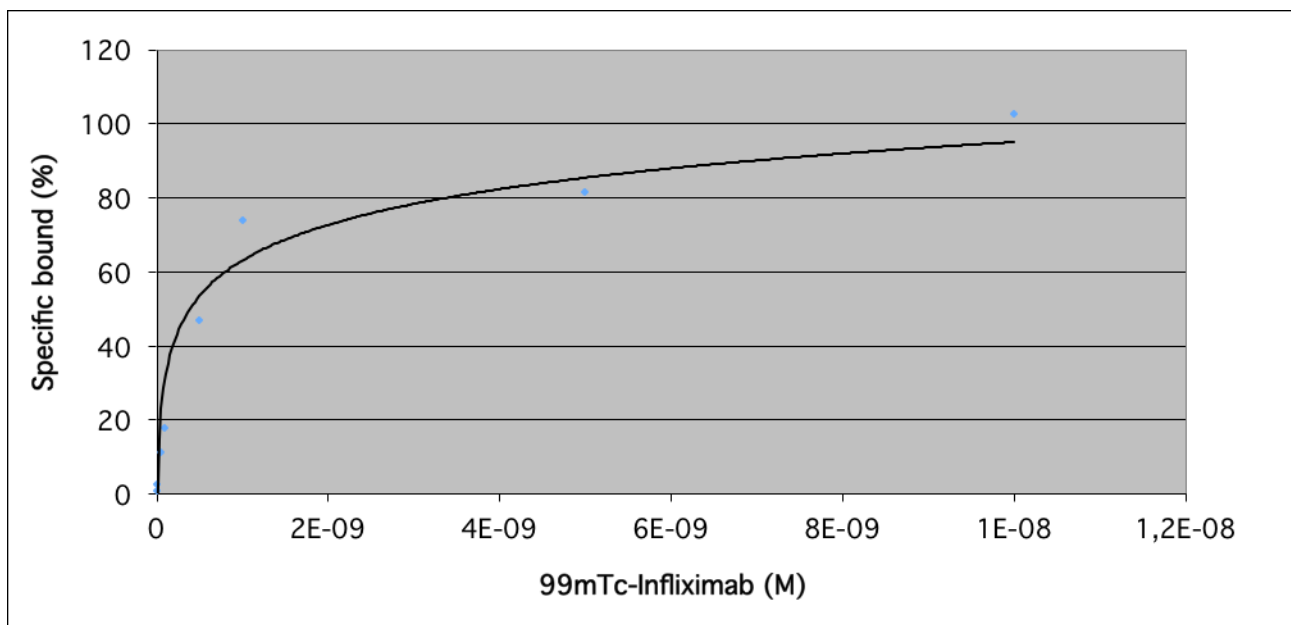


Figure 4: Evaluation of biodistribution of the ^{99m}Tc -Infliximab in NMRI mice.

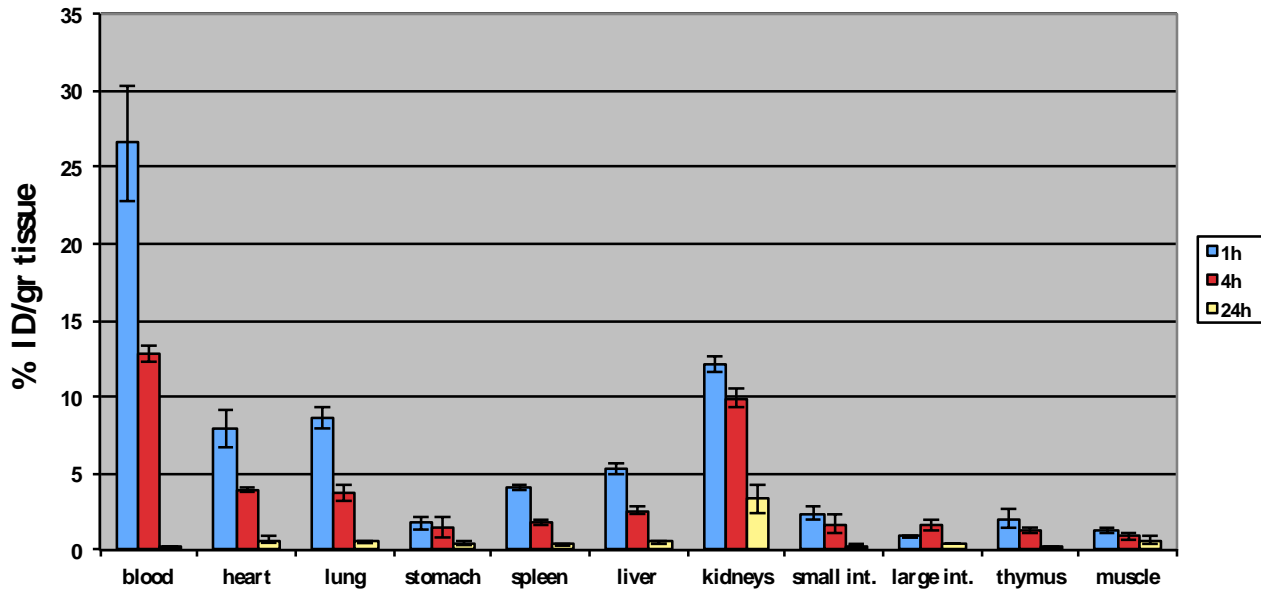


Figure 5: ^{99m}Tc -Infliximab abdominal biodistribution. Significant accumulation of the antibody are visible in the vascular compartment, kidneys and liver. No significant bowel uptake is detectable in this patient, although a faint accumulation in the small bowel can be seen at 6 hrs and in the right colon at 24 hrs. No significant accumulation of radiopharmaceutical is detectable at the level of terminal ileum with the diseased gut.

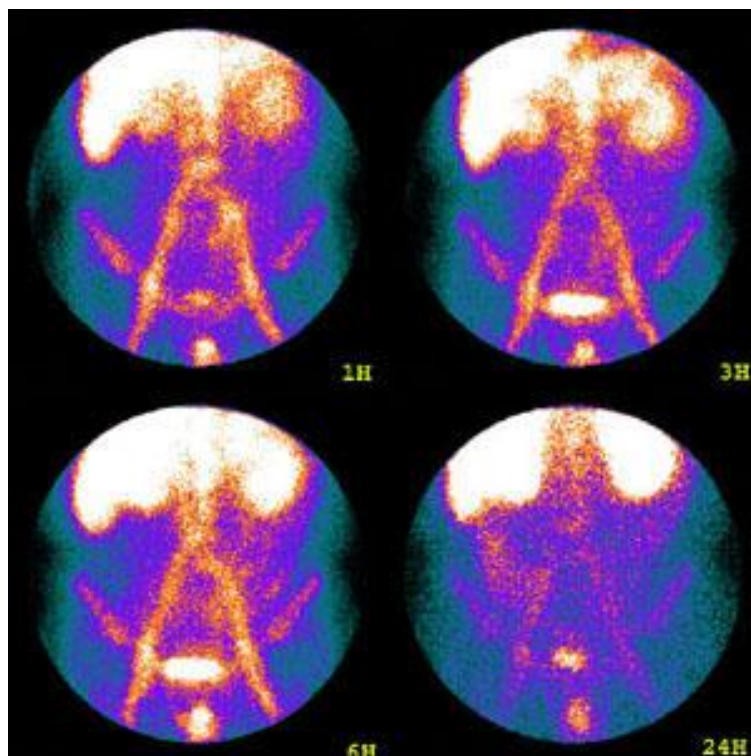


Figure 6: ^{99m}Tc -Inflimab (*right*) and ^{99m}Tc -WBC (*left*) scintigraphy. An intense uptake of labeled WBC is detectable in a small bowel loop. The ^{99m}Tc -Infliximab shows a faint uptake in the region of terminal ileum. Discordant case.

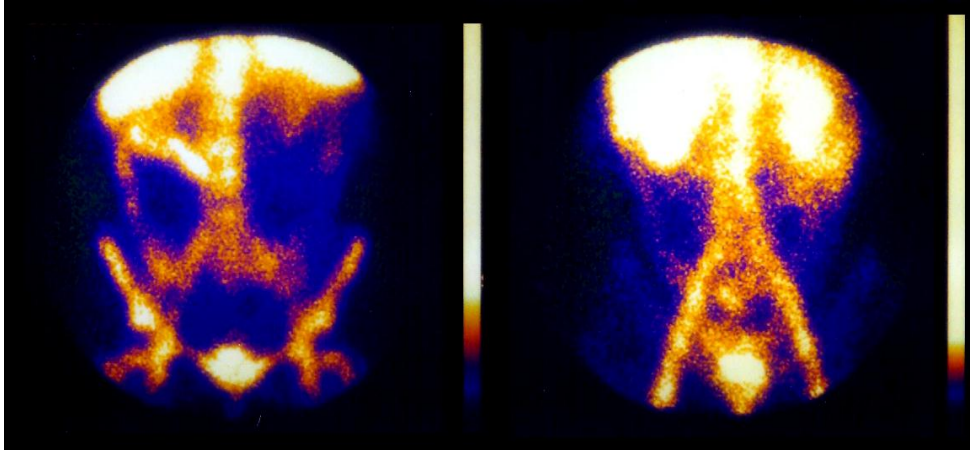


Figure 7: ^{99m}Tc -Inflimab (*right*) and ^{99m}Tc -WBC (*left*) scintigraphy. An intense uptake of labeled WBC is detectable in the terminal ileum. The ^{99m}Tc -Infliximab shows a faint uptake in the same region of terminal ileum. Concordant case.

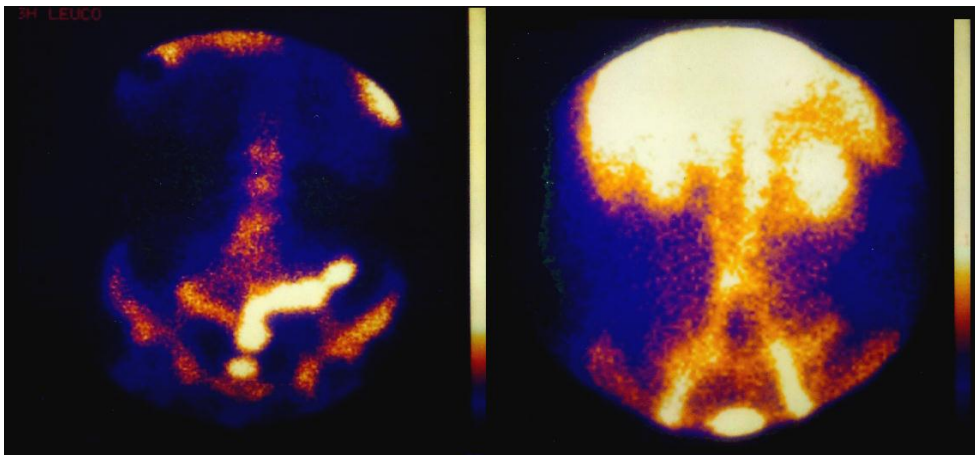


Figure 8: ^{99m}Tc -Inflimab (*right*) and ^{99m}Tc -WBC (*left*). ^{99m}Tc -WBC scan shows no abdominal uptake while a high level of activity in the transverse and left colon is detected with ^{99m}Tc -Infliximab. This patient had an ileal disease which was not detected by both scans.

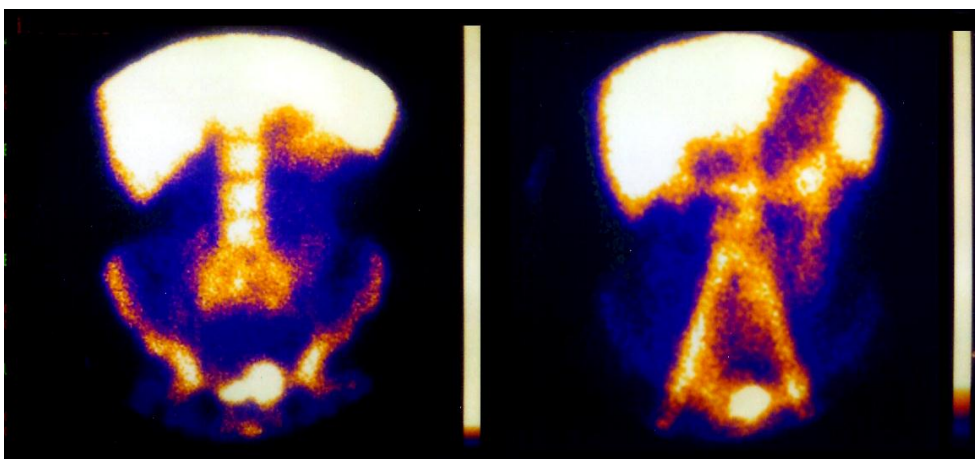


Table 1
Results of ^{99m}Tc-Infliximab and ^{99m}Tc-HMPAO-WBC scintigraphy in patients

#	TNF scan	WBC scan	Results	Therapy after scan
CA	+ terminal ileum	++ terminal ileum	concordant	Surgery
MB	+ trans & disc colon	-	discordant	Steroids
MC	-	+ terminal ileum	discordant	Remicade complete remission
PD	+ terminal ileum	++ terminal ileum	concordant	Surgery
PE	-	++ terminal ileum	discordant	Surgery
PF	-	+ terminal ileum	discordant	Remicade partial response
RG	+ terminal ileum	+ ileum	discordant	Steroids
SI	-	+ ileum	discordant	Steroids
TL	+ ileum	-	discordant	Steroids
NG	+ ileum	+ ileum	concordant	Remicade complete remission



Picture by Francesca Maccioni 2012
Sunset from the dining room window (F)

Chapter 7

Imaging of Cell Trafficking in Crohn's Disease

Andor W.J.M. Glaudemans¹, Francesca Maccioni², Luigi Mansi³, Rudi A.J.O. Dierckx¹, Alberto Signore^{1,4}

J Cell Physiol. 2010;223:562–571

¹*Department of Nuclear Medicine and Molecular Imaging, University Medical Center Groningen, Groningen, the Netherlands*

²*Department of Radiological Sciences, "Sapienza" University, 1st Faculty of Medicine, Rome, Italy*

³*Nuclear Medicine Department, 2nd University of Naples, Naples, Italy*

⁴*Nuclear Medicine Unit, "Sapienza" University, 2nd Faculty of Medicine, Rome, Italy*

Abstract

Inflammatory bowel diseases are represented by ulcerative colitis and Crohn's disease, both consisting of a chronic, uncontrolled inflammation of the intestinal mucosa of any part of the gastrointestinal tract with patchy or continuous inflammation. Ileo-colonoscopy is considered the current gold standard imaging technique for the diagnosis. However, as the majority of patients need a long-term follow-up it would be ideal to rely on a non-invasive technique with good compliance. This review focuses on nuclear medicine imaging techniques in Crohn's disease. Different scintigraphic methods of imaging cells involved in the pathogenesis are described. The radiopharmaceuticals can be divided into non-specific radiopharmaceuticals for inflammation and specific radiopharmaceuticals that directly image lymphocytes involved in the process. This non-invasive molecular imaging approach can be useful also because it images the small bowel or other areas - where colonoscopy is not useful - and that it may play a role for constant follow-up, because relapses are frequent. Finally, an update on other imaging modalities, and particularly MRI, in the evaluation of Crohn's disease activity, is provided. Although MRI cannot directly detect inflammatory cells, it has shown a high sensitivity in detecting the macroscopic signs of inflammation at the level of the intestinal wall affected by Crohn's disease and Ulcerative colitis. The current diagnostic value of MRI in the detection of inflamed bowel segment and in the assessment of CD activity, as well the potentials MR spectroscopy, MR diffusion imaging and MR molecular imaging, is briefly discussed.

Introduction

Inflammatory bowel disease (IBD) is represented mainly by two disorders: ulcerative colitis (UC) and Crohn's disease (CD). The hallmark of both diseases is a chronic, uncontrolled inflammation of the intestinal mucosa, which can affect any part of the gastro-intestinal tract. They have common symptoms that may vary from diarrhea, abdominal pain and vomiting to other disorders that can affect other parts of the body; in some cases they may involve the whole gastrointestinal tract with patchy or continuous areas of inflammation. IBD is a chronic disease without a medical cure, and requires commonly a lifetime of care. It can cause significant morbidity, but is generally not associated with increased mortality (Andres and Friedman, 1999).

The incidence of IBD is very high, where as many as 1.4 million persons in the United States and 2.2 million persons in Europe suffer from these diseases. In these high-incidence areas, the incidence and prevalence are beginning to stabilize, but in low-incidence areas such as southern Europe, Asia and the developing world they continue to rise (Loftus, 2004).

Both UC and CD are believed to be caused by a complex interaction of environmental, genetic, immunoregulatory and inflammatory factors, but their precise etiology is still under. Different theories emphasize different aspects of the same overall process in which UC and CD are not able to downregulate inflammatory responses to commensal bacteria that leads to chronic inflammation and eventually to an abnormal mucosal immune response. A key role is played by the infiltration and activation of leukocytes, macrophages and T-cells. These cells and other molecular markers in the process such as chemokines, cytokines or receptors of the immune response system can be used as markers for scintigraphic imaging. Diagnosis is based on the presence of architectural distortion (e.g., transmural or superficial patchy granulomatous infiltration) and/or acute inflammatory cells. However, chronic inflammation without any diagnostic abnormality can also be a feature of the normal gut (Hanauer, 2006). Key features of UC include diffuse mucosal inflammation that extends proximally

from the rectum to a varying degree. CD is characterized by aggregation of macrophages that frequently form non-caseating granulomas. Involvement of the terminal ileum is most common, but any site of the gastro-intestinal tract may be affected.

CD may be patchy and segmental; the inflammation in CD is typically transmural (Xavier and Podolsky, 2007). Colonoscopy and small bowel follow through are considered by most the

current gold standard imaging techniques for the diagnosis of IBD. As the majority of patients need a long-term follow-up it would be ideal to rely on a non-invasive technique with good compliance. For this purpose, ultrasound, computed tomography (CT) and magnetic resonance imaging (MRI) are more applied but also a lot of radiopharmaceuticals have been proposed for diagnostic and follow-up purposes.

In this review, we will focus mainly on the scintigraphic imaging techniques of different cells involved in the pathogenesis of CD. This can be useful in three different ways:

- (1) it is a non-invasive procedure;
- (2) imaging the small bowel or other areas—where colonoscopy cannot be useful—is possible; and
- (3) it may play a role for constant follow-up, because relapses are frequent and more comfortable techniques are needed. An overview of the results of the different nuclear imaging techniques is given.

Finally, we will report and discuss most recent data on the diagnostic capability of MRI in the detection and quantification of bowel wall inflammation in CD. Similarly to nuclear medicine imaging, MRI is non-invasive radiation-free modality that can be used in severely active disease without any concern; furthermore, it can be safely repeated in short intervals of time to monitor the effects of therapy. MRI future perspectives will be briefly described.

Immune Response and Inflammatory Pathways in CD

The aggregate effect of genetic, environmental, and other processes is the sustained activation of mucosal immune responses. Alterations in and inappropriate mucosal immune responses to antigens within the gut lumen, including the resident bacterial flora, are central to the pathogenesis of CD. An increased number of T-lymphocytes and macrophages within the gut lumen is a feature of CD and most of these cells are activated (Fiocchi, 1998). The mucosa of patients with CD is dominated by CD4⁺ lymphocytes with a type 1 helper-T-cell (Th1) phenotype (Podolsky, 2002). A cellular-mediated immune response driven by cytokines secreted by Th1 is observed, with release of interleukin 2 (IL2), interleukin 8 (IL8), interleukin 12 (IL12), interferon- γ (IFN- γ), interleukin 18 (IL18), and tumor necrosis factor- α (TNF- α) by intestinal lamina propria mononuclear cells (Gratz et al., 2001; Podolsky, 2002; Annovazzi et al., 2003). The activation of central immune cell populations is accompanied by the production of a wide variety of non-specific mediators of inflammation, which includes many other cytokines, chemokines, and growth factors. These mediators enhance the inflammatory

process itself and tissue destruction, eventually leading to the clinical manifestations of disease (Fiocchi, 1998).

In this article, the radiopharmaceuticals that have been used for imaging CD are described. This varies from a "general, nonspecific" radiopharmaceutical for inflammation (radiolabeled white blood cells, IgG-imaging, monoclonal antibody-imaging, ^{18}F -FDG,) to radiopharmaceuticals specific for a certain cytokine or chemokines involved in the pathophysiology of CD (IL2-imaging, TNF α -imaging, imaging E-selectin, etc.).

White Blood Cell (WBC) Imaging ($^{99\text{m}}\text{Tc}$ -HMPAO and ^{111}In -oxine)

Scintigraphy with $^{99\text{m}}\text{Tc}$ -hexamethylpropyleneamine oxine ($^{99\text{m}}\text{Tc}$ -HMPAO) is widely used to investigate the blood flow in the brain and heart. Coupled to autologous white blood cells, it is used for imaging of different causes of inflammation. Studies also showed promising results for the diagnosis of CD. Because of the accumulation of WBC in inflamed areas, it is possible to perform a scintigraphy to detect the presence of CD.

Several large studies have been performed to evaluate $^{99\text{m}}\text{Tc}$ - HMPAO leukocyte scintigraphy for the assessment of disease activity and extent in CD. High sensitivity and specificity values were reported (Li et al., 1992; Papos et al., 1993; Sciarretta et al., 1993; Arndt et al., 1997). Some discussion has been raised about the best imaging time. Overall tendency is a high sensitivity and specificity if imaging is performed within 3 h. Moreover, scanning after 1 and 3 h may be helpful as the pathologic accumulation in actively inflamed segments becomes more pronounced (Arndt et al., 1997). On the other hand, high rate of false-positive findings after 3 h can be found, as a result of the presence of a physiological intestinal inflammation and the excretion of $^{99\text{m}}\text{Tc}$ -HMPAO into the bowel. Aydin et al. defined the usefulness of labeled WBC scintigraphy at three different time points (after 1, 2, and 4 h). They recommend 2 h scintigraphic imaging because it provides the best uptake values and decreases the number of false-positive results (Aydin et al., 2008).

In children, WBC-labeled scintigraphy is a useful tool in the diagnosis and therapeutic strategy of CD, and provides information on the presence, the intensity, and the extent of the disease, particularly in the terminal ileum. However, it may not replace colonoscopy with biopsies for diagnosis confirmation.

Its reliability seems higher than that of ultrasonography (US) (Alberini et al., 2001).

Compared with spiral CT, both labeled WBC scintigraphy and CT are valuable non-invasive diagnostic methods in cases involving severe, active CD. WBC scintigraphy seems better for

the detection of segmental inflammatory activity, whereas CT displayed excellent suitability for the recognition of complications such as abscesses and fistula (Molnar et al., 2001).

Post-operative recurrence after ileo-colonic resection is a feature of CD, almost 73% of patients show endoscopic recurrence at 1 year and 90% at 3 years. After surgical resection for CD, symptoms may be related to the surgical resection itself. The development of an early severe endoscopic recurrence within 1 year represents a risk factor for early clinical recurrence. Early detection and assessment of asymptomatic endoscopic recurrence may allow a timely and appropriate treatment of CD patients after ileo-colonic resection. To address this issue, ^{99m}Tc -HMPAO-labeled WBC scintigraphy was performed 6 and 12 months after operation, with recurrence assessed by colonoscopy within 2 weeks.

Scintigraphic images acquired after 3 h show a low specificity in detecting CD recurrence both at 6 and 12 months, whereas imaged at 30 min show a high sensitivity. Because of the high frequency of false-positive findings, scintigraphy with labeled WBC is not recommended as a non-invasive technique alternative to endoscopy for assessing CD recurrence (Biancone et al., 1997).

WBC can also be labeled with ^{111}In -oxine for inflammatory diseases. This has been used extensively in the past. For the assessment of the presence and location of active inflammation in patients with IBD, ^{111}In -labeled WBC has been shown suitable (Froelich and Field, 1988). Also, *ex vivo* measurement of the excretion of ^{111}In -radioactivity in stools collected from 24 h to 4 days after reinjection the labeled cells proved to be a reliable measurement of the degree of inflammation (Saverymuttu et al., 1983). A direct prospective comparative study between WBC labeled with ^{99m}Tc -HMPAO and with ^{111}In -oxine showed superior results for WBC labeled with ^{99m}Tc -HMPAO in the assessment of active disease, especially for small bowel segments (Arndt et al., 1993). Other reasons for using ^{99m}Tc -HMPAO instead of ^{111}In -oxine are the availability of ^{99m}Tc on daily basis, less radiation burden to the patient, a simpler and less time-consuming preparation and earlier imaging possibilities (as a result of the shorter half-life of ^{99m}Tc compared with ^{111}In).

So, overall agreement is that scintigraphy using radiolabeled leukocytes is a useful technique for assessing intestinal infiltration in CD. However, limits of planar images include overlapping activity in other organs (including the liver, spleen, bone marrow, and bladder) and as a result low specificity. Single photon emission computerized tomography (SPECT) is an imaging technique that provides three-dimensional (3D) distribution of the counts and cross-sectional images of a 3D object in multiple plans, including transaxial sections. This technique showed usefulness for assessing the blood flow in the brain and heart, but only

very few studies investigated this technique in CD. One study compared SPECT images (after 2 h) with the planar images (after 30 min and 2 h). Both planar and SPECT images were comparable in terms of detecting the presence of an active inflammation in patients with a known diagnosis of IBD (19 CD and 2 UC), but SPECT images showed a higher uptake and provided a more detailed visualization of CD lesions than planar images. This technique may better

discriminate between intestinal and bone marrow uptake, thus being useful for assessing CD lesions within the pelvis, including perianal disease (Biancone et al., 2005).

WBC labeling has numerous limitations. As mentioned above, problems related to this technique include the presence of a physiological intestinal inflammation, the excretion of ^{99m}Tc -HMPAO into the bowel, and the shedding of labeled cells into the bowel lumen (Biancone et al., 2005). Using this noninvasive technique, active CD in both the small and the large bowel can be visualized. However, stenosis, fistulas, and malignancies cannot be easily detected (Stathaki et al., 2008).

Another problem is that positive WBC scans only occur when the disease is active and not when it is quiescent or only mild active. It is therefore important to have appropriate referral criteria to optimize the clinical and cost effectiveness of the procedure. C-reactive protein (CRP) can be useful for this, as it is the most sensitive marker, but not sensitive enough to be useful as the only referral indicator. Moreover, the threshold values that were used in different studies for CRP had an appreciable effect on the sensitivity of the test. But it may prove a useful strategy for rationalizing the requests with minimal consequence on clinical management (Kerry et al., 2003).

The erythrocyte sedimentation rate (ESR) may be a predictor of the anatomic distribution of inflammation, in which the ESR appeared to correlate well with activity in cases of predominantly colonic diseases but not in cases of inflammation limited to the small bowel (Sachar et al., 1990). ^{99m}Tc -WBC scintigraphy, ESR and WBC counts are good indicators of the inflammatory activity in CD if the inflammation is limited to the large bowel. There is a trend towards an inverse relationship when the inflammation is limited to the small bowel; thus, scintigraphy using the aforementioned markers may be of limited value when CD is only present in the small bowel (Charron, 2003).

Furthermore, the labeling of autologous WBC itself has limitations that include a complex labeling process requiring specialized facilities, a labor-intensive labeling process involving the handling of blood products, the additional risk of administration of the labeled blood cells to the wrong patient and high costs (Kerry et al., 2005). As a consequence, many centers find

it difficult to offer this as a routine procedure, and only a limited number of cases can be performed each day.

Antigranulocyte Monoclonal Antibody Imaging (99mTc)

For in vivo labeling, immunoscintigraphy with 99mTc labeled monoclonal anti-granulocyte antibodies (AGAb) is used. This does not require leukocyte isolation. AGAb is stored as cold kits and can selectively label granulocytes, involved in the inflammation process. The monoclonal antibody binds to an antigen expressed on the granulocytes, independently from maturation stage of the cells. The labeling time is short (approximately 15 min), and images are obtained at 2—6 and 24 h after injection. The results, however, are rather disappointing. A prospective study comparing the value of 99mTc-AGAb with that of labeled WBC with 99mTc-HMPAO showed that WBCscintigraphy was superior in cases with small bowel involvement, and similar results in cases with large bowel involvement (Papos et al., 1996). A larger study, only with 99mTc-AGAb, revealed 44 bowel segments with increases activity, where no underlying bowel inflammation could be verified.

These activities were regarded as aspecific activity and decreased the reliability of the imaging method (Gyorke et al., 2000). A study in children in young adolescents showed that immunoscintigraphy is a highly sensitive detector of intestinal inflammation and can be useful for reducing diagnostic delay.

However, its specificity was also low in this study and all positive cases must be confirmed histologically (Bruno et al., 2002). In contrast to these results, Neurath et al. (2002) scanned 59 patients with 99mTc-AGAb and found in CD patients an excellent specificity (100%) but only a very low sensitivity (41%) compared with other imaging techniques.

An alternative technique uses only a Fab' fragment of an antigranulocyte murine monoclonal antibody (sulesomab) labeled to 99mTc, the LeukoScan_. Delivered as a single injection technique it removes the need for handling blood and the complex separation and labeling techniques that are required for WBC imaging. A pilot study with 99mTc-LeukoScan showed very discrete activity in the bowel, but the sites did not correspond with the inflammation sites seen on WBC scintigraphy and found at endoscopy (Stokkel et al., 2002). In a prospective pediatric IBD assessment, planar imaging with 99mTc-LeukoScan did not prove very sensitive in detecting inflammation in each bowel segment (57%). SPECT imaging detected the majority inflammation sites in patients (Charron et al., 2001). A prospective trial comparing labeled WBC with 99mTc-LeukoScan demonstrated that LeukoScan located IBD, but the low specificity of 50% precluded its use for the routine

detection of this disease. LeukoScan is taken up slowly in inflammation sites of IBD and also appears in the normal bowel as physiological activity in 4 h (Kerry et al., 2005).

Overall, the antigranulocyte monoclonal antibody labeling has the advantage over WBC labeling that it does not require a complex labeling procedure and can be given to the patient in a single injection. Till now, however, the specificity for detecting CD is too low and imaging inflammation in the bowel with labeled WBC is still preferred.

Immunoglobulin Imaging (99mTc)

Another non-specific radiopharmaceutical is polyclonal human immunoglobulin (HIG), first labeled with ^{111}In and successfully used in diverse inflammatory sites (Fischman et al., 1988). The theory about the mechanism of accumulation suggest that ^{111}In - HIG accumulates in inflammatory lesions as a result of enhanced vascular permeability and subsequent entrapment of the radiolabeled protein (Oyen et al., 1992). For reasons of availability, dosimetry and image quality, ^{111}In was replaced by $^{99\text{m}}\text{Tc}$. This new agent was shown to localize both sepsis and active IBD (Buscombe et al., 1990). However, the value of HIG in IBD has been a subject of controversy. Compared with ^{111}In labeled WBC, fewer diseased segments were seen, the sensitivity and specificity were low (Arndt et al., 1992) and it performed poorly in assessing the distribution of inflammation (Hebbard et al., 1992). Compared with $^{99\text{m}}\text{Tc}$ -HMPAO labeled WBC, ^{111}In -HIG proved to be less sensitive both for the diagnosis and in the evaluation of disease extension of IBD (Mairal et al., 1995). Another major disappointment in the diagnostic value of $^{99\text{m}}\text{Tc}$ -HIG was a reported sensitivity of 33%, whereas the sensitivity of $^{99\text{m}}\text{Tc}$ -HMPAO labeled WBC was 100%. The latter also detected a larger number of affected segments and provided better image quality of the extent of disease. These authors believe that $^{99\text{m}}\text{Tc}$ -HIG is not useful in the evaluation of patients with CD, neither with the identification of location, nor the extension nor the degree of disease activity (Delgado Castro et al., 1997). On the other hand, good results were also reported. The HIG scan was reported as a sensitive study in diagnosing active IBD and in assessing the extent of the disease. Histological and endoscopic findings in cases of CD were similar to that of HIG scintigraphy, suggesting that this diagnostic strategy may have a role in the diagnostic protocol of CD (Versaci et al., 1999).

Overall, the reports about the negative results and low sensitivity of HIG (coupled to $^{99\text{m}}\text{Tc}$ or ^{111}In) were larger in number than the positive results. We think it cannot stand the results of labeled WBC.

Interleukin 2 Imaging (99mTc, 123I, 18F)

IL2 represents the first identified, fully characterized, purified human interleukin. It is a signaling molecule of the immune system that belongs to the chemokines family. It is produced mainly by Th 1 (CD4^b) lymphocytes, stimulates cell-mediated immune responses, is a growth factor and a mediator of self tolerance and therefore of important interest (Olejniczak and Kasprzak, 2008). As known, T-cell activation and macrophage activation are features of CD. In particular, activated mononuclear cells expressing IL2 receptors (IL2-Rs) and capable of binding IL2 represent a major component of gut inflammation in CD (Signore et al., 2000). Soluble IL2-R levels have been reported to reflect accurately disease activity in CD, thus suggesting that the assessment of intestinal activated mononuclear cell infiltration may help to define the lesional activity of the disease (Louis et al., 1995). 123I-IL2 has been successfully used for the assessment of celiac disease, type I diabetes mellitus and autoimmune thyroiditis. Fifteen patients with ileal CD and 10 healthy volunteers were scanned 1 h after injection of 123I-IL2 (Fig. 1). Intestinal IL2 uptake was higher in patients than in volunteers and the uptake positively correlated with the CD activity index. In the same study, six patients with active CD were studied before and after 12 weeks of steroid treatment. IL2 intestinal uptake significantly decreased in patients with CD in steroid-induced remission. IL2 scintigraphy could therefore be an objective tool for the *in vivo* assessment of intestinal activated mononuclear cell infiltration (Signore et al., 2000). Later on, a comparative study was performed between 99mTc-IL2 and WBC labeled with 99mTc-HMPAO in 29 patients with ileal and/or colonic CD in stable clinical remission to evaluate the extent of acute and chronic inflammation in the bowel. Planar and SPECT images were acquired in each patient.

Both 99mTc-IL2 and 99mTc-WBC scintigraphy provided a high negative predictive value (1.00 and 0.91, respectively) but a weak positive predictive value (0.44 and 0.39, respectively).

However, Kaplan—Meier curves generated between the scintigraphic findings and time free from disease were statistically different only for 99mTc-IL2 scintigraphy. This would conclude that 99mTc-IL2 scintigraphy is useful in selecting CD patients in clinical remission who could benefit from preventive therapy to avoid disease relapse (Annovazzi et al., 2003).

The recent development of a specific radiopharmaceutical for imaging the IL2-R on activated T-lymphocytes and monocytes can be a very important step in the non-invasive imaging in patients with CD. IL2 scintigraphy could also be useful to monitor the efficacy of therapies in a more objective way.

Right now, the production of ^{18}F -IL2 is in its final steps (in development in the centers of the authors). This would provide us a specific PET-radiopharmaceutical for imaging CD with the advantages of absolute quantification and better resolution images compared to the above-mentioned radiopharmaceuticals.

Interleukin 8 Imaging ($^{99\text{mTc}}$)

Another proinflammatory cytokine that plays an important role in the recruitment of neutrophils into the colonic mucosa is IL8. Neutrophils expressing receptors for IL8 are markedly increased in active colitis compared with the normal noninflamed bowel tissue (Murata et al., 1995). Different procedures exist for the labeling of IL8. The potential use of IL8 labeled with $^{99\text{mTc}}$ using hydrazinonicotinamide (HYNIC) as chelator was investigated to image IBD in a rabbit model of acute colitis. The results were compared with that of $^{99\text{mTc}}$ -HMPAO-labeled WBC. Both agents visualized the colitis within 1 h after injection. $^{99\text{mTc}}$ -HYNIC-IL8 images of colonic abnormalities were more accurate and the absolute uptake in the affected colon increased until 4 h after injection. Moreover, the absolute uptake in the affected colon was much higher for IL8 than for the labeled WBC. Concluded was that within 1 h of injection, visualization of the extent of colonic inflammation in vivo was possible with $^{99\text{mTc}}$ -HYNIC-IL8 (Gratz et al., 2001). Until now, no patients' study with $^{99\text{mTc}}$ -IL8 is published.

E-selectin Imaging ($^{99\text{mTc}}$, $^{111\text{In}}$)

The vascular endothelium is an active participant in inflammatory processes. The response of endothelial cells to a variety of proinflammatory stimuli includes synthesis and expression of a number of cell surface antigens. E-selectin is a glycoprotein which is expressed on the luminal surface of endothelial cells in response to proinflammatory cytokines, and plays a major role in facilitating the emigration of leucocytes into the tissues. This emigration of polymorphonuclear leukocytes from the circulation into the gut wall is one of the components of the inflammatory process in CD. E-selectin expression has been shown immunohistochemically in areas of active involvement of the gut (Koizumi et al., 1992). E-selectin therefore provides a potential target for in vivo detection and quantification of CD activity. Studies with E-selectin imaging in CD are rather exceptional. E-selectin expression in patients with UC and CD was assessed by measuring the concentration of circulating soluble E-selectin (sE-selectin), by immunohistochemistry of colonic biopsy specimens, and by

scintigraphy after injecting ^{111}In labeled Fab' fragment of a monoclonal anti-E-selectin antibody. The value of this scintigraphy was judged by comparative imaging with $^{99\text{m}}\text{Tc}$ labeled WBC. sE-selectin was elevated in patients with clinically active disease. Tissue expression of E-selectin was enhanced in patients with active inflammation, with weak or absent expression in inactive disease and healthy controls. The results of the two scans were concordant in 14 (of 17) patients with those positive for both (10/17) showing similar localization and extent. Anti-E-selectin imaging with radiolabeled monoclonal antibody identified areas of inflammation in CD and UC. The technique should prove useful clinically for identifying the site and extent of the disease (Bhatti et al., 1998).

Unfortunately, no other studies for imaging E-selectin expression in CD were published. Some groups used $^{99\text{m}}\text{Tc}$ for labeling to the anti-E-selectin Fab' fragment and were successful in other kinds of inflammation, such as rheumatoid arthritis (Jamar et al., 2002).

TNF α Imaging ($^{99\text{m}}\text{Tc}$)

In active phases of CD, an increased production and release of TNF α by macrophages and monocytes of the lamina propria has been described. To detect the presence of TNF α within the gut mucosa in patients with active CD, $^{99\text{m}}\text{Tc}$ -labeled chimeric human/mouse monoclonal antibody anti-TNF α (Infliximab) was used. A product with high labeling efficiency and stability was obtained. In vitro tests indicated that Infliximab bound to $^{99\text{m}}\text{Tc}$ retained its bounding activity to cell bound TNF α as compared with unlabeled Infliximab. Ten patients with active CD were studied and compared with labeled WBC. Unfortunately, the degree of $^{99\text{m}}\text{Tc}$ -Infliximab uptake by the inflamed bowel was much less than that seen with labeled WBC and with a different distribution. Three of these patients received Infliximab for therapeutic purposes with good clinical results despite a negative scintigraphy with $^{99\text{m}}\text{Tc}$ -Infliximab (D'Alessandria et al., 2007). No other studies were performed and the production of products to image the presence of TNF α was stopped.

^{18}F -FDG (PET) Imaging

^{18}F -fluorodeoxyglucose (^{18}F -FDG) is a well-known PET radiopharmaceutical that accumulates in malignant tissues. It can also be used at the sites of infection and inflammation and in autoimmune and granulomatous diseases by the overexpression of glucose transporter (GLUT) isotypes (mainly GLUT-1 and GLUT-3) and by an overproduction

of glycolytic enzymes in inflammatory cells. The advantage of PET radiopharmaceuticals, compared with SPECT, is that PET provides absolute quantification and a better resolution. A prospective study in 59 patients with CD compared findings on FDG-PET with ^{99m}Tc labeled antigranulocyte antibodies and found better results for FDG-PET with high sensitivity and specificity (85% and 89%, respectively). The authors suggested that FDG—PET appears to be a reliable noninvasive tool for simultaneous detection of inflamed areas in the small and large bowel of patients with CD and that it can be used to detect disease activity in the terminal ileum and colon of CD patients (Neurath et al., 2002).

Diagnosis of chronic IBD in children requires non-invasive, atraumatic diagnostic tools that depict localization and acuity of inflammation and yield only a low radiation dose. A retrospective analysis of 23 children evaluated the diagnostic potential of FDG—PET and compared it with ultrasound and colonoscopy with histology as the standard of reference. FDG—PET showed a sensitivity/specificity and accuracy of 98%, 68%, and 83% as compared with colonoscopy (90%/75% and 82%) and ultrasound (56%/92% and 75%) (Esteban et al., 2001). For the small bowel, FDG—PET was even more reliable (100%/86% and 90%). Because of this high sensitivity and accuracy, FDG—PET is an excellent, non-invasive tool in IBD, especially in children (Loffler et al., 2006).

A major disadvantage of PET-scanning is the curtailed anatomic information that it provides and makes accurate localization of lesions difficult. An integrated PET/CT scanner offers a better non-invasive tool for identifying and localizing active intestinal inflammation. In a pilot study, it was confirmed that FDG—PET/CT activity correlated well with active inflammation (as determined by colonoscopy, disease activity indices, and radiology) in both UC and CD, suggesting that this may be a non-invasive method of identifying disease activity in patients with IBD (Meisner et al., 2007). Another study assessed the use of FDG—PET/CT in evaluating the activity and location of CD along the gastrointestinal tract. It was globally well correlated to the clinical, endoscopic, and biological activity of CD with a good sensitivity for the detection of intestinal and colonic segments with moderate to severe mucosal lesions (Louis et al., 2007). Another study evaluated FDG—PET/CT in patients with IBD before and after treatment and saw that FDG uptake decreased with successful treatment of inflammation and correlated with symptom improvement (Spier et al., 2009). Despite all these recently published results for FDG—PET in the evaluation of patients with CD, we have some notes about it. In general, our experience is that in a lot of patients gradual physiological uptake in the bowel can be seen, especially in the large bowel. This may offer some problems in diagnosing CD in colonic segments. Larger, prospective studies have to be

carried out to confirm the good results for FDG—PET (and combined with CT) in CD patients. However, at this moment, FDG—PET/CT may be very useful when conventional imaging studies cannot be performed or fail to complete.

Radiological Imaging of Cell Trafficking in CD

So far, conventional radiologic imaging does not offer any direct information on “cell trafficking” in CD. However, several imaging modalities, including Doppler US, CT, and MRI, have been optimized to be able detect the main macroscopic “indirect” signs caused by “cell trafficking” and active inflammation at the level of the intestinal bowel wall affected by CD (MacKalski and Bernstein, 2006; Fidler, 2007). Thanks to the possibility of intravascular specific contrast agent for a blood enhancement either with CT, US, and MRI, all these imaging modalities can clearly detect vessel dilation, wall thickening, wall stratification with submucosa thickening, wall and mesenteric ipervasculature, lymph nodes enlargement and enhancement, all signs that have been related with increased biological or endoscopic signs of CD activity.

Increased enhancement of the bowel wall is an important finding that is invariably observed with active CD inflammation, either on gadolinium-enhancement T1-weighted MR images, as well on CT and US contrast-enhanced ones (MacKalski and Bernstein, 2006), determined by an increased wall vascularization and capillary permeability recorded in active CD lesions. Undoubtedly, the evidence of gadolinium enhancement of the diseased bowel wall is higher on MR images than on CT or US images, because of the higher intrinsic soft tissue contrast of MRI (Maccioni et al., 2005a).

A correlation between the marked gadolinium enhancement of the wall and disease activity has been found by several authors (Maccioni et al., 2000; Koh et al., 2001; Gourtsoyiannis et al., 2002; Low et al., 2002; Laghi et al., 2003; Ajaj et al., 2005; Sempere et al., 2005; Florie et al., 2006; Maccioni et al., 2005b; Rimola et al., 2009; Jasper et al., 2006). In a study performed on 28 patients, gadolinium-enhanced fat-suppressed spoiled gradient-echo sequences had a 96—100% per-patient sensitivity in comparison with 60% for unenhanced SSFSE sequences. In addition, contrast-enhanced sequences detected more abnormal segments and depicted disease severity more correctly than SSFSE sequences (Low et al., 2002). Furthermore, several studies have been carried out on the pattern of parietal Gd-enhancement, and distinguishing between a homogeneous pattern from a layered pattern to a markedly layered pattern, although a definitive correlation between enhancing patterns and the type of wall inflammation has not been established yet. Others (Sempere et al., 2005;

Florie et al., 2006) have proposed to assess CD activity by MRI analysis of Gd wash-in and wash-out curves at level bowel wall.

Other known signs produced by active CD lesions at the level of the small or large intestine detectable on Gd-enhanced images as well on CT and US images, include a marked concentric wall thickening (usually ranging between 4 and 15 mm, up to 20 mm), the increased wall enhancement, the increased local mesenteric vascularization or "comb's sign" the local lymph nodes enhancement, the presence of fistulas or abscesses enhancement. Deep ulcerations can be identified on both T2-weighted and T1-weighted contrast-enhanced images and related to active disease (Gourtsoyiannis et al., 2002, 2004).

On a recent MRI study focused to the assessment of disease activity, in comparison with endoscopic and clinical indexes (Rimola et al., 2009), ulcers were found in 65% of active lesions, similarly pseudopolyps, wall edema in 75%, whereas increased wall thickening and increased relative contrast enhancement paralleled the endoscopic severity of lesions.

An extremely important sign of activity at MRI is wall edema, which is specifically present in the submucosal layer of active intestinal lesions. Other typical findings of active CD are the serosal and the mesenteric fat inflammation, both expressions of the transmural inflammatory process, which involves all wall layers, extending to the serosa and to the fat immediately outside the intestinal wall. A high signal intensity at the level of the bowel wall and its surrounding mesenteric fat is, in fact, invariably detected in T2-weighted MR images in presence of active disease. On the other hand, a low signal wall on T2-weighted images indicates chronic or inactive CD (Maccioni et al., 2000, 2006; Maccioni, 2008; Rimola et al., 2009). Such mural and transmural intestinal edema can be clearly detected on T2-weighted images only, as a bright wall and perivisceral signal, whereas it is hardly detectable with CT or US, as well on T1-weighted MR images.

MRI has been successfully used to evaluate lesion sextent and ctivity in UC as well, by using similar imaging parameters (wall enhancement, wall thickening, etc.) already tested for CD (Maccioni et al., 2005b). In UC, however, the inflammatory process is confined within the wall, therefore producing a lower evidence of inflammation than in CD, with any imaging modality.

Several authors have used CT to characterize and quantify the inflammatory changes of the intestinal wall, similarly to MRI. In a study of 58 CT scans (Choi et al., 2003), enhancement was classified as type A (multilayered stratification of three or more layers with mucosal and serosal enhancement), type B (two layers with strong mucosal enhancement and low-density submucosa, type C (two layers without strong mucosal enhancement), and type D

(homogenous enhancement). Ninety-one percent of type A and 100% of type B enhancement patterns had evidence of active inflammation, whereas 86% of type D cases had quiescent disease.

In comparison with CT and US, however, MRI has shown a higher sensitivity in detecting most of the signs of intestinal and mesenteric inflammation in CD. With respect to CT, in fact, MRI has an intrinsic higher soft tissue contrast and sensitivity for inflammatory tissues; moreover, differently from CT and US, the signs of inflammation can be detected and analyzed by using different imaging MR parameters. T1-weighted MRI parameters are similar to contrast-enhanced CT or contrast-enhanced US, whereas others parameters are absolutely specific of MRI, such as T2-weighted one, or more recently, diffusion-imaging parameters.

In general, both T1- and T2-weighted MRI parameters have been successfully and reliably correlated with the signs of active CD (Maccioni et al., 2000, 2006; Low et al., 2002; Sempere et al., 2005; Rimola et al., 2009).

In a recently published paper (Rimola et al., 2009), MRI has been proposed as a valuable alternative to endoscopy in the evaluation of disease activity and severity of ileocolonic CD. An excellent correlation was found between several MRI parameters of active inflammation (wall thickness, wall "relative" contrast enhancement, presence of wall edema and ulcers) and the endoscopic signs of inflammation; therefore, an MRI Activity Index (MRIA index) have been suggested, well correlated with the CD Endoscopic Index of Severity (CDEIS).

Finally, the future potentials of the newest MR developments, such as spectroscopy, diffusion imaging and molecular imaging, are still unknown.

MR spectroscopy is used to measure the levels of different metabolites in body tissues. The MR signal produces a spectrum of resonances that correspond to different molecular arrangements of the isotope being "excited." The characteristics of the spectrum can be used to diagnose metabolic disorders, especially those affecting the brain as well as to provide information on tumor metabolism (Rosen, 2007; Golder, 2007).

Magnetic resonance spectroscopic imaging (MRSI) combines both spectroscopic and imaging methods to produce spatially localized spectra from a given tissue or organ (brain, prostate, etc.). The spatial resolution is much lower (limited by the available SNR), but the spectra in each voxel contains information about many metabolites. Because the available signal is used to encode spatial and spectral information, MRSI requires high SNR achievable only at higher field strengths (1.5 T and above). It cannot be excluded that with the increase availability of high field magnets (3 T) spectroscopy imaging could be applied to

study and characterize the wall molecular changes in IBD. Diffusion MRI is a MRI method that produces in vivo images of biological tissues weighted with the local microstructural characteristics of water diffusion. Diffusion-weighted MRI (DWI) expresses molecular diffusion, which is the thermally induced Brownian motion of water molecules, without administration of any contrast agent. Changes in proton self-diffusion have been recognized as an early sign of abnormal cellular homeostasis in acute ischemic stroke. Nowadays, DWI has a well-established role in the detection of early ischemic changes in the clinical practice. In body imaging, DWI is used in solid organs such as liver, pancreas, spleen, and kidney. In gastrointestinal tract imaging, DWI has not been commonly used because the image quality is degraded severely by motion artifacts related to intestinal motion. However, recently free-breathing DWI has been introduced for body evaluation, with reduction of motion artifacts. Free-breathing DWI may allow the evaluation of IBD.

In a recent paper, diffusion imaging has shown the capability to differentiate active from inactive disease, as well to perform a quantitative analysis of disease activity, although results should be considered still preliminary and to be confirmed with further investigations (Kiryu et al., 2009).

Lastly, cells can be labeled with radionuclides, with fluorescent or bioluminescent markers (optical imaging) or with MRI contrast agents, defined as molecular MRI (Cassidy and Radda, 2005). The sensitivity of MRI is low (mM concentrations) and is dependent on the volume of the sample. T1 contrast agents are usually based on paramagnetic ions or stable free radical molecules (Potter, 2002), such as the gadolinium III complexes (Aime et al., 2002) with a short circulating half-life (minutes).

T2 contrast agents produce a negative signal enhancement on T2-weighted images. T2 contrast agents are based on ferromagnetic or superparamagnetic centres. These may take the form of monocrystalline, polycrystalline, cross-linked iron oxide magnetic cores (5—30 nm) embedded in a polymer coating with a total particle diameter of 17—50 nm. However, the large molecular size of these contrast agents can cause problems for their biodistribution and circulating half-life (typically 6 min), and ultrasmall superparamagnetic iron oxide nanoparticles have been introduced to overcome these problems with their smaller size (10 nm), longer half-life (81 min) and improved biodistribution (Cassidy and Radda, 2005).

In the next years, it cannot be excluded that further developments of MR molecular imaging, nowadays purely experimental and mostly focused on oncologic imaging, cell migration, receptors, and angiogenesis, could be effectively used in the detection of active inflammatory cells and cytokines of CD as well.

Discussion

The assessment of disease activity in CD comprises techniques such as endoscopic analysis of the colon (colonoscopy, small bowel follow through) as well as radiological techniques (ultrasound, CT and MRI). Known is that affected gut tissue in CD patients is highly infiltrated by activated mononuclear cells as an expression of an inflammatory condition and intestinal infiltration by polymorphonuclear cells (mainly granulocytes) is also observed, but the sequence of events leading to chronic inflammation and to clinical flare-ups is still unknown. Imaging the molecules involved in these inflammatory processes can be very worthwhile. A non-invasive technique with good compliance will be very helpful, especially because most patients are in need for a long-term follow-up and must be under surveillance at least once a year.

Several scintigraphic methods exist for imaging inflammation. Most of the used radionuclides are non-specific, that is, these radiopharmaceuticals can be used in different kinds of inflammation (labeled WBC, immunoglobulin labeling, LeukoScan, and FDG—PET). Other radiopharmaceuticals are specific for one chemokines or cytokine involved in the process of inflammation (IL2, IL8, TNF α , and E-selectin). The field of the specific radiopharmaceuticals is still in development, several radiopharmaceuticals are studied and attempts are made to label them with a positron emitter, to allow absolute quantification and a better resolution.

Of the non-specific SPECT radiopharmaceuticals, radiolabeling WBC using either ^{99m}Tc -HMPAO or ^{111}In -oxine, is the most widely evaluated method and it has been proposed as a reliable method for the diagnosis of IBD, for the assessment of disease activity and for treatment response. In general, ^{99m}Tc labeling is preferred because of the lower radiation dose, shorter examination time, lower costs, and better image quality. However, a major advantage is still the time-consuming cell labeling procedure and the handling and re-injection of blood with risk for contamination.

A radiopharmaceutical that could combine the high sensitivity and specificity in the detection of CD together with a simpler way of preparation would be ideal. Other non-specific SPECT radiopharmaceuticals have been used, such as labeling the antigranulocyte monoclonal antibody or a Fab' fragment of this antibody (LeukoScan) but aspecific bowel activity seems to preclude the use of these radiopharmaceuticals. The reason for this aspecific activity is unclear. One of the hypotheses is the binding of these antibodies in normal colonic mucosa, which is recognized by in vitro investigations. Another cause could be free pertechnetate as a result of in vivo degradation of the radiopharmaceutical (Gyorke et al., 2000). A positive

AGAb scan or a positive LeukoScan fails to differentiate between different causes of bowel inflammation and between inflammation and aspecific activity and so further endoscopic evaluation is always necessary. Polyclonal HIG was proposed as an alternative to labeled WBC. Slow blood clearance, high and persistent kidney activity, the appearance of physiologic bowel activity, and the minimum accumulation of HIG in the affected bowel segments are the main drawbacks in ^{99m}Tc -HIG, which resulted in a low specificity. The results with ^{111}In -HIG are slightly better, but overall it cannot be considered as an alternative method to labeled WBC in the assessment of CD.

Specific SPECT radiopharmaceuticals for CD have been developed and evaluated since the beginning of this century.

Imaging TNF α with ^{99m}Tc -Infliximab was not predictive of clinical outcome. This could be due to the fact that there is little TNF α production in the gut of CD patients and that this cannot be detected by this scintigraphic method or that there is a low antibody extravasation, as described for labeled antigranulocyte antibodies (D'Alessandria et al., 2007). More studies are necessary to clarify the mechanism of action of anti- TNF α monoclonal antibodies, but unfortunately the production of labeled TNF α has stopped.

E-selectin provides an attractive target for imaging inflammation in CD. The feasibility of using anti-E-selectin monoclonal antibody to evaluate patients with IBD was shown with ^{111}In . The use of ^{99m}Tc labeled anti-E-selectin antibody will improve quality, but has not been tried yet. A ^{99m}Tc labeled Fab' fragment is used with good results in inflammatory arthritis and should also be used in patients with other inflammatory disorders such as CD. The expression of E-selectin on the vascular endothelium of many diseased organs, but not of normal tissues, makes this technique an attractive one in a wide range of clinical situation (Jamar et al., 2002).

The labeling of interleukins has special interest the last years.

They play an important role in the neutrophil recruitment into the colonic mucosa. In a rabbit model, the imaging performances of ^{99m}Tc -HYNIC-IL8 were similar to ^{99m}Tc -HMPAO labeled WBC at 1 h after injection, but appeared even better at 2 h after injection. However, other studies showed that ^{99m}Tc -HYNIC-IL8 induced a transient neutropenia in rabbits. Further increase of the specific activity of the ^{99m}Tc - HYNIC-IL8 preparation and a decrease in biological activity of the agent is necessary to inject this radiopharmaceutical in patients.

T-cell activation and macrophage activation are features of CD, and the diseased CD tissue is severely infiltrated by activated mononuclear cells expressing IL2-R and capable of binding free IL2. Therefore, labeling IL2 is of special interest. ^{123}I -IL2 scintigraphy had good results

and provided an *in vivo* quantification of activated mononuclear cells within the gut wall. Labeling with ^{99m}Tc was also possible and has the advantage over ^{123}I that it is cheaper, earlier imaging is possible and it is available on a larger scale. High intestinal uptake on the ^{99m}Tc -IL2 scintigraphy represents a useful marker for the prediction of clinical relapse in patients with inactive CD. A positive correlation was found between the extent of chronic inflammation on ^{99m}Tc -IL2 scan and the change in CD activity index in the last 12 months. Compared with ^{99m}Tc labeled WBC, the usefulness of both techniques in patients with CD was proven, and the role of IL2 scintigraphy in particular in the long-term follow-up of patients with clinically inactive CD. A negative IL2 scan shows a high negative predictive value for disease relapse during the next 12 months, thus providing information of value in assessing the appropriate treatment of patients with inactive disease. Moreover, IL2 scintigraphy shows several advantages over WBC scintigraphy: it does not require any blood manipulation and maybe a future development of a one-step labeling kit will reduce time and preparation costs (Annovazzi et al., 2003). PET radiopharmaceuticals have always the advantage over SPECT radiopharmaceuticals in the fact that absolute quantification is possible and a better resolution can be achieved. FDG—PET proved to be a reliable tool in known inflamed gut segments in patients with CD with high sensitivity but lower specificity as compared with WBC scan (Figs. 2 and 3). Combining the physiologic properties of the FDG—PET with the anatomic properties of the CT could even give more information. FDG—PET/CT showed a good correlation with endoscopic, clinical, and biologic scores of activity in CD and a reduction in FDG uptake occurs when disease activity was successfully treated. However, the physiological uptake of FDG in especially the large bowel, the significant patient irradiation linked to the PET/CT technique and the high costs could impede frequent use.

At present, conventional radiologic cross-sectional imaging modalities, including US, CT, and MRI do not offer any direct information on “cell trafficking” in CD. These imaging modalities, however, and particularly MRI, have been optimized to accurately detect the main “macroscopic” indirect signs of wall inflammation in CD, such as wall and mesenteric hypervascularity, submucosal edema, wall thickening, and stratification, wall hypervascularity, wall and perivisceral edema, lymph node enlargement, etc. MRI at the moment seems the more valuable imaging modality to detect disease activity in CD, as a result of the lack of invasiveness and ionizing radiation, to the high sensitivity for inflammatory tissues and good spatial resolution.

Although no radiologic tool is currently able to detect directly the presence of lymphocytic infiltration at the level of the affected bowel wall, the potentials of new MR applications, such

as spectroscopy, diffusion imaging, and molecular imaging, are promising. It is possible that the progressive use and evolution of such MRI applications will lead to further characterization and understanding of the inflammatory process of intestinal CD.

In conclusion, several radiopharmaceuticals are available for imaging CD, non-specific and specific. Labeled WBCs is the most used method at the moment, but has some major disadvantages. A specific SPECT-radiopharmaceutical, ^{99m}Tc -IL2 has been developed recently and showed good results. The capacity of this radiopharmaceutical for screening of patients with suspected CD and monitoring disease activity, has to be determined in future studies. Similarly, the potentials of MRI in the characterization of intestinal wall inflammation have not yet been completely investigated and there are good premises for the future.

Acknowledgments

The authors wish to thank Prof. Roberto Grassi and Dr.ssa Angiolina Cistaro, for providing FDG-PET and CT images and Mrs Loreta Camillo Sforza for editing the manuscript.

References

Aime S, Cabella C, Colombatto S, Geninatti C, Gianolio E, Maggioni F. 2002. Insights into the use of paramagnetic Gd(III) complexes in MR-molecular imaging investigations. *J Magn Reson Imaging* 16:394–406.

Ajaj WM, Lauenstein TC, Pelster G, Gerken G, Ruehm SG, Debatin JF, Goehde SC. 2005. Magnetic resonance colonography for the detection of inflammatory diseases of the large bowel: Quantifying the inflammatory activity. *Gut* 54:257–263.

Alberini JL, Badran A, Freneaux E, Hadji S, Kalifa G, Devaux JY, Dupont T. 2001. Technetium- 99m HMPAO-labeled leukocyte imaging compared with endoscopy, ultrasonography, and contrast radiology in children with inflammatory bowel disease. *J Pediatr Gastroenterol Nutr* 32:278–286.

Andres PG, Friedman LS. 1999. Epidemiology and the natural course of inflammatory bowel disease. *Gastroenterol Clin North Am* 28:255–281, vii.

Annovazzi A, Biancone L, Caviglia R, Chianelli M, Capriotti G, Mather SJ, Caprilli R, Pallone F, Scopinaro F, Signore A. 2003. ^{99m}Tc -interleukin-2 and $(^{99m})\text{Tc}$ -HMPAO granulocyte scintigraphy in patients with inactive Crohn's disease. *Eur J Nucl Med Mol Imaging* 30:374–382.

Arndt JW, Sluys Veer A, Blok D, Griffioen G, Verspaget HW, Pena AS, Lamers CB, Pauwels EK. 1992. A prospective comparison of ^{99m}Tc -labeled polyclonal human immunoglobulin and ^{111}In granulocytes for localization of inflammatory bowel disease. *Acta Radiol* 33:140–144.

Arndt JW, Sluys Veer A, Blok D, Griffioen G, Verspaget HW, Lamers CB, Pauwels EK. 1993. Prospective comparative study of technetium- 99m -WBCs and indium- 111 -granulocytes for the examination of patients with inflammatory bowel disease. *J Nucl Med* 34:1052–1057.

Arndt JW, Grootsholten MI, van Hogezaand RA, Griffioen G, Lamers CB, Pauwels EK. 1997. Inflammatory bowel disease activity assessment using technetium- 99m -HMPAO leukocytes. *Dig Dis Sci* 42:387–393.

Aydin F, Dincer D, Gungor F, Boz A, Akca S, Yildiz A, Tosun O, Karayalcin B. 2008. Technetium- 99m hexamethyl propylene amine oxime-labeled leukocyte scintigraphy at three different times in active ulcerative colitis: Comparison with colonoscopy and clinico biochemical parameters in the assessment of disease extension and severity. *Ann Nucl Med* 22:371–377.

Bhatti M, Chapman P, Peters M, Haskard D, Hodgson HJ. 1998. Visualising E-selectin in the detection and evaluation of inflammatory bowel disease. *Gut* 43:40–47.

Biancone L, Scopinaro F, Ierardi M, Paoluzi P, Marcheggiano A, Di Paolo MC, Porowska B, Colella AC, Pallone F. 1997. ^{99m}Tc -HMPAO granulocyte scintigraphy in the early detection of postoperative asymptomatic recurrence in Crohn's disease. *Dig Dis Sci* 42:1549–1556.

Biancone L, Schillaci O, Capocchetti F, Bozzi RM, Fina D, Petruzzello C, Geremia A, Simonetti G, Pallone F. 2005. Technetium- 99m -HMPAO labeled leukocyte single photon

emission computerized tomography (SPECT) for assessing Crohn's disease extent and intestinal infiltration. *Am J Gastroenterol* 100:344–354.

Bruno I, Martelossi S, Geatti O, Maggiore G, Guastalla P, Povolato M, Ventura A. 2002. Antigranulocyte monoclonal antibody immunoscintigraphy in inflammatory bowel disease in children and young adolescents. *Acta Paediatr* 91:1050–1055.

Buscombe JR, Lui D, Ensing G, de Jong R, Ell PJ. 1990. ^{99m}Tc-human immunoglobulin (HIG)— First results of a new agent for the localization of infection and inflammation. *Eur J Nucl Med* 16:649–655.

Cassidy PJ, Radda GK. 2005. Molecular imaging perspectives. Review. *J R Soc Interface* 2:133–144.

Charron M. 2003. Inflammatory bowel disease activity assessment with biologic markers and ^{99m}Tc-WBC scintigraphy: Are there different trends in ileitis versus colitis? *J Nucl Med* 44:1586–1591.

Charron M, Di Lorenzo C, Kocoshis SA, Hickeson MP, Orenstein SR, Goyal A, Kahn S, Collins L. 2001. (^{99m}Tc) antigranulocyte monoclonal antibody imaging for the detection and assessment of inflammatory bowel disease newly diagnosed by colonoscopy in children. *Pediatr Radiol* 31:796–800.

Choi D, Jin Lee S, Ah Cho Y, et al. 2003. Bowel wall thickening in patients with Crohn's disease: CT patterns and correlation with inflammatory activity. *Clin Radiol* 58:68–74.

D'Alessandria C, Malviya G, Viscido A, Aratari A, Maccioni F, Amato A, Scopinaro F, Caprilli R, Signore A. 2007. Use of a ^{99m}Tc labeled anti-TNF α monoclonal antibody in Crohn's disease: In vitro and in vivo studies. *Q J Nucl Med Mol Imaging* 51:334–342.

Delgado Castro M, Lancha C, Prats E, Mitjavilla M, Abos D, Martin-Curto LM, Crespo A, Banzo J. 1997. The diagnostic value of Tc-^{99m} human polyclonal immunoglobulin imaging compared to Tc-^{99m} HMPAO labeled leukocytes in inflammatory bowel disease. *Clin Nucl Med* 22:17–20.

Esteban JM, Maldonado L, Sanchiz V, Minguez M, Benages A. 2001. Activity of Crohn's disease assessed by colour Doppler ultrasound analysis of the affected loops. *Eur Radiol* 11:1423–1428.

Fidler J. 2007. MR imaging of the small bowel. *Radiol Clin N Am* 45:317–331. Fiocchi C. 1998. Inflammatory bowel disease: Etiology and pathogenesis. *Gastroenterology* 115:182–205.

Fischman AJ, Rubin RH, Khaw BA, Callahan RJ, Wilkinson R, Keech F, Nedelman M, Dragotakes S, Kramer PB, LaMuraglia GM. 1988. Detection of acute inflammation with ¹¹¹In-labeled nonspecific polyclonal IgG. *Semin Nucl Med* 18:335–344.

Florie J, Wasser MNJ, Arts-Cieslik K, et al. 2006. Dynamic contrast-enhanced MRI of the bowel wall for assessment of disease activity in Crohn's disease. *AJR Am J Roentgenol* 186:1384–1392.

Froelich JW, Field SA. 1988. The role of indium-111 white blood cells in inflammatory bowel disease. *Semin Nucl Med* 18:300–307.

Golder W. 2007. Magnetic resonance spectroscopy in clinical oncology. *Onkologie* 27:304–309.

Gourtsoyiannis N, Papanikolaou N, Grammatikakis J, et al. 2004. Assessment of Crohn's disease activity in the small bowel with MR and conventional enteroclysis: Preliminary results. *Eur Radiol* 14:1017–1024.

Gourtsoyiannis N, Papanikolaou N, Grammatikakis J, Prassopoulos P. 2002. MR enteroclysis: Technical considerations and clinical applications. *Eur Radiol* 12:2651–2658.

Gratz S, Rennen HJ, Boerman OC, Oyen WJ, Corstens FH. 2001. Rapid imaging of experimental colitis with (99m)Tc-interleukin-8 in rabbits. *J Nucl Med* 42:917–923.

Gyorke T, Duffek L, Bartfai K, Mako E, Karlinger K, Mester A, Tarjan Z. 2000. The role of nuclear medicine in inflammatory bowel disease. A review with experiences of aspecific bowel activity using immunoscintigraphy with ^{99m}Tc anti-granulocyte antibodies. *Eur J Radiol* 35:183–192.

Hanauer SB. 2006. Inflammatory bowel disease: Epidemiology, pathogenesis, and therapeutic opportunities. *Inflamm Bowel Dis* 12:S3–S9.

Hebbard GS, Salehi N, Gibson PR, Lichtenstein M, Andrews JT. 1992. ^{99m}Tc -labelled IgG scanning does not predict the distribution of intestinal inflammation in patients with inflammatory bowel disease. *Nucl Med Commun* 13:336–341.

Jamar F, Houssiau FA, Devogelaer JP, Chapman PT, Haskard DO, Beaujean V, Beckers C, Manicourt DH, Peters AM. 2002. Scintigraphy using a technetium 99m -labelled anti-E-selectin Fab fragment in rheumatoid arthritis. *Rheumatology (Oxford)* 41:53–61.

Jasper F, Wasser MN, Arts-Geslik K, et al. 2006. Dynamic contrast-enhanced MRI of the bowel wall for assessment of disease activity in Crohn's disease. *Am J Radiol* 186:1384–1392.

Kerry JE, Marshall C, Griffiths PA, Scott BB, Griffiths G. 2003. White cell scanning for inflammatory bowel disease: Are biochemical markers useful referral criteria? *Nucl Med Commun* 24:1145–1148.

Kerry JE, Marshall C, Griffiths PA, James MW, Scott BB. 2005. Comparison between Tc-HMPAO labelled white cells and Tc LeukoScan in the investigation of inflammatory bowel disease. *Nucl Med Commun* 26:245–251.

Kiryu S, Dodanuki K, Takao H, et al. 2009. Free-breathing diffusion-weighted imaging for the assessment of inflammatory activity in Crohn's disease. *J Magn Reson Imaging* 29:880–886.

Koh DM, Miao Y, Chinn RJ, Amin Z, et al. 2001. MR imaging evaluation of the activity of Crohn's disease. *Am J Roentgenol* 177:1325–1332.

Koizumi M, King N, Lobb R, Benjamin C, Podolsky DK. 1992. Expression of vascular adhesion molecules in inflammatory bowel disease. *Gastroenterology* 103:840–847.

Laghi A, Borrelli O, Paolantonio P, et al. 2003. Contrast enhanced magnetic resonance imaging of the terminal ileum in children with Crohn's disease. *Gut* 52:393–397, 17

Li DJ, Middleton SJ, Wraight EP. 1992. ⁹⁹Tcm and ¹¹¹In leucocyte scintigraphy in inflammatory bowel disease. *Nucl Med Commun* 13:867–870.

Loffler M, Weckesser M, Franzius C, Schober O, Zimmer KP. 2006. High diagnostic value of ¹⁸F-FDG-PET in pediatric patients with chronic inflammatory bowel disease. *Ann N Y Acad Sci* 1072:379–385.

Loftus EV, Jr. 2004. Clinical epidemiology of inflammatory bowel disease: Incidence, prevalence, and environmental influences. *Gastroenterology* 126:1504–1517.

Louis E, Belaiche J, Van Kemseke C, Schaaf N, Mahieu P, Mary JY. 1995. Soluble interleukin-2receptor in Crohn's disease. Assessment of disease activity and prediction of relapse. *Dig Dis Sci* 40:1750–1756.

Louis E, Ancion G, Colard A, Spote V, Belaiche J, Hustinx R. 2007. Noninvasive assessment of Crohn's disease intestinal lesions with (¹⁸F)-FDG PET/CT. *J Nucl Med* 48:1053–1059.

Low RN, Sebrechts CP, Politoske DA, et al. 2002. Crohn disease with endoscopic and gadolinium-enhanced fat-suppressed spoiled gradient-echo MR imaging. *Radiology* 222:652–660.

Maccioni F. 2008. Double contrast MRI of the small and large bowel: Effectiveness in the evaluation of inflammatory bowel disease. *Abdom Imaging*. [Epub ahead of print]

Maccioni F, Viscido A, Broglia L, et al. 2000. Evaluation of Crohn's disease activity with MRI. *Abdom Imaging* 25: 219–228.

Maccioni F, Viscido A, Broglia L, et al. 2000. Evaluation of Crohn's disease activity with MRI. *Abdom Imaging* 25:219–228.

Maccioni F, Bruni A, Viscido A, Colaiacomo MC, Cocco A, Montesani C, Caprilli R, Marini M. 2005. MR imaging in patients with Crohn disease: Value of T2- versus T1-weighted gadolinium-enhanced MR sequences with use of an oral superparamagnetic contrast agent. *Radiology* 238:517–530.

Maccioni F, Colaiacomo MC, Parlanti S. 2005b. Ulcerative colitis: Value of MR imaging. *Abdom Imaging* 30:584–592 (review).

MacKalski BA, Bernstein CN. 2006. New diagnostic imaging tools for inflammatory bowel disease. *Gut* 55:733–741.

Mairal L, de Lima PA, Martin-Comin J, Baliellias C, Xiol X, Roca M, Ricart Y, Ramos M. 1995. Simultaneous administration of ¹¹¹In-human immunoglobulin and ^{99m}Tc-HMPAO labelled leucocytes in inflammatory bowel disease. *Eur J Nucl Med* 22:664–670.

Meisner RS, Spier BJ, Einarsson S, Roberson EN, Perlman SB, Bianco JA, Taylor AJ, Einstein M, Jaskowiak CJ, Massoth KM, Reichelderfer M. 2007. Pilot study using PET/CT as a novel, noninvasive assessment of disease activity in inflammatory bowel disease. *Inflamm Bowel Dis* 13:993–1000.

Molnar T, Papos M, Gyulai C, Ambrus E, Kardos L, Nagy F, Palko A, Pavics L, Lonovics J. 2001. Clinical value of technetium-99m-HMPAO-labeled leukocyte scintigraphy and spiral computed tomography in active Crohn's disease. *Am J Gastroenterol* 96:1517–1521.

Murata Y, Ishiguro Y, Itoh J, Munakata A, Yoshida Y. 1995. The role of proinflammatory and immunoregulatory cytokines in the pathogenesis of ulcerative colitis. *J Gastroenterol* 30:56–60.

Neurath MF, Vehling D, Schunk K, Holtmann M, Brockmann H, Helisch A, Orth T, Schreckenberger M, Galle PR, Bartenstein P. 2002. Noninvasive assessment of Crohn's disease activity: A comparison of ¹⁸F-fluorodeoxyglucose positron emission tomography,

hydromagnetic resonance imaging, and granulocyte scintigraphy with labeled antibodies. *Am J Gastroenterol* 97:1978–1985.

Olejniczak K, Kasprzak A. 2008. Biological properties of interleukin 2 and its role in pathogenesis of selected diseases—A review. *Med Sci Monit* 14:RA179–RA189.

Oyen WJ, Claessens RA, van der Meer JW, Rubin RH, Strauss HW, Corstens FH. 1992. Indium-111-labeled human nonspecific immunoglobulin G: A new radiopharmaceutical for imaging infectious and inflammatory foci. *Clin Infect Dis* 14:1110–1118.

Papos M, Nagy F, Lang J, Csernay L. 1993. Technetium-99m hexamethylpropylene amine oxime labelled leucocyte scintigraphy in ulcerative colitis and Crohn's disease. *Eur J Nucl Med* 20:766–769.

Papos M, Nagy F, Narai G, Rajtar M, Szantai G, Lang J, Csernay L. 1996. Anti-granulocyte immunoscintigraphy and [99mTc]hexamethylpropyleneamine-oxime-labeled leukocyte scintigraphy in inflammatory bowel disease. *Dig Dis Sci* 41:412–420.

Podolsky DK. 2002. Inflammatory bowel disease. *N Engl J Med* 347:417–429. Potter K. 2002. Magnetic resonance microscopy approaches to molecular imaging: Sensitivity vs. specificity. *J Cell Biochem Suppl* 39:147–153.

Rimola J, Rodriguez S, Garcia-Bosch O, et al. 2009. Magnetic resonance for assessment of disease activity and severity in ileocolonic Crohn's disease. *Gut* 58:1113–1120.

Rosen Y. 2007. The Recent advances in magnetic resonance neurospectroscopy. *Neurotherapeutics* 27:330–345.

Sachar DB, Luppescu NE, Bodian C, Shlien RD, Fabry TL, Gumaste VV. 1990. Erythrocyte sedimentation as a measure of Crohn's disease activity: Opposite trends in ileitis versus colitis. *J Clin Gastroenterol* 12:643–646.

Saverymuttu SH, Peters AM, Lavender JP, Pepys MB, Hodgson HJ, Chadwick VS. 1983. Quantitative fecal indium 111-labeled leukocyte excretion in the assessment of disease in Crohn's disease. *Gastroenterology* 85:1333–1339.

Sciarretta G, Furno A, Mazzoni M, Basile C, Malaguti P. 1993. Technetium-99m hexamethyl propylene amine oxime granulocyte scintigraphy in Crohn's disease: Diagnostic and clinical relevance. *Gut* 34:1364–1369.

Sempere GAJ, Sanjuan VM, Chulia EM, et al. MRI evaluation of inflammatory activity in CD. *Am J Roentgenol* 2005. 184:1829–1835.

Signore A, Chianelli M, Annovazzi A, Bonanno E, Spagnoli LG, Pozzilli P, Pallone F, Biancone L. 2000. ¹²³I-interleukin-2 scintigraphy for in vivo assessment of intestinal mononuclear cell infiltration in Crohn's disease. *J Nucl Med* 41:242–249.

Spier BJ, Perlman SB, Jaskowiak CJ, Reichelderfer M. 2010. PET/CT in the evaluation of inflammatory bowel disease: Studies in patients before and after treatment. *Mol Imaging Biol* 12:85–88.

Stathaki MI, Koutroubakis IE, Koukouraki SI, Karmiris KP, Moschandreas JA, Kouroumalis EA, Karkavitsas NS. 2008. Active inflammatory bowel disease: Head-to-head comparison between ^{99m}Tc-hexamethylpropylene amine oxime white blood cells and ^{99m}Tc(V)-dimercaptosuccinic acid scintigraphy. *Nucl Med Commun* 29:27–32.

Stokkel MP, Reigman HE, Pauwels EK. 2002. Scintigraphic head-to-head comparison between ^{99m}Tc-WBCs and ^{99m}Tc-LeukoScan in the evaluation of inflammatory bowel disease: A pilot study. *Eur J Nucl Med Mol Imaging* 29:251–254.

Versaci A, Bonanno N, Baldari S, Terranova M, Macri A, Leonello G, Famulari C. 1999. Diagnostic possibilities and clinical indications of polyclonal labeled Ig in the bowel inflammatory disease. *Hepatogastroenterology* 46:2260–2264.

Xavier RJ, Podolsky DK. 2007. Unravelling the pathogenesis of inflammatory bowel disease. *Nature* 448:427–434

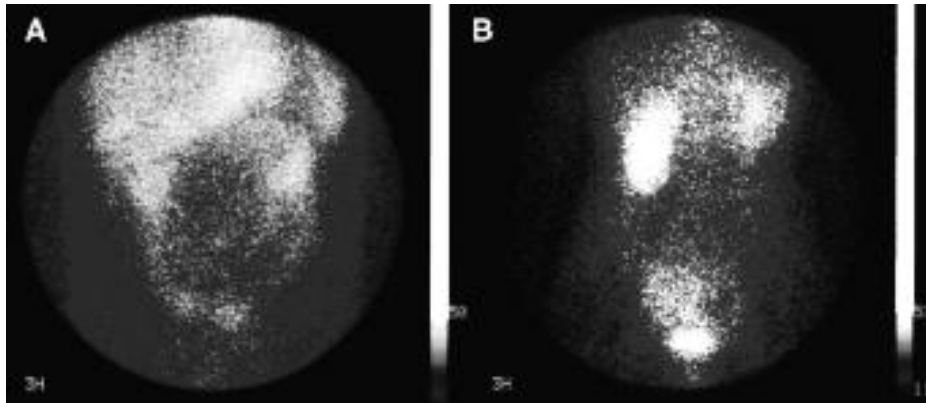


Fig. 1. ^{123}I -IL2 imaging in patients affected by ileal Crohn's disease. Antero-posterior images of the abdomen were acquired 3 h after the i.v. administration of 37–74 MBq of ^{123}I -labelled IL2 and show the presence of activated T-lymphocytes (CD25R) in the gut wall mucosa. Patient in (A), shows a diffuse pattern of activity in the ileum, whereas patient in (B) shows a localized uptake in the terminal ileum. Kidneys and spleen are physiologically seen in both patients.

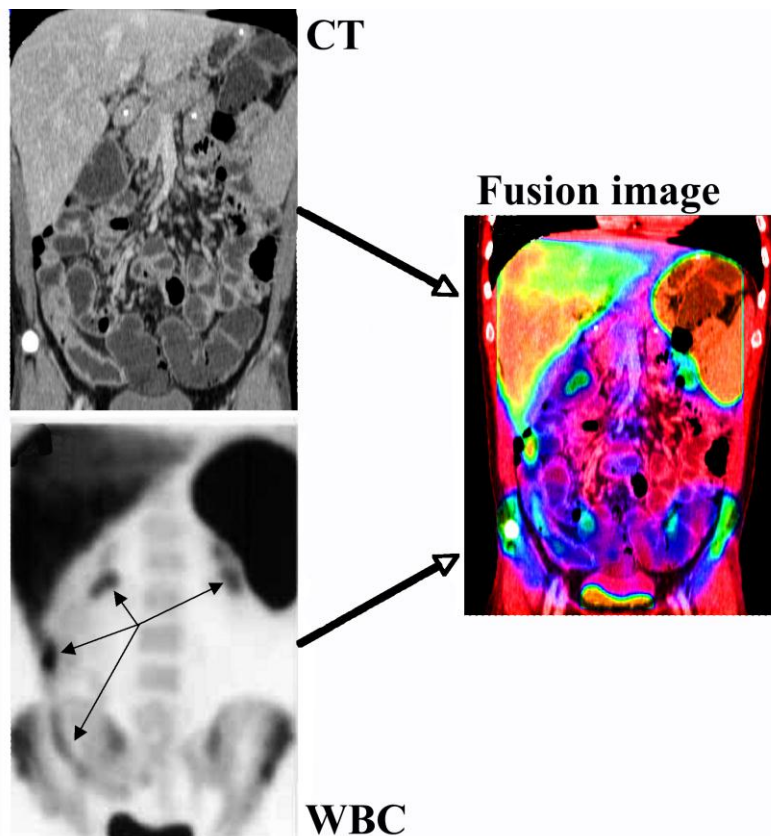


Fig. 2. CT enterocloasis (top left) shows a parietal thickening (10.8 mm) involving most ileum and particularly the distal part, with increased vascularity and a mesenteric hypertrophy. Tc-99m-WBC scan (bottom left) shows only focal leukocyte infiltration in four different ileal segments (small arrows). The post-processing fusion imaging of the two studies, allows us to better co-localize the lesions and to obtain an important patho-physiological information (parts of affected ileum are fibro-stenotic without leukocyte infiltration; other segments show signs of acute inflammation). Similar information can be obtained using hybrid imaging with SPECT/CT.

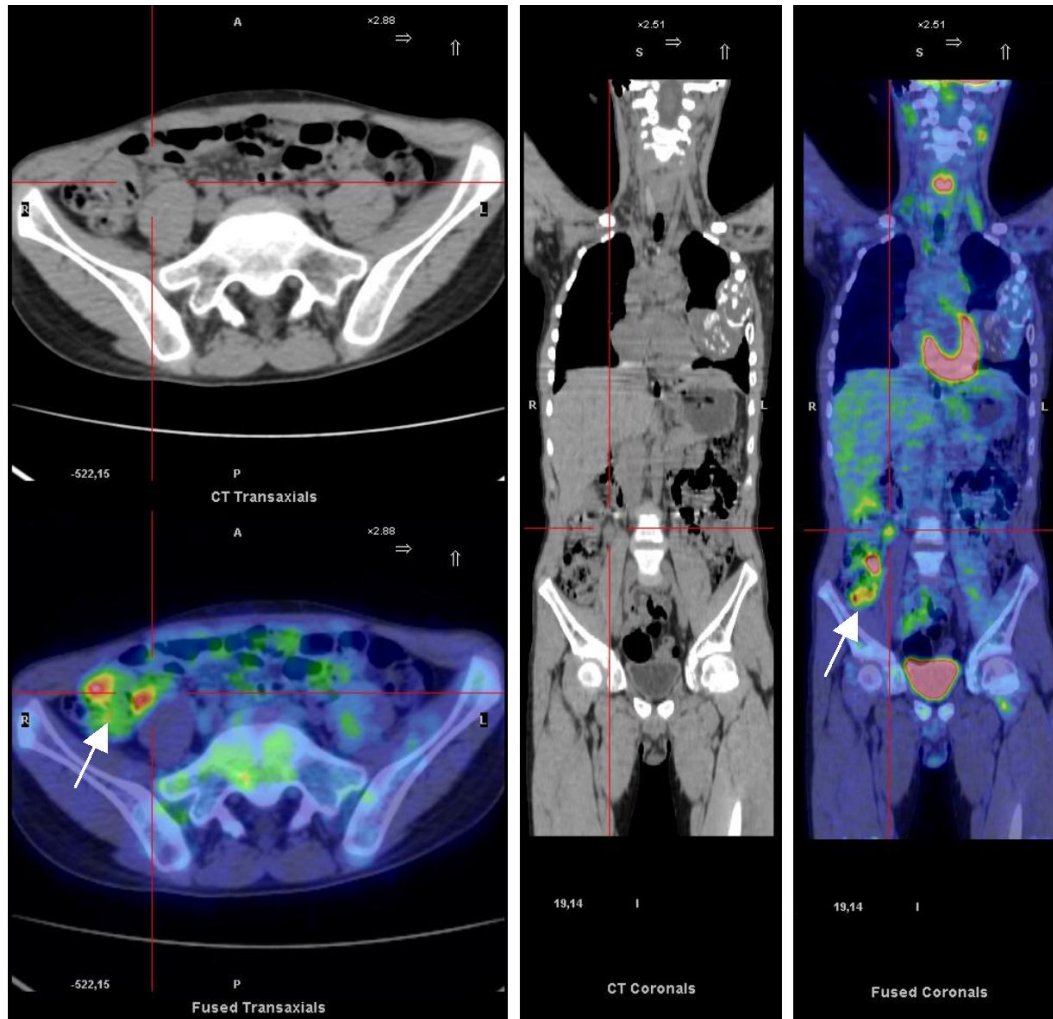


Fig. 3. *18F-FDGPET/CT images (transaxial and coronal slides) in a patient with active CD. Images show areas with increased glucose metabolism. A reactive lymphonode is detectable (defined by red lines) but not necessarily it is an infected site. White arrow shows activity in the inflamed gut wall and because of lack of specificity of the radiopharmaceutical, these areas can be inflamed or infected.*



Picture by Francesca Maccioni 2012
Sunset from the dining room window (G)

Chapter 8

Differences in the location and activity of intestinal Crohn's disease lesions between adult and paediatric patients detected with MRI

Maccioni F¹, Viola F², Carrozzo F¹, Di Nardo G², Pino AR¹, Staltari I¹, Al Ansari N¹, Vestri A³, Signore A⁴, Marini M¹, Cucchiara S².

Eur Radiol. 2012;22(11):2465-77.

¹Department of Radiological Sciences, Oncology and Pathology, Policlinico Umberto I Hospital, "Sapienza" University, Rome, Italy; ²Department of Pediatrics, Pediatric Gastroenterology and Liver, Unit Policlinico Umberto I Hospital, "Sapienza" University, Rome, Italy; ³Department of Statistical Sciences, Policlinico Umberto I Hospital, "Sapienza" University, Roma, Italy;

⁴Nuclear Medicine Unit, Faculty Medicine and Psychology, 2nd Faculty of Medicine, S. Andrea Hospital, "Sapienza" University, Rome, Italy.

Abstract

Objectives To prospectively compare paediatric patients (PP) and adult patients (AP) affected by Crohn's disease (CD) in terms of the location and activity of intestinal lesions.

Methods Forty-three children (mean age 15 years) and 43 adults (mean age 48 years) with proven CD underwent magnetic resonance enterography (MRE) to localise lesions and detect their activity in 9 segments of the small and large bowel. The results were analysed on a per patient and per segment basis. Ileo-colonoscopy was performed in all patients. P values less than 0.05 were considered statistically significant.

Results Involvement of terminal ileum was significantly different in the two groups: observed in 100 % of AP (43/43) versus 58 % (23/43) of PP (P<0.0001). Conversely, the colon was diseased in 84 % of PP versus 64 % of AP. In particular, left colonic segments were significantly more involved in PP (descending colon 53 % versus 21 %, P<0.01; rectum 67 % versus 23 %, P<0.0001; sigmoid colon 56%versus 37%, not significant), whereas caecal involvement was equal in both groups. In children the maximal disease activity was found in left colonic segments, whereas in adults it was in the terminal ileum.

Conclusions MRE detected significant differences between the two populations, showing a more extensive and severe involvement of the left colon in children but the distal ileum in adults.

Key Points

- MRI is useful for assessing Crohn's disease in adult and paediatric patients.
- Adult and paediatric patients show different intestinal involvement on MRI.
- The distal ileum is maximally involved in adults vs. the left colon in children.
- The causes of the severe left colonic disease in children are unknown.
- The extensive colonic involvement in children has clinical diagnostic implications.

Keywords: Magnetic resonance imaging. Inflammatory bowel diseases. Magnetic resonance enterography. Paediatric Crohn's disease. Bowel, small, large.

Introduction

Crohn's disease (CD) is a chronic inflammatory bowel disease which occurs both in adult patients (AP) and paediatric patients (PP). Although the pathogenesis still remains unclear, it is now established that intestinal lesions and symptoms are associated with an overproduction of pro-inflammatory cytokines due to an inappropriate immune activation, determined by an interaction of genetic, environmental and immunological factors. The hallmark of the disease is an uncontrolled transmural inflammation of the intestinal wall, which can affect any part of the gastrointestinal tract, but almost invariably the terminal ileum, involved in approximately 80–90 % of cases [1, 2].

Recent clinical studies, however, suggest that in childhood a different CD phenotype may develop, showing a different genetic basis from adult phenotypes [3–10]. According to these studies, childhood CD seems to have both a more severe course and a more extensive colonic involvement, as compared to the adult type, for reasons still unknown.

To date, only a few comparative studies between the two patient populations are available, mostly based on clinical retrospective data [1, 2]. The complete evaluation of CD lesions in the small and the large bowel is a complex procedure, particularly in PP, requiring the combination of various diagnostic instrumental procedures, some of them relatively invasive [11–13].

To the best of our knowledge, MRI has never been used for comparing the extent and activity of intestinal CD lesions between adult and paediatric patients. In recent years, however, MRI enterography (MRE) has emerged as a reliable, safe and comprehensive examination for CD, showing high accuracy in detecting small and large bowel lesions and their activity, both in adults [14–24] and children [25, 26].

The main purpose of our study was to prospectively compare AP and PP, with regard to the location, distribution and activity of intestinal lesions, by using MRE as the main reference examination. The overall incidence of CD lesions in the colon and small bowel and the relative incidence of lesions in nine different segments of the small and large bowel, from the jejunum to the rectum, were assessed and compared in the two populations on a per patient and per segment basis. Disease activity at the level of the affected intestinal segments was also scored according to established criteria [12–14, 19–25]. A comparison between MRE and other investigations was also performed, although this was not the primary purpose of the study.

Materials and methods

Study design

This clinical-radiological study was carried out to prospectively compare the location and activity of CD intestinal lesions in adult and paediatric patients, from the jejunum to the rectum. It was approved by the local ethics committee of the university hospital.

As part of routine clinical follow-up, adult and paediatric patients with known CD underwent MRE as the principal examination to evaluate the small and large bowel. Other investigations were also scheduled, including ileocolonoscopy (CS) and high-resolution ultrasonography (HRUS) with colour Doppler ultrasound for all patients, small bowel follow-through barium studies (SBFT) and capsule endoscopy (CE) as second-level examinations, in selected cases. A comparison between MRI and other investigations was performed, although it was not a primary objective of the study.

Patient population

Inclusion criteria were (1) proven CD, diagnosed on the basis of established clinical, radiological, endoscopic and histological criteria [27, 28] and (2) age over 18 years for the adult group, age 5–18 years for the paediatric group.

Patients with previous extensive intestinal resections were excluded, whereas those with ileo-caecal resection equal to or less than 25 cm were included.

Between January 2009 and December 2010, 90 consecutive patients were enrolled. Four patients (2 AP and 2 PP) were excluded because they could not complete the examinations. Finally, 43 PP (21 girls and 22 boys, median age 14.8 years, range 8–18) and 43 AP (16 women and 27 men, median age 46.6 years, range 21–77) were included.

Clinical data are summarised in Table 1. For PP, written consent was obtained from both parents before any procedure; informed written consent was obtained from AP.

MRI examination

The same MRE technique was adopted for AP and PP. An intestinal contrast agent (Lumirem, Guerbet Co., France) was orally administered 45–60 min before the examination, at a mean dose of 400 mL for PP, 900 mL for AP. It contains silicon-coated non-absorbable iron oxide particles that produce negative (superparamagnetic) signal intensities.

MRE was performed with a 1.5-T magnet (Avanto, Siemens Medical System, Erlangen, Germany). The study protocol included (Table 2): (a) T2-weighted (T2w) HASTE (half-Fourier

single-shot turbo spin-echo) breath-hold-free sequences to examine the entire small and large bowel. (b) T2-weighted breath-hold-free fat-suppressed HASTE sequences. (c) Axial T1-weighted breath-hold 3D VIBE (volumetric interpolated breath-hold examination) sequences, first acquired at the level of the abnormal loops after the intravenous administration of a gadolinium chelate contrast agent (Dotarem, Laboratories Guerbet, Paris, France) at a dose of 0.1 mmol/kg (0.2 ml/kg) body weight (at approximately 45–50 s of delay in children, 50–55 s in adults) to obtain an early venous phase of enhancement, followed by a saline flush. Contiguous MR images were also acquired above and below the abnormal loops, to study the entire abdomen and pelvis. Delayed, axial and coronal images were always repeated at the level of the diseased bowel, approximately 3 min after injection of the contrast agent, to obtain a delayed venous phase. (d) Additional breath-hold BLADE T2-weighted sequences were always acquired in the case of complicated disease (fistulae, abscesses, multiple lymph nodes, adhesions) to evaluate the diseased intestinal segments at higher resolution than HASTE sequences, in order to confirm the abnormal findings. The overall examination time was approximately 30–40 min.

Lesion location and MRI scoring of disease activity In order to localise intestinal lesions, the small intestine was divided into three segments (jejunum, proximal-mid ileum, distal ileum), the colon into six (caecum, ascending, transverse, descending, sigmoid colon and rectum). The distal ileum refers to approximately the last 25–30 cm of the small bowel above the ileo-caecal valve. The distinction between jejunum and mid-proximal ileum was subjective and based on the abdominal distribution, course and features of the bowel loops. In case of previous ileo-caecal resection (less than 25 cm), the anastomotic ileal loop was considered as distal ileum, whereas the colonic anastomotic side was considered as caecum.

MRI studies were independently evaluated by two experienced radiologists on dedicated workstations (Syngo Acquisition Workplace, Siemens, Germany), blinded to the results of endoscopy, ultrasonography or other investigations. Results on which there was agreement by both radiologists were accepted. Disagreements were re-examined together by the two radiologists and settled after reaching a final consensus.

At the level of each intestinal segment, CD lesions were identified on the basis of well-established parameters [12–14, 19–25], including (a) concentric wall thickening (more than 4 mm), with or without fibrofatty proliferation on T1- and T2-weighted images; (b) increased mural hyperintensity on T2-weighted fat-suppressed images; (c) increased intestinal wall gadolinium enhancement on T1-weighted images; (d) perivisceral fat oedema on T2-weighted images; (e) number of enlarged mesenteric lymph nodes on T1- and T2-weighted

images [29] (Figs. 1 and 2). In order to assess and score CD disease activity at the level of the affected intestinal segments, the previous MRI parameters were qualitatively or quantitatively analysed and scored using a three-point scale system, according to well-established criteria [12, 13, 19–24, 30], as reported in Table 3.

A total basic score (ranging 0–18) was thus achieved for each patient. This score was further simplified, for analysis purposes, to a final 0–3 activity score: 0 for inactive disease (basic score range 0–1); 1 for low activity (basic score range 2–5); 2 for active disease (basic score range 6–12); 3 for extremely active/severe disease (basic score range 13–18) (Table 3).

Other diagnostic examinations

Within 10 days from MRI, CS with multiple biopsies, including evaluation of the ileo-caecal valve and terminal ileum, was performed by experienced gastroenterologists, both in AP and PP. Thus, in each patient gastroenterologists evaluated 7/9 segments, from the distal ileum to the rectum, by adopting the same radiological topographic criteria of MRI. The evidence of inflammatory lesions was based on well-established endoscopic criteria [2, 29] and scored as 0 (no activity), 1 (low activity), 2 (activity), 3 (high activity). MRI findings were compared (blinded) with endoscopic results with regard to the location of lesions and scoring of their activity.

To evaluate CD lesions in the upper gastrointestinal tract (jejunum and mid-proximal ileum), HRUS was performed in all patients using a 7.5-MHz probe, focused on the evaluation of the intestinal wall. The inflammatory activity was assessed by using the colour Doppler module and qualitatively scored 0–3, according to the degree of mural hypervascularity [31]. SBFT or CE was performed in doubtful cases only. Concordance between MRI findings and results of other examinations was calculated.

Data analysis

MRI results were analysed to determine, for both patients populations: (a) the overall incidence of upper gastrointestinal disease, of colonic disease, of terminal ileum disease, on a per patient basis; (b) the incidence of CD lesions at the level of each one of the nine different portions of the small or large bowel considered, on a per patient and per segment basis; (c) the degree of disease activity at the level of the small and large bowel; (d) association of different intestinal segments. Finally, results obtained in the two patient populations were directly compared.

Statistical analysis

Data are reported as absolute value and proportion, with 95 % confidence interval, and determined on a per patient and per segment basis. The differences between the two groups were analysed using Pearson chi-square or Fisher exact test, when appropriate. The 95 % confidence interval (CI) was calculated by using Wilson's method. P values less than 0.05 were considered statistically significant. All analyses were carried out with SPSS (version 13) and CIA software.

Results

MRE was performed in all patients. Ten children (23 %) could not completely drink the intestinal contrast agent; the overall diagnostic value of their examinations was, nonetheless, considered sufficient for evaluating the location and activity of lesions. CS and HRUS were performed in all patients. Results of HRUS were doubtful or incomplete in 20 PP and 18 AP, therefore second level examinations (SBFT and CE) were performed to complete the evaluation of the small bowel. In particular, SBFT were performed in 18/43 PP and 15/43 AP, whereas CE in 4/43 PP and 7/43 AP.

Overall intestinal involvement on a per patient basis

Overall involvement of the upper GI tract was higher in adults than in children, 49 % (21/43) versus 26 % (11/43), the difference being statistically significant ($P=0.039$). Involvement of the terminal ileum was significantly higher in adults than children ($P<0.0001$), being observed in 100 % of AP (43/43) versus 58 % of PP (25/43) (Fig. 3).

Involvement of the colon (isolated or associated with ileum) was higher in PP [(36/43 (84 %))] than AP [28/43 (64 %)], although the difference did not reach statistical significance ($P=0.062$) (Fig. 3). Sites of small and large bowel involvement on a per patient basis. Table 4 shows the percentage of involvement at the level of each of the nine different bowel segments, from the jejunum or the rectum, in AP and PP, on a per patient basis (Fig. 4).

No difference ($P=0.46$) was found between the paediatric and adult group with regard to the jejunal involvement (16 and 25 %, respectively), whereas a higher incidence of involvement of proximal-mid ileum (37 % vs 14 %, $P<0.05$) was observed in AP vs PP. Considering colonic segments, no difference was found with regard to the involvement of the caecum (30 % both groups), ascending colon (14 % PP, 16 % AP) or transverse colon (16 % PP, 14 % AP). Involvement of the sigmoid colon was higher in PP, although not significant (56 % PP,

37 % AP, $P=0.012$).

Conversely, the involvement of left colon and rectum was significantly higher in children (53 % and 67 %, respectively) as compared to adults (21 % and 23 %, respectively), $P < 0.01$ and $P < 0.001$, respectively.

Sites of small and large bowel involvement on a per segment basis

A total of 387 segments were evaluated both in adult and paediatric patients: 129 small bowel segments, 258 colonic segments (Tables 5 and 6). In PP, MRI detected CD lesions in 36% of segments (140/387), being concordant with other diagnostic examinations (CE, HRUS; SBFT) in 95 % of lesions (134/141, 6 false positive and 7 false negative results).

In AP, MRI detected lesions in 34 % of segments (132/387), being concordant with other examinations in (128/133, 4 false positive and 5 false negative results) (Table 7).

With regard to the small bowel, 55 % of segments (71/129) were found to be affected in adults while 29 % (38/129) in children, the difference being statistically significant ($P < 0.0001$), (Table 5). Disagreement between MRI and HRUS occurred in one paediatric patient and one adult, due to proximal-mid ileal lesions being found on MRI only (Table 7).

Regarding only the large bowel, the incidence of disease in colonic segments was significantly higher ($P < 0.0001$) in children with respect to adults: 40 % (102/258) versus 24 % (61/258) (Tables 5, 6 and 7, Fig. 5).

By considering each pathologic segment (Table 6, Fig. 5), a higher rate of involvement of mid-proximal and terminal ileum was observed in adults as compared to children ($P < 0.05$ and $P < 0.01$, respectively), whereas a higher incidence of disease was found in the descending colon and rectum in PP ($P < 0.01$ and $P < 0.01$, respectively). No differences were found regarding the remaining sites (Tables 4 and 5, Fig. 5).

Scoring of disease activity

1. Severe or high activity lesions (score 3) were observed in 34 % of the affected intestinal segments in children versus 9 % of segments in adults (Fig. 6). In children, 85 % of score-3 lesions were observed in segments of the colon-rectum (Figs. 1 and 6) whereas in adults 100 % score-3 lesions were in the distal ileum (Table 8, Fig. 6).

2. Active lesions (score 2) were observed in 47 % of the segments in children, in 60 % of segments in adults. In children 64 % of score-2 lesions were located in the colon, whereas in adults 56 % were in the distal ileum—small bowel (45/80) (Table 8, Figs. 2 and 6).

3. Low activity lesions (score 1) were observed in 18 % of diseased segments in PP, of which

73 % were in the colon. In AP these lesions were detected in 30 % of affected segments, of which 65 % were in the colon (Table 8, Fig. 6).

Associations of different intestinal segments

Some of the commonest associations of involved segments of the small and large bowel found in the two patient populations are reported in Table 9.

The isolated involvement of the terminal ileum was more frequently observed in adults than children (23 % versus 8 %) although the difference did not reach the statistical significance ($P=0.076$) (Table 9).

A statistically significant difference between adult and paediatric patients was found with regard to the isolated colonic involvement, observed in 30% of children but in none of the adults ($P<0.001$) (Table 9).

Discussion

Recent epidemiological data indicate an increased incidence of CD in childhood over the last four decades [2, 4] Furthermore, the latest clinical experience suggests that childhood-onset disease may have a different genetic basis and more "severe" phenotype than adult-onset disease, the former being characterized by an extensive intestinal involvement at presentation, frequently with a colitispredominant disease [3–10]. Despite these interesting clinical results, comparative morphologic data between adult and paediatric patients (AP, PP) affected by CD are limited. To date, the few comparative studies available are based on clinical retrospective data and do not show relevant differences with regard to the location and distribution of lesions [1, 2]. Undoubtedly, a comparative analysis is extremely demanding due to the complexity of evaluating the small and large bowel, particularly in paediatric patients, without invasiveness. The evaluation of the distribution of CD lesions usually requires multiple investigations, including colonoscopy, barium studies, ultrasonography and other procedures, like capsule endoscopy, if needed [11, 27, 28].

Besides, AP and PP are usually followed by different groups of clinicians and radiologists, using different diagnostic tools in the two patient populations. Nowadays, however, MRI has the diagnostic capability to replace almost entirely such multi-modality approaches, both in adult and paediatric patients, owing to the high diagnostic value, safety and lack of invasiveness. In adult patients, MRI performed with oral contrast agents (MRE) has shown an accuracy of approximately 90–95 % for jejunal and ileal lesions and 92–97 % for colonic

lesions [20–26], whereas in the assessment of CD activity it was considered comparable to endoscopy [11–14, 18–26].

To date, no previous study has prospectively compared adult and paediatric patients by using MRI. Therefore, the primary purpose of our study was to compare two large groups of patients affected by CD (overall 86), regarding the location, distribution of intestinal lesions and their degree of activity, by using MRE as the main reference examination. From this comparison, several relevant differences have emerged between the two groups.

Involvement of the terminal ileum was the primary location of CD in the adult population, observed in 100 % of AP, almost double the value in PP ($P < 0.0001$). In general, the involvement of the small bowel was significantly greater in adults than children (Figs. 3 and 4). On the other hand, in children the overall rate of colonic lesions (84 %) was higher than in adults (65 %). In particular, the incidence of disease in the left colonic segments (from descending colon to rectum) was approximately twofold higher in PP than in AP (Fig. 4). Above all, the descending colon and rectum were found to be more frequently involved in children than in adults (53 % and 67 % versus 21 % and 23 %, respectively), the difference being statistically significant ($P < 0.01$ and $P < 0.001$, respectively). Similarly, the sigmoid colon was involved in 56 % of children versus in 37 % of adults. With regard to the caecum, ascending and transverse colon, similar percentages were found in the two populations.

Undoubtedly, the involvement of the left colon was the primary site of CD in the paediatric population, rather than the distal ileum.

Another relevant difference between the two populations concerns the sites of highest disease activity. Severe (score-3) lesions were more frequently observed in PP (34 %) than AP (9 %), suggesting a more severe disease course in children. Moreover, in paediatric patients severe (score-3) lesions were found predominantly in the colon (87 %), whereas in adults such lesions were found in the distal ileum (100 %) (Fig. 6).

There are several possible clinical-diagnostic consequences of these data. From a diagnostic point of view, it is important to emphasize that, in the evaluation of CD, imaging investigations should contemporarily evaluate both small bowel and colon, especially in children. In the latter, the combination of colonoscopy and MRI is currently the best diagnostic option for a complete evaluation of IBD disease, including both mucosa profile and mural activity in the small and large bowel, perianal disease and complications.

The primary role of MRI in children affected by CD is to complete the information obtained by endoscopy, particularly on the severity of transmural inflammation in the colon and rectum. Furthermore, during acute phases of the disease, colonoscopy may be incomplete or

contraindicated due to the severity of colonic disease. In these cases, MRI may provide a complete and non-invasive evaluation of colonic disease.

In adult patients, MRI offers an excellent evaluation of the small bowel and particularly of the distal ileum, which is invariably the main CD location. However, MRI should also evaluate the colon in adults too. Many complications, such as adhesions, fistulae or abscesses, may involve both the small and large bowel. Moreover, the MRI assessment of the transmural inflammation is equally important, both in the small bowel and colon.

Information gained from MRI may have relevant clinical therapeutic implications, because the prevailing site of damage, as well as the occurrence of transmural or extra-wall complications, may influence the choice of drugs which have a particular target. Therefore, in the therapy decision-making process, it is relevant to detect the degree of severity of the disease both at the level of the colon and the small bowel. Finally, these results are interesting and exciting in the context of the general understanding of the disease. The reason why the disease is more aggressive and extensive in the colon rather than in the distal ileum in children is still unknown. The rapidly evolving disease in childhood age may partially explain how the disease could change from a predominantly left colonic disease in children, to a dominant distal ileal disease in adults. Longitudinal studies are warranted to evaluate how a prevailing colonic paediatric disease may evolve (or remain unchanged) into the adulthood. It is conceivable, however, that genetic, environmental or infective agents may cause a different severity and location of the lesions in the two patient groups. An age-related tendency for isolated colitis has been described in early childhood [9]. Several studies reported that in younger children NOD2/CARD15 genetic mutations are associated with colitis-predominant disease and less with isolated ileitis [6–10]. On the other hand, in genotype–phenotype association studies, it has been shown that NOD2 mutations are rather associated with ileal disease [32], whereas HLA region, in particular the DRB1*0103 allele, was associated with extensive colonic disease [33]. Only larger clinical studies will provide a definitive answer to these open questions. The main limitation of the present study consists in the relatively small number of patients in the two groups, as compared to larger clinical series. Available clinical comparative studies are multicentric, designed to assess several aspects of the disease, not only location or activity, and are necessarily based on numerous different investigations providing a heterogeneous assessment of CD. To our knowledge, a complete morphological comparison of the two groups of patients, performed by using the same non-invasive diagnostic tool, has never been published before. Another possible limitation relates to the use of MRE as the main reference examination, a choice that is open

to several criticisms. However, MRE has been shown to be a reliable all-in-one investigation in the clinical assessment of CD, able to provide the main information on the disease (activity, site, complications), otherwise obtained by different and invasive or radiation techniques [18, 19, 22–24]. Recently, it was stated that MRE could completely replace endoscopy in the assessment of disease activity [18, 19, 21]. In the next few years, thanks to its diagnostic value, lack of invasiveness and repeatability, MRI will likely play a major role in the investigation of the pathologic mechanisms underlying inflammatory bowel diseases. It is conceivable that MRI will become a primary diagnostic tool in clinical trials and for clinical research purposes.

In conclusion, MRE revealed several remarkable morphological differences between paediatric and adult patients affected by CD. Our results seem to suggest that paediatric disease could be considered as a “different entity” with respect to the adult one, the former being characterized by a more extensive and severe colonic involvement and a less frequent involvement of the terminal ileum. It is conceivable that in childhood age one or more different CD phenotypes may develop, showing different features and genetic basis with respect to the most common adult phenotypes. This hypothesis needs to be further addressed in larger clinical and diagnostic studies.

Acknowledgments

A particular thanks goes to Professor Renzo Caprilli, gastroenterologist, for his critical revision of the manuscript. We are very grateful to the intestinal pathologist Adriana Clark Marcheggiano and to the following gastroenterologists: Manuela Merli, Nadia Pallotta, Piero Vernia, Angelo Viscido, Maddalena Zippi, Claudio Papi, for having provided us with clinical information regarding adult Crohn's disease patients. We thank the paediatric radiologists Paolo Capocaccia and Mario Rogini for the radiological information on paediatric patients. We also thank the radiology technicians Giancarlo Prossamariti and Sante Iori. Finally, we thank Beatrice Bozzao for English editing.

References

1. Farmer RG, Hawk WA, Turnbull RB (1975) Clinical patterns in Crohn's disease: a statistical study of 615 cases. *Gastroenterol* 68:627–635
2. Vernier-Massouille G, Balde M, Salleron J et al (2008) Natural history of pediatric Crohn's

- disease: a population-based cohort study. *Gastroenterol* 135:1106–11
3. Van Limbergen J, Russel RK, Drummond HE et al (2008) Definition of phenotypic characteristics of childhood-onset inflammatory bowel disease. *Gastroenterol* 135:1114–1122
 4. Auvin S, Molinie F, Gower-Rousseau C et al (2005) Clinical presentation and location at diagnosis of pediatric inflammatory bowel disease: a prospective population-based study in Northern France (1988–1999). *J Pediatric Gastroenterol Nutr* 41:49–55
 5. Heyman MB, Kirschner BS, Gold BD et al (2005) Children with early onset inflammatory bowel disease (IBD): analysis of a pediatric IBD consortium registry. *J Pediatr* 146:35–40
 6. Paul TM, Birnbaum AM, Pal DKP et al (2006) Distinct phenotype of early childhood inflammatory bowel disease. *J Clin Gastroenterol* 40:583–586
 7. Gupta N, Bostrom AG, Kirschner BS et al (2008) Presentation and disease course in early- compared to later-onset pediatric Crohn's disease. *Am J Gastroenterol* 103:2092–8
 8. Meinzer U, Idestrom M, Alberti C et al (2005) Ileal involvement is age-dependent in paediatric Crohn's disease. *Inflamm Bowel Dis* 11:639–644
 9. Levine A, Kugathasan S, Annese V et al (2007) Pediatric onset Crohn's colitis is characterized by genotype-dependent age-related susceptibility. *Inflamm Bowel* 13:1509–1515
 10. Cucchiara S, Latiano A, Palmieri O et al (2007) Polymorphisms of tumor necrosis factor-[alpha] but not MDR1 influence response to medical therapy in paediatric-onset inflammatory bowel disease. *J Pediatr Gastroenterol* 44:171–179
 11. MacKalski BA, Bernstein CN (2006) New diagnostic imaging tools for inflammatory bowel disease. *Gut* 55:733–741
 12. Maccioni F, Viscido A, Broglia L et al (2000) Evaluation of Crohn's disease activity with MRI. *Abdom Imaging* 25:219–28
 13. Koh DM, Miao Y, Chinn RJS et al (2001) MRI imaging evaluation of the activity of Crohn's disease. *AJR Am J Roentgenol* 177:1325–32
 14. Low RN, Sebrechts CP, Politoske DA (2002) Crohn disease with endoscopic correlation: single shot fast spin echo and gadoliniumenhanced fat suppressed spoiled gradient echo MR imaging. *Radiol* 222:652–60
 15. Albert JG, Martiny F, Krummenerl A et al (2005) Diagnosis of small bowel Crohn's disease: a prospective comparison of capsule endoscopy with magnetic resonance imaging and fluoroscopic enteroclysis. *Gut* 54:1721–1727
 16. Martin DR, Lauenstein T, Sitaraman SV (2007) Utility of magnetic resonance imaging in

- small bowel Crohn's disease. *Gastroenterol* 133:385–90
17. Lin MF, Narra V (2008) Developing role of magnetic resonance imaging in Crohn's disease. *Curr Opin Gastroenterol* 24:135–14
 18. Javier Sempere GA, Sanjuan VM, Chulia EM (2005) MRI evaluation of inflammatory activity in Crohn's disease. *AJR* 184:1829–1835
 19. Ajaj WM, Lauenstein TC, Pelster G et al (2005) Magnetic resonance colonography for the detection of inflammatory diseases of the large bowel: quantifying the inflammatory activity. *Gut* 54:257–263
 20. Maccioni F, Bruni A, Viscido A et al (2006) MR imaging in patients with Crohn disease: value of T2- versus T1-weighted gadolinium-enhanced MR sequences with use of an oral superparamagnetic contrast agent. *Radiol* 238:517–530
 21. Rimola J, Rodriguez S, García-Bosch O et al (2009) Magnetic resonance for assessment of disease activity and severity in ileocolonic Crohn's disease. *Gut* 58:1113–20
 22. Horsthuis K, Bipat S, Stokkers PCF, Stoker J (2009) Magnetic resonance imaging for evaluation of disease activity in Crohn's disease: a systematic review. *Eur Radiol* 19:1450–1460
 23. Hafeez R, Punwani S, Pendse D et al (2011) Derivation of a T2-weighted MRI total colonic inflammation score (TCIS) for assessment of patients with severe acute inflammatory colitis—a preliminary study. *Eur Radiol* 21:366–77
 24. Cronin CG, Lohan DG, Browne AM et al (2010) Does MRI with oral contrast medium allow single-study depiction of inflammatory bowel disease enteritis and colitis? *Eur Radiol* 20:1667–74
 25. Laghi A, Borrelli O, Paolantonio P, Dito L, Bueno de Mesquita M, Falconieri P, Passariello R, Cucchiara S (2003) Contrast enhanced magnetic resonance imaging of the terminal ileum in children with Crohn's disease. *Gut* 52:393–397
 26. Casciani E, Masselli G, Di Nardo G et al (2011) MR enterography versus capsule endoscopy in paediatric patients with suspected Crohn's disease. *Eur Radiol* 21:823–31
 27. Wills JS, Lobis IF, Denstman FJ (1997) Crohn's disease: state of the art. *Radiology* 2597–610
 28. Stange EF, Travis SPL, Vermeire S et al (2006) European evidence based consensus on the diagnosis and management of Crohn's disease: definitions and diagnosis. *Gut* 55:i1–i15
 29. D'Haens GR, Geboes K, Peeters M et al (1998) Early lesions of recurrent Crohn's disease caused by infusion of intestinal contents in excluded ileum. *Gastroenterol*

114:262–7

30. Gourtsoyianni S, Papanikolaou N, Amanakis E, Bourikas L, Roussomoustakaki M, Grammatikakis J, Gourtsoyiannis N (2009) Crohn's disease lymphadenopathy: MR imaging findings. *Eur J Radiol* 69:425–8
31. Drews BH, Barth TFE, Hanle MM, Akinli AS, Mason RA, Muche R, Thiel R (2009) Comparison of sonographically measured bowel wall vascularity, histology and disease activity in Crohn's disease. *Eur Radiol* 19:1379–1386
32. Cuthbert AP, Fisher SA, Mirza MM et al (2002) The contribution of NOD gene mutations to the risk and site of disease in inflammatory bowel disease. *Gastroenterol* 122:867–874
33. Lesage S, Zouali H, Cezard JP et al (2002) CARD 15/NOD2 mutational analysis and genotype correlation in 612 patients with inflammatory bowel disease. *Am J Hum Genet* 70:845–857

Table 1
Clinical data of adult and paediatric patients

Sex	Age at referral (years)	Age at diagnosis (years)	Exam date	Disease duration (years)	Previous surgery	Treatment
43 paediatric patients (PP)						
21 females, 22 males	14.8 (8–18)	11.9 (5–18)	2009–2010	3.1	2 patients had ileo-caecal resection	All 43 patients receiving pharmacological treatment
43 adult patients (AP)						
16 females, 27 males	46.6 (21–77)	38.9 (5–73)	2009–2010	8.3	3 patients had ileo-caecal resection, 1 patient had abscess drainage	36/43 patients receiving pharmacological treatment

Age data are presented as median (range).

Table 2
MR imaging parameters

	T2w HASTE	T2w fat-suppressed HASTE	T2w BLADE-TSE	T1w VIBE
Repetition time (ms)	1000	1000	3880	6
Echo time (ms)	85	85	130	2.7/3
Section thickness (mm)	6	40	6	3/3.5
Slice/s	30/20	30/23	10/20	30/19
Slice gap (%)	10–0	10	10	3D
Matrix	256×182	320×164	356×256	256×159
FOV (mm ²)	350	350	350×350	350
Flip angle (°)	150–180	150–180	150	10
Slice orientation	Axial-Coronal	Axial	Axial-Coronal	Axial-Coronal

HASTE half-Fourier single-shot turbo spin-echo, VIBE volumetric interpolated breath-hold examination, BLADE-TSE BLADE (breath-hold) turbo spin echo, FOV field of view.

Table 3
MRI assessment of CD activity: activity parameters and relative scores

Parameter	Score 0	Score 1	Score 2	Score 3
A Wall thickening (T1-T2 w images)	<4 mm	4–6 mm	6–8 mm	>8 mm
B Wall Gd-enhancement (T1 w images)	Normal ^a	Present–fair (lower/equal to spleen)	Well evident–high (comparable to renal cortex)	Extremely high–marked (comparable to arterial vessels)
C T2 wall signal intensity (T2 w fat-suppressed images)	Normal ^a	Present–fair (lower than spleen)	Well evident-high (comparable to spleen/renal cortex)	Extremely high–marked (comparable to CSF)
D Perivisceral oedema (T2 w fat-suppressed images)	Absent	Present–fair	Well evident	Extremely high–marked
E Active local lymph nodes ^b	None	1–2	3–5	>5
F Local abscess phlegmons	None	2 cm in diameter	2–3 cm in diameter	>3 cm in diameter

Final Activity Score: range 0–1 inactive disease (Activity Score 0); range 2–5 low activity (Activity Score 1); range 6–12 active disease (Activity Score 2); range 13–18 extremely active-severe disease (Activity Score 3).

^aEqual to the signal of the normal bowel wall.

^bEnlarged and hyperintense on T2 weighted and T1w Gd-enhanced images.

Table 4
Per patient analysis: relative incidence (%) of affected small and large bowel segments, from the jejunum to the rectum, detected by MRE in the paediatric and adult population, on a per patient basis

Lesion location	Paediatric patients (n=43)	Adult patients (n = 43)	P value	95 % CI for difference
Jejunum	7/43 (16.2 %)	11/43 (25.5 %)	0.426	(-0.26 to -0.08)
Mid-prox ileum	6/43 (13.9 %)	16/43 (37 %)	0.027*	(-0.42 to 0.047)
Terminal ileum	25/43 (58 %)	43/43 (100 %)	<0.0001**	(-0.51 to -0.25)
Caecum	13/43 (30 %)	13/43 (30 %)	0.814	(-0.19 to 0.19)
Ascending colon	6/43 (14 %)	7/43 (16 %)	0.966	(-0.17 to 0.13)
Transverse colon	7/43 (16 %)	6/43 (14 %)	0.966	(-0.13 to 0.17)
Descending colon	23/43 (53 %)	9/43 (21 %)	0.004 #	(0.12 to 0.52)
Sigmoid colon	24/43 (56 %)	16/43 (37 %)	0.121	(-0.02 to 0.40)
Rectum	29/43 (67 %)	10/43 (23 %)	<0.0001**	(0.23 to 0.65)

The difference between the paediatric and adult patients was considered statistically significant for $p < 0.05$ (see Fig. 4, where statistically significant differences were further differentiated for * $p < 0.05$, # $p < 0.01$ and ** $p < 0.001$). 95 % CI relative 95 % confidence interval.

Table 5
Per segment analysis

Segments	Paediatric patients (segments %)	Adult patients (segments %)	P	95 % CI for difference
Total no. affected segments/total no. assessed ^a	140/387 (36 %)	132/387 (34 %)	0.612	-0.05 to 0.09
Small bowel affected/total affected segments	38/140 (28 %)	71/132 (54 %)	<0.0001	-0.37 to -0.15
Large bowel affected/total affected segments	102/140 (73 %)	61/132 (46 %)	<0.0001	0.15 to 0.37
Small bowel affected/small bowel evaluated	38/129 (29 %)	71/129 (55 %)	<0.0001	-0.37 to -0.14
Large bowel affected/large bowel evaluated	102/258 (40 %)	61/258 (24 %)	<0.0001	0.08 to 0.24

The difference between the paediatric and adult patients was considered statistically significant for $p < 0.05$.

^aA total of 9 bowel segments x 43 patients (387 segments) were assessed by MRE both in the adult and paediatric group: 129 small bowel and 258 large bowel segments.

Table 6
Per segment analysis

Lesion location on MRE	Paediatric patients ^a	Adult patients ^a	P value	95 % CI for difference
Jejunum	7/140 (5 %)	11/132 (8 %)	0.448 (NS)	-0.10 to 0.03
Upper-mid ileum	6/140 (4 %)	17/132 (13 %)	0.026 (<0.05)	-0.16 to -0.02
Terminal ileum	25/140 (18 %)	43/132 (32 %)	0.007 (< 0.01)	-0.25 to -0.04
Caecum	13/140 (9 %)	13/132 (10 %)	0.941 (NS)	-0.08 to 0.07
Ascending colon	6/140 (4 %)	7/132 (5 %)	0.916 (NS)	-0.07 to 0.04
Transverse colon	7/140 (5 %)	6/132 (5 %)	0.781 (NS)	-0.05 to 0.06
Descending colon	23/140 (17 %)	9/132 (7 %)	0.034 (<0.05)	0.02 to 0.17
Sigmoid colon	24/140 (17 %)	16/132 (12 %)	0.319 (NS)	-0.04 to 0.13
Rectum	29/140 (21 %)	10/132 (8 %)	0.004 (<0.01)	0.05 to 0.21

This table reports the data shown in Fig. 5. The difference between the paediatric and adult patients was considered statistically significant for $p < 0.05$ NS not significant.

^aData are number of affected segments over total number of pathologic segments with percentage in parenthesis.

Table 7
False positive and false negative results of MRE

	Intestinal segments	Upper GI	Distal ileum	Colon
Paediatric patients				
True positive	134	12	25	97
True negative	240	73	18	149
False positive	6	1	0	5
False negative	7	0	0	7
Adult patients				
True positive	128	27	43	58
True negative	250	58	0	192
False positive	4	1	0	3
False negative	5	0	0	5

First-level reference examinations were high resolution ultrasonography (HRUS) of the upper GI and distal ileum and ileocolonoscopy (CS) of the distal ileum and colon. Second-level reference examinations were small bowel follow-through (SBFT) and capsule endoscopy (CE) of the small bowel.

Table 8
MRI activity scores in adult and children

	Adult patients	Paediatric patients
Score 3 (very high)	12/132 (9 %) 12/12 terminal ileum 0 colon	48/140 (34 %) 41/48 (85 %) colon-rectum 7/48 (15 %) small bowel
Score 2 (activity)	80/132 (60 %) 45/80 (56 %) terminal ileum- small bowel 35/80 (44 %) colon-rectum	66/140 (47 %) 24/66 (36 %) terminal ileum-small bowel 42/66 (64 %) colon-rectum
Score 1 (low activity)	40/132 (30 %) 14/40 (35 %) terminal ileum- small bowel 26/40 (65 %) colon-rectum	26/140 (18 %) 7/26 (27 %) terminal ileum-small bowel 19/26 (73 %) colon-rectum

Table 9
Associated involvement of different segments of the small and large bowel

Association of diseased segments on MRE	Adult patients	Paediatric patients	<i>P</i> value
Isolated involvement of terminal ileum	10 (23 %)	3 (8 %)	0.076
Isolated colonic involvement	0	13 (30 %)	<0.0001
Isolated upper GI, proximal ileum or jejunum	0	0	NS
Small bowel (any tract) + colonic segments (any tract)	33 (74 %)	27 (63 %)	NS
Caecum + terminal ileum	13 (30 %)	8 (18 %)	NS

The difference between the paediatric and adult patients was considered statistically significant for $p < 0.05$. NS not significant.

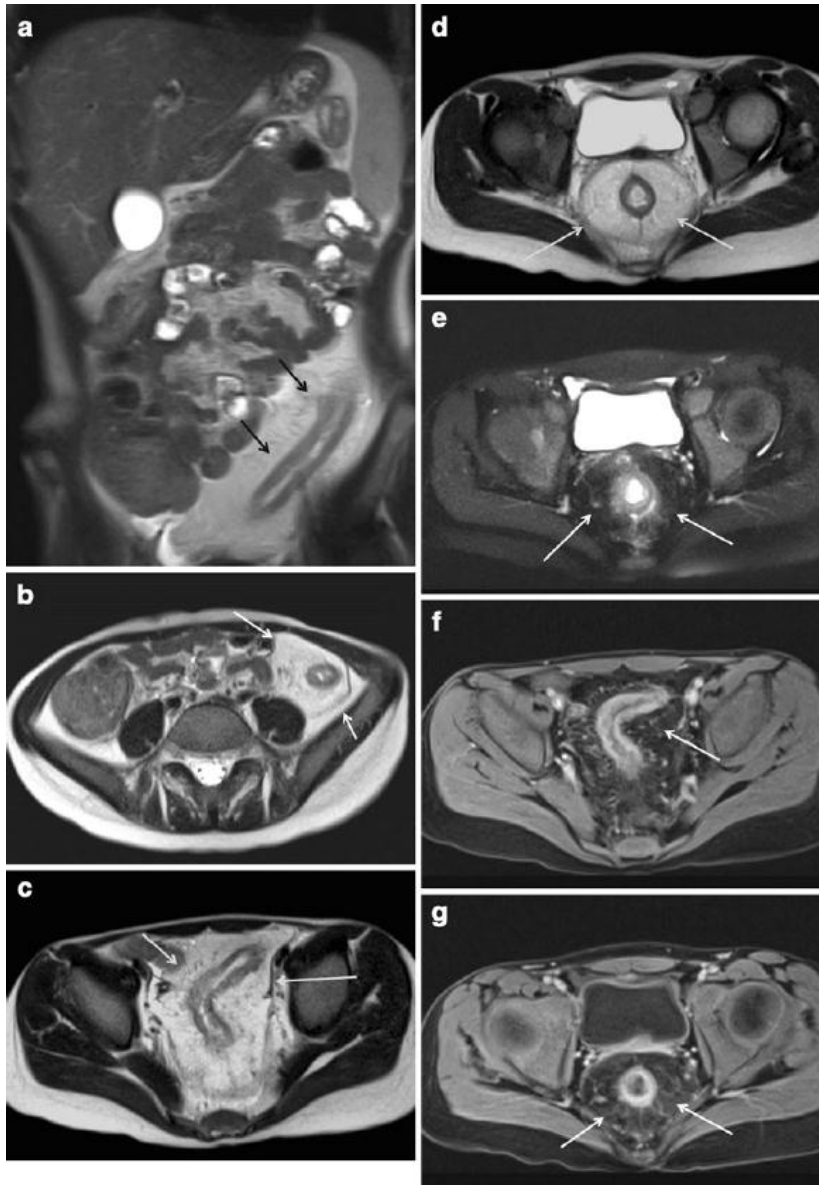


Figure 1

A 12-year-old girl with extensive and severe CD (score-3 lesions) of the descending colon, sigmoid colon and rectum. All disease sites were detected by MRI and confirmed by colon-ileoscopy. a Coronal T2-weighted image shows disease of the left colon (black arrows), with marked mesenteric hypertrophy. No other signs of inflammation were observed on MR images at the level of the remaining segments of the small and large bowel. The signal intensity of the bowel appears inhomogeneous since the child could not completely drink the oral contrast. Nonetheless, the colorectal involvement is clearly evident, as well as the sparing of the ileocecal region. Axial T2-weighted HASTE images show marked concentric intestinal wall thickening (9–10 mm) at the level of the descending colon (b), sigmoid colon (c) and rectum (d) with remarkable mesenteric hypertrophy (white arrows) and mesorectal fat hypertrophy (white arrows). (e) Axial T2-weighted fatsuppressed HASTE image shows high grade intestinal wall T2-signal (score-3 lesion) due to oedema (arrow) at the level of the rectum, with mesorectal fat oedema and small local lymph nodes (arrows). Axial T1-weighted VIBE image, acquired after gadolinium injection (same level as Fig. 1d), showing severe involvement of the sigmoid colon (f) and rectum (g) with high grade gadolinium enhancement (score-3 lesions).

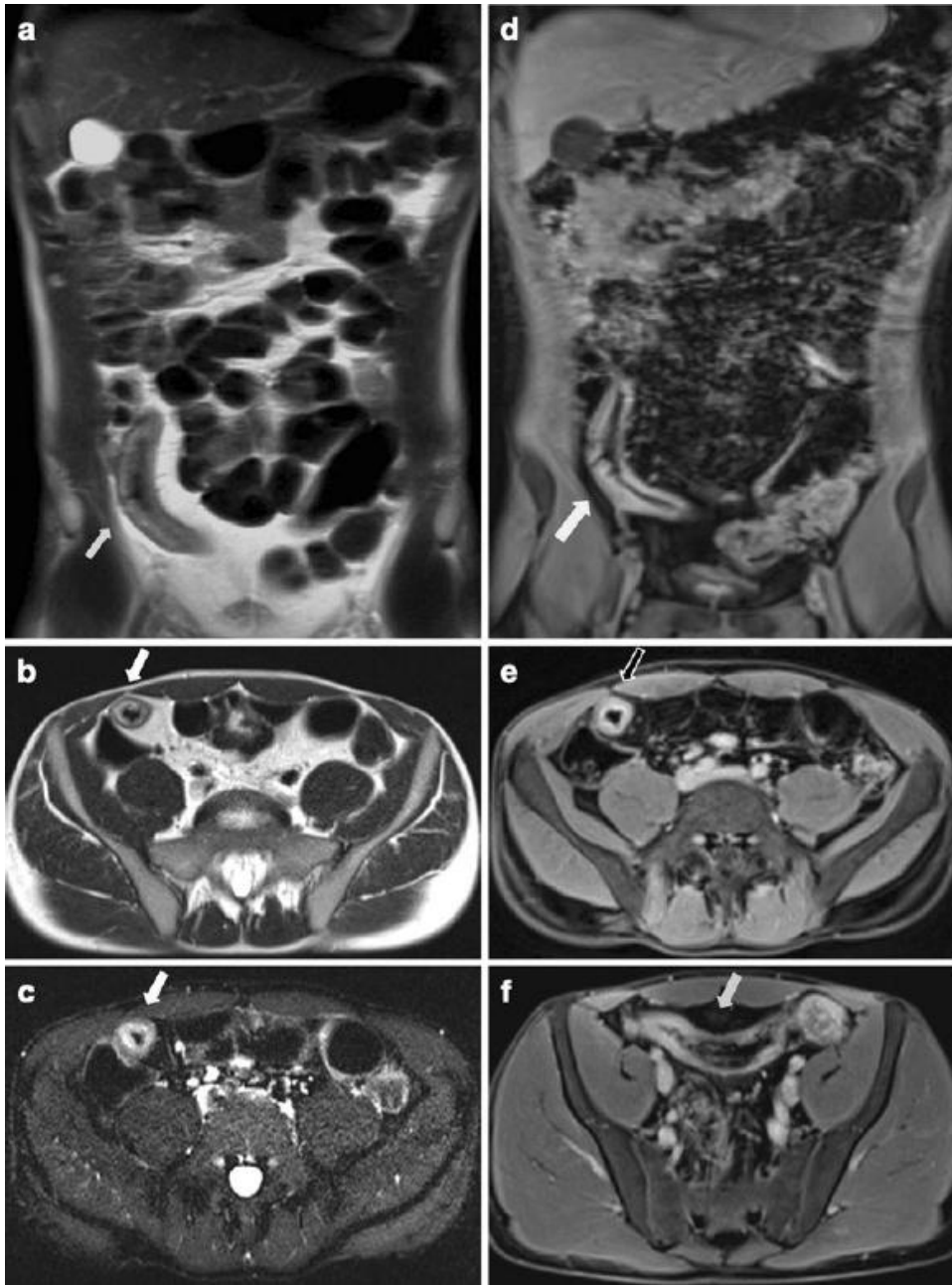


Figure 2

A 25-year-old man affected by active ileo-caecal CD (score-2 lesions). (a) Coronal T2-weighted HASTE image showing a 20-cm-long stricture (arrow) of the terminal ileum, associated with local mesenteric fat hypertrophy. (b) Axial T2-weighted image demonstrates remarkable wall thickening and wall oedema (arrow) at the level of the distal ileum, due to mural and transmural inflammation. (c) Axial T2-weighted axial fat-suppressed image obtained at the same level as Fig. 2b, showing diffuse hyperintensity of the thickened wall (arrow), related to oedema and inflammatory changes. Coronal (d) and axial (e-f) T1-weighted post-Gd images, obtained at the same level as Figs. 2a-c, reveal marked concentric wall thickening and enhancement (arrows) of the distal ileum, associated with increased mesenteric vascularity. These findings, suggestive of active CD (score-2 lesion) located in the distal ileum, were confirmed by ileo-colonoscopy.

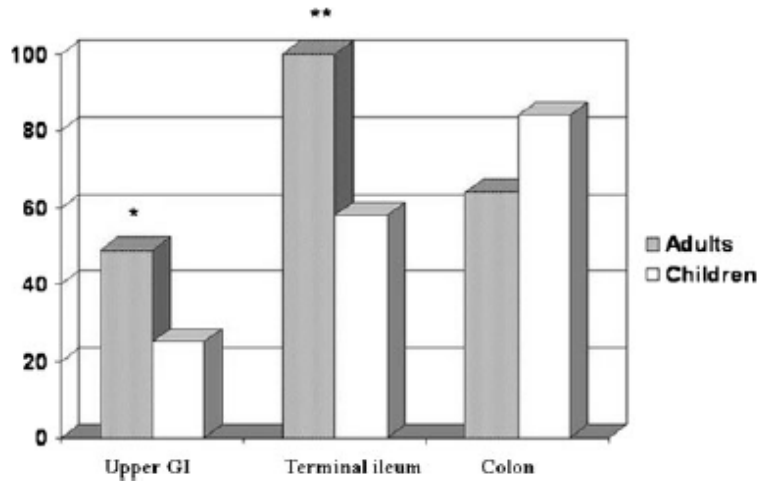


Figure 3

Different percentages of disease involvement of the small and large bowel on per patient analysis. Upper GI: involvement of the upper GI tract only (jejunum plus proximal-mid ileum), independently from associated lesions; terminal ileum: involvement of the terminal ileum only; colon: involvement of the entire colon, in both groups of patients. Statistically significant difference was observed between AP and PP in the first two pairs of columns: * $p < 0.05$, ** $p < 0.001$.

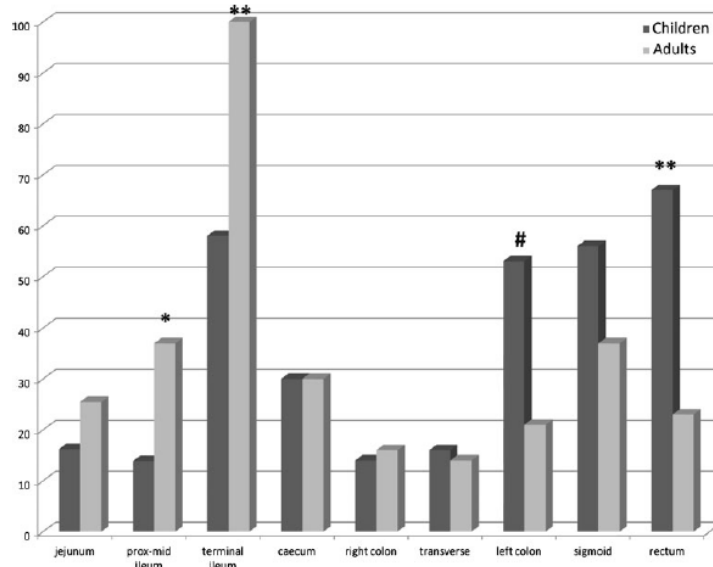


Figure 4

Percentage of each of the nine affected segments in the small and large bowel in both groups of patients on per patient basis, as reported in Table 4. * $p < 0.05$, # $p < 0.01$, ** $p < 0.001$.

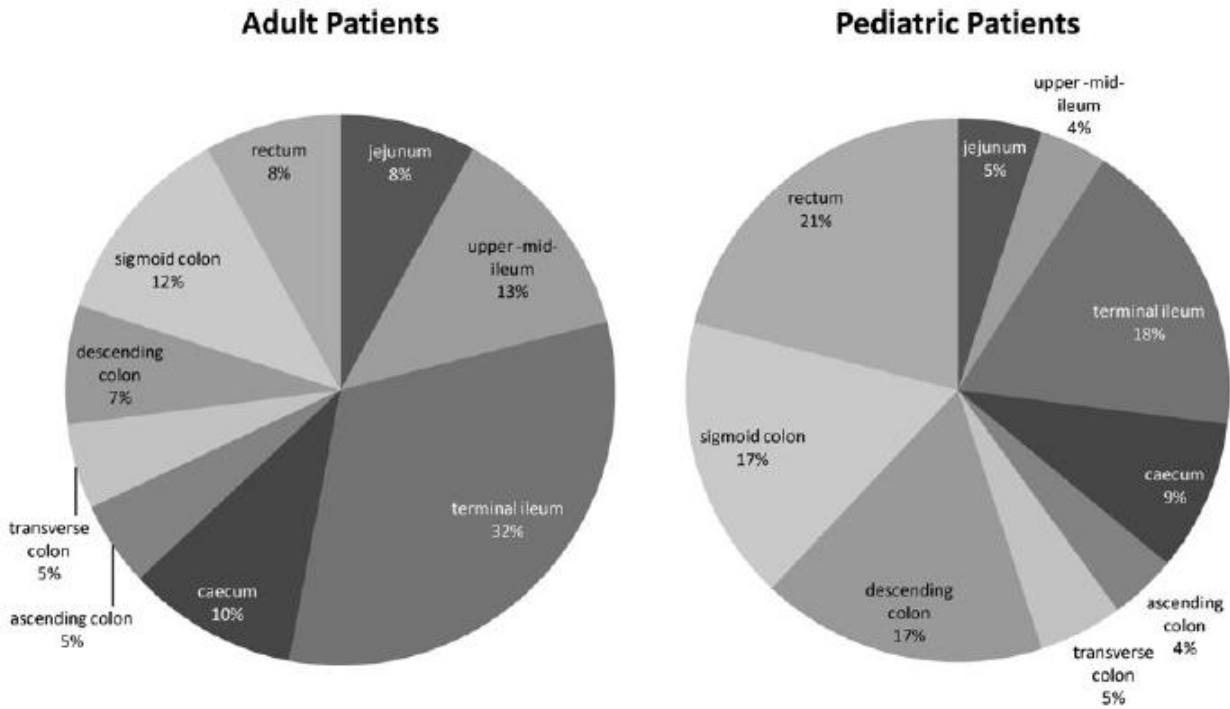


Figure 5 Percentage of the affected segments over the total number of affected segments in the small bowel and large bowel in adult (a) and paediatric patients (b) on per segment analysis, as reported in Table 6. *p<0.05, **p<0.01.

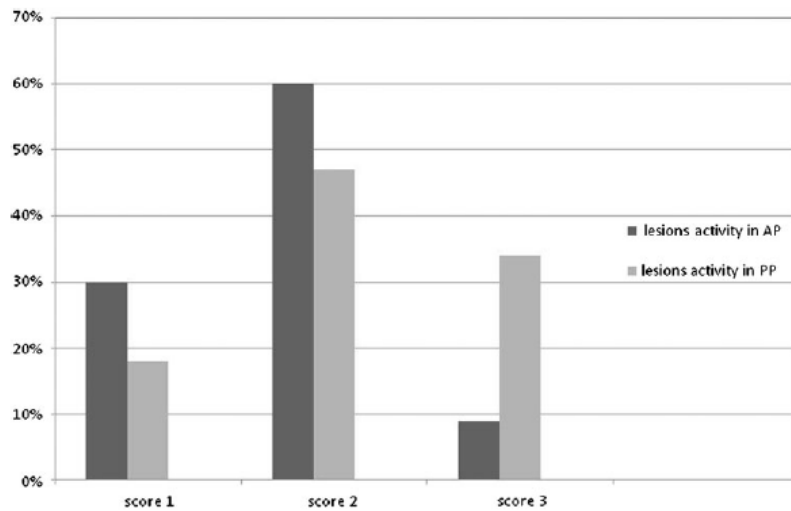


Figure 6 Activity scores in adult (AP) and children (PP): a higher percentage of high activity lesions (score 3) is observed in the PP: 34 % vs 9 %. Low activity (score 1) lesions are more frequently observed in AP (30 %) vs PP (18 %). Active (score 2) lesions are observed in 60 % of AP and 47 % of PP, as reported in Table 8.



Picture by Francesca Maccioni 2010
Sunset from the dining room window (H)

Chapter 9

New frontiers of MRI in Crohn's disease: motility imaging, diffusion-weighted imaging, perfusion MRI, MR spectroscopy, molecular imaging, and hybrid imaging (PET/MRI)

Maccioni F³, Patak MA¹, Signore A², Laghi A⁴.

Abdom Imaging. 2012; 37(6):974-82

1University Hospital Zu" rich, Zu" rich, Switzerland

2Nuclear Medicine Unit, Medical-Surgical Dept of Clinical Sciences, Technobiomedicine and Translational Medicine, "Sapienza" University of Rome, Ospedale S. Andrea, Rome, Italy

3Department of Radiological Sciences, Oncology and Pathology, "Sapienza" University of Rome, Policlinico Umberto I Hospital, Rome, Italy

4Department of Radiological Sciences, Oncology and Pathology, "Sapienza" University of Rome, Polo Pontino, ICOT Hospital, Latina, Italy

Abstract

This article reviews the latest diagnostic advances in the evaluation of the CD, including functional studies on intestinal motility and molecular characterization of the inflammatory process at the level of the involved bowel.

Molecular changes related to inflammation of the intestinal wall may be evaluated by different MRI techniques, including diffusion-weighted imaging, perfusion weighted imaging, in vivo spectroscopy, molecular imaging, and fusion imaging (PET–MRI).

Key words

Magnetic resonance imaging—Crohn's disease—Diffusion weighted imaging—Perfusion imaging—Magnetic resonance spectroscopy—Molecular imaging—PET–MRI

Introduction

The newest applications of MRI have still unknown potentials in the evaluation of the bowel wall abnormalities of the Crohn's disease (CD). So far, most of these MRI techniques have been applied to neurologic or oncologic diseases, such as diffusion-weighted imaging (DWI), magnetic resonance spectroscopy (MRS), and perfusion imaging. In the coming years, however, certainly the role of these advanced imaging techniques is destined to expand and become increasingly important also in the evaluation and characterization of CD. Similarly, it is conceivable that further developments of MR molecular imaging and PET–MRI, nowadays purely experimental, will provide relevant information on active inflammatory cells in CD.

Motility imaging in CD

The peristaltic contractions of the small bowel mix the food, homogenize it with digestive enzymes and therefore optimize the extraction of nutrition. Furthermore this motility, coordinated contractions of the smooth muscle cells within the bowel wall, propels the food through the gastrointestinal (GI) tube from the mouth to the rectum.

The use of MRI as a tool to depict and monitor small bowel motility could have an impact on the research on small bowel physiology and the diagnosis of small bowel pathologies. The sequence to acquire small bowel motility is a fast cine sequence using fast T2-weighted SSFP or echo planar imaging sequences with a maximum repetition time of 1 s. These sequences allow the repeated acquisition of images every 300–1000 ms on the same plane for one breath hold period (Fig. 1A). The aim is to cover the whole abdomen with repetitive sequences using a slice thickness of 10 mm, needing overall 10–15 sequences, depending on the patient's size. Motility imaging can be done in about 10–15 min. It is important for the planning of imaging is that motility images must be acquired before the application of a spasmolytic drug such as glucagon or n-hyoscine (Buscopan®, Boehringer Ingelheim, Basel, Switzerland) [1]. Evaluation of these images should be done in two stages: first, the qualitative stage is the primary visual assessment of cine loops to obtain an overview of small bowel motility of a patient.

Most of the segments present about the same bowel wall motion pattern of regular contractions. Other segments may stand still, move slower or faster. The direct comparison of segments within the same patient is helpful to get an overview. Segments that display a markedly slower or absent motility are usually evidence of bowel wall pathology. The second

step is quantitative where the bowel wall motion and peristalsis are measured as change of cross-section diameter over time [2]. As measurement of the luminal diameter by hand is time consuming and potentially burdened with error, software has been developed to automatically measure these small bowel diameters and display them as a plot over time (Fig. 1B). This dedicated software speeds up this stage of motility analysis and minimizes user generated errors [3–6].

Many pathologies affecting the small bowel can alter its motility (diabetes, obstipation, functional dyspepsia, irritable bowel syndrome, and visceral inflammatory neuropathies) [7]. Crohn's disease (CD) also affects motility of inflamed small bowel segments, a phenomenon known from fluoroscopy. The use of MR motility imaging to evaluate CD-related affected bowel segments showed a significant increase in the number of lesions in each patient and a significant increase in the overall number of patients with CD-lesions [8]. Of 40 patients included in the study, 26 CD-related lesions were found by standard MRE, compared to 35 lesions using additional motility imaging ($P = 0.001$). Only 25 patients were found to have CD-related lesions by standard imaging but 34 patients were identified by analysis of motility ($P = 0.007$). Clearly, MR motility imaging in patients with inflammatory bowel disease has improved the diagnosis of CD. Another study could prove the correlation between histopathological changes and motility alteration. In a retrospective study with 43 enrolled patients, evaluation was done on the level of the terminal ileum between motility and local biopsy. Motility was classified as normal, hypomotility, and complete arrest. Biopsies were evaluated for the activity of the disease and the amount of chronic inflammatory changes. The presence and grading of motility alterations significantly correlated with histopathology in both active and chronic signs. Motility changes of the terminal ileum show a highly significant correlation to histopathological changes both in active and chronic CD not only for the presence of disease but also for its severity. It seems that the motility changes are more a grading for severity of the disease than a predictor of activity [9]. In conclusion, motility can be quantified by MR-imaging. The use of semiautomatic software tremendously helps the evaluation process. There is clear evidence that the evaluation of motility alterations may help to increase the sensitivity and specificity of MRI of the small bowel. Further studies are needed to establish fundamental classifications of motility disorders as assessed by MRI.

DWI in CD

The process of diffusion of water molecules in biological tissues is caused by their random translational motion, also known Brownian motion. DW-MRI is the only imaging method that

can evaluate the diffusion process in vivo [10]. The speed of diffusion of water molecules is different in the extracellular and intracellular components of the tissues [10, 11]. The apparent diffusion coefficients (ADCs) are quantitative expressions of the diffusion characteristics of tissues. Numerous studies have proved that ADC values decrease with increased tissue cellularity or cell density, showing that DW-MRI is sensitive for differentiating histopathologic tissue characteristics [10]. High ADC values express free diffusion of water molecules and are typical for healthy tissues or benign pathologic processes, while low values, that express a restricted diffusion, may indicate malignancies or high cellularity [10]. In the last two decades, DW-MRI has been widely used in neuroimaging, whereas its application within the abdomen is relatively recent, due to the availability of newer acquisition techniques less sensitive to the peristalsis and respiratory movements [12].

Several preliminary studies [13–17] have tested the efficacy of DWI in detecting wall inflammation in CD, although results still need further validation and leave some open questions. All authors agree that in active CD the diffusion is restricted at the level of the inflamed wall in CD. However, histopathology features underlying such restriction are still unclear.

Kilickesmez et al. [13] by using DW-MRI in 14 patients with rectal-sigmoid colon cancer and in 9 patients with IBD, detected restriction of diffusion in all subjects, although less pronounced in patients with IBD. The restriction, measured at the level of the intestinal walls of patients with IBD, was explained by the authors as an increase of cellularity in the inflammatory phase of the disease. In another study, Kiryu et al. [14] compared the ADC values of intestinal segments (from jejunum to rectum) with those of inactive active segments on the basis of signal intensity in diffusion-weighted sequences, as expressed in the values of b equal to 800 s/mm². They found a restriction of diffusion at the level of active segments as compared to non-active ones, without use of oral contrast. This study also demonstrated a difference of restriction between small and large intestines, ADC values being lower for the large intestine, likely due to viscosity of the luminal content. Oto et al. [15] in a preliminary study on DWI in CD evaluated 39 intestinal segments with a robust gold standard, 19 of them showed active inflammation. A restricted diffusion was demonstrated at the level of the inflamed intestinal segments. The mean ADC values of proven inflamed bowels was $1.59 \pm 0.45 \times 10^{-3}$ mm²/s compared to $2.74 \pm 0.68 \times 10^{-3}$ mm²/s in normal bowel segments ($P < 0.0001$) In a more recent published study [16], based on a larger series, Oto et al. reported a comparison between perfusion imaging and DWI in 18 patients. Dynamic contrast-enhanced MRI (DCE-MRI) and DWI can both provide quantitative measures of small bowel inflammation, helpful in

differentiating actively inflamed small bowel segments from normal small bowel in CD. DWI provided better sensitivity compared with DCE-MRI, while a combination of ADC and K(trans) parameters for analysis improved overall specificity.

Oussalah et al. [17] recently reported clinical–radiological results obtained with DW-MRI on 96 patients with IBD, 35 with ulcerative colitis (UC), and 61 with CD. A segmental magnetic resonance score (MR-score-S) based on DWI values and other MRI parameters detected endoscopic inflammation with a sensitivity and specificity of 89.4 % and 86.6 % in UC, while of 58.33 % and 84.48 % in CD, respectively. They stated that in patients with UC it is possible to replace completely the use of the intravenous contrast medium with MR-DWI in the identification of active inflammatory bowel segments. In fact, UC is characterized by a continuous diffuse inflammation of the intestinal wall that makes it well detectable with DWI, in contrast to the segmental distribution of Crohn's disease that makes more difficult to correctly identify diseased segments. A bias of this study is likely related to the complete lack of bowel preparation and the use of a score based on different parameters, rather than DWI/ADC values only.

In conclusion, preliminary results suggest that active wall inflammation in CD determines a restricted diffusion.

It is unclear, however, if this applies to acute wall inflammation (edema) only, or wall fibrosis only, or inflammation associated with fibrosis. Further studies are needed to determine whether and how this correlates to the degree of wall inflammation and/or fibrosis. We agree with Oto et al. [15] “Explanation of the reason for restricted diffusion in the inflamed bowel is a challenging issue that warrants further studies, and at this point, we can only speculate about possible mechanisms”. It is likely that lymphocyte aggregates, dilation of lymphatic ducts, hypertrophy of neuronal tissue, and the presence of granulomas in the intestinal wall, occupying and increasing the extracellular space, may contribute to induce restriction to the diffusion of water molecules, similarly to what happens in the brain in the presence of abscesses or in renal parenchyma in case of pyelonephritis [15]. The presence of fibrosis in the intestinal wall, frequently observed in advanced Crohn's disease, could determine a restricted diffusion, as already observed by several AA [18] in liver cirrhosis.

A possible limit of previously published studies may be related to the overestimation of the ADC value of normal wall, as the ROI may frequently include both the ADC value of the wall and of the intestinal fluid. The normal bowel wall is so thin that to place an ROI on the ADC map is challenging. As a matter of fact, the reproducibility of ADC samples is extremely difficult at the level of the bowel wall. In CD, ADC values may significantly vary throughout the

same segment.

According to our personal experience [19], restriction of diffusion is more frequently observed in the presence of active disease associated with the presence of wall fibrosis, rather than edema. Moreover, signal intensities detected at DWI may be affected by a significant shine-through effect [19] (Fig. 2). Therefore, the value to assign to this type of analysis needs further critical analysis and discussion. However, independently from the absolute value of DWI in the assessment of disease activity and in disease characterization, it may be helpful in clinical practice to identify the sites of active CD, particularly when using biphasic intestinal contrast agents. In this case, DWI offers a display of the inflamed bowel loops similar to that obtained from the association of T2-weighted fat-suppressed imaging with negative superparamagnetic intestinal contrast agents, although at lower spatial resolution. In both techniques, the inflamed bowel loops are better identified and characterized due to darkening of endoluminal and extraluminal signal.

Perfusion MRI in CD

Advances in vascular biology have underlined the pathogenic role of microvascular alterations and angiogenesis for the initiation and maintenance of CD [20, 21].

Intestinal mucosa of patients with CD suffers a continuous epithelial damage followed by regeneration. Vascular remodeling determines the activation of angiogenesis due to an abnormal expression of pro- and antiangiogenic molecules [22–24]. In particular, in the early stages of CD, acute inflammation is demonstrated by an increase of vascular perfusion correlated with an abnormal distribution of arteries with small luminal irregularities in the peripheral branches. On the contrary, in the advanced stages of CD, there is a decrease of vessel diameter, vascular density and a reduction of regional blood flow [25–27].

DCE-MRI can provide quantitative and semiquantitative measurements of bowel wall perfusion on the bases of the kinetics of contrast media uptake and washout [28, 29]. The evaluation of perfusion alterations increases the accuracy of MRI in the determination of disease activity and help to design more effective therapies for CD [30].

DCE-MRI can be analyzed with a quantitative or a semiquantitative approach. The semiquantitative analysis is based on the evaluation of parameters directly derived by the time–enhancement curve, area under the curve, enhancement slope, time to peak enhancement, and enhancement ratio. These parameters are easier and faster to be calculated but are not directly related to pathophysiology, despite they have been demonstrated to be useful in differentiating normal and inflamed bowel loops [31] (Fig. 3).

Quantitative analysis is based on the evaluation of parameters directly related to the uptake and washout of contrast, applying a two-compartmental model (intravascular vs. extravascular-extracellular space), like the volume transfer coefficient (K_{trans}) and the extracellular volume fraction (V_e).

To date, few investigations, performed on small series, on the accuracy of DCE-MRI in the assessment of CD have been published showing diverging results [16, 31–33]. One recent experience [16] demonstrated quantitative analysis to be accurate in the assessing of bowel inflammation while another [15] did not find a relationship between DCE-MRI imaging and histologic markers of inflammation or clinical parameters. The reason for inhomogeneity of the results is mainly related to technical limitation such as motion artifacts leading to measurements misregistration. Thus, both the optimization of MRI technique and large randomized trials are needed to validate the technique.

MRS in CD

MRS allows noninvasive and in vivo exploration of the molecular composition of tissue. MRS identifies certain molecular constituents—the metabolites—involved in physiological or pathological processes. Even though spectroscopy can be performed on different nuclei, spectroscopy of the hydrogen nucleus is the most widely studied in clinical MR. Only a limited number of molecules with protons are observable in MRS like N-acetyl-aspartate, creatine/phosphocreatine, choline, lactate, and citrate [34]. With greater feasibility in the clinical practice setting, the indications for MRS are multiplying especially for brain and prostate disease [35, 36]. Currently in the literature no studies on MRS in CD are present. Various stages of inflammatory changes can be found in CD due to the production of a wide variety of specific and non-specific mediators of inflammation; therefore it is possible to hypothesize that a variation of any metabolites concentration could be useful in the evaluation of CD activity. Further studies are necessary to assess the diagnostic value of MRS in CD.

Molecular imaging and hybrid imaging (PET–MRI) in CD

Radiological imaging and nuclear medicine imaging may work in tandem to detect early sites of inflammation and improve medical care and reduce costs in CD. In vivo tracking of lymphocyte/macrophage migration could give important insights into the dynamics of CD, helping to monitor and guide new anti-inflammatory treatment strategies [37].

CD may also greatly benefit from the combined use of positron emission computerized

tomography (PET) and magnetic resonance imaging (MRI), with several advantages respect to PET/CT or SPECT/CT or MRI alone.

While MRI mainly provides exquisite morphological details in human tissue, PET investigates the human body at the molecular level enabling the acquisition of exquisite functional data. Due to different technological requirements, PET and MRI were considered techniques that were mutually exclusive for simultaneous application.

Recently, however, hybrid PET–MRI systems either simultaneous or sequential have been developed that can bring these imaging principles together in close proximity.

Thus, simultaneous acquisition of PET and MR signals would enable simultaneous registration of dynamic and moving phenomena. This is especially important in the abdomen where the relative positions of organs may be altered due to peristaltic motion and bladder filling and, furthermore, both images will be acquired under the same physiological conditions.

MRI data may substantially improve PET reconstruction and data analysis, in particular during pharmacokinetic modeling. Contrast-enhanced MRI offers information about perfusion and blood flow. When this information is integrated into the pharmacokinetic modeling of PET data, the modeling results could be much more precise. Consequently, biological and physiological parameters can be more accurately measured, particularly within soft tissues.

An additional important advantage of MRI compared to CT is its superior functional soft tissue analysis, for example for inflammation, dynamic perfusion, and identification of different tissue types, such as edema and fibrosis for example. Last but not least, a major advantage compared with the clinical PET/CT systems of today is the absence of radiation burden.

A better characterization of the lesion could be achieved when PET is combined not only with anatomical MRI, but also with functional MRI, like DWI, spectroscopy, and combined new paramagnetic nanocell-contrast agent with radiolabelled probes for histological characterization of tissues in vivo non-invasively. Both UC and CD are believed to be caused by a complex interaction of environmental, genetic, immunoregulatory and inflammatory factors, but their precise etiology is still under debate. A key role is played by the infiltration and activation of leukocytes, macrophages, and T-cells [38]. These cells and other molecular markers in the process such as chemokines, cytokines, or receptors of the immune response system can be used as markers for scintigraphic imaging.

Finally, cells can be labelled with radionuclides or with MRI contrast agents, defined as molecular MRI, and the combined use of nuclear medicine techniques (namely, PET for

imaging cells and molecular events involved in the disease) with MRI (for morphological definition of affected bowel segments) is the key for the future approach to IBD. We foresee further developments of MR molecular imaging, alone or combined with nuclear medicine imaging, nowadays purely experimental and mostly focused on oncologic imaging, cell migration, receptors, and angiogenesis. In the coming years molecular imaging could be effectively used in the detection of active inflammatory cells and cytokines of IBD as well.

However, as an important constraint, conventional MRI only reflects non-specific proton changes caused by a variety of different processes rather than just tissue infiltration by mononuclear cells. It does not visualize histological details such as the accumulation of inflammatory cells. Thus, there is a demand for further developments in the field of cellular MRI.

PET radiopharmaceuticals do not include only ^{18}F -FDG but a long list of new radiopharmaceuticals are now available for imaging several receptor pathways and cells in the complex network of immune-mediated diseases such as ^{18}F -labelled cytokines, ^{18}F - and ^{64}Cu -labelled immune cells, radiopharmaceutical for imaging apoptosis, and also several ^{11}C - and ^{18}F -labelled drugs.

In 2008, Fogel et al. [39] used ^{19}F -MRI to visualize inflammatory processes in mice with myocardial infarction.

In contrast to previous ^{19}F -MRI studies that tracked cells after ex vivo loading, they applied perfluorocarbons (PFC) systemically leading to an efficient uptake by cells of the monocyte/macrophage system.

Competing contrast agents to enhance the detection of inflammation include established modalities and preclinical products in development. Already in clinical use, radiopharmaceuticals, such as probes for positron emission tomography (PET), have a high sensitivity and specificity but relatively low spatial resolution, yet some studies have found the technique sufficient for inflammation localization [37, 39–42]. However, this approach has not been widely embraced for monitoring therapeutic responses in autoimmune diseases. In fact, the need for repeating imaging sessions in chronic disease states may increase risk associated with repeated radiation exposure.

MRI is uniquely situated in that high-resolution images of anatomy, including soft tissue differentiation, can be obtained without radiation load on the patient.

To enhance the detection of inflammation, superparamagnetic iron oxide (SPIO)-based contrast agents for MRI have been studied pre-clinically and clinically for their ability to detect inflammatory processes [43–48]: they are highly sensitive, although not very specific. It is

also worthwhile to note the SPIO is a contrast-modulating agent; that is pre- and post-delivery scans are needed to detect changes in grey scale contrast. ^{19}F contrast agents are directly detected by MRI, yielding a quantitative signal of the presence and location of ^{19}F after just one imaging session. Fluorine-MRI is also extremely specific to the detection of the contrast agent itself, as there is little to no native fluorine in biological tissues.

From these early experimental studies emerges the importance of MRI in the field of inflammation imaging but also the intrinsic difficulty to use this approach in humans.

Indeed the ability to image the inflammatory process at the cellular level would drastically improve diagnostic capabilities as well as provide in-depth data for new drug development and biological understanding of the inflammatory process under different conditions [48].

The future is to combine PET imaging with MRI not only to increase anatomic resolution but to bring up the highest possible technology and the potentialities of these two emerging techniques.

Conclusions

The potentials of the newer MRI applications, such as motility imaging, spectroscopy, diffusion imaging, and molecular imaging, are still not fully predictable but extremely exciting in the evaluation of CD. Motility studies, recently introduced, are more and more used in the clinical practice to assess the peristalsis of the small bowel. In CD, interesting results have been reported in the identification and characterization of diseased segments.

DWI, first applied to neurologic and oncologic diseases, is increasingly used in abdominal and intestinal imaging. Preliminary clinical studies, performed both in patients with CD and UC, suggest a potential role in the assessment and quantification of disease activity [5–9].

The large clinical interest on the role of microvascular alterations and angiogenesis in the characterization of CD [20–24] suggests a potential clinical use of perfusion MRI [16, 32, 33]. MRS, being able to identify *in vivo* different biological molecules, could play a role in the characterization of inflammatory diseases, although no clinical studies are available so far.

Molecular imaging, performed either with MRI or nuclear medicine techniques, will likely be addressed to selectively identify inflammatory cells and cytokines involved in CD, to fully characterize the disease, thus leading to a rational therapeutic use of monoclonal antibodies.

PET–MRI and MR molecular imaging, nowadays purely experimental and mostly focused on oncologic imaging, could lead to a deeper knowledge of the inflammatory process of CD [38, 48]. In the coming years advanced functional MRI or molecular imaging will likely be able to guide clinicians in the choice of the most effective and specific biological therapy.

References

1. Froehlich JM, Patak MA, von Weymarn C, et al. (2005) Small bowel motility assessment with magnetic resonance imaging. *J Magn Reson Imaging* 21(4):370–375
2. Froehlich JM, Daenzer M, von Weymarn C, et al. (2009) Aperistaltic effect of hyoscine N-butylbromide versus glucagon on the small bowel assessed by magnetic resonance imaging. *Eur Radiol* 19(6):1387–1393
3. Patak M, Szuecs-Farkas Z, Cattin R, et al. (2009) “Motasso” a new software to analyze small bowel motility. Work in Progress. In: Book of abstracts of ESGAR (European Society of Gastrointestinal and Abdominal Radiology) Annual Congress, Valencia, 2009
4. Taylor S, Steward M, Punwani S, Proctor I, et al. (2011) Non perforating small bowel Crohn's disease assessed by MRI enterography: derivation and histopathological validation of an MRbased activity index. In: ECR Annual Meeting Vienna: 2011 (European Congress of Radiology), Suppl.1 to European Radiology, 2011
5. Menys A, Ahmed A, Punwani S, et al. (2011) Quantified small bowel motility during MR enterography in Crohn's disease as a marker of inflammatory activity. In: Book of abstracts of ESGAR (European Society of Gastrointestinal and Abdominal Radiology) Annual Congress, Venice, 2011
6. Sprengers A, van Der Paardt M, Zijta et al. (2011) Motility assessment using continuously tagged imaging. ISMRM, Montreal 2011
7. Jones MP, Bratten JR (2008) Small intestinal motility. *Curr Opin Gastroenterol* 1;24(2):164–172
8. Froehlich JM, Waldherr C, Stoupis C, et al. (2010) MR motility imaging in Crohn's disease improves lesion detection compared with standard MR imaging. *Eur Radiol* 20(8):1945–1951
9. Patak MA, Cullmann J, Szeucs-Farkas Z, et al. (2011) MR motility measurement for the evaluation of Crohn's disease activity compared to biopsy. In: Book of abstracts of ESGAR (European Society of Gastrointestinal and Abdominal Radiology) Annual Congress, Venice, 2011
10. Koh D, Collins DJ (2007) DWI applications and challenges in oncology. *AJR Am J Roentgenol* 188:1622–1635
11. Ichikawa T, Erturk SM, Motosugi U (2006) High-B-value diffusion-weighted MRI in colorectal cancer. *AJR Am J Roentgenol* 187:181–184

12. Chow LC, Bammer R, Moseley ME, et al. (2003) Single breathhold diffusion-weighted imaging of the abdomen. *J Magn Reson Imaging* 18:377–382
13. Kilickesmez O, Atilla S, Soylu A, et al. (2009) Diffusion-weighted imaging of the rectosigmoid colon: preliminary findings. *J Comput Assist Tomogr* 33(6):863–866
14. Kiryu S, Dodanuki K, Takao H (2009) Free-breathing diffusion weighted imaging for the assessment of inflammatory activity in Crohn's disease. *J Magn Reson Imaging* 29:880–886
15. Oto A, Zhu F, Kulkarni K, et al. (2009) Evaluation of diffusionweighted MR imaging for detection of bowel inflammation in patients with Crohn's disease. *Acad Radiol* 16:597–603
16. Oto A, Kayhan A, Williams JTB, et al. (2011) Active Crohn's disease in the small bowel: evaluation by diffusion weighted imaging and quantitative dynamic contrast enhanced MR imaging. *J Magn Reson Imaging* 33:615–624
17. Oussalah A, Laurent V, Bruot O, et al. (2010) Diffusion-weighted magnetic resonance without bowel preparation for detecting colonic inflammation in inflammatory bowel disease. *Gut* 59:1056–1065
18. Taouli B, Tolia AJ, Losada M, et al. (2007) Diffusion-weighted MRI for quantification of liver fibrosis: preliminary experience. *AJR Am J Roentgenol* 189:799–806
19. Maccioni F, Martinelli M, Al-Ansari N, et al. (2010) DWI in patients with Crohn's Disease. In: Book of abstract of ESGAR (European Society of Gastrointestinal and Abdominal Radiology) Annual Congress, Dresden, 2010
20. Danese S, Sans M, Scaldaferrri F, et al. (2006) TNF-alpha blockade down-regulates the CD40/CD40L pathway in the mucosal microcirculation: a novel anti-inflammatory mechanism of infliximab in Crohn's disease. *J Immunol* 176:2617–2624
21. Goebel S, Huang M, Davis WC, et al. (2006) VEGF-A stimulation of leukocyte adhesion to colonic microvascular endothelium: implications for inflammatory bowel disease. *Am J Physiol Gastrointest Liver Physiol* 290:G648–G654
22. Fiocchi C (1997) Intestinal inflammation: a complex interplay of immune and nonimmune cell interactions. *Am J Physiol* 273:G769–G775
23. Danese S, Dejana E, Fiocchi C (2007) Immune regulation by microvascular endothelial cells: directing innate and adaptive immunity, coagulation, and inflammation. *J Immunol* 178:6017–6022
24. McDonald DM (2001) Angiogenesis and remodeling of airway vasculature in chronic inflammation. *Am J Respir Crit Care Med* 164:S39–S45

25. McGarrity TJ, Manasse JS, Koch KL, et al. (1987) Crohn's disease and massive lower gastrointestinal bleeding: angiographic appearance and two case reports. *Am J Gastroenterol* 82:1096–1099
26. Mellor JA, Chandler GN, Chapman AH, et al. (1982) Massive gastrointestinal bleeding in Crohn's disease: successful control by intraarterial vasopressin infusion. *Gut* 23:872–874
27. Hatoum OA, Heidemann J, Binion DG (2006) The intestinal microvasculature as a therapeutic target in inflammatory bowel disease. *Ann NY Acad Sci* 1072:78–97
28. Pupillo VA, Cesare ED, Frier G, et al. (2007) Assessment of inflammatory activity in Crohn's disease by means of dynamic contrast-enhanced MRI. *Radiol Med* 112:798–809
29. Florie J, Wasser MN, Arts-Cieslik K, et al. (2006) Dynamic contrast-enhanced MRI of the bowel wall for assessment of disease activity in Crohn's disease. *AJR Am J Roentgenol* 186:1384–1392
30. Kanazawa S, Tsunoda T, Onuma E, et al. (2001) VEGF, basic-FGF, and TGF-beta in Crohn's disease and ulcerative colitis: a novel mechanism of chronic intestinal inflammation. *Am J Gastroenterol* 96:822–828
31. Oto A, Fan X, Mustafi D, et al. (2009) Quantitative analysis of dynamic contrast enhanced MRI for assessment of bowel inflammation in Crohn's disease pilot study. *Acad Radiol* 16:1223–1230
32. Oommen J, Oto A (2011) Contrast-enhanced MRI of the small bowel in Crohn's disease. *Abdom Imaging* 36:134–141
33. Taylor SA, Punwani S, Rodriguez-Justo M, et al. (2009) Mural Crohn disease: correlation of dynamic contrast-enhanced MR imaging findings with angiogenesis and inflammation at histologic examination-pilot study. *Radiology* 251:369–379
34. Skoch A, Jiru F, Bunke J (2008) Spectroscopic imaging: basic principles. *Eur J Radiol* 67:230–239
35. Cunningham CH, Vigneron DB, Marjanska M, et al. (2005) Sequence design for magnetic resonance spectroscopic imaging of prostate cancer at 3 T. *Magn Reson Med* 53:1033–1039
36. Tzika AA, Astrakas LG, Zarifi MK, et al. (2004) Spectroscopic and perfusion magnetic resonance imaging predictors of progression in pediatric brain tumors. *Cancer* 100:1246–1256
37. Glaudemans AW, Maccioni F, Mansi L, et al. (2010) Imaging of cell trafficking in Crohn's disease. *J Cell Physiol* 223:562–571
38. Hanauer SB (2006) Inflammatory bowel disease: epidemiology, pathogenesis, and

therapeutic opportunities. *Inflamm Bowel Dis* 12(Suppl 1):S3–S9

39. Flo" gel U, Ding Z, Hardung H, et al. (2008) In vivo monitoring of inflammation after cardiac and cerebral ischemia by fluorine magnetic resonance imaging. *Circulation* 118(2):140–148
40. Tawakol A, Migrino RQ, Bashian GG (2006) In vivo 18F-fluorodeoxyglucose positron emission tomography imaging provides a noninvasive measure of carotid plaque inflammation in patients. *J Am Coll Cardiol* 48:1818–1824
41. Tahara N, Kai H, Ishibashi M, et al. (2006) Simvastatin attenuates plaque inflammation: evaluation by fluorodeoxyglucose positron emission tomography. *J Am Coll Cardiol* 48:1825–1831
42. Signore A, Mather SJ, Piaggio G, et al. (2010) Molecular imaging of inflammation/infection: nuclear medicine and optical imaging agents and methods. *Chem Rev* 110:3112–3145
43. Denis MC, Mahmood U, Benoist C, et al. (2004) Imaging inflammation of the pancreatic islets in type 1 diabetes. *Proc Natl Acad Sci USA* 101:12634–12639
44. Gaglia JL, Guimaraes AR, Harisinghani M, et al. (2011) Noninvasive imaging of pancreatic islet inflammation in type 1A diabetes patients. *J Clin Investig* 121:442–445
45. Beckmann N, Falk R, Zurbrugg S, et al. (2003) Macrophage infiltration into the rat knee detected by MRI in a model of antigen-induced arthritis. *Magn Reson Med* 49:1047–1055
46. Jander S, Schroeter M, Saleh A (2007) Imaging inflammation in acute brain ischemia. *Stroke* 38:642–645
47. Saleh A, Schroeter M, Jonkmanns C, et al. (2004) In vivo MRI of brain inflammation in human ischaemic stroke. *Brain* 127:1670–1677
48. Glaudemans AW, Quintero AM, Signore A (2012) PET/MRI in infectious and inflammatory diseases: will it be a useful improvement? *Eur J Nucl Med Mol Imaging* [Epub ahead of print]

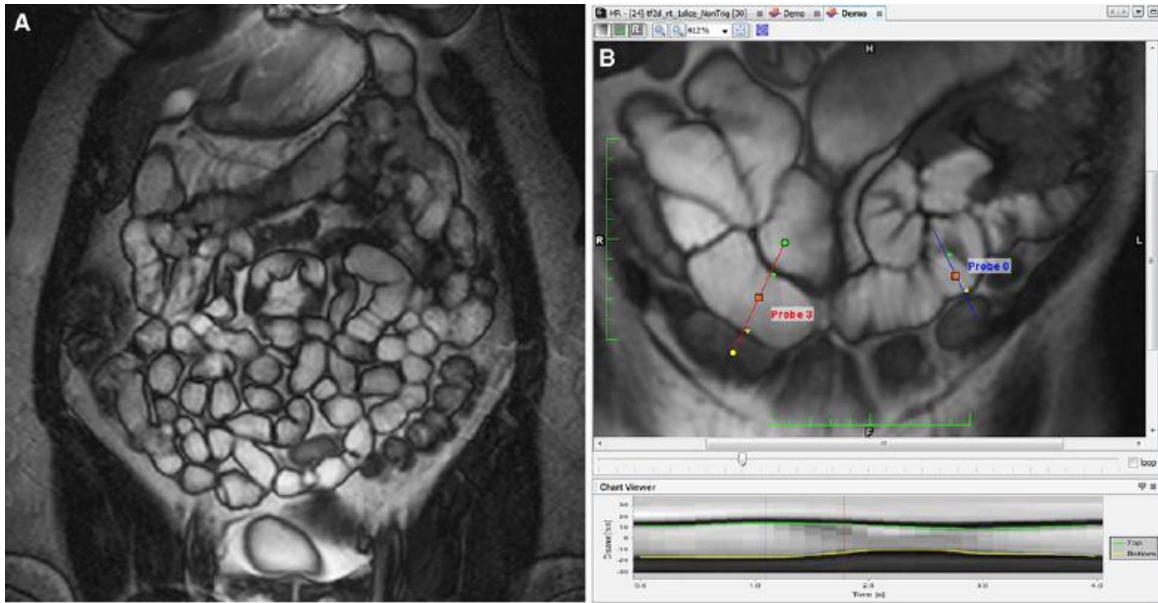


Figure 1.

A Fast cine coronal sequence (T2-weighted SSFP, slice thickness of 10 mm) which allows the repeated acquisition of images every 300–1000 ms on the same plane for one breath hold period, covering the whole abdomen with repetitive 10–15 sequences. B As measurement of the luminal diameter by hand is time consuming and potentially burdened with error, software has been developed to automatically measure these small bowel diameters and display them as a plot over time.

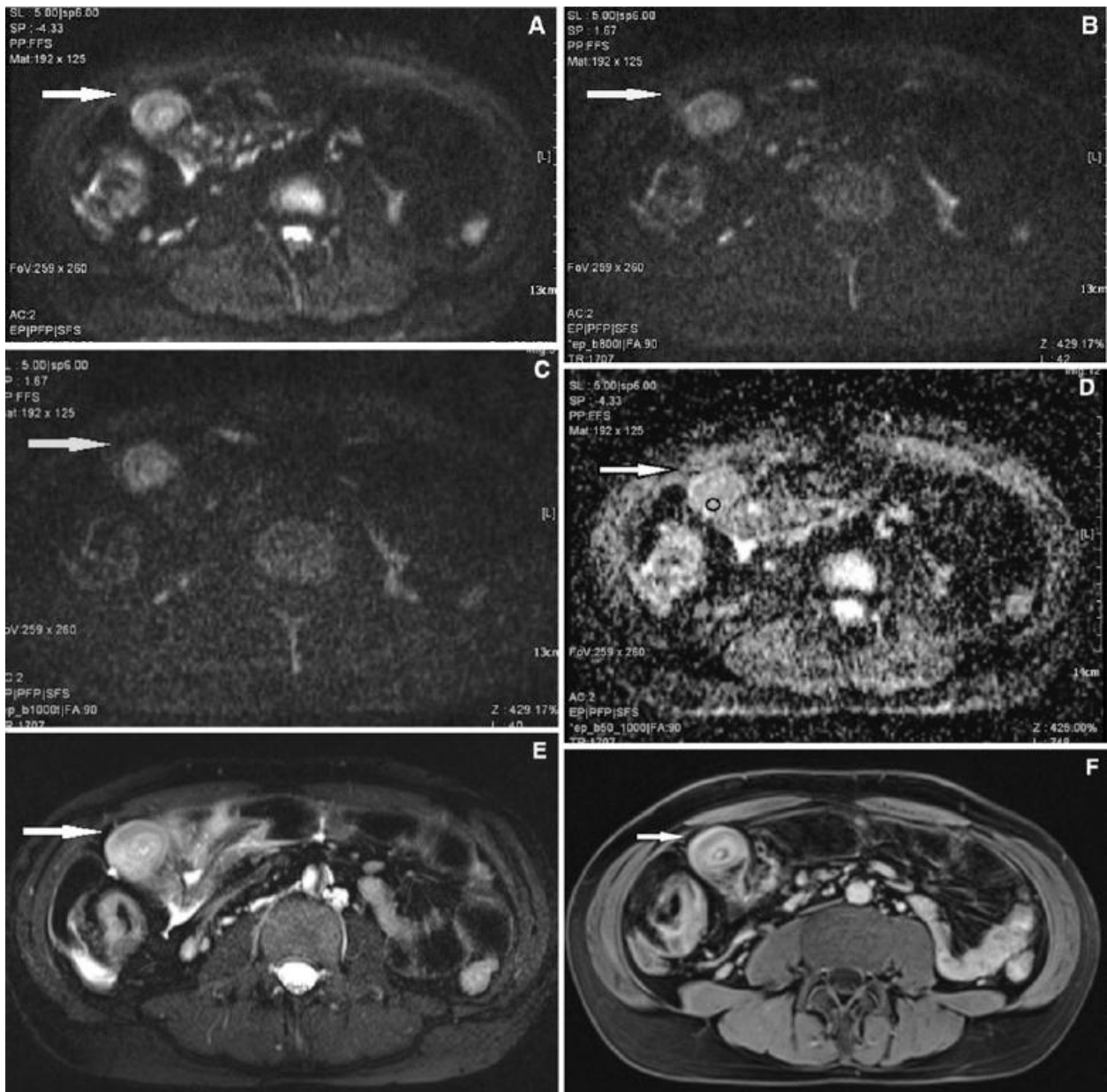


Figure 2.

A 28-year-old male patient with active disease of the distal ileum. A–C Axial DWI images obtained at different b values, respectively b50 (A), b800 (B), and b1000 (C) demonstrate marked wall thickening of the terminal ileum (arrow) with increased wall signal, which persists at high b values, suggesting restricted diffusion. D The wall signal (arrow) on the ADC map is low. In the ROI: min 816, max 1332, Avg 1016, SD 144 consistent with restricted. E Axial T2-weighted BLADE image reveals marked wall thickening and increased signal of the terminal ileum wall (arrow), with perivisceral fluid and hyperintense lymph nodes, suggesting active inflammation. F Contrast-enhanced 3D VIBE T1-weighted axial image shows significant wall thickening of the terminal ileum with stratification and increased enhancement (arrow), increased size of mesenteric vessels, and enhancing lymph nodes, similarly to E, suggestive for active disease.

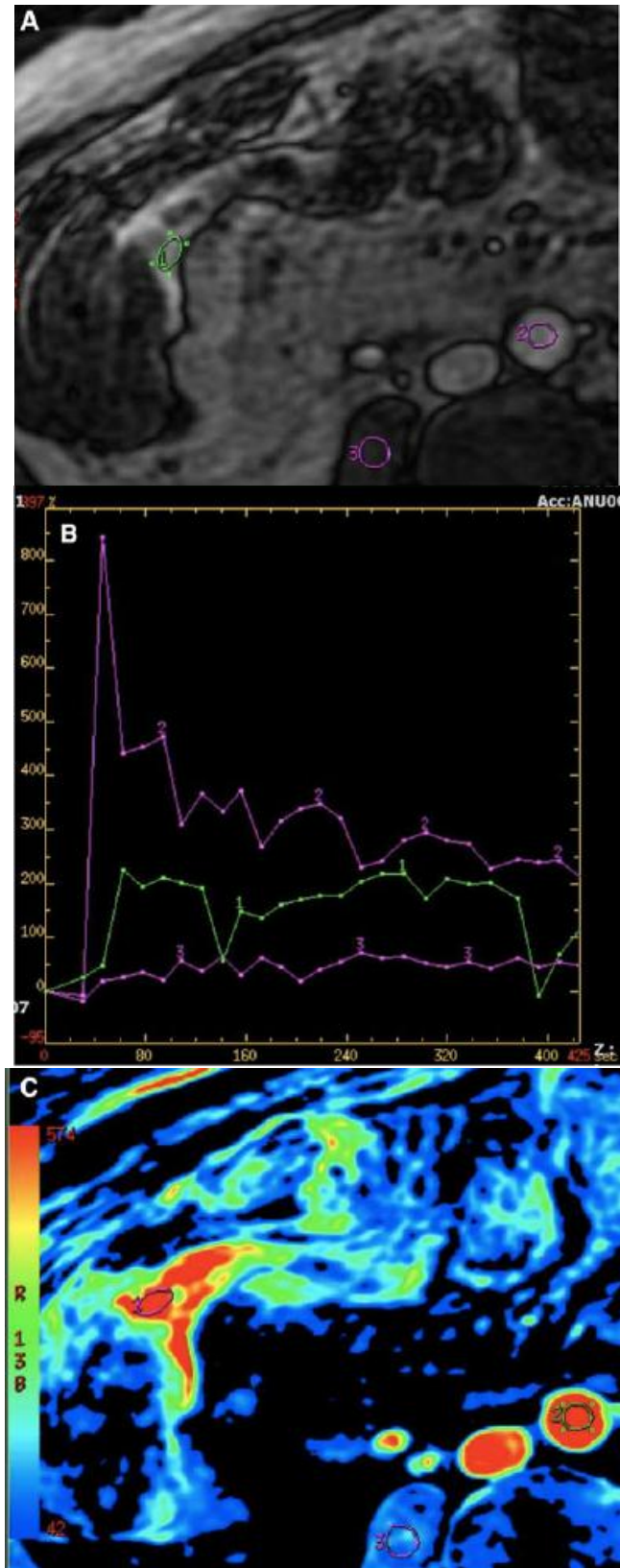


Figure 3.

A Axial T1w dynamic contrast-enhanced spoiled GRE image showing a pathologic ileal loop, demonstrating a severe enhancement. Semiquantitative analysis is performed by positioning of three ROIs, respectively, on ileal wall [1], abdominal aorta [2], and paravertebral muscle, used as control. B Graph showing the results of semiquantitative analysis with enhancement of the pathologic loop. C Color-coded map clearly defining inflamed terminal ileum.



Picture by Francesca Maccioni 2012
Sunset from the dining room window (I)

Chapter 10

Summary

This thesis describes the diagnostic value of MRI in the evaluation of the inflammatory activity of Crohn's Disease (CD). Like Nuclear Medicine, MRI may detect specific features of intestinal CD lesions that are crucial in the therapy decision making process, particularly in the choice of the new biological "target" therapies. Quantification of the activity of CD lesions, their characterization (oedema versus fibrosis) and assessment of their intestinal extent and complications, are widely considered the major issues in the management of the disease. We have demonstrated with different studies that all these issues can be fully addressed by optimizing at the outmost MRI techniques for evaluation of the bowel.

Similarly, by using specific radio-labeled tracers, NM has shown the potential to assess the presence of specific inflammatory cytokines in CD lesions "in vivo", in order to address clinicians towards a rationale choice of the most effective biological therapy. The possible association of the two imaging modalities, now achievable with the new PET-MRI units, could lead to a more comprehensive in vivo characterization of the disease, with still unexplored potentials.

Chapter 1. This is an introduction on the main pathologic and clinical aspects of CD. Recent hypotheses on the pathogenesis of the disease are shortly described, as well as the main microscopic and macroscopic CD features and phenotypes, according to the Vienna Classification. The pharmacological treatment and the newest biological agents (monoclonal antibodies) are here mentioned. The complexity of the diagnostic work up of the disease, related to its longitudinal extent in the small and large bowel and to the typical transmural extent of inflammation with frequent complications, are discussed. MRI intrinsic advantages related to the availability of multiple imaging parameters (T1, T2 weighted, etc) highly sensitive for tissue inflammation are outlined. Similarly, the specific diagnostic capabilities of NM in CD are explained, mostly related to the use of different radiopharmaceuticals that allow assessment and visualisation of the intestinal inflammatory process in vivo.

Chapter 2. In this paper we proposed the first clinical-radiological study on CD activity, based on the analysis of several MRI parameters. In 20 adult patients affected by CD and studied with MRI, five different T1 and T2-weighted MRI parameters were analyzed and tested at the level of the inflamed bowel wall for the assessment of disease activity, including wall thickening, degree of wall Gd-enhancement, T2 wall signal intensity, T2 signal of mesenteric fat. Each one of these MR parameters turned out to be statistically correlated with the

“biological” activity, expressed as positivity of two or more acute phase reactants ($p < 0.001$, r values between 0.78 to 0.96).

At that time (2000), only two previous early preliminary papers had been published on this subject. In the ten following years, more than 120 clinical-radiological papers have been published on MRI-CD activity. To date, MRI seems to be the most complete and powerful radiological tool to detect inflammatory changes in human tissues, and specifically in CD.

In **Chapter 3** it is described a large and complex study comparing the efficacy of different MRI parameters (both T1-weighted and T2-weighted) in the overall assessment of CD. Fifty-nine patients affected by Crohn disease were examined with MRI after oral administration of a superparamagnetic contrast agent. MRI evaluation of CD included either the detection of lesions site and length and complications in the small and large bowel (morphologic evaluation), as well as the assessment of the severity of lesions inflammation (evaluation of disease activity). T2-weighted MR was 95% accurate, 98% sensitive, and 78% specific for detection of ileal lesions. Agreement between T1- and T2-weighted images ranged from 0.77 for ileal lesions to 1.00 for colic lesions. T2-weighted signal intensities of the wall and mesentery correlated with biologic activity ($P < .001$, r 0.774 and 0.712, respectively), as well as Gd-enhancement ($P < .001$, r 0.751). Results were extremely satisfactory for both T1 and T2-weighted parameters, suggesting that MRI had the capability of evaluating the site, extent and activity of the disease with different parameters like no other radiological imaging modality. Disease activity was detected by MRI somehow similarly to NM. Differently from NM, however, MRI had the added value of offering an excellent morphological display of the lesions and their complications, in the small and large bowel.

In **Chapter 4** it is described and suggested the use of a specific MRI technique for the evaluation of the bowel, called “double contrast MR Enterography”, effective in the evaluation of IBD, and particularly of CD. The rationale of this technique is the contemporary optimization of both T1 and T2-weighted imaging parameters. Most of the published papers on MRI, in fact, underestimate T2-weighted parameters being predominantly focused on the amount of wall Gd-enhancement. Wall enhancement assessable on T1-weighted images, it is certainly crucial in the detection of the inflamed wall, but it is not the only pathologic event. Detection of wall oedema or fibrosis, better assessable on T2-weighted rather than T1-weighted images, is equally relevant for the therapy decision process of CD. Therefore, the optimization of T2-weighted imaging is of paramount importance in the evaluation and characterization of CD. Currently, the detection of wall fibrosis is considered a contraindication to several biological treatments and in most of the cases a major indication

for surgical resection. On the other hand, the presence of wall oedema may predict a positive response to medical treatments.

In **Chapter 5** we have briefly reviewed the pathophysiology and the new therapeutic approaches to IBD. The importance of tumour necrosis factor-alpha (TNF α), a highly proinflammatory molecule, in the pathogenesis of inflammation is reviewed. Genetic factor, particularly the association between NOD2 gene mutations on chromosome 16 and increased susceptibility to CD were also outlined. The management of patients with IBD and the potential therapeutic efficacy of the monoclonal antibody anti-TNF α (infliximab) was discussed. From the new therapeutic achievements the diagnostic flow charts were critically discussed and updated. The final diagnostic assessment of IBD proposed in this paper was still based on conventional guidelines, although a very early introduction of MRI was suggested for the diagnosis of CD in doubtful cases. Interestingly very recently (2013) the newest clinical-radiological guidelines (ECCO-ESGAR joint committee) have confirmed the primary role of MRI in the diagnosis of most of the aspects of CD and mainly for the assessment of CD activity.

Chapter 6. The monitoring of the therapeutic response is another major issue in the clinical management of the disease. In active phases of the disease, an increased production and release of TNF α by macrophages and monocytes of the lamina propria has been described. In order to visualise the presence of TNF α within the gut mucosa in patients with active CD candidate for immunotherapy with a chimeric human/mouse monoclonal antibody anti-TNF α (Infliximab, Remicade®), was labelled with ^{99m}Tc-technetium obtaining a stable product. Seven patients with active CD and candidate for immunotherapy with Infliximab were studied. Images of the abdomen were acquired at 6 to 20 hrs after i.v. injection of about 10 mCi of ^{99m}Tc-Infliximab and a week later, all patients were also studied with ^{99m}Tc-HMPAO-labelled autologous white blood cells (WBC). Despite the disease activity documented by endoscopy and elevated CDAI values, a significant ileal ^{99m}Tc-Infliximab accumulation was observed only in 5 patients, whereas a significant uptake of radiolabelled WBC was detected 8 out of 10 patients. Therefore the degree of ^{99m}Tc-Infliximab uptake by the inflamed bowel evaluated at 20 hrs post injection was less than that seen with labelled WBC and with a different distribution. Likely, more studies are necessary to clarify the mechanism of action of anti-TNF α monoclonal antibodies.

Chapter 7. In this paper on cell trafficking in CD, the present and future capabilities of MRI and NM in the evaluation of the inflammatory process of CD and the potential value of their integration are discussed and reviewed.

Different scintigraphic methods of imaging cells involved in the pathogenesis are described. The radiopharmaceuticals can be divided into non-specific radiopharmaceuticals for inflammation and specific radiopharmaceuticals that directly image lymphocytes involved in the process. General, "nonspecific" radiopharmaceutical for inflammation include radiolabeled white blood cells, IgG-imaging, monoclonal antibody-imaging, ^{18}F -FDG, while "specific" radiopharmaceuticals are targeted for a certain cytokine or chemokines involved in the patho-physiology of CD, such as IL2-imaging, TNF α -imaging, imaging E-selectin, etc. Finally, an update on other imaging modalities, and particularly MRI, in the evaluation of Crohn's disease activity, is provided. Although MRI cannot directly detect inflammatory cells, it has shown a high sensitivity in detecting the macroscopic signs of inflammation at the level of the intestinal wall affected by Crohn's disease and Ulcerative colitis. The current diagnostic value of MRI in the detection of inflamed bowel segment and in the assessment of CD activity, as well the potentials MR spectroscopy, MR diffusion imaging and MR molecular imaging, are briefly discussed. MRI has great potentials in characterization of the Crohn's disease, being able to assess microscopic structural wall changes, such as oedema and fibrosis, ipervasularity, capillary permeability, diffusion of water molecules, and likely, in the next years, specific molecular abnormalities.

Chapter 8. In this study on pediatric CD for the first time MRI was used for a direct comparative study between pediatric and adult patients, by evaluating either morphological and activity findings of the intestinal disease. The safety of MRI makes it useful to monitor disease in pediatric population, as well as to monitor effects of biological therapies. Forty-three adult and 43 pediatric patients were studied with the same MRI technique and extensively evaluated with clinical and endoscopic examinations as well. All the small and large bowel intestinal segments were analyzed. The site of the lesions and their activity, as shown by MRI, were directly compared. Results were surprising, interesting and original. Involvement of terminal ileum was observed in 100% adult patients (43/43) versus 58% (23/43) of pediatric ones ($P < 0.0001$). Conversely, the colon was diseased in 84% of pediatric patients versus 64% of adults, In particular, left colonic segments were significantly more involved were the descending colon (53% versus 21%, $P < 0.01$) and the rectum (67% versus 23%, $P < 0.0001$). In children the maximal disease activity was found in left colonic segments while in adults in the terminal ileum. Thus MRI showed a more extensive and severe involvement of the left colon in children, but of the distal ileum in adults. These relevant differences emerged between the two populations suggesting a possible phenotypic and genetic difference.

Finally, in **Chapter 9**, we have discussed the potential usefulness of the newest imaging parameters able to assess intestinal motility, molecular structure and angiogenesis at the level of the inflamed bowel loops. By using Diffusion Weighted Imaging (DWI), MRI can detect differences in the motility of water molecules at the level of the diseased bowel wall. Moreover, MR molecular imaging and MR spectroscopy, although still experimental, are very promising for the evaluation of IBD, due to possibility to analyze and characterize the molecular structure of the inflamed intestinal wall. Differentiation between intestinal oedema and fibrosis or between ulcerative colitis and Crohn's disease colitis could hopefully be easier by using these new imaging parameters. Both PET–MRI and MR molecular imaging, nowadays purely experimental and mostly focused on oncologic imaging, could lead to a deeper knowledge of the inflammatory process of CD.

Chapter 11

Conclusions

To date, MRI seems to be the most complete and powerful imaging tool to detect inflammatory changes in human tissues and specifically in CD. The high sensitivity of MRI for inflammatory tissues is related to the availability of different imaging parameters, mainly fluid-sensitive (T2-weighted) and gadolinium-enhanced ones, which are able to view the intestinal wall inflammation, fibrosis and edema in different ways. Thanks to these parameters, MRI can detect intestinal oedema and hypervascularity, like no other imaging modalities. The value and diagnostic utility of the T1 and T2-weighted imaging in the evaluation of inflammatory disease and characterization of the intestinal bowel wall have been specifically and extensively analyzed in various chapters of the thesis (chapter 2, 3 and 4). Several T1 and T2-weighted parameters, either morphological or functional, have been tested for the evaluation of disease activity, including wall thickening, degree of wall Gd-enhancement, T2 signal intensity of the intestinal wall and mesenteric fat. In our experience these MRI parameters turned out to be significantly correlated with the “biological” activity of CD, which is widely considered a reliable index of disease activity.

Tissue inflammation may be then easily assessed with different MRI parameters, to detect oedema, vascularization or fibrosis at the level of the pathological wall. In addition, new imaging parameters and sequences are continuously introduced in MRI. For example, using Diffusion Weighted Imaging (DWI), MRI can detect differences in the motility of water molecules at the level of the bowel wall affected by CD. Moreover, MR molecular imaging and MR spectroscopy, although still in an experimental phase, seem very promising for the evaluation of IBD, due to possibility to analyze and characterize the molecular structure of the inflamed intestinal wall (chapter 9). Only updated and advanced MRI systems, however, are currently able to offer the widest range of imaging parameters for assessing inflammation, able not only to differentiate the intestinal wall edema by fibrosis, but also to quantify the degree of parietal vascularization and angiogenesis, to detect subtle differences in the motility of the water molecules with DWI and molecular abnormalities with MR spectroscopy.

Definitely, the potentials of MRI in the detection of CD inflammation are vast and destined to expand in the next years, but they will be appreciated and fully understood only in the light of the most recent advances in clinical research. A close synergy and osmosis between

clinical and radiological knowledge will certainly be the key to many future advances in the clinical-diagnostics research. For too many years the clinical management of any disease, and more specifically of CD, has led to a disjunction between the clinical research and the morphological-radiological research. Nuclear Medicine instead, historically has been more widely linked to the clinical research, likely due to a more direct biological approach. PET–MRI, nowadays purely experimental and mostly focused on oncologic imaging, could lead to a deeper knowledge of the inflammatory process of CD. Specific radiopharmaceuticals targeted for a certain cytokines or chemokines involved in the patho-physiology of CD, such as IL2-imaging, TNFa-imaging, etc, will likely be more and more used in the clinical and experimental diagnostic evaluation of CD, In the coming years advanced NM, functional MRI or molecular imaging will likely be able to guide clinicians in the choice of the most effective and specific biological therapy.

In the coming years, it is expected that radiologists, while maintaining their technical knowledge, will cooperate more closely with gastroenterologists and, on the other hand, gastroenterologists will be increasingly involved in issues of imaging. Probably, the boundaries between clinical and radiological sciences will become less and less defined, as is already the case in nuclear medicine. At the same time, integration of different imaging modalities, such as MRI and NM, will surely open further horizons in the evaluation and understanding of the inflammatory process of Crohn's disease.

A deeper integration between NM, MRI and clinical research will surely provide new information and knowledge on this and other diseases. The junction between morphological and molecular imaging is very close by.



Picture by Francesca Maccioni 2010
Sunset from the dining room window (L)

Chapter 12

Curriculum Vitae



Citizen:

Italian, Born in Rome, february 11, 1963.

Work address:

Dept. Radiological Science University La Sapienza

Policlinico Umberto I, Viale Reginal Elena 321, 00161 Rome Italy, +39-06-49972429

E-mail: francesca.maccioni@uniroma1.it

Education:

- Classical High School Virgilio, in Rome: 1977-1981.
- Medical School at University La Sapienza of Rome, Italy: 1981-1987. Final degree 110/110 cum laude.
- Three months internships in USA in 1988 (Cleveland University Hospitals).
- Past ECFMG examination in 1989-90 to access to the residency schools in USA.
- Residency in Radiology, University La Sapienza: 1987-1991. Final degree 70/70 cum laude.
- One month MRI center of Philadelphia University in 1994.
- Residency in Gastroenterology, University La Sapienza: 2001-2005. Final degree 70/70 cum laude.

Publications:

Author of more than 60 papers in peer reviewed journals and over 20 chapters on English and Italian books. Reviewer for the European Journal of Radiology.

Member of the Editorial Board of the Journal Abdominal Imaging.

Memberships:

SIRM (Società Italiana Radiologia Medica), ESR (European Society of Radiology) and ESGAR (European Society of Gastrointestinal Abdomina Radiology) member.

Fellow of the ESGAR (European Society of Gastrointestinal and Abdominal Radiology).

Actual Position:

Tenured University position as Senior Lecturer (Ricercatore confermato) in Radiology, Dept. Radiological Sciences Sapienza University, Policlinico Umberto I.

Chief of the Imaging Unit of the Hematology Clinic, Policlinico Umberto I.

Clinical work:

1992-2001: Emergency Radiology, interventional and Vascular Radiology, CT, MRI and US at the Dept. of Radiological Sciences University Sapienza.

2001-2011: Multislice CT Units (64 s and 128s) for body imaging; MRI 1.5T unit (Siemens Avanto) for abdominal-gastrointestinal imaging; US unit for gastrointestinal and abdominal imaging.

2012-2013: 3T MRI Unit (GE) for oncological abdominal imaging. MSCT units and Whole body diffusion imaging at 1.5 and 3T MRI for staging onco-hematological diseases

Teaching at University of Rome Sapienza:

- *Integrate course of Diagnostic Radiology and Integrate course of Methodology 8th.* Forth year of the First Medical School of Medicine;

-*Imaging of the liver, spleen and pancreas*, third year of the post-graduate Residency School of Diagnostic Radiology;

- *Cross sectional imaging of the bowel*; forth year of the of the post-graduate Residency School of Gastroenterology;

-*Vascular Imaging*; University School for Radiology Technicians.

Invited Speaker:

Over 60 national and Interational Meetings, including in 1998, 2000, 2002, 2004, 2008, 2012 at SIRM (Italian Society of Radiology) congresses; in 1996, 1997, 2000, 2004, 2008, 2009, 2010, 2011 and 2012 at ESGAR (European Society of Gastrointestinal Abdomina Radiology) annual congresses; in 2003, 2010, 2011 and 2012 at ECR (European Congress of

Radiology) congresses. In 2003 and 2012 at EANM (European Meeting of Nuclear Medicine); in 2006 at Leeds Radiology GI course (UK); in 2007 at Danish Radiology Society meeting.

Organizer and speaker of over 40 Refresher Courses at the Dept. Radiological Sciences "La Sapienza" (1991-2009).

Actual fields of research:

MRI and cross sectional imaging of the small-large intestine, MRI of Crohn's Disease and Ulcerative Colitis in adult and pediatric patients (morphological changes, complications, disease activity).

Functional MR Imaging of pelvic floor disorders. Functional MRI of the intestine. CT colonoscopy and CT-MRI staging of GI neoplasms. Diffusion Liver imaging. Imaging of Chirrosis. Whole body MRI in the staging of onco-hematological diseases.



Picture by Alessandro Bozzao 2010
Sunset from the dining room window (M)

Chapter 13

Acknowledgements

I wish to thank Prof Alberto Signore for following my PhD program and addressing me towards it with patience and enthusiasm.

I thank also Prof Rudi Dierckx for the great opportunity given to me with this PhD and for all the seminars and useful comments he made.

Many thanks to Alessandro Bozzao, my husband and neuroradiologist, for supporting my work and for his suggestions. Thanks to my father Antioco Franco and my two children, Luigi and Beatrice, for being always so close to me.

I also wish to thank the past-Chairman of the Department of Radiology of "Sapienza" University of Rome, Prof Mario Marini, for allowing me to start this program and present Chairman Prof Carlo Catalano for supporting me to the end of it.

I sincerely wish to thank Prof Morton Meyers, the Editor of Abdominal Imaging, for always trusting in my work, and particularly for publishing my first paper on MRI assessment of CD activity in the year 2000, when two of the major radiological journals had refused it. It received over 250 citations.

I wish to thank Prof Renzo Caprilli, full professor of Gastroenterology at "Sapienza" University of Rome, for teaching me clinical gastroenterology and leading me in the world of IBDs.

I also thank Prof Salvatore Cucchiara for driving me into the world of pediatric IBDs.

A sincere and gentle thank to Prof Gianni Morana for supporting this thesis and my work.

I thank all my residents that, during the last 15 years, have followed with interest and dedication my clinical-radiological work on Crohn's disease, particularly Francesca Siliquini, Sara Parlanti, Federica Carrozzo, Viola Garbarino, Martina Martinelli, Anna Rosaria Pino, Ilaria Staltari, Giulia Bella, Najwa Al Ansari, Fabrizio Mazzamurro, Valentina De Marco and Valeria Bonocore.

Last but not least a special thank to my paranymphs Dr Adrienne Brouwer and Dr Gaurav Malviya for their precious help in the organization of the PhD ceremony.

