

**Plastic and Reconstructive Surgery Advance Online Article**

**DOI: 10.1097/PRS.0000000000001710**

**MANDIBULAR DISTRACTION OSTEOGENESIS IN LOW WEIGHT NEONATES  
WITH ROBIN SEQUENCE: IS IT SAFE?**

MDO in the very small

**Authors:**

Youssef Tahiri, MD, CM, MSc, FRCSC, FAAP

Assistant Professor of Surgery

Riley Hospital for Children

Indiana University

youssef\_tahiri@hotmail.com

S. Travis Greathouse, MD

Craniofacial Fellow

Riley Hospital for Children

Division of Plastic Surgery

Indiana University

stgreath@iupui.edu

Sunil S. Tholpady, MD, PhD

Assistant Professor of Surgery

Riley Hospital for Children

---

This is the author's manuscript of the article published in final edited form as:  
Tahiri, Y., Greathouse, S. T., Tholpady, S. S., Havlik, R., Sood, R., & Flores, R. L. (2015). Mandibular Distraction Osteogenesis in Low-Weight Neonates with Robin Sequence: Is It Safe? *Plastic and Reconstructive Surgery*, 136(5), 1037–1044. <http://doi.org/10.1097/PRS.0000000000001710>

Indiana University

stholpad@iupui.edu

Robert Havlik, MD

Professor of Surgery

Department of Plastic Surgery

Medical College of Wisconsin

rhavlik@mcw.edu

Rajiv Sood, MD

Professor of Surgery

Riley Hospital for Children

Indiana University

rsood@iupui.edu

Roberto L. Flores, MD

Associate Professor

Department of Plastic Surgery

NYU Langone Medical Center

Robert.Flores2@nyumc.org

**Name of Department(s) and Institution(s)**

Division of Plastic Surgery

Riley Hospital for Children

Indiana University

**Corresponding Author:**

Youssef Tahiri, MD, CM, MSc, FRCSC, FAAP

Assistant Professor of Surgery

Riley Hospital for Children

Indiana University

ytahiri@iupui.edu

**Presentation History:**

The data included in this manuscript have not been previously presented.

**Institutional Review Board:**

This study was reviewed and approved by the Indiana University Institutional Review Board

**Conflict of Interest:**

No conflicts of interest to disclose

**Financial Disclosures:**

The authors have no financial disclosures to report.

**Authorship Participation and Contributions**

Youssef Tahiri, MD: Study Conception, data interpretation, and manuscript preparation

S. Travis Greathouse, MD: Data analysis, data interpretation, and manuscript preparation

Sunil Tholpady, MD: Data analysis, data interpretation, and manuscript preparation

Robert Havlik, MD: Data interpretation, manuscript preparation

Rajiv Sood, MD: Data interpretation, manuscript preparation

Roberto Flores, MD: Data interpretation manuscript preparation

ACCEPTED

## ABSTRACT

**Background:** The aim of this study is to evaluate the efficacy, safety profile and the complications associated with mandibular distraction osteogenesis (MDO) performed in infants < 4kg with Robin sequence (RS).

**Methods:** A 11-year retrospective review of all infants (< 6 months) with MDO treated RS was performed. Patients < 4 kg (experimental) and  $\geq$  4 kg (control) who underwent MDO were compared. Demographics, medical comorbidities, improvement in apnea/hypopnea index (AHI), need for tracheostomy, repeat distraction, and complications were evaluated.

**Results:** One hundred twenty-one patients underwent MDO. 81 patients were < 4 kg while 40 were  $\geq$  4 kg. The mean follow up was 2.8 years in patients < 4 kg and 3.0 years in the control group. Mean age and weight at time of distraction were 23 days old / 3.1 kg and 2.7 years / 11 kg; respectively. There was no significant difference in success of MDO to treat airway obstruction in the < 4 kg group versus the control group (92.6% vs. 88.9%;  $p = 0.49$ ). The most common complication in each group was surgical site infection (9.9% and 20.0%;  $p = 0.15$ ). Overall complication rates were similar between the two groups (17.3% vs. 25.0%;  $p = 0.34$ ). The rates of repeat distraction were similar between the two groups (6.3% and 13.5%;  $p = 0.28$ ).

**Conclusion:** MDO is a safe and effective treatment modality for infants < 4 kg with severe airway obstruction. The efficacy, safety, and complication profiles are not significantly different from larger patients.

## INTRODUCTION

Mandibular distraction osteogenesis (MDO) is a standard technique in the armamentarium of the craniofacial surgeon treating bony deficiencies of the lower jaw. The surgical treatment of Robin sequence (RS), in particular, was revolutionized by the introduction of the distraction technique which restores airflow behind the tongue-base by direct, anterior translation of the mandible. After popularization by McCarthy,<sup>1</sup> MDO was successfully applied to children with RS to relieve affected patients from tracheostomy.<sup>2-4</sup> After these initial reports, MDO was applied to progressively younger patients including infants with severe airway obstruction associated with RS who would otherwise require tracheostomy.<sup>5-8</sup> In many craniofacial centers, MDO is now the first line surgical intervention to treat severe RS in which conservative measures have been unsuccessful.

The timing of intervention of MDO in newborns with RS can be a complex decision. Robin sequence is characterized by a heterogeneous population<sup>9</sup> defined by mandibular hypoplasia, glossoptosis and airway obstruction.<sup>10</sup> Cleft palate has been erroneously included in the definition of RS despite Robin's original description of the triad. Affected patients can have other medical diagnoses including syndromic/genetic abnormalities or additional anomalies of the respiratory, central nervous or circulatory systems. In addition, newborns with severe respiratory obstruction can present immediately after birth. In this subset of patients with the most severe presentation of airway obstruction, the timing of surgery may be delayed due to concerns for increased complications associated surgical intervention performed in the very small (< 4kg) or in the first days of life.

Although infant distraction has been demonstrated to be safe<sup>3,11-17</sup> and effective<sup>3,6,8,12,13,15-17</sup> surgical outcomes in the newborn patient population have not been specifically reported. The purpose of this study is to report the surgical outcomes of MDO performed on infants who were less than 4kg at the time of their surgery. The goal of this analysis is to guide indications for MDO in neonates during the first days of life who are affected by severe airway obstruction.

## METHODS

### *Patient Population*

This study was approved by the Indiana University Institutional Review Board. An 11-year retrospective review of all infants with RS treated with mandibular distraction, at a tertiary referral children's hospital from January 2004 to March 2015, was performed. Patients < 6 months of age and weighing < 4 kg at the time of distraction were included. A control group of all Robin sequence patients  $\geq$  4 kg undergoing mandibular distraction during the same time period was used for comparison.

### ***Outcomes***

Patients' demographics were recorded as well as associated medical comorbidities such as low birth weight, prematurity, intrauterine growth restriction, syndromic diagnosis, cardiac, respiratory or gastrointestinal (gastroesophageal reflux (GER), history of Nissen fundoplication or gastrostomy tube) comorbidities. Other variables included improvement in apnea/hypopnea index (AHI), need for tracheostomy, repeat distraction, and complications. Complications were categorized as major, moderate, or minor, as defined by Davidson et al.<sup>18</sup> Major complications were those that failed to improve or could not be improved with invasive therapy (i.e. tooth injury, fibrous nonunion, and device failure). Moderate complications were those that could be resolved by invasive therapy (i.e. premature ossification, device breakage/dislodgement, improper vector, and abscess). Minor complications were self-limited or would improve without invasive therapy (i.e. pin-site infection, hypertrophic scarring, neurapraxia, hematoma).

### ***Treatment Protocol***

A multidisciplinary team including plastic surgery, neonatology, genetics, pulmonology, developmental pediatrics, otolaryngology and nursing was involved in the care. Indication for MDO have been previously described.<sup>8,19</sup> Briefly, patients were initially treated with prone positioning, supplemental oxygen, or non-invasive positive pressure ventilation. Patients who failed to improve with conservative intervention, were unable to be discharged from the hospital safely with conservative treatments, and underwent polysomnography demonstrating no central apnea and either an AHI > 20 or significant CO<sub>2</sub> retention, are considered for mandibular distraction. All patients received a maxillofacial computed tomography scan with 3-D reconstructions to evaluate the quality of bone, mandibular morphology, position of the inferior

alveolar nerve, and presence of tooth buds. Under the same anesthetic and prior to mandibular distraction, a pediatric otolaryngologist performed a direct laryngoscopy and rigid bronchoscopy. If other airway obstruction was observed, the treatment algorithm was altered appropriately at the discretion of the surgeon, and tracheotomy performed if indicated. In the case of laryngomalacia, the protocol used was for a laser supraglottoplasty at that time if not contraindicated. All patients underwent mandibular distraction using either the micro Zurich or the Urata distractors (KLS Martin, Jacksonville, FL); with distraction started after a latency period of 2 to 5 days, activation at a rate of approximately 1mm/day and a consolidation of approximately 8 weeks. The activation rate and vector were monitored with serial skull radiographs at weekly intervals.

### ***Statistical Analysis***

Statistical analysis was performed using IBM SPSS for Windows, version 22 (IBM Corp., Armonk, NY). A student's t-test was used to analyze parametric continuous variables, Mann-Whitney test for independent nonparametric continuous data, Wilcoxon signed-rank test for related nonparametric continuous data, and Fisher's exact test was used to analyze dependent variable effects on the success or failure of MDO. Statistical significance was defined as  $p \leq 0.05$ .

### **RESULTS**

One hundred twenty-one patients underwent MDO during the study period and 81 patients met inclusion criteria. The remaining 40 patients were  $\geq 4$  kg and used as a control group (Table 1). Mean age and weight at time of distraction were 23 days old (range 5 to 97 days) and 3.1 kg (range 2.00 to 3.99). The mean age and weight for the control group was 2.7 years (range 9 days to 14.6 years) and 11 kg (range 3.9 to 57.0 kg). Prematurity ( $< 37$  weeks of gestation), low birth weight ( $< 2500$  g) and intrauterine growth restriction (IUGR) ( $< 10^{\text{th}}$  percentile based on gestational age) were present in 25.0%, 30.0% and 31.3% of the patients  $< 4$  kg and 29.7%, 31.4% and 34.3% of the patients  $\geq 4$  kg ( $p = 0.65, 1.00, \text{ and } 0.83$  respectively). Identifiable genetic syndrome was present in 34.2% of patients  $< 4$  kg and 35.9% of patients  $\geq 4$



kg ( $p = 1.00$ ). The rates of significant neurologic, cardiac, gastrointestinal (non-GER), genitourinary, and other system anomalies were similar between those patients  $< 4$  kg and  $\geq 4$  kg: 21.3% vs 15.4%,  $p = 0.62$ ; 23.8% vs. 15.0%,  $p = 0.34$ ; 3.8% vs. 7.7%,  $p = 0.39$ ; 12.5% vs 5.1%,  $p = 0.33$ ; and 30.0% vs. 20.5%,  $p = 0.38$  respectively (Figure 1). The rate of concomitant lower airway disease was 30.0% in patients  $< 4$  kg and 53.8% in patients  $\geq 4$ kg ( $p < 0.05$ ), of which 79.2% and 81.0% were laryngomalacia respectively ( $p = 1.0$ ). Supraglottoplasty was performed in 56.3% of patients with laryngomalacia if  $< 4$ kg and 75.0% of patients  $\geq 4$  kg ( $p = 0.46$ ). Gastroesophageal reflux (GER) was present in 38.8% of patients  $< 4$ kg and 46.2% of patients  $\geq 4$  kg ( $p = 0.55$ ). Nissen fundoplication cited as an additional risk factor was performed in 10.1% of patients  $< 4$  kg and 18.0% of patients  $\geq 4$  kg ( $p = 0.25$ ). Gastrostomy tube was present in 66.3% of patients  $< 4$ kg and 69.2% of patients  $\geq 4$ kg ( $p = 0.84$ ) (Figure 1).

There was no significant difference in success of MDO to treat airway obstruction in the  $< 4$  kg group vs. the control group (92.6% vs. 88.9%,  $p = 0.45$ ) (Table 2). Success was defined as either decannulation of tracheostomy, avoidance of tracheotomy, or significant improvement of obstructive sleep apnea symptoms allowing safe discharge home. The mean pre-operative AHI was 41.5 vs. 26.1 in the control group ( $p < 0.008$ ). The mean post-operative AHI was 12.1 vs. 12.4 ( $p = 0.21$ ) at 1 month and 5.8 vs. 3.1 ( $p = 0.90$ ) at 1 year. In patients  $< 4$  kg and  $\geq 4$ kg, AHI was significantly improved from preoperative values at 1 month (67.6% improvement,  $p < 0.001$  and 71.2% improvement,  $p < 0.001$ ) and at 1 year (73.0% improvement,  $p < 0.02$  and 89.8% improvement,  $p < 0.005$ ) (Figure 2).

The number of patients  $< 4$  kg with 1 or more complications (major, moderate, or minor including infectious) was 14 (17.3%) vs. 10 (25.0%) in the control group ( $p = 0.34$ ) (Table 3). Within the  $< 4$  kg group, major complications were present in 2 patients (2.5%), moderate complications in 6 patients (7.4%), and minor complications in 7 patients (8.6%) (Figure 3A). A similar distribution of complications occurred in the control group: 0 major, 7 (17.5%) moderate, and 3 (7.5%) minor ( $p = 1.00$ , 0.12, and 1.00) (Figure 3B). The only major complications in the patients  $< 4$ kg were fibrous non-union (1.2%) and severe trismus (1.2%) that did not respond to operative intervention. Moderate complications were device malfunction or dislodgement (3.7% in  $< 4$ kg and 5.0% in  $\geq 4$  kg,  $p = 1.00$ ) and surgical site infection (SSI) requiring return to the operating room (4.9% in  $< 4$  kg and 12.5% in  $\geq 4$  kg,  $p = 0.15$ ). Minor complications were SSI managed with oral antibiotics (4.9% in  $< 4$  kg and 7.5 % in  $\geq 4$  kg,  $p = 0.68$ ), ventilator-

associated pneumonia (1.2% in < 4 kg and 0 in  $\geq$  4 kg,  $p = 1.00$ ), hematoma (1.2% in < 4 kg and 0 in  $\geq$  4 kg,  $p = 1.00$ ) and facial nerve neurapraxia (1.2% in < 4 kg and 0 in  $\geq$  4 kg,  $p = 1.00$ ). The most common complication was SSI (9.9% of patients < 4 kg and 20.0% of patients  $\geq$  4 kg,  $p = 0.15$ ), of which 50.0% and 35.3% were successfully treated by oral antibiotics alone. There were no instances of TMJ ankyloses or permanent facial nerve palsies demonstrated in this series.

The rates of repeat distraction were similar between the < 4 kg group and the control group (6.3% and 13.5%;  $p = 0.28$ ). The mean age at repeat distraction was 2.3 years in the < 4 kg group and 9.2 years in the control group ( $p < 0.0001$ ). The mean follow up was 2.8 years (range 0.1 to 9.4 years) in patients < 4 kg and 3.0 years (range 0.1 to 10.1 years) in the control group ( $p = 0.68$ ).

## DISCUSSION

Mandibular Distraction Osteogenesis (MDO) has been demonstrated to be a safe<sup>3,11-17</sup> and effective<sup>3,6,8,12,13,15-17</sup> intervention to relieve airway obstruction in infants with severe RS. Surgical outcomes in neonates during their first days of life however, have not been specifically studied. Due to concerns for performing jaw lengthening surgery at such an early age, some surgeons may opt to delay intervention until the newborn child grows and matures. Unfortunately, this delay in care may result in a prolonged period of intubation, longer NICU stay, temporary tracheostomy or an extended period of time in which the infant exists in a state of severe respiratory obstruction. Prolonged intubation increases risk to nosocomial pneumonia, tracheobronchial plugging, loss of airway, and increases the complexity of ICU care.

Tracheotomy has been associated with multiple complications including increased risk to tracheomalacia, chronic pneumonia, laryngeal stenosis, intellectual and physical impairments, compromised social interaction and requirement of complex nursing care and education.<sup>20-25</sup> An extended ICU stay increases risk to nosocomial infection and increases the economic burden to the healthcare system. Alternatively, there can be significant risk associated with early MDO intervention in neonates during their first days of life. These children may be premature, underweight and may have multiple associated co-morbidities including intrauterine growth restriction (IUGR) and other organ system anomalies. In the background of these dichotomous

forces, the ideal time to intervene in neonates in their first days of life with RS and severe airway obstruction can be unclear.

Early complications following MDO include surgical site infection, hematoma, device failure or dislodgement, neurapraxia, fibrous non-union, and fracture.<sup>11,18</sup> Long-term complications include facial nerve injury, inferior alveolar nerve injury, temporomandibular joint (TMJ) ankylosis, trismus, injury to unerupted dentition, asymmetry, and disturbances of facial growth. Most early complications can be managed effectively in the perioperative period with conservative therapy or early return to the operating room. Long-term complications, although rare, can cause significant morbidity for the patient and are often referenced by centers opposed to early mandibular distraction.<sup>26-29</sup> Further work with longer follow-up will be needed to delineate the long-term effects of distraction, although our series demonstrates promising results with nearly a decade of follow-up in some patients.

We demonstrate that surgical outcomes of MDO in neonates with RS and severe airway obstruction are comparable to MDO applied to older and larger infants with RS. The incidence of the majority of comorbidities was similar between the two groups. We chose <4 kg as our study population as surgical risk and complexity in other pediatric surgery specialties is associated with children who are low weight at the time of surgery, and the CPT code modifier uses the weight limit of 4 kg.<sup>30-32</sup> One of the earliest reports by Denny on the use of MDO for the treatment of RS described 5 successfully treated patients who were under 4 kg at the time of surgery.<sup>5</sup> There are several other reports on MDO for the treatment of RS, however these reports either describe a large patient population<sup>2</sup> or make no specific mention of weight at the time of surgery.<sup>3,6,7,13,15</sup>

Gastroesophageal reflux disease is a commonly associated condition with RS, and has been cited as a potential marker for more severe disease and worse outcomes.<sup>8, 15, 33-34</sup> The etiology of GER in Robin sequence may be secondary to increased negative intrathoracic pressure, increased use of abdominal muscles, increased gastric pressure, the immaturity of the esophageal sphincter. Untreated GER may lead to irreversible damage to the respiratory system. Monasterio *et al* demonstrate improvement in GER via esophageal pH monitoring on all patients prior to MDO and 4 months after intervention<sup>4</sup>. The retrospective nature of the current study and lack of consistently employed objective monitoring techniques is a limitation of the current study for evaluating the effects of MDO on GER.

Other limitations of this study include the retrospective design and lack of long-term follow up. It is entirely possible that lower jaw surgery performed at the neonatal age is detrimental to future bony growth. Mandibular growth after MDO has not been fully studied and it is possible that mandibular distraction can cause iatrogenic damage to lower jaw growth. In addition, other complications associated with mandibular distraction could not be assessed by this relatively short-term follow up. These complications include: inferior alveolar nerve damage, iatrogenic damage to the deciduous and permanent teeth, TMJ ankylosis, effects on facial growth, and long-term scarring. These patients will need to be followed until skeletal maturity to fully appreciate these effects. Furthermore, this is a single institution experience which follows an institutionally derived algorithm and indications for MDO. The concomitant treatment of laryngomalacia with supraglottoplasty adds a second intervention, and it is impossible to delineate the beneficial contribution of that intervention with the current retrospective study. We suspect that supraglottoplasty in this case has only a minimal effect on overall outcome and could be performed at any time during the treatment algorithm, however further prospective or case-control studies will be needed. Although our indications have been previously published,<sup>8,19</sup> other distraction centers may have different indications, techniques and experience all of which can affect surgical outcome.

It is important to stress that although the reported results suggest that MDO is safe to perform in infants less than 4 kg at the time of surgery, we do not recommend that MDO should be performed at this age at all centers. Neonatal as well as infant distraction should only be performed by experienced, high volume distraction centers with expert pediatric anesthesia and neonatal ICU care. Our recommendation for active distraction centers who are considering MDO in infants less than 4 kg is to progress to an earlier time of intervention with close collaboration with your pediatric anesthesia and neonatal ICU teams. The treacherous nature of MDO as applied to this very young subset of neonates cannot be more strongly emphasized. However, vigilant adherence to appropriate technique and airway control can result in an acceptably low complication profile as demonstrated in this report. Safety should be the first concern in guiding clinical decisions, therefore if the caring team is not experienced, prepared or comfortable with the timing of this type of intervention then surgery should be delayed and other treatment options, including tracheotomy should be considered.

## CONCLUSIONS

Mandibular distraction osteogenesis is a safe and effective treatment option for the treatment of severe Robin Sequence in infants weighing less than 4 kg. If the appropriate team and experience is available, the small or newborn status of the child should not delay the implementation of this treatment intervention.

## REFERENCES

1. [McCarthy JG, Schreiber J, Karp N, Thorne CH, Grayson BH. Lengthening the human mandible by gradual distraction. Plast Reconstr Surg 1992;89:1-8; discussion 9-10.](#)
2. [Denny AD, Talisman R, Hanson PR, Recinos RF. Mandibular distraction osteogenesis in very young patients to correct airway obstruction. Plast Reconstr Surg 2001;108:302-11.](#)
3. [Monasterio FO, Molina F, Berlanga F, et al. Swallowing disorders in Pierre Robin sequence: its correction by distraction. J Craniofac Surg 2004;15:934-41.](#)
4. [Williams JK, Maull D, Grayson BH, Longaker MT, McCarthy JG. Early decannulation with bilateral mandibular distraction for tracheostomy-dependent patients. Plast Reconstr Surg 1999;103:48-57; discussion 8-9.](#)
5. [Denny A, Kalantarian B. Mandibular distraction in neonates: a strategy to avoid tracheostomy. Plast Reconstr Surg 2002;109:896-904; discussion 5-6.](#)

6. [Denny AD. Distraction osteogenesis in Pierre Robin neonates with airway obstruction. Clin Plast Surg 2004;31:221-9.](#)
7. Kohan E, Hazany S, Roostaeian J, et al. Economic advantages to a distraction decision tree model for management of neonatal upper airway obstruction. *Plast Reconstr Surg*;126:1652-64.
8. [Murage KP, Tholpady SS, Friel M, Havlik RJ, Flores RL. Outcomes analysis of mandibular distraction osteogenesis for the treatment of Pierre Robin sequence. Plast Reconstr Surg 2013;132:419-21.](#)
9. Cohen MM, Jr. The Robin anomalad - its nonspecificity and associated syndromes. *J Oral Surg* 1976;34:587-93.
10. Robin P. LaGlossoptosis son diagnostic, ses consequences, son traitement. *Bulletin de l'Academie National de Medecine, Paris* 1923.
11. [Murage KP, Costa MA, Friel MT, Havlik RJ, Tholpady SS, Flores RL. Complications associated with neonatal mandibular distraction osteogenesis in the treatment of Robin sequence. J Craniofac Surg 2014;25:383-7.](#)
12. Hammoudeh J, Bindingnavele VK, Davis B, et al. Neonatal and infant mandibular distraction as an alternative to tracheostomy in severe obstructive sleep apnea. *Cleft Palate Craniofac J* 2012;49:32-8.
13. [Andrews BT, Fan KL, Roostaeian J, Federico C, Bradley JP. Incidence of concomitant airway anomalies when using the university of California, Los Angeles, protocol for neonatal mandibular distraction. Plast Reconstr Surg 2013;131:1116-23.](#)
14. [Scott AR, Tibesar RJ, Lander TA, Sampson DE, Sidman JD. Mandibular distraction osteogenesis in infants younger than 3 months. Arch Facial Plast Surg 2011;13:173-9.](#)
15. [Genecov DG, Barcelo CR, Steinberg D, Trone T, Sperry E. Clinical experience with the application of distraction osteogenesis for airway obstruction. J Craniofac Surg 2009;20 Suppl 2:1817-21.](#)
16. [Burstein FD, Williams JK. Mandibular distraction osteogenesis in Pierre Robin sequence: application of a new internal single-stage resorbable device. Plast Reconstr Surg 2005;115:61-7; discussion 8-9.](#)
17. [Tahiri Y, Viezel-Mathieu A, Aldekhayel S, Lee J, Gilardino M. The effectiveness of mandibular distraction in improving airway obstruction in the pediatric population. Plast Reconstr Surg 2014;133: 352e-359e.](#)
18. Davidson EH, Brown D, Shetye PR, et al. The evolution of mandibular distraction: device selection. *Plast Reconstr Surg*;126:2061-70.

19. Flores RL, Tholpady SS, Sati S, et al. The Surgical Correction of Pierre Robin Sequence: Mandibular Distraction Osteogenesis versus Tongue-Lip Adhesion. *Plast Reconstr Surg* 2014;133:1433-9.
20. Guilleminault C, Simmons FB, Motta J, et al. Obstructive sleep apnea syndrome and tracheostomy. Long-term follow-up experience. *Arch Intern Med* 1981;141:985-8.
21. [Sasaki CT, Horiuchi M, Koss N. Tracheostomy-related subglottic stenosis: bacteriologic pathogenesis. \*Laryngoscope\* 1979;89:857-65.](#)
22. [Zeitouni A, Manoukian J. Tracheotomy in the first year of life. \*J Otolaryngol\* 1993;22:431-4.](#)
23. [Arola MK. Tracheostomy and its complications. A retrospective study of 794 tracheostomized patients. \*Ann Chir Gynaecol\* 1981;70:96-106.](#)
24. [Singer LT, Kercksmar C, Legris G, Orłowski JP, Hill BP, Doershuk C. Developmental sequelae of long-term infant tracheostomy. \*Dev Med Child Neurol\* 1989;31:224-30.](#)
25. [Tomaski SM, Zalzal GH, Saal HM. Airway obstruction in the Pierre Robin sequence. \*Laryngoscope\* 1995;105:111-425.](#)
26. Evans AK, Rahbar R, Rogers GF, et al. Robin sequence: a retrospective review of 115 patients. *Int J Pediatr Otorhinolaryngol* 2006;70:973-80.
27. Kirschner RE, Low DW, Randall P, et al. Surgical airway management in Pierre Robin sequence: is there a role for tongue-lip adhesion? *Cleft Palate Craniofac J* 2003;40:13-8.
28. [Schaefer RB, Stadler JA, 3rd, Gosain AK. To distract or not to distract: an algorithm for airway management in isolated Pierre Robin sequence. \*Plast Reconstr Surg\*. 2004;113:1113-25.](#)
29. [Rogers GF, Murthy AS, LaBrie RA, Mulliken JB. The GILLS score: part I. Patient selection for tongue-lip adhesion in Robin sequence. \*Plast Reconstr Surg\* 2011; 128:243-51. 29.](#)
30. Gupta P, Jacobs JP, Pasquali SK, et al. Epidemiology and outcomes after in-hospital cardiac arrest after pediatric cardiac surgery. *Ann Thorac Surg*. 2014;98:2138-43; discussion 2144.
31. Kalfa D, Krishnamurthy G, Duchon J, et al. Outcomes of cardiac surgery in patients weighing <2.5 kg: affect of patient-dependent and -independent variables. *Thorac Cardiovasc Surg*. 2014;148:2499-506.
32. [Egbe AC, Mittnacht AJ, Nguyen K, Joashi U. Risk factors for morbidity in infants undergoing tetralogy of fallot repair. \*Ann Pediatr Cardiol\*. 2014;7:13-8.](#)
33. [Bull MJ, Givan DC, Sadove AM, et al. Improved outcome in Pierre Robin sequence: effect of multidisciplinary evaluation and management. \*Pediatrics\*. 1990; 86: 294-301.](#)
34. [Dudkiewicz Z, Sekula E, Nielepiec-Jalosinska A. Gastroesophageal reflux in Pierre Robin sequence--early surgical treatment. \*Cleft Palate Craniofac J\*. 2000; 37: 205-8.](#)

## Tables and Figures Legends

Table 1. Patients' demographics

Table 2. Outcomes of infant mandibular distraction osteogenesis

Table 3. Complications associated with infant mandibular distraction osteogenesis

Figure 1. Comparison of comorbidities between patients  $< 4$  kg and  $\geq 4$  kg

Figure 2. Comparison of polysomnography data between patients  $< 4$  kg and  $\geq 4$  kg

Figure 3A. Complications associated with infant mandibular distraction osteogenesis in patients  $< 4$ kg

Figure 3B. Complications associated with infant mandibular distraction osteogenesis in patients  $\geq 4$  kg

ACCEPTED



## Tables

**Table 1:** *Patients' demographics*

	< 4kg	≥ 4kg	p-values
n	81	40	
Male/Female ratio	1.53	0.90	0.44
Mean Age at MDO	23 ± 21 days	2.7 ± 3.7 years	
Mean Weight at MDO (kg)	3.1 ± 0.5	11 ± 12	
Prematurity	25.0%	29.7%	0.65
Low Birth Weight	30.0%	31.4%	1.00
IUGR	31.3%	34.3%	0.83
Mean Length of Follow-up (years)	2.8 ± 2.3	3.0 ± 3.0	0.57

**Table 2:** *Outcomes of infant Mandibular Distraction Osteogenesis*

	< 4 kg	≥ 4 kg	p-value
Pre-op Tracheostomy	0.0%	25.0%	<0.0001
Post-op Tracheostomy	6.2%	11.1%	0.45
Success	92.6%	88.9%	0.49
Repeat	6.3%	13.5%	0.28

**Table 3:** *Complications associated with infant Mandibular Distraction Osteogenesis*

	< 4kg	≥ 4 kg	p-value
All Complications	17.3%	25.0%	0.34
Major	2.5%	0.0%	1.00
Moderate	7.4%	17.5%	0.12
Minor	8.6%	7.5%	1.00
Surgical Site Infections*	9.9%	20.0%	0.15
Infections requiring I&D	4.9%	12.5%	0.15

\*Infectious complications included in all complications above

Figure 1.

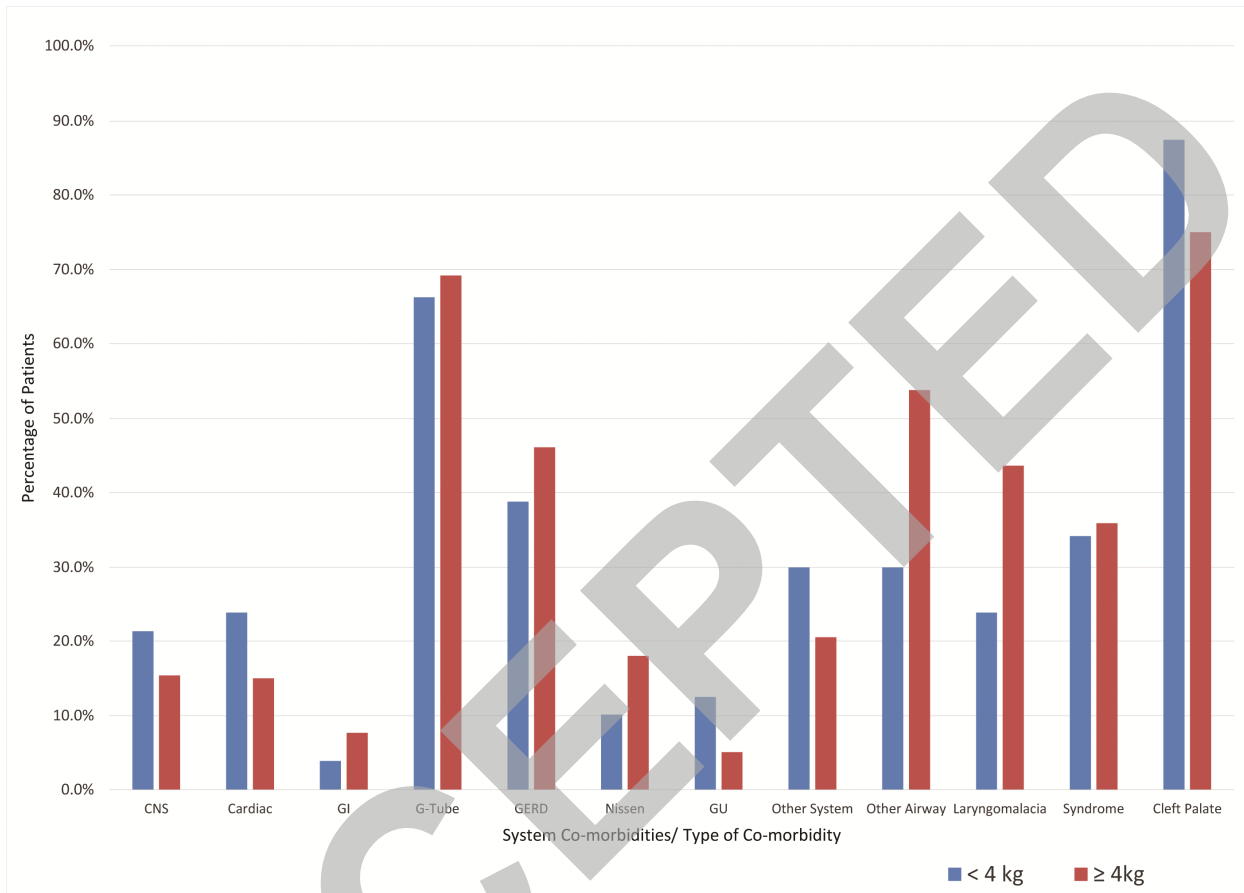


Figure 2.

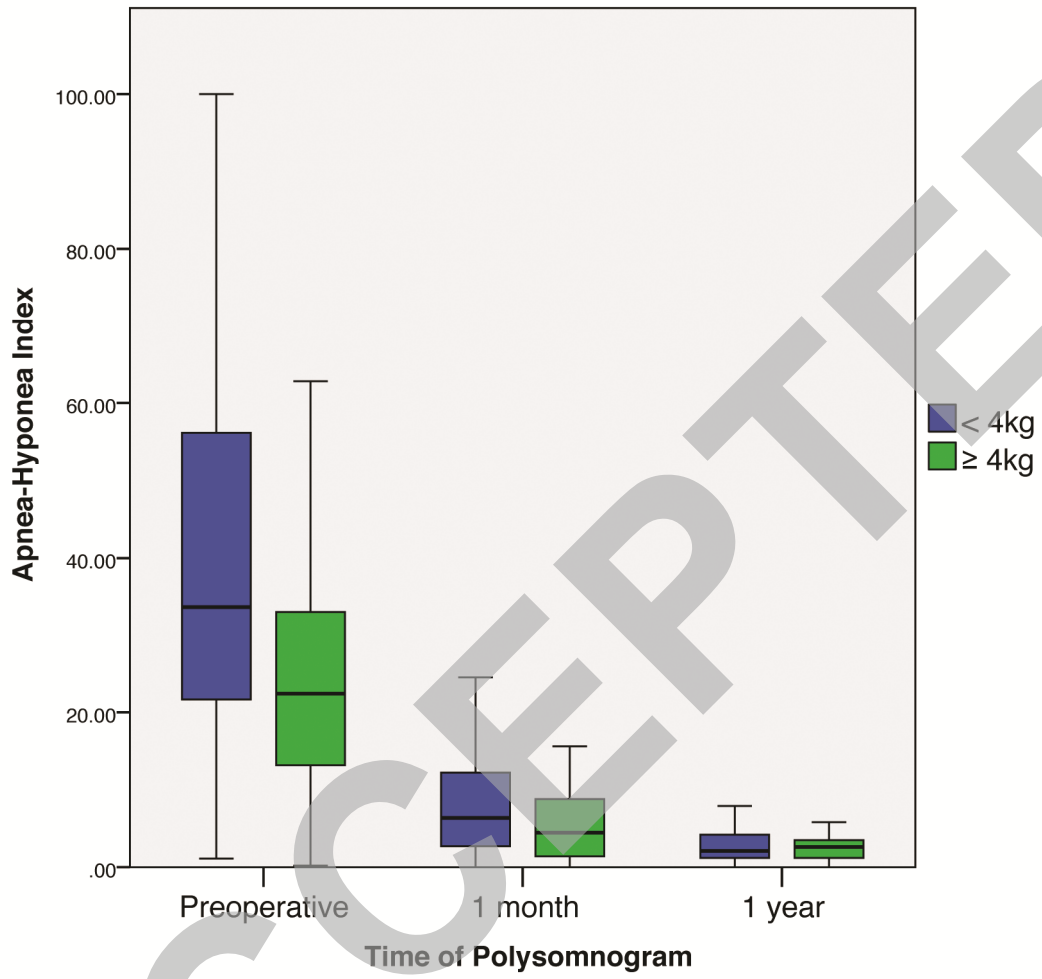


Figure 3.

