



Images Paediatr Cardiol. 2008 Jul-Sep; 10(3): 1–9.

PMCID: PMC3232590

Central venous catheters in children and neonates (Part 3) – Access via the femoral vein

U Trieschmann,¹ M Kruessell,¹ Udink ten F Cate,² and N Sreeram²

¹Department of Anaesthesiology and Intensive Care Medicine, University Hospital of Cologne, Germany

²Department of Paediatric Cardiology, University Hospital of Cologne, Germany

Contact information: N. Sreeram, Department of paediatric cardiology, University Hospital of Cologne, Kerpenerstrasse 62, 50937 Cologne, Germany. Phone: +49 221 478 32517 begin_of_the_skype_highlighting

FREE +49 221 478 32517 end_of_the_skype_highlighting Fax: +49 221 478 32515 ; Email: N.Sreeram@uni-koeln.de

Copyright : © Images in Paediatric Cardiology

This is an open-access article distributed under the terms of the Creative Commons Attribution-Noncommercial-Share Alike 3.0 Unported, which permits unrestricted use, distribution, and reproduction in any medium, provided the original work is properly cited.

Abstract

Background

Central venous access via the femoral vein (FV) is safe, relatively easy and very usual in infants and children undergoing cardiac surgery for congenital heart disease. It has a low insertion-related complication rate.

Results

It is therefore a good choice for short-term central venous lines and a preferred insertion site for less experienced staff. The maintenance-related complications of thrombus formation and infections are higher compared to the internal jugular and the subclavian venous access.

Conclusions

Some of these complications are reduced by the use of heparin bonded catheters, routine use of antibiotics, and timely removal of these lines in patients with persistent signs of infection but without another focus being defined.

MeSH: Heart Catheterization, Femoral Vein

Introduction

Central venous access is an essential part of perioperative management for infants and children undergoing major surgery. For general aspects of central venous lines we refer to parts 1 and 2 of this series of papers describing the various approaches to venous access.^{1,2} A detailed discussion of complications of central venous catheters in critically ill children may be found in recently published studies and reviews.^{3–5} The key issue for choosing a particular access site is the relative ease of insertion and the incidence of complications. Access via the femoral vein is routinely used for diagnostic cardiac catheterization and interventions. It is also very commonly used by less experienced staff as there is no major anatomical variation in the superficial femoral venous system, and the incidence of severe complications related to line insertion is low.

Landmarks and depth of insertion

The femoral vein lies medial to the femoral artery (around 0.3-1 cm, figs. 1,2) puncture site is about 1-3 cm below the groin. The tip of the catheter should lie either in the inferior vena cava downstream from the level of the renal vein, or above the diaphragm in the right atrium. The latter position will be indicated if measurement of right atrial pressure or repeated blood sampling from the atrium is indicated. This higher position however has a higher incidence of thrombosis – especially renal vein thrombosis. Therefore in the majority of the cases the more peripheral position of the catheter tip is chosen.

Fig. 1 Ultrasound visualisation of the femoral artery and vein.

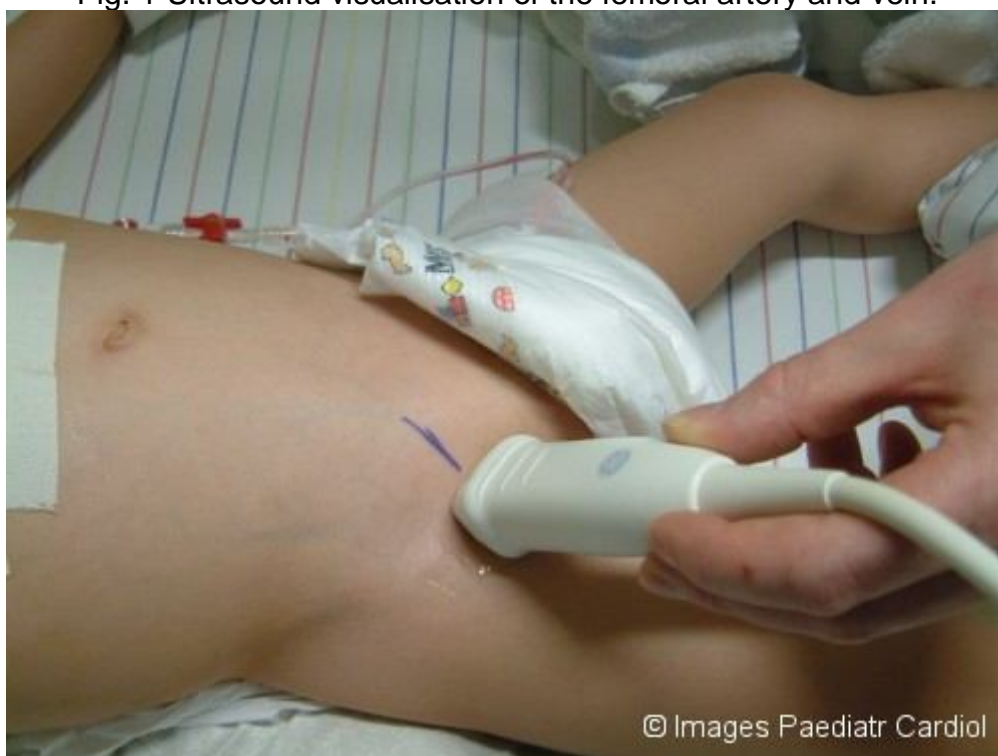
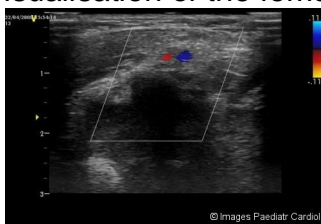
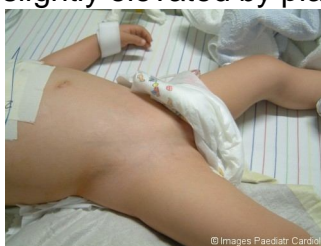Fig. 2 Ultrasound visualisation of the femoral artery and vein.



Positioning

The pelvis is elevated slightly by placing a towel under the hips (fig. 3). That causes a slight stretching of the vein. If the groin is elevated too much, compression of the vein can be the result and it may be impossible to puncture the vein, especially if the child is dehydrated or hypovolemic. During puncture venous filling can be improved by slight abdominal compression.

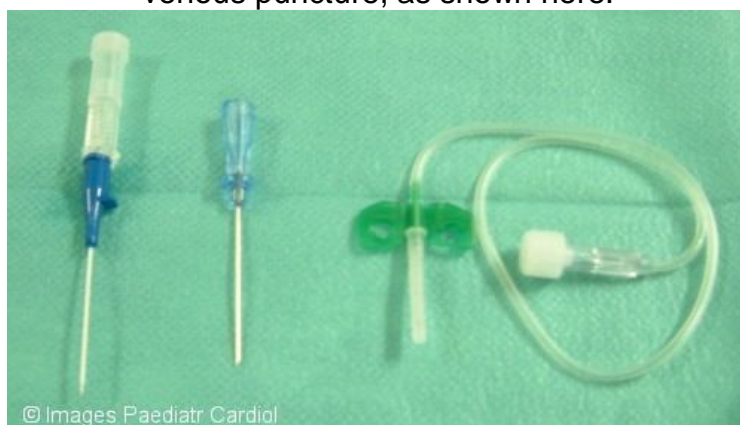Fig. 3 Appropriate positioning of the patient to facilitate femoral venous access. The pelvis may be slightly elevated by placing a towel under the hips.



Classical puncture technique

The femoral artery is palpated with one hand, then the skin is usually punctured 0.3-1 cm medially. The needle is advanced at a 30-40° angle to the skin towards the umbilicus. If the insertion angle is too steep the needle may transfix the vessel, and the guide wire cannot be threaded into the vessel. Different needles (fig. 4) and puncture techniques are in use:

Fig. 4 A wide variety of needles and cannulae may be employed for femoral venous puncture, as shown here.



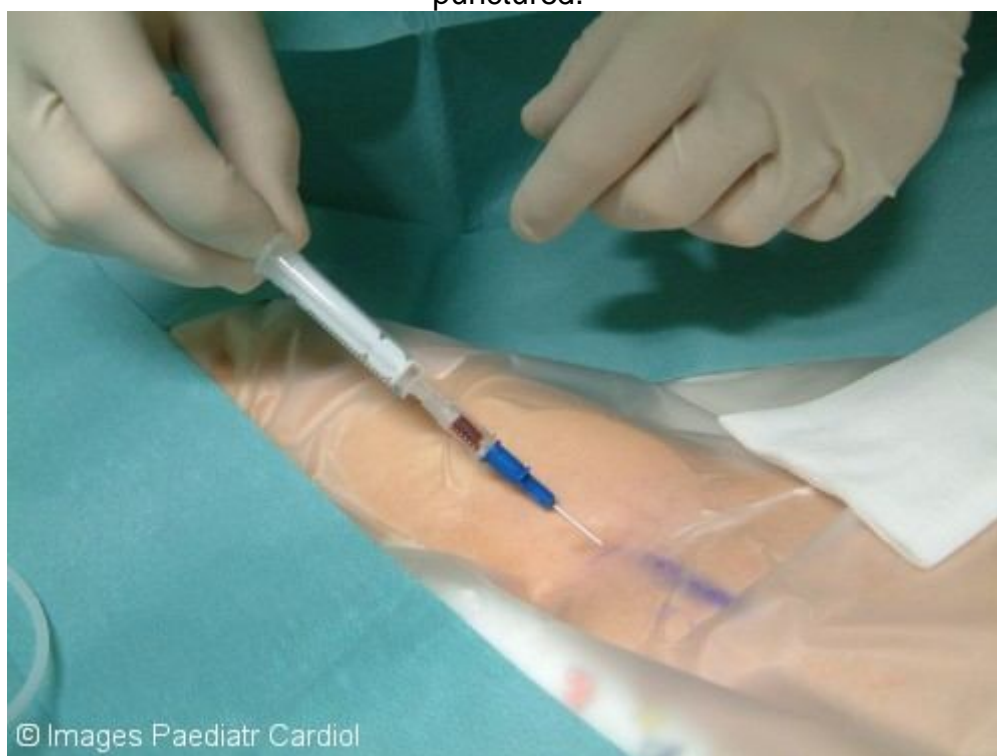The classical Seldinger technique means puncture with the provided needle. As soon as blood is aspirated the needle may be advanced another millimetre, then the guide wire is inserted via the needle. In many situations the vein is compressed and then perforated during puncture. That means the blood is only aspirated once the needle is slowly pulled back.

A variation of this technique is the puncture with a sharp 21 gauge butterfly needle. After aspiration of blood the plastic tube is cut with sterile scissors. The advantage of this technique is that the vein is less compressed because of the sharpness of the needle and blood can already be aspirated while advancing the needle.

Another variation (see figs. 5-11) is the creation of a normal venous access with a venous cannula. In most cases the vein is perforated. As soon as blood is aspirated during pulling back, the cannula can be advanced (see Video 1). Afterwards this venous access can be used for introducing the guide wire. The advantage of this technique is the easy insertion of the guide wire: as the venous plastic cannula already lies within the vessel for a certain distance and the problem of transfixation of the vessel (puncture of the posterior wall of the vessel by the bevel of the needle with consequent inability to advance the guidewire) will be avoided.

After the insertion of the guide wire, the skin needs a small incision and a dilator is introduced and finally the catheter positioned and sutured.

Fig. 5 Puncture technique: Gentle aspiration of the cannula with a syringe during puncture results in blood being aspirated when the vessel has been punctured.



© Images Paediatr Cardiol

Fig. 6 Thereafter, a suitable guidewire is prepared.

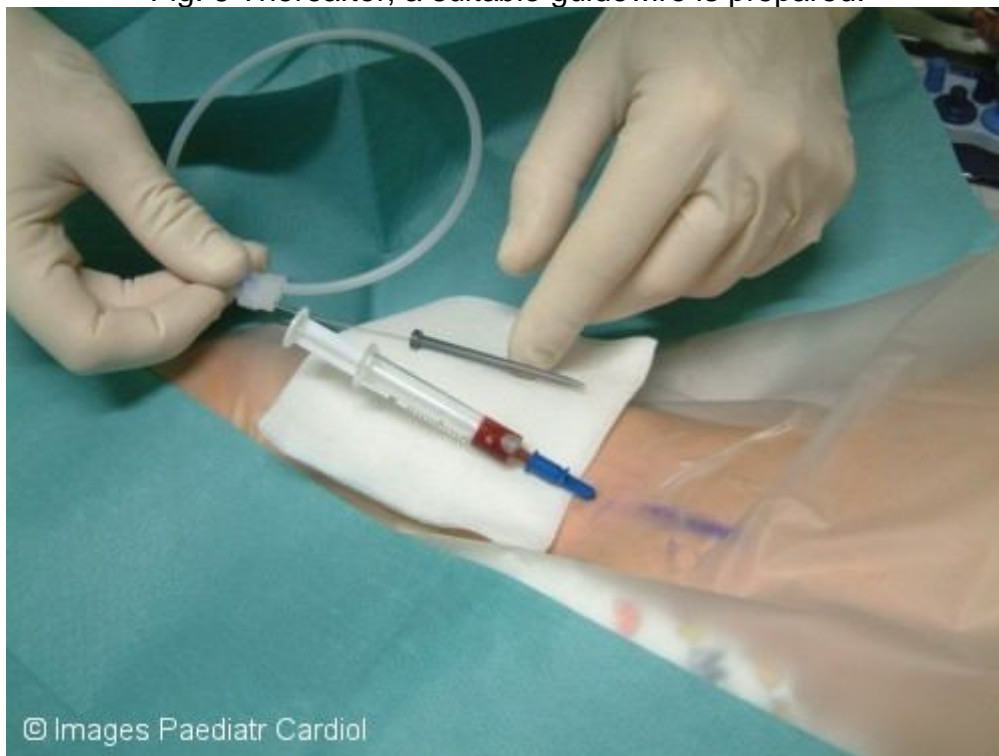

Fig. 7 The guidewire is introduced into the vein. A dilator may be used to enlarge the wiretrack.

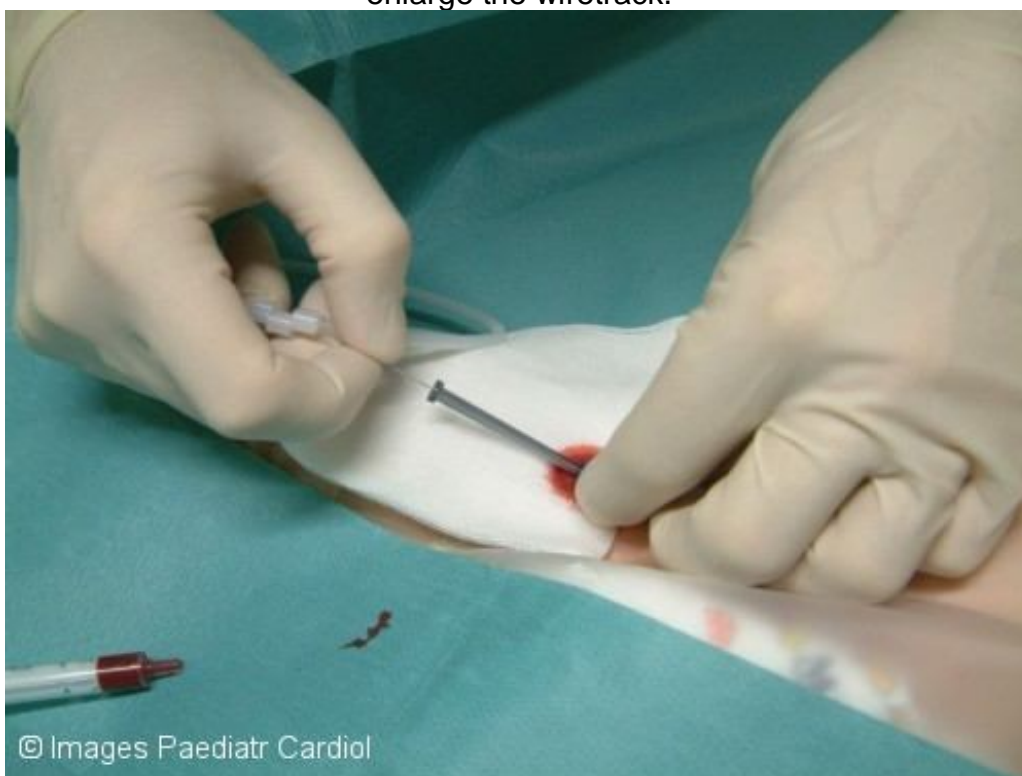

Fig 8 In some instances, it may also be necessary to make a small skin incision with a scalpel.

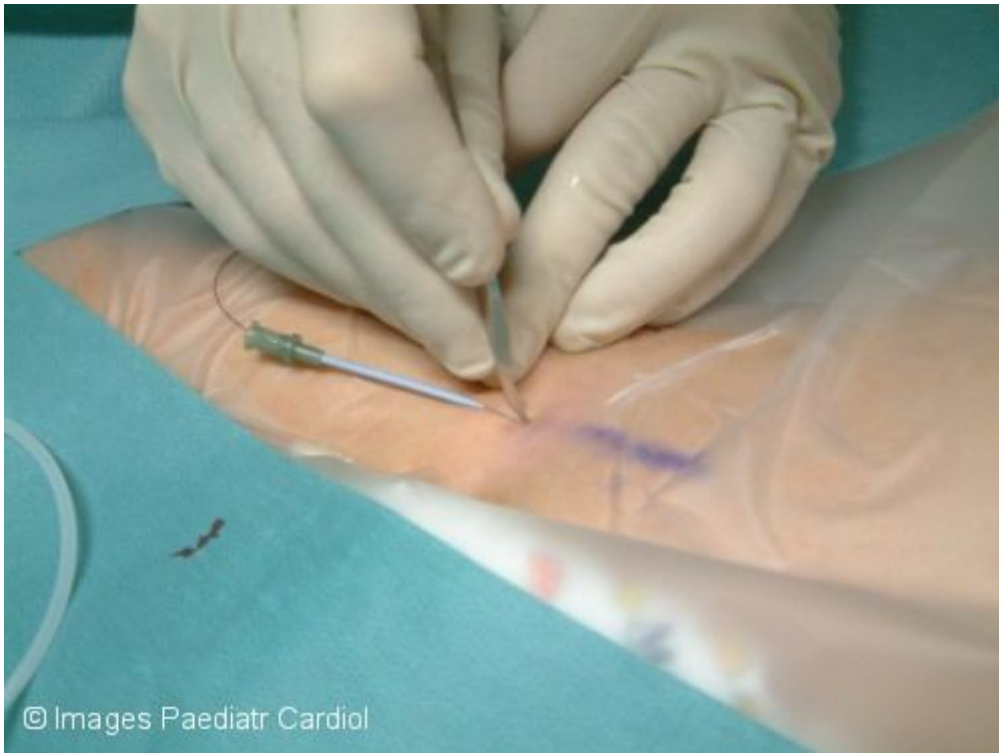

Fig 9 Thereafter, the chosen central venous line may be inserted over the wire.

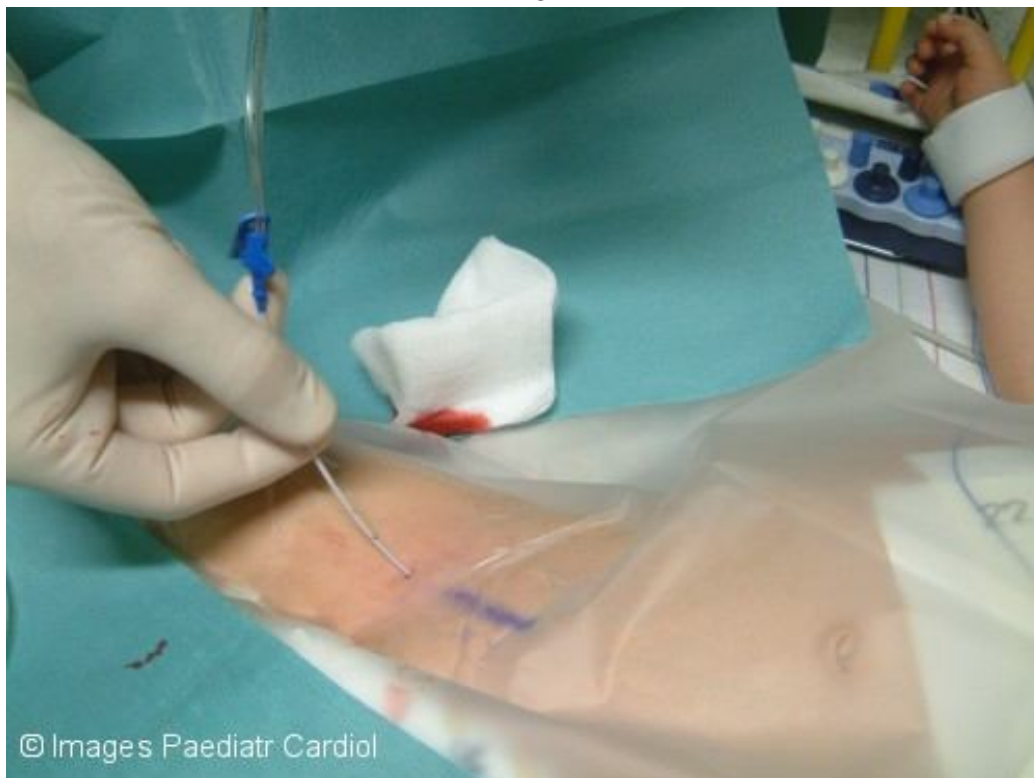

Fig 10 The line is sutured in place.

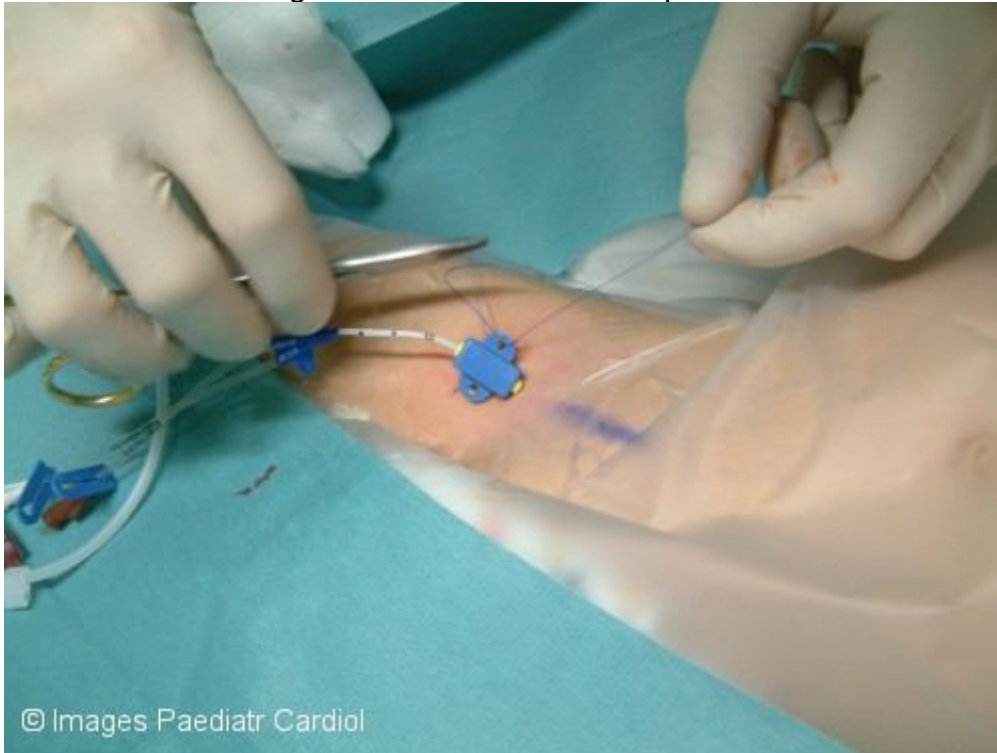
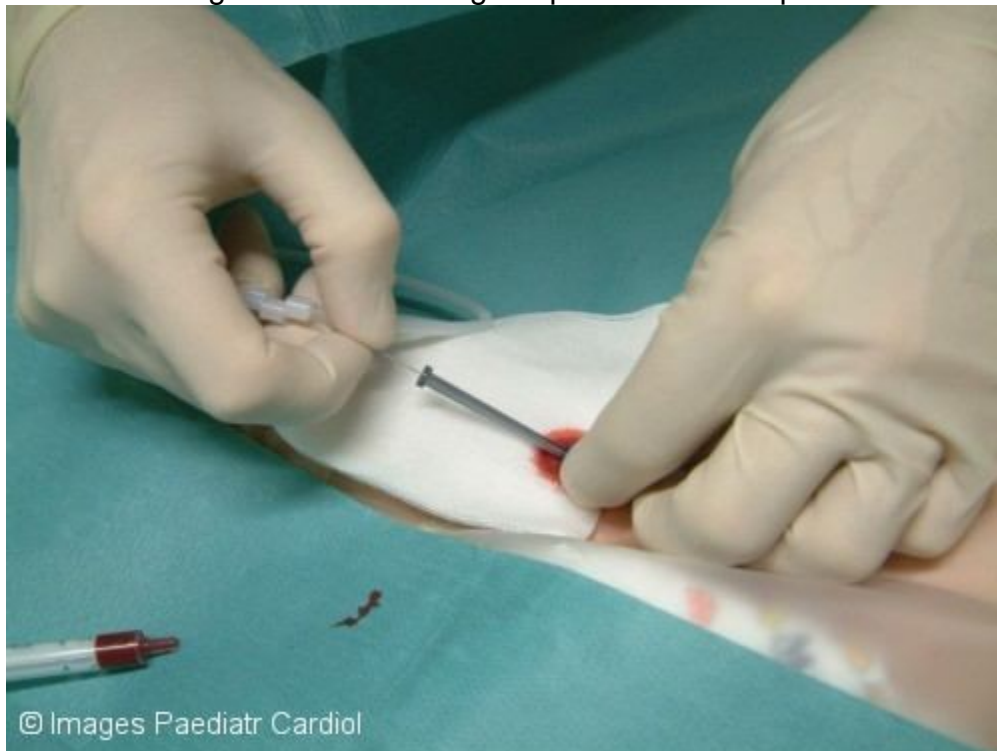

Fig 11 Video showing the puncture technique.



Ultrasound

Ultrasound can be used to visualise the dimension and position of the femoral vein in relation to the femoral artery. In particular in patients with expected difficulties, with previous central lines or previously inserted cardiac catheters in that position an ultrasound improves the likelihood of a successful puncture either by ultrasound prior to puncture for definition of the anatomy or by direct ultrasound guidance during puncture.⁶

For real-time observation of the puncture the ultrasound device is kept in a sterile glove. The position of the needle can then be observed. The compression of the vein with the tip of the needle is seen very clearly. The direct puncture of the vein is not always seen, but it is sufficient to observe the needle in the correct direction towards the vein and not hitting the artery.

Risks and complications

The central venous access via the femoral vein has a low complication rate during insertion but higher maintenance problems.^{3–5}

Difficulties and complications during insertion

The major risk is the accidental puncture of the femoral artery with the creation of hematomas. Maintenance problems include thrombus formation and infection.

In young patients in whom the femoral venous catheter needs to remain for periods of >one week, it is essential to scrupulously practise a sterile maintenance technique. In patients with persistent fever and clinical signs of infection (raised CRP, leucocytosis) in whom no other focus of infection is found, the femoral line may have to be electively removed, and another venous access site used.

Discussion

Access via the femoral vein for placement of a central venous line is easy, has a low insertion-related complication rate and is therefore often the preferred site. Two particular problems are discussed in the available literature: a) the risk of infection and b) the risk of thrombus formation.

The infection rates in adults are lowest for the subclavian access and highest for the femoral site. In children these findings have not been confirmed.^{3–5} The rate of infection seems to depend mainly on the duration of the central venous line and lower age.⁸ Other studies have shown that the overall rate of infection can be reduced by using heparin coated catheters.^{9,10}

Concerning the risk of thrombus formation there are conflicting data in the literature. Some papers report increased risk of catheter obstruction and thrombosis for the femoral vein, while others such as the Canadian Registry of Venous Thromboembolic Complications report higher risk for venous thrombosis in children when the central venous line is placed in the upper venous system.^{5,11}

Conclusions

Minor variations in venous anatomy, and ease of access mean that the femoral venous site is the one most commonly used for central venous access in infants and children for diagnostic catheterization or interventional procedures, and also when the catheters do not need to be in place for durations exceeding seven days.

References

1. Trieschmann U, Udink ten Cate F, Sreeram N. Central venous catheters in children and neonates – what is important? *Images Paediatr Cardiol.* 2007;9(4):1–8.
2. Trieschmann U, Kruessell M, Udink ten Cate F, Sreeram N. Central venous catheters in children and neonates (Part 2) – Access via the internal jugular vein. *Images Paediatr Cardiol.* 2008;10(1):1–7.
3. Jonge RC, Polderman KH, Gemke RJ. Central venous catheter use in the pediatric patient: mechanical and infectious complications. *Pediatr Crit Care Med.* 2005;6:329–39.[PubMed: 15857534]
4. Karapinar B, Cura A. Complications of central venous catheterization in critically ill children. *Pediatr Int.* 2007;49:593–9.[PubMed: 17875082]
5. Casado-Flores J, Barja J, Martino R, Serrano A, Valdivielso A. Complications of central venous catheterization in critically ill children. *Pediatr Crit Care Med.* 2001;2:57–62.[PubMed: 12797890]
6. Maecken T, Grau T. Ultrasound imaging in vascular access. *Crit Care Med.* 2007;35:S178–S185.[PubMed: 17446777]
7. Bosman M, Kavanagh RJ. Two dimensional ultrasound guidance in central venous catheter placement, a postal survey of the practice and opinions of consultant pediatric anesthetists in the UK. *Pediatr Anesth.* 2006;16:530–537.
8. Garcia-Teresa MA, Casado-Flores J, Delgado Dominguez MA, Roqueta-Mas J, Cambra-Lasaosa F, Concha-Torre A, Fernando-Perez C. Infectious complications of percutaneous central venous catheterization in pediatric patients- A Spanish multicenter study. *Intensive Care Med.* 2007;33:466–76.[PubMed: 17235512]
9. Pierce CM, Wade A, Mok Q. Heparin-bonded central venous lines reduce thrombotic and infective complications in critically ill children. *Intensive Care Med.* 2000;26:967–72.[PubMed: 10990114]
10. Long DA, Coulthard MG. Effect of heparin-bonded central venous catheters on the incidence of catheter-related thrombosis and infection in children and adults. *Anaesth Intensive Care.* 2006;34:481–4.[PubMed: 16913346]
11. Massicotte MP, Dix D, Monagle P, et al. Central venous catheter related thrombosis in children: Analysis of the Canadian Registry of Venous Thromboembolic Complications. *J Pediatr.* 1998;133:770–776.[PubMed: 9842042]

