SIGNS AND SYMPTOMS OF CARDIOVASCULAR SYSTEM DISEASES

LECTURE IN INTERNAL MEDICINE PROPAEDEUTICS

M. Yabluchansky, L. Bogun, L.Martymianova, O. Bychkova, N. Lysenko, N. Makienko
V.N. Karazin National University Medical School' Internal Medicine Dept.

Plan of the lecture

- The importance of the cardiovascular system
- Reminder
  - The primary function
  - How does cardiovascular system work
  - Purpose
  - History-taking
  - Patient examination
    - Clinical
    - Laboratory
    - Instrumental
    - Imaging
    - Other tests
- Spectrum of cardiovascular system diseases
- Syndromes of cardiovascular system diseases
- Acquired valvular heart defects
  - (Arterial) hypertension
  - Coronary insufficiency
  - Heart failure
- Glossary of cardiovascular system pathology' terms

The importance of the cardiovascular system

- Cardiovascular diseases (CVDs) are the number 1 cause of death globally: more people die annually from CVDs than from any other cause
- An estimated 17.5 million people died from CVDs in 2012, representing 31% of all global deaths
- Over three quarters of CVD deaths take place in low- and middle-income countries
- Out of the 16 million deaths under the age of 70 due to noncommunicable diseases, 82% are in low and middle income countries and 37% are caused by CVDs

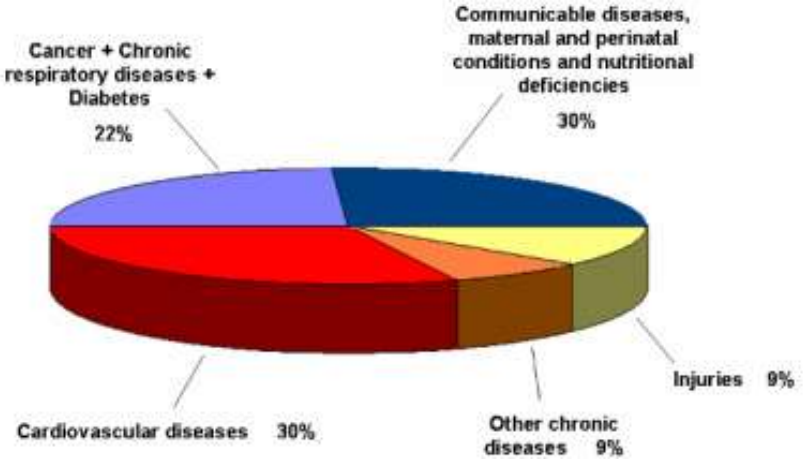

http://biommeda.elis.ugent.be/sites/biommeda.elis.ugent.be/files/image/jan1.png http://www.who.int/mediacentre/factsheets/fs317/en/

Reminder: : the cardiovascular system functions

The four major functions of the cardiovascular system are:

1. To transport nutrients, gases and waste products around the body
2. To protect the body from infection and blood loss
3. To help the body maintain a constant body temperature (‘thermoregulation’)
4. To help maintain fluid balance within the body

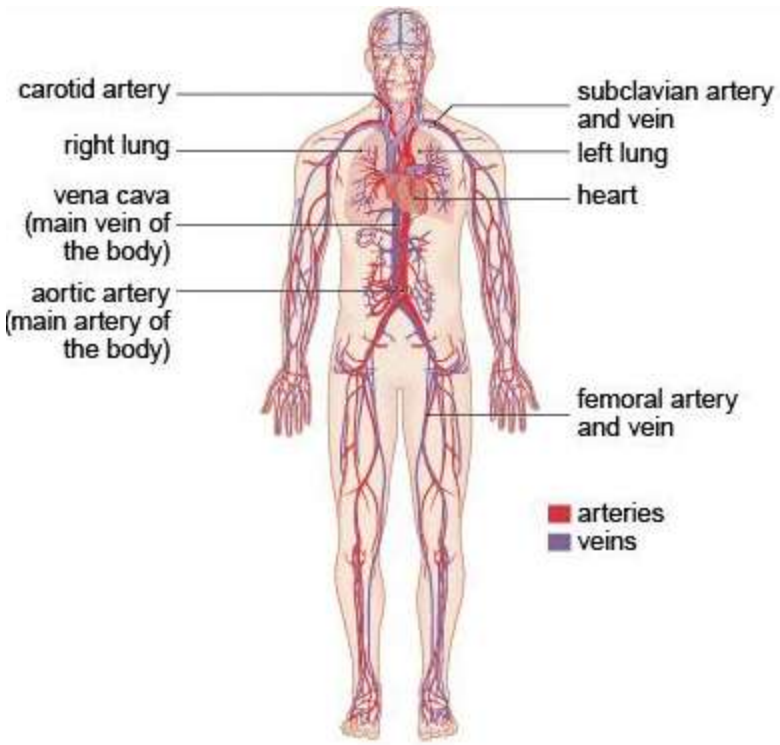

The main organs, arteries and veins in the cardiovascular system

http://www.healthcare-online.org/Functions-Of-The-Cardiovascular-System.html
http://www.ptdirect.com/training-design/anatomy-and-physiology/major-functions-of-the-cardiovascular-system-2013-a-closer-look

Reminder: how does the cardiovascular system work

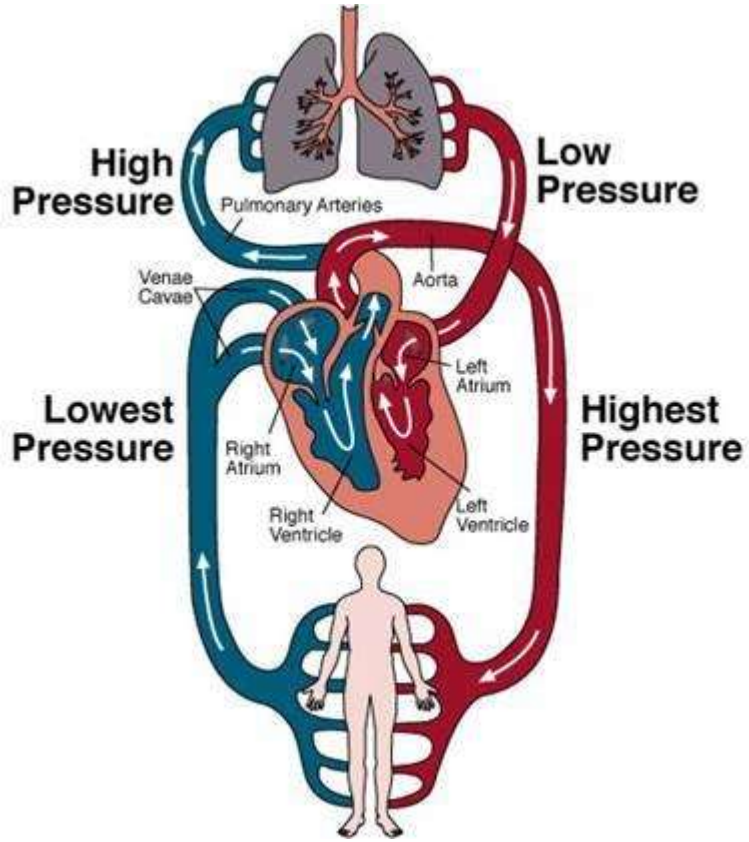

http://www.mayoclinic.org/diseases-conditions/heart-disease/multimedia/circulatory-system/vid-20084745

http://img.ehowcdn.com/default/ehow/images/a04/ol/6n/human-circulatory-system-work-800x800.jpg

Reminder: purpose

- General evaluation of health
- Diagnosis of disease or disorders of the cardiovascular system
- Diagnosis of other systemic diseases that affect cardiovascular system functions
- Monitoring of patients with cardiovascular system diseases

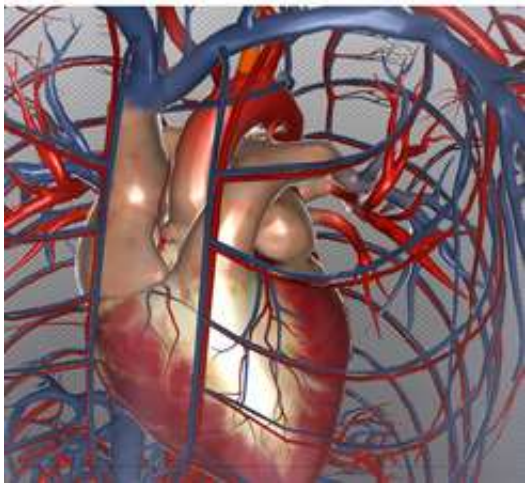

http://sciencehumanbodyproject.wikispaces.com/file/view/circulatory_system.png/334472954/400x250/circulatory_system.png

History-taking
(patient interviewing)

- Gathering of information
- patient’s narrative
- Biomedical perspective
- Psychosocial perspective
- Context

https://www.uchealth.org/PublishingImages/img-general/ABOUT-stock-interview.jpg

Patient clinical examination

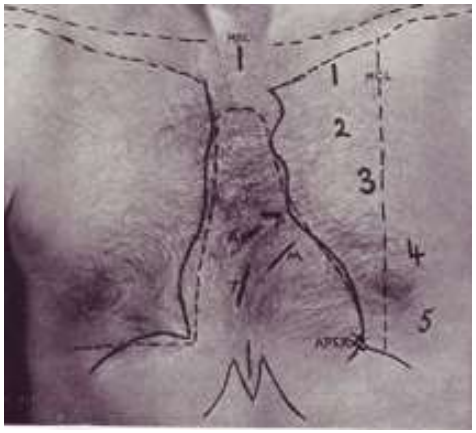

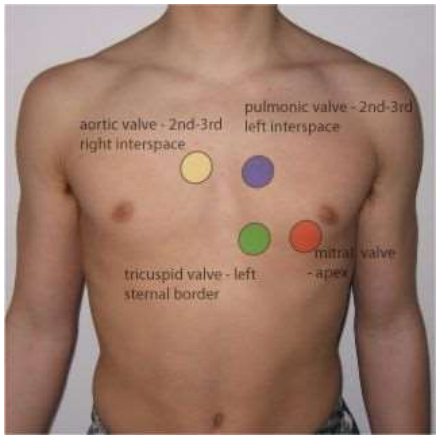

Inspection **Palpation** **Percussion** **Auscultation**

http://usercontent1.hubimg.com/8263290_f520.jpg https://s-media-cache-ak0.pinimg.com/736x/54/75/7f/54757fae51975182a269410d1d1b31d1.jpg http://www.osceskills.com/resources/Palpate-for-

Laboratory tests ordinarily used for examination of patients with cardiovascular diseases

Test Name	Lower/normal risk	High risk
Total Cholesterol	<200 mg/dL	>240 mg/dL
LDL-C	<100 mg/dL	>160 mg/dL
HDL-C	>60 mg/dL	<40 mg/dL
Triglyceride	<150 mg/dL	>200 mg/dL
Blood Pressure	<120/80 mmHg	>140/90 mmHg
C-reactive protein	<1 mg/L	>3 mg/L
Fibrinogen	<300 mg/dL	>460 mg/dL
Homocysteine	<10 µmol/L	>14 µmol/L
Fasting Insulin	<15 µIU/mL	>25 µIU/mL
Ferritin	male 12–300 ng/mL female 12–150 ng/mL	
Lipoprotein (a) - Lp(a)	<14 mg/dL	>19 mg/dL
Calcium Heart Scan	<100	>300

s_and_procedures

Patient laboratory examination: additional tests

- Homocysteine
- Blood sugar control (fasting, after eating or averages using glycosylated albumen or hemoglobin)
- Myoglobin
- Creatine kinase
- Troponin
- Brain-type natriuretic peptide
- etc.

http://images.sciencedaily.com/2014/11/141126075113_1_900x600.jpg https://en.wikipedia.org/wiki/Cardiology_diagnostic_tests_and_procedures

Patient instrumental examination

- Electrocardiogram
- Holter Monitoring
- Event monitoring
- Blood Pressure Monitoring
- Stress Testing (Exercise Treadmill Test)
- Echocardiograms
- Venous Duplex or Venous Doppler Studies
- Arterial Segmental Pressure Studies
- Carotid Doppler Studies
- Electrophysiology study
- Cardiac imaging techniques include coronary catheterization, computer tomography (CT), etc.

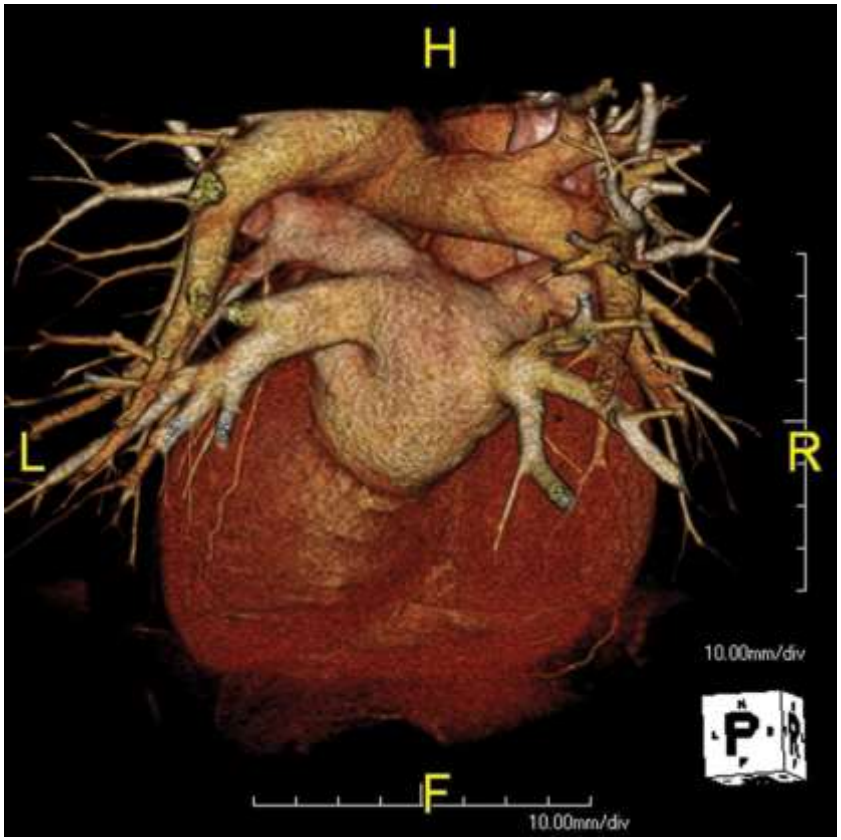

Pulmonary venous anatomy by cardiac CT

http://bmb.oxfordjournals.org/content/93/1/49/F5.large.jpg

Types of cardiovascular system diseases and syndromes

- Ischemic heart disease
- Arterial hypertension
- Cardiomyopathies
- Rheumatic heart disease
- Congenital heart diseases/abnormalities (conductive system, valves, vessels, heart defects)
- Inflammatory diseases (endocarditis, myocarditis, pericarditis)
- Peripheral vascular disease
- Heart failure
- Cerebrovascular disease (Stroke)

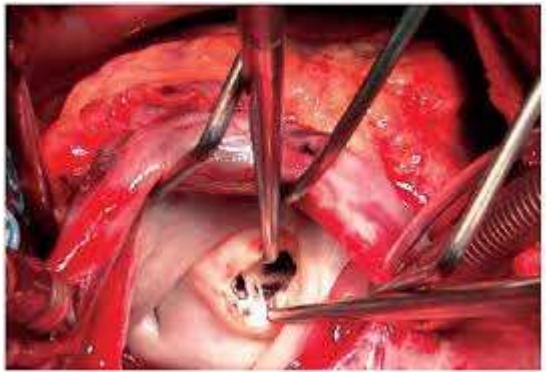

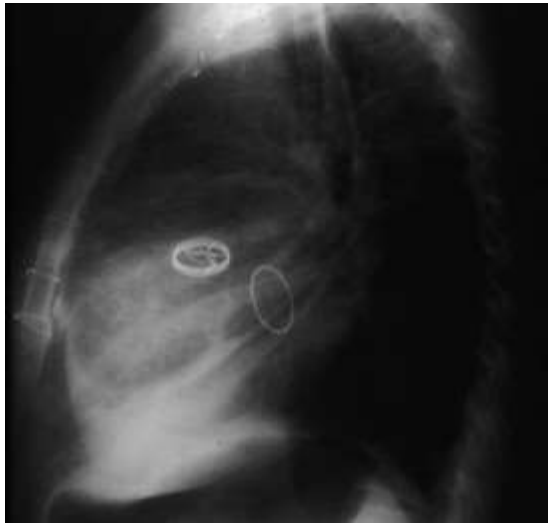

http://www.mediologiest.com/rheumatic-heart-disease-rhd-symptoms-effects-causes-risk-factor-diagnosis-complications-prevention-and-treatment-of-rheumatic-heart-disease-rhd/
http://www.phac-aspc.gc.ca/cd-mc/cvd-mcv/cvd-mcv-eng.php

Acquired valvular heart defects

Acquired valvular heart defects: definition, classification

- The heart valves are part of the dense connective tissue makeup of the heart known as the heart skeleton
- Valves that are formed properly at birth can still develop problems (acquired valvular heart defects) related to aging, infection, heart attack, damage and other events that cause wear and tear to the valves, e.g. by a build-up of calcium deposits on the valve leaflets, making them stiff and inflexible
- Acquired valvular heart defects develop after birth and may involve one or more of the four valves of the heart (the aortic and mitral valves on the left and the pulmonary and tricuspid valves on the right)
- The two major types defects of everyone heart valve are:
  - Insufficiency/regurgitation (the valve's tissue flaps (leaflets), which control the flow and direction of the blood, do not fully close or the edges do not fully meet, which causes blood to leak back into the heart)
  - Stenosis (the leaflets cannot open fully to allow enough blood to flow through)
- The aortic and mitral valves are the ones that most commonly become affected by acquired heart valve pathological processes

http://secondscount.org/heart-condition-centers/info-detail-2/types-causes-of-heart-valve-problems-2#.VcNQwCbtmko

Heart valves

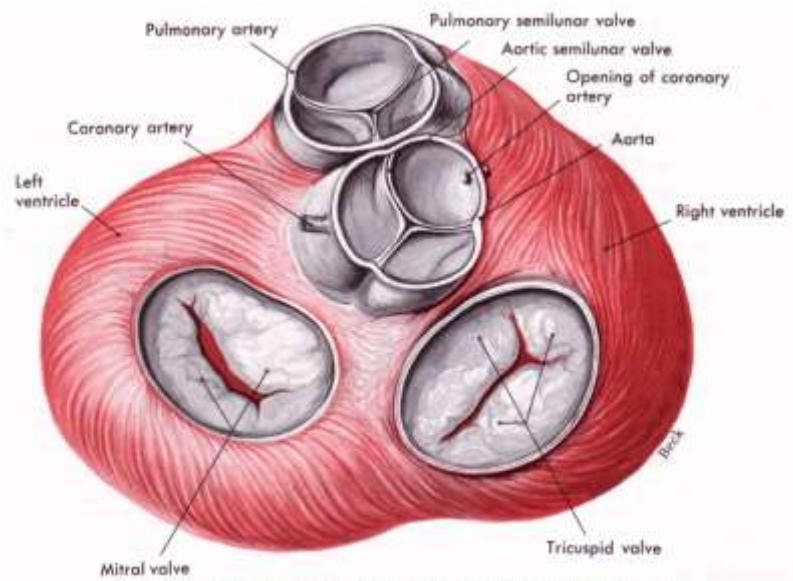

The valves of the heart viewed from above. The atria are removed to show the mitral and tricuspid valves.

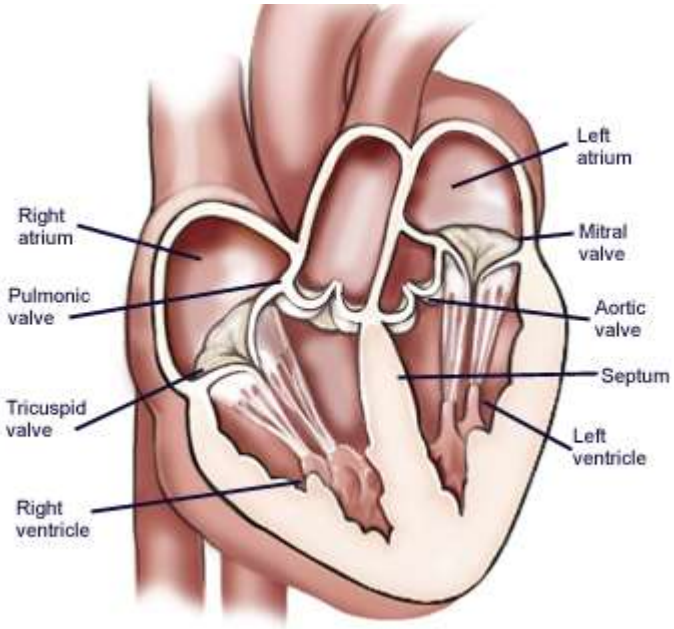

http://my.clevelandclinic.org/ccf/media/Images/heart/insideheart2.JPG http://sundar.me/wp-content/uploads/2011/03/heart-valves-from-above.gif

Principal elements of the heart' fibrous skeleton

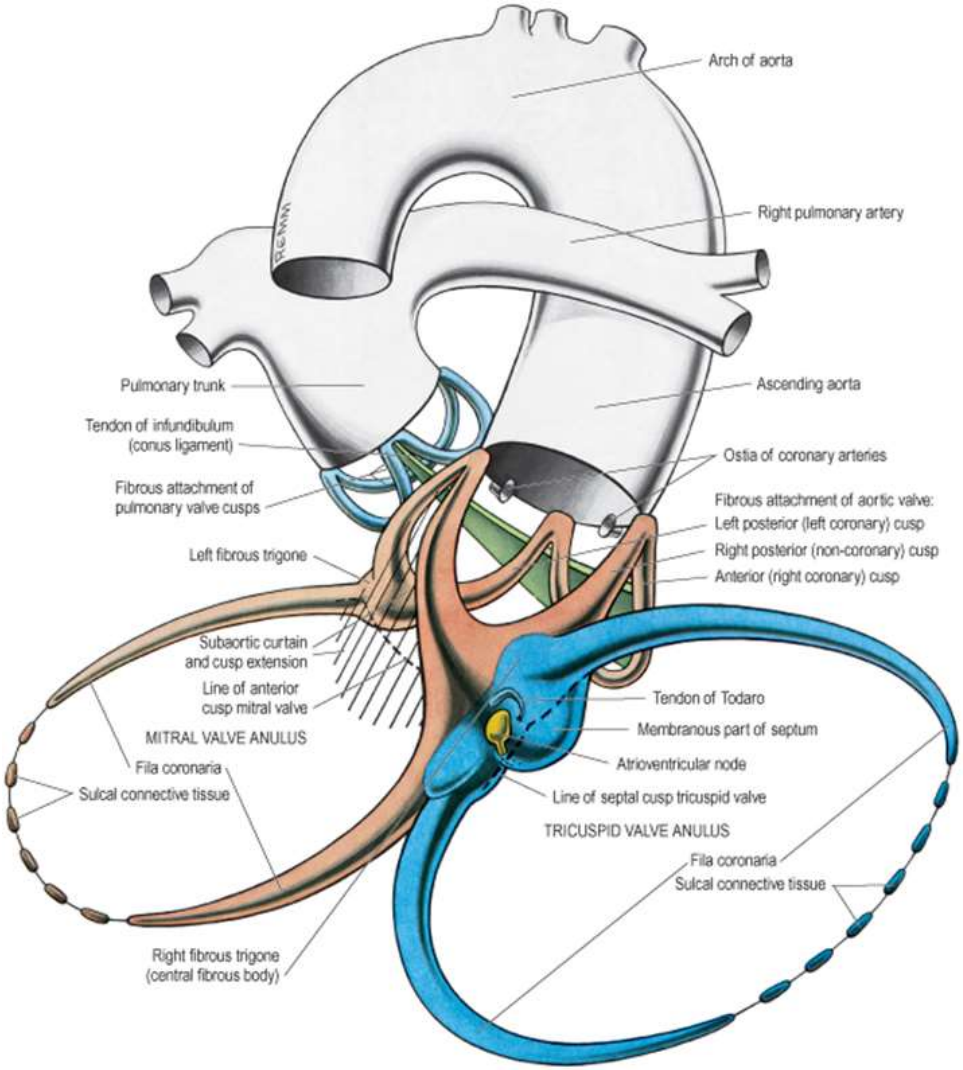

https://drkamaldeep.files.wordpress.com/2011/05/image109_thumb.png?w=720&h=818

Acquired valvular heart defects: causes and risk factors

- Age
- Heart attack
- Heredity
- Calcium deposits
- Endocarditis
- Rheumatic fever
- High blood pressure
- Cardiomyopathy
- Connective tissue diseases

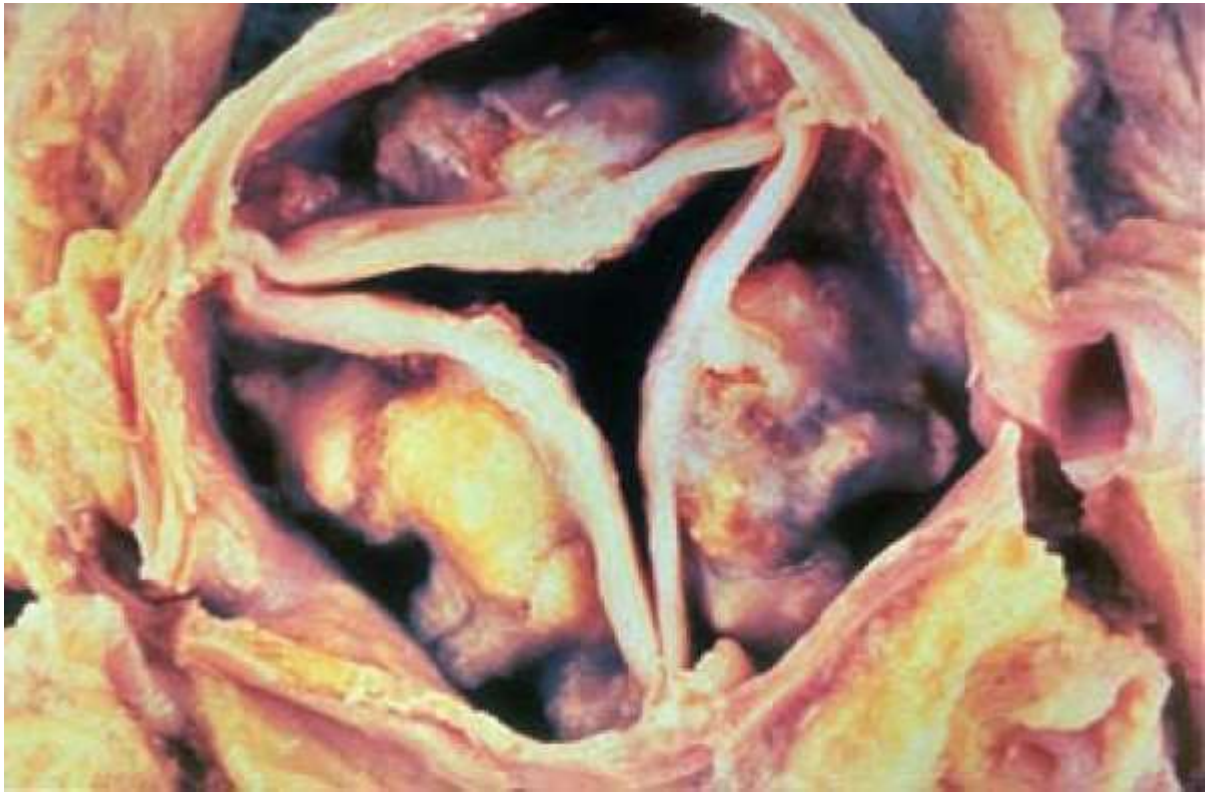

Calcified aortic valves

http://secondscount.org/heart-condition-centers/info-detail-2/types-causes-of-heart-valve-problems-2#.VcNQwCbtmko

Acquired valvular heart defects: common symptoms

- Shortness of breath
- Weakness
- Dizziness
- Discomfort in chest
- Palpitations
- Edema

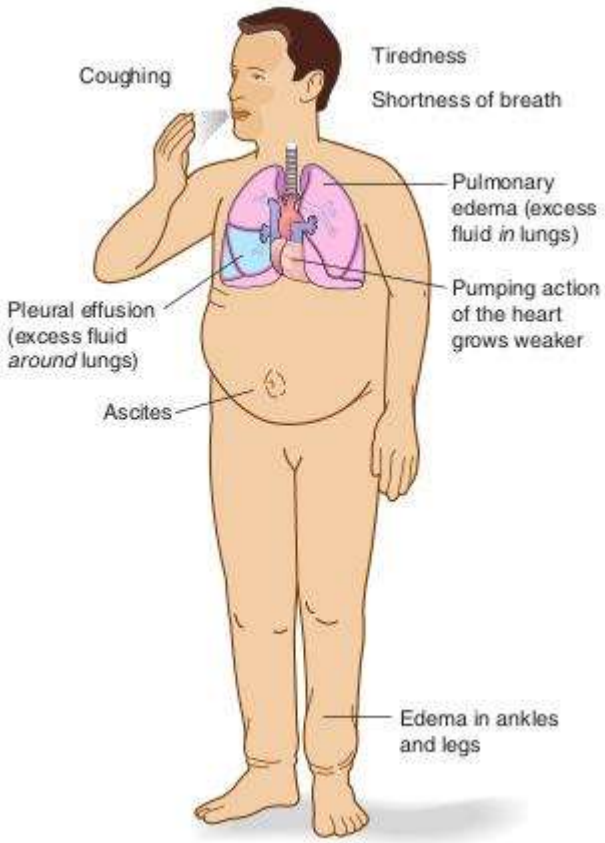

http://body-disease.com/wp-content/uploads/2012/04/Congestive-heart-failure-indicating-signs-and-symptoms.jpeg
http://secondscount.org/heart-condition-centers/info-detail-2/types-causes-of-heart-valve-problems-2#.VcNQwCbtmko

Aortic valve stenosis

Aortic valve stenosis: definition, classification

- Aortic valve stenosis (aortic stenosis) is the most common type of acquired valvular heart defects that requires valve replacement
- Aortic valve stenosis can be classified according to the anatomical location: supravalvular, valvular and subvalvular

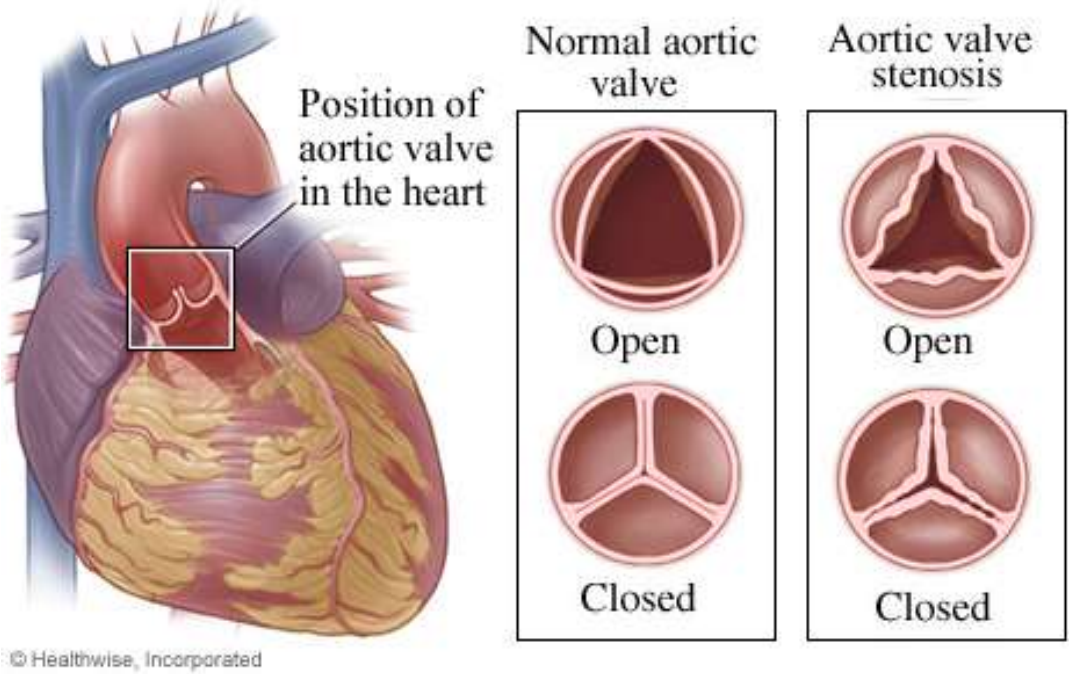

http://img.webmd.com/dtmcms/live/webmd/consumer_assets/site_images/media/medical/hw/h9991304_002.jpg http://radiopaedia.org/articles/aortic-valve-stenosis

Aortic valve stenosis: causes, risk factors

- The causes of aortic valve disease include bicuspid aortic valve, degenerative aortic valve disease, rheumatic heart disease, atherosclerotic aortic disease, etc.
- Risk factors are closely associated with atherosclerosis including diabetes, smoking, hypertension and dyslipidemia

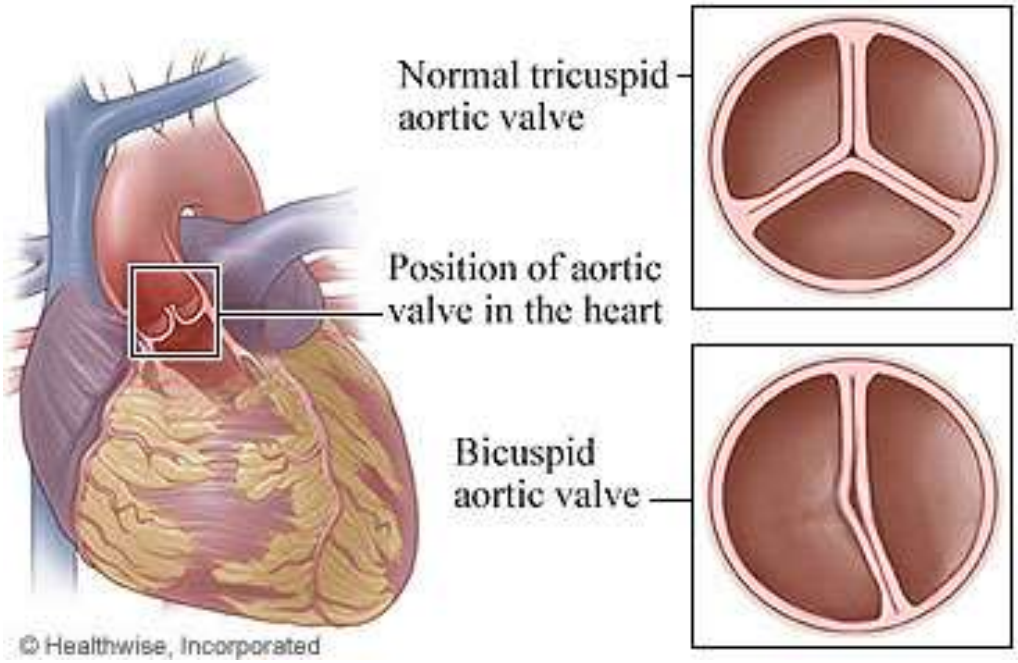

Bicuspid aortic valve

https://myhealth.alberta.ca/health/aftercareinformation/_layouts/15/healthwise/media/medical/hw/h9991304_004_pi.jpg http://radiopaedia.org/articles/aortic-valve-stenosis

Aortic valve stenosis: heart changes

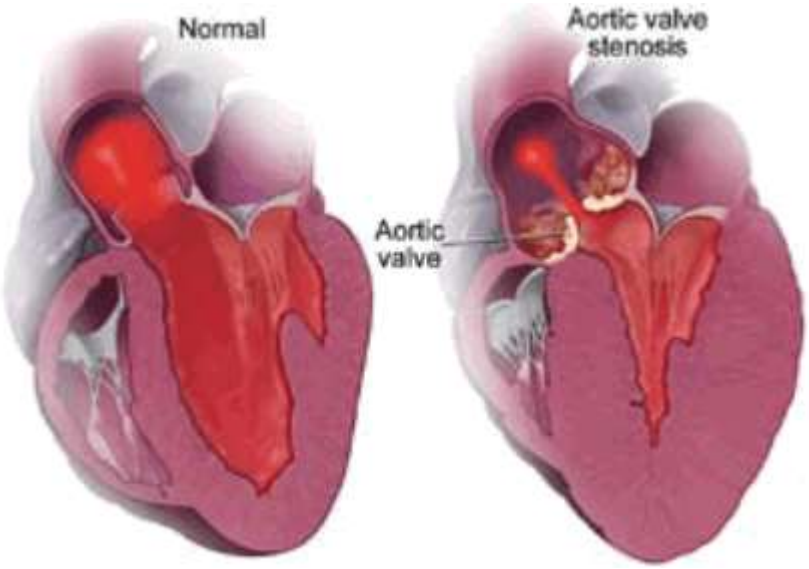

Normal and aortic stenosis' hearts: find difference

http://www.marvistavet.com/assets/images/aortic_stenosis.gif

Aortic valve stenosis: signs and symptoms: classic triad

- Chest pain: angina pectoris in patients with aortic stenosis is typically precipitated by exertion and relieved by rest
- Heart failure: symptoms include paroxysmal nocturnal dyspnea, orthopnea, dyspnea on exertion, and shortness of breath
- Syncope: often occurs upon exertion when systemic vasodilatation in the presence of a fixed forward stroke volume causes the arterial systolic blood pressure to decline

http://emedicine.medscape.com/article/150638-overview

Aortic valve stenosis: signs and symptoms: other

- Systolic hypertension
- Low values of systolic and pulse blood pressure
- Pulsus alternans
- Hyperdynamic left ventricle
- Soft or normal S1, diminished or absent A2, paradoxical splitting of the S2, accentuated P2, ejection click, prominent S4, the classic crescendo-decrescendo systolic murmur

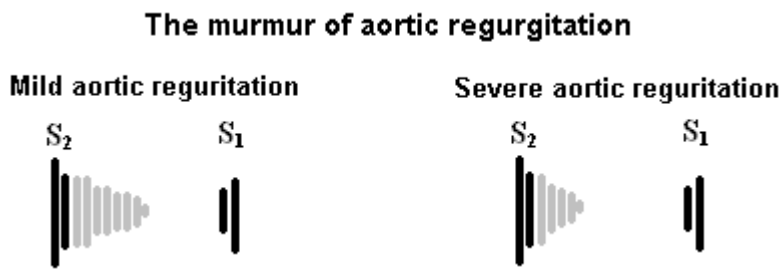

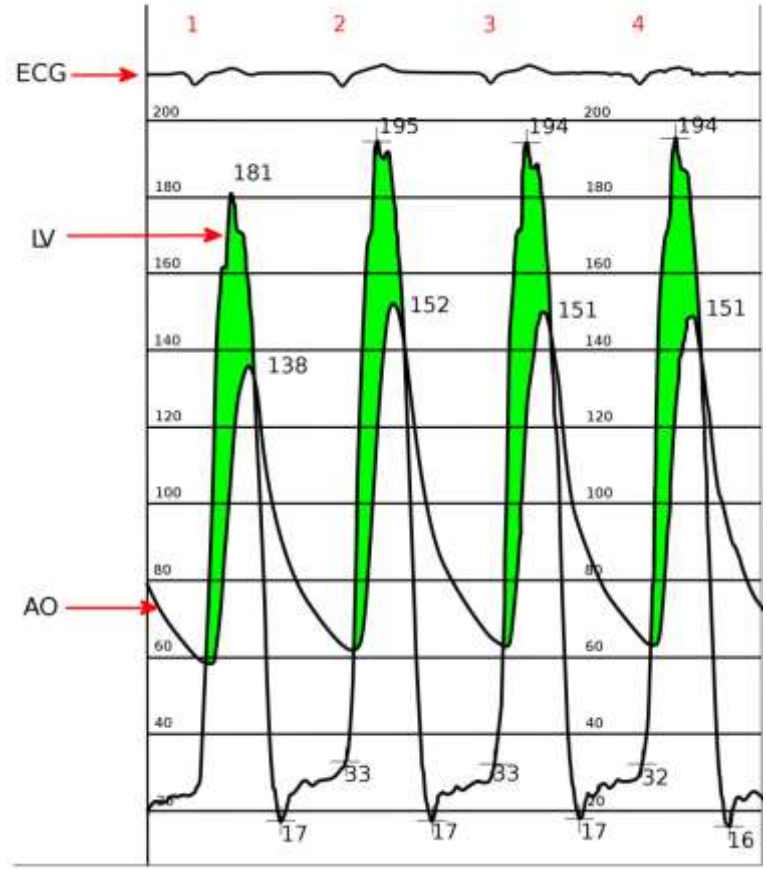

Pressure gradient between the left ventricle and aorta, suggesting aortic stenosis

https://upload.wikimedia.org/wikipedia/commons/thumb/8/83/Aortic_Stenosis_-_Hemodynamic_Pressure_Tracing.svg/2000px-Aortic_Stenosis_-_Hemodynamic_Pressure_Tracing.svg.png
http://www.learntheheart.com/assets/1/7/AR.png http://radiopaedia.org/articles/aortic-valve-stenosis

Aortic valve stenosis: selected laboratory studies

- Serum electrolyte levels
- Cardiac biomarkers
- Complete blood count
- B-type natriuretic peptide: May provide incremental prognostic information for predicting symptom onset in asymptomatic patients with severe aortic stenosis

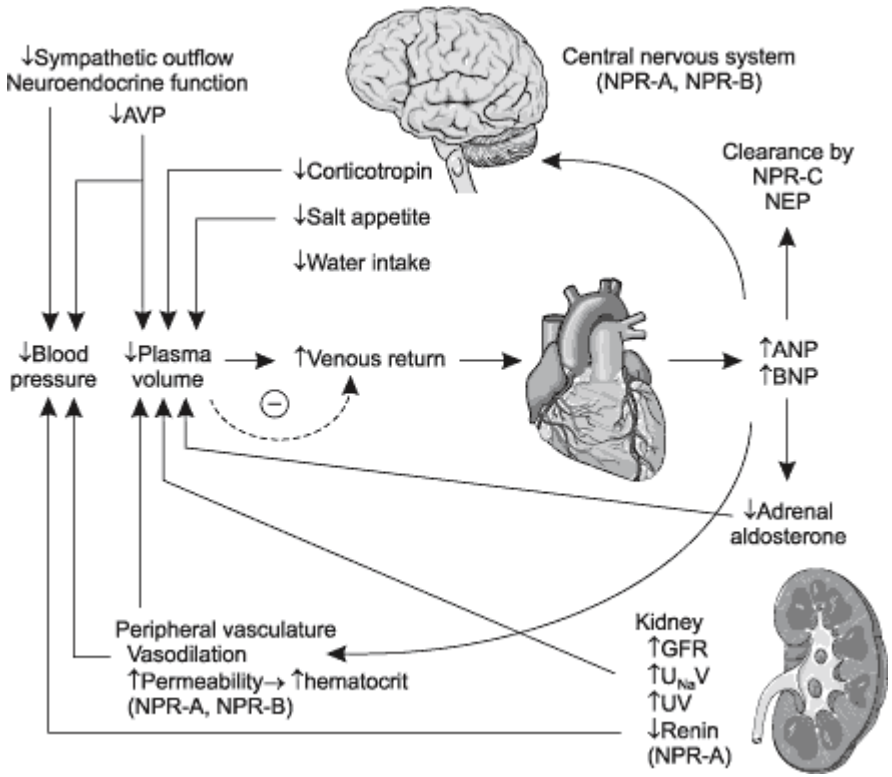

The effects of B-type natriuretic peptide (BNP) on target organs

https://journals.prous.com/journals/dot/20033910/html/dt390767/images/Mills_f2.gif http://radiopaedia.org/articles/aortic-valve-stenosis

Aortic valve stenosis: instrumental studies

- Chest X-ray
- Electrocardiogram
- Echocardiogram
- Exercise electrocardiogram
- Cardiac MRI
- Cardiac catheterization
- Radionuclide ventriculography

Parameters	Slight	Moderate	Severe
PG max	15-40 mmHg	40-70 mmHg	70-100 mmHg (> 100 mmHg severe AoS)
PG mean	<20mmHg	20-40mmHg>	40mmHg
AVA>	1.5cm^2	1.5-1cm^2	<1cm^2
Dimensionless index>	0.50	0.25 to 0.50	<0.25
Vmax	<3m/s	3-4m/s	>4m/s
AVA BSAindex	>0.85cm^2/m^2	0.85-0.60cm^2/m^2	<0.60cm^2/m^2

Aortic stenosis quantification

http://radiopaedia.org/articles/aortic-valve-stenosis

Aortic valve stenosis: B-mode echocardiography

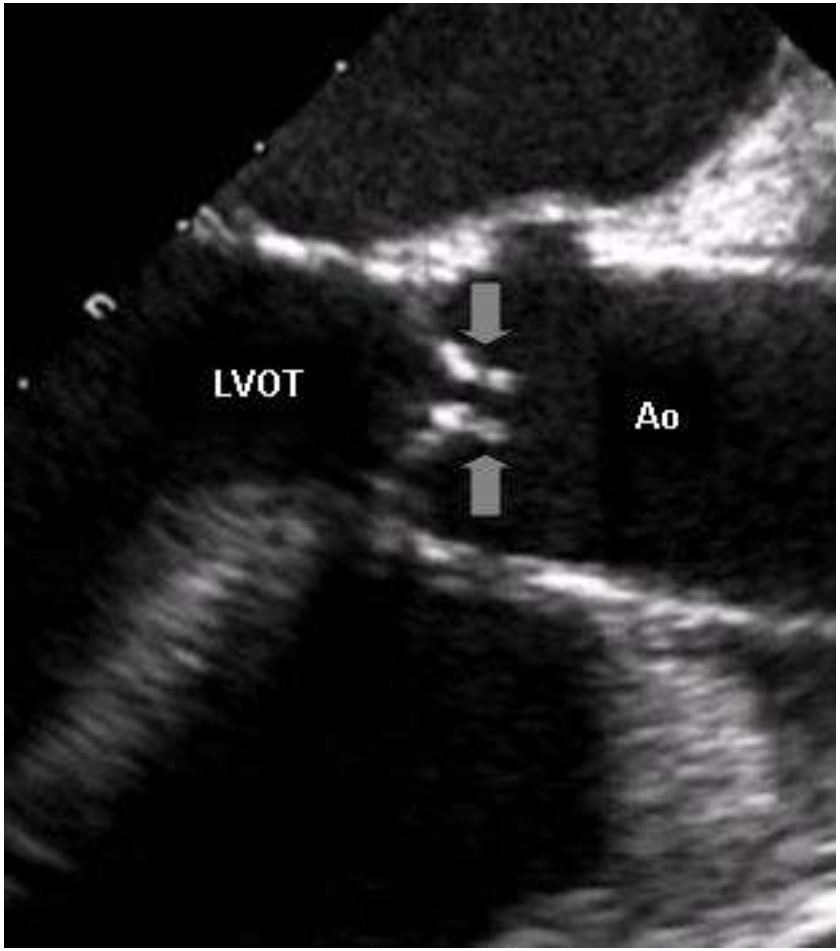

Transoesophageal echocardiogram of a severely stenotic aortic valve

http://bestpractice.bmj.com/best-practice/monograph/325/resources/image/bp/3.html

Aortic valve stenosis:
B-mode echocardiography

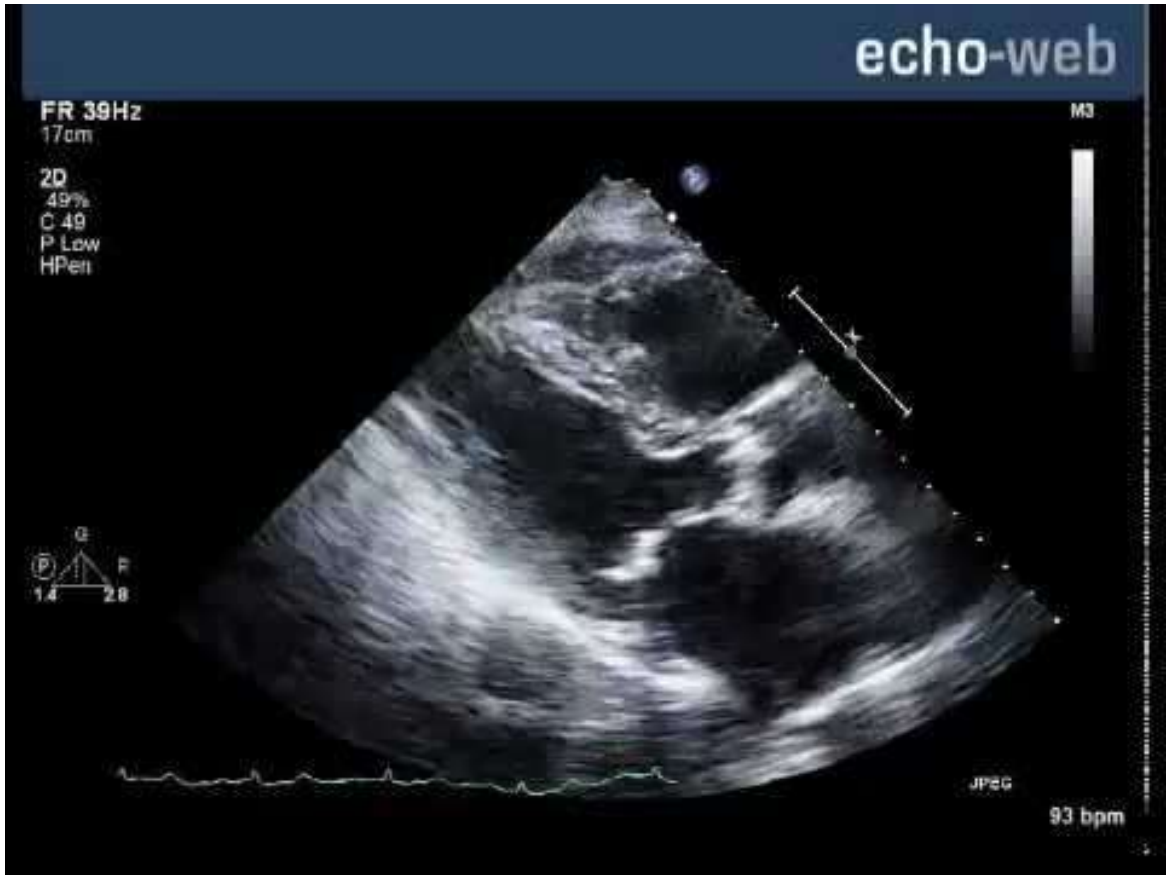

Severe Aortic Stenosis

http://i.ytimg.com/vi/dbKIxyktcds/hqdefault.jpg

Aortic valve stenosis:
B-mode echocardiography



Echocardiography for transcatheter aortic valve implantation

http://d2crugzdgfmp7d.cloudfront.net/content/ejechocard/10/1/i21/F5.medium.gif

Aortic valve stenosis: Doppler echocardiography

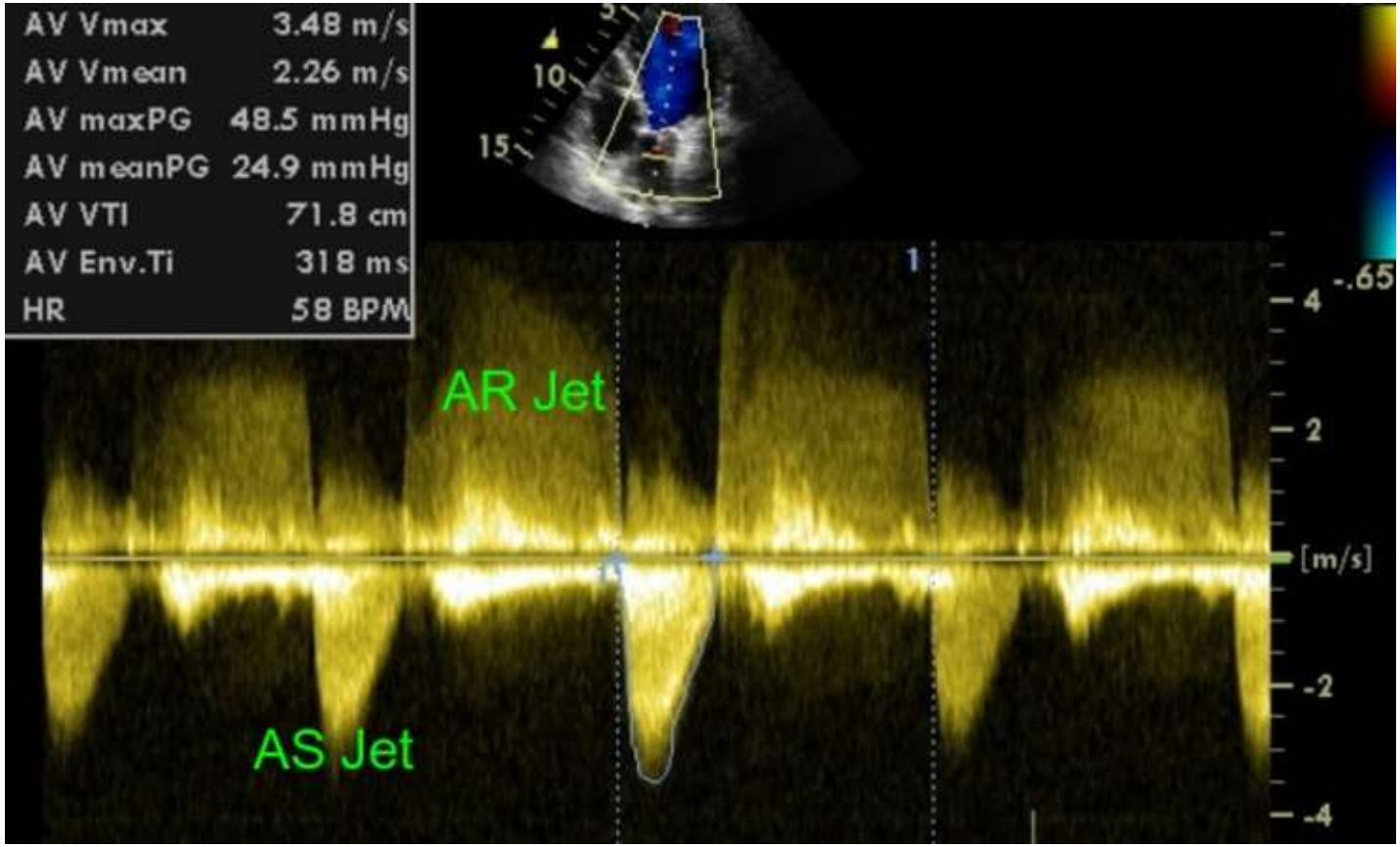

Aortic stenosis gradient

https://cardiophile.org/aortic-stenosis-gradient-by-doppler-echocardiogram/

Aortic valve stenosis: computer tomography

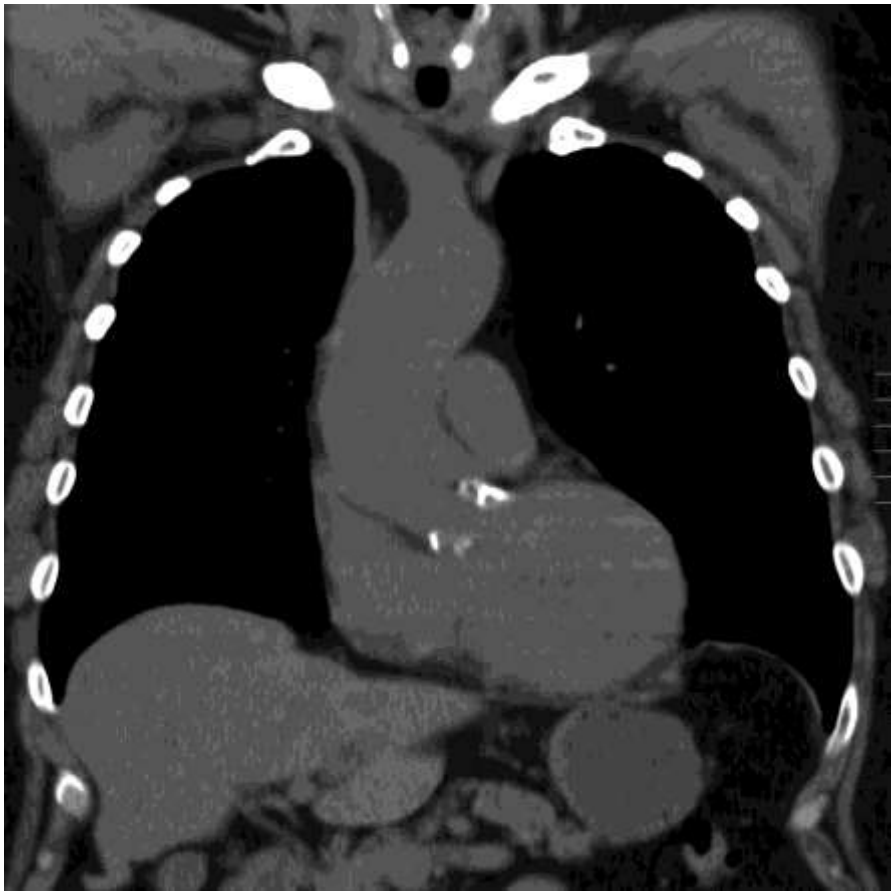

The effects of B-type natriuretic peptide (BNP) on target organs

http://radiopaedia.org/articles/aortic-valve-stenosis

Aortic valve stenosis: cardiac catheterization

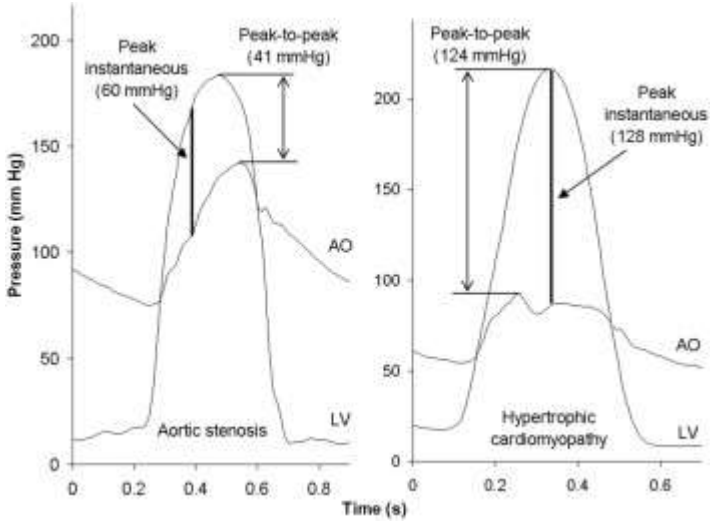

Assessment of Left Ventricular Outflow Gradient

http://interventions.onlinejacc.org/article.aspx?articleid=1207395

Aortic valve insufficiency/regurgitation

Aortic valve insufficiency/regurgitation: definition, types, causes

- Aortic insufficiency/ regurgitation (AI) is the leaking of the aortic valve of the heart that causes blood to flow in the reverse direction during ventricular diastole, from the aorta into the left ventricle
- Types: acute, chronic
- About half of the cases of AI are due to the aortic root dilation, which is idiopathic in over 80% of cases, but otherwise may result from aging, syphilitic aortitis, osteogenesis imperfecta, aortic dissection, Behçet's disease, reactive arthritis and systemic hypertension
- In about 15% the cause is innate bicuspidal aortic valve, while another 15% cases are due to retraction of the cusps as part of postinflammatory processes of endocarditis in rheumatic fever/infective endocarditis and various collagen vascular diseases
- AI has been linked to the use of some medications (fenfluramine, dexfenfluramine isomers, dopamine agonists, etc.)
- Other potential causes include Marfan's syndrome, Ehlers–Danlos syndrome, ankylosing spondylitis, etc.

https://en.wikipedia.org/wiki/Aortic_insufficiency

Aortic valve insufficiency/regurgitation: types of causes

AI Class	Type I Normal cusp motion with FAA dilatation or cusp perforation				Type II Cusp Prolapse	Type III Cusp Restriction
	Ia	Ib	Ic	Id		
Mechanism	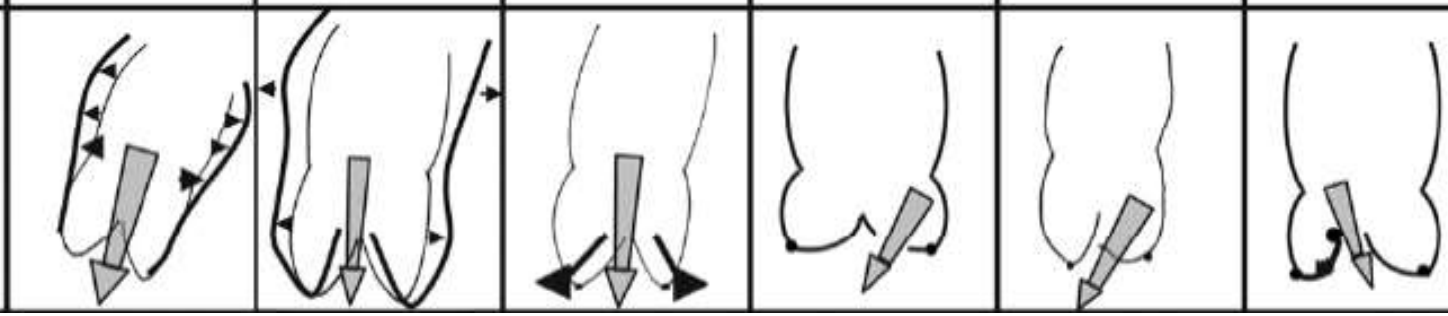					

Functional classification of aortic insufficiency (AI) with description of disease mechanisms

http://www.annalscts.com/article/viewFile/1401/2024/5273

Aortic valve insufficiency/regurgitation: pathophysiology

- In aortic insufficiency (AI), when the pressure in the left ventricle falls below the pressure in the aorta, the aortic valve is not able to completely close, and this causes a leaking of blood from the aorta back into the left ventricle (*regurgitating)*
- The percentage of blood that regurgitates back through the aortic valve due to AI is known as the regurgitant fraction
- The regurgitant flow causes a decrease in the diastolic blood pressure in the aorta, and therefore an increase in the pulse pressure
- While diastolic blood pressure is diminished and the pulse pressure widens, systolic blood pressure generally remains normal or can even be slightly elevated because sympathetic nervous system and the renin-angiotensin-aldosterone axis compensate for the decreased cardiac output
- The volume overload causes left ventricular hypertrophy (LVH) and dilation

https://en.wikipedia.org/wiki/Aortic_insufficiency

Aortic valve insufficiency/regurgitation: heart changes

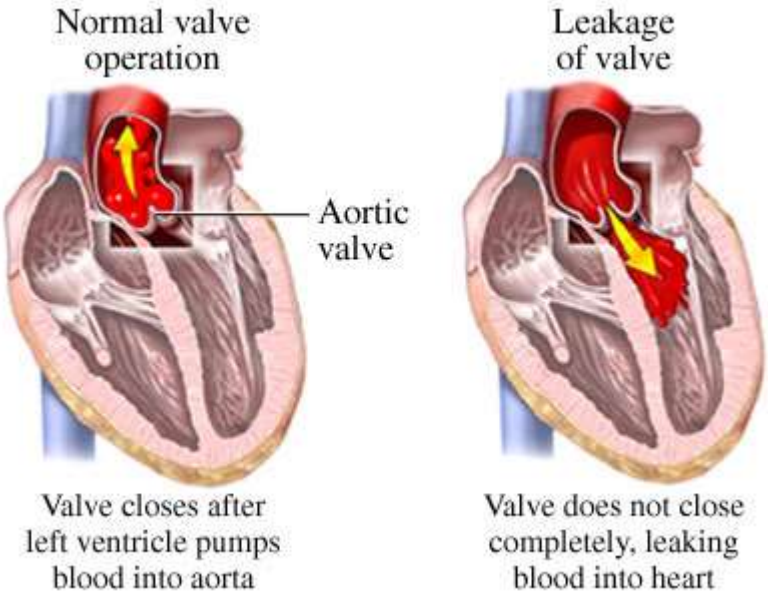

Normal and aortic insufficiency/regurgitation' hearts: find difference

http://www.doctortipster.com/wp-content/uploads/2011/07/aortic-regurgitation1.jpg

Aortic valve insufficiency/regurgitation: main hemodynamics disturbances

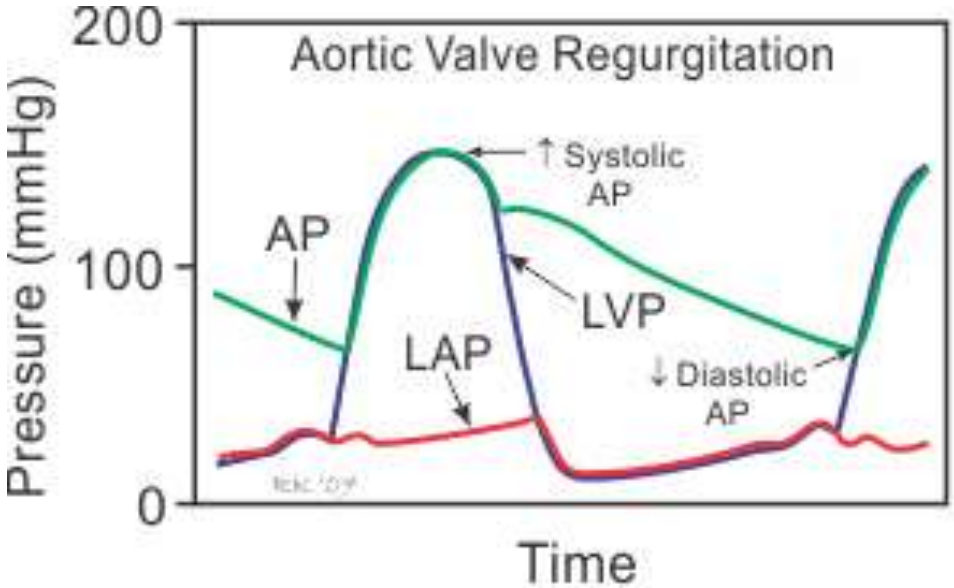

During ventricular relaxation, blood flows backwards from aorta into the ventricle. Aortic systolic pressure increases, aortic diastolic pressure decreases, and pulse pressure increases; LAP increase.
Abbreviations: LAP, left atrial pressure; LVP, left ventricular pressure; AP, aortic pressure.

The changes in aortic pressure (AP), left ventricular pressure (LVP) and left atrial pressure (LAP)

http://www.cvphysiology.com/Heart%20Disease/HD005%20aortic%20regurgitation.gif

Aortic valve insufficiency/regurgitation: symptoms

- Dyspnea on exertion
- Orthopnea
- Paroxysmal nocturnal dyspnea
- Palpitations
- Heart murmur
- Angina pectoris
- Fatigue
- Weakness
- Swollen ankles and feet (edema)
- Lightheadedness or fainting
- Cyanosis
- Circulatory shock

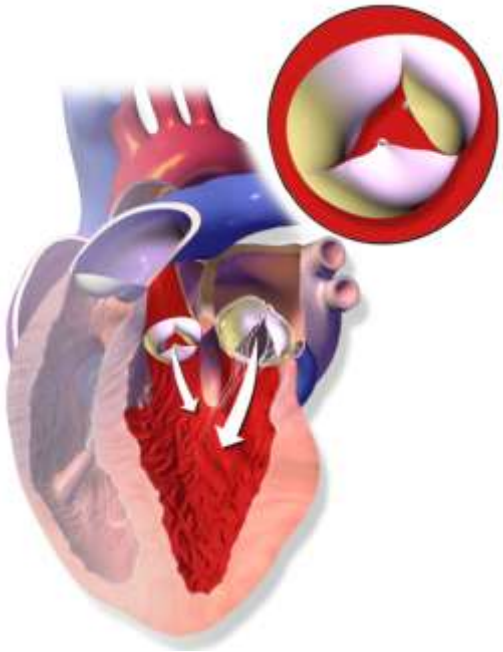

https://upload.wikimedia.org/wikipedia/commons/7/74/Blausen_0039_AorticRegurgitation.png https://en.wikipedia.org/wiki/Aortic_insufficiency

Aortic valve insufficiency/regurgitation: physical examination

- Heart murmur that can be heard through a stethoscope
- Very forceful beating of the heart
- Bobbing of the head in time with the heartbeat
- Hard pulses in the arms and legs
- Low diastolic blood pressure
- Signs of fluid in the lungs

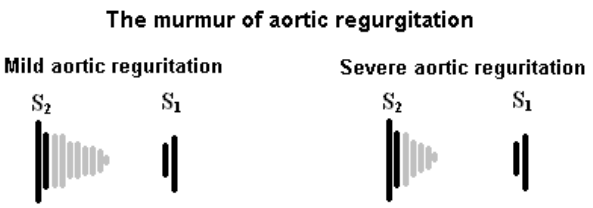

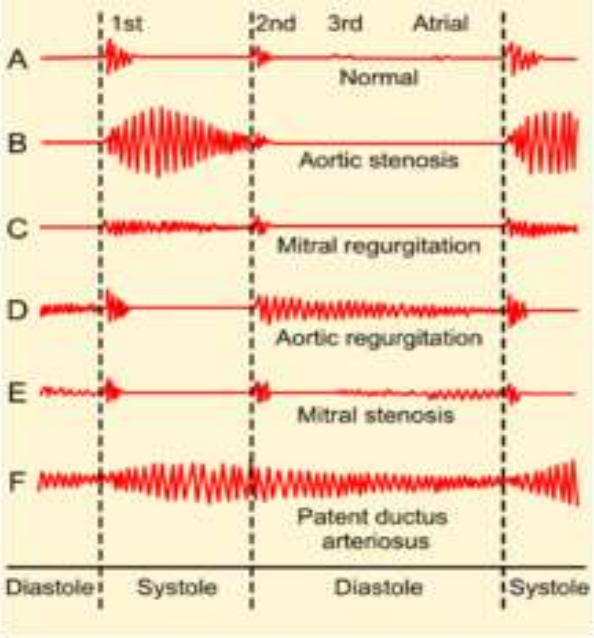

http://www.learntheheart.com/assets/1/7/AR.png https://en.wikipedia.org/wiki/Aortic_insufficiency

Aortic valve insufficiency/regurgitation: diagnostic tests

- Echocardiography
- Stress tests
- Cardiac magnetic resonance imaging
- Electrocardiography (ECG) .
- Chest X-ray
- Cardiac catheterization

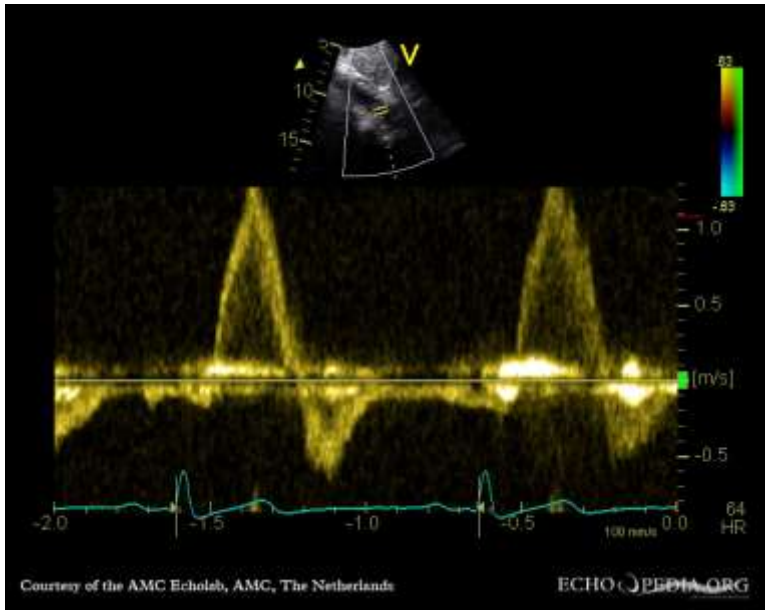

https://upload.wikimedia.org/wikipedia/commons/d/da/Bicuspid_aortic_valve,_severe_aortic_regurgitation_E00859_(CardioNetworks_ECHOpedia).jpg
https://en.wikipedia.org/wiki/Aortic_insufficiency

Aortic valve insufficiency/regurgitation: echocardiography

- The severity of aortic regurgitation is estimated using three parameters on echocardiography:
- Regurgitant jet size
- Pressure half-time
- Regurgitant fraction

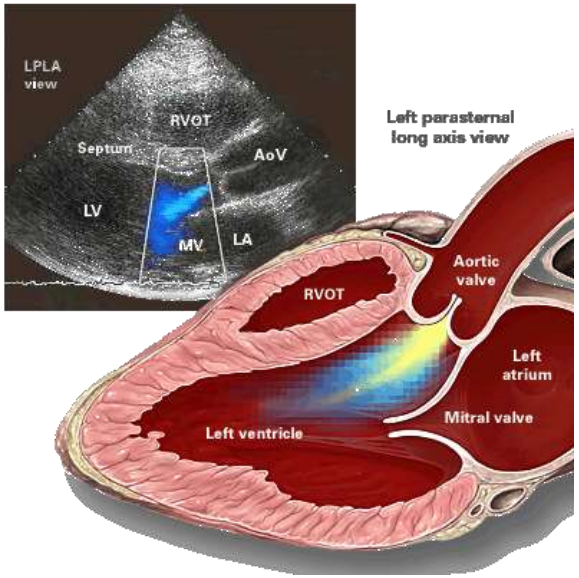

Severity	Jet Size Ratio	Pressure Half-Time	Regurgitant Fraction (%)
Mild	<24	>500	<20
Moderate	25-45	500-349	20-35
Moderate-severe	46-64	349-200	56-50
Severe	> 65	< 200	> 50

http://www.learntheheart.com/cardiology-review/aortic-regurgitation/

Aortic valve insufficiency/regurgitation: echocardiography

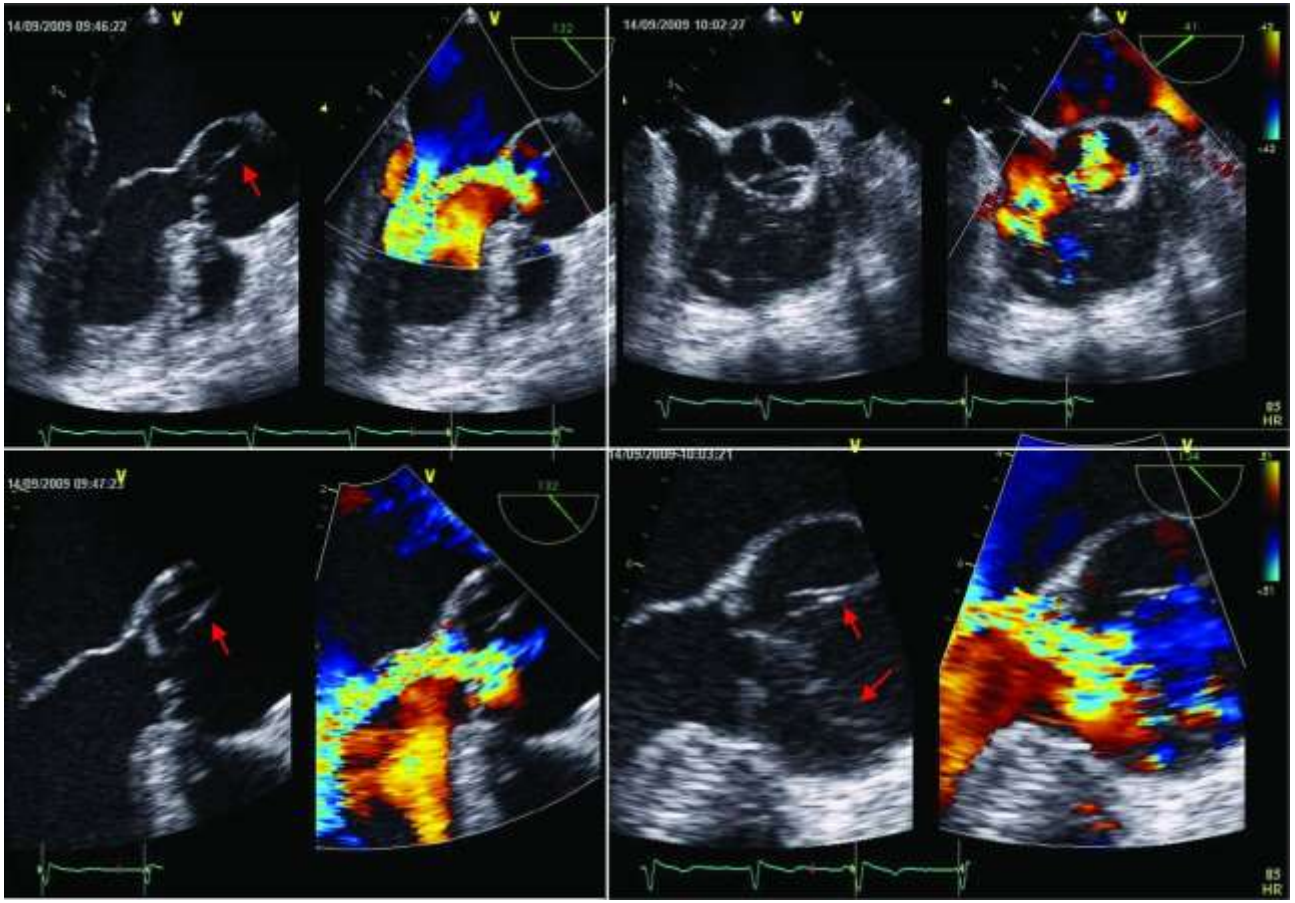

Transesophageal echocardiography showing the chordae tendineae strands (arrows) connecting a mildly dilated aortic root to sigmoid cusps that present tenting and restriction with a severe aortic regurgitation

http://circ.ahajournals.org/content/126/10/e139.figures-only

Aortic valve insufficiency/regurgitation: echocardiography

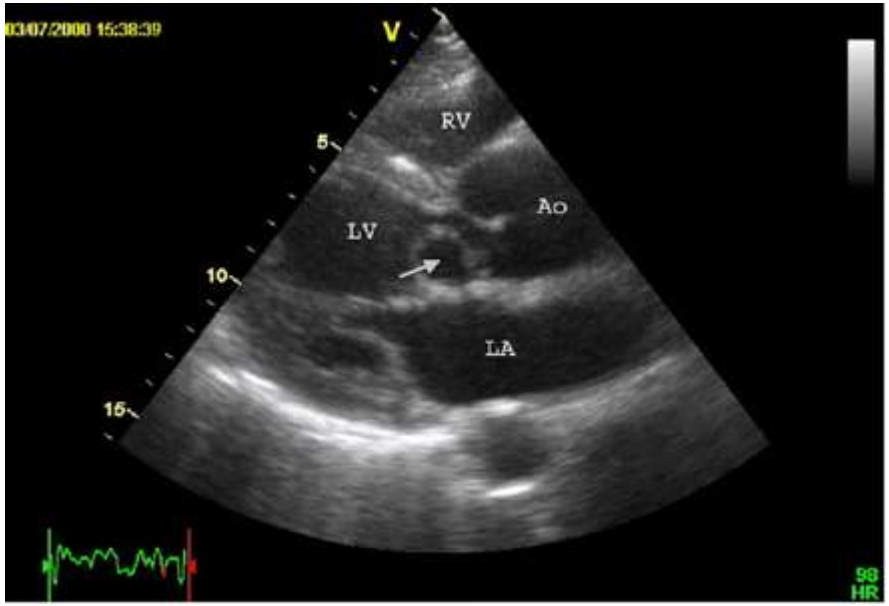

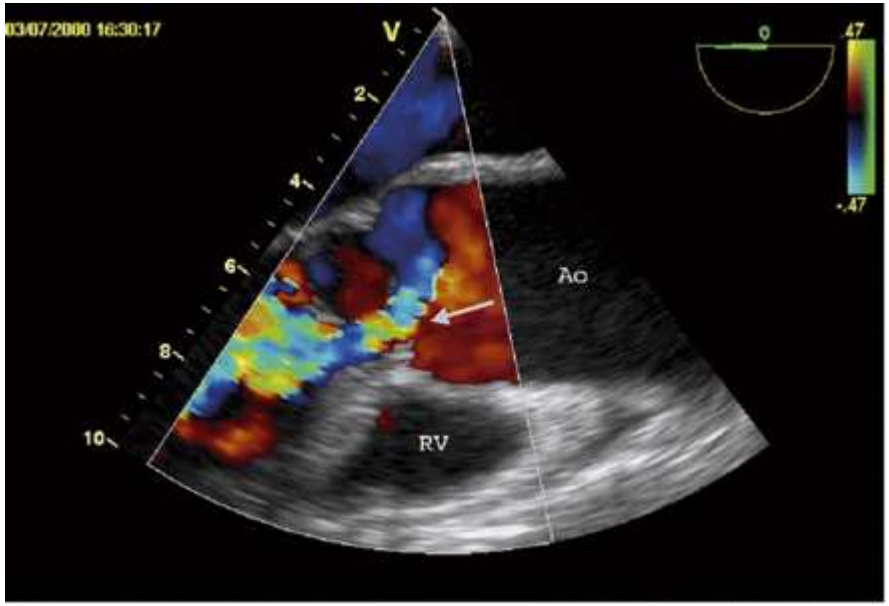

Aortic valve regurgitation due to cusp aneurysm

http://ehjcimaging.oxfordjournals.org/content/5/3/231

Aortic valve insufficiency/regurgitation: echocardiography

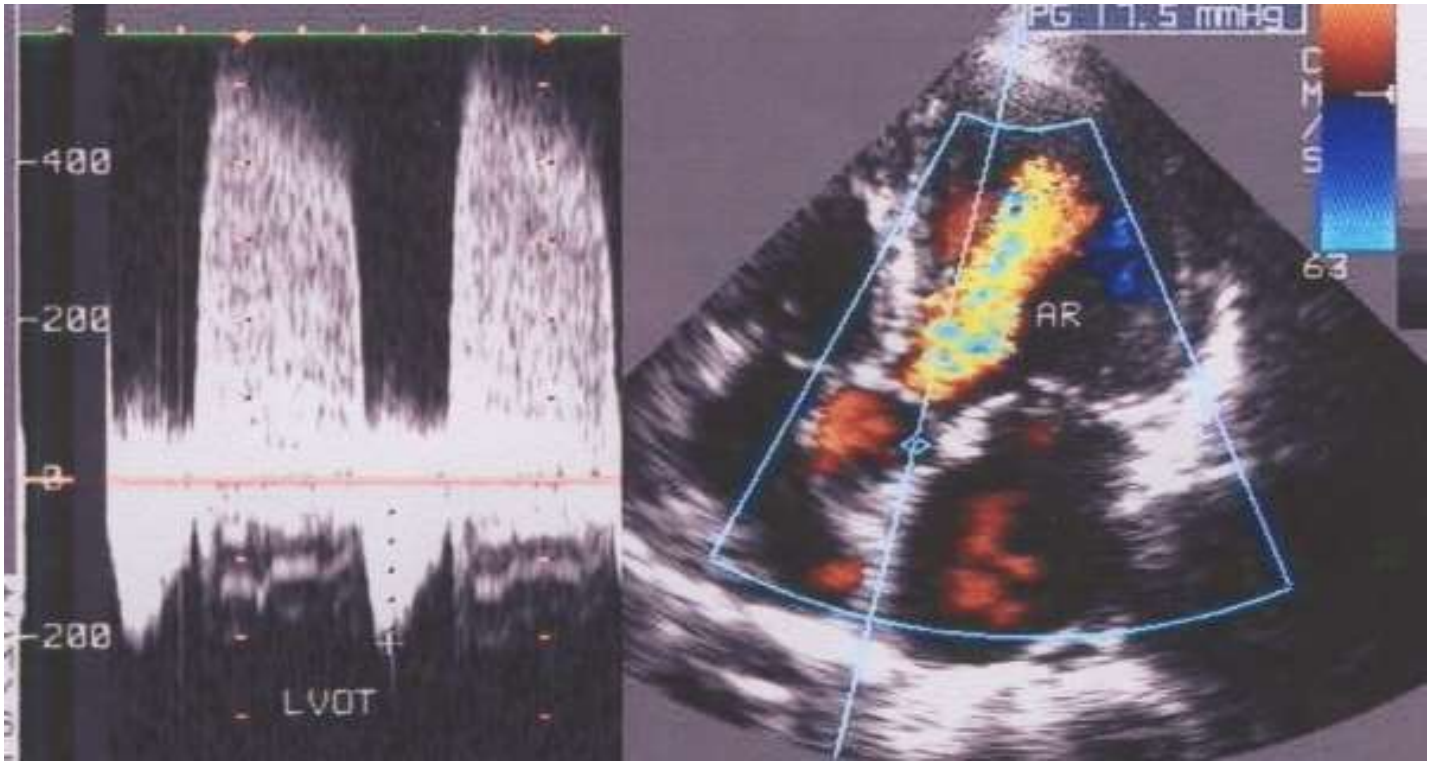

Aortic regurgitation (multicoloured mosaic jet seen in left ventricle)

https://cardiophile.org/aortic-regurgitation/

Aortic valve insufficiency/regurgitation: echocardiography

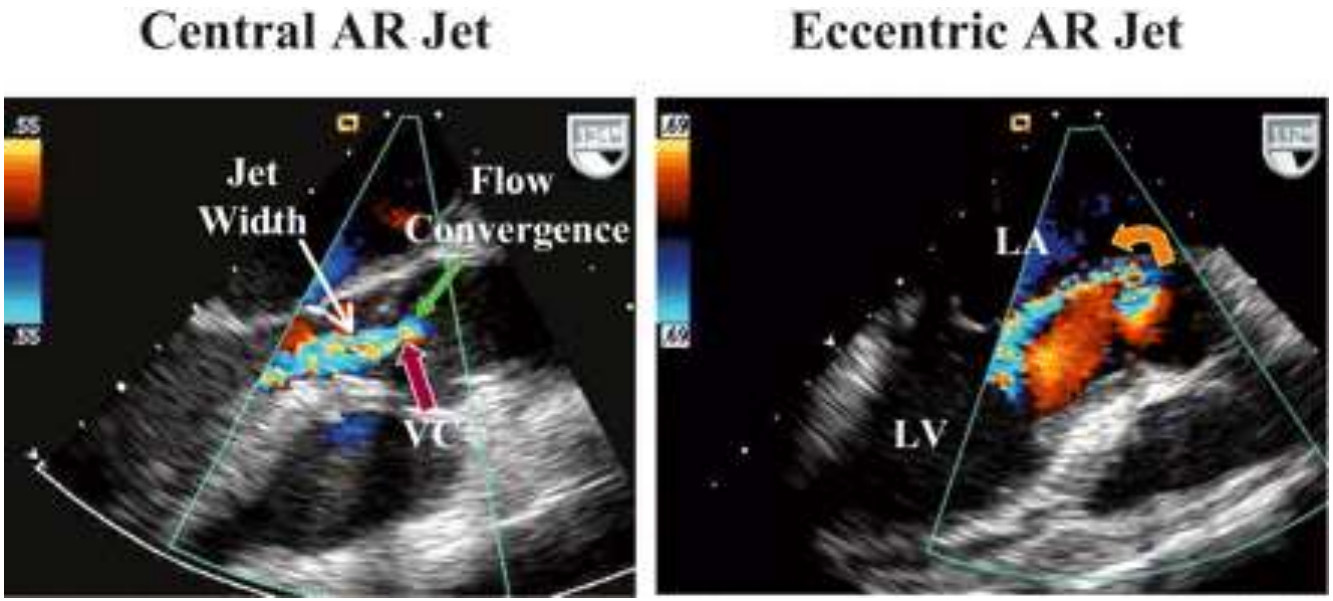

Examples of central and eccentric aortic regurgitation (AR) jets

http://ehjcimaging.oxfordjournals.org/content/4/4/237

Aortic valve insufficiency/regurgitation: cardiac magnetic resonance imaging

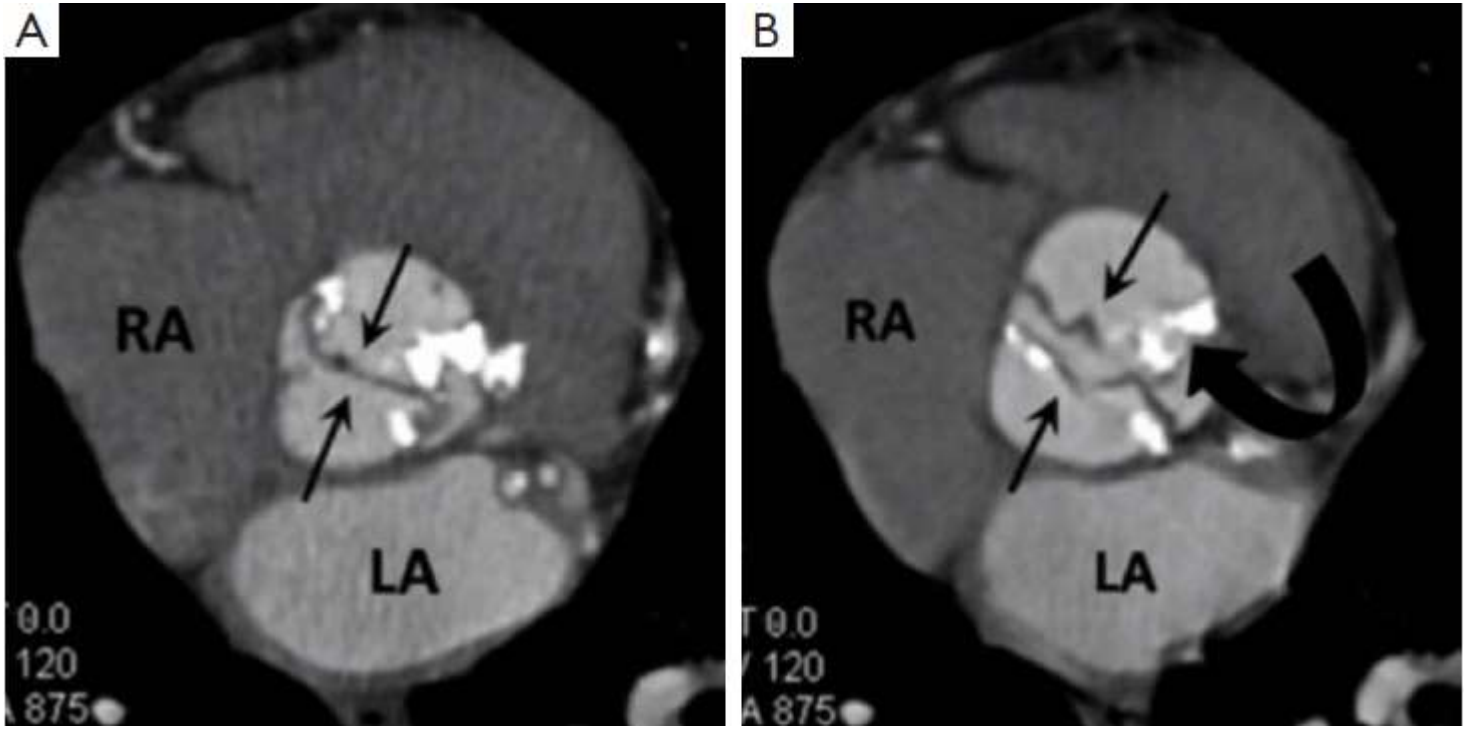

BAV in a 35-year-old man. (A) Cross sectional CT reconstruction through the aortic valve plane in diastole showing an apparent single line of valve fusion (arrows) raising the possibility of a BAV. Note the heavy valvular calcification as a marker of degeneration; (B) cross sectional CT reconstruction through the aortic valve plane in systole showing an elliptical "fishmouth" opening pattern in keeping with a BAV. Calcification can be seen along the line of left and right cusp fusion (curved arrow). BAV, bicuspid aortic valve; LA, left atrium; RA, right atrium.

http://ehjcimaging.oxfordjournals.org/content/4/4/237

Aortic valve insufficiency/regurgitation: cardiac magnetic resonance imaging

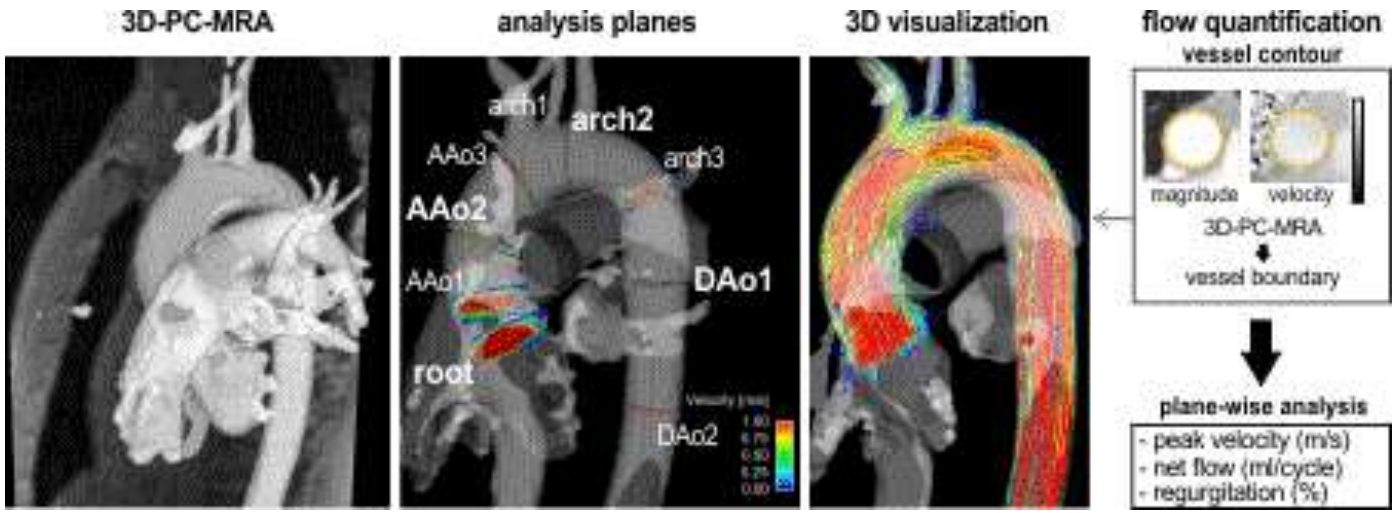

4D flow MRI-based analysis of aortic hemodynamics can be performed with good reproducibility and accuracy using a new faster and semi-automated workflow

http://ehjcimaging.oxfordjournals.org/content/4/4/237

Aortic valve insufficiency/regurgitation: computed tomography

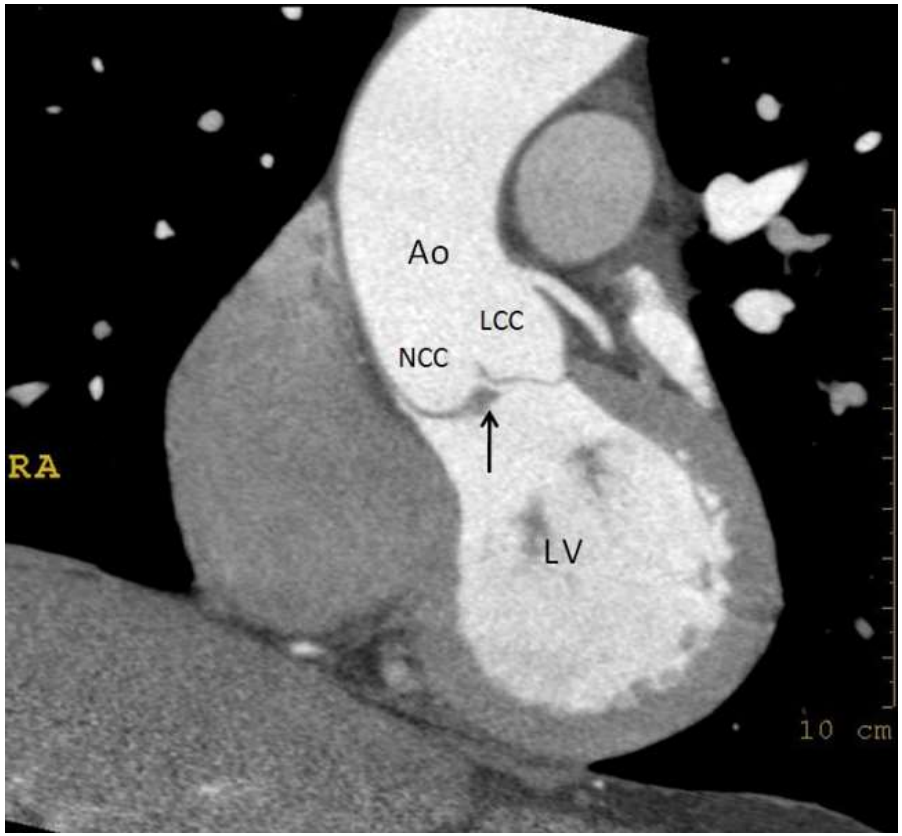

Arrow points to vegetation below non-coronary cusp (NCC). Vegetation measures 10 x 6mm in this view. NB: the two aortic valve cusps fail to meet in this diastolic (75% R-R) image consistent with aortic regurgitation.

http://www.eurorad.org/eurorad/case.php?id=8217

Aortic valve insufficiency/regurgitation: stress tests

Parameters	Baseline	20µg/kg/min	P
HR (bpm)	74.5±12.2	94.2±18.0	<0.001
EF (%)	62.3±7.9	71.5±10.5	<0.001
mG (mmHg)	6.8±2.5	14.7±9.3	<0.001

Bpm - beats per minute, HR - heart rate; EF - ejection fraction, mG - mean aortic gradient; min - minutes.

Dobutamine-stress echocardiography

http://www.scielo.br/scielo.php?pid=S0066-782X2009000700010&script=sci_arttext&tlng=en#t3

Aortic valve insufficiency/regurgitation: chest X-ray

A Case of Severe Aortic Valve Regurgitation Caused by an Ascending Aortic Aneurysm in a Young Patient With Autosomal Dominant Polycystic Kidney Disease and Normal Renal Function

http://openi.nlm.nih.gov/detailedresult.php?img=3291727_kcj-42-136-g001&req=4#

Aortic valve insufficiency/regurgitation: cardiac catheterisation

After adjustment for the systolic blood pressure level, the transvalvular gradient results in an ARI of 16.7 in a patient with moderate paravalvular aortic regurgitation PAR (A) and an ARI of 30.8 in a patient with trivial PAR(B). LVEDP = left-ventricular end-diastolic blood pressure; RR_{dia} = end-diastolic blood pressure in the aorta; RR_{sys} = systolic blood pressure in the aorta.

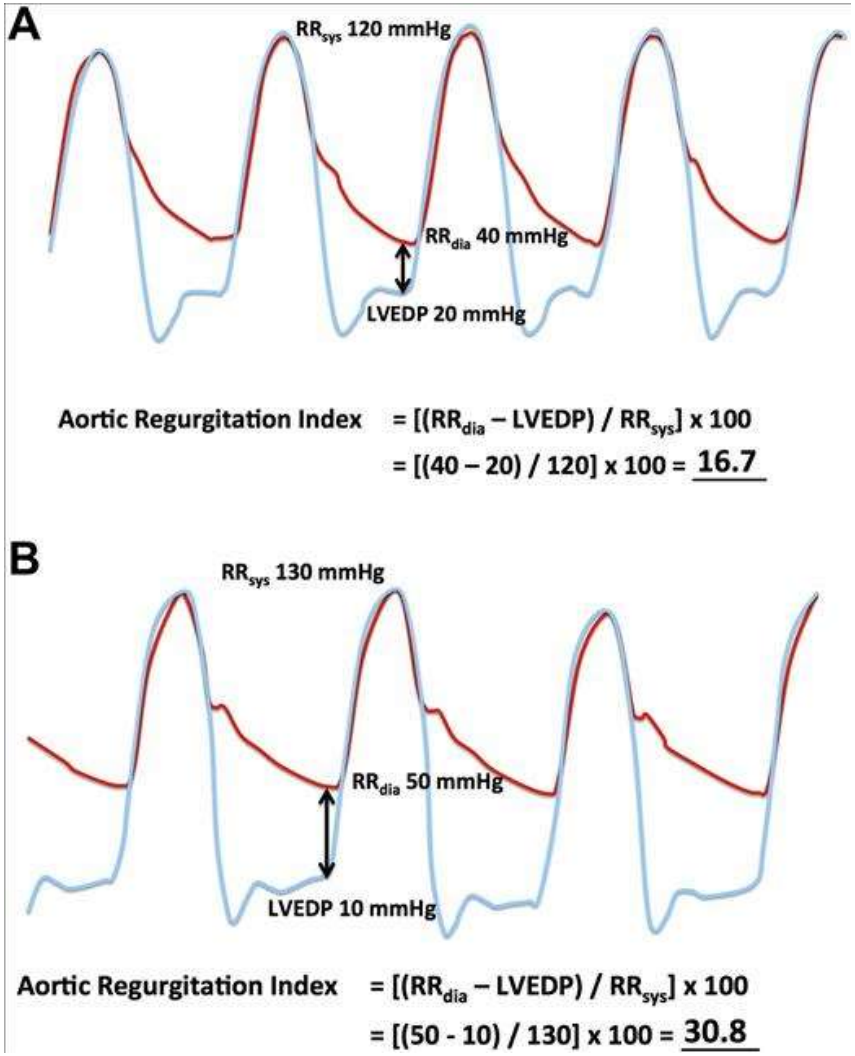

http://openi.nlm.nih.gov/detailedresult.php?img=3291727_kcj-42-136-g001&req=4#

Mitral valve stenosis

Mitral valve stenosis: definition, causes

- Mitral stenosis (MS) is characterized by obstruction to left ventricular inflow at the level of mitral valve due to structural abnormality of the mitral valve apparatus
- The most common cause of mitral stenosis is rheumatic fever
- Other, less common causes include malignant carcinoid disease, systemic lupus erythematosus, rheumatoid arthritis, mucopolysaccharidoses of the Hunter-Hurler phenotype, Fabry disease, Whipple disease, methysergide therapy, nonrheumatic mitral annular calcification, etc.

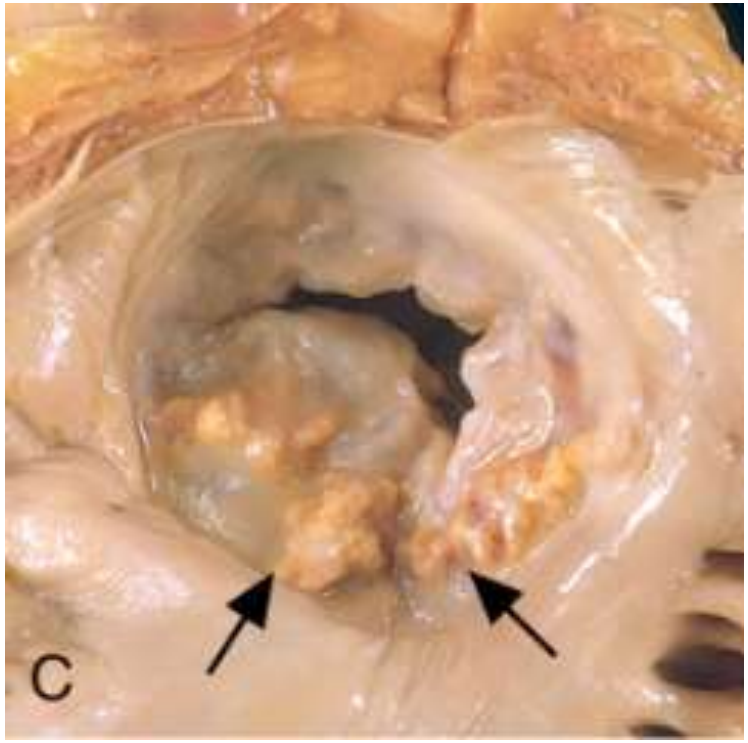

https://classconnection.s3.amazonaws.com/210/flashcards/1428210/png/111343050180267.png http://emedicine.medscape.com/article/155724-overview

Mitral valve stenosis: pathophysiology

- The normal area of the mitral valve orifice is about 4 to 6 cm^2
- Severity of stenosis is characterized echocardiographically as
  - Moderate: Valve area 1.5 to 2.5 cm^2
  - Severe: Valve area < 1.5 cm^2; symptoms are often present
  - Very severe: Valve area < 1.0 cm^2

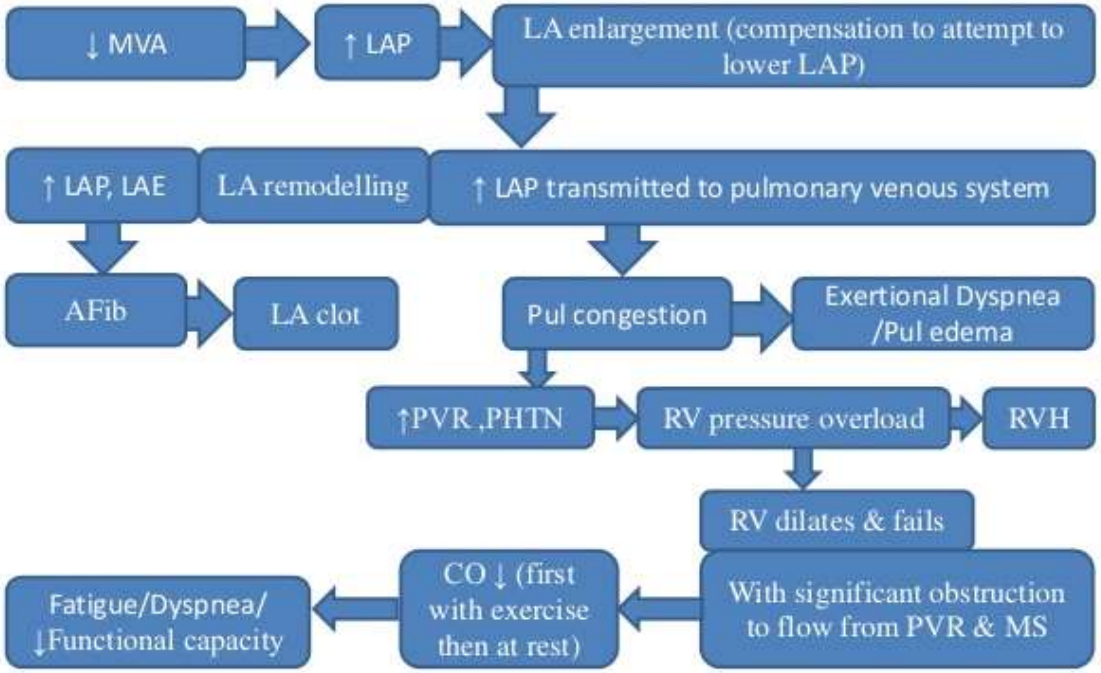

MVA –mitral valve area , LAP – left atrium pressure, LAE – left atrium ejection, PVR - pulmonary vascular resistance, PHTN - pulmonary hypertension, RV – right ventricle, RVH - right ventricular hypertrophy, CO - carbon oxide

https://http://image.slidesharecdn.com/mitralstenosis-141230095422-conversion-gate01/95/mitral-stenosis-8-638.jpg?cb=1419954930 http://emedicine.medscape.com/article/155724-overview

Mitral valve stenosis: heart changes

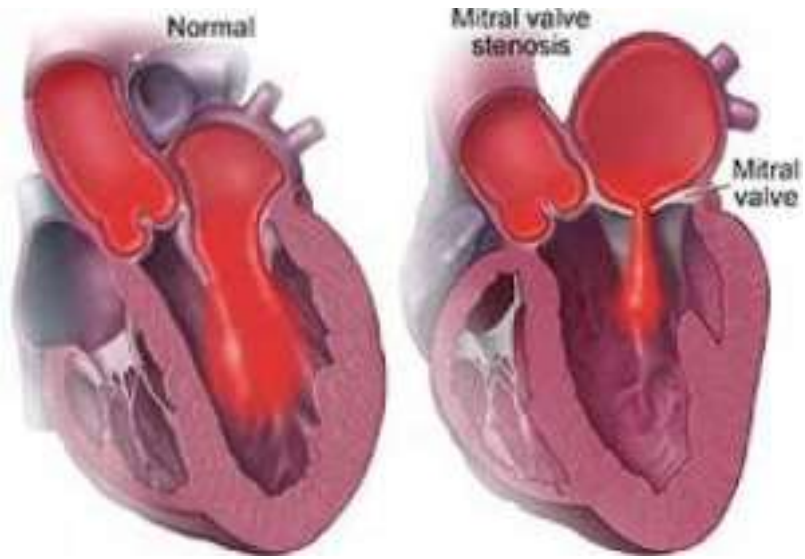

Normal and mitral valve stenosis' hearts: find difference

http://i2.wp.com/www.heartupdate.com/wp-content/uploads/2014/04/mitral-valve-with-stenosis.jpg?resize=300%2C225

Mitral valve stenosis: signs and symptoms

- Irregular pulse of atrial fibrillation
- Rise in jugular venous pressure (with coexistent tricuspid regurgitation)
- Parasternal heave with right ventricular hypertrophy
- Loud first heart sound
- Tapping apex beat (manifestation of a loud first heart sound)
- Opening snap, which disappears as the leaflets become rigid
- Classic late diastolic murmur with presystolic accentuation (the longer the murmur, the more severe the lesion)
- Shortness of breath
- Fatigue or weakness
- Paroxysmal nocturnal dyspnea (cardiac asthma)

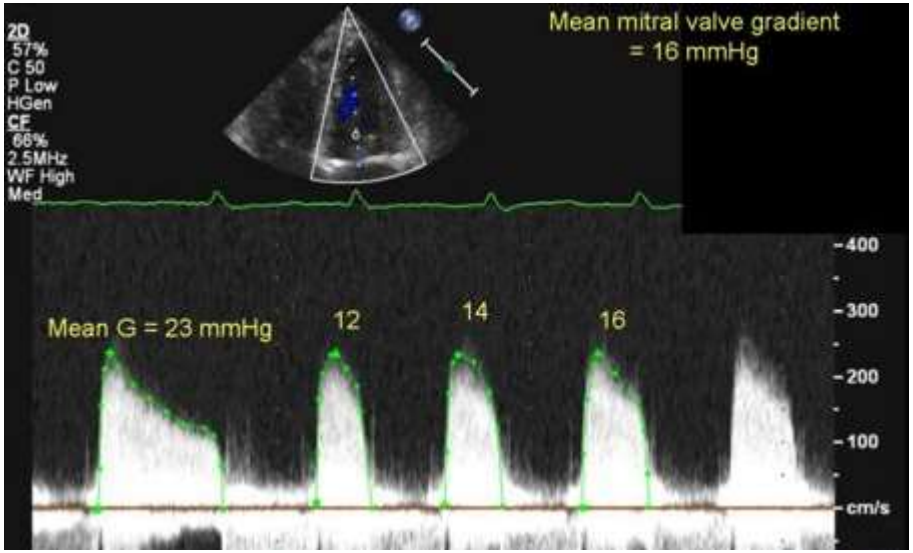

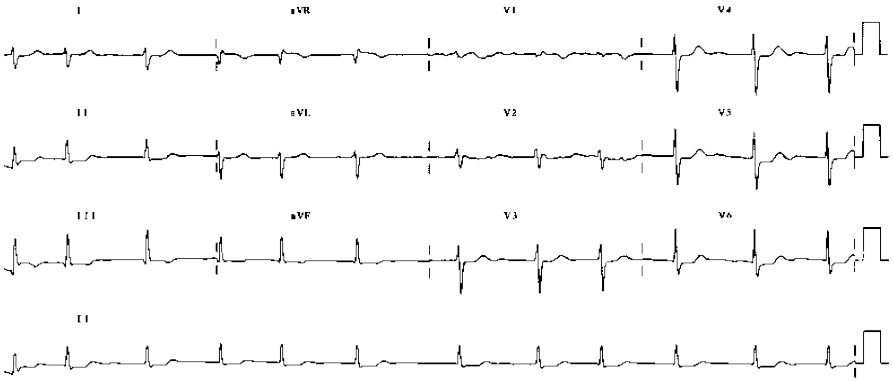

https://web.stanford.edu/group/ccm_echocardio/wikiupload/thumb/3/3d/MS_severe_MV_gradient.jpg/480px-MS_severe_MV_gradient.jpg http://www.ecglibrary.com/ecgs/m_sten3.gif
http://www.ncbi.nlm.nih.gov/books/NBK2220/

Mitral valve stenosis: other less common signs and symptoms

- Hoarseness and vocal cord paralysis
- Trouble swallowing
- Chest pain
- Skin color changes, such as pink to purple shades on the cheeks or a dark blue color on the body from reduced blood flow, usually only in the end stages of the disease
- Coughing up blood (Hemoptysis)
- Thromboembolism in later stages when the left atrial volume is increased (i.e., dilation)
- Ascites and edema and hepatomegaly (if right-side heart failure develops)

https://pbs.twimg.com/media/B6cH3g-IYAI4rt7.png:large http://www.webmd.com/heart-disease/tc/mitral-valve-stenosis-symptoms

Mitral valve stenosis: physical examination

- Jugular venous distension due to rise in jugular venous pressure (with coexistent tricuspid regurgitation)
- Irregular pulse of atrial fibrillation
- Parasternal heave with right ventricular hypertrophy
- Tapping apex beat (manifestation of a loud first heart sound
- Shift of heart dullness upward (left atrium) and to the right (right ventricle)
- The first heart sound is usually loud and may be palpable (tapping apex beat) because of increased force in closing the mitral valve
- If pulmonary hypertension secondary to mitral stenosis is severe, the pulmonic component of the second heart sound will become loud
- A mid-diastolic rumbling murmur with presystolic accentuation will be heard after the opening snap
- Signs of pulmonary hypertension
- Hepatomegaly
- Ascites

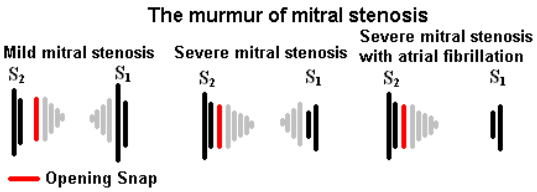

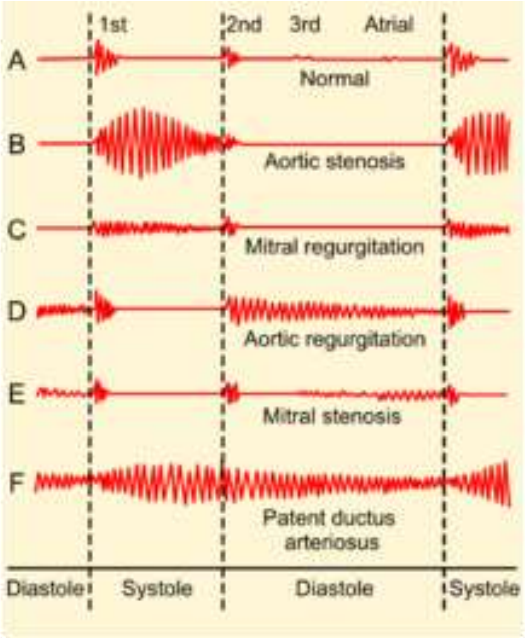

http://http://www.learntheheart.com/assets/1/7/MS.png https://en.wikipedia.org/wiki/Mitral_valve_stenosis

Mitral valve stenosis: selected laboratory studies

- Serum electrolyte levels
- Cardiac biomarkers
- Complete blood count
- Antistreptolysin O (ASLO) antibodies
- Renal and liver function tests
- Acute phase reactions: ESR / CRP / Leukocytosis
- Evidence of antecedent Strep. infection: ASO / Strep antibodies / Strep group A throat culture / Recent scarlet fever / anti-deoxyribonuclease B / anti-hyaluronidase
- Levels of antinuclear antibodies, etc.
- Assess for amyloid deposits in affected tissues

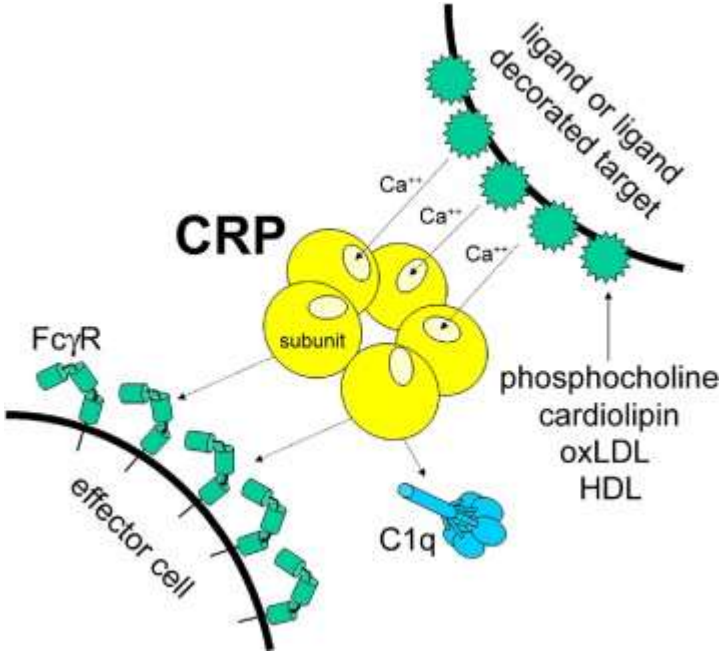

The effects of B-type natriuretic peptide (BNP) on target organs

http://content.onlinejacc.org/data/journals/jac/23098/m_06012_gr1.jpeg https://journals.prous.com/journals/dot/20033910/html/dt390767/images/Mills_f2.gif
http://radiopaedia.org/articles/aortic-valve-stenosis

Mitral valve stenosis: instrumental studies

- Chest X-ray
- Electrocardiogram
- Echocardiogram
- Cardiac MRI
- Cardiac catheterization
- Radionuclide ventriculography

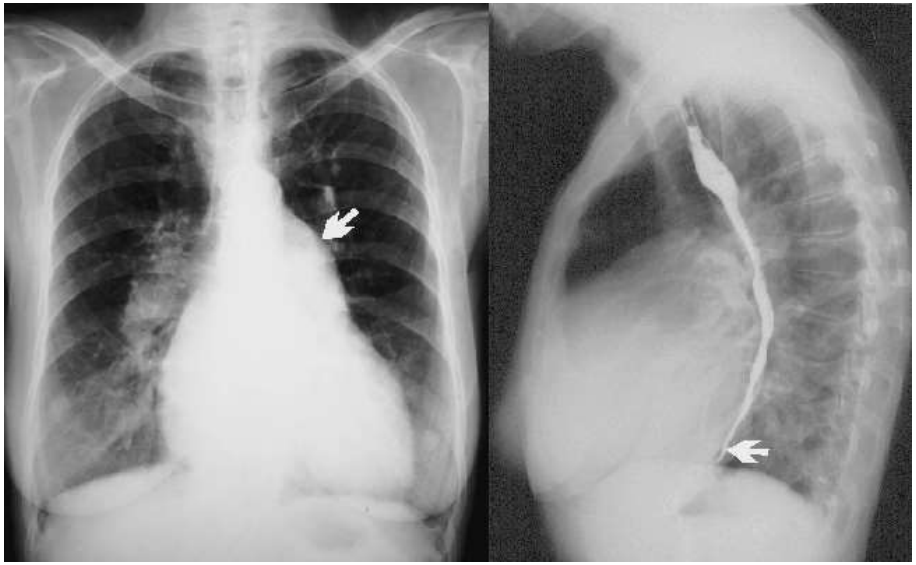

Mitral stenosis I

http://www.hxbenefit.com/wp-content/uploads/2012/09/Mitral-stenosis-Image.gif

Mitral valve stenosis:
M -mode echocardiography

Mitral Stenosis M Mode

https://web.stanford.edu/group/ccm_echocardio/cgi-bin/mediawiki/index.php/Mitral_stenosis_assessment

Mitral valve stenosis:
M and B -mode echocardiography

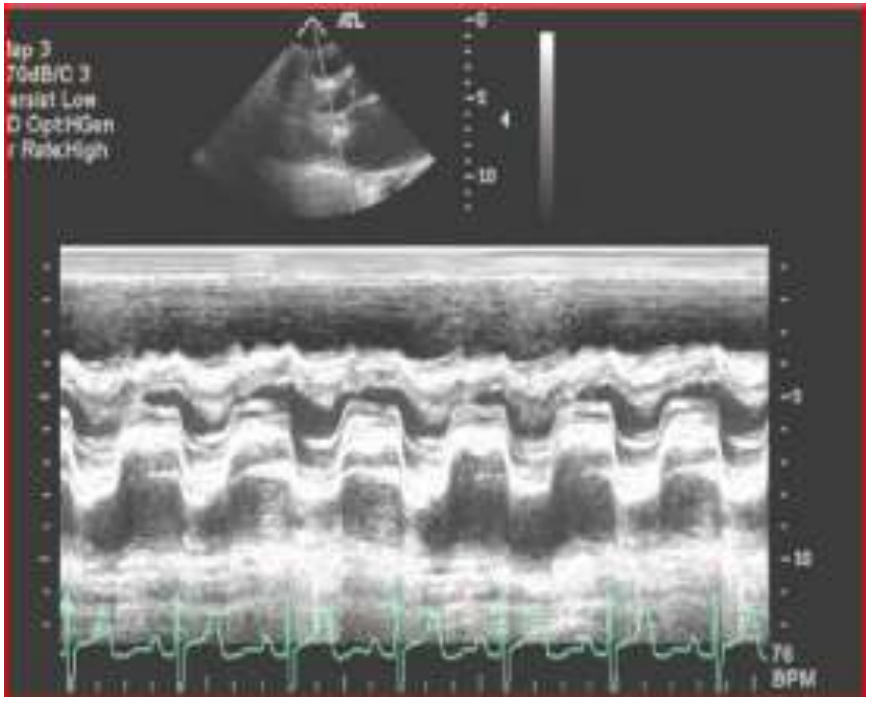

Hyperechogenicity of valvular leaflets and annulus together with calcification of supporting valvular structures

https://web.stanford.edu/group/ccm_echocardio/cgi-bin/mediawiki/index.php/Mitral_stenosis_assessment

Mitral valve stenosis:
B-mode echocardiography

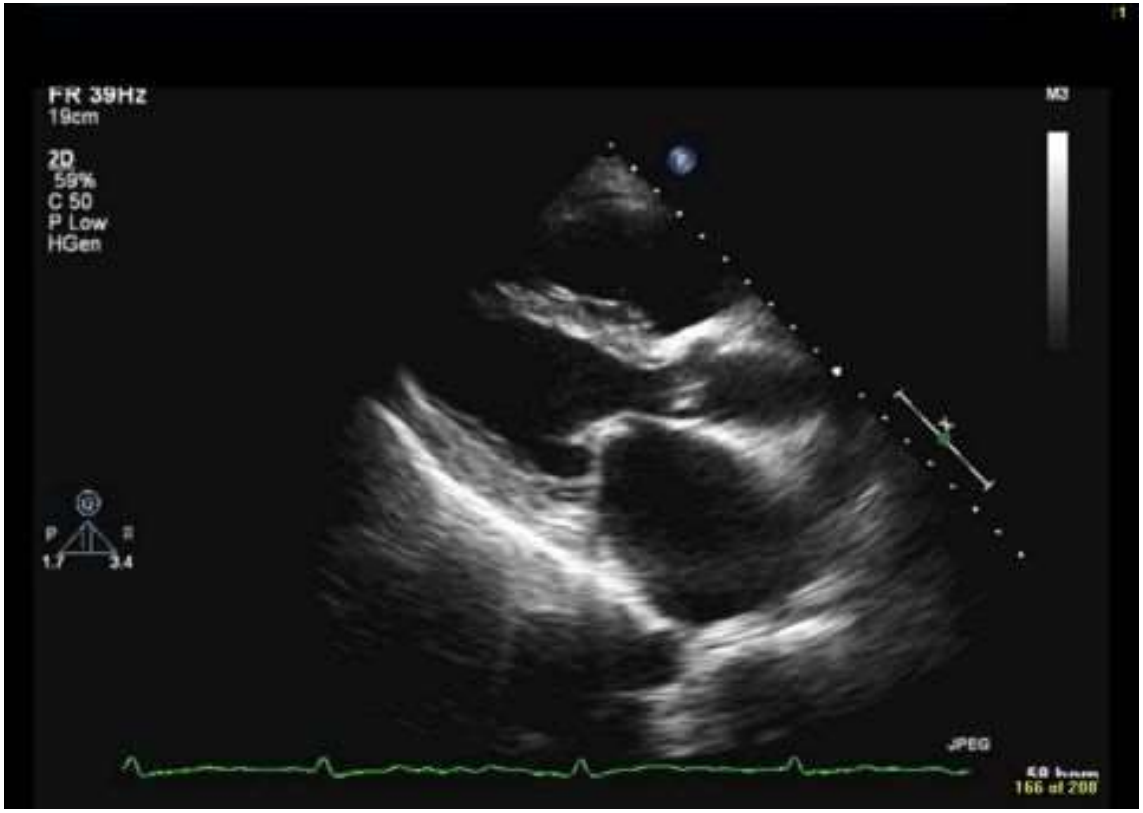

There is thickening and fusion of the mitral valve commissural edges and chordae, which will result in a"doming" appearance of the mitral valve opening

https://web.stanford.edu/group/ccm_echocardio/cgi-bin/mediawiki/index.php/Mitral_stenosis_assessment

Mitral valve stenosis:
B-mode echocardiography

The anterior leaflet has been described as opening in a "hockey stick" appearance in parasternal long axis view

https://web.stanford.edu/group/ccm_echocardio/cgi-bin/mediawiki/index.php/Mitral_stenosis_assessment

Mitral valve stenosis: B-mode echocardiography

(A) Leaflet thickening at the edges is shown in a parasternal long axis transthoracic view.

(B) The immobility of the posterior leaflet and the doming of the anterior leaflet as typical morphological characteristics of rheumatic mitral valve disease are shown in a 3-dimensional transesophageal image. The 3-dimensional transesophageal images (left atrial aspect

[C]) and (left ventricular aspect **[D]**) show the fusion of both commissures **(red arrows)**. AML = anterior mitral leaflet; PML = posterior mitral leaflet.

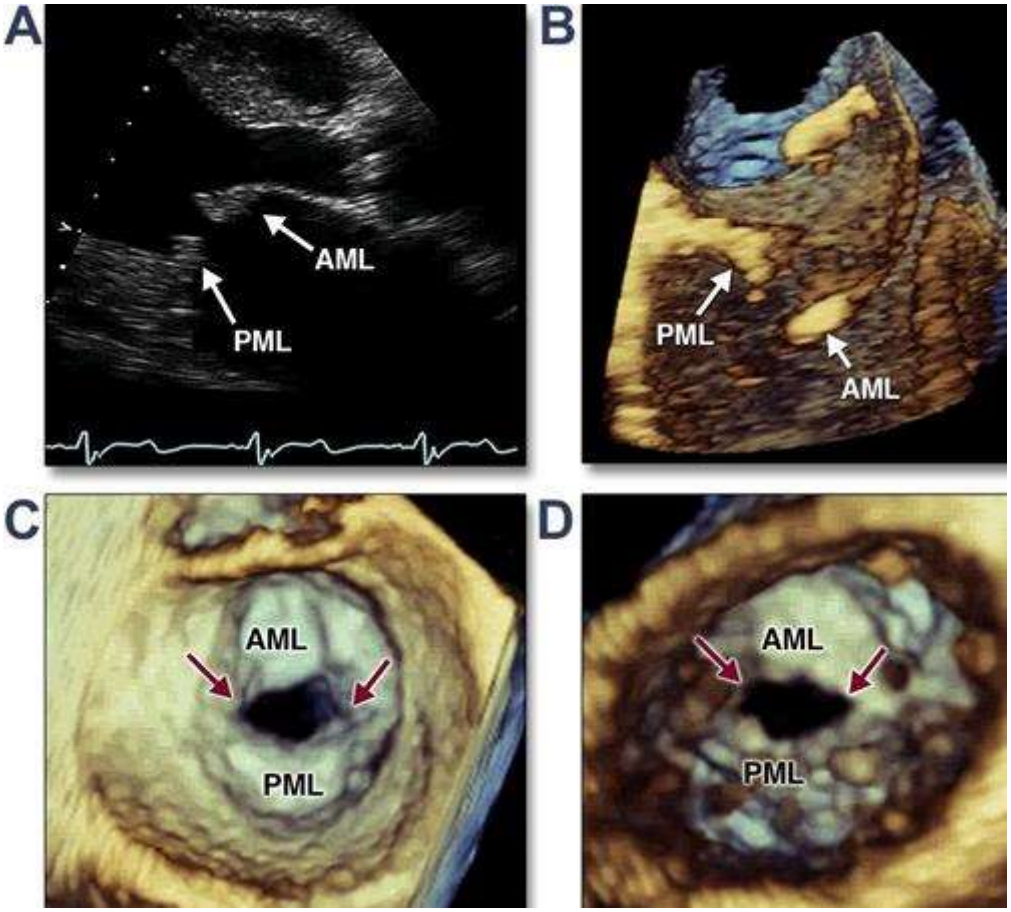

https://web.stanford.edu/group/ccm_echocardio/cgi-bin/mediawiki/index.php/Mitral_stenosis_assessment

Mitral valve stenosis: Doppler echocardiography

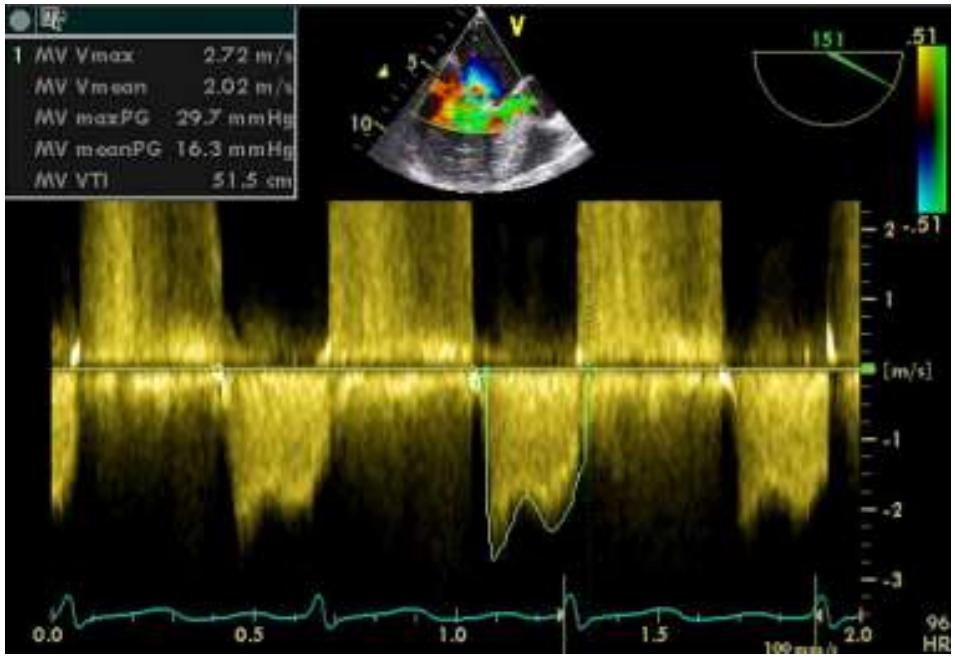

Transesophageal echocardiogram with continuous wav

http://img.medscapestatic.com/pi/meds/ckb/12/34912tn.jpg

Mitral valve stenosis: computed tomography

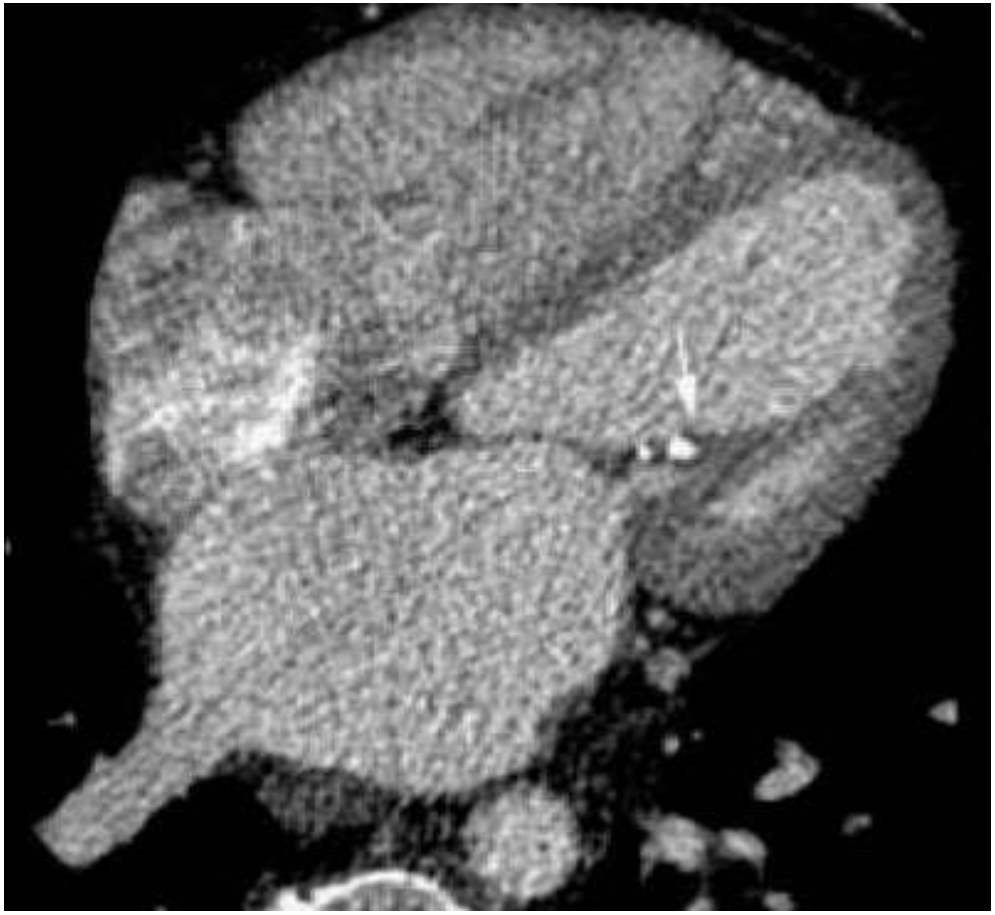

http://img.medscape.com/fullsize/migrated/494/431/ar494431.fig2a.jpg

Mitral valve stenosis: cardiac catheterization

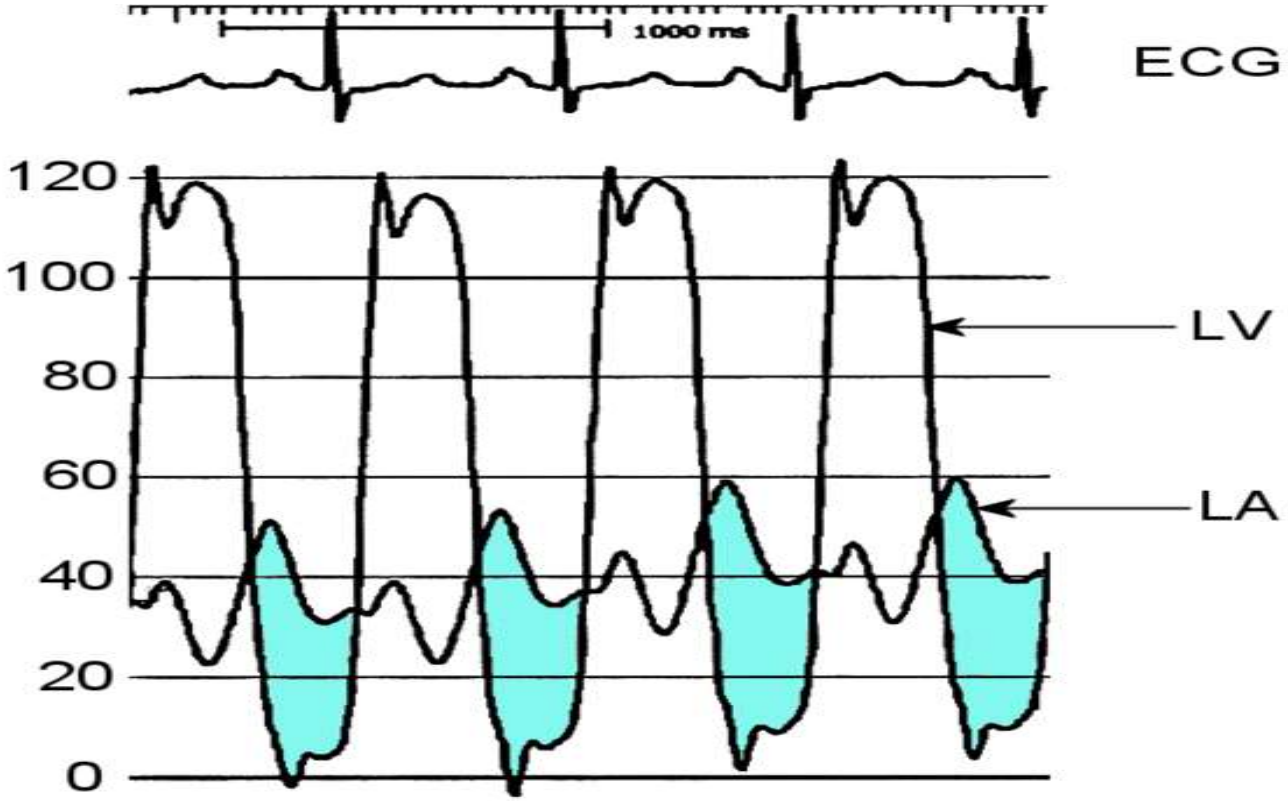

Shown is an image depicting intracardiac pressure measurements in an individual with severe mitral stenosis. Pressure tracings in the left atrium (LA) and the left ventricle (LV) in an individual with severe mitral stenosis. Blue areas represent the diastolic pressure gradient due to the stenotic valve.

http://static.wikidoc.org/7/79/Mitral_stenosis_pressure_tracings.png

Mitral valve insufficiency/regurgitation

Mitral valve insufficiency/regurgitation: definition, types, causes

- Mitral insufficiency/regurgitation (MI) or mitral incompetence is a disorder of the heart in which the mitral valve does not close properly when the heart pumps out blood; it is the abnormal leaking of blood backwards from the left ventricle, through the mitral valve, into the left atrium, when the left ventricle contracts, i.e. there is regurgitation of blood back into the left atrium
- MI is the most common form of valvular heart disease
- Types: acute, chronic
- The most common cause of MI is mitral valve prolapse (MVP)
- Ischemic heart disease causes MI by the combination of ischemic dysfunction of the papillary muscles, and the dilatation of the left ventricle
- Rheumatic fever, Marfan's syndrome and Ehlers Danlos Syndrome are other typical causes
- Secondary mitral insufficiency is due to the dilatation of the left ventricle that causes stretching of the mitral valve annulus and displacement of the papillary muscles (dilated cardiomyopathy, etc.)

https://en.wikipedia.org/wiki/Mitral_insufficiency

Mitral valve insufficiency/regurgitation: pathophysiology

- Eccentric hypertrophy
  - Increased preload
  - Increased afterload
  - Increased total stroke volume AND forward stroke volume AND LVESV returns to normal
- Increased LA size
  - Increased LA compliance
  - Larger volume at lower pressure

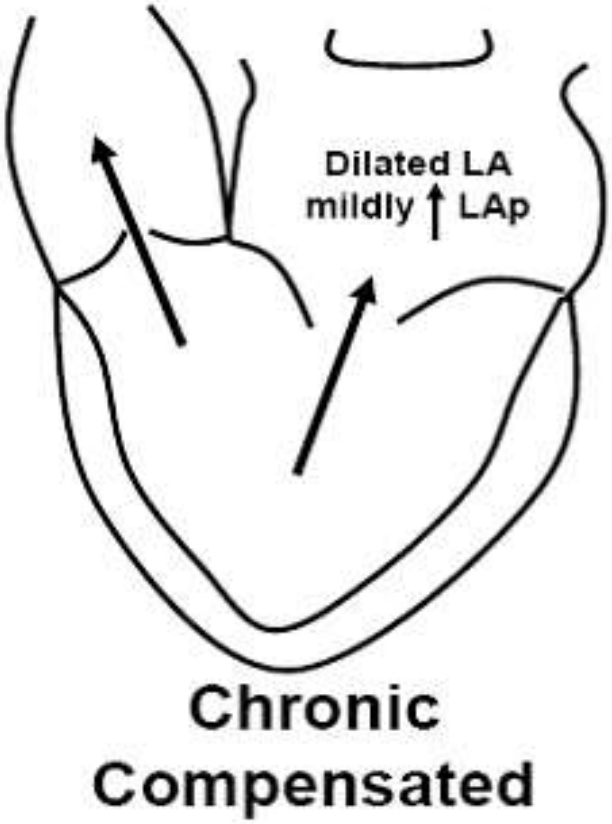

http://intranet.tdmu.edu.ua/data/kafedra/internal/surgery2/classes_stud/en/med/lik/ptn/Surgery/5/Topic%2005%20Acquired%20heart%20defects.files/image025.gif

Mitral valve insufficiency/regurgitation: heart changes

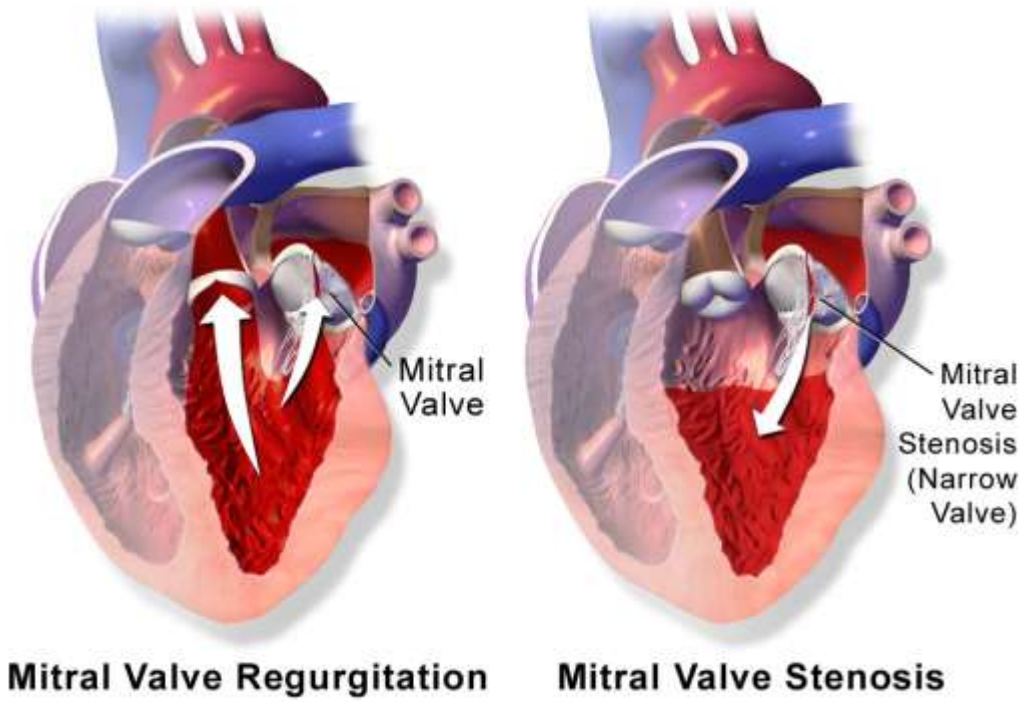

Mitral valve insufficiency/regurgitation' and stenosis hearts: find difference

https://upload.wikimedia.org/wikipedia/commons/4/4e/Blausen_0645_MitralValve_RegurgitationvsStenosis.png

Mitral valve insufficiency/regurgitation: main hemodynamics disturbances

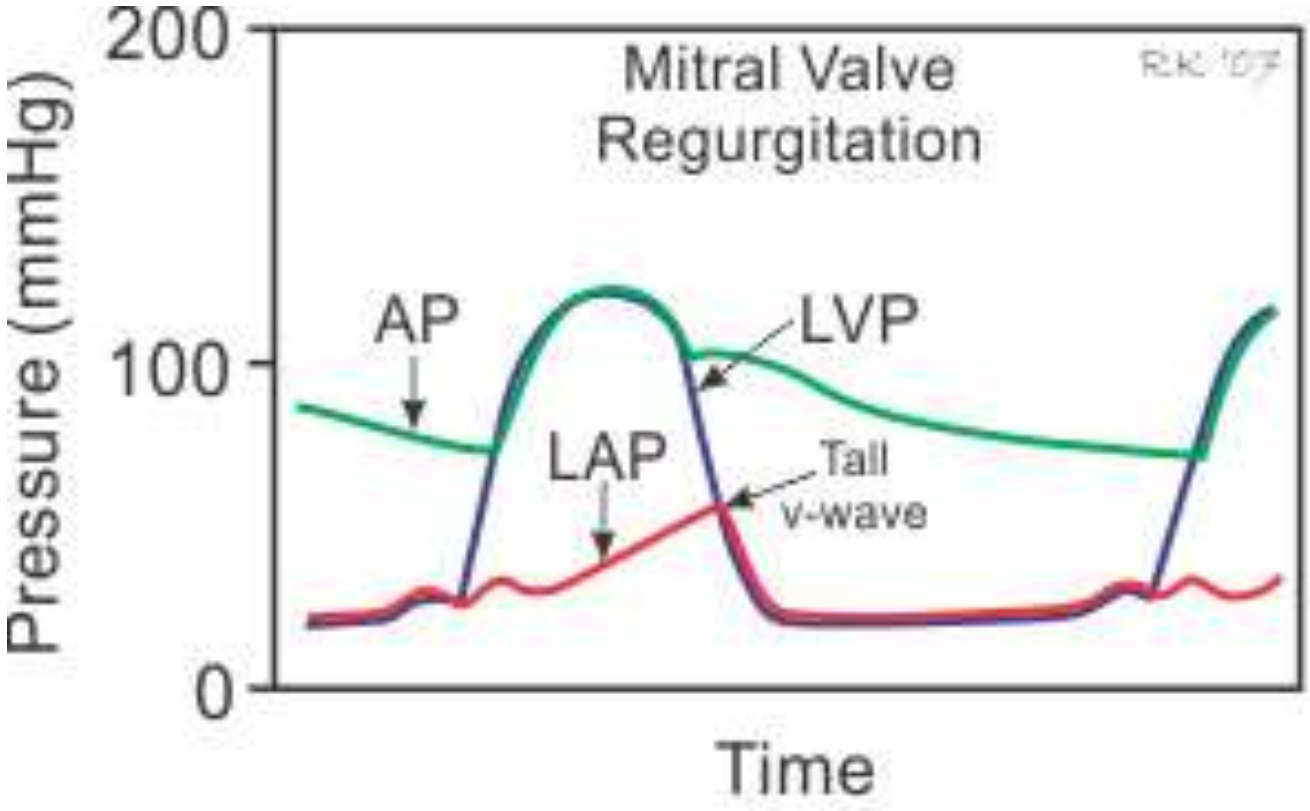

The changes in aortic pressure (AP), left ventricular pressure (LVP) and left atrial pressure (LAP)

http://www.cvphysiology.com/Heart%20Disease/HD005%20mitral%20regurgitation.gif

Mitral valve insufficiency/regurgitation: symptoms

- Symptoms appear as the left ventricle expands to accommodate the larger amount of blood (volume overload) flowing into the chamber
- The larger the left ventricle, the more advanced is the MR
- Symptoms include:
  - Shortness of breath with exertion, which may later develop into shortness of breath at rest and at night.
  - Fatigue and weakness
  - Edema (fluid buildup in the legs and feet, orthopnea, paroxysmal nocturnal dyspnea)
  - Heart palpitations (atrial fibrillation, which can lead to blood clots forming in the atrium)

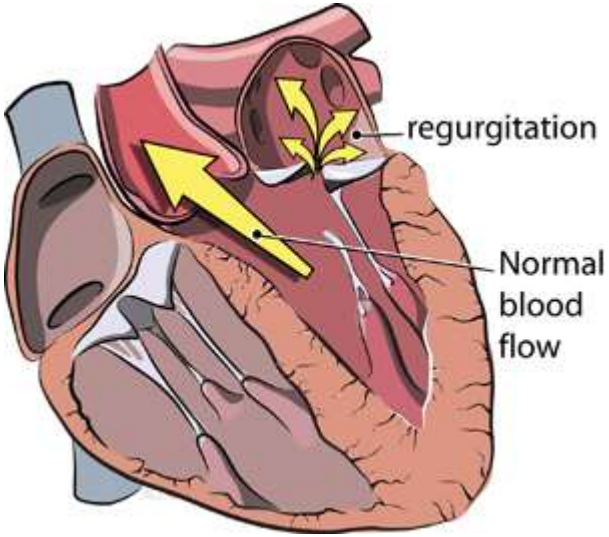

http://aortic-valve-replacement.com/gallery/132510.jpg http://www.webmd.com/heart-disease/tc/mitral-valve-regurgitation-symptoms

Mitral valve insufficiency/regurgitation: physical examination

- Asthenic body habitus
- Low body weight or body mass index (BMI)
- Straight-back syndrome
- Scoliosis or kyphosis
- Pectus excavatum
- Hypermobility of the joints (e.g., Marfan syndrome)
- The 1st heart sound (S_1) may be soft (or occasionally loud); a 3rd heart sound (S_3) at the apex reflects a dilated LV and important MR; an S_3 that accompanies mitral regurgitation suggests a dilated left ventricle and progression to heart failure
- The cardinal sign of MR is a holosystolic (pansystolic) murmur, heard best at the apex with the diaphragm of the stethoscope when the patient is in the left lateral decubitus position

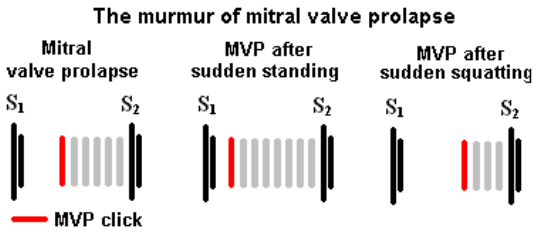

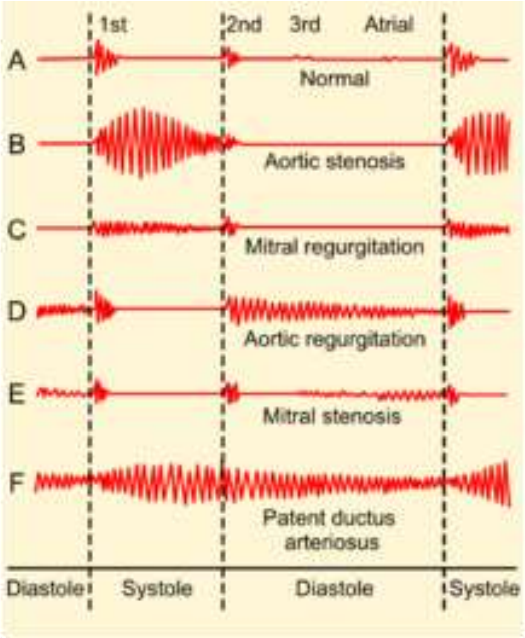

http://emedicine.medscape.com/article/155494-clinical#b4 https://upload.wikimedia.org/ http://www.learntheheart.com/assets/1/7/MVP.png

Mitral valve insufficiency/regurgitation: diagnostic tests

- Echocardiography
- Quantification of mitral insufficiency
- Cardiac magnetic resonance imaging
- Electrocardiography (ECG)
- Chest X-ray
- Cardiac catheterization

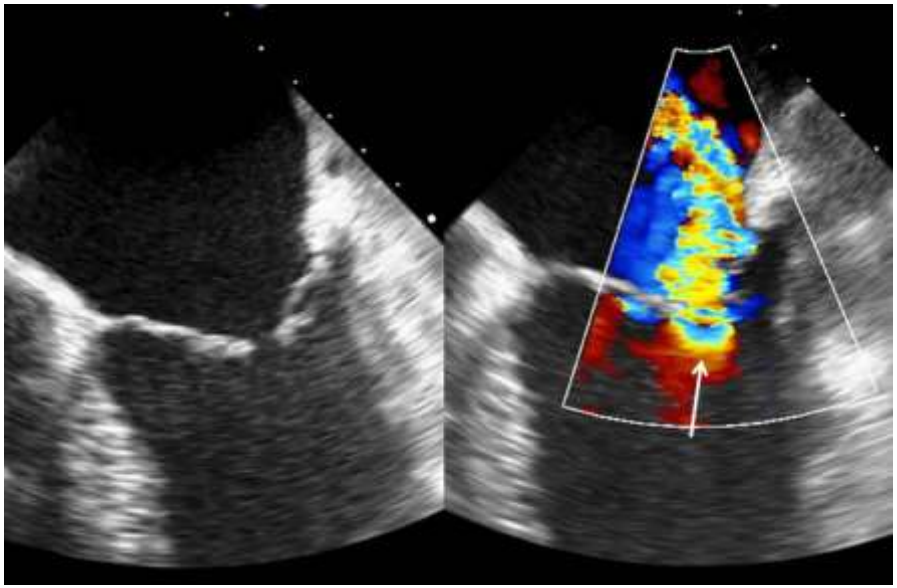

Transthoracic echocardiogram of secondary (functional) mitral regurgitation. With secondary mitral regurgitation, left ventricular dilation results in functional mitral regurgitation. The image shows failure of central coaptation of tethered mitral valve leaflets due to left ventricular dilation (left panel) with a color Doppler display (highlighted) of the resultant central jet of secondary mitral regurgitation (right panel).

https://upload.wikimedia.org/wikipedia/commons/d/da/Bicuspid_aortic_valve,_severe_aortic_regurgitation_E00859_(CardioNetworks_ECHOpedia).jpg
http://www.clevelandclinicmeded.com/medicalpubs/diseasemanagement/cardiology/mitral-valve-disease/#figure3 https://en.wikipedia.org/wiki/Aortic_insufficiency

Mitral valve insufficiency/regurgitation: echocardiography

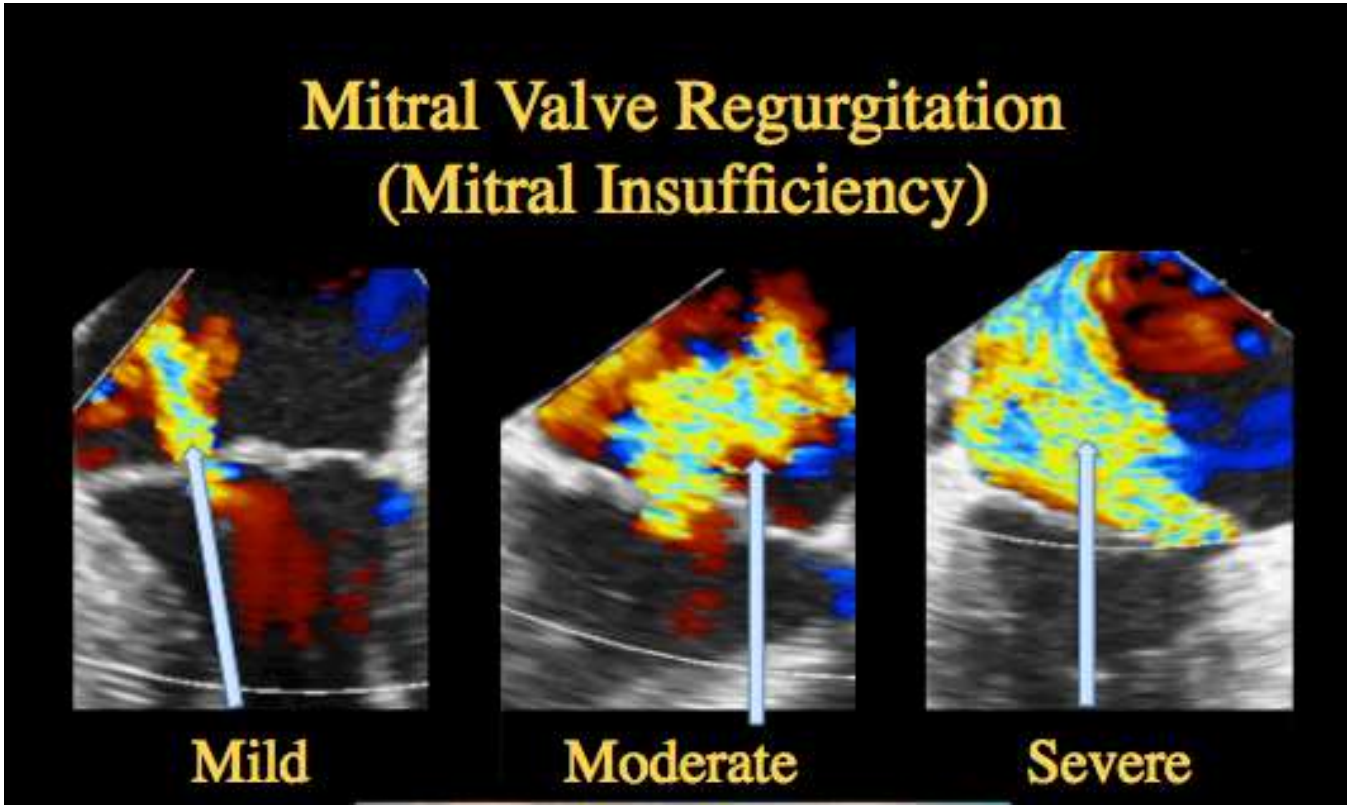

http://myheart.net/wp-content/uploads/2014/11/mitral-valve-regurgitation-mitral-insufficiency-mild-moderate-severe11.png

Mitral valve insufficiency/regurgitation: quantification of mitral insufficiency

Degree of mitral regurgitation	Regurgitant fraction	Regurgitant Orifice area
Mild	< 20 percent	
Moderate	20 - 40 percent	
Moderate to severe	40 - 60 percent	
Severe	> 60 percent	> 0.4 cm^2

The degree of severity of MI can be quantified by the regurgitant fraction, which is the percentage of the left ventricular stroke volume that regurgitates into the left atrium

https://en.wikipedia.org/wiki/Mitral_insufficiency

Mitral valve insufficiency/regurgitation: echocardiography

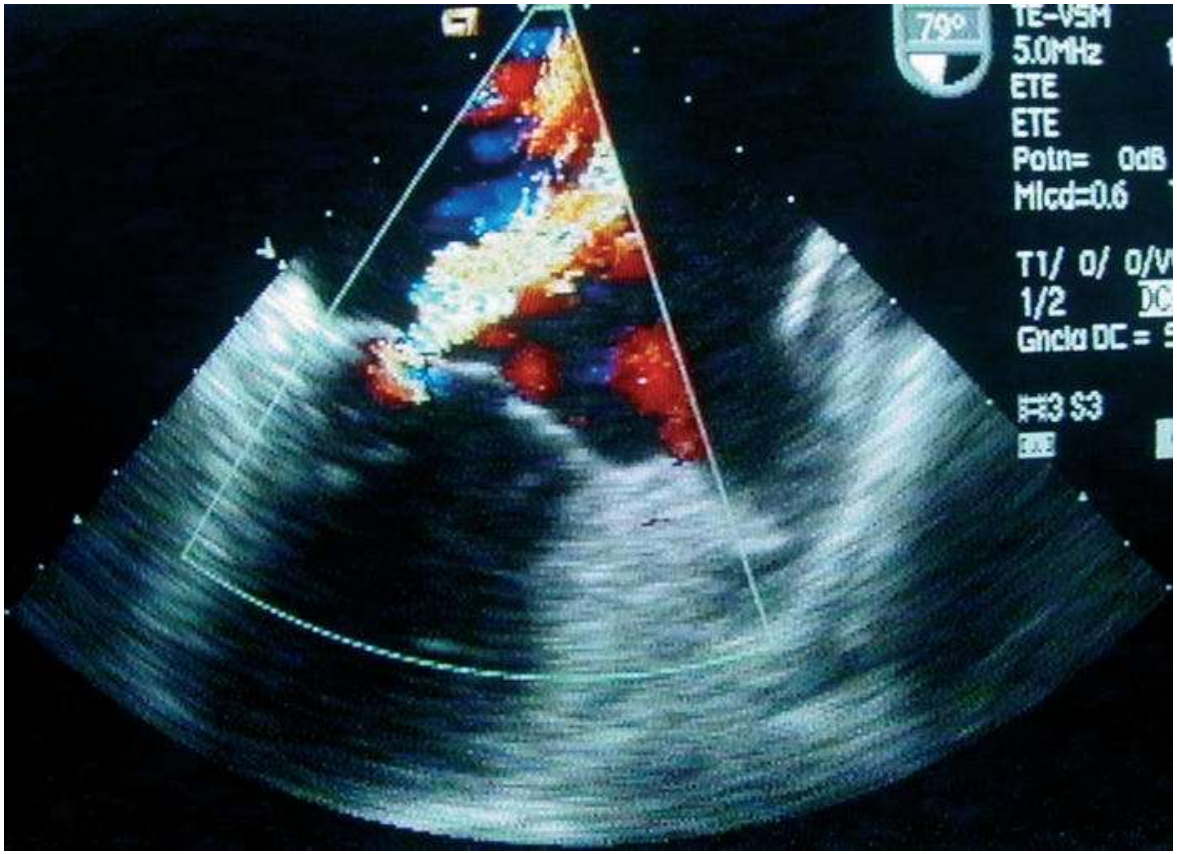

Transesophageal echocardiogram: apical 4-chamber projection where small vegetations can be observed on both mitral valves (arrows). Severe Mitral Regurgitation.

http://circ.ahajournals.org/content/126/10/e139.figures-only

Mitral valve insufficiency/regurgitation: echocardiography

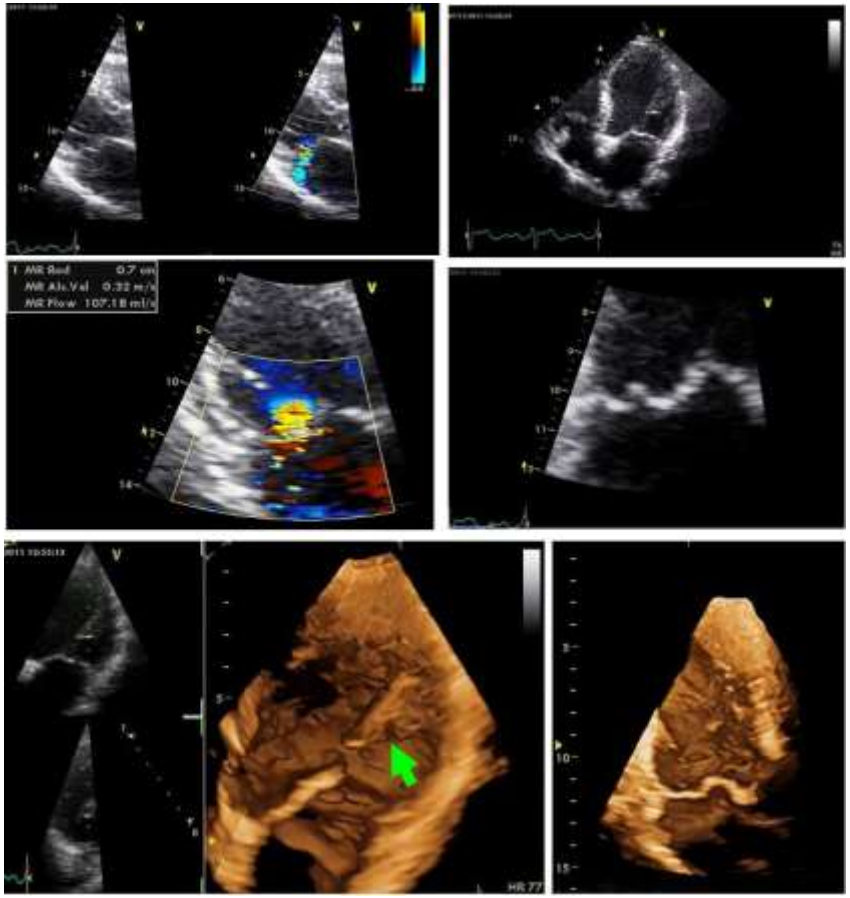

Ischemic mitral regurgitation due to acute elongation of papillary muscle, appearing as mitral valve prolapse

http://ehjcimaging.oxfordjournals.org/content/5/3/231

Mitral valve insufficiency/regurgitation: echocardiography

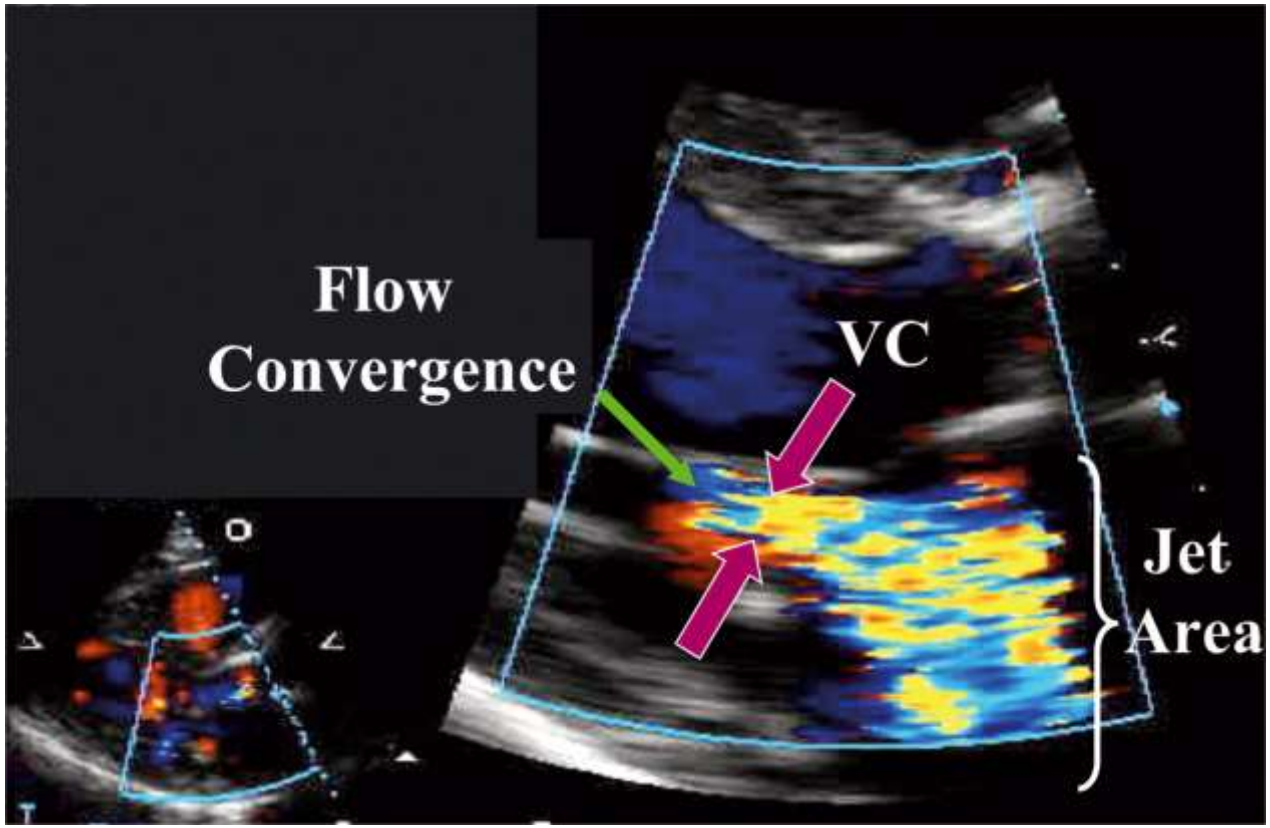

Color flow recording of a mitral regurgitation jet obtained from a zoomed view in the parasternal long axis depicting the three components of the regurgitant jet: flow convergence, vena contracta (VC), and jet area in the left atrium. Measurement of the vena contracta is shown between the red arrows. Vena contracta is defined as the narrowest central flow region of a jet that occurs at, or just downstream to, the orifice of a regurgitant valve.

http://d2crugzdgfmp7d.cloudfront.net/content/ejechocard/4/4/237/F1.large.jpg?width=800&height=600&carousel=1

Mitral valve insufficiency/regurgitation: echocardiography

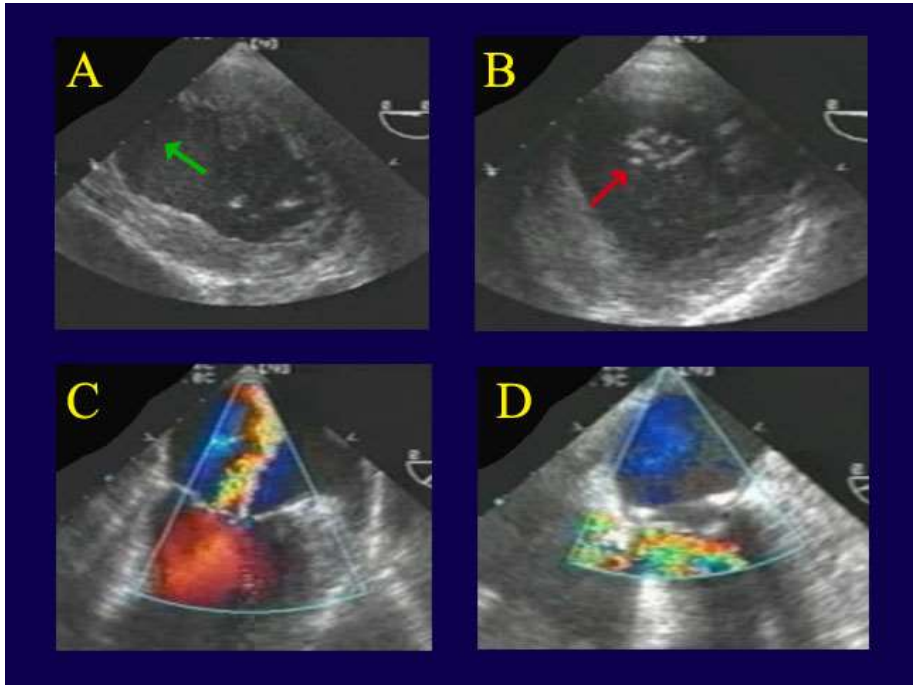

Transesophageal echocardiogram in a patient undergoing valve repair for ischemic mitral regurgitation. Panel A is a short axis view of the left ventricle, showing an expanded posterior-lateral wall infarct (green arrow). Panel B shows a gap in mitral coaptation at the posterior commissure during systole (red arrow), producing a central regurgitant jet (Panel C), but the leaflets are at the annular plane. This is the most common echocardiographic appearance of ischemic mitral regurgitation. In panel D, the valve is entirely competent after full ring annuloplasty alone.

http://www.heartlungandvessels.org/index.php?pag=rivista_articles&id_numero=2&id_articolo=221

Mitral valve insufficiency/regurgitation: echocardiography combine with cardiac magnetic resonance imaging

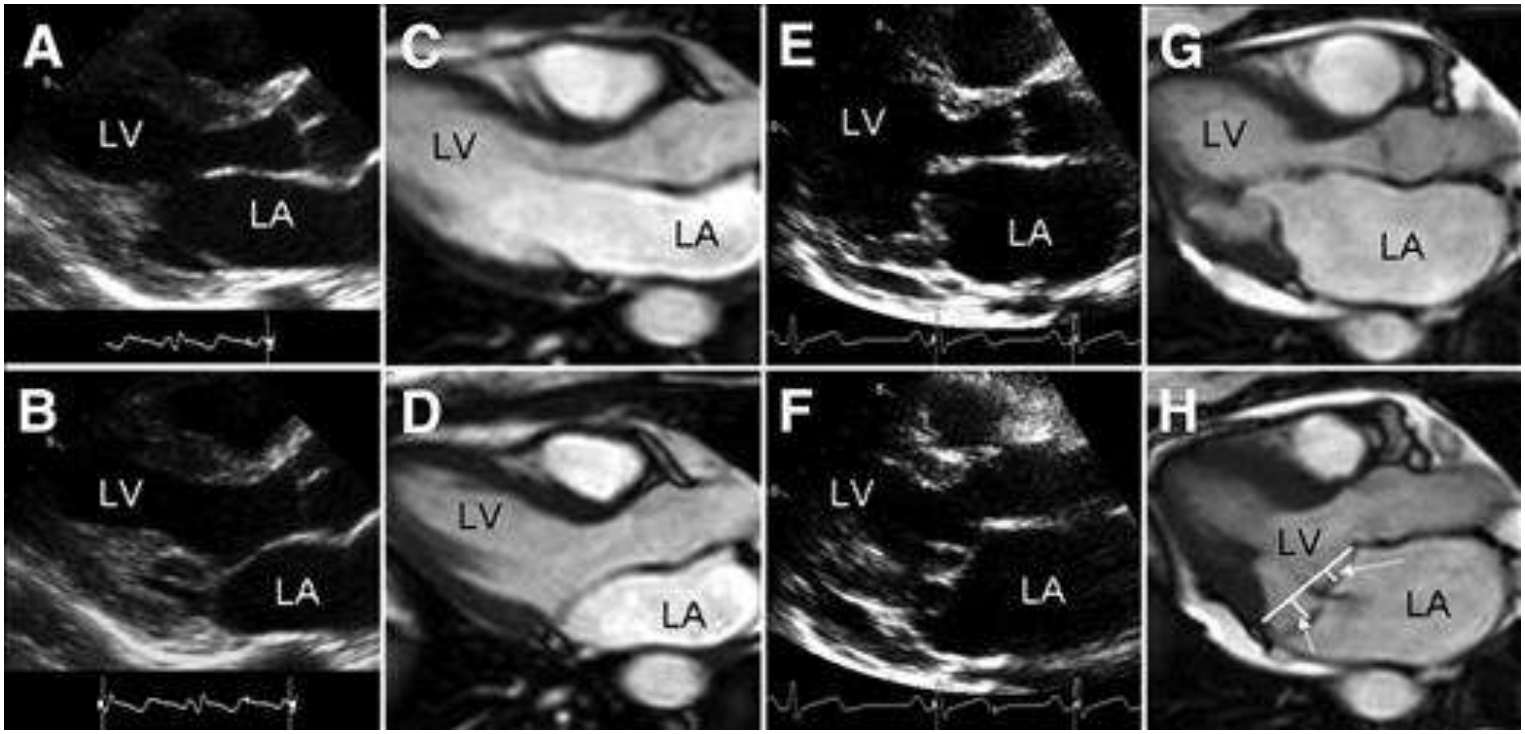

Control (A to D) and mitral valve prolapse (MVP) (E to H) patients. The two-dimensional transthoracic echocardiography (TTE) parasternal long-axis views (A, B, E, F) and cardiovascular magnetic resonance (CMR) left ventricle (LV) outflow tract views (C, D, G, H).(A, C, E, G) Diastole; (B, D, F, H) systole. In panel H, arrowsindicate the prolapsed distance measured by the maximum distance of the prolapsed leaflet to the mitral annular plane. LA = left atrium.

http://ehjcimaging.oxfordjournals.org/content/4/4/237

Mitral valve insufficiency/regurgitation: cardiac magnetic resonance imaging

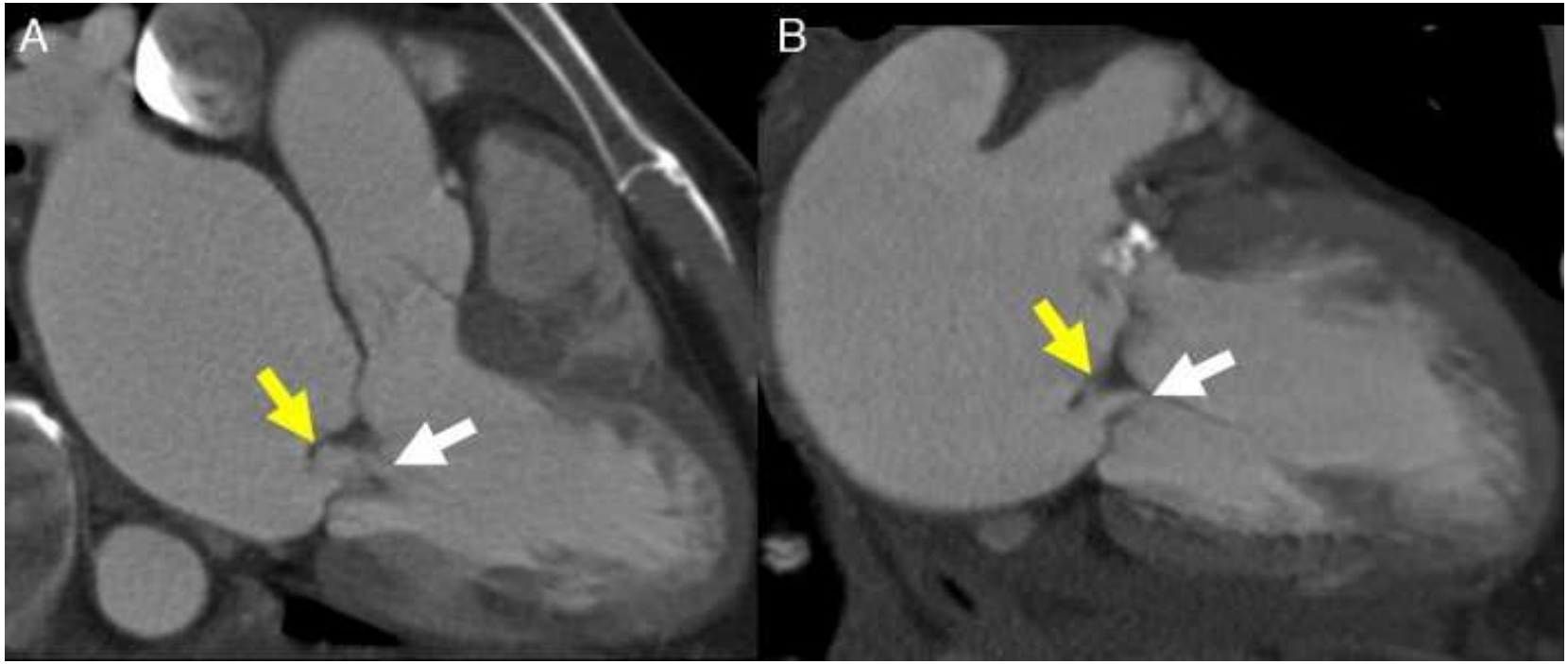

Mitral insufficiency in three-chamber (A) and two-chamber (B) views in diastole show a closure defect of the mitral valve (white arrow),

http://ehjcimaging.oxfordjournals.org/content/4/4/237

Mitral valve insufficiency/regurgitation: computer tomography

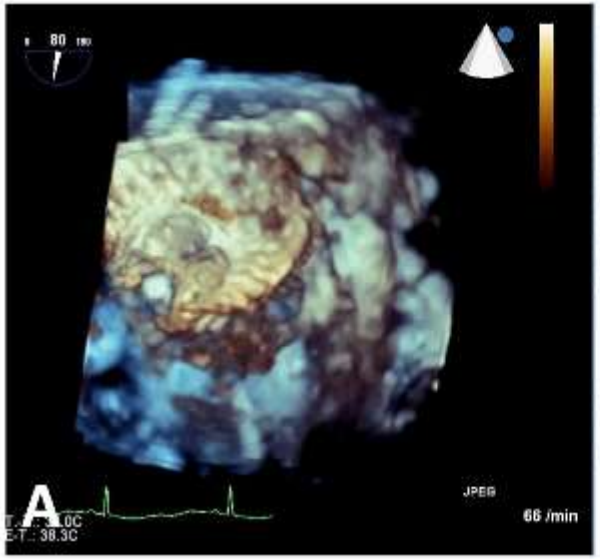

3D transesophageal echocardiographic image showing the valved stent after successful deployment in the native mitral annulus during systole.

http://www.dicardiology.com/sites/daic/files/styles/content_feed_large/public/field/image/X0000_Abbott_MitraClip%20system.jpg?itok=V0lK3Shj
http://www.heartlungandvessels.org/allegati/numeri/images/art_00230_img_01868.jpg

Mitral valve insufficiency/regurgitation: chest X-ray

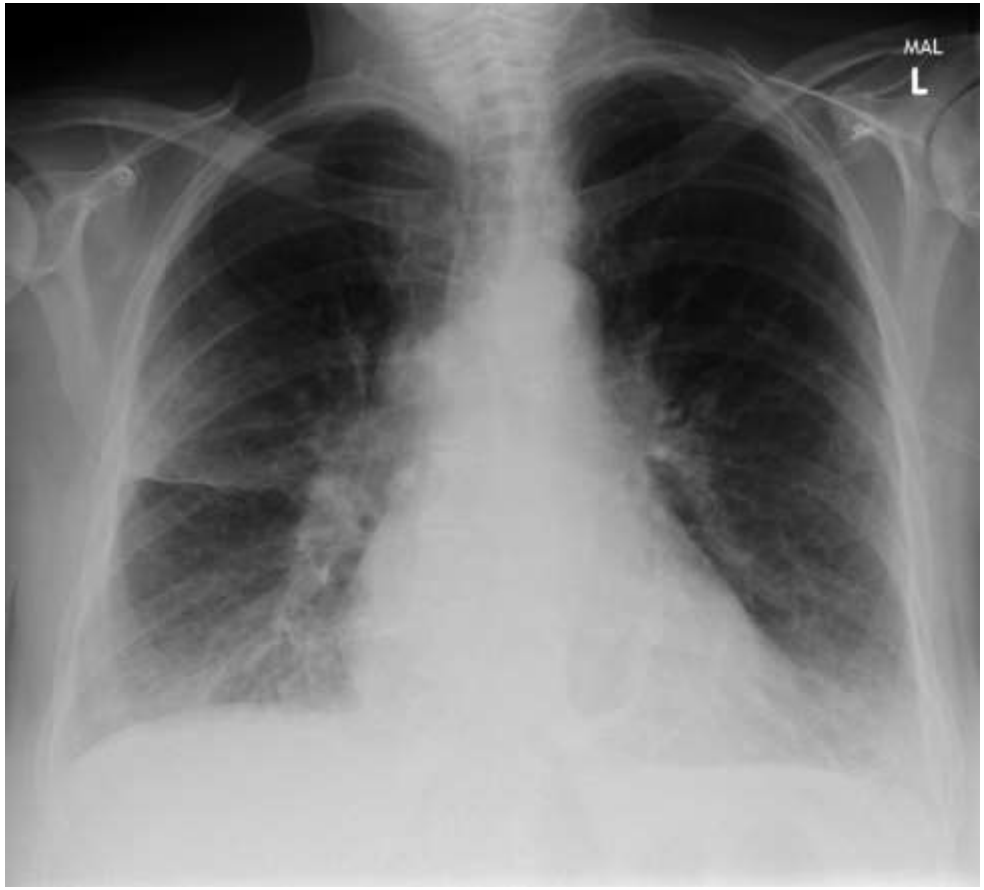

Unilateral pulmonary oedema in severe mitral regurgitation from posterior leaftlet prolapse.

http://images.radiopaedia.org/images/2760131/e0b4f87c533abf2f18ec3aa2f9cbbe.jpg

Mitral valve insufficiency/regurgitation: cardiac catheterisation

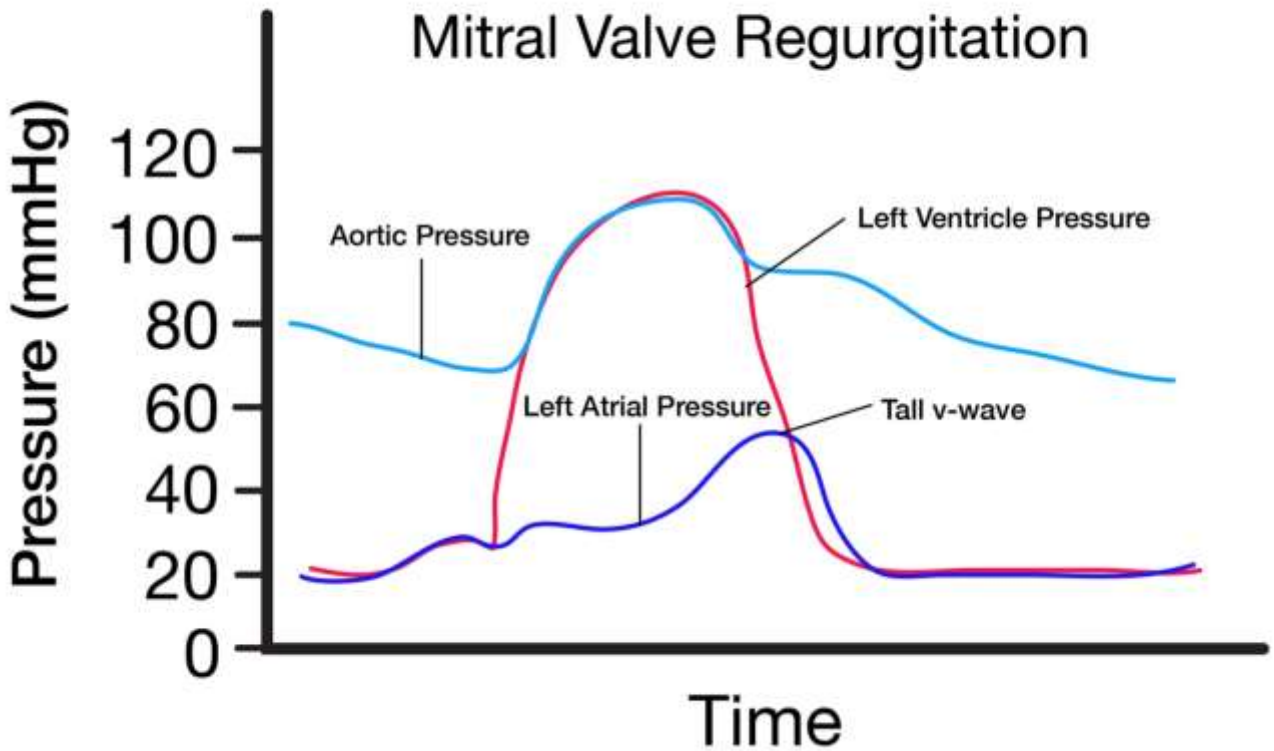

http://musom.marshall.edu/graphicdesign/ibooks/website-portfolio-images/Systems/Cardiovascular%20Normal/Cardiac%20Cycle%20in%20Mitral%20Regurgitation-MU.jpg

(Arterial) hypertension

(Arterial) hypertension: definition

- Hypertension (HTN or HT), also known as high blood pressure or arterial hypertension, is a chronic medical condition in which the blood pressure in the arteries is elevated
- Hypertension is having a blood pressure higher than 139 over 89 (≥ 140 and/or ≥ 90) mmHg for most adults; different criteria apply to children

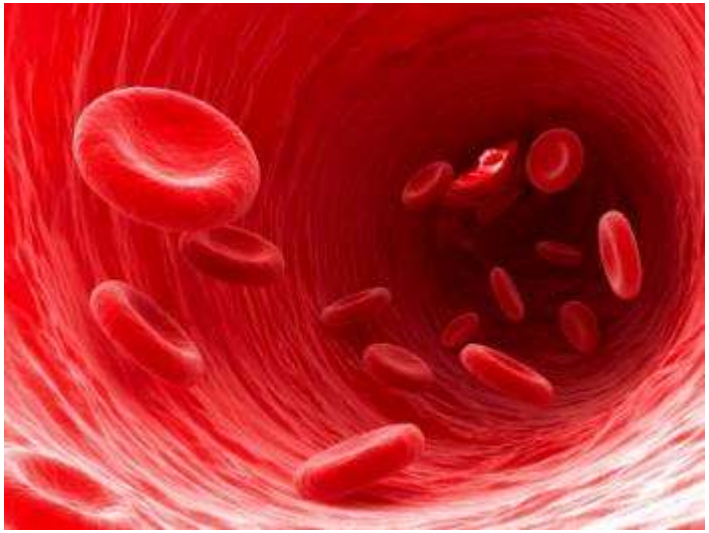

The blood flowing inside vessels exerts a force against the walls – this is blood pressure

http://www.medicalnewstoday.com/articles/150109.php#what_is_hypertension https://en.wikipedia.org/wiki/Hypertension

(Arterial) hypertension: types

- Primary (essential) hypertension, defined as high blood pressure with no obvious underlying cause
- Secondary hypertension, defined as high blood pressure due to an identifiable cause, such as chronic kidney disease, narrowing of the aorta or kidney arteries; endocrine disorders such as
excess aldosterone, cortisol, catecholamines overproduction, etc.

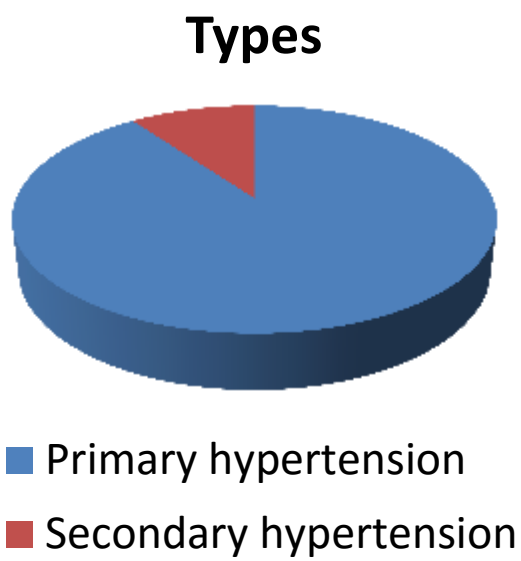

http://http://https://en.wikipedia.org/wiki/Hypertension

(Arterial) hypertension: classification of blood pressure for adults

Category	Systolic, mm Hg	Diastolic, mm Hg
Normal	90–119	60–79
High normal (Prehypertension)	120–139	80–89
Stage 1 hypertension	140–159	90–99
Stage 2 hypertension	160–179	100–109
Stage 3 hypertension (Hypertensive emergency)	≥180	≥110
Isolated systolic hypertension	≥140	<90

https://en.wikipedia.org/wiki/Hypertension

(Arterial) hypertension: causes of primary hypertension

- Hypertension results from a complex interaction of genes and environmental factors
- Numerous common genetic variants with small effects on blood pressure have been identified as well as some rare genetic variants with large effects on blood pressure, but the genetic basis of hypertension is still poorly understood

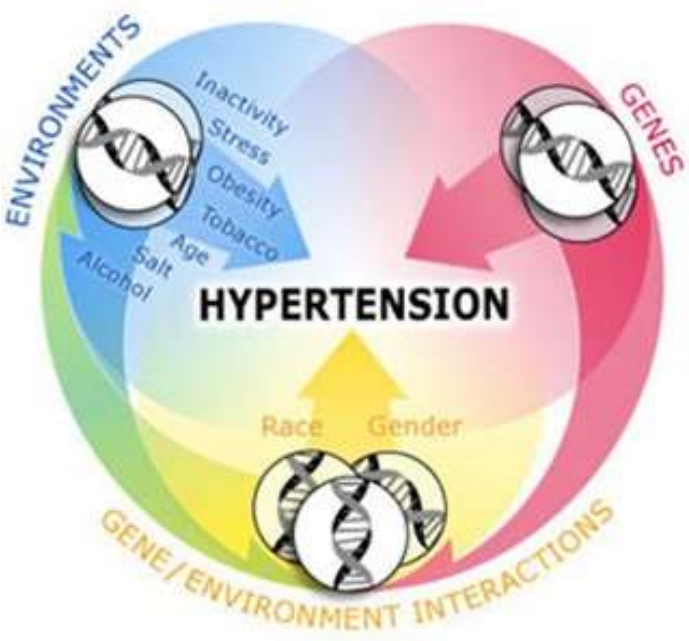

http://cdn3.nursingcrib.com/wp-content/uploads/hypertension2-thumb.jpg
http://http://www.mayoclinic.org/diseases-conditions/high-blood-pressure/basics/symptoms/con-20019580 https://en.wikipedia.org/wiki/Hypertension

(Arterial) hypertension: causes of secondary hypertension

- Kidney disease
- Cushing's syndrome
- Hyperthyroidism
- Hypothyroidism
- Acromegaly
- Conn's syndrome
- Hyperaldosteronism (other causes)
- Hyperparathyroidism
- Pheochromocytoma
- Obesity
- Sleep apnea
- Pregnancy
- Drug-induced
- Etc.

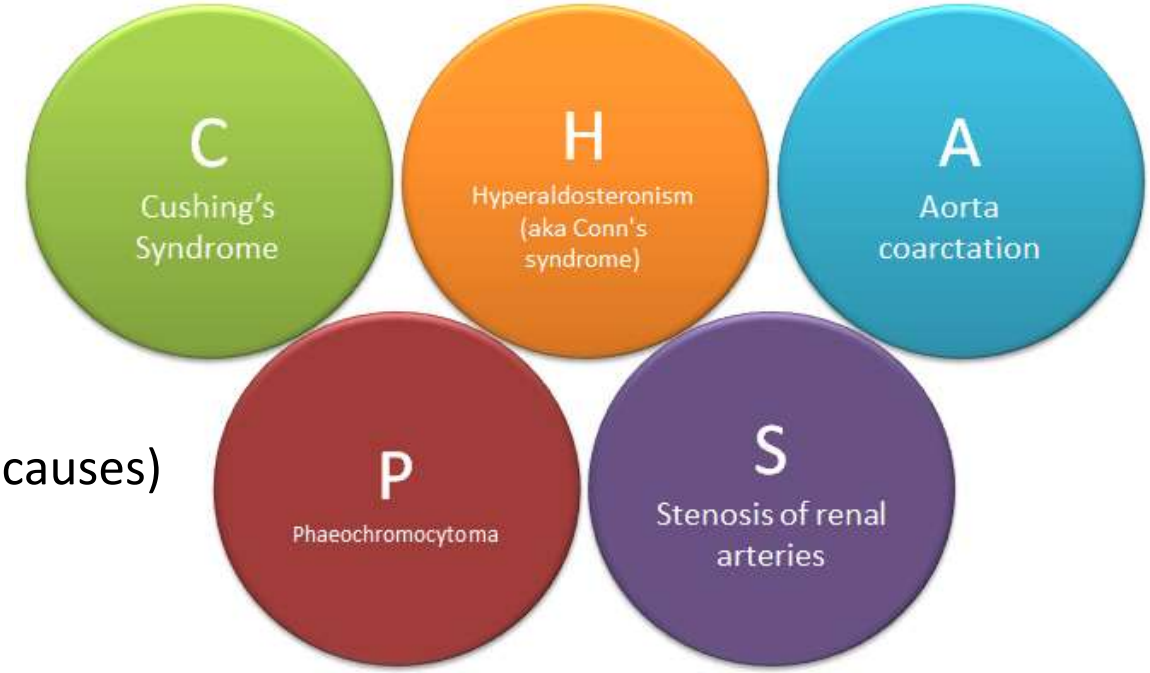

Mnemonic "CHAPS"

http://knowmedge.com/blog/wp-content/uploads/2014/04/Medical-Mnemonics-Secondary-Causes-Hypertension.png
http://http://www.mayoclinic.org/diseases-conditions/high-blood-pressure/basics/symptoms/con-20019580 https://en.wikipedia.org/wiki/Hypertension

(Arterial) hypertension: hypertensinogenic (risk) factors

- Age
- Race
- Sex
- Family history
- Obesity
- A sedentary lifestyle
- Insulin resistance
- Using tobacco
- High alcohol intake
- High salt intake
- Stress
- Dyslipidemia
- Low potassium intake
- Low calcium intake
- Too little vitamin D in diet
- Certain chronic conditions

http://circ.ahajournals.org/content/101/3/329.long

(Arterial) hypertension: SCORE and HeartScore

- SCORE (Systematic Coronary Risk Evaluation) is a cardiovascular disease risk assessment system initiated by the European Society of Cardiology
- SCORE is based on the following risk factors: gender, age, smoking, systolic blood pressure and total cholesterol
- HeartScore is the interactive version of SCORE
- The threshold for high risk based on fatal cardiovascular events is defined as "higher than 5%", instead of the previous "higher than 20%" using a composite coronary endpoint

http://www.heartscore.org

http://circ.ahajournals.org/content/101/3/329.long

(Arterial) hypertension: stratification of total cardiovascular disease risk

Other risk factors, asymptomatic organ damage or disease	Blood Pressure (mmHg)			
	High normal SBP 130–139 or DBP 85–89	Grade 1 HT SBP 140–159 or DBP 90–99	Grade 2 HT SBP 160–179 or DBP 100–109	Grade 3 HT SBP ≥180 or DBP ≥110
No other RF		Low risk	Moderate risk	High risk
1–2 RF	Low risk	Moderate risk	Moderate to high risk	High risk
≥3 RF	Low to Moderate risk	Moderate to high risk	High Risk	High risk
OD, CKD stage 3 or diabetes	Moderate to high risk	High risk	High risk	High to very high risk
Symptomatic CVD, CKD stage ≥4 or diabetes with OD/RFs	Very high risk	Very high risk	Very high risk	Very high risk

BP = blood pressure; CKD = chronic kidney disease; CV = cardiovascular; CVD = cardiovascular disease; DBP = diastolic blood pressure; HT = hypertension; OD = organ damage; RF = risk factor; SBP = systolic blood pressure.

http://d1vzuwdl7rxiz0.cloudfront.net/content/ehj/34/28/2159/F1.large.jpg

(Arterial) hypertension: pathophysiology

- Key factors:
  - Abnormal Na transport
  - Increased sympathetic nervous activity
  - Increased renin-angiotensin-aldosterone system activity
  - Vasodilator deficiency

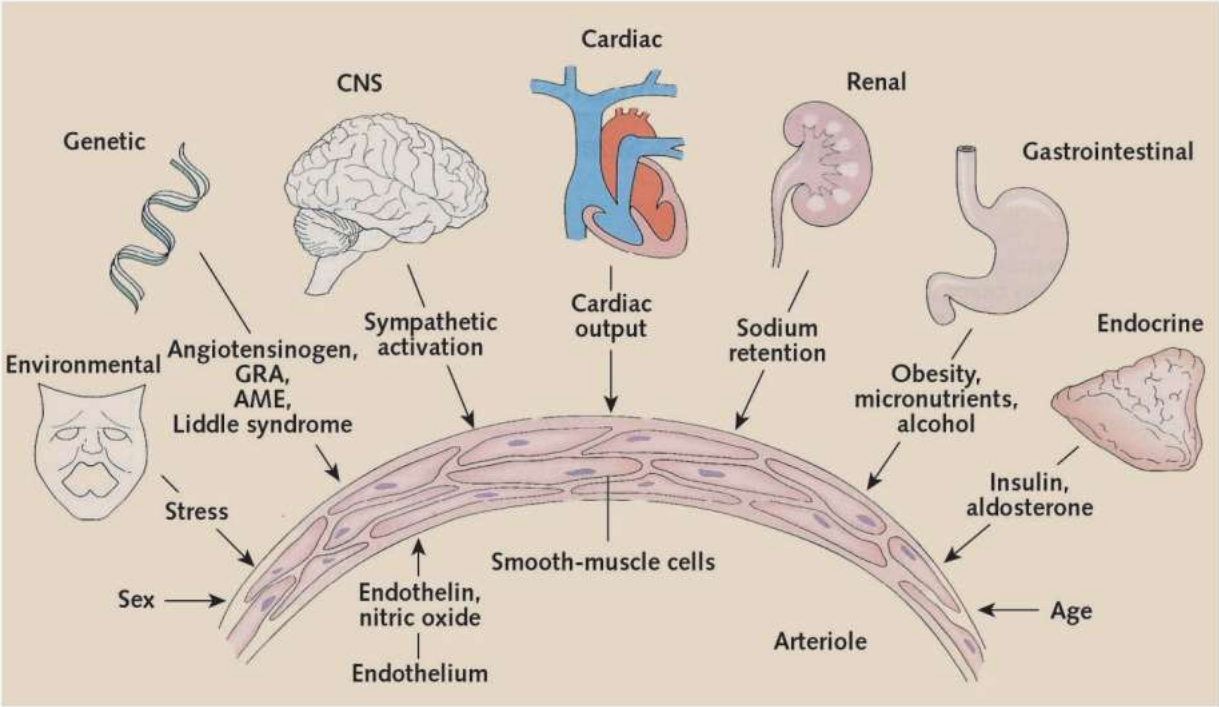

AME - apparent mineralocorticoid excess; CNS - central nervous system; GRA - glucocorticoid-remediable aldosteronism

http://www.the-aps.org/mm/publications/journals/pim/oparil-pdf.pdf

(Arterial) hypertension: signs and symptoms

- Most people with high blood pressure have no signs or symptoms, even if blood pressure readings reach dangerously high levels
- A few people with high blood pressure may have headaches, shortness of breath or nosebleeds, but these signs and symptoms aren't specific and usually don't occur until high blood pressure has reached a severe or life-threatening stage

http://www.webhealthjournal.com/common-symptoms-signs-of-high-blood-pressure/
http://http://www.mayoclinic.org/diseases-conditions/high-blood-pressure/basics/symptoms/con-20019580 https://en.wikipedia.org/wiki/Hypertension

(Arterial) hypertension: main complications

- Hypertensive heart disease
- Coronary artery disease
- Stroke
- Aortic aneurysm
- Peripheral artery disease
- Chronic kidney disease
- Chronic heart failure
- Hypertensive retinopathy

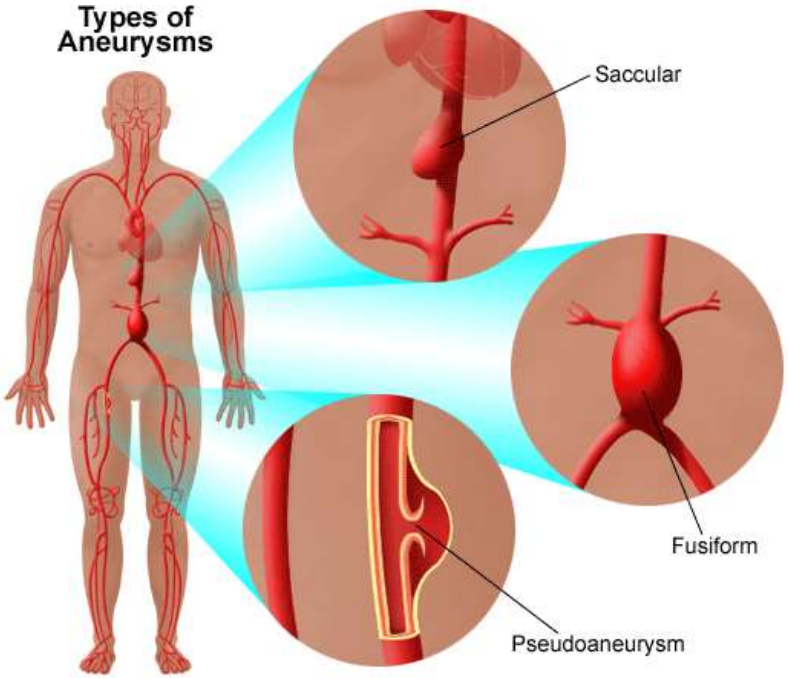

https://stanfordhealthcare.org/content/dam/SHC/conditions/blood-heart-circulation/images/abdominalaorticaneurysm-diagram-veinsaneurysms.gif
http://http://www.mayoclinic.org/diseases-conditions/high-blood-pressure/basics/symptoms/con-20019580 https://en.wikipedia.org/wiki/Hypertension

(Arterial) hypertension: medical history

- The known duration of hypertension and previously recorded levels
- Any history or symptoms of coronary artery disease (CAD), heart failure (HF)
- Other relevant coexisting disorders (e.g., stroke, renal dysfunction, peripheral arterial disease, dyslipidemia, diabetes, gout)
- Family history of any of these disorders
- Social history includes exercise levels and use of tobacco, alcohol, and stimulant drugs (prescribed and illicit)
- A dietary history focuses on intake of salt and stimulants (e.g., tea, coffee, caffeine-containing sodas, energy drinks)
- Lifestyle factors
- Current and previous medications

http://http://www.mayoclinic.org/diseases-conditions/high-blood-pressure/basics/symptoms/con-20019580 https://en.wikipedia.org/wiki/Hypertension

(Arterial) hypertension: physical examination

- Height, weight, and waist circumference
- Funduscopic examination for retinopathy
- Auscultation for bruits in the neck and abdomen (a unilateral renal artery bruit may be heard in slim patients with renovascular hypertension)
- Full cardiac, respiratory, and neurologic examination
- Heart auscultation (a 4th heart sound is one of the earliest signs of hypertensive heart disease)
- The abdomen palpation for kidney enlargement and abdominal masses
- Peripheral arterial pulses investigation (diminished or delayed femoral pulses suggest aortic coarctation, particularly in patients < 30)

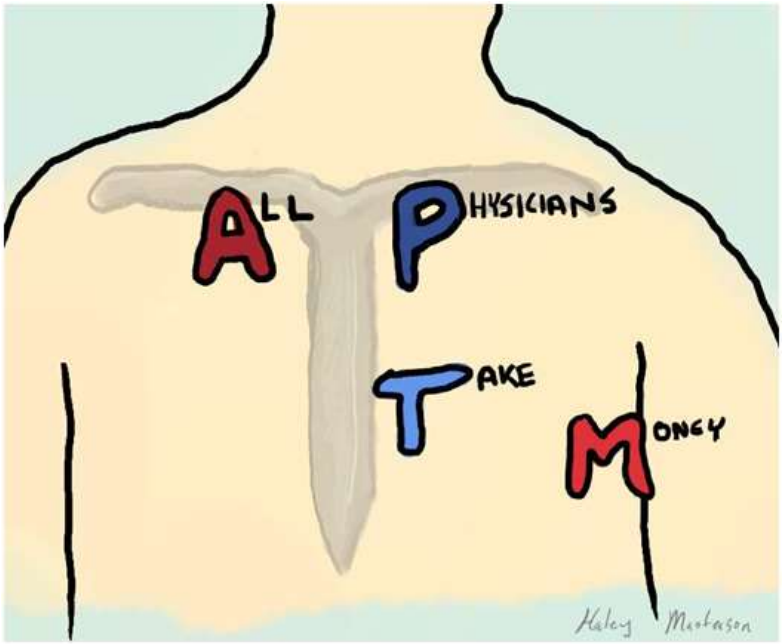

Aortic, Pulmonic, Tricuspid, Mitral

http://www.firstaidteam.com/4457/mnemonic-monday-positions-of-heart-auscultation
http://http://www.mayoclinic.org/diseases-conditions/high-blood-pressure/basics/symptoms/con-20019580 https://en.wikipedia.org/wiki/Hypertension

(Arterial) hypertension: hypertensive crisis

- Severely elevated blood pressure equal to or greater than a systolic 180 or diastolic of 110 is referred to as a hypertensive crisis
- Hypertensive crisis is categorized as hypertensive urgency, according to the presence or absence of end organ damage
- The most affected organs include the brain, kidney, heart, aorta and lungs

In hypertensive emergency, the blood pressure must be reduced rapidly to stop ongoing organ damage

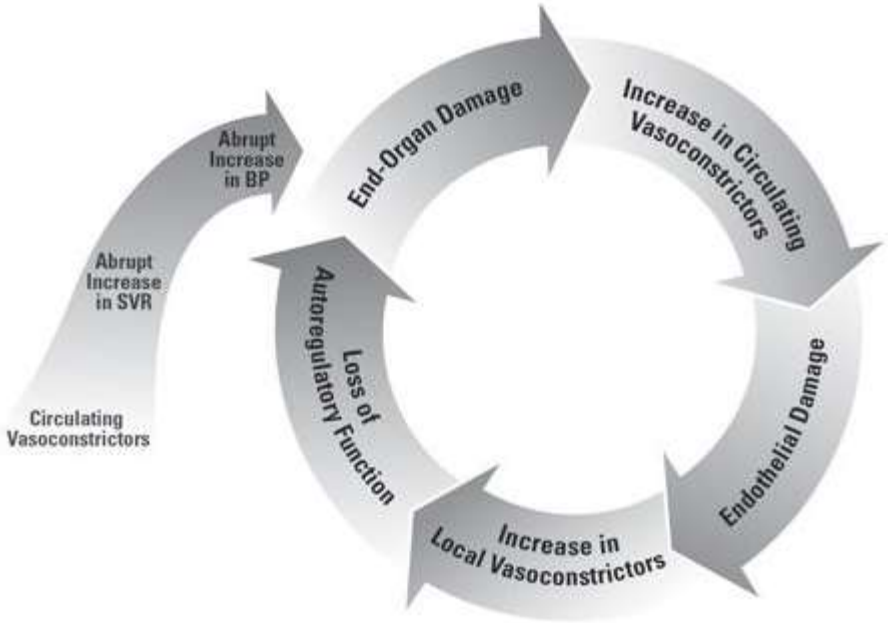

Pathophysiologic mechanism, SVR - systemic vascular resistance, BP – blood pressure

https://s-media-cache-ak0.pinimg.com/736x/ed/ce/82/edce823cecd94c5554703f83bc956057.jpg
http://http://www.mayoclinic.org/diseases-conditions/high-blood-pressure/basics/symptoms/con-20019580 https://en.wikipedia.org/wiki/Hypertension

(Arterial) hypertension: diagnosis

- Multiple measurements of blood pressure (BP) to confirm
- Urinalysis and urinary albumin: creatinine ratio
- Blood tests: fasting lipids, hematocrit, creatinine, serum potassium (K), creatinine (or the corresponding estimated glomerular filtration rate), calcium, lipid profile, glucose
- Renal ultrasonography if creatinine increased
- Evaluate for aldosteronism if K decreased
- ECG: If left ventricular hypertrophy, consider echocardiography
- Sometimes measurement of thyroid-stimulating hormone, T3-T4 hormones, cortisol
- Evaluation for pheochromocytoma or a sleep disorder if BP elevation sudden and labile or severe

Blood pressure is measured by sphygmomanometry.

http://www.merckmanuals.com/professional/cardiovascular-disorders/hypertension/overview-of-hypertension#v932160

(Arterial) hypertension: office blood pressure monitoring

- The patient should be seated comfortably with the back supported and the upper arm bared without constrictive clothing
- The legs should not be crossed
- The arm should be supported at the level of the heart, and the bladder of the blood pressure (BP) cuff should encircle at least 80% of the arm circumference
- The BP measuring device should be deflated at the rate of 2 to 3 mm/sec, and the first and last audible sounds should be taken as the systolic and diastolic pressure respectively
- Neither the patient nor the observer should talk during the measurement
- Measurements may be both while seated and after standing, to look for orthostatic or postural hypotension
- At least the first measurement should be done on the right and left arms

http://www.clevelandclinicmeded.com/medicalpubs/diseasemanagement/nephrology/arterial-hypertension/

(Arterial) hypertension: office blood pressure monitoring

Man getting his blood pressure taken at the doctor's office.

http://www.cdc.gov/dhdsp/images/hbp_patient.jpg

(Arterial) hypertension: ambulatory blood pressure monitoring

- The National Institute of Health and Clinical Excellence (NICE) guidelines recommend that a diagnosis of primary hypertension should be confirmed with 24-hour ambulatory blood pressure monitoring or home blood pressure monitoring rather than by relying solely on office blood pressure measurement
- Twenty-four-hour ambulatory BP monitoring is indicated to rule out white-coat hypertension, to uncover apparent drug resistance (office resistance), to better define resistant hypertension, to identify hypotensive symptoms while the patient is being treated with anti-hypertensive medications, to monitor episodic hypertension, and to identify autonomic dysfunction states
- Twenty-four-hour ambulatory BP monitoring also helps identify abnormal patterns in blood pressure that could remain undetected if a patient is evaluated based on physician office blood pressure measurements alone

http://www.merckmanuals.com/professional/cardiovascular-disorders/hypertension/overview-of-hypertension#v932160

(Arterial) hypertension: ambulatory blood pressure monitoring

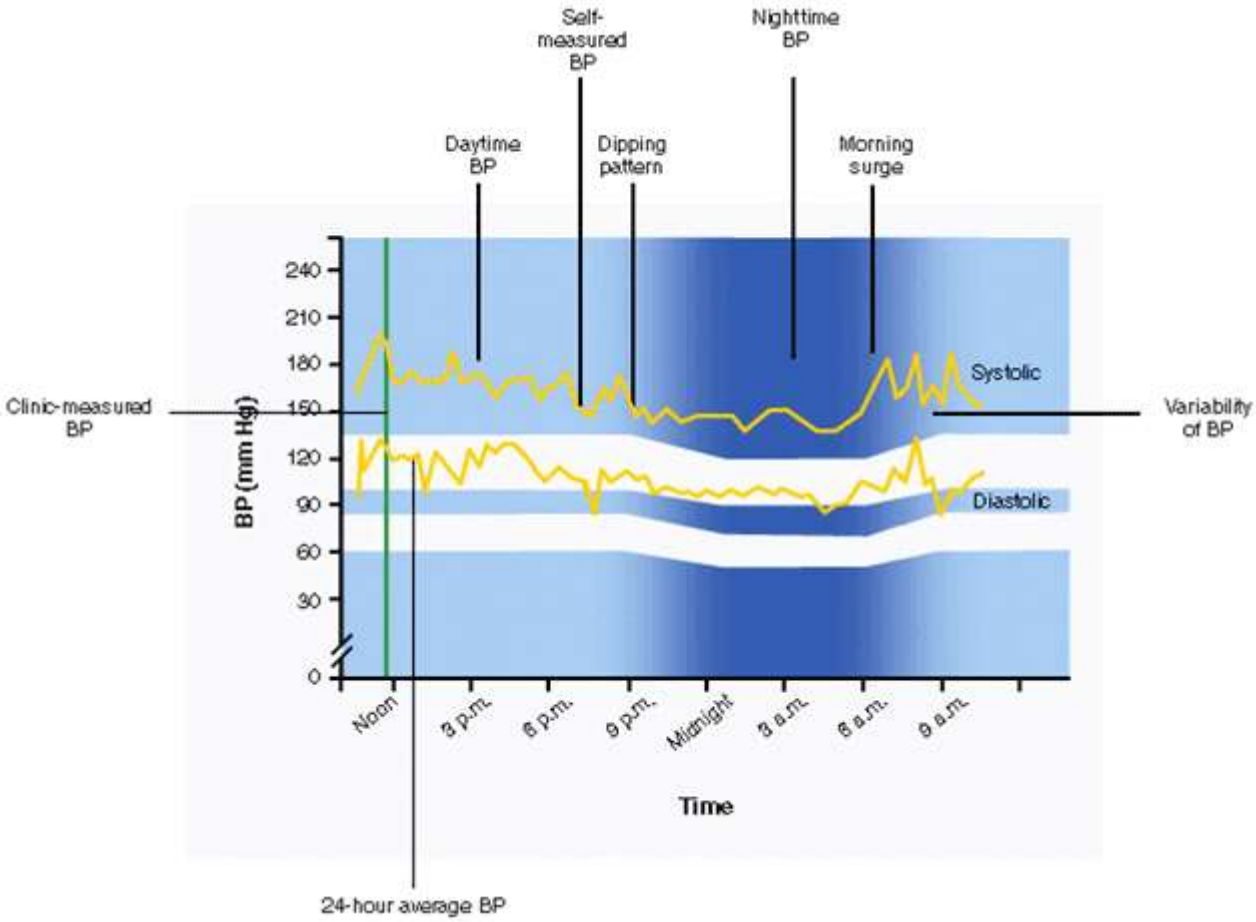

http://img.medscape.com/fullsize/migrated/571/657/ajh571657.fig2.gif

(Arterial) hypertension: extent of the night time BP attenuation

- The extent of the nighttime BP attenuation has been mainly quantified through the so-called “sleep-time relative BP decline”, which is defined as the percent decrease in mean BP during nighttime sleep relative to the mean BP during daytime activity
- More recently, the classification has been extended by dividing individuals into four groups:
- Extreme-dippers (sleep-time relative BP decline >20%)
- Dippers (sleep-time relative BP decline >=10% but <20%)
- Non dippers (sleep-time relative BP decline <10%)
- Inverse-dippers or risers (sleep-time relative BP decline <0%, indicating asleep BP>awake BP mean)

http://www.ncbi.nlm.nih.gov/pubmed/23517220

(Arterial) hypertension: ambulatory blood pressure monitoring

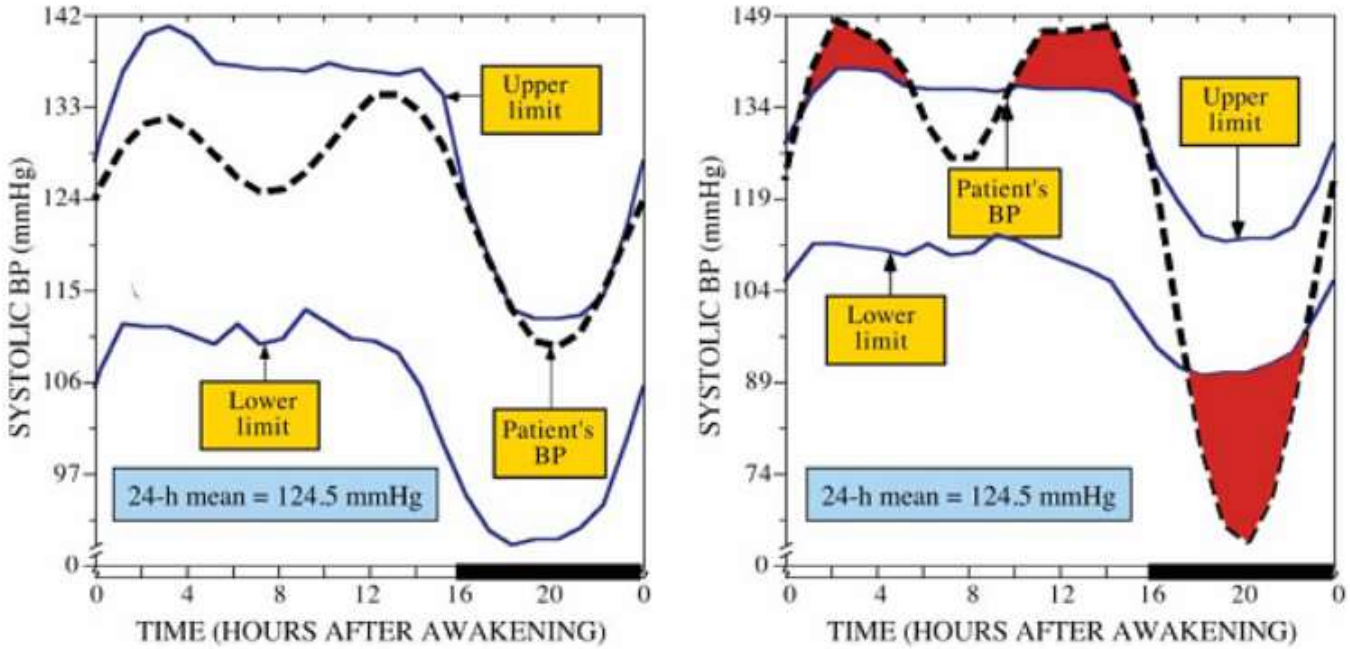

24-h SBP pattern (dashed thick lines) of a normotensive dipper subject (left) and a hypertensive extreme-dipper patient (right), plotted with respect to circadian time-specified tolerance limits(continuous thin lines), calculated from a reference population of normotensive individuals as a function of their rest-activity cycle and sex.

http://www.ncbi.nlm.nih.gov/pubmed/23517220

(Arterial) hypertension: ambulatory blood pressure monitoring

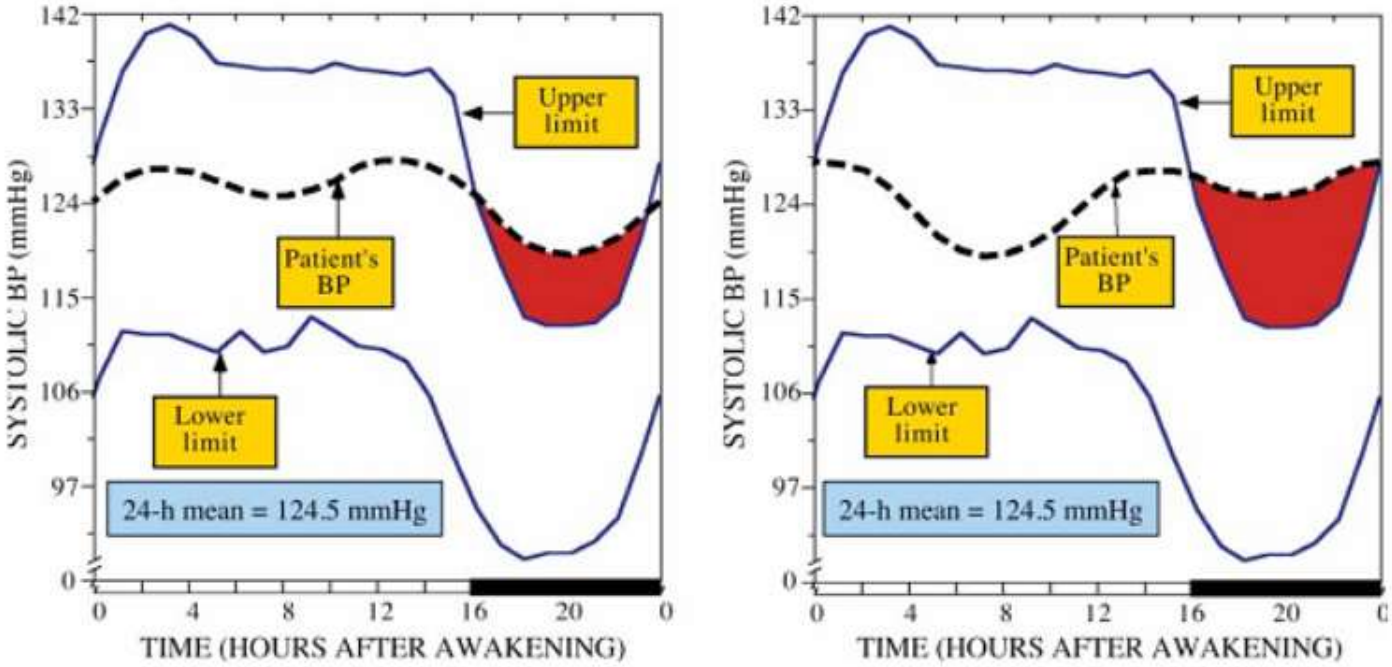

24-h SBP pattern (dashed thick lines) of a hypertensive non-dipper (left) and a hypertensive riser patient (right), plotted with respect to circadian time-specified tolerance limits (continuous thin lines), calculated from a reference population of normotensive individuals as a function of their rest-activity cycle and sex.

http://www.ncbi.nlm.nih.gov/pubmed/23517220

(Arterial) hypertension: home blood pressure monitoring

- The home BP is a better predictor of cardiovascular morbidity and mortality than are office BP measurements
- Hypertension is defined as a mean home blood pressure of ≥135/85 mmHg
- Home blood pressure monitoring provides an inexpensive alternative to 24-hour ambulatory BP monitoring which is not yet widely available
- One of the main drawbacks in home blood pressure measurement when compared to 24-hour ambulatory BP monitoring, is that sleep time blood pressures cannot be recorded and therefore those patients with abnormal dipping pattern in blood pressure and nocturnal hypertension will be missed

http://www.clevelandclinicmeded.com/medicalpubs/diseasemanagement/nephrology/arterial-hypertension/#figure01

(Arterial) hypertension: ankle brachial index

- The ankle brachial pressure index (ABPI or ankle brachial index (ABI) is the ratio of the blood pressure in the lower legs to the blood pressure in the arms
- Compared to the arm, lower blood pressure in the leg is an indication of blocked arteries (peripheral artery disease or PAD) or secondary arterial hypertension due to aortic coarctation
- The ABI is calculated by dividing the systolic blood pressure at the ankle by the systolic blood pressures in the arm

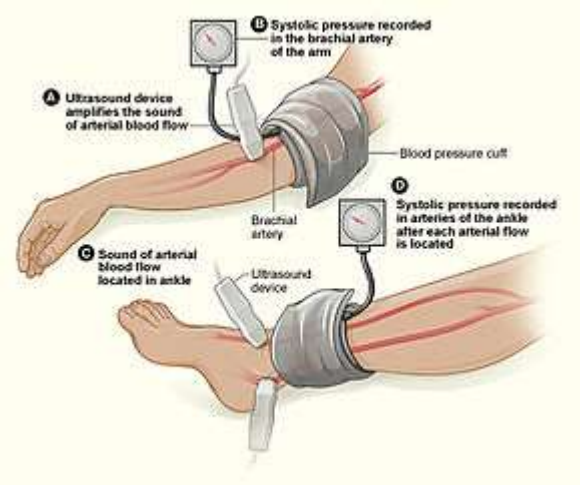

https://en.wikipedia.org/wiki/Ankle_brachial_pressure_index

(Arterial) hypertension: ankle brachial index interpretation

ABPI value	Interpretation	Action	Nature of ulcers, if present
above 1.2	Abnormal vessel hardening from PVD	Refer routinely	Venous ulcer use full compression bandaging
1.0 - 1.2	Normal range	None	
0.9 - 1.0	Acceptable		
0.8 - 0.9	Some arterial disease	Manage risk factors	
0.5 - 0.8	Moderate arterial disease	Routine specialist referral	Mixed ulcers use reduced compression bandaging
under 0.5	Severe arterial disease	Urgent specialist referral	Arterial ulcers no compression bandaging used

ABPI - the ankle brachial pressure index

https://en.wikipedia.org/wiki/Ankle_brachial_pressure_index

(Arterial) hypertension: patterns of blood pressure

The time of change color and model of coat

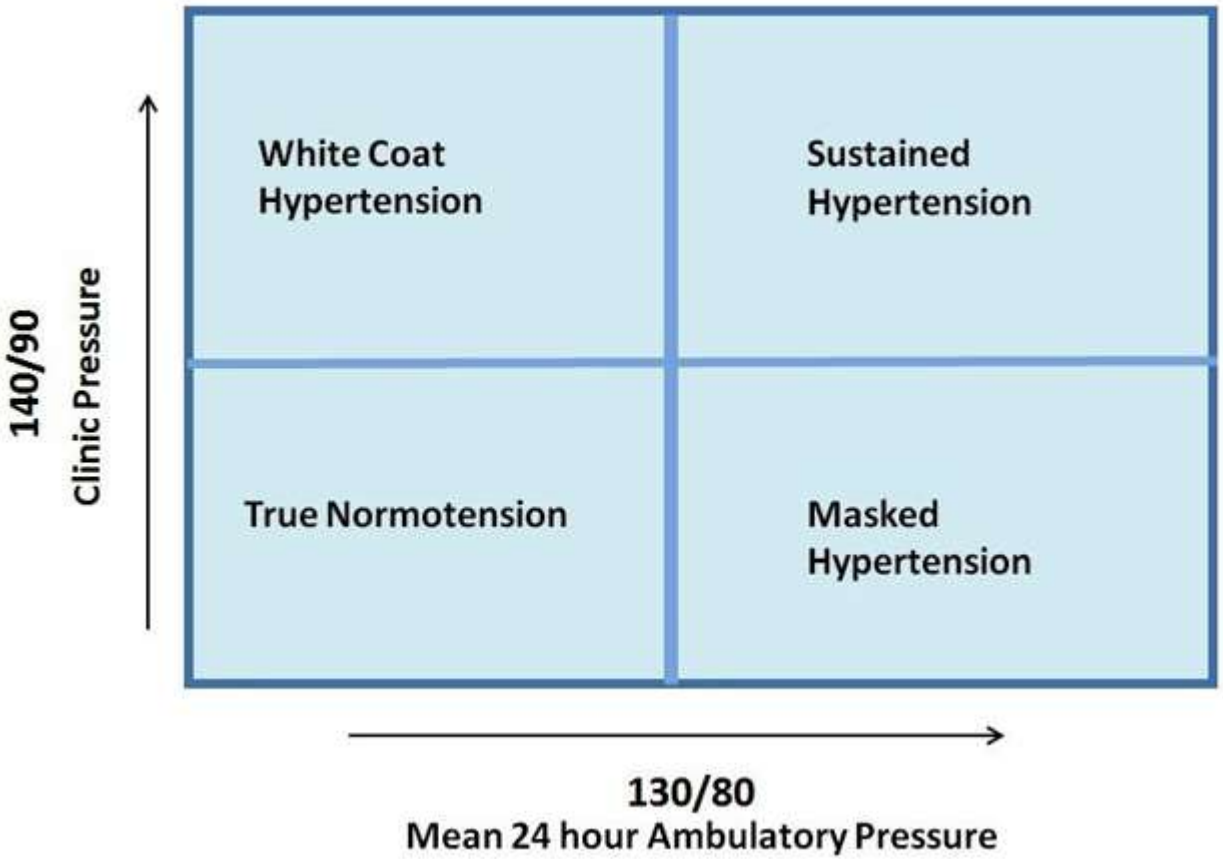

http://cdn3.healthcommunities.com/hcmedia/2011/06/bp-measurement-women.gif
http://www.clevelandclinicmeded.com/medicalpubs/diseasemanagement/nephrology/arterial-hypertension/#figure01

(Arterial) hypertension: white coat hypertension

- White coat hypertension, more commonly known as white coat syndrome, is a phenomenon in which patients exhibit a blood pressure level above the normal range, in a clinical setting, though they don't exhibit it in other settings
- It is believed that the phenomenon is due to anxiety that those afflicted experience, during a clinic visit

http://www.thebroadstreetpractice.co.uk/wp-content/uploads/2013/09/White-coat-hypertension.jpg https://en.wikipedia.org/wiki/White_coat_hypertension

(Arterial) hypertension: masked hypertension

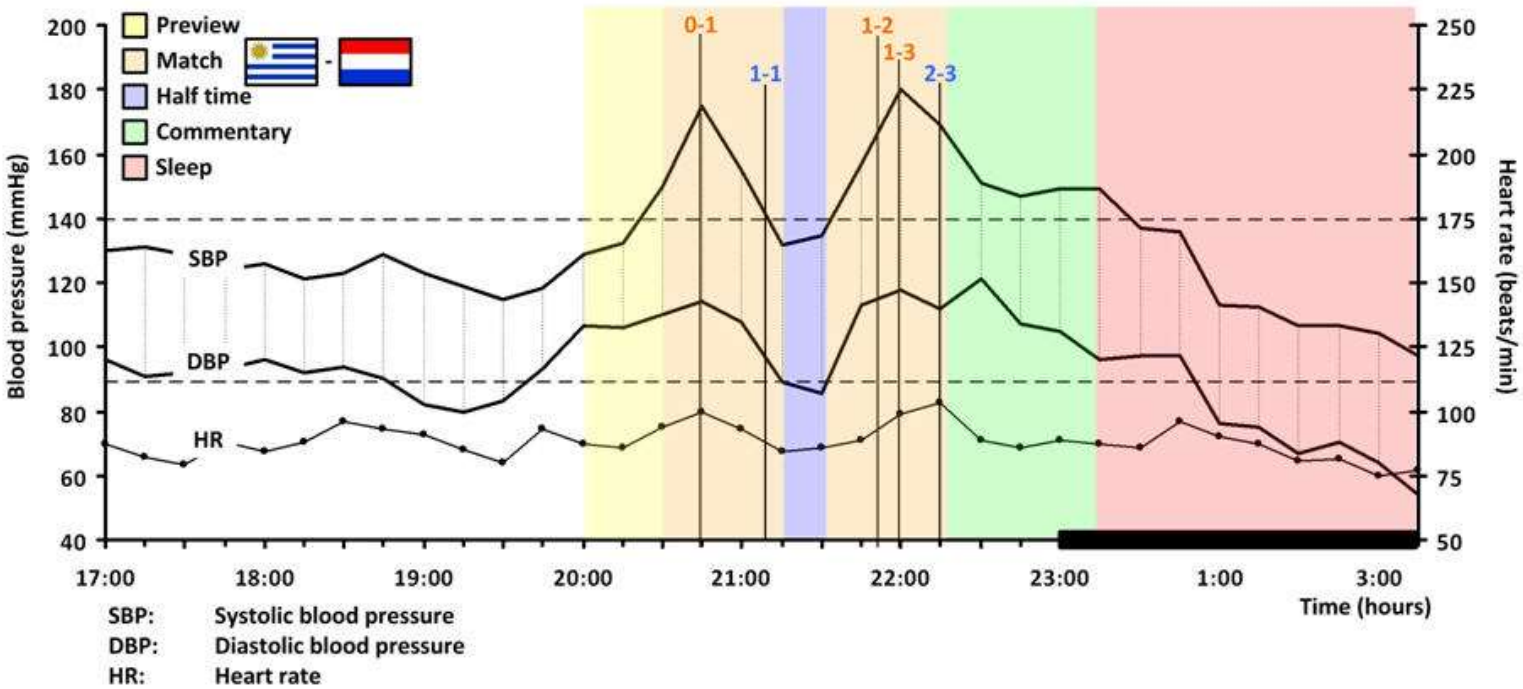

The term "masked hypertension" can be used to describe the contrasting to the white coat hypertension phenomenon, where a patient's blood pressure is above the normal range during daily living, although it isn't above the normal range when the patient is in a clinic setting

http:// http://www.dutchbuttonworks.com/wp-content/uploads/2010/11/Bloeddrukregistratie.jpg https://en.wikipedia.org/wiki/White_coat_hypertension

(Arterial) hypertension: Keith Wagener Barker (KWB) grades of hypertensive retinopathy

- Hypertensive retinopathy is damage to the retina and retinal circulation due to high blood pressure
- KWB grades:
  1. Arteriolar constriction/attenuation/sclerosis - `silver wiring` and vascular tortuosities
  2. As grade 1 + Irregularly located, tight constrictions - known as `AV nicking` or `AV nipping`
  3. As grade 2 + Retinal edema, cotton wool spots and flame-hemorrhages
  4. As grade 3 + swelling of the optic disc (papilloedema) + macular star

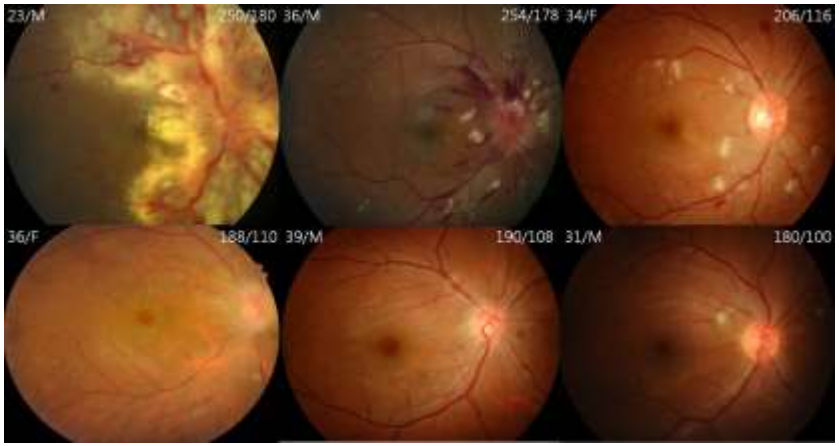

Peripapillary and periarteriolar retinal changes are apparent, including cotton wool spots, retinal hemorrhages, and exudates

http://iovs.arvojournals.org/Article.aspx?articleid=2212632 https://en.wikipedia.org/wiki/Hypertensive_retinopathy

(Arterial) hypertension: ophthalmoscopy

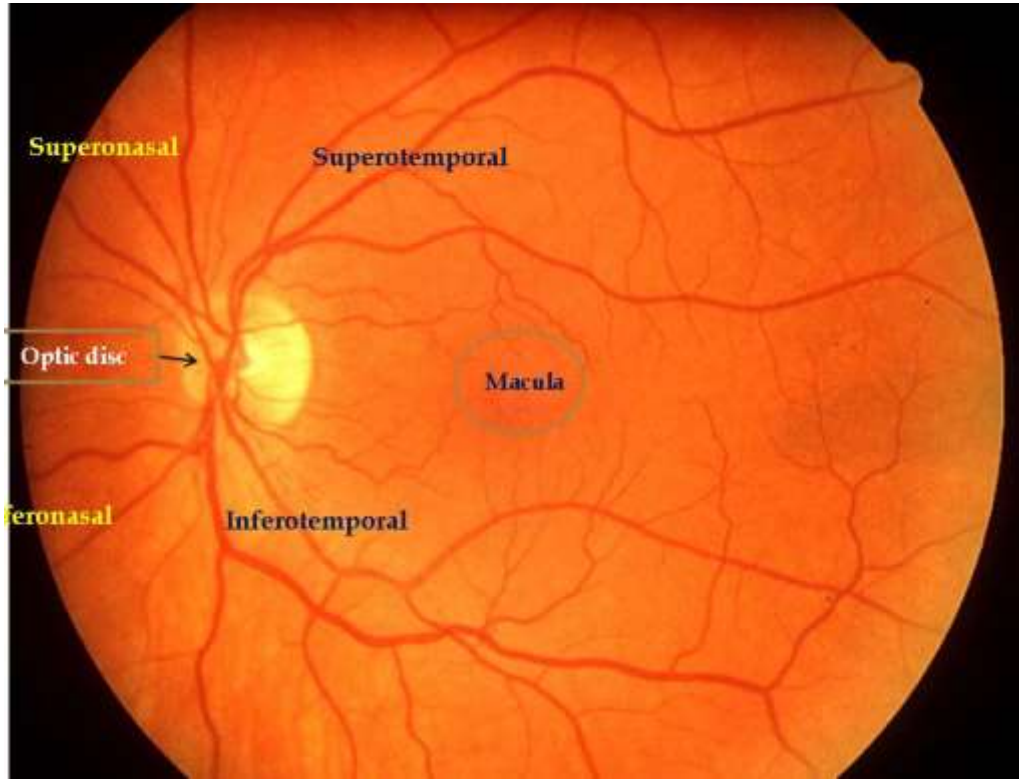

Normal Fundus

http://pharmaworlds.com/wp-content/uploads/www.pharmaworlds.jpg http://intl.welchallyn.com/promotions/PanOptic/images/img_home_doctorPatient.jpg

(Arterial) hypertension: renal sonography

The size of the left kidney is small (8.37 cm in lenth) and echogenicity of the kidney is increased in a patient with left renal artery stenosis. LK, left kidney; SAG, saggital view of the left kidney.

http://numonthly.com/956.fulltext

(Arterial) hypertension: combine renal artery Doppler ultrasound and arteriography

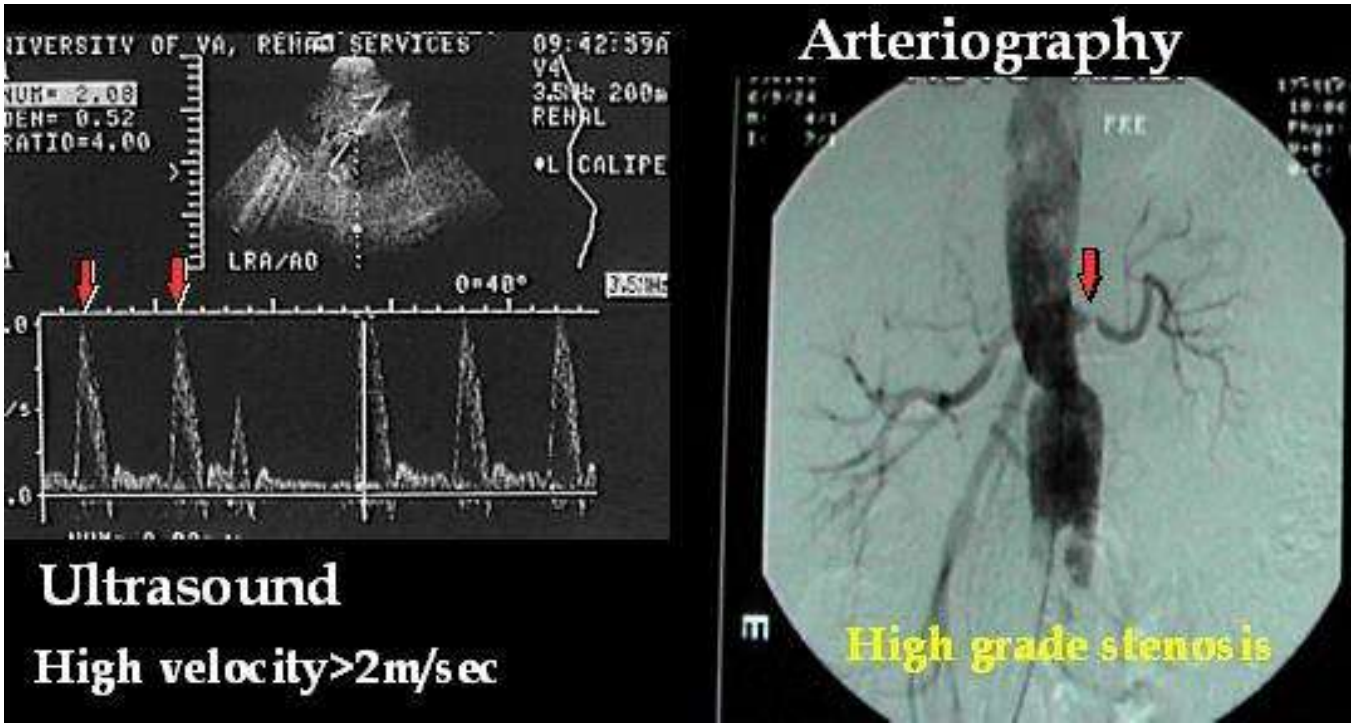

Renal artery Doppler ultrasound (1) screening for renal artery stenosis shows very high velocity flow at the level of the left renal artery origin from the aorta. This indicated a significant stenosis. (2) Subsequent arteriogram in same patient shows tight stenosis at the left renal artery ostium. Following angioplasty, the stenosis was gone and the patient's hypertension resolved.

https://www.med-ed.virginia.edu/courses/rad/gu/kidneys/images/ras.jpg
https://edc2.healthtap.com/ht-staging/user_answer/avatars/987606/large/open-uri20130330-29617-1myknrg.jpeg?1386654286

(Arterial) hypertension: renal color duplex sonography

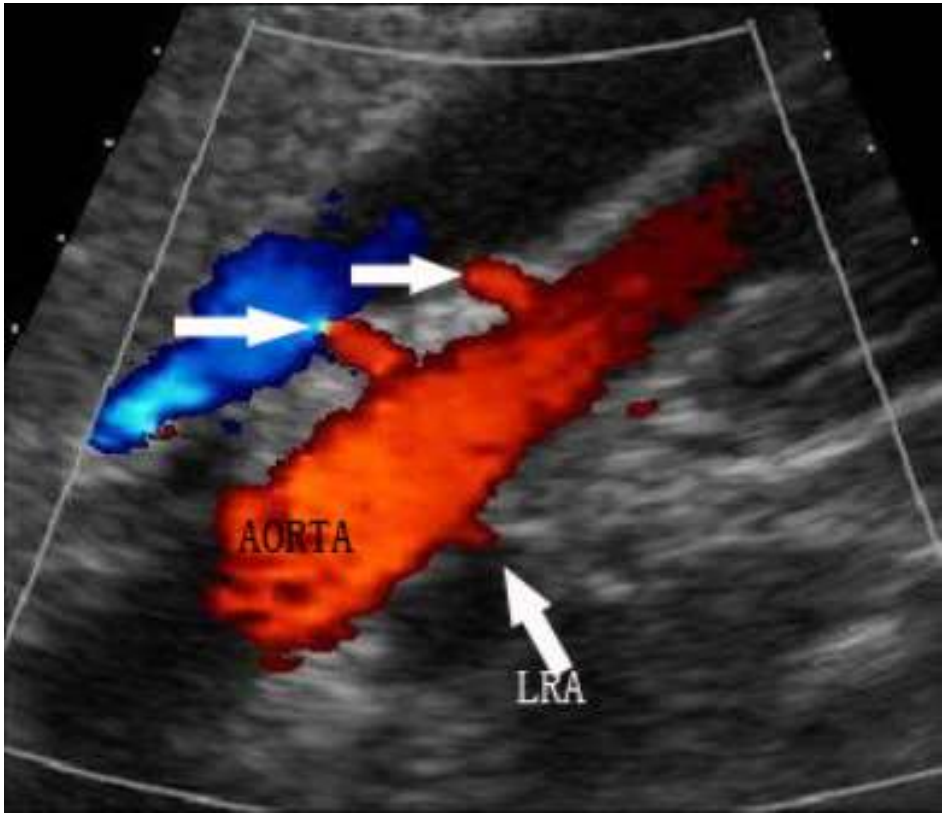

Normal appearance of the right renal artery, right accessory real artery, single left renal artery (arrows), and abdominal aorta on longitudinal view of color flow image. LRA, left renal artery.

http://numonthly.com/956.fulltext

(Arterial) hypertension: renal color duplex sonography

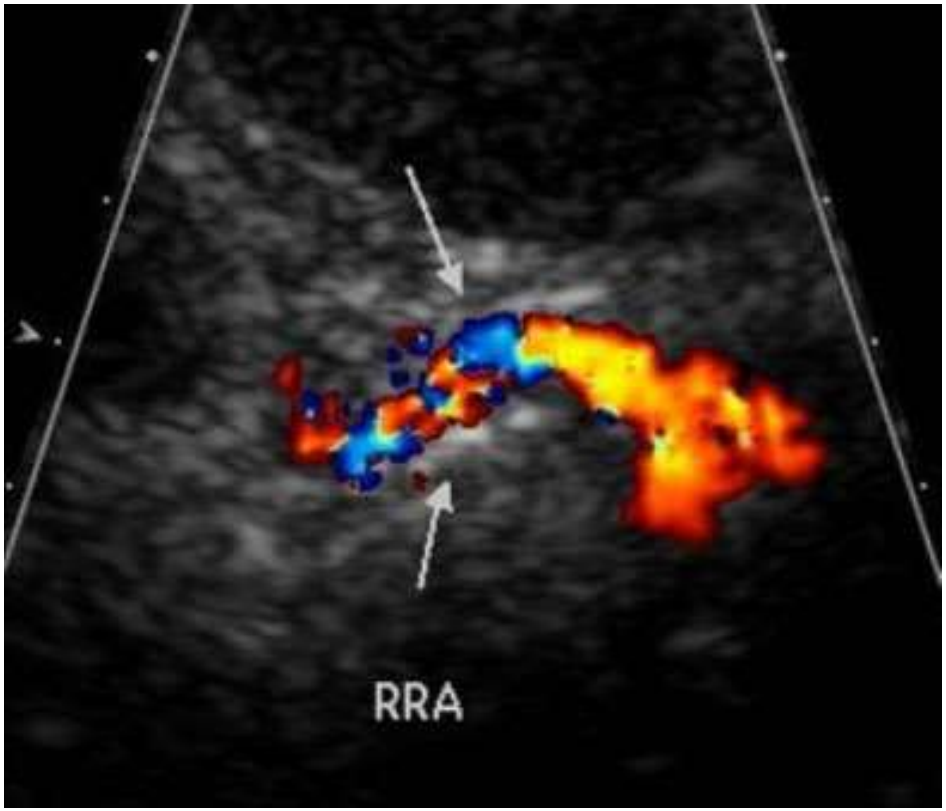

Remarkably turbulent flow at the stenosis of the right proximal renal artery on longitudinal view of color flow image.

http://numonthly.com/956.fulltext

(Arterial) hypertension: renal color duplex sonography

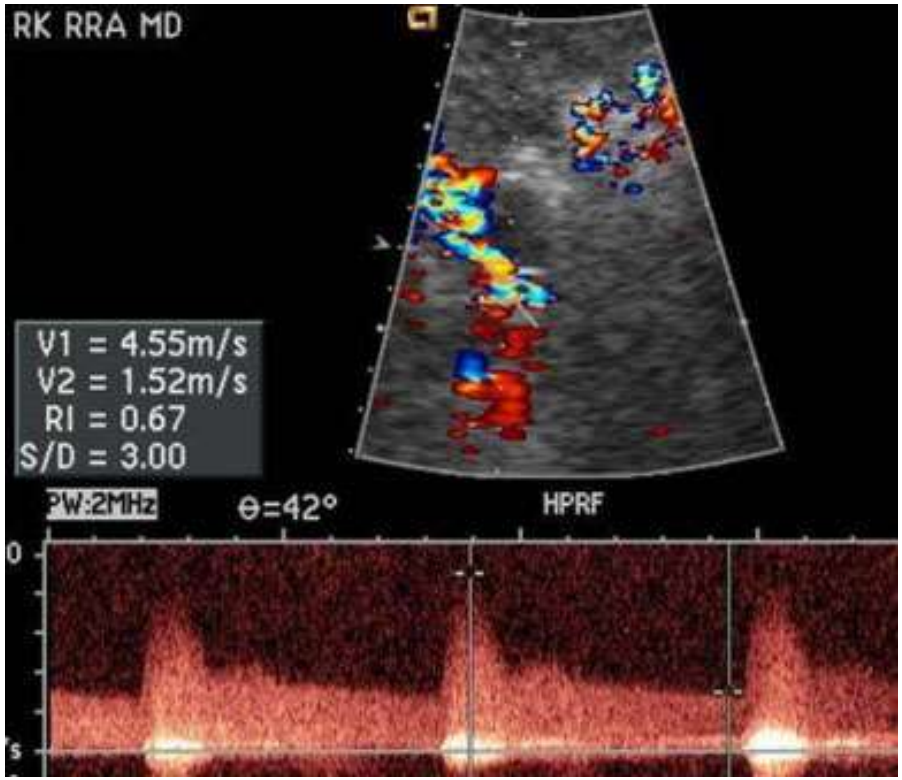

Spectral Doppler demonstrated high peak systolic velocity (6.27 m/s) at the right renal artery with hemodynamically significant stenosis.

http://numonthly.com/956.fulltext

(Arterial) hypertension: renal magnetic resonance imaging

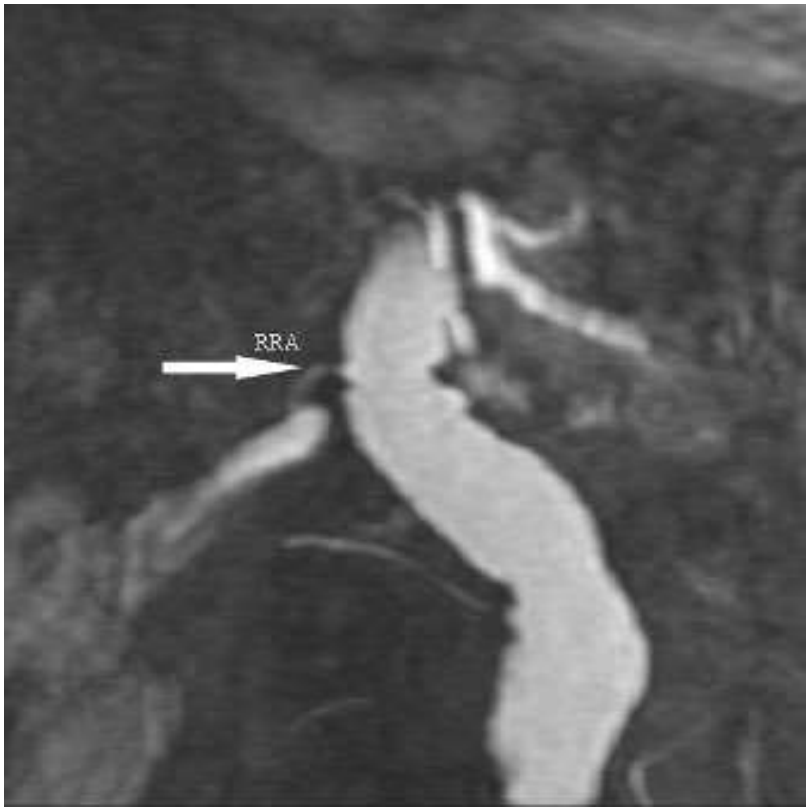

The stenosis at the right proximal renal artery.

http://d1gqps90bl2jsp.cloudfront.net/content/brain/130/8/1988/F1.large.jpg http://ehjcimaging.oxfordjournals.org/content/4/4/237

(Arterial) hypertension: renal radionuclide imaging

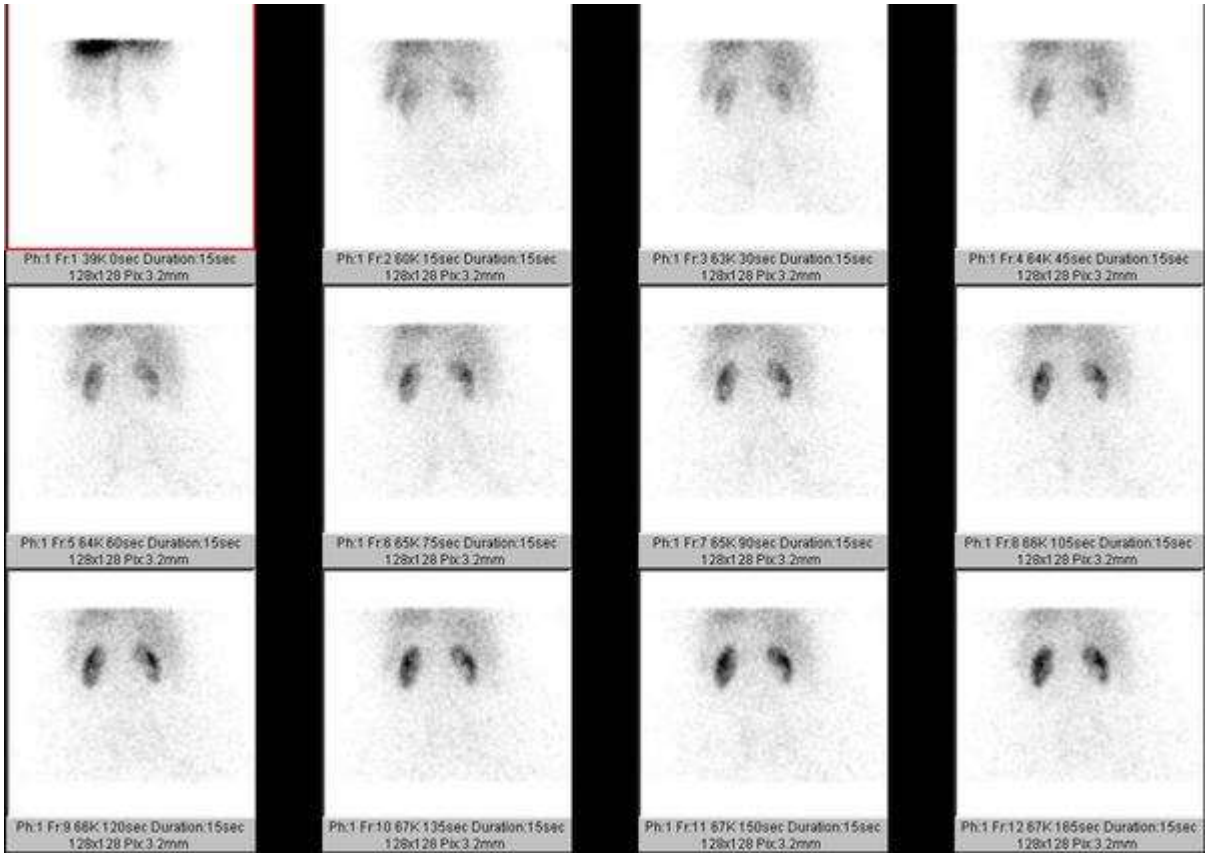

Imaging of kidneys involves intravenous injection of tc mag3 (mercaptoacetyltriglycine) ets., and lying on table for hour or more while imaged by gamma camera

https://edc2.healthtap.com/ht-staging/user_answer/avatars/987606/large/open-uri20130330-29617-1myknrg.jpeg?1386654286

(Arterial) hypertension: brain magnetic resonance imaging

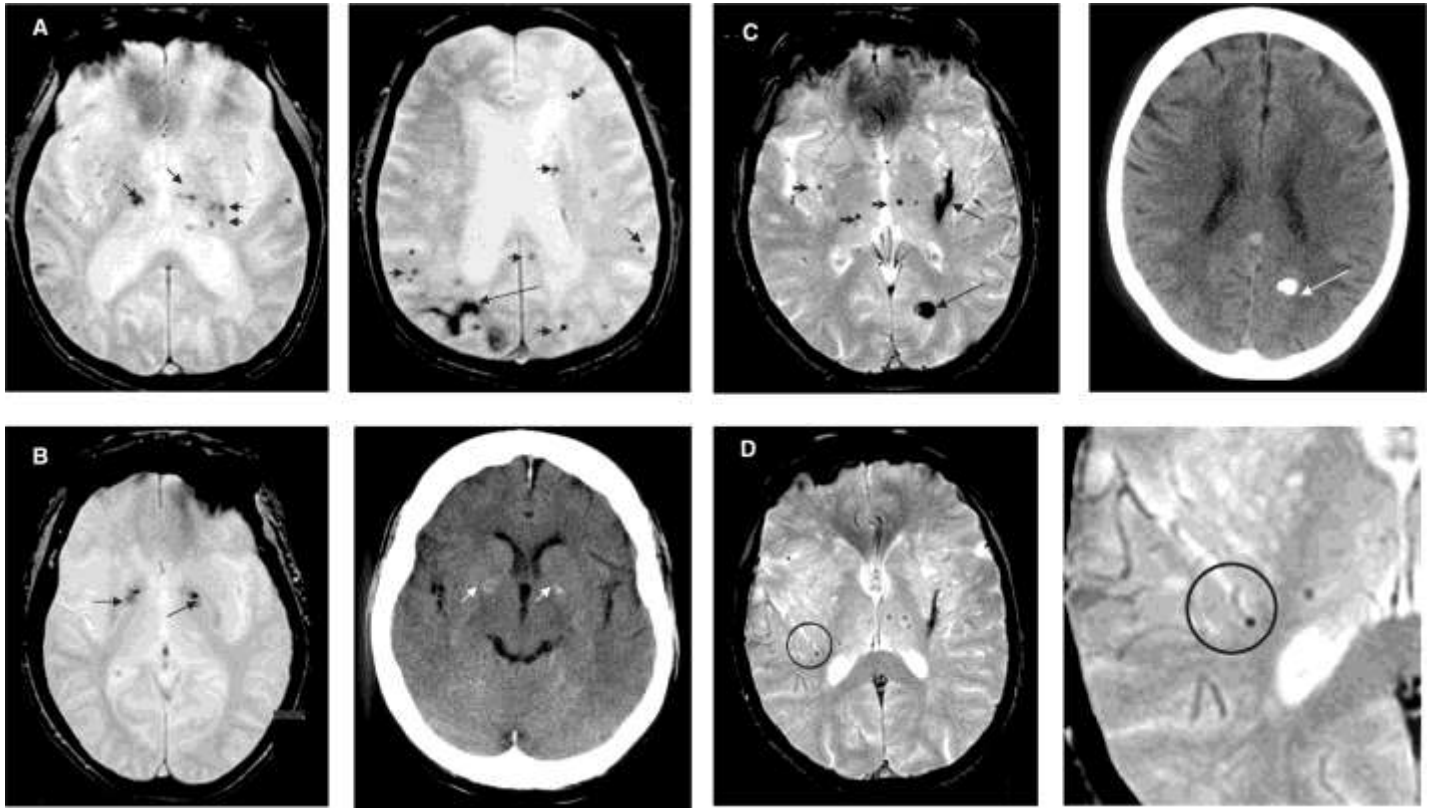

Brain microbleeds (BMBs) in arterial hypertension patient are seen as small, homogeneous, round foci of low signal intensity on magnetic resonance imaging gradient echo (GRE) T∗2 sequences

http://d1gqps90bl2jsp.cloudfront.net/content/brain/130/8/1988/F1.large.jpg http://ehjcimaging.oxfordjournals.org/content/4/4/237

(Arterial) hypertension: chest x-ray

The x-ray chest is suggesting a definite LV enlargement

http://www.merckmanuals.com/professional/cardiovascular-disorders/hypertension/overview-of-hypertension#v932160

(Arterial) hypertension: indication for renal ultrasonography

- If urinalysis detects albuminuria (proteinuria), cylindruria, or microhematuria or if serum creatinine is elevated (≥ 1.4 mg/dL [124 µmol/L] in men; ≥ 1.2 mg/dL [106 µmol/L] in women), renal ultrasonography to evaluate kidney size may provide useful information

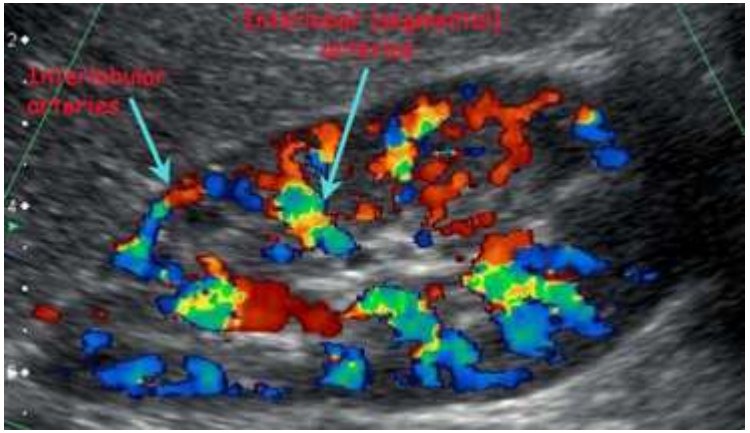

Normal renal arteries ultrasound.

http://www.merckmanuals.com/professional/cardiovascular-disorders/hypertension/overview-of-hypertension#v932160

Coronary insufficiency

Coronary insufficiency: definition, types

- Coronary insufficiency (CI) is the state in which an imbalance occurs between the oxygen supply and demand, which prevents adequate maintenance of the metabolic needs of the myocardium, resulting in ischemia of several degrees of intensity
- Types: acute (acute coronary syndrome), chronic (stable angina)

http:// http://highimpact.com/upload/project_headers/hr_MED07354-CORONARYINSUFFICIENCY.jpg http://www.scielo.br/scielo.php?script=sci_arttext&pid=S0066-782X1999000100002

Coronary insufficiency : causes

- Atherosclerotic obstructive coronary insufficiency (Coronary Artery Disease - CAD) –main cause
- Cardiac valvular diseases (aortic stenosis)
- Hypertrophic cardiomyopathy
- Microvasculature diseases (diabetes mellitus, syndrome X)
- Anomalous origin of coronary arteries, and coronary fistulas

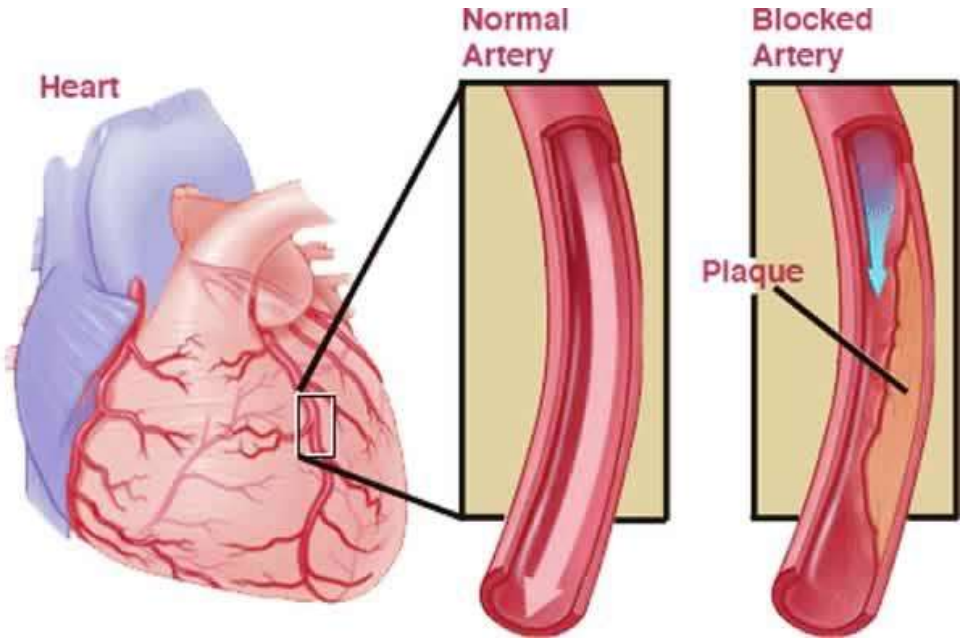

Coronary occlusion.

livemedical.net/images/coronary-artery-occlusion-due-to-plaque.jpg http://www.scielo.br/scielo.php?script=sci_arttext&pid=S0066-782X1999000100002

Coronary insufficiency: pathophysiology

The three fundamental components:

1. Endothelial dysfunction
2. Obstruction of the lumen of the vessel
3. Thrombosis at the location of the lesion

Any of the components could individually trigger coronary insufficiency , but they often occur at the same time

The decline of coronary reserve starts when lesions occupy at least 70% of the vessel diameter

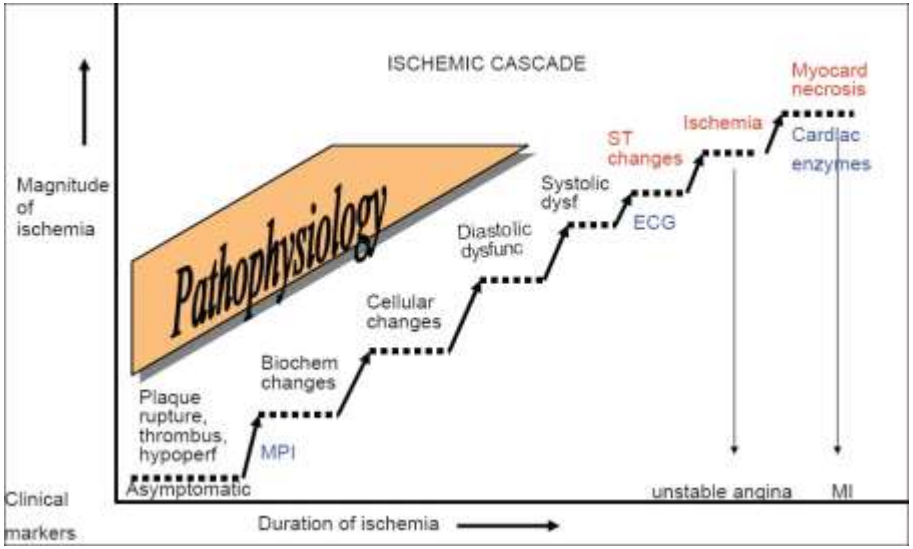

Depicts the myocardial ischemic cascade and stepwise changes, which occur at molecular and tissue level.

www.wjnm.org/article.asp?issn=1450-1147;year=2014;volume=13;issue=1;spage=6;epage=15;aulast=Padma
http://www.scielo.br/scielo.php?script=sci_arttext&pid=S0066-782X1999000100002

Coronary insufficiency: risk factors

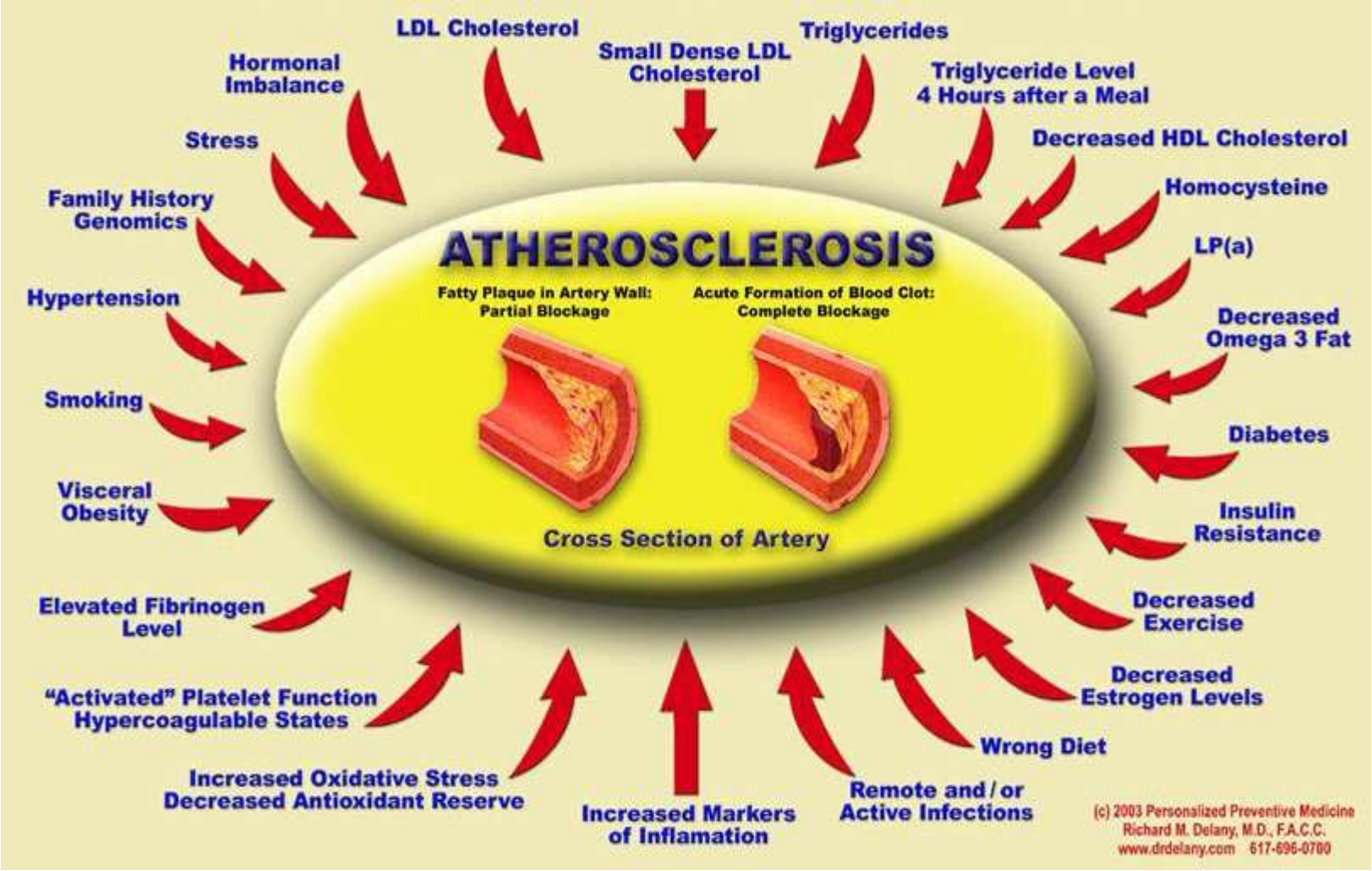

http://admin.itxpacks.com/pcpdelany/WebSite/MyImages/global-risk-powerpoint.modi_37.jpg

Coronary insufficiency: signs and symptoms

- Chest pain or discomfort
- Shortness of breath
- Heart failure
- Irregular heartbeat
- Nausea
- Sweating
- Decreased exercise tolerance
- Etc.

http://thumbs.dreamstime.com/z/heart-disease-symptoms-signs-coronary-artery-cad-ischemic-ihd-also-known-as-atherosclerotic-52190105.jpg

Coronary insufficiency: signs and symptoms (chest pain or discomfort)

But there is a disorder of the breast marked with strong and peculiar symptoms, considerable for the kind of danger belonging to it, and not extremely rare, which deserves to be mentioned more at length. The seat of it and the sense of strangling and anxiety with which it is attended, may make it not improperly be called angina pectoris. Those who are afflicted with it, are seized while they are walking (more especially if it be uphill, and soon after eating) with a painful and most disagreeable sensation in the breast, which seems as if it would extinguish life if it were to increase or to continue; but the moment they stand still, all this uneasiness vanishes. In all other respects, the patients are, at the beginning of this disorder, perfectly well, and in particular have no shortness of breath, from which it is totally different. The pain is sometimes situated in the upper part, sometimes in the middle, sometimes in the bottom of the os. sterni, and often more inclined to the left than to the right side. It likewise very frequently extends from the breast to the middle of the left arm.

WILLIAM HEBERDEN, 1772

https://melchiormeijer.files.wordpress.com/2011/12/f1-medium.gif http://www.epi.umn.edu/cvdepi/essay/william-heberden-on-angina-pectoris-1772/

Coronary insufficiency: signs and symptoms (chest pain or discomfort)

Nomenclature and Criteria for Diagnosis of Diseases of the Heart and Blood Vessels, 1953

In this syndrome the major symptom is thoracic pain, which is precipitated usually by effort but sometimes by excitement, a heavy meal or exposure to cold. The pain is usually substernal or just to the left of the sternum. Occasionally the pain is epigastric and in rare instances it may be localized in the neck or the left arm or shoulder. There is a tendency for the pain to radiate, most frequently to the left shoulder and arm and occasionally to the fingers. Less frequently it may radiate to the neck, jaw and teeth, to the back, upper abdomen, or to the right shoulder and arm. At times the pain will start at one of these points before focusing on the anterior surface of the chest. The intensity varies from a slight sense of heaviness to a severe crushing pain. Since the precipitating cause is commonly physical exertion, rest usually causes the pain to subside. The length of the episode, therefore, is relatively short. Occasionally an attack may come on while the patient is at rest or even when asleep. The pain is often accompanied by a sense of choking or inability to breathe which is also relieved by rest. The patient will often complain of flatulence as well. If the attack is not relieved by rest or a nitrite and lasts for an hour or more, and especially if it is accompanied by circulatory collapse, myocardial infarction should be strongly suspected. Occasionally the pain of myocardial infarction may be identical with the pain of the anginal syndrome. The associated symptomatology and the subsequent course will determine the diagnosis.

http://circ.ahajournals.org/content/21/6/1061.full.pdf

Coronary insufficiency: signs and symptoms (chest pain or discomfort)

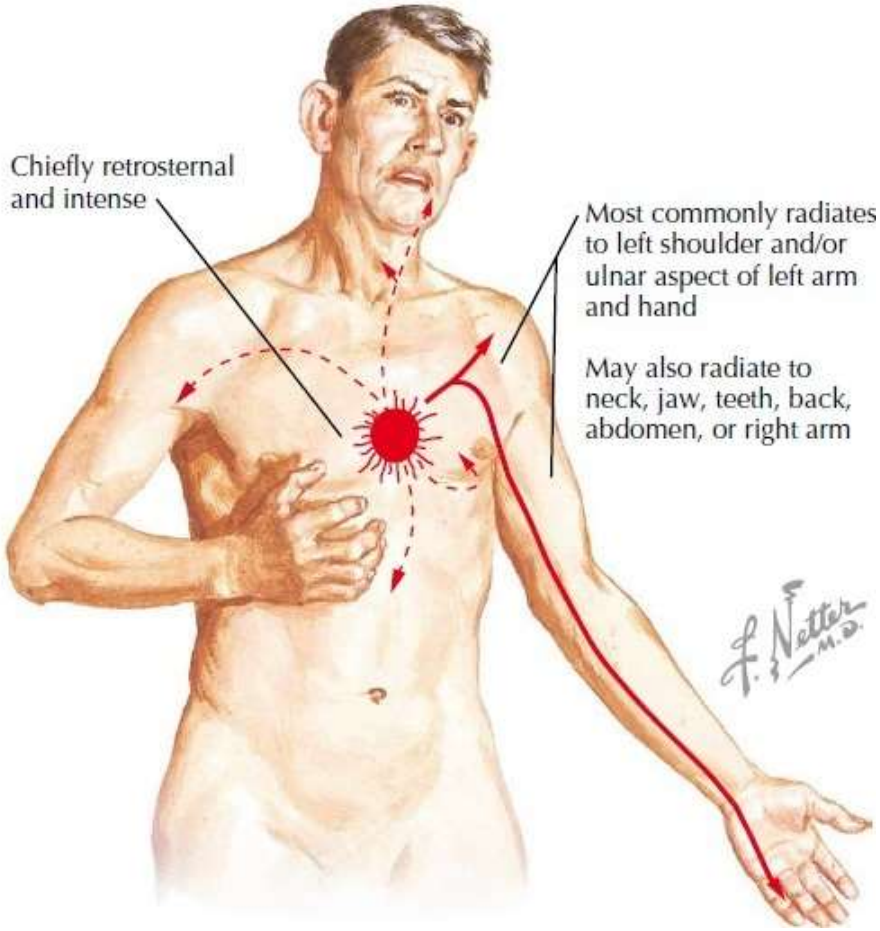

http://healthsciencedegree.info/heart-disease-chest-pain/

Coronary insufficiency: signs and symptoms (chest pain or discomfort)

Pain (Chest)		Cardiac	Pleuritic	Traumatic
D	Description: • Can you describe the pain to me? (You need to determine it's nature.) • Is it there all the time ? Does it come and go? • Have you ever had this pain before? • What was it that time?	• Heavy • Tight • Squeezing • Dull	• Sharp • Catching • Stabbing	• Sharp • Catching • Stabbing
O	Onset: • When did it start? • What were you doing at the time? • Did it come only suddenly or slowly?	• Gradual (Angina) • Sudden (UA/Infarct) • With exercise (Angina) • At Rest (UA/Infarct)	• Gradual (Infection) • Sudden (Pneumothorax)	• Gradual (post trauma) • Sudden (post trauma)
L	Location: • "Take one finger and point to the pain? • "Does it extend anywhere else" • If well localised palpate and visualise	• Poorly localised • Chest to back to jaw • Rarely changes with palpation	• Well localised • Usually chest wall • Usually changes with palpation / ventilation	• Well defined • Usually chest wall • Changes with palpation / ventilation
O	Other Signs and Symptoms: • "Do you fell nauseous? • (If yes) "Have you vomited" • "Do you feel SOB?" • "Have you noticed palpitations?" • "What came first, the discomfort or the (OSS)?"	• SOB % • Diaphoresis % • Palpatations %	• SOB (on exertion) • Chest infection (pro dromal)	• SOB (on exertion)
R	Relief: • "Have you taken anything for the discomfort?" • (If yes) "Has it helped?" • "Does it usually?" • "Does taking a deep breath make the pain bet-ter, worse or no different?" • "Does moving make the pain better, worse or no	• Relieved with Nitrates (Angina) • Unrelieved with Nitrates (UA/Infarct) • Poor relief with NSAIDS • Poor relief with position	• Unrelieved with Nitrates • Mild relief with NSAIDS • Some relief with position	• Unrelieved with Nitrates • Mild relief with NSAIDS • Some relief with position

https://prehospitalresearcher.files.wordpress.com/2013/06/dolor-for-chest-pains-e1370077515315.png

Coronary insufficiency: signs and symptoms (shortness of breath)

A man experiences shortness of breath.

https://en.wikipedia.org/wiki/Coronary_artery_disease

Coronary insufficiency: signs and symptoms (heart failure)

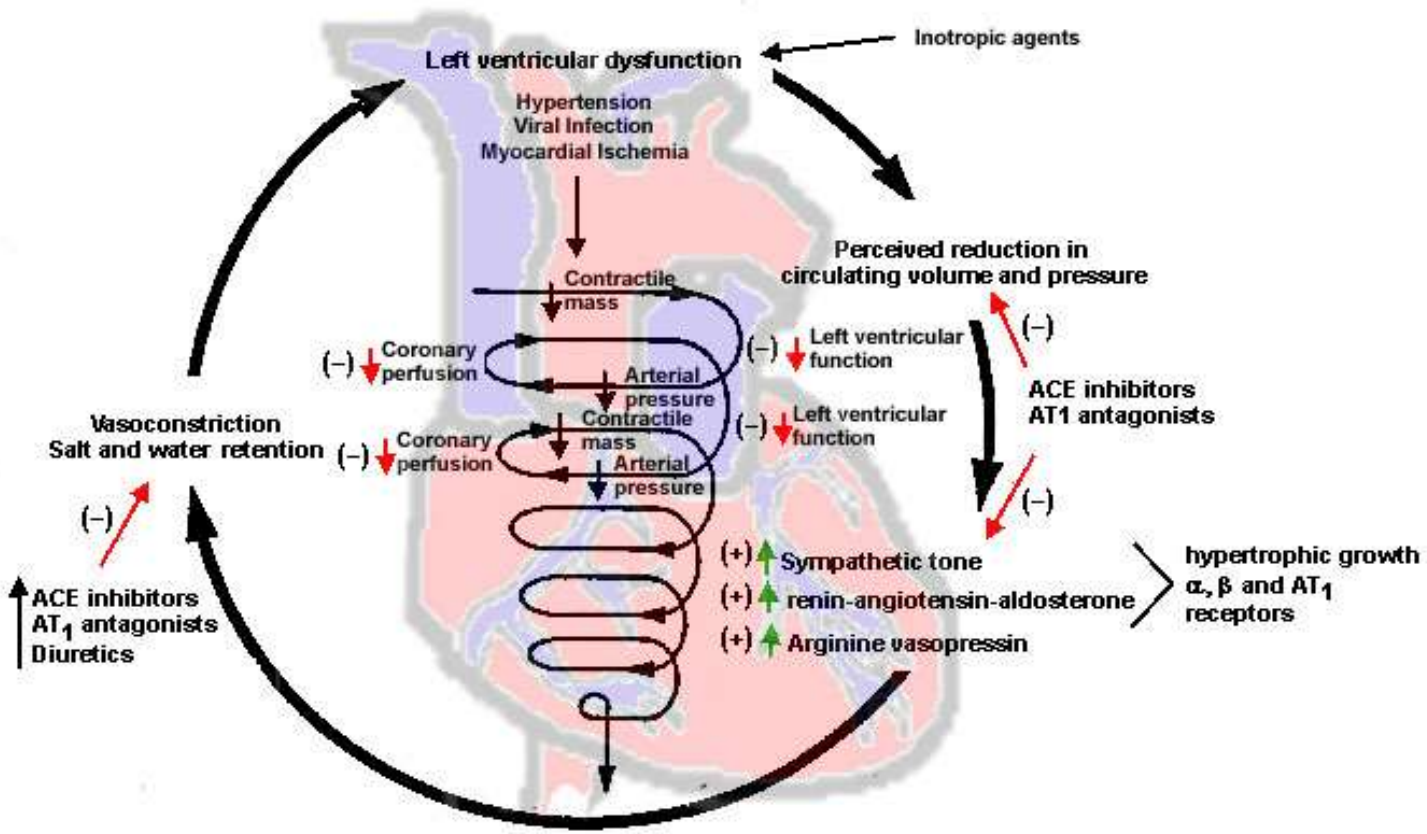

An overview of heart failure and its treatment.

http://www.uky.edu/~mtp/heartfailure/vcycle.jpg

Coronary insufficiency: signs and symptoms (irregular heartbeat)

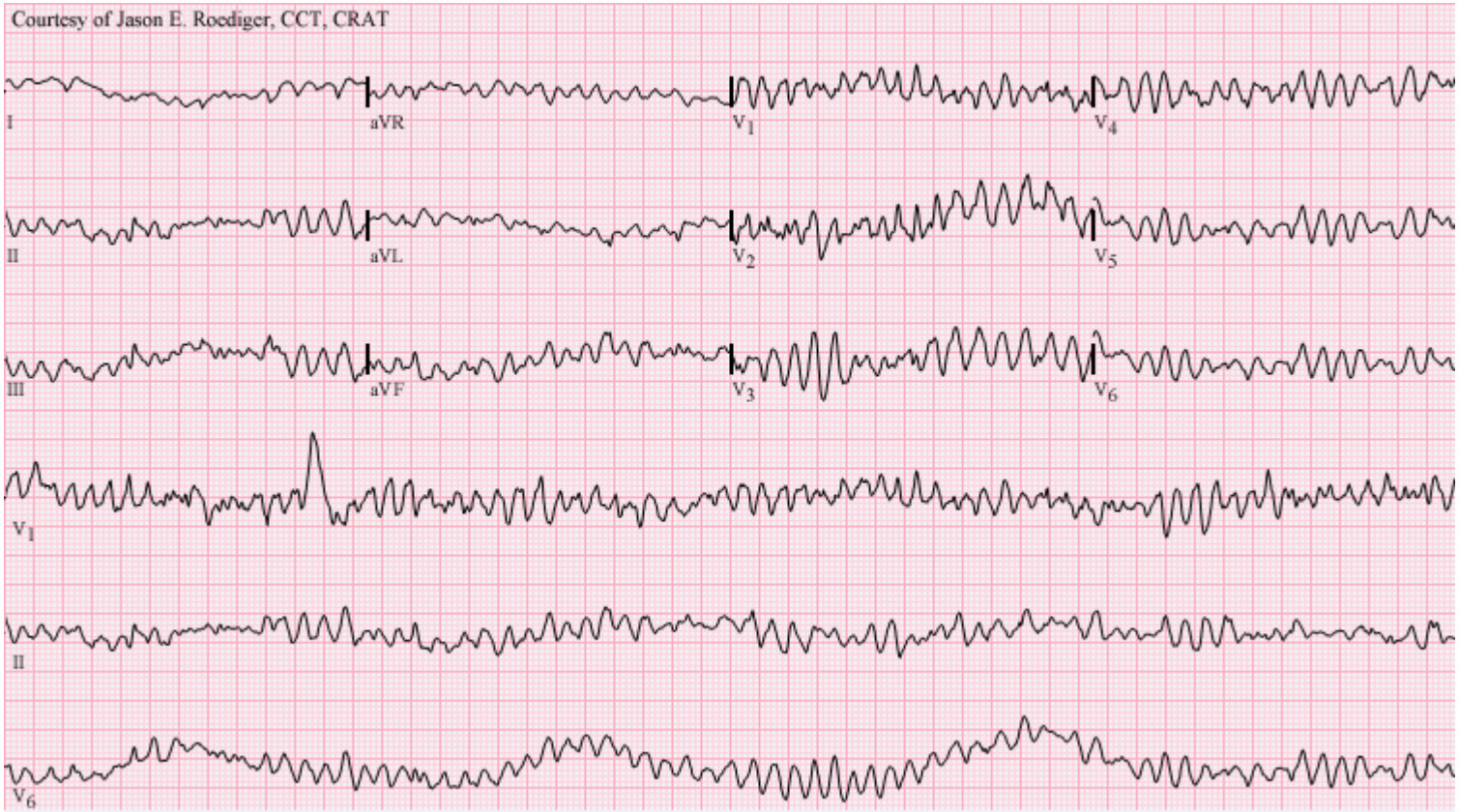

Ventricular fibrillation.

https://upload.wikimedia.org/wikipedia/commons/f/f1/Ventricular_fibrillation.png

Coronary insufficiency: signs and symptoms (nausea)

http://cdn1.medicalnewstoday.com/content/images/articles/290/290196/woman-curled-up-with-nausea.jpg

Coronary insufficiency: signs and symptoms (sweating)

http://images.medicinenet.com/images/slideshow/15-heart-symptoms-s13-businessman-in-cold-sweat.jpg

Coronary insufficiency : acute

- Acute coronary insufficiency (acute coronary syndrome (ACS)) refers to a group of conditions due to decreased blood flow in the coronary arteries such that part of the heart muscle is unable to function properly or dies
- These types are named according to the appearance of the electrocardiogram (ECG/EKG):
  - Non-ST segment elevation myocardial infarction (NSTEMI)
  - ST- segment elevation myocardial infarction (STEMI)
- Acute coronary insufficiency should be distinguished from stable angina, which develops during exertion and resolves at rest
- In contrast with stable angina, unstable angina occurs suddenly, often at rest or with minimal exertion, or at lesser degrees of exertion than the individual's previous angina ("crescendo angina")
- New onset angina is also considered unstable angina, since it suggests a new problem in a coronary artery

https://en.wikipedia.org/wiki/Acute_coronary_syndrome

Coronary insufficiency: chronic

- Chronic coronary insufficiency (stable angina (angina pectoris, angina)) is the sensation of chest pain, pressure, or squeezing, often due to ischemia of the heart muscle from obstruction or spasm of the coronary arteries
- The term derives from the Latin angere ("to strangle")
- There is a weak relationship between severity of pain and degree of oxygen deprivation in the heart muscle
- Worsening ("crescendo") angina attacks, sudden-onset angina at rest, new onset effort angina and angina lasting more than 15 minutes are symptoms of unstable angina (sudden-onset angina at rest and angina lasting more than 15 minutes usually grouped with similar conditions as the acute coronary syndrome)

https://en.wikipedia.org/wiki/Acute_coronary_syndrome

Coronary insufficiency: chronic (symptoms)

- Occurs when the heart must work harder, usually during physical exertion
- Doesn't come as a surprise, and episodes of pain tend to be alike
- Usually lasts a short time (5 minutes or less)
- Is relieved by rest or medicine
- May feel like gas or indigestion
- May feel like chest pain that spreads to the arms, back, or other areas
- May be associated with fear of dying

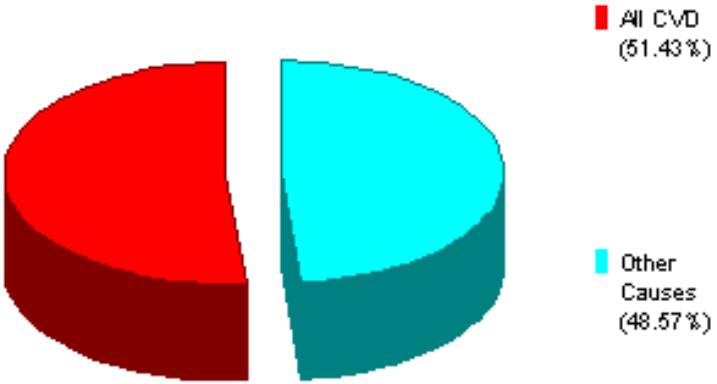

Other specified forms of chronic ischemic heart disease

http://www.varimed.hu/hypertension/dashlink/greece_elemei/GCVI50637683924GRP.gif
http://www.heart.org/HEARTORG/Conditions/HeartAttack/SymptomsDiagnosisofHeartAttack/Angina-Pectoris-Stable-Angina_UCM_437515_Article.jsp

Coronary insufficiency : syndromes (silent ischemia)

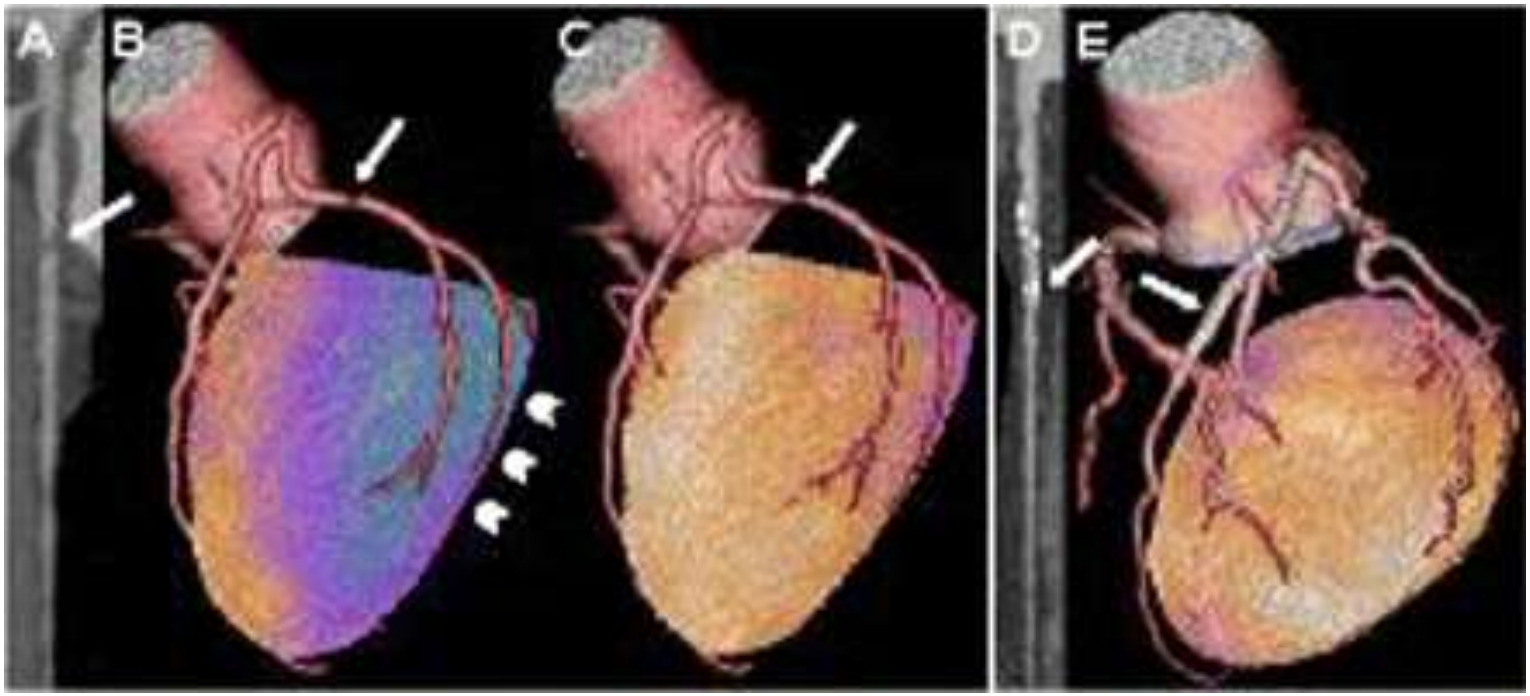

Patient with silent ischemia. Cardiac hybrid imaging integrating single-photon emission computed tomography with computed tomography coronary angiography.

http://eurheartjsupp.oxfordjournals.org/content/13/suppl_A/A1 http://

Coronary insufficiency: diagnosis

- Electrocardiography
- Stress test
- Echocardiography (including stress echocardiography and intravascular ultrasound)
- Coronary angiography
- Exercise radioisotope test (nuclear stress test, myocardial scintigraphy)
- Radioisotopes
- Magnetic resonance imaging
- Computed tomography
- Blood Test

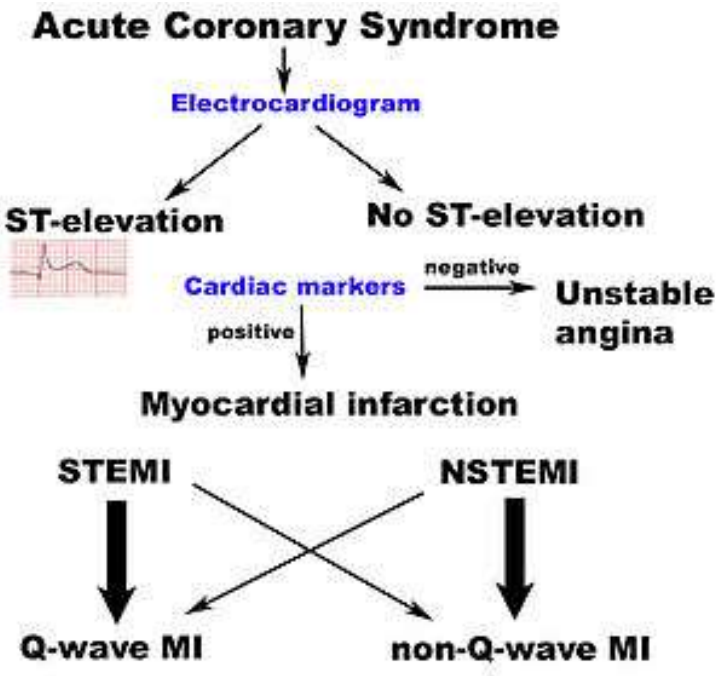

Diagnostics algorythm:
STEMI ST-elevation Myocardial Infarction,
NCTEMI – No ST-elevation Myocardial Infarction

https://upload.wikimedia.org/wikipedia/commons/thumb/e/e5/ACS_scheme.jpg/300px-ACS_scheme.jpg https://en.wikipedia.org/wiki/Coronary_artery_disease

Coronary insufficiency: diagnosis (electrocardiography)

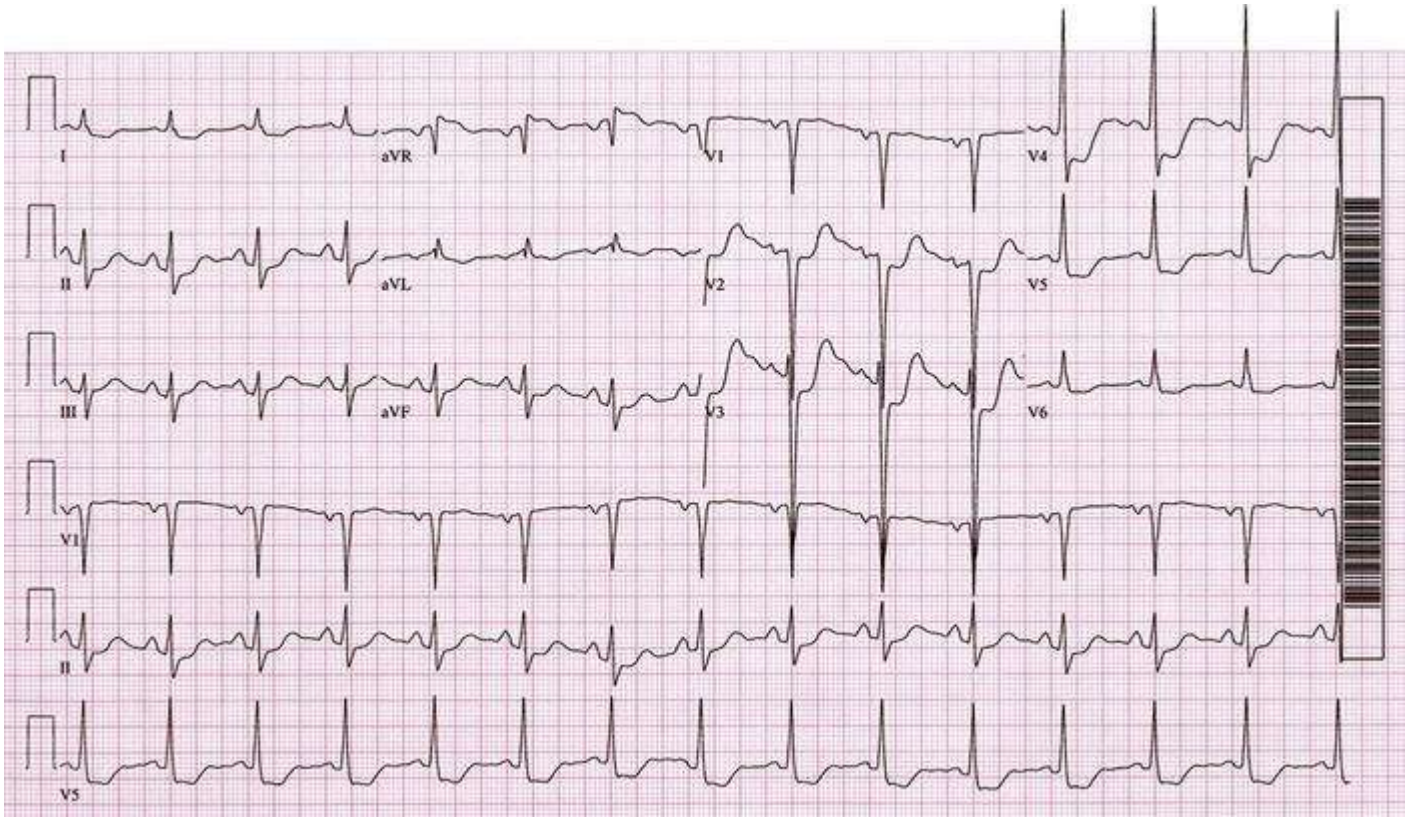

A 12-lead electrocardiograph of ischemic anterolateral ST-segment depression in a patient with known coronary artery disease.

http://emedicine.medscape.com/article/153647-overview

Coronary insufficiency: diagnosis (electrocardiography)

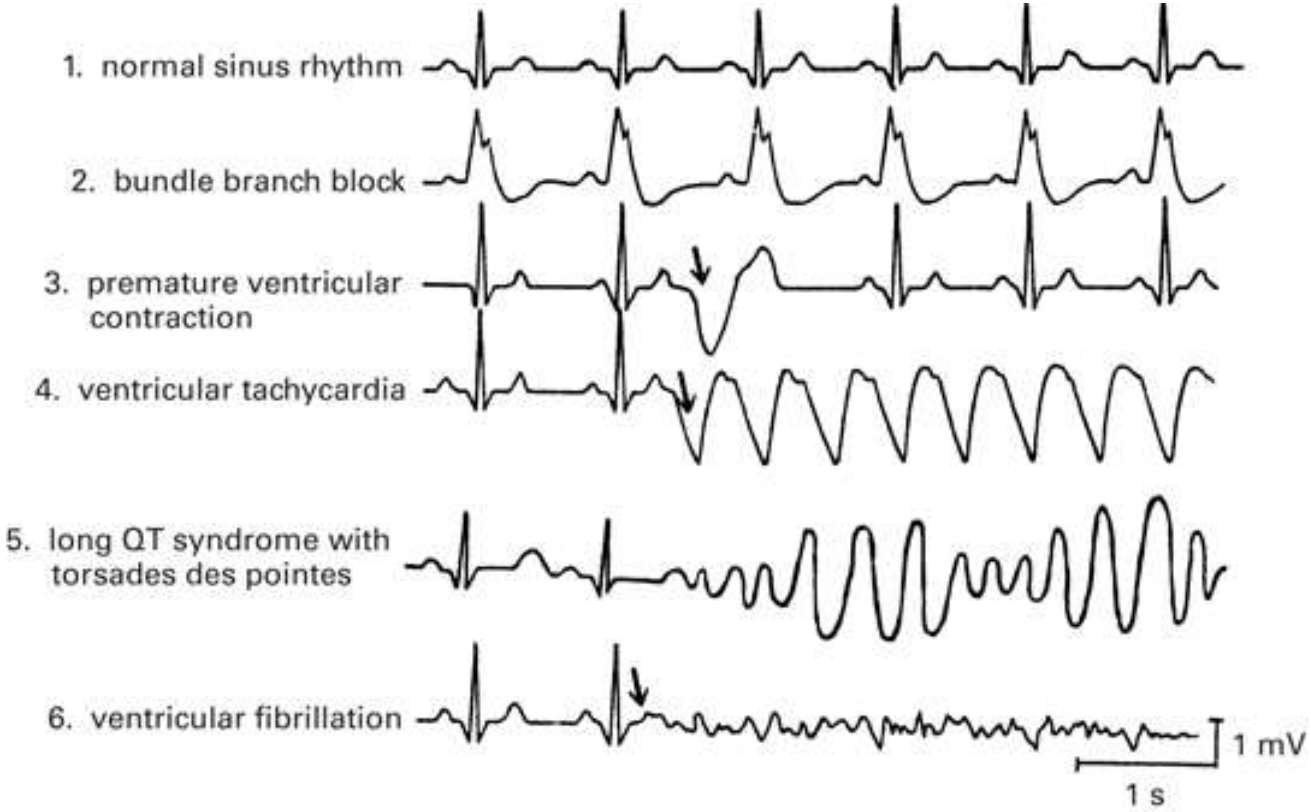

Ventricular arrhythmias.

http://flylib.com/books/4/5/1/html/2/05.%20print%20chapter%205_%20cardiac%20abnormalities_files/loadbinarycaprnv89.gif

Coronary insufficiency: diagnosis (electrocardiography)

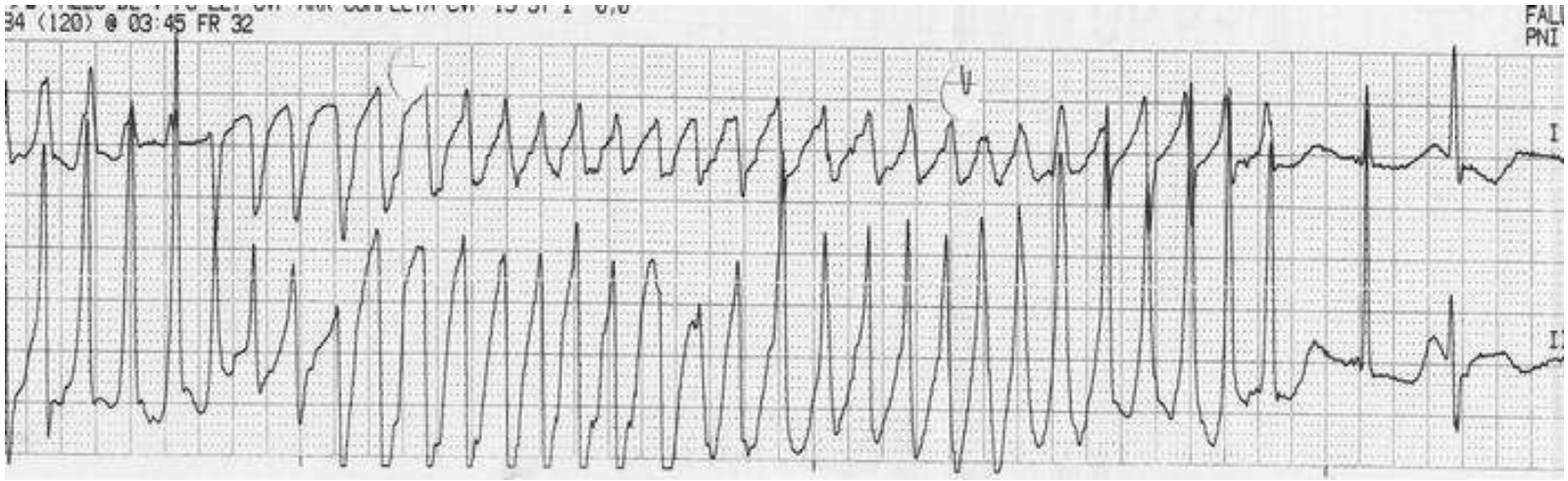

Polymorphic ventricular tachycardia in torsade de pointes.

http://www.revespcardiol.org/imatges/255/255v60n04/grande/255v60n04-13106381fig01.jpg

Coronary insufficiency: diagnosis (stress test)

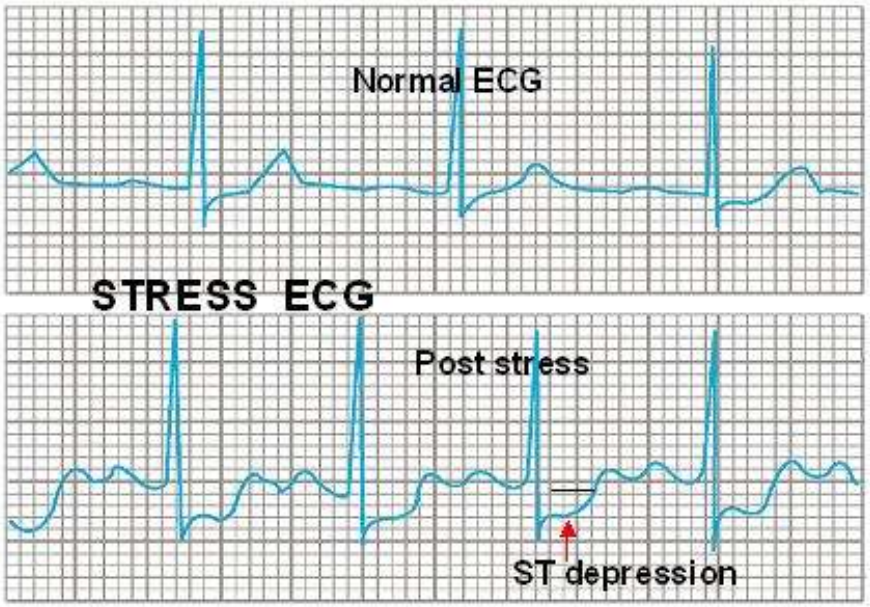

ST-segment depression confirms ischemia and positive stress test

https://edc2.healthtap.com/ht-staging/user_answer/reference_image/12066/large/stress_test.jpeg?1386670054
http://photos1.blogger.com/blogger/2473/2137/1600/stress.jpg http://www.revespcardiol.org/imatges/255/255v60n04/grande/255v60n04-13106381fig01.jpg

Coronary insufficiency: diagnosis (Canadian Cardiovascular Society Functional Classification of Angina Pectoris)

Class	Definition	Specific Activity Scale
I	Ordinary physical activity (eg, walking and climbing stairs) does not cause angina; angina occurs with strenuous, rapid, or prolonged exertion at work or recreation.	Ability to ski, play basketball, jog at 5 mph, or shovel snow without angina
II	Slight limitation of ordinary activity. Angina occurs on walking or climbing stairs rapidly, walking uphill, walking or stair climbing after meals, in cold, in wind, or under emotional stress, or only during the few hours after awakening, when walking more than 2 blocks on level ground, or when climbing more than 1 flight of stairs at a normal pace and in normal conditions.	Ability to garden, rake, roller skate, walk at 4 mph on level ground, have sexual intercourse without stopping
III	Marked limitation of ordinary physical activity. Angina occurs on walking 1 to 2 blocks on level ground or climbing 1 flight of stairs at a normal pace in normal conditions.	Ability to shower or dress without stopping, walk 2.5 mph, bowl, make a bed, play golf
IV	Inability to perform any physical activity without discomfort.	Anginal symptoms may be present at rest. Inability to perform activities requiring 2 or fewer metabolic equivalents without angina

http://www.clevelandclinicmeded.com/medicalpubs/diseasemanagement/cardiology/coronary-artery-disease/

Coronary insufficiency : diagnosis (echocardiography)

Left main stem coronary artery and proximal segment of left anterior descending coronary artery (LAD) in color-coded transthoracic Doppler echocardiography

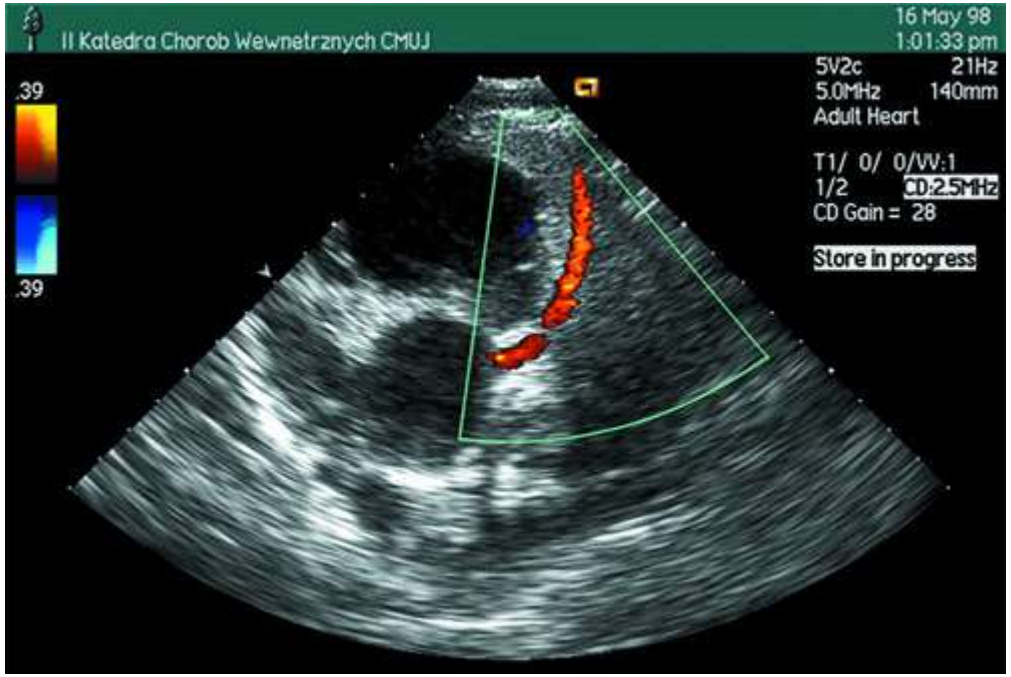

http://www.fac.org.ar/tcvc/llave/c307/dimitrow.htm

Coronary insufficiency : diagnosis (echocardiography)

- Direct visualization of coronary artery stenosis
- The portion of mid segment of left anterior descending coronary artery (LAD) with color mosaic (a sign of high-velocity, turbulent flow) at stenotic site

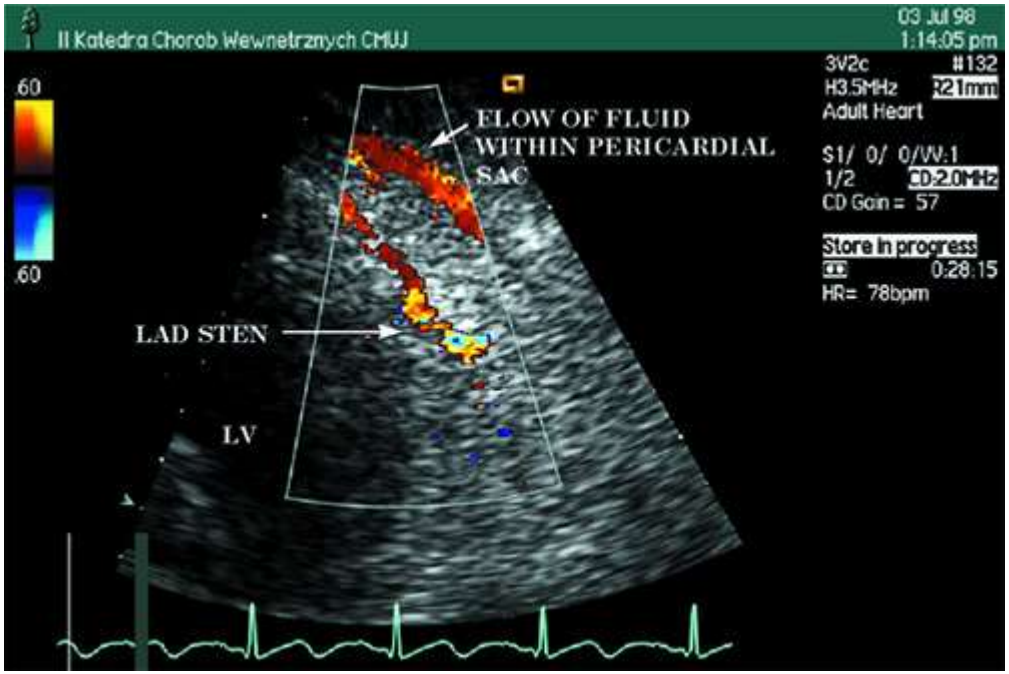

http://www.fac.org.ar/tcvc/llave/c307/dimitrow.htm

Coronary insufficiency : diagnosis (echocardiography)

- Echocardiography, parasternal short-axis view
- In presence of pericardial effusion, proximal part of right coronary artery (RCA) is suspicious for dissection (arrow). Imaging plane is off axis of nondilated RCA ostium

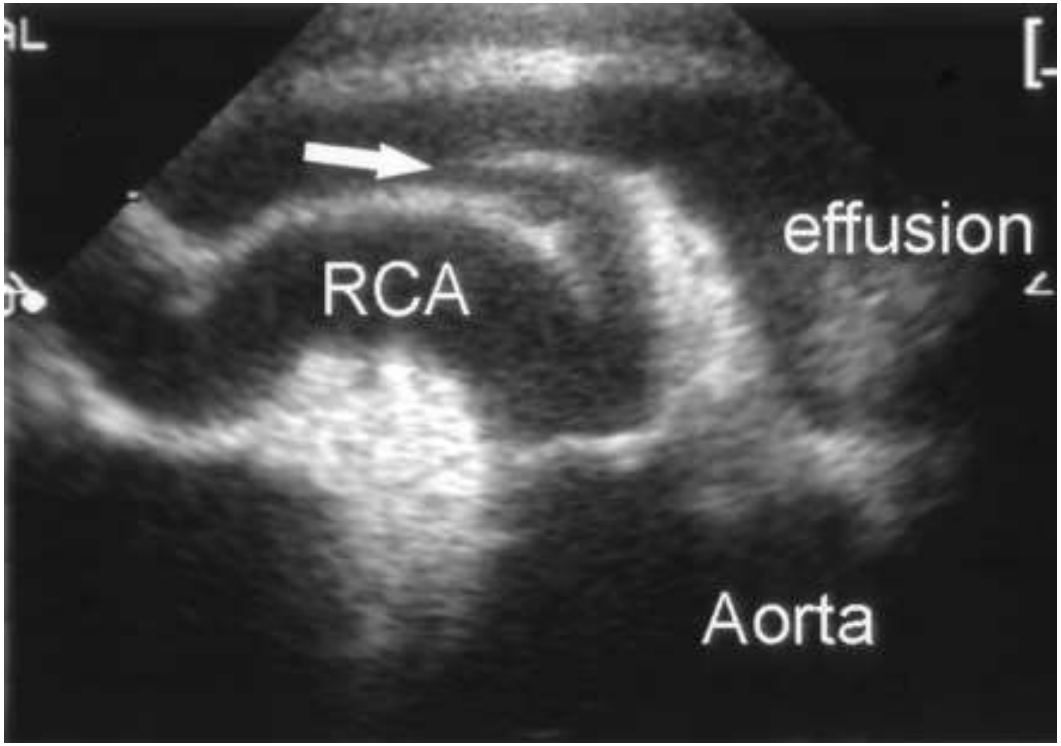

http://circ.ahajournals.org/content/111/24/e440/F2.expansion.html

Coronary insufficiency : diagnosis (echocardiography)

Contrast echocardiography in apical 4-chamber, 2-chamber and 3-chamber views (upper panels) demonstrating the extensive reduction of myocardial perfusion in a non ST-elevation myocardial infarction (NSTEMI) patient with angiographic trippel-vessel disease including acute occlusion of the right coronary artery and left main stem stenosis (lower panels)

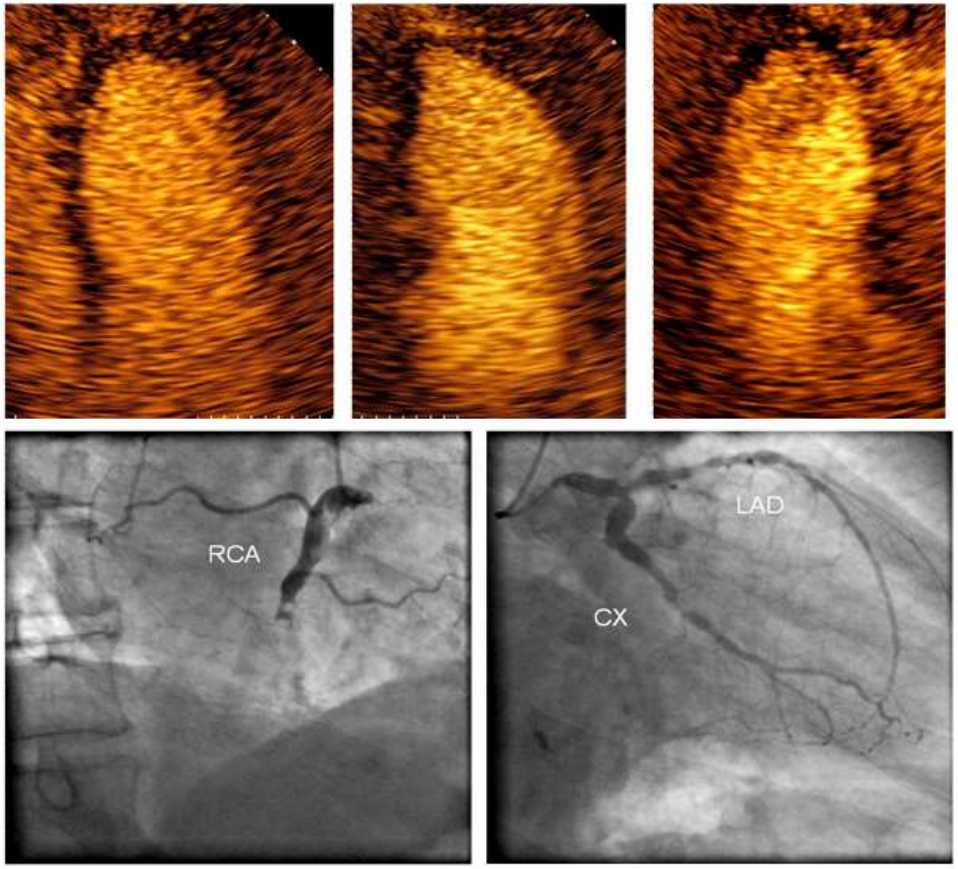

http://www.intechopen.com/source/html/18294/media/image8.png

Coronary insufficiency : diagnosis (stress echocardiography)

- Four-chamber diastolic (left) and systolic (right) apical frames at rest (top), peak (middle) and post-exercise (bottom) imaging in a patient with a history of previous inferior infarction and showed three-vessel disease on coronary angiography
- Rest regional wall motion was normal, whereas apical hypokinesia developed at peak exercise (asterisk) and had been resolved by the time post-exercise imaging was performed

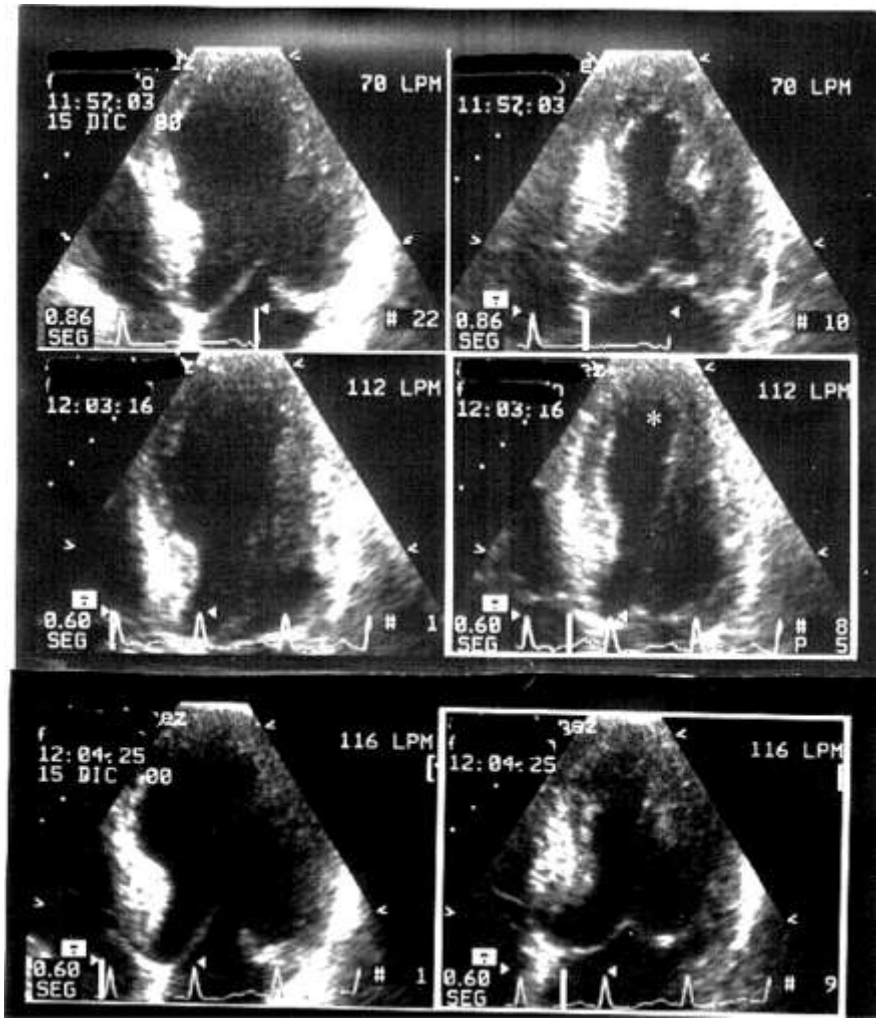

http://ehjcimaging.oxfordjournals.org/content/4/3/182

Coronary insufficiency : diagnosis (stress echocardiography)

- Two-chamber apical view of the same patient diastolic (left) and systolic (right) apical frames at rest (top), peak (middle) and post-exercise (bottom) imaging in a patient with a history of previous inferior infarction and showed three-vessel disease on coronary angiography
- Rest regional wall motion was normal, whereas apical hypokinesia developed at peak exercise (asterisk) and had been resolved by the time post-exercise imaging was performed

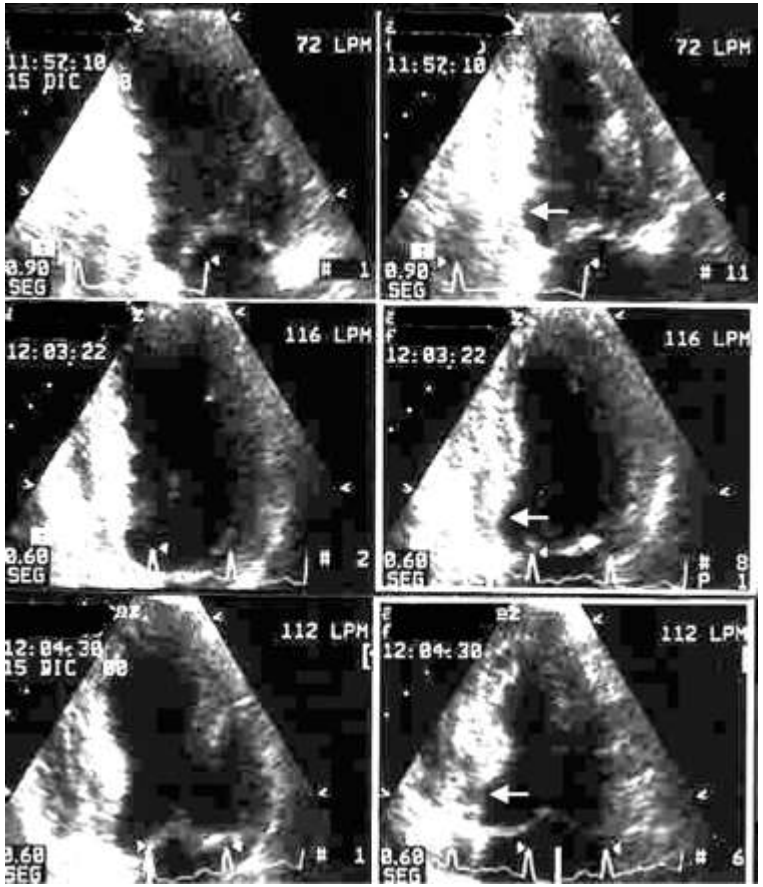

http://ehjcimaging.oxfordjournals.org/content/4/3/182

Coronary insufficiency : diagnosis (intravascular echocardiography)

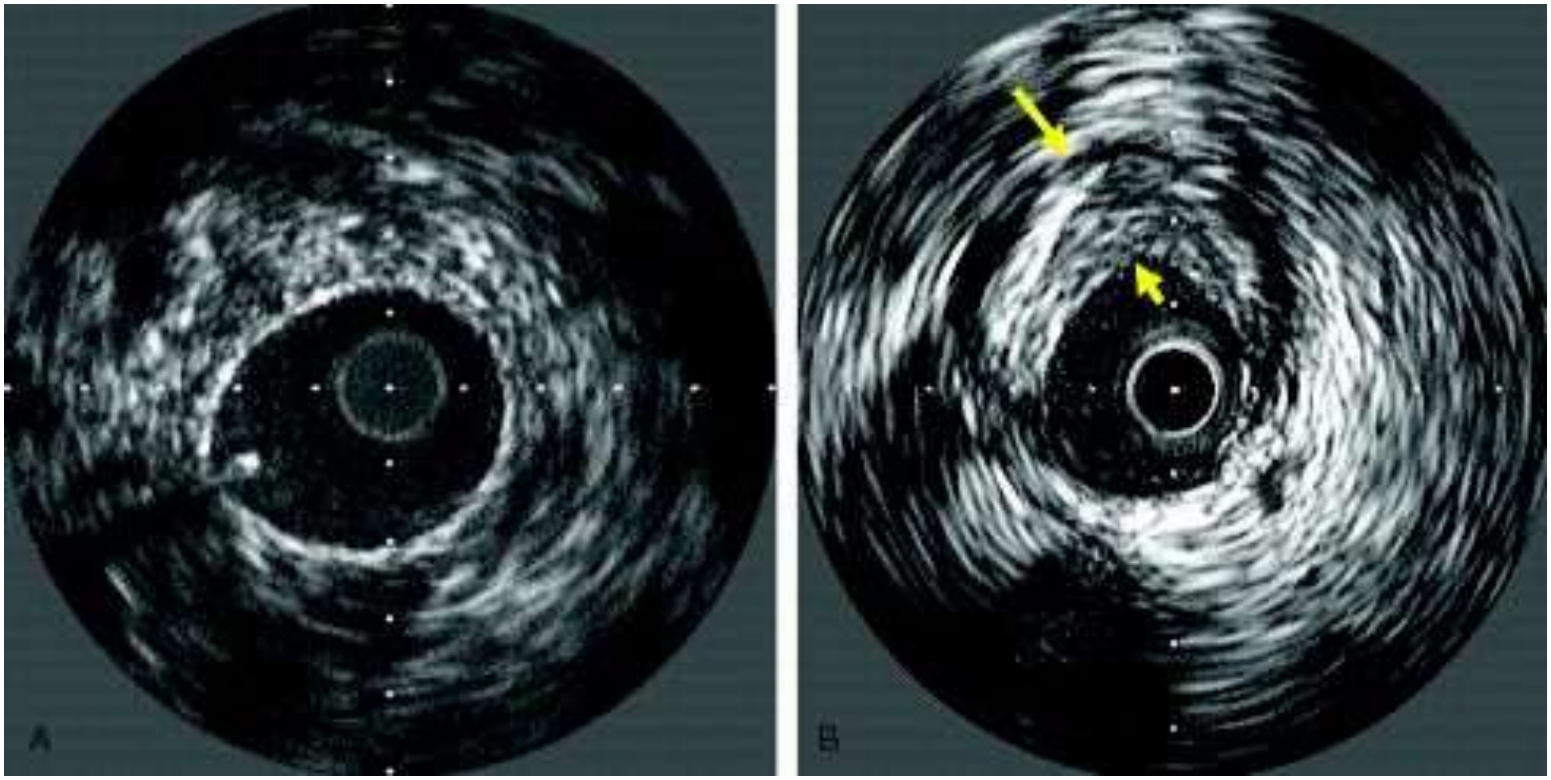

- Left - patient with normal coronaries
- Right - patient with increased coronary intimal thickness (1.2 mm; arrows), suggesting severe vasculopathy

http://www.clevelandclinicmeded.com/medicalpubs/diseasemanagement/cardiology/heart-transplantation/images/figure-3.jpg

Coronary insufficiency: diagnosis (coronary angiography)

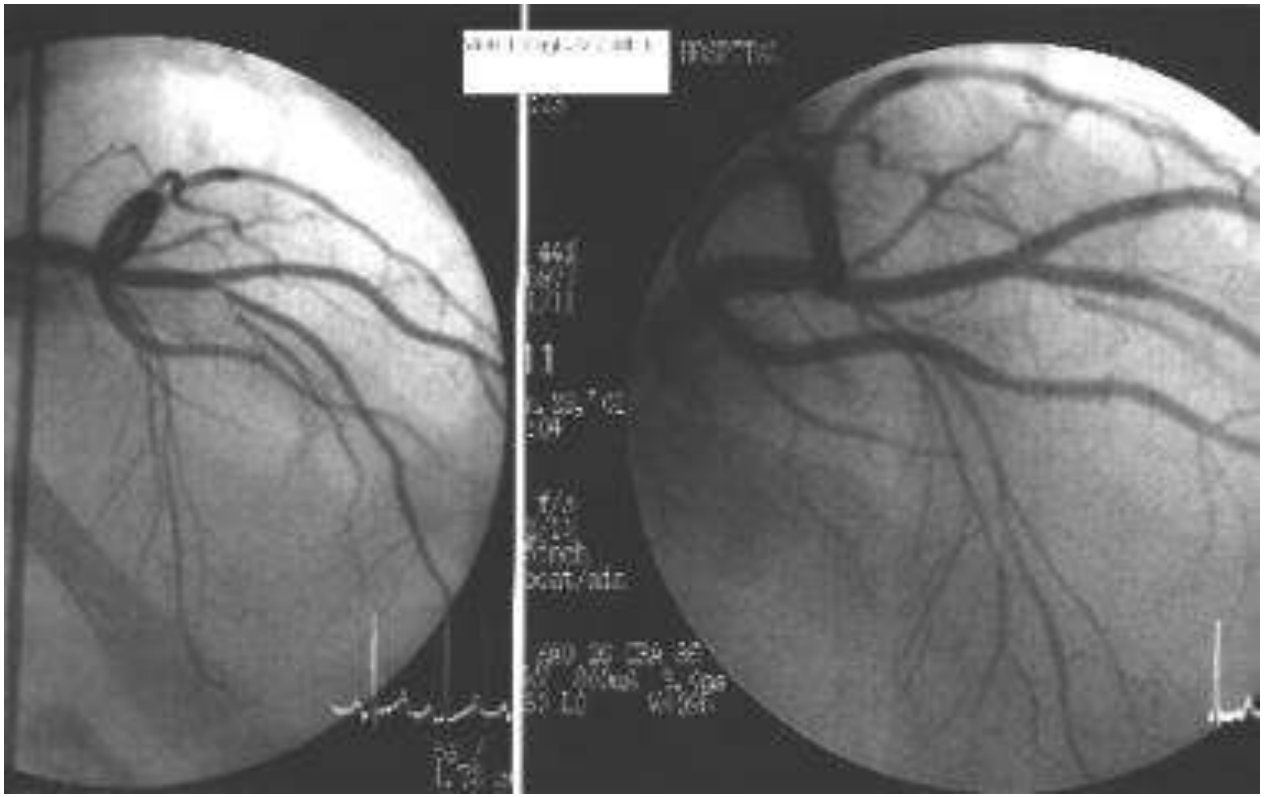

Cardiac catheterization and coronary angiography in the left panel shows severe left anterior descending coronary artery stenosis. This lesion was treated with stent placement in the left anterior descending coronary artery, as observed in the right panel.

http://emedicine.medscape.com/article/153647-overview

Coronary insufficiency : diagnosis (coronary angiography)

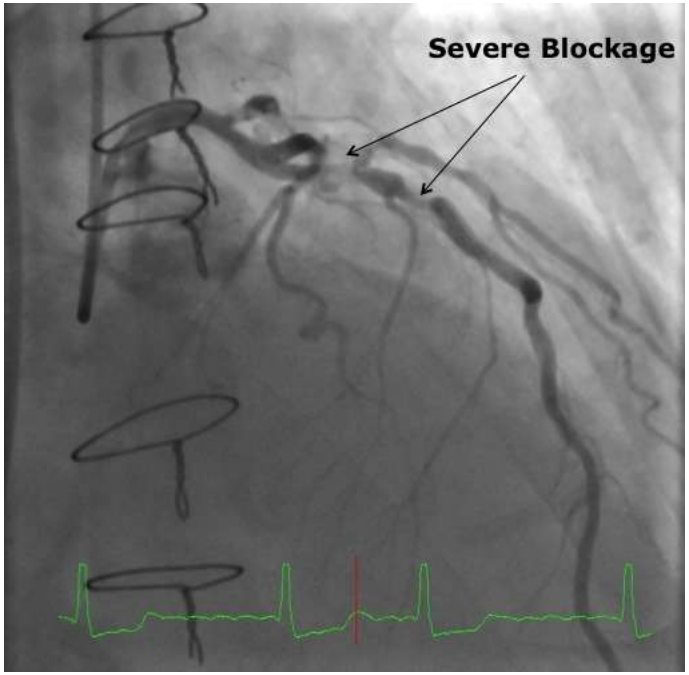

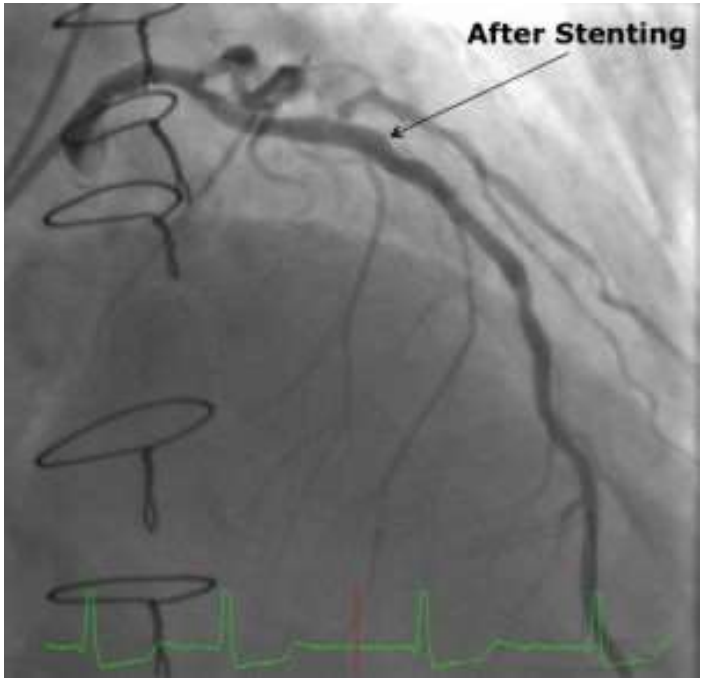

Single-vessel coronary artery disease

http://www.uvaphysicianresource.com/reoperative-cardiac-surgery/

Coronary insufficiency : diagnosis (coronary angiography)

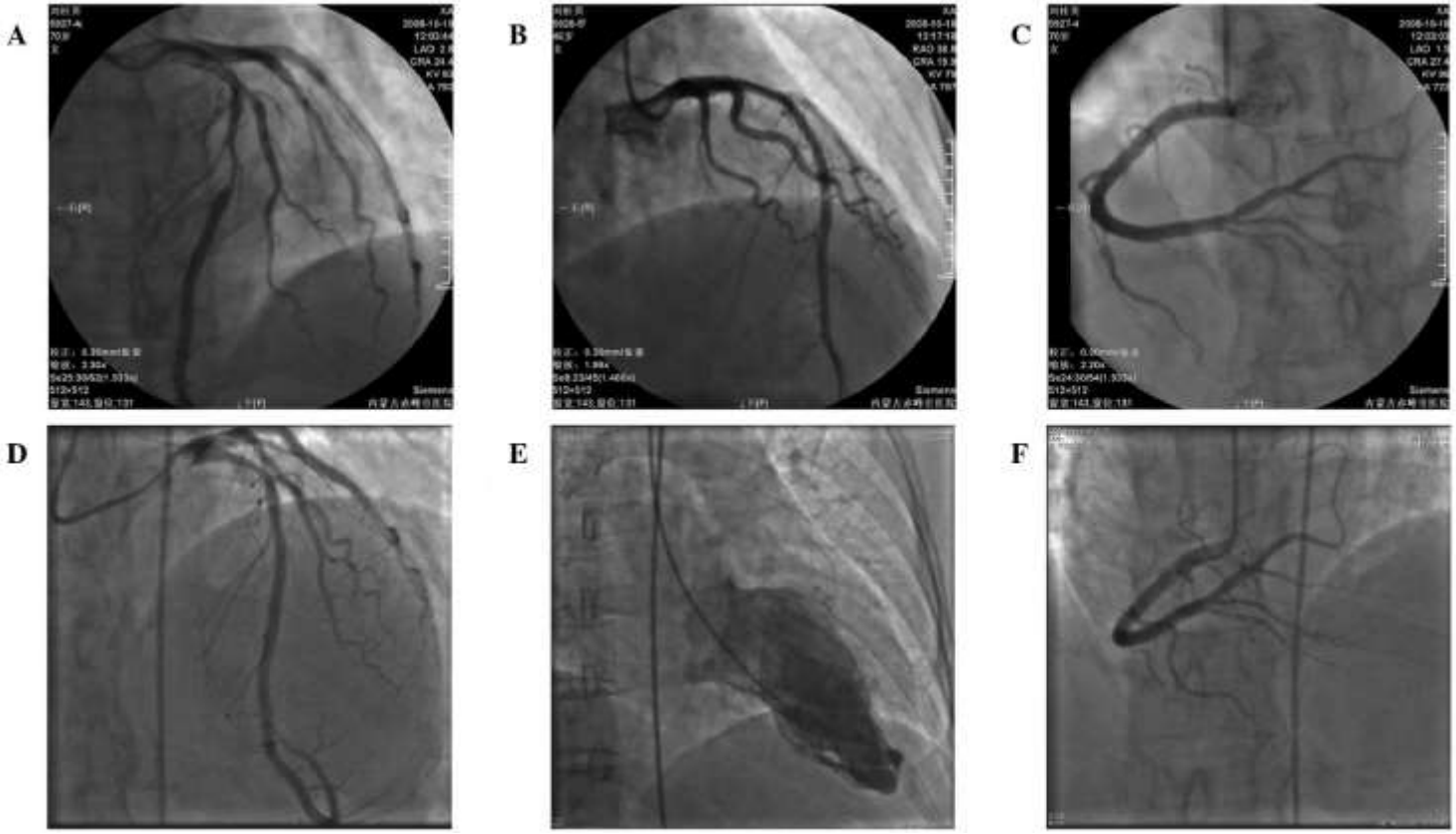

Coronary angiography of an essential thrombocythemia case with acute myocardial infarction. Examination results of the (A–C) first and (D–F) second time admissions.

http://www.spandidos-publications.com/etm/7/1/267

Coronary insufficiency: diagnosis (radioisotopes)

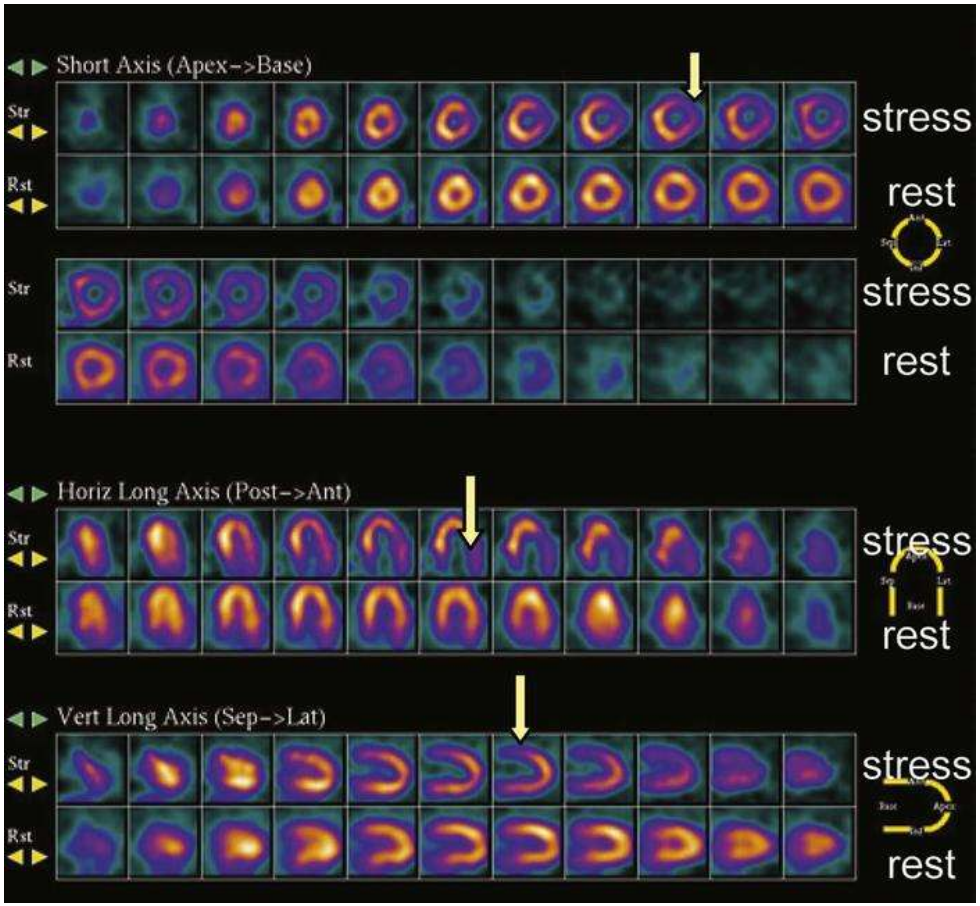

Myocardial perfusion scan. Stress images (arrows) demonstrate inferolateral and anterolateral (left circumflex) ischemia.

http://www.clevelandclinicmeded.com/medicalpubs/diseasemanagement/cardiology/coronary-artery-disease/

Coronary insufficiency : diagnosis (magnetic resonance imaging)

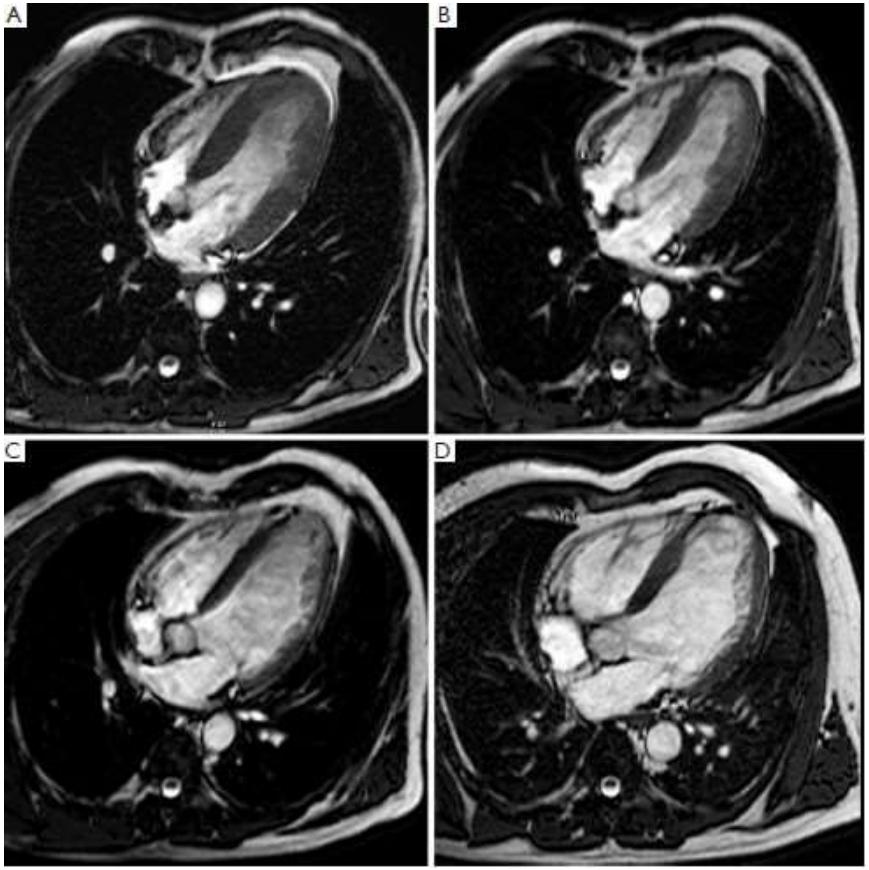

Ventricular remodeling post myocardial infarction.

http://www.thecdt.org/article/view/682/751

Coronary insufficiency : diagnosis (positron emission tomography)

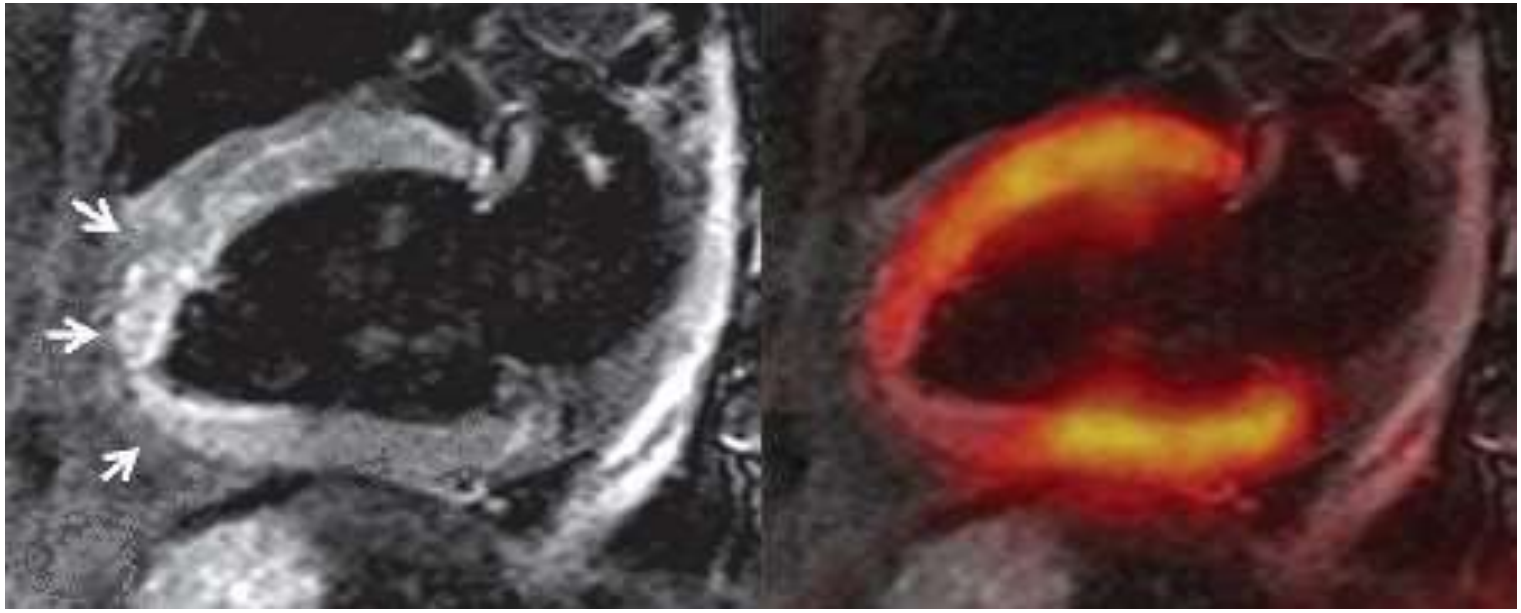

The infarct zone of the entire left ventricular myocardium.

http://pharmaceuticalintelligence.com/tag/magnetic-resonance-imaging/

Coronary insufficiency : diagnosis (computed tomography)

1. Mild proximal stenosis with expansive remodelling and predominantly nonexpansive plaque

2. Partially calcified advanced mid to distal stenosis

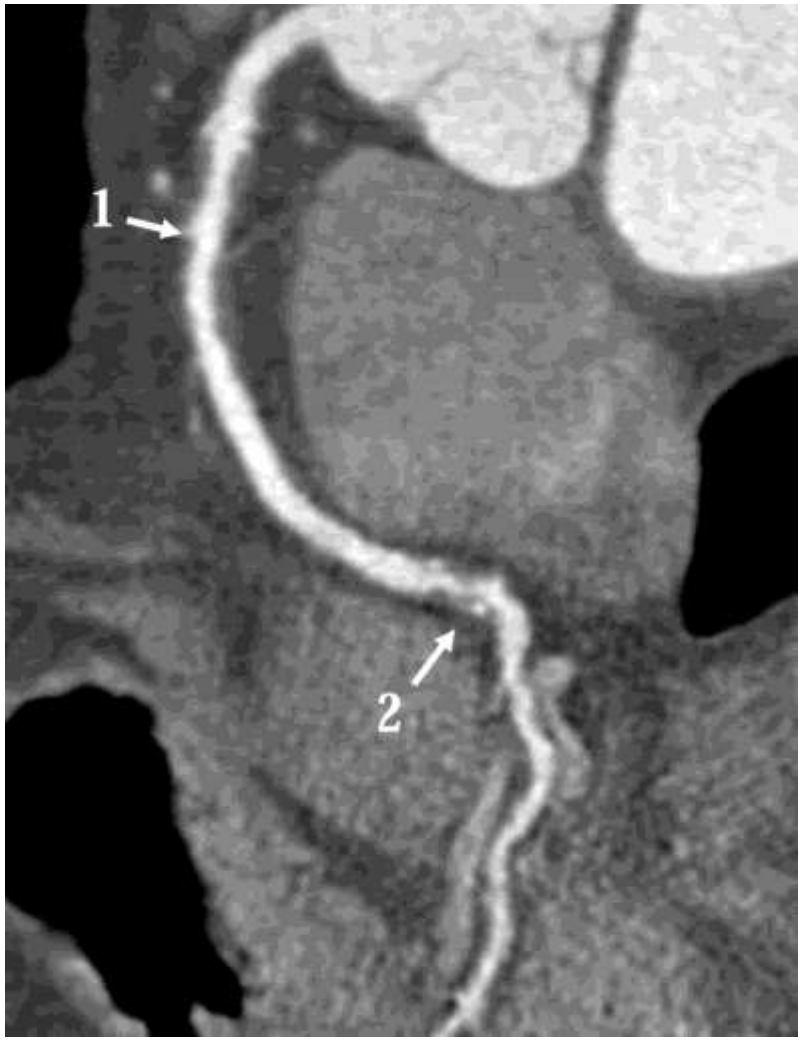

http://www.clevelandclinicmeded.com/medicalpubs/diseasemanagement/cardiology/coronary-artery-disease/

Coronary insufficiency : diagnosis (blood test)

Screening for risk of cardiovascular disease may include:

- Lipid profile (LDL-C,HDL-C, cholesterol, triglycerides)—a group of tests that examine the amount and type of lipids (fats) in the blood
- hs-CRP—detects low concentrations of C-reactive protein, a marker of inflammation that is associated with atherosclerosis, among other conditions
- Lp(a)—an additional lipid test that may be used to identify an elevated level of lipoprotein (a), a modification to LDL-C that increases risk of atherosclerosis; the test may be used in conjunction with a routine lipid profile to provide additional information

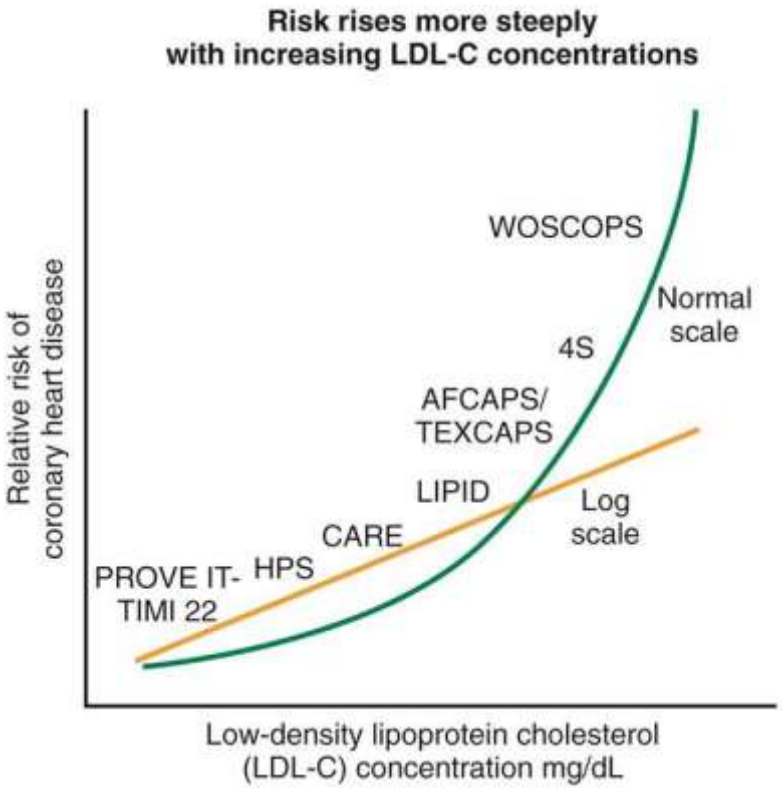

http://www.clevelandclinicmeded.com/medicalpubs/diseasemanagement/cardiology/heart-disease-risk-reduction/images/figure-1-ldl-c.jpg
https://labtestsonline.org/understanding/conditions/heart/start/3

Coronary insufficiency : diagnosis (blood test)

Heart attacks tests include:

- Troponin—the most commonly ordered and cardiac-specific of the markers; will be elevated within a few hours of heart damage and remain elevated for up to two weeks
- Myoglobin levels
- CK-MB—one particular form of the enzyme creatine kinase that is found mostly in heart muscle and rises when there is damage to the heart muscle cells; this test has largely been replaced with the troponin test

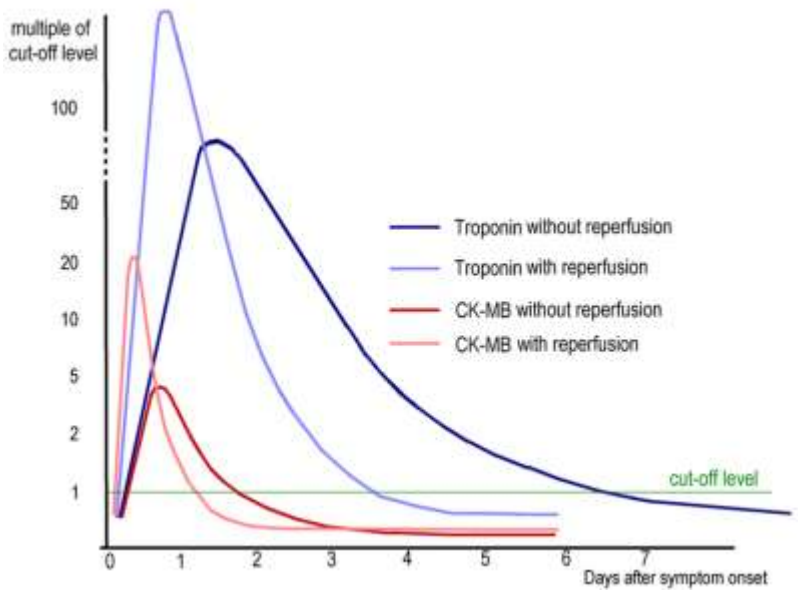

http://old.sinobiological.com/Elevated-Creatine-Kinase-a-5892.html http://old.sinobiological.com/Elevated-Creatine-Kinase-a-5892.html

Heart failure

Heart failure: definition

- Heart failure can be defined as an abnormality of cardiac structure or function leading to failure of the heart to deliver oxygen at a rate commensurate with the requirements of the metabolizing tissues, despite normal filling pressures (or only at the expense of increased filling pressures)
- HF is defined, clinically, as a syndrome in which patients have typical symptoms (e.g. breathlessness, ankle swelling, and fatigue) and signs (e.g. elevated jugular venous pressure, pulmonary crackles, and displaced apex beat) resulting from an abnormality of cardiac structure or function

http://kehatlab.net.technion.ac.il/files/2012/12/heart-failure-icon.jpg http://eurheartj.oxfordjournals.org/content/ehj/33/14/1787.full.pdf

Heart failure: pathophysiology

- In heart failure, the heart may not provide tissues with adequate blood for metabolic needs, and cardiac-related elevation of pulmonary or systemic venous pressures may result in organ congestion
- This condition can result from abnormalities of systolic or diastolic function or, commonly, both
- Although a primary abnormality can be a change in myocyte function, there are also changes in collagen turnover of the extracellular matrix

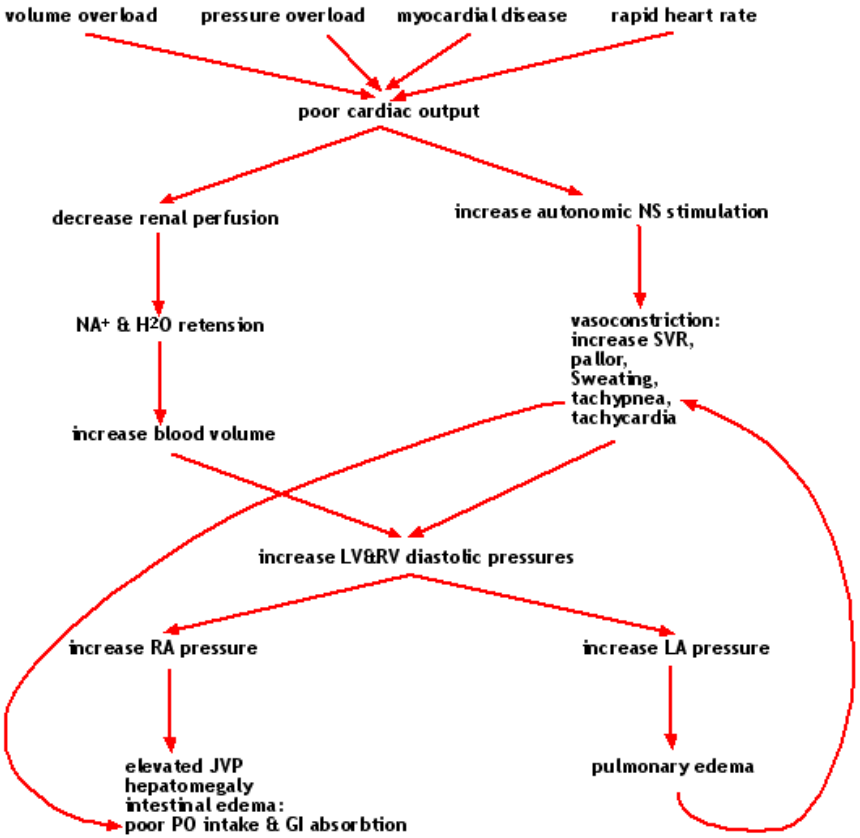

http://www.pedcard.rush.edu/MP/physiology/CHF%20physiology.gif http://www.merckmanuals.com/professional/cardiovascular-disorders/heart-failure/heart-failure-hf

Heart failure: pathophysiology

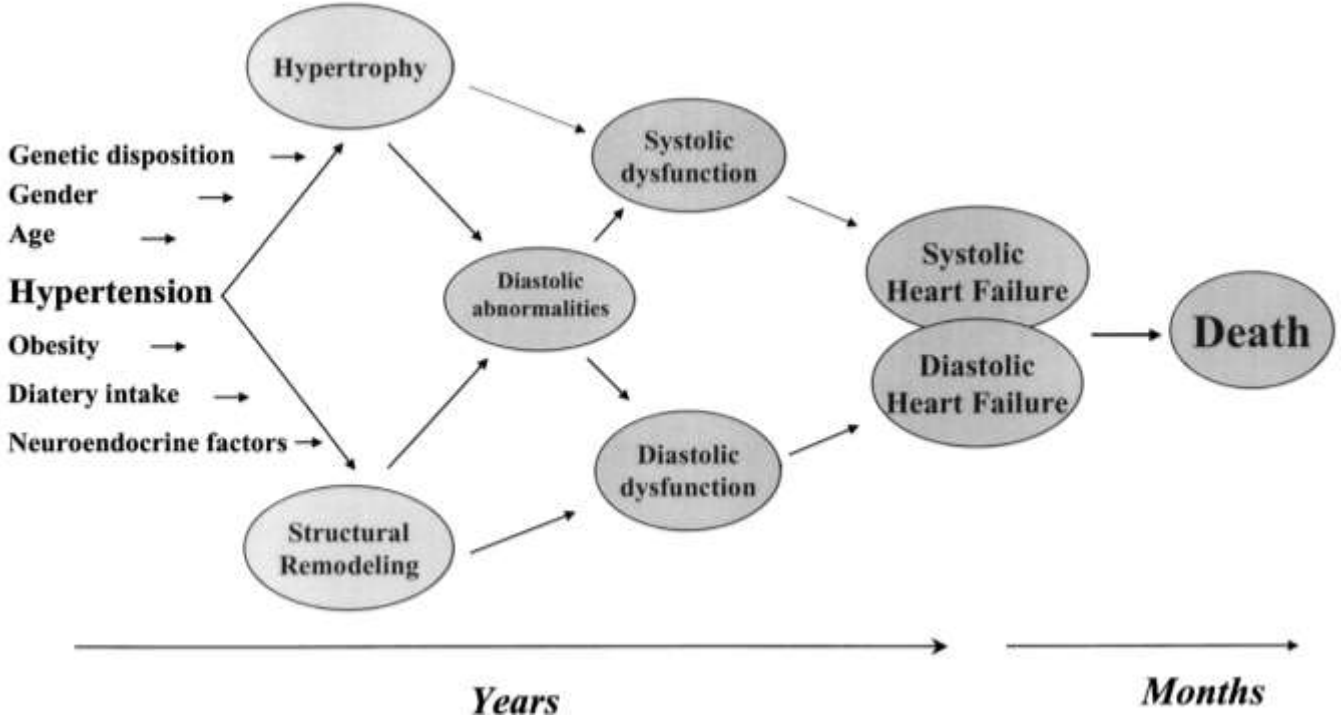

Progression from hypertrophy to diastolic heart failure. Several cardiovascular risk factors are associated with the occurrence of LV hypertrophy and structural remodeling. At the initial stage diastolic abnormalities are present with maintained systolic and diastolic function. During follow-up, systolic and diastolic dysfunction occur and are associated either systolic pump or diastolic filling failure. In the presence of congestive symptoms the time course of heart failure may become progressive and may end with sudden cardiac death or intractable end-stage failure.

http://cardiovascres.oxfordjournals.org/content/45/4/813

Heart failure:
systolic dysfunction

- In systolic dysfunction (heart failure (HF) with reduced ejection fraction (EF)), the ventricle contracts poorly and empties inadequately, leading initially to increased diastolic volume and pressure and decreased EF
- Many defects in energy utilization, energy supply, electrophysiologic functions, and contractile element interaction occur, with abnormalities in intracellular Ca modulation and cAMP production
- Predominant systolic dysfunction is common in HF due to MI, myocarditis, and dilated cardiomyopathy
- Systolic dysfunction may affect primarily the left ventricle (LV) or the right ventricle (RV)
- LV failure often leads to RV failure

http://www.merckmanuals.com/professional/cardiovascular-disorders/heart-failure/heart-failure-hf

Heart failure: systolic dysfunction

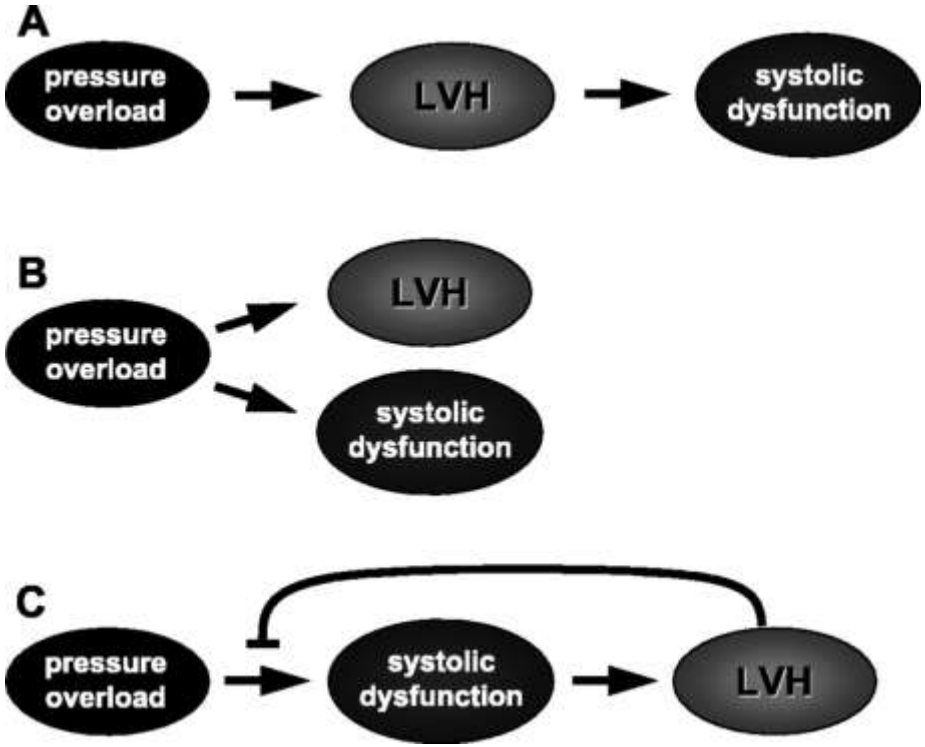

Left ventricular hypertrophy (LVH) and systolic dysfunction. *A*: LVH is a mechanistic step in the pathogenesis of load-induced systolic dysfunction. *B*: development of LVH occurs in parallel with systolic dysfunction. *C*: LVH is a compensatory response to stress-mediated systolic dysfunction.

http://ajpheart.physiology.org/content/289/1/H8 http://www.merckmanuals.com/professional/cardiovascular-disorders/heart-failure/heart-failure-hf

Heart failure: diastolic dysfunction

- In diastolic dysfunction (heart failure (HF) with preserved ejection fraction (EF), ventricular filling is impaired, resulting in reduced ventricular end-diastolic volume, increased end-diastolic pressure, or both
- Contractility and hence EF remain normal
- EF may even increase as the poorly filled LV empties more completely to maintain cardiac output (CO)
- Markedly reduced LV filling can cause low CO and systemic symptoms Elevated left atrial pressures can cause pulmonary hypertension and pulmonary congestion
- Diastolic dysfunction usually results from impaired ventricular relaxation (an active process), increased ventricular stiffness due to valvular disease, constrictive pericarditis, acute myocardial ischemia, hypertrophic cardiomyopathy, disorders with ventricular hypertrophy (e.g., hypertension, significant aortic stenosis), and amyloid infiltration of the myocardium.
- Resistance to filling increases with age, probably reflecting myocyte loss

http://www.merckmanuals.com/professional/cardiovascular-disorders/heart-failure/heart-failure-hf

Heart failure:
diastolic dysfunction

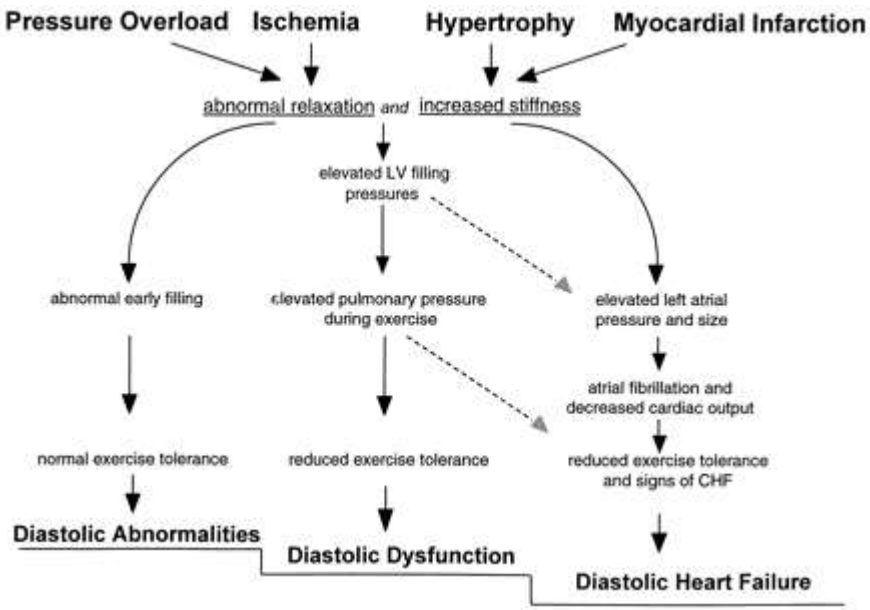

Pathophysiology of diastolic heart failure. Abnormal relaxation and increased stiffness are associated with diastolic filling abnormalities and normal exercise tolerance in the early phase of diastolic dysfunction. When the disease progresses, pulmonary pressures increase abnormally during exercise with reduced exercise tolerance. When filling pressures increases further, left atrial pressure and size increase and exercise tolerance falls with clinical signs of congestive heart failure (CHF).

http://cardiovascres.oxfordjournals.org/content/45/4/813

Heart failure:
left ventricle failure

- Cardiac output (CO) decreases and pulmonary venous pressure increases
- When pulmonary capillary pressure exceeds the oncotic pressure of plasma proteins (about 24 mm Hg), fluid extravasates from the capillaries into the interstitial space and alveoli, reducing pulmonary compliance and increasing the work of breathing
- Lymphatic drainage increases but cannot compensate for the increase in pulmonary fluid
- Marked fluid accumulation in alveoli (pulmonary edema) significantly alters ventilation/perfusion relationships
- In severe or chronic LV failure, pleural effusions characteristically develop in the right hemithorax and later bilaterally, further aggravating dyspnea

http://www.merckmanuals.com/professional/cardiovascular-disorders/heart-failure/heart-failure-hf

Heart failure:
left ventricle failure

Left ventricular injury leading to structural remodeling and dysfunction is the seminal event in the progression of heart failure

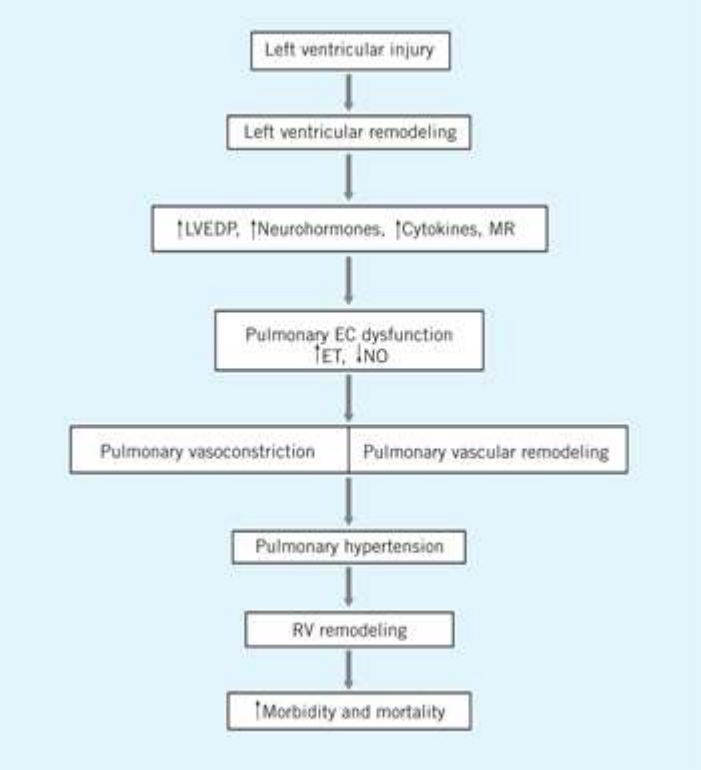

http://www.phaonlineuniv.org/Journal/Article.cfm?ItemNumber=657

Heart failure: right ventricle failure

- Systemic venous pressure increases, causing fluid extravasation and consequent edema, primarily in dependent tissues (feet and ankles of ambulatory patients) and abdominal viscera
- The liver is most severely affected, but the stomach and intestine also become congested
- Fluid accumulation in the peritoneal cavity (ascites) can occur
- Right ventricle failure commonly causes moderate hepatic dysfunction, with usually modest increases in conjugated and unconjugated bilirubin, hepatic enzymes, etc.
- The impaired liver breaks down less aldosterone, further contributing to fluid accumulation
- Chronic venous congestion in the viscera can cause anorexia, malabsorption of nutrients and drugs, protein-losing enteropathy (characterized by diarrhea and marked hypoalbuminemia), chronic GI blood loss, and rarely ischemic bowel infarction

http://www.merckmanuals.com/professional/cardiovascular-disorders/heart-failure/heart-failure-hf

Heart failure:
right ventricle failure

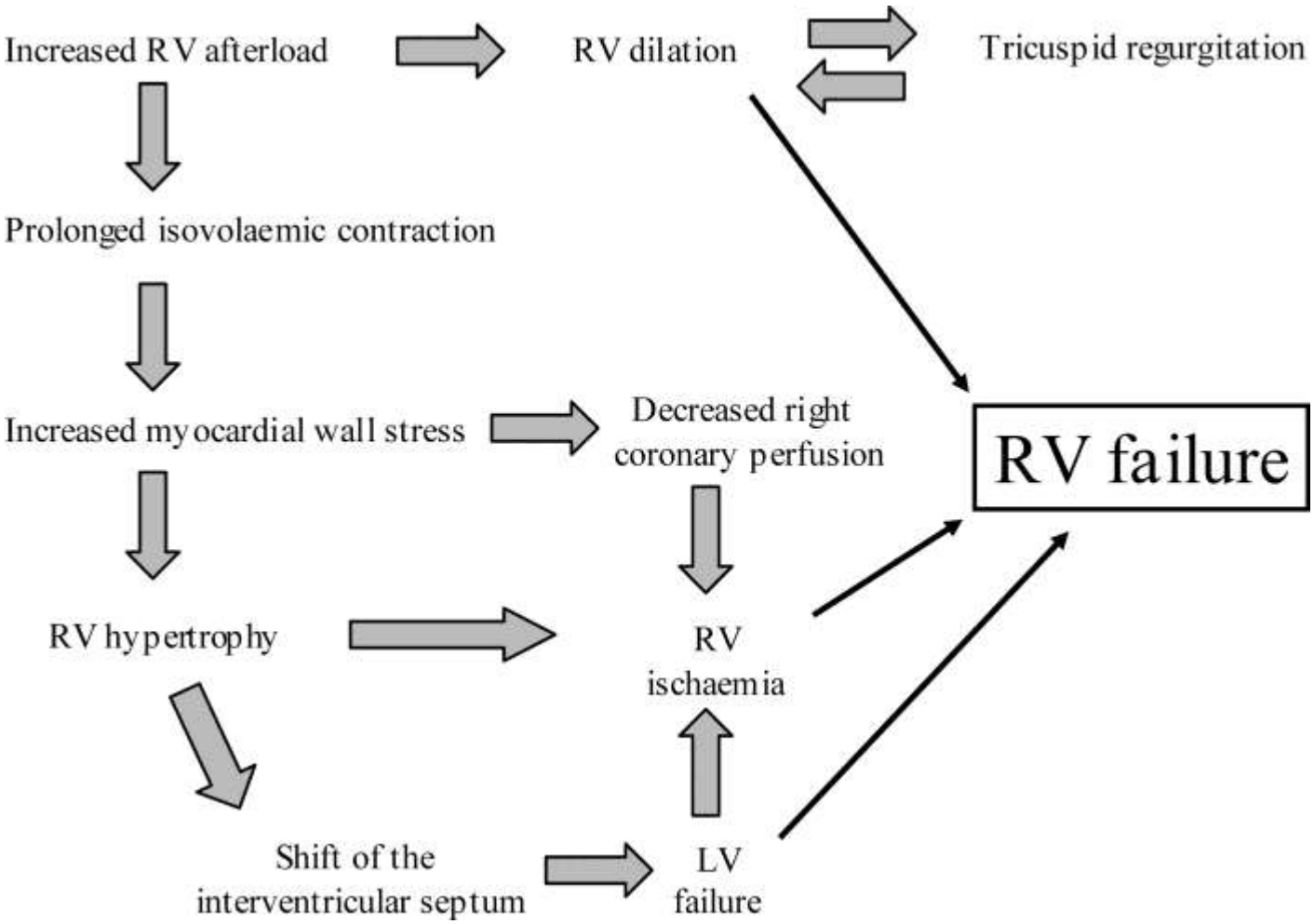

http://ceaccp.oxfordjournals.org/content/7/3/89/F2.large.jpg

Heart failure: cardiac response

- If ventricular function is impaired, a higher preload is required to maintain cardiac output (CO)
- The ventricles are remodeled over time: the left ventricle (LV) becomes less ovoid and more spherical, dilates, and hypertrophies; the right ventricle (RV) dilates and may hypertrophy.
- Initially compensatory, these changes eventually increase diastolic stiffness and wall tension (i.e., diastolic dysfunction develops), compromising cardiac performance, especially during physical stress
- Increased wall stress raises O_2 demand and accelerates apoptosis (programmed cell death) of myocardial cells
- Dilation of the ventricles can also cause mitral or tricuspid valve regurgitation with further increases in end-diastolic volumes

http://www.merckmanuals.com/professional/cardiovascular-disorders/heart-failure/heart-failure-hf

Heart failure: cardiac response

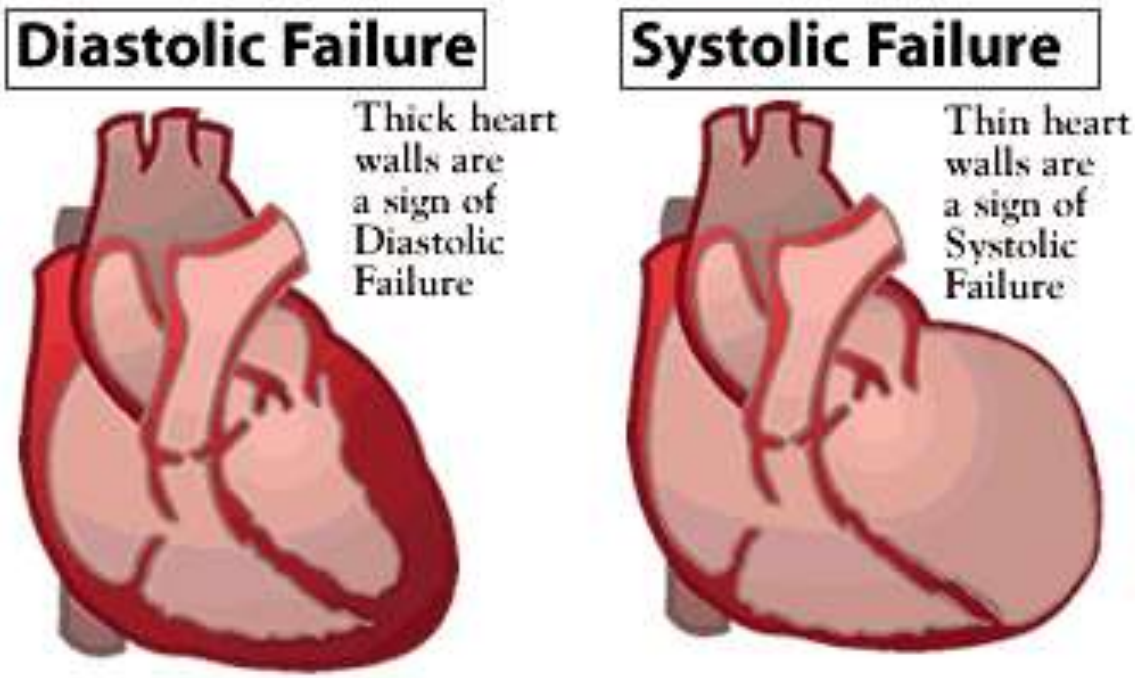

http://3.bp.blogspot.com/_m7f1iV3WaEI/TN5VdR38VNI/AAAAAAAAFP8/uPqLj-VEhtM/s400/dia_systolicheart.gif

Heart failure: hemodynamic responses

- With reduced cardiac output (CO), O_2 delivery to the tissues is maintained by increasing O_2 extraction and sometimes shifting the oxyhemoglobin dissociation curve to the right to favor O_2release
- Reduced CO with lower systemic blood pressure (BP) activates arterial baroreflexes, increasing sympathetic tone and decreasing parasympathetic tone
- Heart rate and myocardial contractility increase, arterioles in selected vascular beds constrict, venoconstriction occurs, and Na and water are retained
- These changes compensate for reduced ventricular performance and help maintain hemodynamic homeostasis in the early stages of heart failure (HF)
- These compensatory changes increase cardiac work, preload, and afterload; reduce coronary and renal perfusion; cause fluid accumulation resulting in congestion; increase K excretion; and may cause myocyte necrosis and arrhythmias

http://www.merckmanuals.com/professional/cardiovascular-disorders/heart-failure/heart-failure-hf

Heart failure: hemodynamic responses

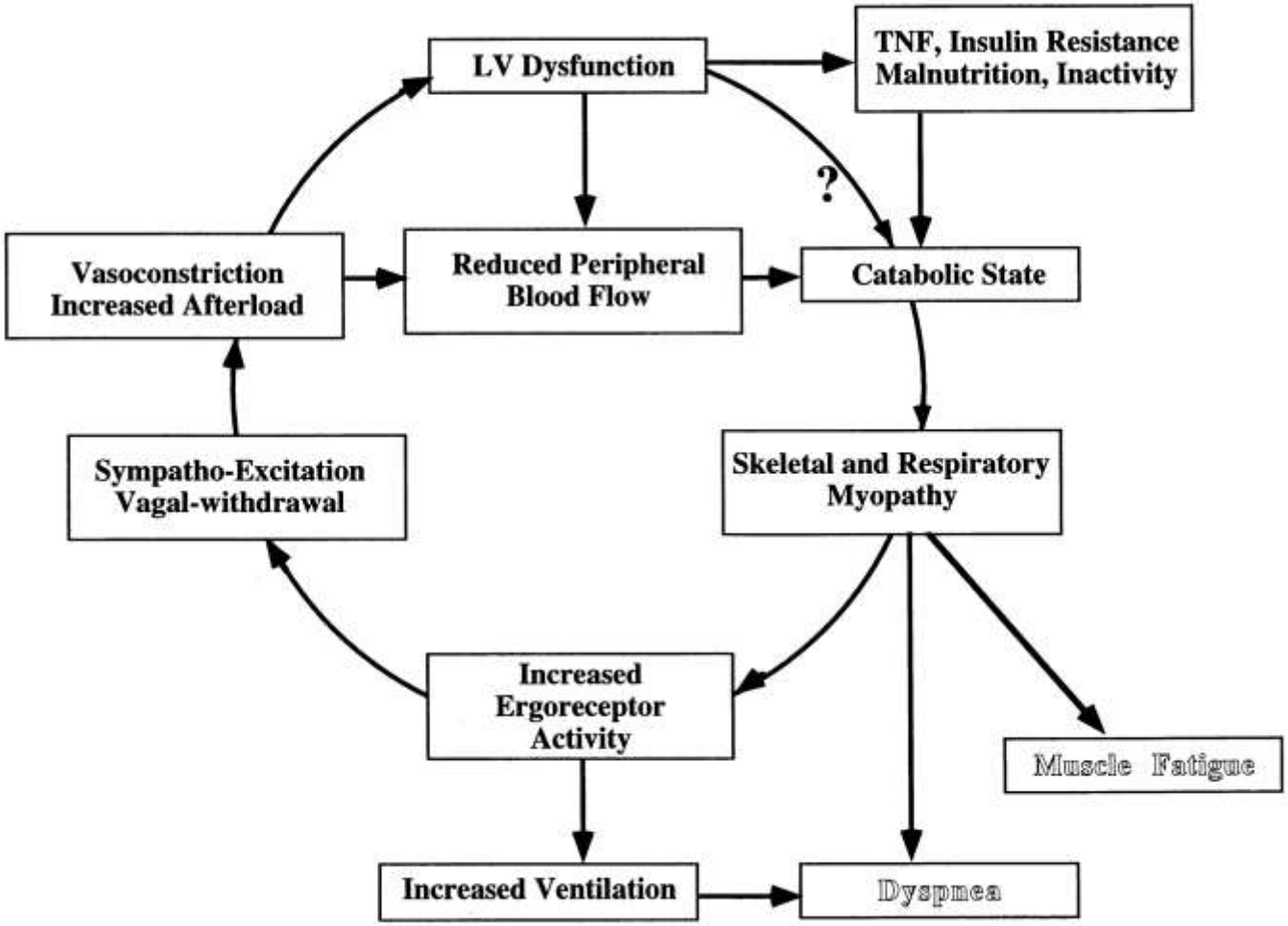

http://circ.ahajournals.org/content/93/5/940/F6.large.jpg

Heart failure: renal responses

- As cardiac function deteriorates, renal blood flow and Glomerular Filtration Rate (GFR) decrease, and blood flow within the kidneys is redistributed
- The filtration fraction and filtered Na decrease, but tubular resorption increases, leading to Na and water retention
- Blood flow is further redistributed away from the kidneys during exercise, but renal blood flow improves during rest, possibly contributing to nocturia
- Decreased perfusion of the kidneys (and possibly decreased arterial systolic stretch secondary to declining ventricular function) activates the renin-angiotensin-aldosterone system, increasing Na and water retention and renal and peripheral vascular tone; these effects are amplified by the intense sympathetic activation accompanying heart failure (HF)
- These processes causes a cascade of potentially deleterious long-term effects with myocardial and vascular collagen deposition and fibrosis, vascular and myocardial hypertrophy, thus contributing to the remodeling of the heart and peripheral vasculature, potentially worsening HF

http://www.merckmanuals.com/professional/cardiovascular-disorders/heart-failure/heart-failure-hf

Heart failure: renal responses

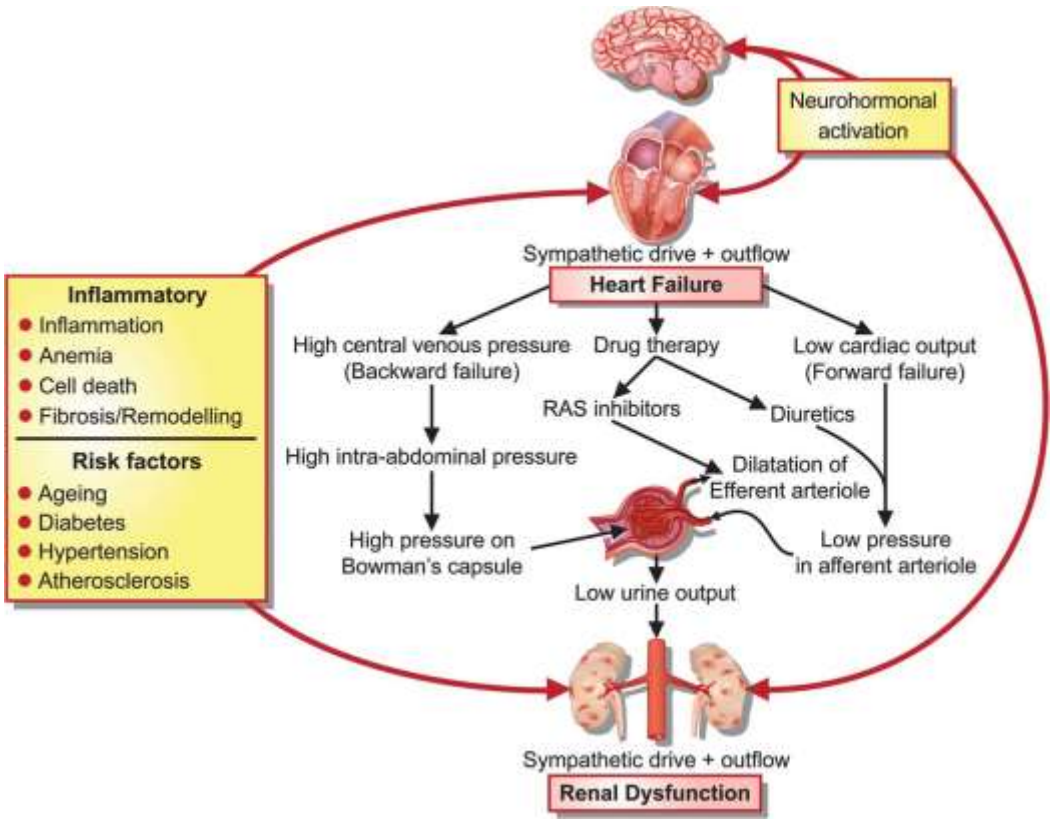

Potential pathogenetic pathways linking heart failure with renal dysfunction. RAS, renin–angiotensin system.

http://eurheartj.oxfordjournals.org/content/35/7/416

Heart failure: neurohumoral responses

- Chronic activation of neurohumoral responses is detrimental to the normal balance between myocardial-stimulating and vasoconstricting hormones and between myocardial-relaxing and vasodilating hormones :
  - β_1 receptors are downregulated , probably in response to intense sympathetic activation
  - Plasma norepinephrine levels are increased, largely reflecting sympathetic nerve stimulation as plasmaepinephrine levels are not increased
  - Vasopressin is released in response to a fall in blood pressure (BP)
  - Atrial natriuretic peptide is released in response to increased atrial volume and pressure
  - Brain (B-type) natriuretic peptide (BNP) is released from the ventricle in response to ventricular stretching
  - Fewer endogenous vasodilators are produced, and more endogenous vasoconstrictors are produced, thus increasing afterload
  - The failing heart and other organs produce tumor necrosis factor (TNF)-α

http://www.merckmanuals.com/professional/cardiovascular-disorders/heart-failure/heart-failure-hf

Heart failure: neurohumoral responses

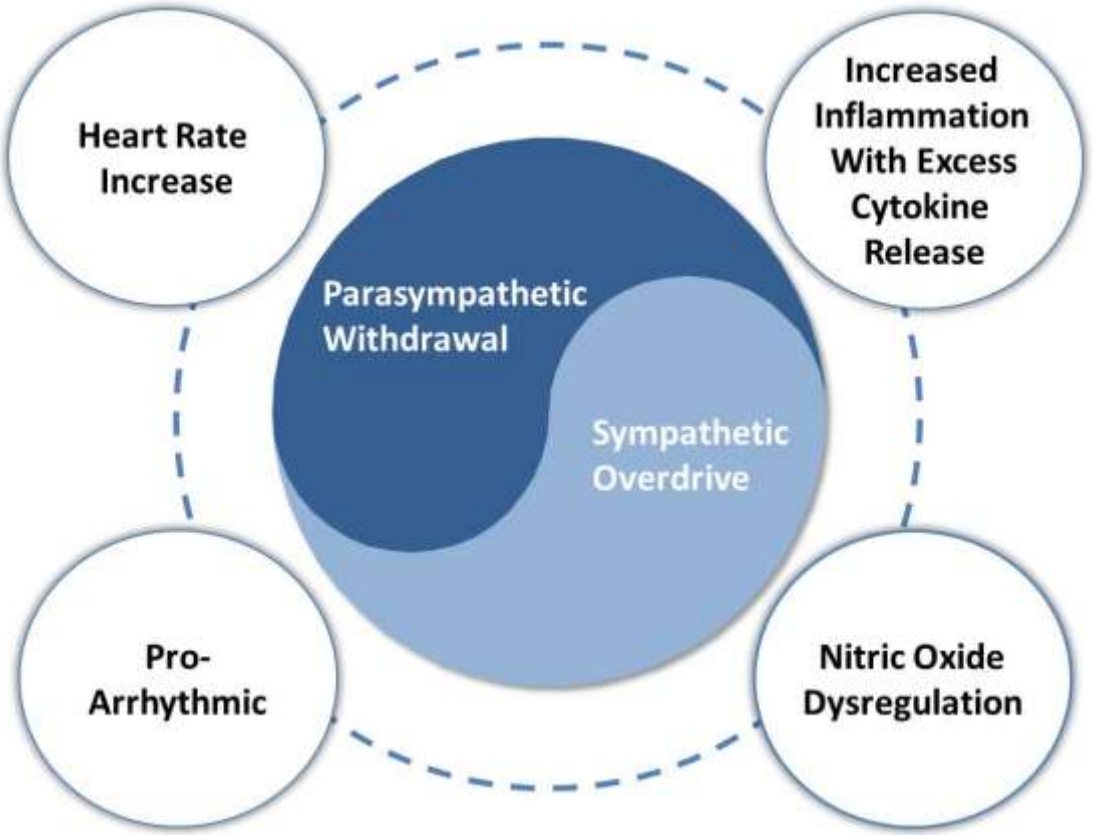

http://www.biocontrol-medical.com/files/files/sympathovagal%20imbalance(1).jpg

Heart failure: changes with aging

- Age-related changes in the heart and cardiovascular system lower the threshold for expression of heart failure (HF0
- Interstitial collagen within the myocardium increases, the myocardium stiffens, and myocardial relaxation is prolonged
- These changes lead to a significant reduction in diastolic LV function, even in healthy elderly people
- Modest decline in systolic function also occurs with aging
- An age-related decrease in myocardial and vascular responsiveness to β-adrenergic stimulation further impairs the ability of the cardiovascular system to respond to increased work demands

http://www.merckmanuals.com/professional/cardiovascular-disorders/heart-failure/heart-failure-hf

Heart failure: changes with aging

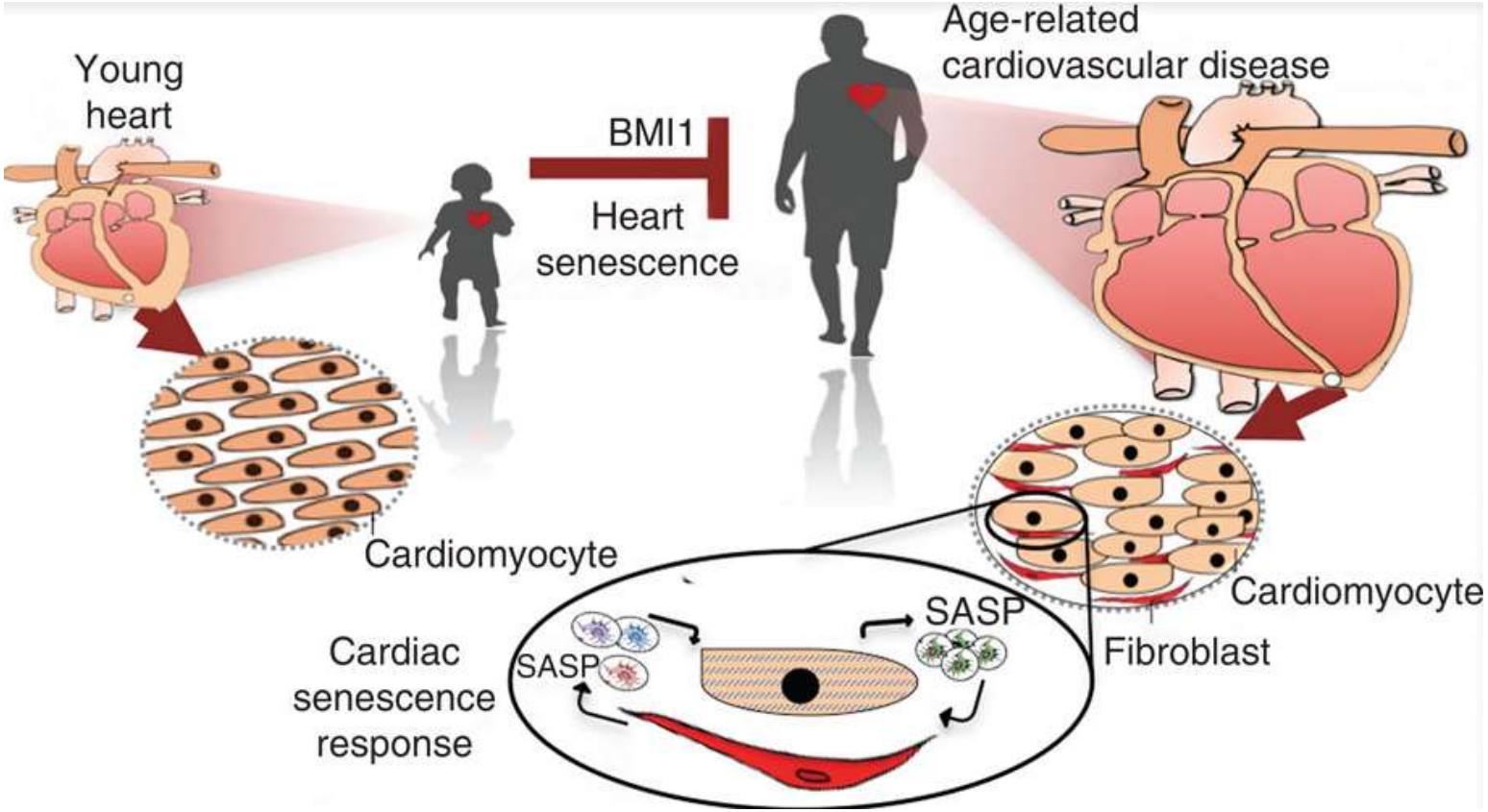

As aging poses the largest risk for cardiovascular disease, the cardiac Bmi1 action could be determinant to limit the heart senescence response. Our data establish the idea that the nonproliferative cardiomyocyte-related senescence phenotype can be locally propagated through the SASP (senescence-associated secretory phenotype)

http://www.nature.com/ncomms/2015/150309/ncomms7473/images/ncomms7473-f8.jpg

Heart failure: causes

Heart failure can complicate any cardiovascular disease sooner or later

- Coronary artery disease
- High blood pressure
- Atrial fibrillation
- Valvular heart disease
- Excess alcohol use
- Infection
- Cardiomyopathy
- Thyroid disease
- Kidney disease
- Diabetes
- Heart defects present at birth

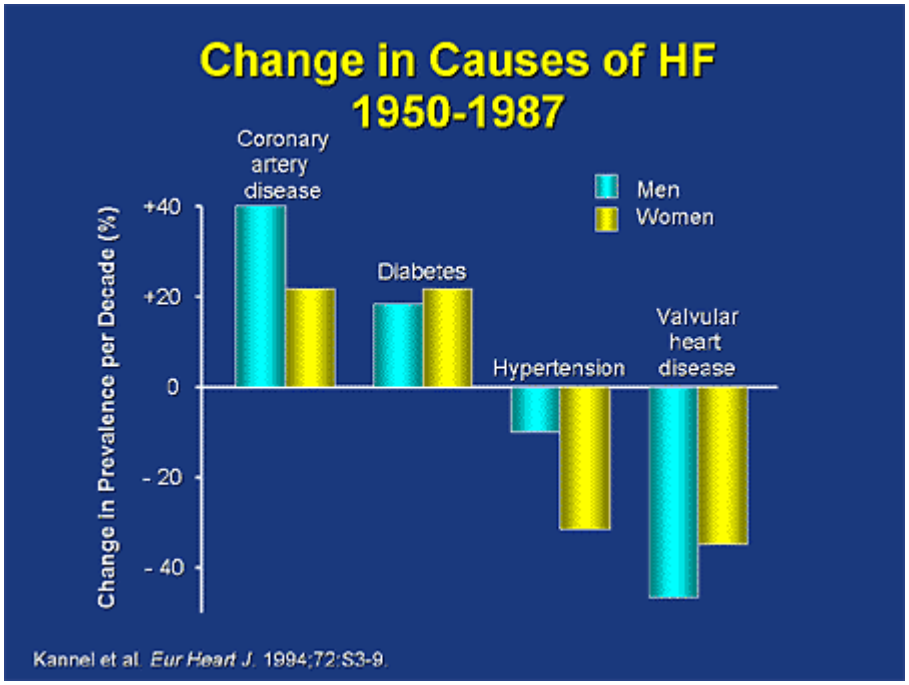

http://img.medscape.com/slide/migrated/editorial/cmecircle/2003/2850/images/braunwald/slide05.gif
http://www.webmd.com/heart-disease/guide-heart-failure#2 https://en.wikipedia.org/wiki/Heart_failure

Heart failure: risk factors

Risk factors for cardiovascular diseases = risk factors for heart failure

- High blood pressure
- Coronary artery disease
- Heart attack
- Diabetes
- Some diabetes medications
- Sleep apnea
- Congenital heart defects
- Valvular heart disease
- Viruses
- Alcohol use
- Tobacco use
- Obesity
- Irregular heartbeats

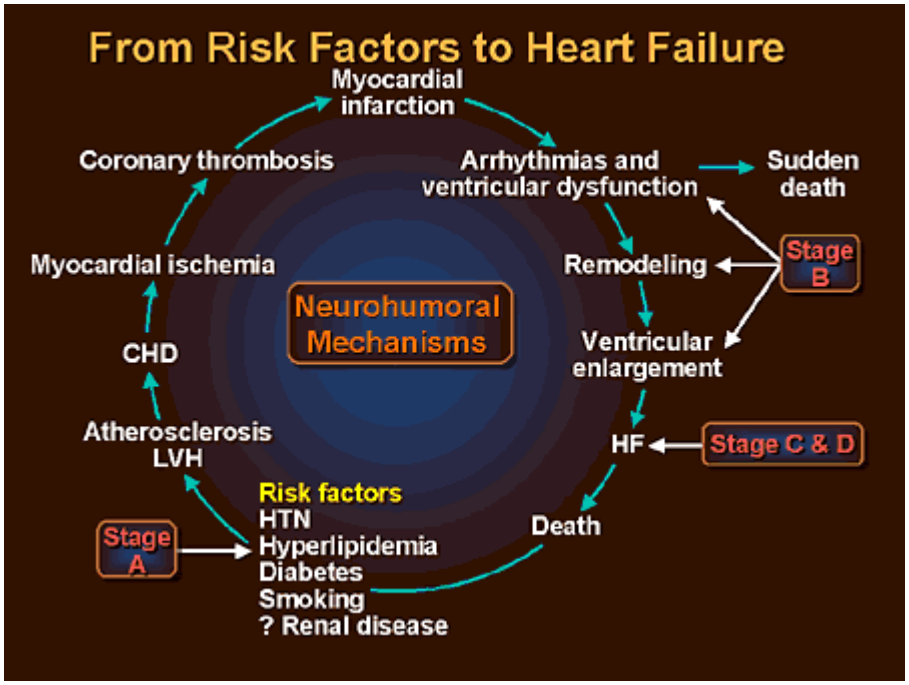

http://img.medscape.com/slide/migrated/editorial/cmecircle/2004/3530/images/burnett/slide031.gif
http://www.mayoclinic.org/diseases-conditions/heart-failure/basics/risk-factors/con-20029801
http://www.webmd.com/heart-disease/guide-heart-failure#2 https://en.wikipedia.org/wiki/Heart_failure

Heart failure: classification

- Acute or chronic (congestive)
- High output or low output
- Systolic or diastolic
- Left heart or right heart or biventricular
- Dilated or nondilated
- Cause: ischemic, hypertensive, idiopathic dilated cardiomyopathy, etc.

http://www.onmedica.com/getresource.aspx?resourceid=d8c24110-e9ad-4e79-8628-09359cf36637
http://www.webmd.com/heart-disease/guide-heart-failure#2 https://en.wikipedia.org/wiki/Heart_failure

Heart failure: signs and symptoms

- Shortness of breath (dyspnea)
- Fatigue and weakness
- Swelling (edema) in legs, ankles and feet
- Rapid or irregular heartbeat
- Reduced ability to exercise
- Persistent cough or wheezing with white or pink blood-tinged phlegm
- Increased need to urinate at night
- Swelling of abdomen (ascites)
- Sudden weight gain from fluid retention
- Lack of appetite and nausea
- Difficulty concentrating or decreased alertness
- Sudden, severe shortness of breath and coughing up pink, foamy mucus
- Chest pain if heart failure is caused by a heart attack

http://www.mayoclinic.org/diseases-conditions/heart-failure/basics/symptoms/con-20029801

Heart failure:
signs and symptoms of left heart failure

- The most common symptoms are dyspnea, reflecting pulmonary congestion, and fatigue, reflecting low cardiac output (CO)
- Dyspnea occurs during exertion and is relieved by rest, and as heart failure (HF) worsens, it can occur during rest and at night, sometimes causing nocturnal cough
- In paroxysmal nocturnal dyspnea (PND), dyspnea awakens patients several hours after they lie down and is relieved only after they sit up for 15 to 20 min
- In severe HF, periodic cycling of breathing (Cheyne-Stokes) can occur during the day or night
- Sleep-related breathing disorders, such as sleep apnea, are common in HF and may aggravate HF
- Severely reduced cerebral blood flow and hypoxemia can cause chronic irritability and impair mental performance

http://www.mayoclinic.org/diseases-conditions/heart-failure/basics/symptoms/con-20029801

Heart failure:
signs and symptoms of right heart failure

- The most common symptoms are ankle swelling and fatigue
- Hepatic congestion can cause right upper quadrant abdominal discomfort, and stomach and intestinal congestion can cause anorexia and abdominal bloating
- Less specific symptoms include cool peripheries, postural light-headedness, nocturia, and decreased daytime micturition
- Skeletal muscle wasting can occur in severe biventricular failure and may reflect some disuse but also increased catabolism associated with increased cytokine production
- Significant weight loss (cardiac cachexia) is an ominous sign associated with high mortality
- In the elderly, presenting complaints may be atypical, such as confusion, delirium, falls, sudden functional decline, nocturnal urinary incontinence, or sleep disturbance
- Coexisting cognitive impairment and depression

http://www.mayoclinic.org/diseases-conditions/heart-failure/basics/symptoms/con-20029801

Heart failure: signs and symptoms

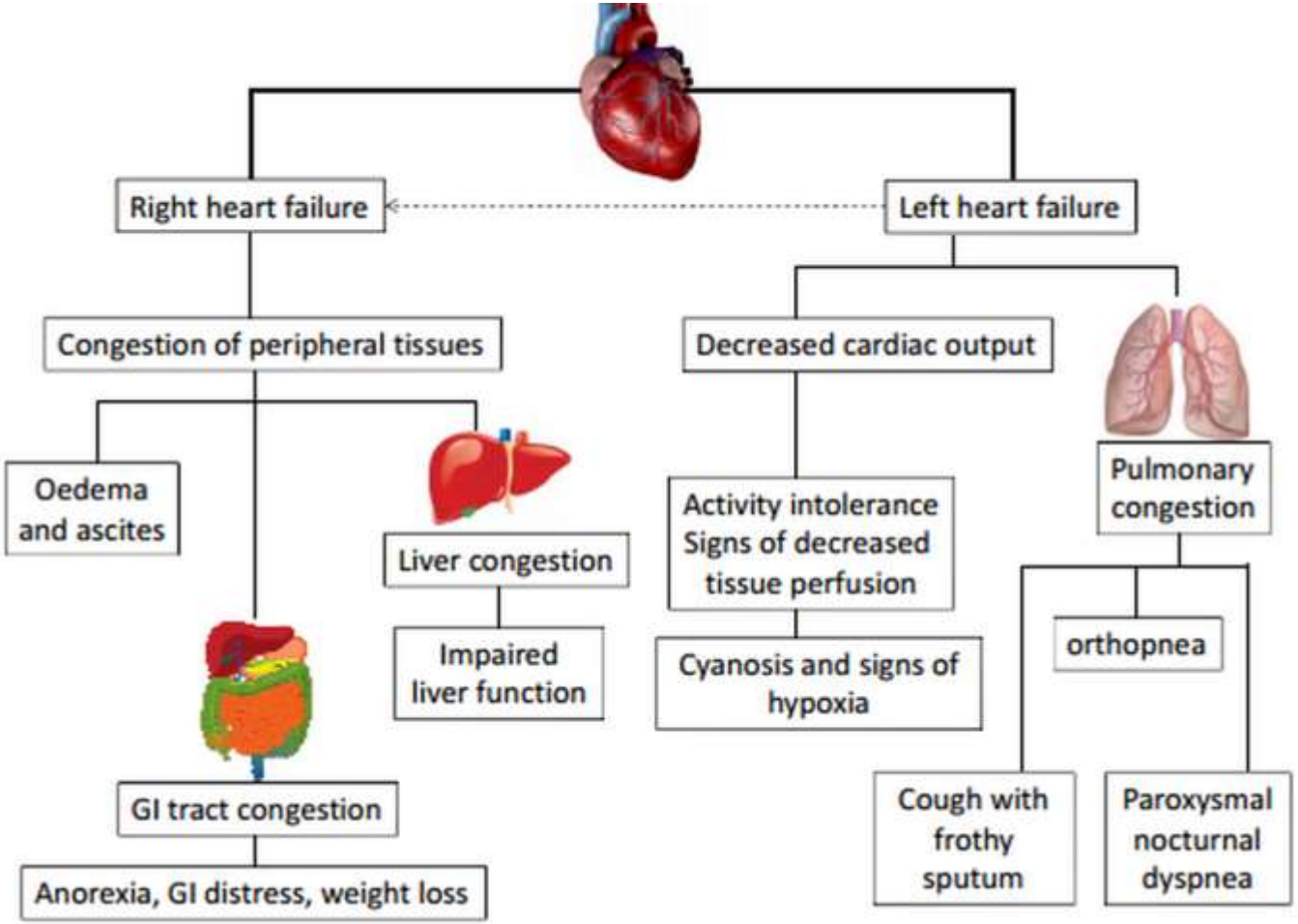

https://classconnection.s3.amazonaws.com/930/flashcards/3853930/png/screen_shot_2013-10-16_at_92756_am-141C06124857054B85A.png

Heart failure: examination in left heart failure

- In left heart (left ventricle - LV) failure, tachycardia and tachypnea, hypotension, and confusion because of hypoxia and poor cerebral perfusion may occur
- Central cyanosis reflects severe hypoxemia; peripheral cyanosis of the lips, fingers, and toes reflects low blood flow with increased O_2 extraction
- LV systolic dysfunction include a diffuse, sustained, and laterally displaced apical impulse; audible and occasionally palpable 3rd (S_3) and 4th (S_4) heart sounds, and an accentuated pulmonic component (P_2) of the 2nd heart sound (S_2); a pansystolic murmur of mitral regurgitation at the apex may occur
- Pulmonary findings include early inspiratory basilar crackles that do not clear with coughing and, if pleural effusion is present, dullness to percussion and diminished breath sounds at the lung base(s)

http://www.mayoclinic.org/diseases-conditions/heart-failure/basics/symptoms/con-20029801

Heart failure:
examination in left heart failure (tachycardia)

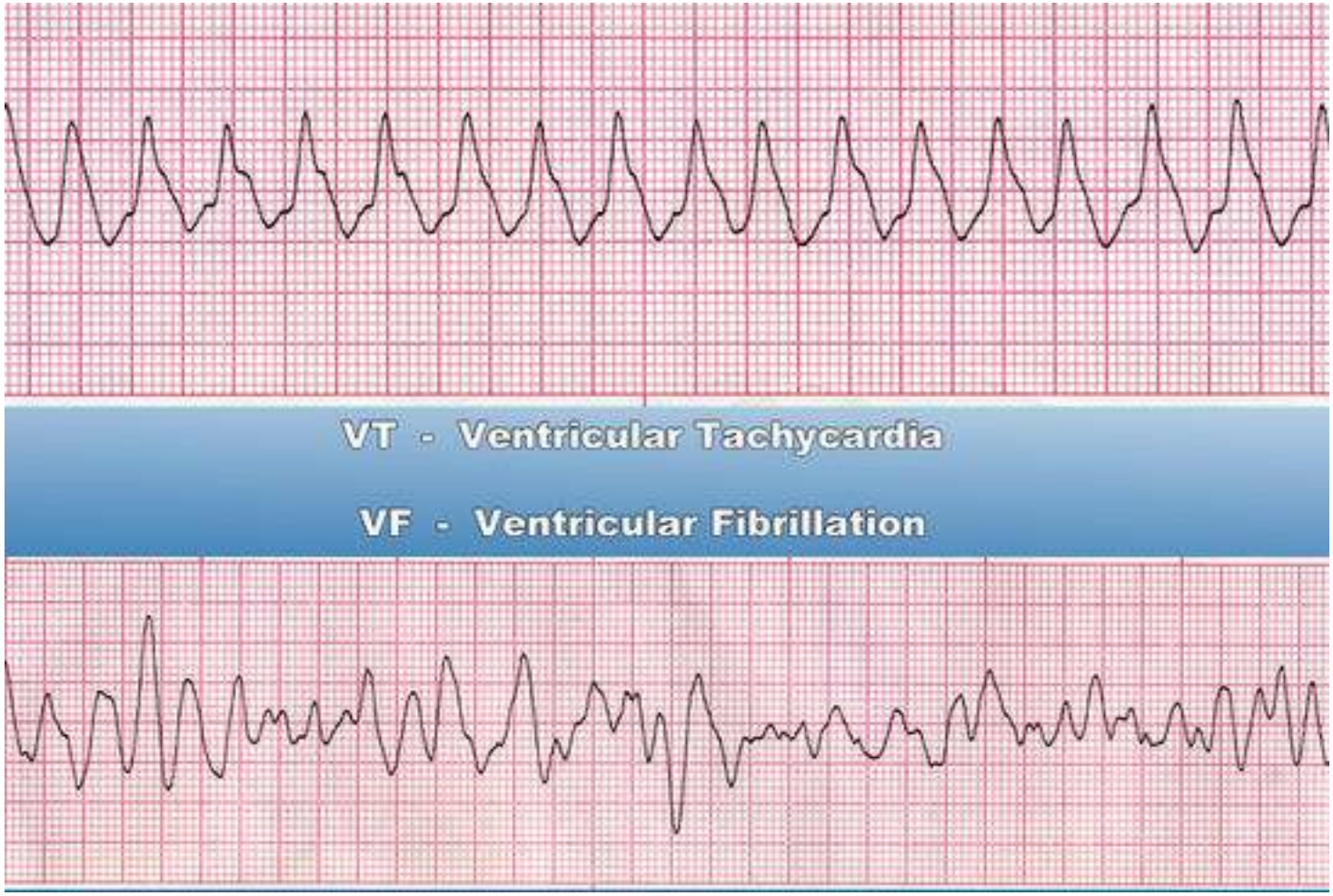

http://www.mayoclinic.org/diseases-conditions/heart-failure/basics/symptoms/con-20029801

Heart failure:
examination in left heart failure (central cyanosis)

Central cyanosis is caused by abnormal composition of hemoglobin such as sulphaemoglobinaemia and methaemoglobinaemia or decreased in the saturation of the oxygen because of cyanotic congenital heart disease, pulmonary embolism, pulmonary edema (required urgent treatment) and severe respiratory disease

http://www.medicalzone.net/symptom-finder---the-causes-of-cyanosis.html

Heart failure:
examination in left heart failure (peripheral cyanosis)

- Peripheral cyanosis can be a result of the causes of central cyanosis or can occur in isolation
- Common causes of peripheral cyanosis without central cyanosis are:
  - Peripheral vasoconstriction due to cold, Raynaud's phenomenon or beta blocker drugs
  - Reduced cardiac output due to cardiac failure or hypovolemia
  - Peripheral vascular disease
  - Venous obstruction, such as a deep vein thrombosis or obstruction of the superior vena cava

http://www.fastbleep.com/medical-notes/heart-lungs-blood/14/30/448

Heart failure:
examination in left heart failure (heart sounds)

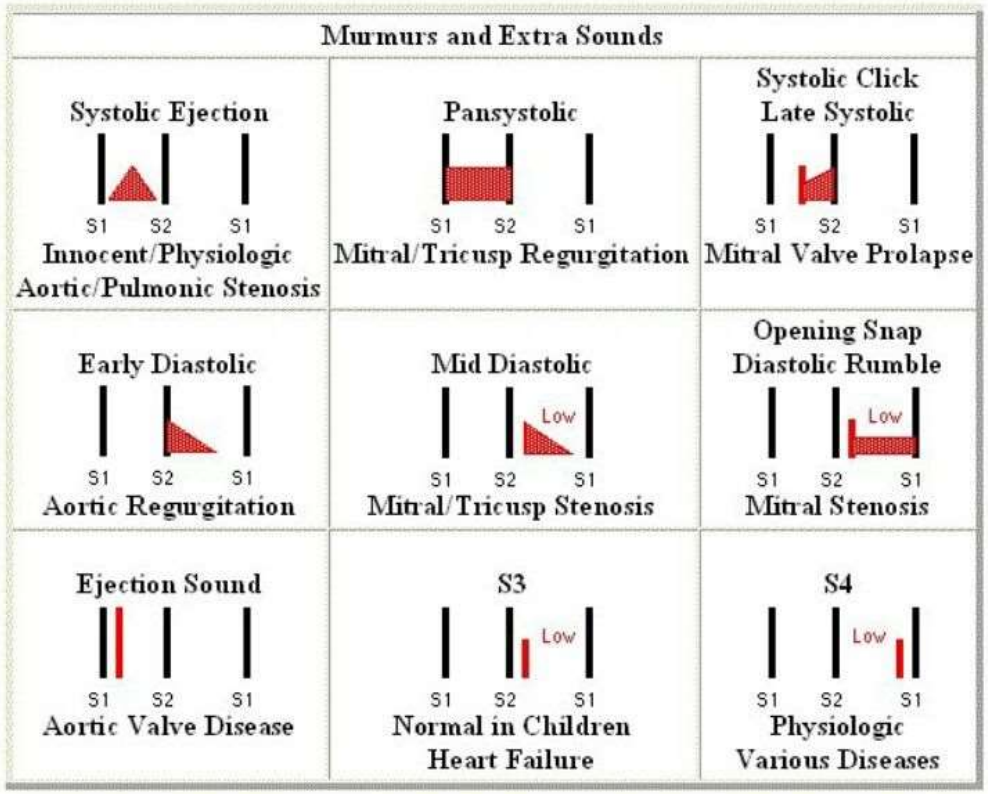

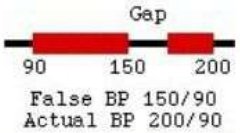

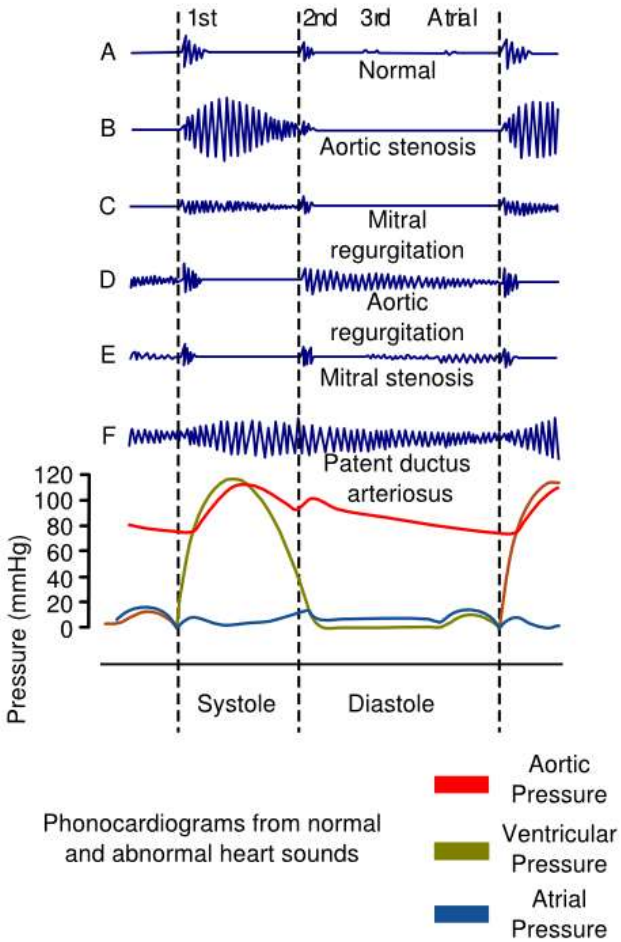

Phonocardiograms from normal and abnormal heart sounds

http://ktthebest4u.blogspot.com/2015_01_01_archive.html http://www.textbookofcardiology.org/

Heart failure: examination in right heart failure

- Nontender peripheral pitting edema (digital pressure leaves visible and palpable imprints, sometimes quite deep) in the feet and ankles; an enlarged and sometimes pulsatile liver palpable below the right costal margin; abdominal swelling and ascites; and visible elevation of the jugular venous pressure, sometimes with large *a* or *v* waves that are visible even when the patient is seated or standing
- In severe cases, peripheral edema can extend to the thighs or even the sacrum, scrotum, lower abdominal wall, and occasionally even higher (anasarca); edema may be asymmetric if patients lie predominantly on one side
- With hepatic congestion, the liver may be palpably enlarged or tender, and hepato jugular or abdominal-jugular reflux may be detected
- Precordial palpation may detect the left parasternal lift of RV enlargement, and auscultation may detect the murmur of tricuspid regurgitation or the RV S_3 along the left sternal border; both findings are augmented upon inspiration

http://www.mayoclinic.org/diseases-conditions/heart-failure/basics/symptoms/con-20029801

Heart failure:
examination in right heart failure (peripheral edema)

http://img.medscapestatic.com/pi/meds/ckb/84/6284tn.jpg
https:// https://classconnection.s3.amazonaws.com http://www.cormedicalgroup.com/wp-content/uploads/2014/01/pitting-edema-300x231.png

Heart failure:
examination in right heart failure (anasarca)

Anasarka is whole body edema.

https://classconnection.s3.amazonaws.com/683/flashcards/4419683/png/screen_shot_2014-01-25_at_125401_pm-143CB2C3EC22D2BA818.png

Heart failure:
examination in right heart failure (heart sounds)

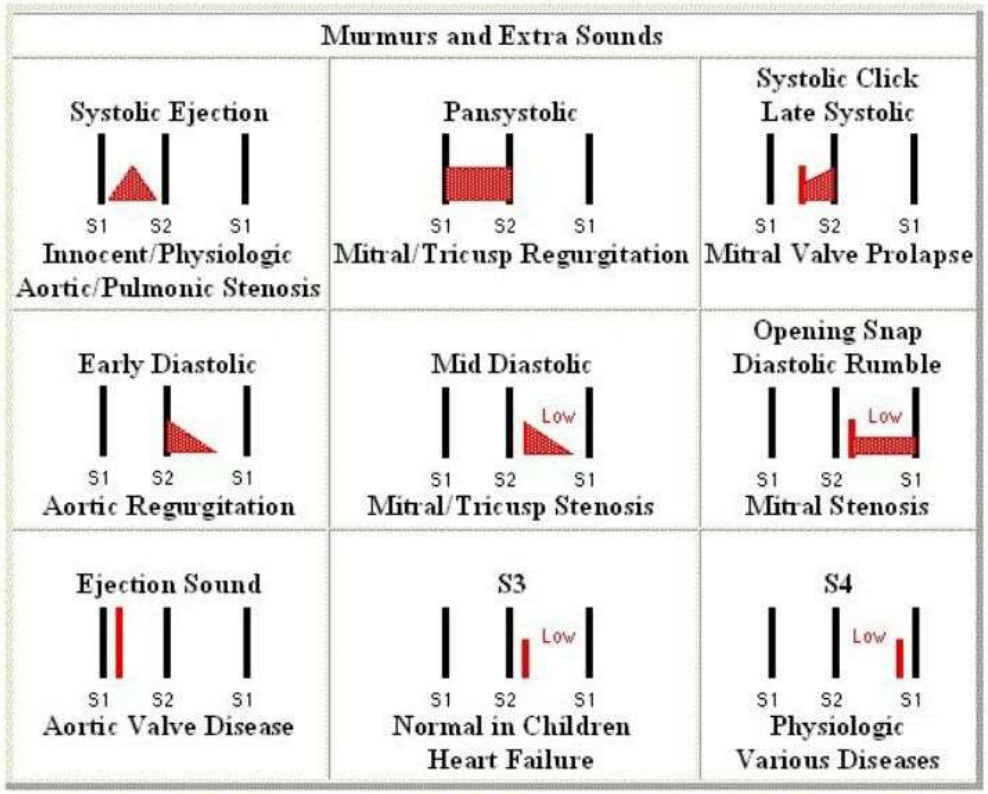

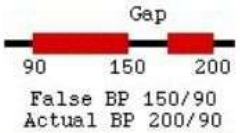

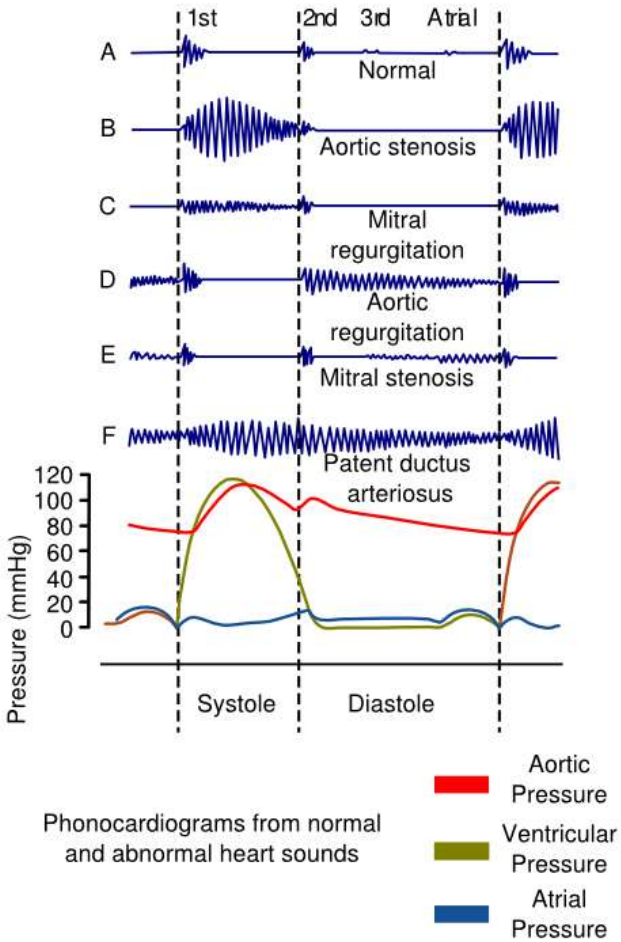

Phonocardiograms from normal and abnormal heart sounds

http://ktthebest4u.blogspot.com/2015_01_01_archive.html http://www.textbookofcardiology.org/

Heart failure: complications

- Kidney damage or failure
- Heart valve problems
- Heart rhythm problems
- Liver damage

http://nutritionfacts.org/wp-content/uploads/2012/10/Preventing-and-Treating-Kidney-Failure-with-Diet.jpg
http://www.mayoclinic.org/diseases-conditions/heart-failure/basics/symptoms/con-20029801

Heart failure: diagnosis

- Sometimes only clinical evaluation
- Chest x-ray
- Electrocardiography
- Echocardiography
- Cardiac radionuclide scan
- Magnetic resonance imaging
- Sometimes blood NP/BNP or N-terminal-pro-BNP (NT-pro-BNP) levels (other blood tests are not used for diagnosis but are useful for identifying cause of heart failure)
- Other tests for etiology as needed

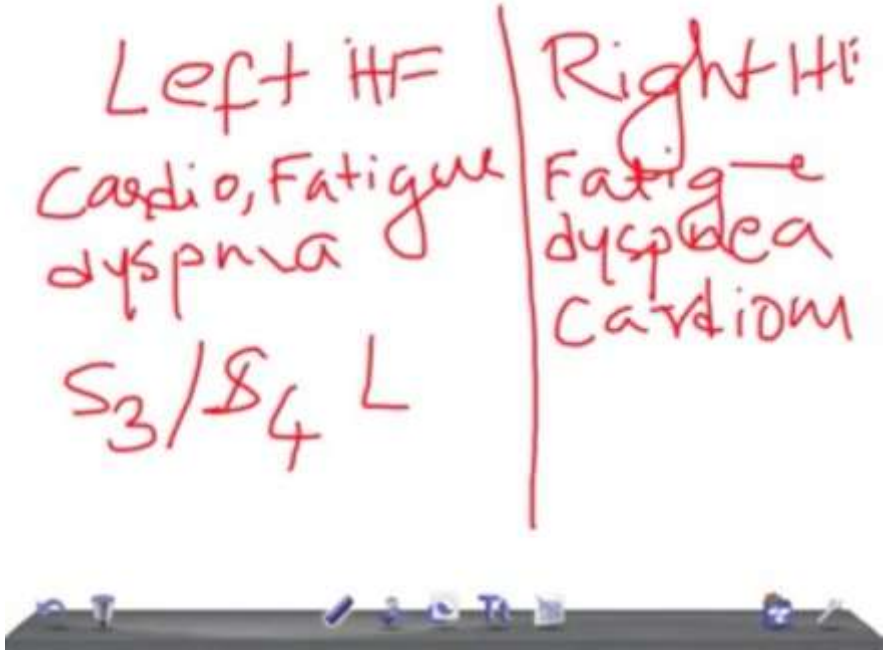

http://i.ytimg.com/vi/mYJ-V2Y6KTc/maxresdefault.jpg http://www.mayoclinic.org/diseases-conditions/heart-failure/basics/symptoms/con-20029801

Heart failure: diagnosis (clinical evaluation)

- Clinical findings suggest heart failure (HF) but are usually not apparent early
- Similar symptoms may result from chronic obstructive pulmonary disease (COPD) or recurrent pneumonia or may be erroneously attributed to obesity or old age
- Suspicion for HF should be high in patients with a history of myocardial infarction (MI), hypertension, or valvular disorders or murmurs and should be moderate in any patient who is elderly or has diabetes

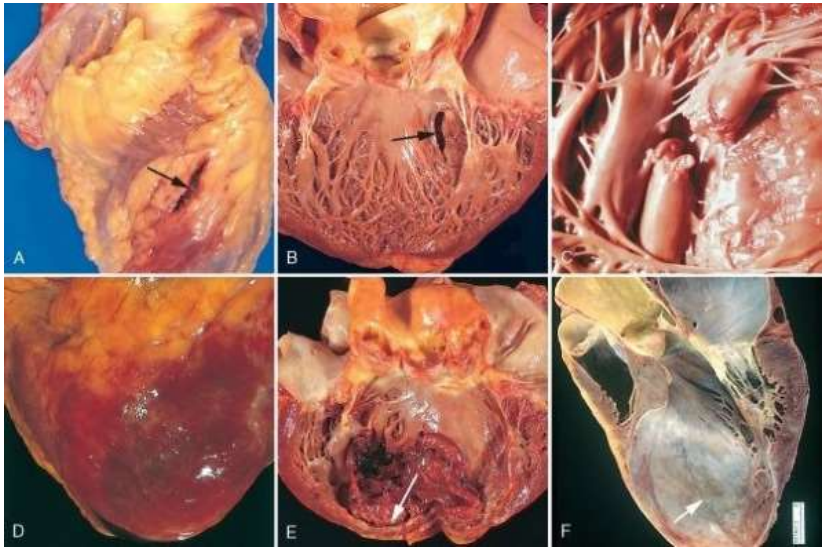

Complications of acute myocardial infarction
A. Anterior wall rupture
B. Interventricular septum rupture
C. Papillary muscle rupture
D. Fibrinous pericarditis
E. Mural thrombus
F. Ventricular aneurysm

https://usmle287.files.wordpress.com/2012/12/20121223-183507.jpg?w=594 http://www.mayoclinic.org/diseases-conditions/heart-failure/basics/symptoms/con-20029801

Heart failure: diagnosis (chest x-ray)

- Chest x-ray findings include an enlarged cardiac silhouette, pleural effusion, fluid in the major fissure, and horizontal lines in the periphery of lower posterior lung fields (Kerley B lines)
- Careful examination of the cardiac silhouette on a lateral projection can identify specific ventricular and atrial chamber enlargement
- The x-ray may also suggest alternative diagnoses (e.g., chronic obstructive pulmonary disease (COPD), pneumonia, interstitial pulmonary fibrosis, lung cancer)

Enlargement of the cardiac silhouette, increased pulmonary vasculature, and pleural effusions are evident in the patient suffering from congestive heart failure.

https://www.med-ed.virginia.edu/courses/rad/chest/images/x-rays/chf.jpg http://www.mayoclinic.org/diseases-conditions/heart-failure/basics/symptoms/con-20029801

Heart failure: diagnosis (electrocardiography)

- Electrocardiography (ECG) findings are not diagnostic, but an abnormal ECG, especially showing previous myocardial infarction (MI), left ventricle (LV) hypertrophy, left bundle branch block, or tachyarrhythmia (e.g., rapid atrial fibrillation), increases suspicion for heart failure (HF) and may help identify the cause
- An entirely normal ECG is uncommon in chronic HF

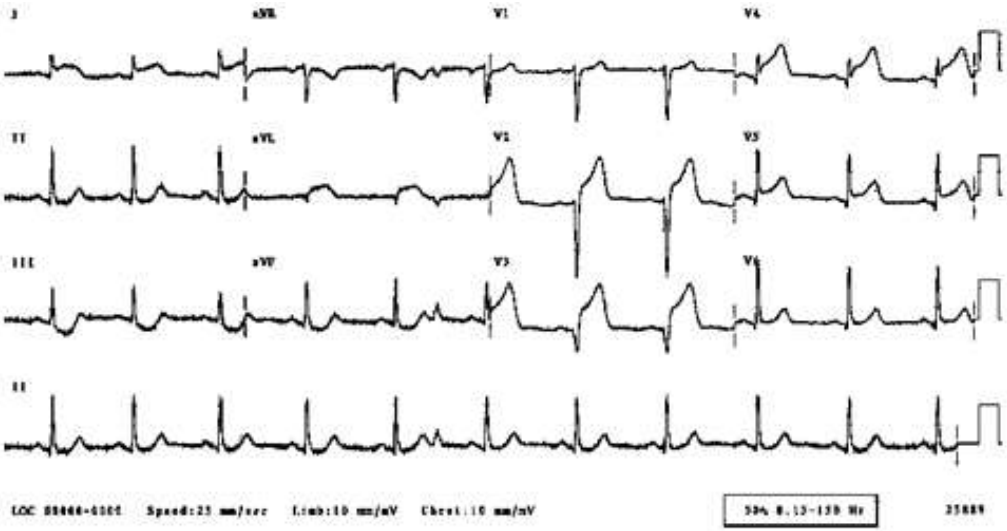

ECG showing myocardial infarction.

http://www.mayoclinic.org/diseases-conditions/heart-failure/basics/symptoms/con-20029801

Heart failure: diagnosis (echocardiography)

- Echocardiography can help evaluate chamber dimensions, valve function, ejection fraction (EF), wall motion abnormalities, left ventricle (LV) hypertrophy, and pericardial effusion
- Measuring LV EF can distinguish between predominant diastolic dysfunction (EF > 0.50) and systolic dysfunction (EF < 0.40)
- Intracardiac thrombi, tumors, and calcifications within the heart valves, mitral annulus, and aortic wall abnormalities can be detected
- Localized or segmental wall motion abnormalities strongly suggest underlying coronary artery disease (CAD) but can also be present with patchy myocarditis
- Doppler echocardiography accurately detects valvular disorders and shunts, can help identify and quantify LV diastolic dysfunction

http://www.mayoclinic.org/diseases-conditions/heart-failure/basics/symptoms/con-20029801

Heart failure: diagnosis (echocardiography)

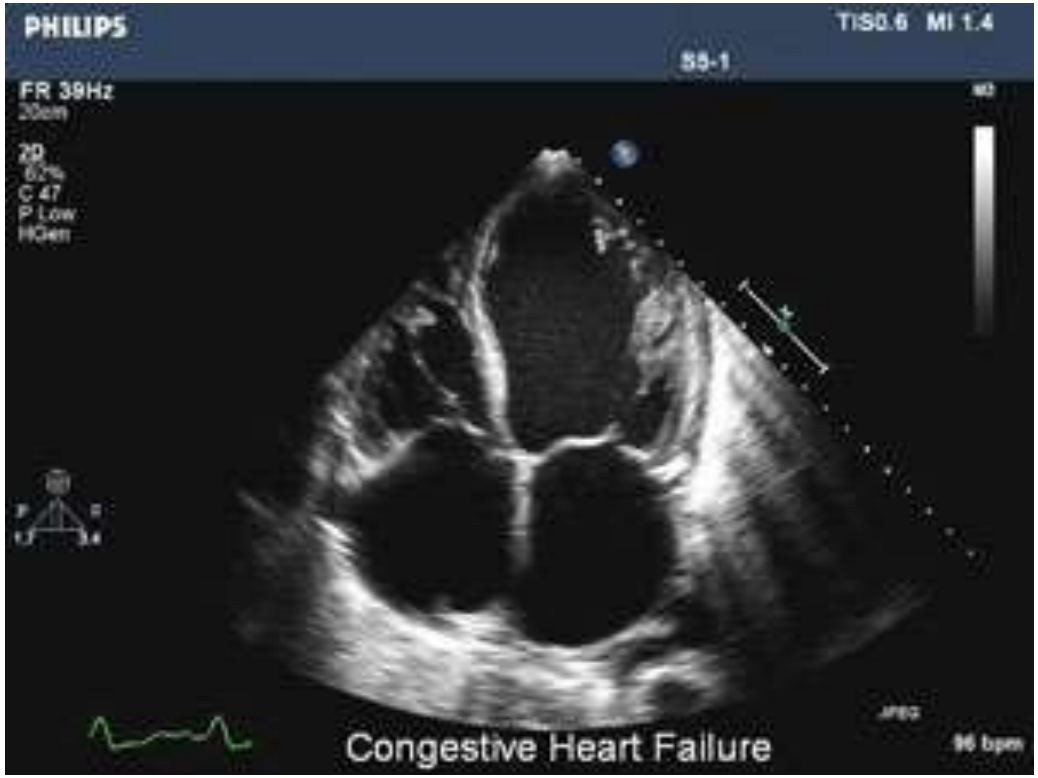

http://tursweet.com/e/echocardiogram-of-heart-failure.html

Heart failure: diagnosis (echocardiography)

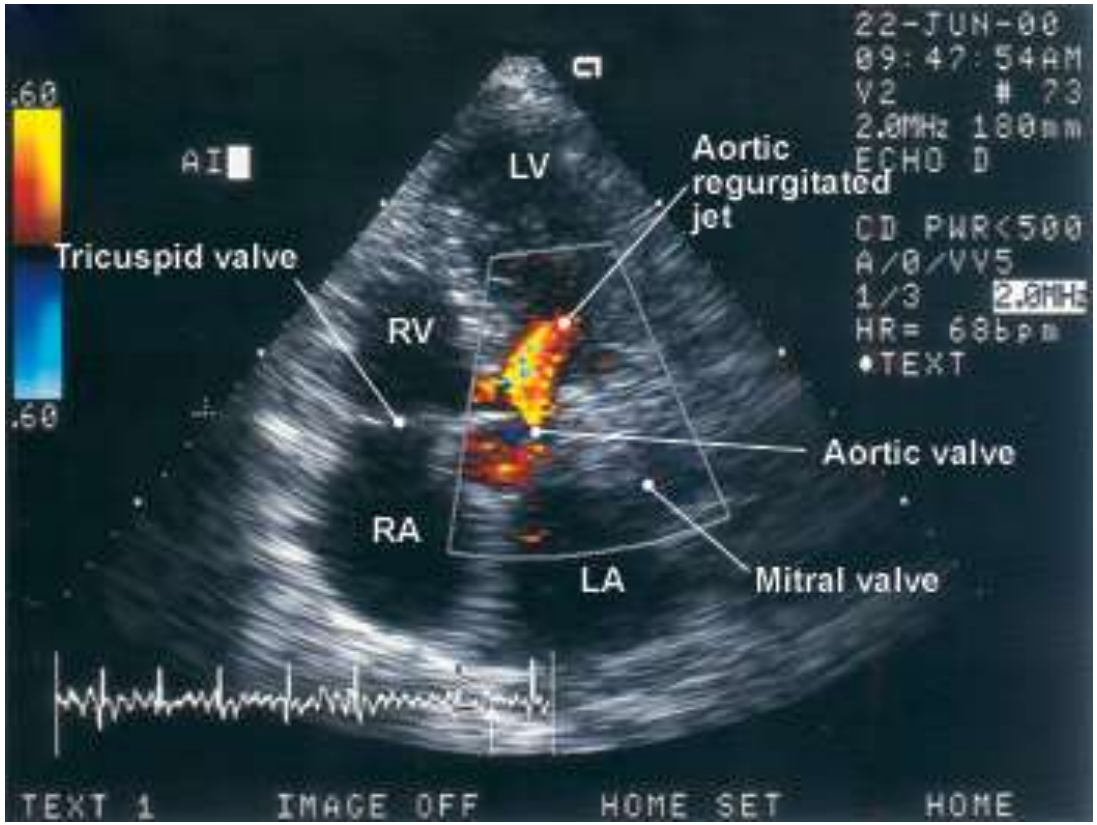

http://www.aafp.org/afp/2001/0601/afp20010601p2201-f1.jpg

Heart failure: diagnosis (echocardiography)

http://www.escardio.org/static_file/Escardio/Medias/working-groups/myocardial-pericardial/case-dec12-fig2.jpg

Heart failure: diagnosis (echocardiography)

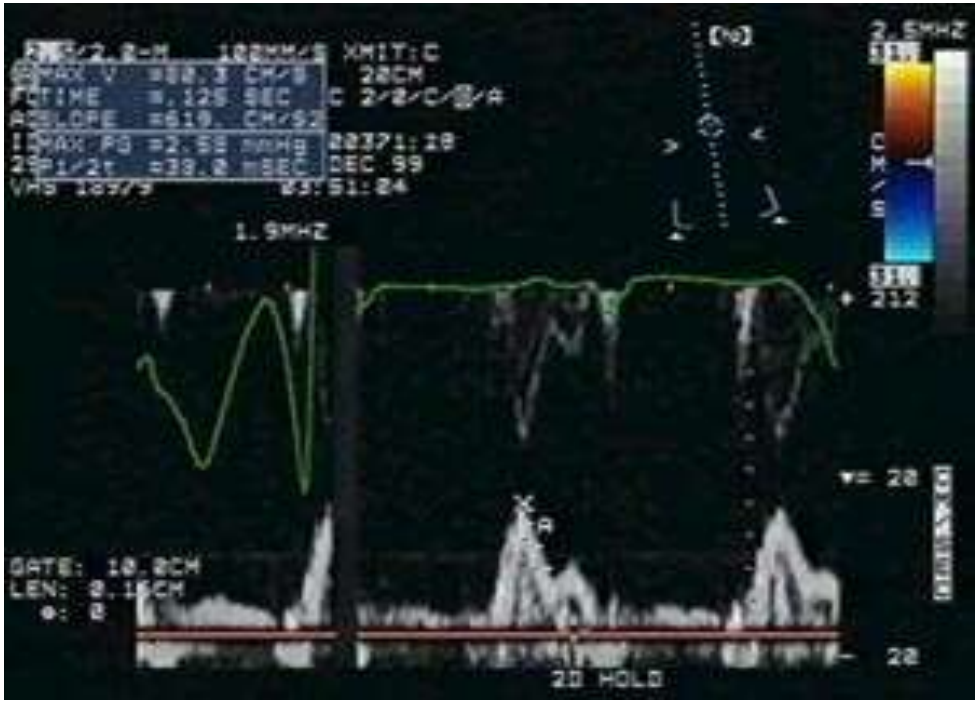

http://my.clevelandclinic.org/ccf/media/Images/heart/echo2.JPG

Heart failure:
diagnosis (echocardiography)

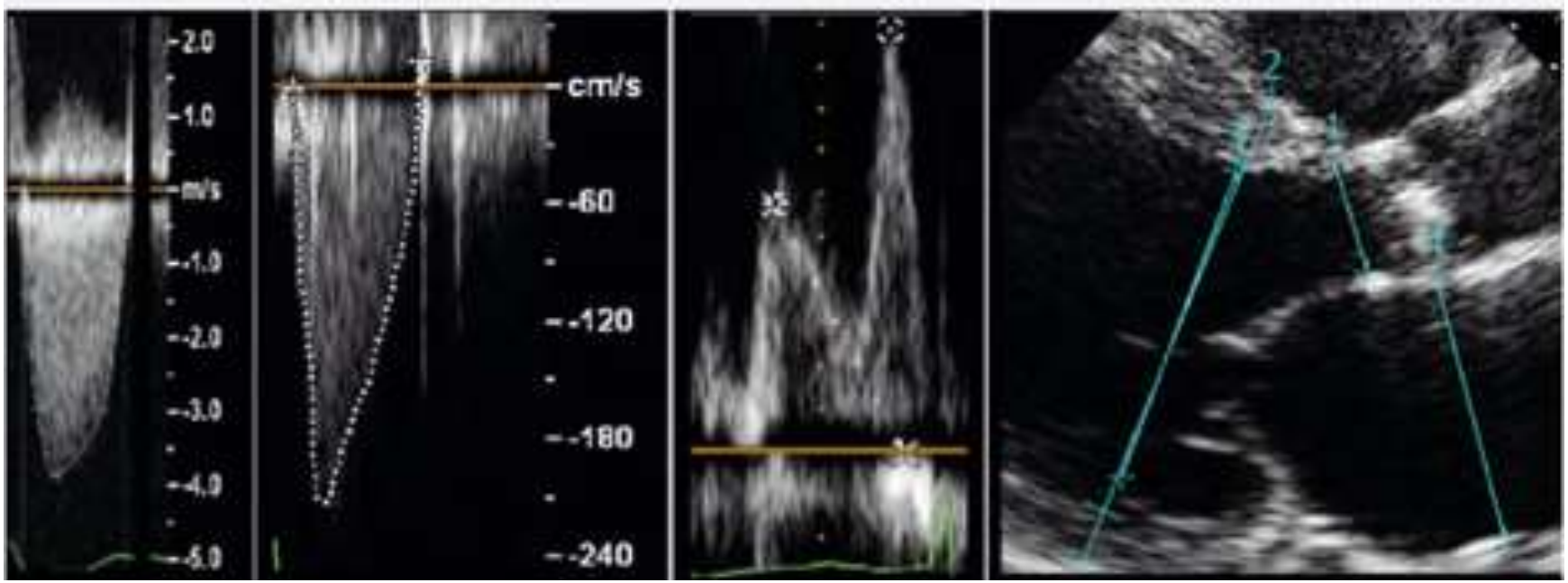

http://www.cardialysis.com/files/echo-2904-1.jpg

Heart failure: diagnosis (echocardiography)

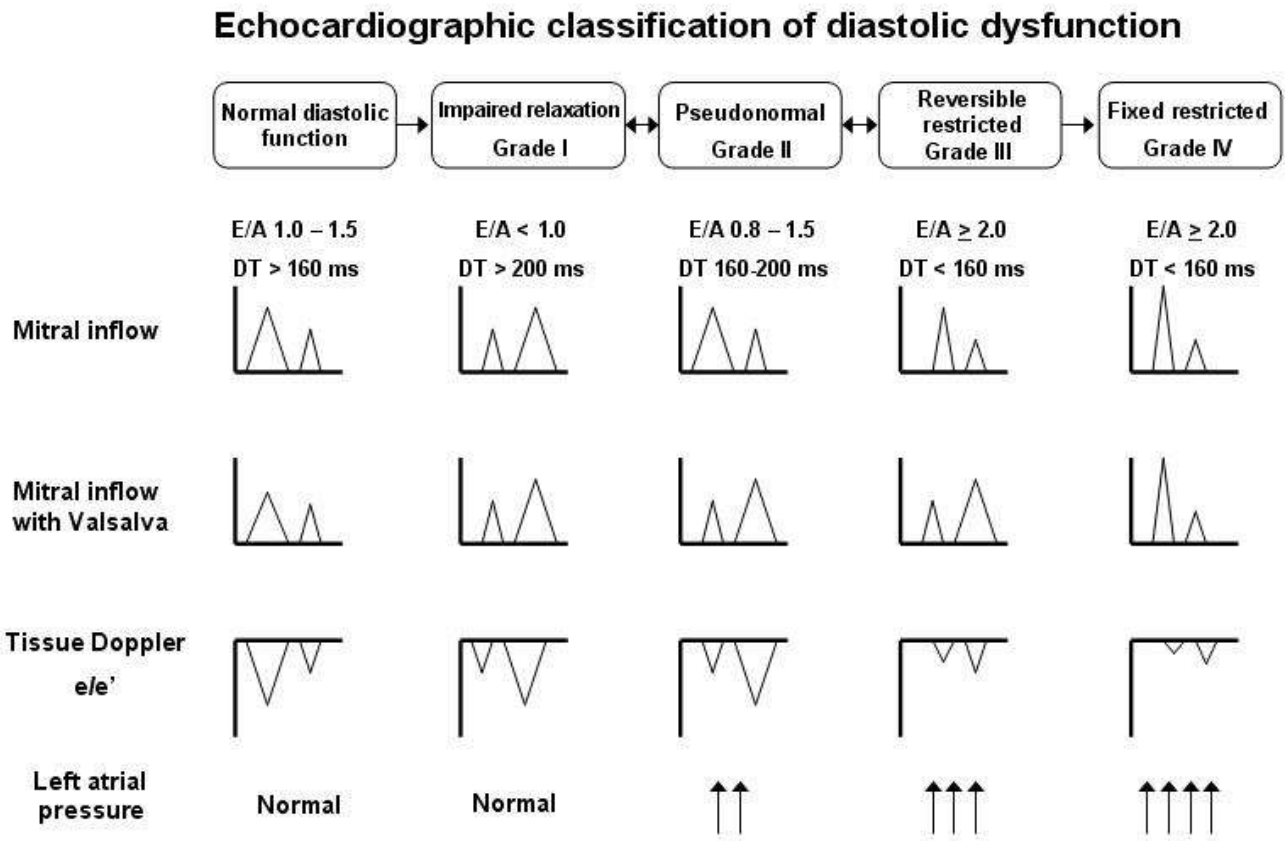

http://www.learntheheart.com/assets/1/7/DD-echoClassification.JPG

Heart failure: diagnosis (echocardiography)

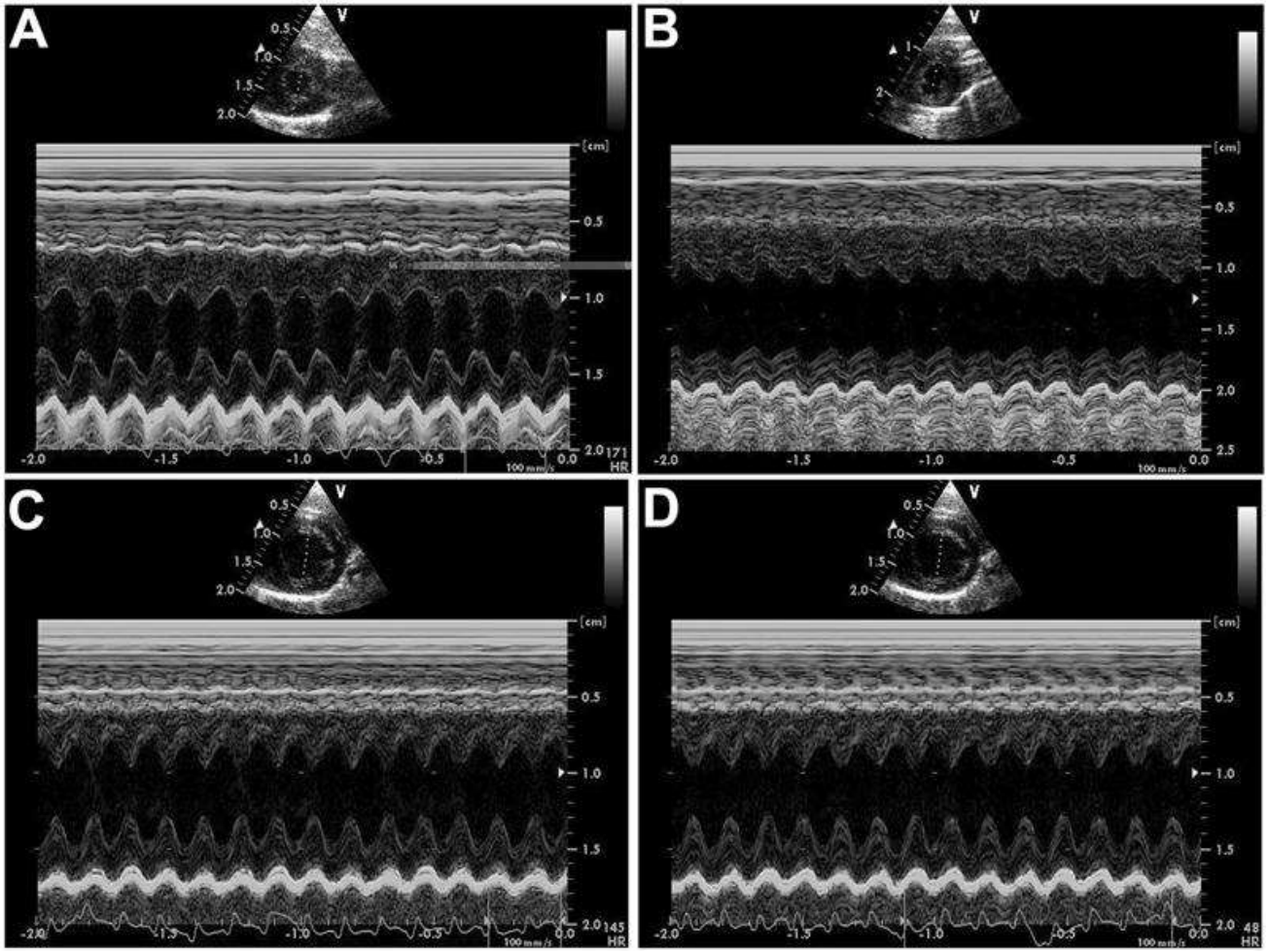

http://www.scielo.br/img/revistas/bjmbr/v47n8//1414-431X-bjmbr-1414-431X20143474-gf001.jpg

Heart failure: diagnosis (cardiac radionuclide scan)

Radionuclide imaging can help assess systolic and diastolic function, previous myocardial infarction (MI), and inducible ischemia or myocardial hibernation

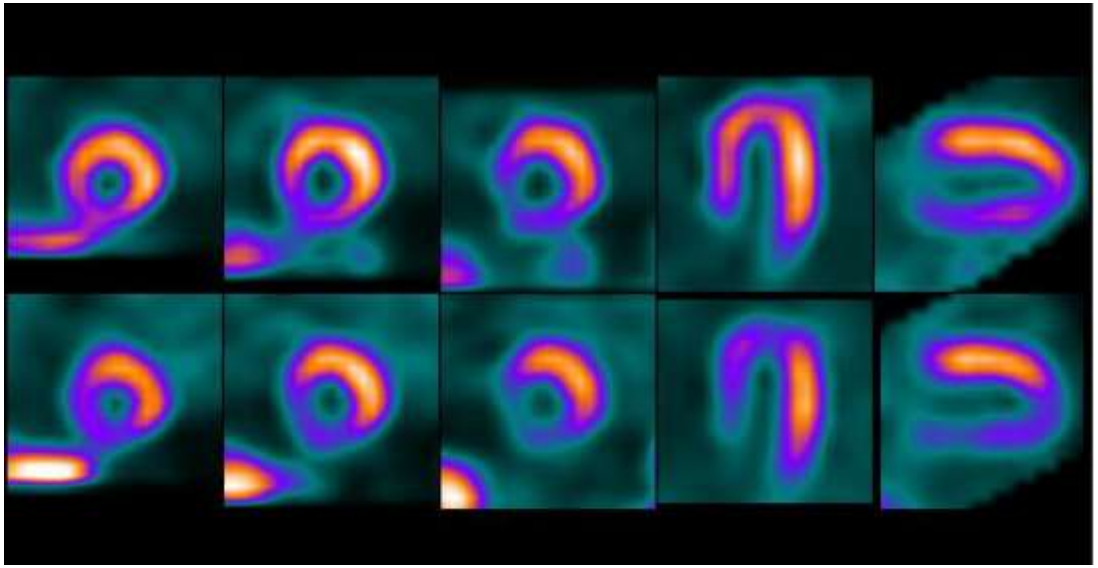

A myocardial perfusion SPECT (Single Photon Emission Computed Tomography) study, also called a cardiac stress-rest test, is used to evaluate the heart's blood supply. Two sets of images showing blood flow are obtained: the first following a period of rest, and the second following a period of stress, which involves exercise on a treadmill.

http://cedars-sinai.edu/Patients/Programs-and-Services/Imaging-Center/For-Physicians/Cardiac-Imaging/Cardiac-SPECT/SPECT.JPG
http://www.mayoclinic.org/diseases-conditions/heart-failure/basics/symptoms/con-20029801

Heart failure: diagnosis (magnetic resonance imaging)

Cardiac magnetic resonance imaging (MRI) provides accurate images of cardiac structures and is becoming more widely available

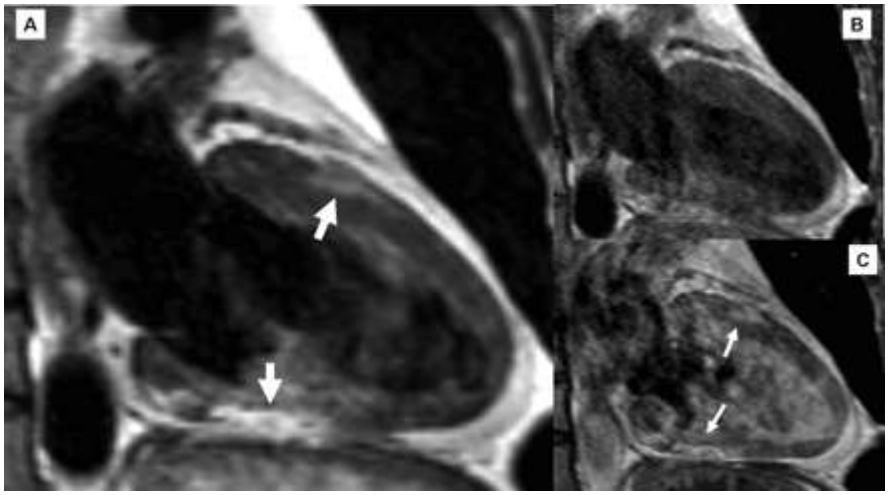

T2-weighted dark-blood imaging of the left ventricular long axis showing high signal intensity in the left ventricular anterior and inferior wall, a sign of myocardial edema. A, T1-weighted dark-blood imaging (early enhancement) shows high signal intensity directly after gadolinium administration in the corresponding area of the anterior left ventricular wall. Arrows indicate myocardial edema. B, T1-weighted imaging before gadolinium administration. C, Arrows indicate myocardial early enhancement.

http://circ.ahajournals.org/content/123/13/1451/F3.medium.gif http://www.mayoclinic.org/diseases-conditions/heart-failure/basics/symptoms/con-20029801

Heart failure: diagnosis (NP/BNP or N-terminal-pro-BNP levels)

- Serum NP/BNP levels are high in heart failure (HF); this finding may help when clinical findings are unclear or other diagnoses (e.g., chronic obstructive pulmonary disease (COPD)) need to be excluded
- It may be particularly useful for patients with a history of both pulmonary and cardiac disorders
- NT-pro-BNP, an inactive moiety created when pro BNP is cleaved, can be used similarly to NP/BNP

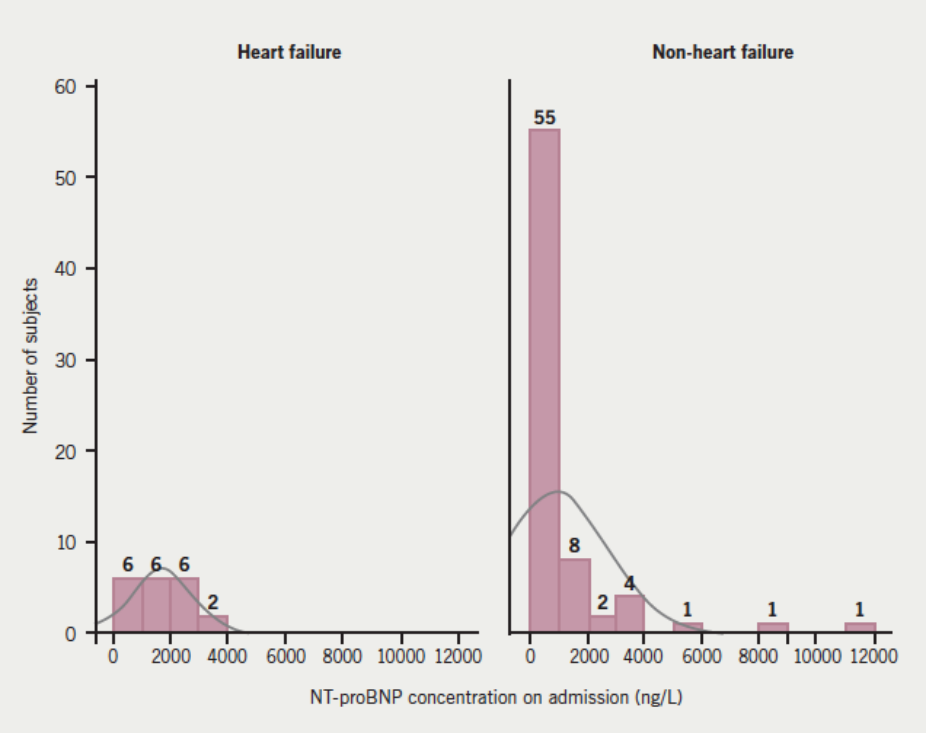

http://bjcardio.co.uk/files/uploads/2014/12/Figure-1.png http://www.mayoclinic.org/diseases-conditions/heart-failure/basics/symptoms/con-20029801

Heart failure: diagnosis (the Framingham criteria)

- Diagnosis of congestive heart failure requires the simultaneous presence of at least 2 of the following major criteria or 1 major criterion in conjunction with 2 of the following minor criteria
- Major criteria include an enlarged heart on a chest x-ray, an S3 gallop (a third heart sound), acute pulmonary edema, episodes of waking up from sleep gasping for air, crackles on lung auscultation, central venous pressure of more than 16 cm H_2O at the right atrium, jugular vein distension, positive abdomino jugular test, and weight loss of more than 4.5 kg in 5 days in response to treatment
- Minor criteria include an abnormally fast heart rate of more than 120 beats per minute, nocturnal cough, difficulty breathing with physical activity, pleural effusion, a decrease in the vital capacity by one third from maximum recorded, liver enlargement, and bilateral ankle swelling

https://en.wikipedia.org/wiki/Heart_failure

Heart failure: stage (the American College of Cardiology classification)

Stage	Definition of Stage
A	High risk of heart failure (HF) but no structural heart disease or symptoms
B	Structural heart disease but no symptoms of HF
C	Structural heart disease with symptoms of HF
D	Refractory HF requiring specialized interventions

Medscape® www.medscape.com

Stages of heart failure (CHF)

A – Asymptomatic high risk patients

B – Myocardial damage without symptoms

C – LV systolic dysfunction and symptomatic CHF

D – End-stage or refractory chronic heart failure

Source: Geriatrics Aging © 2008 1453987 Ontario, Ltd.

http://img.medscape.com/fullsize/migrated/579/830/ga579830.tab1.gif http://www.merckmanuals.com/professional/cardiovascular-disorders/heart-failure/heart-failure-hf

Heart failure:
Class (New York Heart Association (NYHA) Classification)

NYHA Class	Definition	Limitation
I	Ordinary physical activity does not cause undue fatigue, dyspnea, or palpitations.	None
II	Ordinary physical activity causes fatigue, dyspnea, palpitations, or angina.	Mild
III	Comfortable at rest; less than ordinary physical activity causes fatigue, dyspnea, palpitations, or angina.	Moderate
IV	Symptoms occur at rest; any physical activity increases discomfort.	Severe

http://www.merckmanuals.com/professional/cardiovascular-disorders/heart-failure/heart-failure-hf

Heart failure:
Class (New York Heart Association (NYHA) Classification)

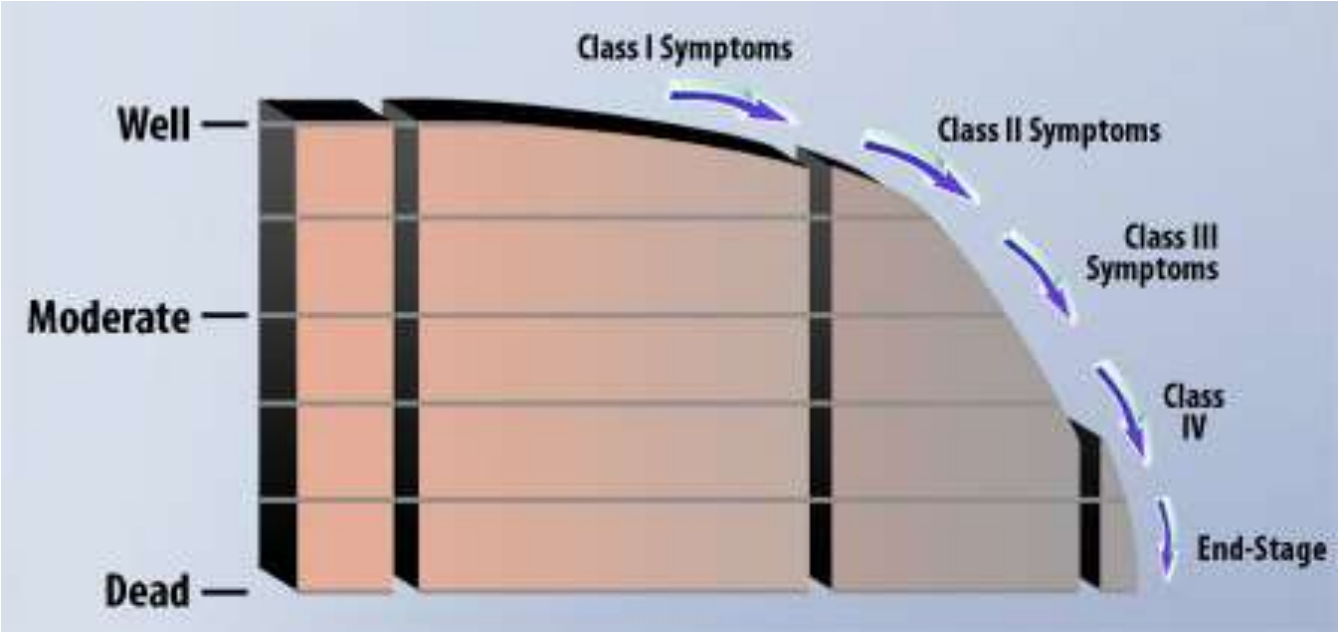

http://reliantheart.com/wp-content/uploads/2013/04/newyorkclasses-big.jpg

Glossary of cardiovascular pathology' terms 1

Abdomen - The area of the body between the bottom of the ribs and the top of the thighs.
Abdominal aorta - The portion of the aorta in the abdomen.
Ablation - Elimination or removal.
ACE (angiotensin-converting enzyme) inhibitor - A medicine that lowers blood pressure by interfering with the breakdown of a protein-like substance involved in blood pressure regulation
Acetylcholine - A type of chemical (called a neurotransmitter) that transmits messages among nerve cells and muscle cells.
Acquired heart disease - Heart disease that arises after birth, usually from infection or through the build-up of fatty deposits in the arteries that feed the heart muscle.
Alveoli - Air sacs in the lungs where oxygen and carbon dioxide are exchanged.
Amiodarone - A kind of medicine (called an antiarrhythmic) used to treat irregular heart rhythms such as atrial fibrillation and ventricular tachycardia. It works by regulating nerve impulses in your heart. Amiodarone is mainly given to patients who have not responded to other antiarrhythmic medicines

Aneurysm - A sac-like protrusion from a blood vessel or the heart, resulting from a weakening of the " (see below). **Ischemia** - Decreased blood flow to an organ, usually due to constriction or obstruction of an artery.
Ischemic heart disease - Also called coronary artery disease and coronary heart disease, this term is applied to heart problems caused by narrowing of the coronary arteries, thereby causing a decreased blood supply to the heart.
Ischemic stroke - A type of stroke that is caused by blockage in a blood vessel.
Jugular veins - The veins that carry blood back from the head to the heart.
Left ventricular assist device (LVAD) - A mechanical device that can be placed outside the body or implanted inside the body. An LVAD does not replace the heart—it "assists" or "helps" it pump oxygen-rich blood from the left ventricle to the rest of the body.

http://www.texasheart.org/HIC/Gloss/

Glossary of cardiovascular pathology' terms 2

Lesion - An injury or wound. An atherosclerotic lesion is an injury to an artery due to hardening of the arteries.
Lipid - A fatty substance that is insoluble (cannot be dissolved) in the blood.
Lipoprotein - A lipid surrounded by a protein; the protein makes the lipid soluble (can be dissolved) in the blood.
Low density lipoprotein (LDL) - The body's primary cholesterol-carrying molecule. High blood levels of LDL increase a person's risk of heart disease by promoting cholesterol attachment and accumulation in blood vessels; hence, the popular nickname "bad cholesterol."
Lumen - The hollow area within a tube, such as a blood vessel.
Magnetic resonance imaging (MRI) - A technique that produces images of the heart and other body structures by measuring the response of certain elements (such as hydrogen) in the body to a magnetic field. MRI can produce detailed pictures of the heart and its various structures without the need to inject a dye.
Maze surgery - A type of heart surgery that is used to treat chronic atrial fibrillation by creating a surgical "maze" of new electrical pathways to let electrical impulses travel easily through the heart. Also called the Maze procedure.
Mitral stenosis - A narrowing of the mitral valve, which controls blood flow from the heart's upper left chamber to its lower left chamber. May result from an inherited (congenital) problem or from rheumatic fever.
Mitral valve - The structure that controls blood flow between the heart's left atrium (upper chamber) and left ventricle (lower chamber).
Mitral valve prolapse - A condition that occurs when the leaflets of the mitral valve between the left atrium and left ventricle bulge into the atrium and permit backflow of blood. The condition can be associated with progressive mitral regurgitation.
Mitral valve regurgitation - Failure of the mitral valve to close properly, causing blood to flow back into the heart's upper left chamber (the left atrium) instead of moving forward into the lower left chamber (the left ventricle).
mm Hg - An abbreviation for millimeters of mercury. Blood pressure is measured in units of mm Hg—how high the pressure inside the arteries would be able to raise a column of mercury.

http://www.texasheart.org/HIC/Gloss/

Glossary of cardiovascular pathology' terms 3

Monounsaturated fats - A type of fat found in many foods but mainly in avocados and in canola, olive, and peanut oils. Monounsaturated fat tends to lower LDL cholesterol levels, and some studies suggest that it may do so without also lowering HDL cholesterol levels.
Mortality - The total number of deaths from a given disease in a population during an interval of time, usually a year.
Murmur - Noises superimposed on normal heart sounds. They are caused by congenital defects or damaged heart valves that do not close properly and allow blood to leak back into the chamber from which it has come.
Myocardial infarction - A heart attack. The damage or death of an area of the heart muscle (myocardium) resulting from a blocked blood supply to the area. The affected tissue dies, injuring the heart. Symptoms include prolonged, intensive chest pain and a decrease in blood pressure that often causes shock.
Myocardial ischemia - Occurs when a part of the heart muscle does not receive enough oxygen.
Myocarditis – A rare condition in which the heart muscle becomes inflamed as a result of infection, toxic drug poisoning, or diseases like rheumatic fever, diphtheria, or tuberculosis.
Myocardium - The muscular wall of the heart. It contracts to pump blood out of the heart and then relaxes as the heart refills with returning blood.
Myxomatous degeneration - A connective tissue disorder that causes the heart valve tissue to weaken and lose elasticity.
Nitroglycerin - A medicine that helps relax and dilate arteries; often used to treat cardiac chest pain (angina).
Necrosis - Refers to the death of tissue within a certain area.
Noninvasive procedures - Any diagnostic or treatment procedure in which no instrument enters the body.
NSTEMI - Non-ST-segment-elevation myocardial infarction. The milder form of the 2 types of heart attack, an NSTEMI does not produce an ST-segment elevation on an electrocardiogram. See also STEMI.

http://www.texasheart.org/HIC/Gloss/

Glossary of cardiovascular pathology' terms 4

Obesity - The condition of being significantly overweight. It usually applies when a person is 30% or more over ideal body weight. Obesity puts a strain on the heart and can increase the risk of developing high blood pressure and diabetes.
Occluded artery - An artery in which the blood flow has been impaired by a blockage.
Open heart surgery - An operation in which the chest and heart are opened surgically while the bloodstream is diverted through a heart-lung (cardiopulmonary bypass) machine.
Pacemaker - A surgically implanted electronic device that helps regulate the heartbeat.
Palpitation - An uncomfortable feeling within the chest caused by an irregular heartbeat.
Pancreas - The organ behind the stomach that helps control blood sugar levels.
Pancreatitis - Swelling (inflammation) of the pancreas.
Paralysis -Loss of the ability to move muscles and feel in part of the body or the whole body. Paralysis may be temporary or permanent.

Paroxysmal supraventricular tachycardia (PSVT) – An occasional rapid heart rate (150-250 beats per minute) that is caused by events triggered in areas above the heart's lower chambers (the ventricles). See also supraventricular tachycardia (SVT).
Patent ductus arteriosus - A congenital defect in which the opening between the aorta and the pulmonary artery does not close after birth.

Patent foramen ovale - An opening between the left and right atria (the upper chambers) of the heart. Everyone has a PFO before birth, but in 1 out of every 3 or 4 people, the opening does not close naturally, as it should, after birth.

Percutaneous coronary intervention (PCI)- Any of the noninvasive procedures usually performed in the cardiac catheterization laboratory. Angioplasty is an example of a percutaneous coronary intervention. Also called a transcatheter intervention.

http://www.texasheart.org/HIC/Gloss/

Glossary of cardiovascular pathology' terms 5

Percutaneous transluminal coronary angioplasty (PTCA) - See angioplasty.
Pericarditis - Inflammation of the outer membrane surrounding the heart. When pericarditis occurs, the amount of fluid between the two layers of the pericardium increases. This increased fluid presses on the heart and restricts its pumping action.
Pericardiocentesis - A diagnostic procedure that uses a needle to withdraw fluid from the sac or membrane surrounding the heart (pericardium).
Pericardium - The outer fibrous sac that surrounds the heart.
Plaque - A deposit of fatty (and other) substances in the inner lining of the artery wall characteristic of atherosclerosis.
Platelets - One of the three types of cells found in blood; they aid in the clotting of blood.
Polyunsaturated fat - The major fat in most vegetable oils, including corn, safflower, sunflower, and soybean oils. These oils are liquid at room temperature. Polyunsaturated fat actually tends to lower LDL cholesterol levels but may reduce HDL cholesterol levels as well.
Positron emission tomography (PET) - A test that uses information about the energy of certain elements in your body to show whether parts of the heart muscle are alive and working. A PET scan can also show if your heart is getting enough blood to keep the muscle healthy.
Postural orthostatic tachycardia syndrome (POTS) - A disorder that causes an increased heart rate when a person stands upright.
Premature ventricular contraction (PVC) - An early or extra heartbeat that happens when the heart's lower chambers (the ventricles) contract too soon, out of sequence with the normal heartbeat.
Prevalence - The total number of cases of a given disease that exist in a population at a specific time.
Pulmonary - Refers to the lungs and respiratory system.
Pulmonary embolism - A condition in which a blood clot that has formed elsewhere in the body travels to the lungs.

http://www.texasheart.org/HIC/Gloss/

Glossary of cardiovascular pathology' terms 6

Pulmonary valve - The heart valve between the right ventricle and the pulmonary artery that controls blood flow from the heart into the lungs.
Pulmonary vein - The blood vessel that carries newly oxygenated blood from the lungs back to the left atrium of the heart.
Radial artery access - Using the radial artery in the wrist as the entry point for the catheter in an angioplasty or stent procedure. Also called transradial access, the transradial approach, or transradial angioplasty.
Radionuclide imaging - A test in which a harmless radioactive substance is injected into the bloodstream to show information about blood flow through the arteries. Damaged or dead heart muscle can often be identified, as can serious narrowing in an artery.
Radionuclide studies - Any of the diagnostic tests in which a small amount of radioactive material is injected into the bloodstream. The material makes it possible for a special camera to take pictures of the heart.
Radionuclide ventriculography - A diagnostic test used to determine the size and shape of the heart's pumping chambers (the ventricles).
Regurgitation - Backward flow of blood through a defective heart valve.
Renal - Pertains to the kidneys.
Restenosis- The re-closing or re-narrowing of an artery after an interventional procedure such as angioplasty or stent placement.
Revascularization - A procedure to restore blood flow to the tissues. Coronary artery bypass surgery is an example of a revascularization procedure.
Rheumatic fever - A disease, usually occurring in childhood, that may follow a streptococcal infection. Symptoms may include fever, sore or swollen joints, skin rash, involuntary muscle twitching, and development of nodules under the skin. If the infection involves the heart, scars may form on heart valves, and the heart's outer lining may be damaged.

http://www.texasheart.org/HIC/Gloss/

Glossary of cardiovascular pathology' terms 7

Rheumatic heart disease - A disease of the heart (mainly affecting the heart valves) caused by rheumatic fever.
Right ventricular assist device (RVAD) - A mechanical device that can be placed outside the body or implanted inside the body. An RVAD does not replace the heart—it "assists" or "helps" it pump oxygen-poor blood from the right ventricle to the lungs.
Risk factor - An element or condition involving a certain hazard or danger. When referring to heart and blood vessels, a risk factor is associated with an increased chance of developing cardiovascular disease, including stroke.
Rubella - Commonly known as German measles.
Saccular aneurysm - A round aneurysm that bulges out from an artery; involves only part of the circumference (outside wall) of the artery.
Sarcoidosis - An inflammatory disease that starts as tiny, grain-like lumps called granulomas, which most often appear in your lungs or lymph nodes. The granulomas can clump together and form larger lumps that attack other organs. Sarcoidosis often affects your skin, eyes, or liver, but it can lead to heart problems, such as irregular heartbeats (arrhythmias) or restrictive cardiomyopathy.
Saturated fat - Type of fat found in foods of animal origin and a few of vegetable origin; they are usually solid at room temperature. Abundant in meat and dairy products, saturated fat tends to increase LDL cholesterol levels, and it may raise the risk of certain types of cancer.
Second-degree heart block - Impulses traveling through the heart's upper chambers (the atria) are delayed in the area between the upper and lower chambers (the AV node) and fail to make the ventricles beat at the right moment.
Septal defect - A hole in the wall of the heart separating the atria or in the wall of the heart separating the ventricles.
Septum - The muscular wall dividing a chamber on the left side of the heart from the chamber on the right.
Sheath - A catheter-like tube that is placed inside a patient's vessel during an interventional procedure to help the doctor with insertion and proper placement of the actual catheter. Also called an introducer sheath.

http://www.texasheart.org/HIC/Gloss/

Glossary of cardiovascular pathology' terms 8

Shock - A condition in which body function is impaired because the volume of fluid circulating through the body is insufficient to maintain normal metabolism. This may be caused by blood loss or by a disturbance in the function of the circulatory system.
Shunt - A connector that allows blood to flow between two locations.
Sick sinus syndrome - The failure of the sinus node to regulate the heart's rhythm.
Silent ischemia - Episodes of cardiac ischemia that are not accompanied by chest pain.
Sinus (SA) node - The "natural" pacemaker of the heart. The node is a group of specialized cells in the top of the right atrium which produces the electrical impulses that travel down to eventually reach the ventricular muscle, causing the heart to contract.
Sodium - A mineral essential to life found in nearly all plant and animal tissue. Table salt (sodium chloride) is nearly half sodium.
Sphygmomanometer - An instrument used to measure blood pressure.
Stem cells - Special cells in the body that are able to transform into other cells. It is possible for stem cells to transform into heart cells, nerve cells, or other cells of the body, possibly helping to improve the function of failing organs, including the heart.
STEMI - ST-segment-elevation myocardial infarction. The more severe form of the 2 types of heart attack. See also NSTEMI. A STEMI produces a characteristic elevation in the ST segment on an electrocardiogram.
Stent - A device made of expandable, metal mesh that is placed (by using a balloon catheter) at the site of a narrowing artery. The stent is then expanded and left in place to keep the artery open.
Stenosis - The narrowing or constriction of an opening, such as a blood vessel or heart valve.
Stethoscope - An instrument for listening to sounds within the body.

http://www.texasheart.org/HIC/Gloss/

Glossary of cardiovascular pathology' terms 9

Stokes-Adams disease - Also called third-degree heart block; a condition that happens when the impulses that pace your heartbeat do not reach the lower chambers of your heart (the ventricles). To make up for this, the ventricles use their own "backup" pacemaker with its slower rate. This rhythm can cause severe dizziness or fainting and can lead to heart failure or death.
Streptococcal infection ("strep" infection) - An infection, usually in the throat, resulting from the presence of streptococcus bacteria.
Streptokinase - A clot-dissolving medicine used to treat heart attack patients.
Sternum - The breastbone.
Stress - Bodily or mental tension resulting from physical, chemical, or emotional factors. Stress can refer to physical exertion as well as mental anxiety.
Stroke - A sudden disruption of blood flow to the brain, either by a clot or a leak in a blood vessel.
Subarachnoid hemorrhage - Bleeding from a blood vessel on the surface of the brain into the space between the brain and the skull.
Subclavian arteries - Two major arteries (right and left) that receive blood from the aortic arch and supply it to the arms.
Sudden death - Death that occurs unexpectedly and instantaneously or shortly after the onset of symptoms. The most common underlying reason for patients dying suddenly is cardiovascular disease, in particular coronary heart disease.
Superior vena cava - The large vein that returns blood from the head and arms to the heart.
Supraventricular tachycardia (SVT) - A regular rapid heart rate (150-250 beats per minute) that is caused by events triggered in areas above the heart's lower chambers (the ventricles); see also paroxysmal supraventricular tachycardia (PSVT).

http://www.texasheart.org/HIC/Gloss/

Glossary of cardiovascular pathology' terms 10

Syncope - A temporary, insufficient blood supply to the brain which causes a loss of consciousness. Usually caused by a serious arrhythmia.
Systolic blood pressure - The highest blood pressure measured in the arteries. It occurs when the heart contracts with each heartbeat.
Tachycardia - Accelerated beating of the heart. Paroxysmal tachycardia is a particular form of rapid heart action, occurring in seizures that may last from a few seconds to several days.
Tachypnea - Rapid breathing.
Tamponade - Also called cardiac tamponade. A condition in which the heart is compressed or constricted because of a large amount of fluid or blood in the space between the heart muscle and the sac that surrounds the heart (the pericardium).
Thallium-201 stress test - An x-ray study that follows the path of radioactive potassium carried by the blood into heart muscle. Damaged or dead muscle can be defined, as can the extent of narrowing in an artery.
Third-degree heart block - A serious condition also called Stokes-Adams disease; impulses from the heart's upper chambers (the atria) are completely blocked from reaching the heart's lower chambers (the ventricles). To make up for this, the ventricles use their own "backup" pacemaker with its slower rate.
Thrombolysis - The breaking up of a blood clot.
Thrombosis - A blood clot that forms inside the blood vessel or cavity of the heart.
Thrombolytic therapy - Intravenous or intra-arterial medicines that are used to dissolve blood clots in an artery.
Thrombus - A blood clot.
Thyroid - A gland located in the front of the neck, just below the voice box.
Tissue plasminogen activator (tPA) - A clot-dissolving medicine that is used to treat heart attack and stroke patients.

http://www.texasheart.org/HIC/Gloss/

Glossary of cardiovascular pathology' terms 11

Trans fat - Created when hydrogen is forced through an ordinary vegetable oil (hydrogenation), converting some polyunsaturates to monounsaturates, and some monounsaturates to saturates. Trans fat, like saturated fat, tends to raise LDL cholesterol levels, and, unlike saturated fat, trans fat also lowers HDL cholesterol levels.
Transcatheter aortic valve implantation (TAVI) - A minimally invasive procedure to repair a damaged or diseased aortic valve. A catheter is inserted into an artery in the groin and threaded to the heart. A balloon at the end of the catheter, with a replacement valve folded around it, delivers the new valve to take the place of the old. Also called TAVR (Transcatheter aortic valve replacement).
Transcatheter intervention - Any of the noninvasive procedures usually performed in the cardiac catheterization laboratory. Angioplasty is an example of a transcatheter intervention. Also called a percutaneous coronary intervention (PCI).
Transesophageal echocardiography - A diagnostic test that analyzes sound waves bounced off the heart. The sound waves are sent through a tube-like device inserted in the mouth and passed down the esophagus (food pipe), which ends near the heart. This technique is useful in studying patients whose heart and vessels, for various reasons, are difficult to assess with standard echocardiography.
Transient ischemic attack (TIA) - A stroke-like event that lasts only for a short time and is caused by a temporarily blocked blood vessel.
Transplantation - Replacing a failing organ with a healthy one from a donor.
Tricuspid valve - The structure that controls blood flow from the heart's upper right chamber (the right atrium) into the lower right chamber (the right ventricle).
Triglyceride - The most common fatty substance found in the blood; normally stored as an energy source in fat tissue. High triglyceride levels may thicken the blood and make a person more susceptible to clot formation. High triglyceride levels tend to accompany high cholesterol levels and other risk factors for heart disease, such as obesity.

http://www.texasheart.org/HIC/Gloss/

Glossary of cardiovascular pathology' terms 12

Ultrasound - High-frequency sound vibrations, which cannot be heard by the human ear, used in medical diagnosis.
Valve replacement - An operation to replace a heart valve that is either blocking normal blood flow or causing blood to leak backward into the heart (regurgitation).
Valvuloplasty - Reshaping of a heart valve with surgical or catheter techniques.
Varicose vein - Any vein that is abnormally dilated (widened).
Vascular - Pertains to the blood vessels.
Vasodilators - Any medicine that dilates (widens) the arteries.
Vasopressors - Any medicine that elevates blood pressure.
Vein - Any one of a series of blood vessels of the vascular system that carries blood from various parts of the body back to the heart, returning oxygen-poor blood to the heart.
Ventricle (right and left) - One of the two lower chambers of the heart.
Ventricular Assist Device (VAD) - A mechanical pump that helps the ventricles pump blood, easing the workload of the heart in patients with heart failure.
Ventricular fibrillation - A condition in which the ventricles contract in a rapid, unsynchronized fashion. When fibrillation occurs, the ventricles cannot pump blood throughout the body.
Ventricular tachycardia - An arrhythmia (abnormal heartbeat) in the ventricle characterized by a very fast heartbeat.
Vertigo - A feeling of dizziness or spinning.
Wolff-Parkinson-White syndrome - A condition in which an extra electrical pathway connects the atria (two upper chambers) and the ventricles (two lower chambers). It may cause a rapid heartbeat.
X-ray - Form of radiation used to create a picture of internal body structures on film.

http://www.texasheart.org/HIC/Gloss/