

## Percutaneous Coronary Intervention for Chronic Total Occlusion

Giovanni Maria Vescovo, MD, Carlo Zivelonghi, MD, Benjamin Scott, MD, and Pierfrancesco Agostoni, MD, PhD

*Department of Cardiology, Hartcentrum, Ziekenhuis Netwerk Antwerpen Middelheim, Antwerp, Belgium*

### Abstract

Treatment of coronary chronic total occlusions represents one of the major challenges in the field of interventional cardiology. This is due to the complexity of these procedures and to the relatively higher risk of complications. In recent years, the development of innovative techniques and the evolution of materials have produced significant progress in this field. Better procedural outcomes have been achieved, with fewer complications. This article highlights the most recent scientific evidence and techniques, with the intention to guide interventional cardiologists in optimal patient selection and procedure choice.

### Keywords

Chronic total occlusion, angina, quality of life, antegrade approach, retrograde approach, dissection and re-entry technique

**Disclosure:** The authors have no conflicts of interest to declare.

**Received:** February 28, 2020 **Accepted:** July 7, 2020 **Citation:** *US Cardiology Review* 2020;14:e11. **DOI:** <https://doi.org/10.15420/usc.2020.10>

**Correspondence:** Pierfrancesco Agostoni, Department of Cardiology, Hartcentrum, Ziekenhuis Netwerk Antwerpen Middelheim, Lindendreef 1, 2020 Antwerp, Belgium. E: [agostonipf@gmail.com](mailto:agostonipf@gmail.com)

**Open Access:** This work is open access under the CC-BY-NC 4.0 License which allows users to copy, redistribute and make derivative works for non-commercial purposes, provided the original work is cited correctly.

Coronary chronic total occlusion (CTO), defined as complete occlusion of a coronary artery for at least 3 months with thrombolysis in myocardial infarction (TIMI) grade 0 flow, represents one of the most complex situations in the field of interventional cardiology.<sup>1</sup> Despite an incidence of CTO in patients with stable coronary artery disease (CAD) undergoing coronary angiography of 18–46%, the number of percutaneous coronary interventions (PCIs) for CTO is still less than 4% of all percutaneous revascularizations.<sup>2–4</sup>

In fact, the high rate of complications and failures of CTO revascularization, together with the lack of supporting data from randomized clinical trials, discourage interventional cardiologists from embracing this procedure. However, thanks to the progress of technology and to greater operator experience, the percentage of successful revascularizations has increased over the years, reaching approximately 90% in specialized centers.<sup>5</sup> In addition, the number of procedural complications and adverse clinical events has also decreased significantly.<sup>6</sup> Although randomized trials conducted so far have failed to demonstrate superiority of CTO revascularization strategies over medical therapy alone in terms of hard endpoints, observational studies and meta-analysis suggest a wide range of benefits of interventional treatment.<sup>7–9</sup>

### Anatomy of Chronic Total Occlusion

In the context of CTO treatment, the assessment of risks and benefits of the intervention and the planning of the procedure are essential to achieve a successful revascularization. The first step is to carefully analyze the anatomy of the occlusion and the presence of collateral

circulation. To do this, it is necessary to obtain accurate coronary angiography. Several authors suggest the use of simultaneous double coronary injection every time contralateral collateral circulation is present. This consists of injecting the contrast at the level of the donor vessel, followed 2–3 seconds later by injection into the CTO target vessel. During dual injection angiographic film exposure should be prolonged and the image acquired at low magnification avoiding panning, in order to gain a precise definition of both the lesion and collateral vessels.<sup>10</sup>

CTO consists of an atherosclerotic plaque and a thrombotic component that can be homogeneous or made up of several layers of differently organized tissues as a result of multiple thrombotic episodes occurring at different times.<sup>11</sup> The proximal endoluminal part of the plaque (proximal cap) can be more or less hard depending on the age of the occlusion. Usually older lesions have a calcific cap that is more difficult to cross. Conversely, more recent occlusions are characterized by a softer cap that is easier to cross. The proximal cap is morphologically classified in three ways: blunt, tapered, and ambiguous. A tapered cap is usually less resistant to penetration than a blunt cap, making it crossable with low penetration force guidewires. In the case of proximal cap ambiguity, defined as the inability to accurately define the subsequent course of the vessel, it may be necessary to use a selective contrast injection with microcatheter, intravascular ultrasound (IVUS), or coronary CT angiography (CCTA) in order to better define the cap anatomy.<sup>12,13</sup>

To correctly define the complexity of the lesion, other characteristics such as length, tortuosity and composition of the occlusion should be defined.

**Table 1: Randomized Controlled Trials on the Efficacy of Percutaneous Coronary Intervention in Chronic Total Occlusion Versus Medical Therapy**

Study	Design	Population	Patients (n)	Primary Endpoint	Follow-up	Results	CTO Success Rate (%)
DECISION-CTO <sup>14</sup>	Multicenter	Silent ischemia, stable angina, ACS	834	Composite of death from any cause, MI, stroke, or any revascularization.	4 years	No differences between groups (p=0.86)	91
EuroCTO <sup>15</sup>	Multicenter	Symptoms and/or ischemia and viability	396	Change in health status assessed on the SAQ	12 months	Greater improvements in health status in the PCI group (p=0.007)	87
IMPACTOR-CTO <sup>16</sup>	Single center RCT	RCA CTO and stable angina	72	Decrease in MIB from baseline to 12-month control	12 months	Decrease in MIB was significantly higher in the PCI group (p<0.01)	83
EXPLORE <sup>20</sup>	Multicenter RCT	STEMI with coexisting CTO	304	LVEF and LVEDV on cMRI after 4 months	4 months	No differences between groups (LVEF: p=0.60; LVEDV: p=0.70)	73
REVASC <sup>22</sup>	Single center	Symptoms and/or non-invasive functional testing	205	Change in SWT in the CTO territory	12 months	No differences between groups (p=0.57)	97

ACS = acute coronary syndrome; cMRI = cardiovascular MRI; CTO = chronic total occlusion; LVEDV = left ventricular end-diastolic volume; LVEF = left ventricular ejection fraction; LVEDV = left ventricular end-diastolic volume; MIB = myocardial ischemia burden; PCI, percutaneous coronary intervention; RCA = right coronary artery; RCT = randomized controlled trial; SAQ = Seattle Angina Questionnaire; STEMI = ST-elevation MI; SWT = segmental wall thickening.

Long (>20 mm), tortuous, and calcified chronic occlusions make lesion crossing more difficult. They are also associated with a higher complication rate. Finally, the presence, size, and course of collateral vessels are fundamental to the planning of a retrograde approach, which may be the strategy of choice in the case of ambiguous lesions or antegrade technique failure.

## Rationale for Revascularization of Chronic Total Occlusion Symptoms and Quality of Life

It is widely established that CTO PCI carries advantages in terms of improving symptoms compared with drug therapy alone. Looking at randomized trials in which angina and quality of life (QoL) were taken as endpoints, only the Drug-Eluting stent Implantation versus optimal Medical Treatment in patients with Chronic Total Occlusion (DECISION CTO) study failed to demonstrate superiority of PCI compared with pharmacological treatment.<sup>14</sup> In contrast, the Randomized Multicentre Trial to Evaluate the Utilization of Revascularization or Optimal Medical Therapy for the Treatment of Chronic Total Coronary Occlusions (EuroCTO study) and the Impact on Inducible Myocardial Ischemia of Percutaneous Coronary Intervention versus Optimal Medical Therapy in Patients with Right Coronary Artery Chronic Total Occlusion (IMPACTOR CTO study) showed, at 1-year follow-up, advantages of percutaneous revascularization in reducing angina and improving QoL, assessed with the Seattle Angina Questionnaire (SAQ; *Table 1*).<sup>15,16</sup>

These differences could be due to the limitations found in the DECISION CTO trial, such as the slow and early termination of enrollment, the high percentage of cross-over in both arms, the high frequency of PCI for non-CTO lesions and the inclusion of patients with mild or absent symptoms.<sup>14</sup> Moreover, the study was not focused specifically on CTO-only lesions: many patients with multivessel disease and one CTO were randomized to PCI of all vessels besides CTO, versus PCI of everything including CTO

(thus the real impact of CTO on symptoms was not assessed). Finally, in the first days after randomization there was a cross-over rate of approximately 20% from the conservative to the PCI treatment, which may also have affected the final results.<sup>14</sup>

A recent study conducted by Hirai et al. analyzed 1,000 consecutive patients with high-grade refractory angina undergoing CTO PCI and showed that successful revascularization leads to higher improvement in the SAQ Angina Frequency and SAQ Summary Scores compared with unsuccessful PCI (35.0 ± 26.8 versus 18.8 ± 28.9, p<0.01; and 34.2 ± 19.4 versus 22.5 ± 20.8, p<0.01, respectively).<sup>17</sup> This suggests that patients who may receive greater benefit from CTO revascularization are those with the highest degree of ischemia.

Further confirmation of the efficacy of percutaneous revascularization in terms of improvement of symptoms was obtained from a meta-analysis conducted by Joyal et al., with a lower persistence of angina in the group of patients who underwent successful revascularization.<sup>18</sup> A better QoL, due to improvement of the depression-related symptoms common in patients with CAD, was also seen.<sup>19</sup> The presence of refractory angina can lead to psychological distress and a depressive state. From this point of view, revascularization of CTO could lead to an improvement in health status in patients with angina and depression, as reported by Yeh et al.<sup>19</sup>

## Regional and Global Left Ventricular Dysfunction

The improvement of left ventricular (LV) systolic function in patients undergoing CTO PCI is one of the most explored outcomes. In the randomized controlled multicenter trial Evaluating Xience and Left Ventricular Function in Percutaneous Coronary Intervention on Occlusions After ST-Elevation Myocardial Infarction (EXPLORE), 304 patients with ST-elevation MI (STEMI) and coexisting CTO in a non-infarct-related vessel were enrolled.<sup>20</sup> The aim of the study was to evaluate, using MRI, the improvement of LV function and the reduction of LV end-diastolic volume

**Table 2: Chronic Total Occlusion Scoring Systems**

Score	J-CTO <sup>34</sup>	RECHARGE <sup>36</sup>	PROGRESS CTO <sup>39</sup>	CL <sup>37</sup>	CASTLE <sup>35</sup>
Characteristics assessed	Blunt stump (1) Length >20 mm (1) Intralesion bending ≥45° (1) Mild–severe calcification (1) Previous CTO failure (1)	Blunt stump (1) Length >20 mm (1) Intralesion bending ≥45° (1) Visible calcification in the CTO segment (1) Bypassed on the CTO target vessel (1) Diseased distal landing zone (1)	Ambiguous proximal cap (1) Circumflex target vessel (1) Moderate/severe proximal tortuosity (1)* Lack of interventional collateral vessels (1)	Blunt stump (1) Length >20 mm (1.5) Non-left anterior descending artery (1) Severe calcification (2) Previous CABG or MI (1.5)	Blunt or no stump (1) Length >20 mm (1) Severe/unseen tortuosity (1) <sup>†</sup> Severe calcification (1) Age >70 years (1) Previous CABG (1)
Probability of success or failure	Successful guidewire crossing in <30 min 0: 92.3% 1: 58.3% 2: 34.8% ≥3: 22.2%	Technical success 0–1: 98% 2: 90% 3: 73% 4: 69% 5: 44% 6: 14%	Technical success 0: 98.2% 1: 97.5% 2: 91.6% ≥3: 76.7%	Technical success 0–1: 88.3% 1.5–2.5: 73.1% 3–4.5: 59.4% ≥5%: 46.2%	CTO failure 0: 5.8% 1: 9.3% 2: 14.5% 3: 22.1% 4: 32.3% 5: 44.7% 6: 56.5%

\*Moderate/severe tortuosity = 2 bends >70° or 1 bend >90°. †Severe = ≥2 pre-occlusive bends >90° or ≥1 bend >120°. CABG = coronary artery bypass grafting; CL score = clinical and related lesion score; CTO = chronic total occlusion.

in patients treated with PCI compared with those on medical therapy alone. The study showed, no advantages of PCI compared with drug treatment at 4 months after the acute event. However, the slow enrollment (leading to potential selection bias) and the relatively low PCI success rate (73%) may have affected the results. Moreover, the evaluation of the outcome only 4 months after randomization could have represented a further limitation. And, as evidenced by Bondarenko et al., myocardial recovery in many cases may be delayed.<sup>21</sup>

Similarly to the EXPLORE trial, the Recovery of Left Ventricular Function After Stent Implantation in Chronic Total Occlusion of Coronary Arteries (REVASC) trial at 1 year showed no differences between the two groups (CTO PCI versus medical therapy) in terms of changes in segmental wall thickening (SWT) in the CTO territory.<sup>22</sup> However, the result could have been influenced by the revascularization of non-CTO stenosis in the group treated with medical therapy. Also, PCI for non-CTO lesions may have increased the flow in the collateral circulation, leading to recovery of areas of hibernating myocardium even in the group of patients without CTO PCI. This speculation arose from subgroup analysis that showed, in patients with less complex CAD (SYNTAX score <13), an improvement in SWT only in patients undergoing CTO revascularization. A further limitation of the study was the lack of assessment of myocardial viability on MRI. SWT was shown to improve significantly only in segments with <75% transmural infarct, with a significant remaining viable myocardium.<sup>23</sup> Finally, in patients included in the study, mean LV ejection fraction (LVEF) was normal.<sup>22</sup> A recent meta-analysis of 34 studies with a total of 2,804 patients, by Megaly et al., showed that successful revascularization of a CTO is associated with a significant increase in LVEF, especially in those with lower baseline values.<sup>24</sup>

### Arrhythmic Events and Sudden Cardiac Death

Chronic total occlusion of an infarct-related coronary artery has been associated with higher risk of ventricular arrhythmia or appropriate ICD shock.<sup>25</sup> Ventricular arrhythmias in patients with previous infarction arise in the myocardial area surrounding the fibrous scar.<sup>26</sup> At this level, in patients with CTO, hypoperfusion could represent an arrhythmic substrate and favor the occurrence of ventricular tachycardia. Therefore, CTO revascularization,

by restoring blood flow in the area close to the fibrotic scar, may generate positive electrical remodeling and reduce arrhythmias. A recent meta-analysis that assessed ventricular arrhythmias in patients with CTO has shown that CTO is associated with an increased risk of ventricular arrhythmia and all-cause mortality.<sup>27</sup> Therefore, it is reasonable to consider defibrillator implantation in patients with an infarct-related CTO.

### Mortality and Major Adverse Cardiac Events

There is a great discordance in the literature between observational studies and randomized clinical trials, regarding hard endpoints such as mortality and major adverse cardiac events (MACE). In the DECISION CTO trial, which assessed all-cause mortality, MI, revascularization, stroke and MACE, no advantages were found in the PCI group compared with medical treatment alone. One of the weaknesses of the study, in addition to those already mentioned above, was the exclusion of patients with LVEF <30% who appear to benefit more from revascularization.<sup>28</sup> In contrast, data from several registries showed an increase in survival in patients undergoing successful recanalization compared with those with unsuccessful PCI.<sup>29,30</sup>

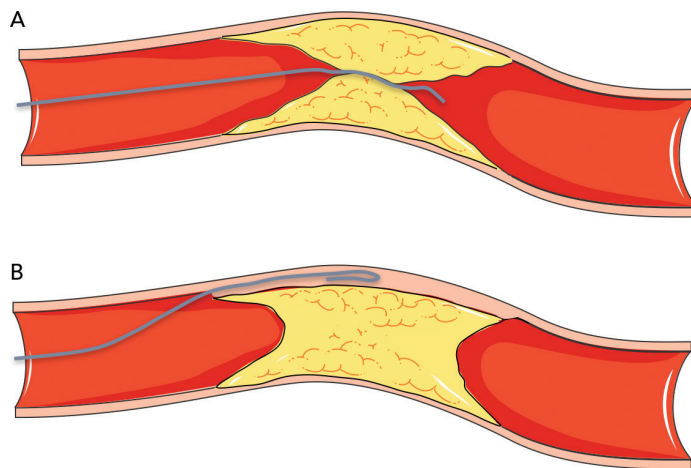
A meta-analysis of 25 studies (28,486 patients) conducted by Christakopoulos et al. showed that compared with failed procedures, successful CTO PCIs were associated with a lower incidence of death, stroke, coronary artery bypass grafting (CABG) and less recurrent angina.<sup>31</sup> Furthermore, another more recent meta-analysis suggested possible advantages of revascularization of CTOs, compared with medical therapy, in terms of all-cause mortality, cardiac death and MACE.<sup>7</sup> Finally, the REVASC study evaluated MACE, defined as total mortality, MI and any clinically driven repeat revascularization, at 12 months as a secondary endpoint. Although the trial was not powered for clinical endpoints, the CTO PCI group had a lower risk of MACE than the group with medical therapy alone.<sup>22</sup>

### Recommendations for Revascularization of Chronic Total Occlusions

Current European and US recommendations for percutaneous revascularization of CTOs are derived from the randomized clinical trials conducted so far. The European guidelines recommend CTO PCI (Class IIa,

# Complex Coronary Intervention

**Figure 1: Crossing a Chronic Total Occlusion: Antegrade Approach**



A: Antegrade wire escalation. B: Antegrade dissection and re-entry with knuckle technique. Modified from Servier Medical Art, licensed under a Creative Commons Attribution 3.0 Generic License. [https://smart.servier.com/smart\\_image/atherosclerosis-34/](https://smart.servier.com/smart_image/atherosclerosis-34/)

level of evidence B), in patients with expected reduction of ischemia in a tributary territory and/or angina relief.<sup>32</sup> At variance with US guidelines, CTO revascularization should be performed by an expert operator in patients with appropriate clinical indication and suitable anatomy.<sup>33</sup>

## Risk Scores

In order to define the degree of lesion complexity and predict the technical success of CTO, several scores have been proposed (Table 2). The Japan-CTO (Multicenter CTO Registry of Japan) score (J-CTO score) was developed to estimate the likelihood of successful guidewire passage of the CTO body within 30 minutes.<sup>34</sup> The score consists of five variables, and 1 point is assigned to each: previous CTO failure; blunt stump of proximal cap; mild–severe calcification; intralumen bending  $\geq 45^\circ$ ; and occlusion length  $>20$  mm. Patients are classified into four grades of difficulty: easy (J-CTO score 0); intermediate (J-CTO score 1); difficult (J-CTO score 2); and very difficult (J-CTO score  $\geq 3$ ).<sup>34</sup> In the EuroCTO (CASTLE) score the variables considered are: CABG history; age (70 years); stump anatomy (blunt or invisible); tortuosity; length of occlusion  $>20$  mm; and extent of calcification.<sup>35</sup> Tortuosity is defined as severe when the CTO vessel contains either two or more pre-occlusive bends  $>90^\circ$  or at least one bend  $>120^\circ$ ; and moderate when it contains two bends  $>70^\circ$  or one bend  $>90^\circ$ . The CTO is defined as straight if the pre-occlusive segment contains a bend  $<70^\circ$ .

Other popular scores are the Prospective Global Registry for the Study of Chronic Total Occlusion Intervention (PROGRESS CTO), the Registry of CrossBoss and Hybrid Procedures in France, the Netherlands, Belgium and United Kingdom (RECHARGE), and the clinical and lesion-related (CL) scores, which have been widely validated, as demonstrated in a meta-analysis by Karatasakis et al.<sup>36–39</sup>

## Strategies to Cross a Chronic Total Occlusion

There are four strategies to cross a CTO: two antegrade and two retrograde. In both approaches, the lesion can be crossed by passing through the true lumen of the vessel or through the subintimal space

(using dissection and re-entry techniques). They are therefore defined as follows: antegrade wire escalation (AWE), antegrade dissection and re-entry (ADR), retrograde wire escalation (RWE), and retrograde dissection and re-entry (RDR).

## Antegrade Approach

The antegrade wire (or AWE) technique consists of advancing various guidewires in an antegrade direction to cross the CTO while remaining within the true lumen of the vessel (true to true). Usually, for proximal cap penetration, tapered polymer guidewires with a low-penetration power soft-tip (Fielder family guidewires; Ashai Intecc), allowing advancement along visible or invisible microchannels, are the preferred first choice. If the operator encounters difficulties in crossing the lesion, they can switch to guidewires with greater penetration force. In general, when the proximal cap is blunt, guidewires with intermediate penetration force (Gaia 2nd–3rd [Ashai Intecc] or Pilot 200 [Abbott Vascular]) are used. If ineffective, guidewires with high penetration force (Conquest Pro 9–12 [Ashai Intecc] or Hornet 10–14 [Boston Scientific]) are used. In addition, the use of a microcatheter, placed near the lesion, may be helpful to increase the support and the penetration power of the guidewire (Figure 1).

Once the proximal cap has been penetrated, de-escalation to less penetrating guidewires can be carried out (quick and precise changing of guidewires is made easier by the presence of a microcatheter, because the path already run by the guidewire followed by a microcatheter does not need to be run again by the new guidewire, which can instead be used immediately at the level where the previous guidewire stopped). There are several methods for advancing the guidewire in the true-to-true lumen technique. In the sliding technique, using tapered polymer guidewires with soft tips, slight rotational movements and cautious advances are used to cross the lesion. The drilling technique, performed when there are harder caps, consists of advancing the guidewire, making rotational movements less than  $90^\circ$ . In the presence of more calcified lesions the operator may proceed with the penetration technique in which stiff guidewires are pushed without rotational movements.

Finally, in the push and torque technique the operator advances and rotates the guidewire until the hardest portion of the plaque is reached and then redirects it to a softer part. Once the lesion is crossed, in order to understand where the guidewire is located, it is necessary to perform the contralateral injection with the acquisition of at least two orthogonal projections. If during the wiring escalation technique, the guidewire accidentally reaches the subintimal space, it is possible to proceed with the dissection and re-entry technique. Alternatively, the guidewire can be left in the subintimal space as a reference, and a second guidewire advanced through the plaque (parallel guidewire technique).<sup>40</sup> The first dissection and re-entry technique to be described was the subintimal tracking and re-entry (STAR) with a knuckled guidewire advanced in the subintimal space (Figure 1B).

The subsequent re-entry into the distal lumen was unpredictable and uncontrollable.<sup>41</sup> This implies that the stent is implanted in a long subintimal tract with higher risk of branch occlusion and vessel restenosis. A more recent technique with a particular flat balloon characterized by the presence of two juxtaposed holes (Stingray; Boston scientific) has been developed, allowing a controlled re-entry and collateral preservation.

Once the balloon has reached the subintimal space beyond the CTO segment, a very stiff guidewire (or the dedicated Stingray guidewire [Boston Scientific] or a Hornet 14 [Boston Scientific] or a Confianza PRO 12 [Ashai Intecc]) is advanced through the hole in the luminal side, to regain the lumen of the distal vessel (*Figure 2*). A recent study conducted by Karatasakis et al. showed that limited dissection and re-entry techniques can lead to a lower risk of restenosis and target vessel revascularization.<sup>42</sup>

### Retrograde Approach

The retrograde approach is mainly used in complex anatomical settings or when antegrade methods have failed. The introduction of the retrograde approach has led to a successful rate of revascularization of approximately 90%.<sup>43</sup> The first step in the retrograde approach is to pass the collaterals. There are several types of collaterals depending on the anatomy of the coronary tree and the specific occlusion: epicardial or septal, contralateral or ipsilateral. Moreover, in post-bypass patients the bypass itself can be used as a conduit to tackle the CTO using a retrograde approach. The careful assessment of collaterals is fundamental to the choice of the most appropriate collateral to cross. The passage of guidewires and microcatheters through the collateral channels is not without risk. One of the most frequent complications of CTO revascularization is coronary perforation, which may occur also during attempts to cross collaterals: specifically, epicardial collaterals are at higher risk for this type of complication due to their anatomical position close to the pericardium.

Conversely, the risk of perforation is lower (but still present) in the case of crossing septal collaterals. Once the collaterals are passed with guidewire (usually soft dedicated guidewires such as Fielder XT-R [Ashai Intecc], Sion [Ashai Intecc], Suoh03 [Ashai Intecc]) and with microcatheter, the next step is to pass in a retrograde fashion the CTO body, from the distal cap to the proximal cap. It is important to note that usually the distal CTO cap is anatomopathologically softer than the proximal cap because it is exposed to lower arterial pressures. This helps for an easier passage of guidewires through the distal CTO cap. In the RWE technique, as well in the AWE technique, guidewires with higher penetration power are progressively inserted into the distal cap (*Figure 3A*). In the case of failure of the true lumen to true lumen retrograde approach, or when a long lesion is present, it is necessary to use a dissection and re-entry technique such as the reverse controlled antegrade and retrograde tracking (CART; *Figure 3B*). With this technique the subintimal space is reached with an antegrade guidewire that is subsequently expanded with a balloon in order to permit the advancement of the retrograde guidewire from the subintimal space back to the true lumen.<sup>44</sup>

### Chronic Total Occlusion Equipment


A deep knowledge of guidewire and microcatheter properties is crucial for any attempt at CTO revascularization.

#### Guidewires

To better understand the peculiarities of each guidewire, it is necessary to analyze every single component. Guidewires are composed of four elements, as follows.

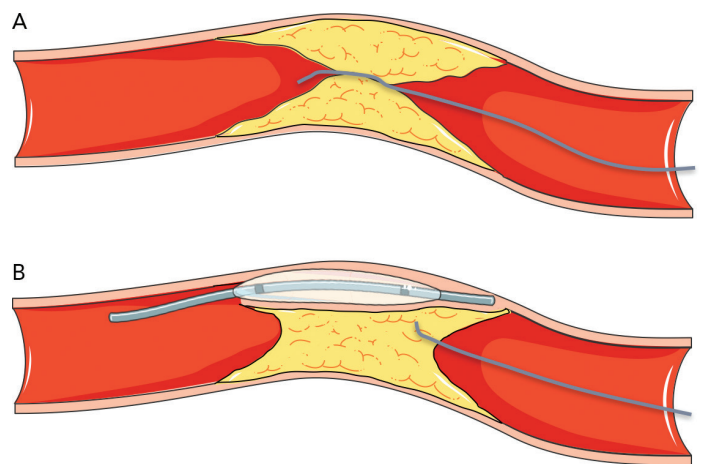
The first element is the core: it is the inner part of the guidewire, which is usually composed of stainless steel, nitinol or both (dual core). In general, a stainless core provides excellent support, pushability (amount of force

**Figure 2: Re-entry Into the Distal Lumen: Controlled Dissection and Re-entry Technique Using Stingray Re-entry System**



A: Stingray balloon is placed into the subintimal space beyond the distal cap of the chronic total occlusion. B: A stiff guidewire is advanced through the hole of the Stingray balloon into the distal lumen of the vessel.

**Figure 3: Crossing a Chronic Total Occlusion: Retrograde Approach**



A: Retrograde wire escalation. B: Reverse controlled antegrade and retrograde tracking. Modified from Servier Medical Art, licensed under a Creative Commons Attribution 3.0 Generic License. [https://smart.servier.com/smart\\_image/atherosclerosis-34/](https://smart.servier.com/smart_image/atherosclerosis-34/)

needed to advance the guidewire once it has penetrated a lesion) and torqueability (ability of the guidewire to transmit efficiently a rotation from the proximal to the distal end). Conversely, the nitinol core has excellent flexibility and trackability (ability of the guidewire to follow the tip around bends and tortuous vessels). Beyond the composition of the core, its thickness is directly related to the support of the guidewire.

The second element is the tip: this is the distal part of the guidewire and has two different designs depending on the extension of the core to the tip. The core-to-tip design consists of a direct connection between the two parts, allowing great torqueability and good tactile feedback. In contrast, when the core is shorter and does not reach the tip a small metal ribbon bridges the gap, ensuring flexibility and good shape retention.

The tip is also responsible for the penetration power (penetrability), defined as the force needed to bend the tip against resistance. Penetration power is directly related to tip stiffness and inversely related to the tip area. Therefore, tapered guidewires have a greater penetration power compared with guidewires with a non-tapered tip. Guidewires with high penetration force are used for crossing calcified lesions when softer guidewires have failed.

# Complex Coronary Intervention

Table 3: Overview of the Most Commonly Used Guidewires

Indication	Guidewire	Manufacturer	Coating	Tip morphology	Tip load (g)	Tip diameter (inches)	Shaft diameter (inches)	Penetration force	Properties
Sliding technique (crossing microchannels)	Fielder FC	Asahi Intecc	Hydrophilic Polymer jacketed	Non-tapered	0.8	0.014	/	Low	Excellent lubricity and trackability in tortuous vessels
	Fielder XT	Asahi Intecc	Hydrophilic Polymer jacketed	Tapered	0.8	0.009	0.014	Low	Moderate support
	Fielder XTA	Asahi Intecc	Hydrophilic Polymer jacketed	Tapered	1	0.009	0.014	Low	Higher tip load than Fielder XT and XT-R, facilitating entry into the chronic occluded lesion
	Fielder XTR	Asahi Intecc	Hydrophilic Polymer jacketed	Tapered	0.6	0.009	0.014	Low	Extremely low friction and high flexibility Less support than XT-A
Drilling technique	Miracle 6	Asahi Intecc	Hydrophobic	Non-tapered	6	0.014	/	Intermediate	Good tactile feedback (hydrophobic tip)
	Ultimate Bros 3	Asahi Intecc	Hydrophilic Polymer jacketed	Non-tapered	3	0.014	/	Intermediate	High maneuverability Good pushability Reduced risk of false lumen expansion
Penetrating technique	Miracle 12	Asahi Intecc	Hydrophobic	Non-tapered	12	0.014	/	High	Good tactile feedback (hydrophobic tip) High lateral support.
	Conquest Pro 9	Asahi Intecc	Hydrophilic	Tapered	9	0.009	0.014	High	Stiff and tapered tip allows penetration of heavily calcified lesions High pushability Uncoated tip provides good tactile feedback
	Conquest Pro 12	Asahi Intecc	Hydrophilic	Tapered	12	0.009	0.014	High	
	Hornet 10	Boston Scientific	Hydrophilic	Tapered	10	0.008	0.014	High	
		Hornet 14	Boston Scientific	Hydrophilic	Tapered	14	0.008	0.014	High
Push and torque technique	Gaia First	Asahi Intecc	Hydrophilic	Tapered	1.5	0.010	0.014	Low	High maneuverability and torqueability Tip designed (micro-cone tip) to improve penetrability
	Gaia Second	Asahi Intecc	Hydrophilic	Tapered	3.5	0.011	0.014	Intermediate	
	Gaia Third	Asahi Intecc	Hydrophilic	Tapered	4.5	0.012	0.014	High	
Knuckle technique (dissection)	Pilot 50	Abbott Vascular	Hydrophilic Polymer jacketed	Non-tapered	1.5	0.014	/	Low	Good steerability and flexibility
	Pilot 150	Abbott Vascular	Hydrophilic Polymer jacketed	Non-tapered	2.7	0.014	/	Intermediate	Excellent torqueability Moderate support

Table 3: Cont.

Knuckle technique (dissection)	Pilot 200	Abbott Vascular	Hydrophilic Polymer jacketed	Non-tapered	4.1	0.014	/	Intermediate	Excellent torqueability Moderate support Higher penetration force compared with Pilot 150 Makes larger knuckles than the Fielder XT
	Sion Black	Asahi Intecc	Hydrophilic Polymer jacketed	Non-tapered	0.8	0.014	/	Low	Excellent torqueability Very low friction due to polymer jacket
	Fielder XT	Asahi Intecc	Hydrophilic Polymer jacketed	Tapered	0.8	0.009	0.014	Low	Excellent lubricity and trackability in tortuous vessels Moderate support
Crossing collateral channel	Sion	Asahi Intecc	Hydrophilic	Non-tapered	0.7	0.014	/	Low	High lubricity (hydrophilic tip)
	Sion Blue	Asahi Intecc	Hydrophilic	Non-tapered	0.5	0.014	/	Low	High torqueability and flexibility
	Sion Black	Asahi Intecc	Hydrophilic Polymer jacketed	Non-tapered	0.8	0.014	/	Low	Excellent torqueability Very low friction due to polymer jacket
	Suoh03	Asahi Intecc	Hydrophilic	Non-tapered	0.3	0.014	/	Low	High trackability, torqueability and flexibility
	Fielder XTR	Asahi Intecc	Hydrophilic Polymer jacketed	Tapered	0.6	0.009	0.014	Low	Extremely low friction and high flexibility Less support than XT-A
Re-entry	Stingray guidewire	Boston Scientific	Hydrophilic	Tapered	12	0.0035	0.014	High	Dedicated guidewire advanced into the Stingray balloon
	Hornet 14	Boston Scientific	Hydrophilic	Tapered	14	0.008	0.014	High	High torqueability, penetrability and pushability
	Conquest Pro 12	Asahi Intecc	Hydrophilic	Tapered	12	0.009	0.014	High	High pushability Uncoated tip provides good tactile feedback
	Pilot 200	Abbott Vascular	Hydrophilic Polymer jacketed	Non-tapered	4.1	0.014	/	Intermediate	Excellent torqueability Moderate support More penetrability compared with Pilot 150
Externalization	RG3	Asahi Intecc	Hydrophilic	Non-tapered	3	0.010	/	Intermediate	Optimal inside-catheter pushability
	R350	Vascular solutions	Hydrophilic	Non-tapered	3	0.013	/	Intermediate	Nitinol core for flexibility Excellent deliverability during advancement through tortuous vessels

# Complex Coronary Intervention

Table 4: Overview of the Most Commonly Used Microcatheters

Microcatheter	Manufacturer	Lumen	Coating	Crossing profile (Fr)	Length (cm)	Advancement	Properties
Finecross	Terumo	Single	Distal hydrophilic coating	1.8	130–150	Forward push (no rotation at all)	Floppy distal segment ultra-flexible for improved trackability around bends and tortuous vessels
Corsair Pro	Ashai Intecc	Single	Distal hydrophilic coating	2.6	135–150	Counter-clockwise rotation	Increased tip flexibility Developed as a septal channel dilator
Turnpike	Teleflex	Single	Distal hydrophilic coating	2.6	135–150	Rotation in both directions	Flexible and tapered tip for improved trackability
Turnpike LP	Teleflex	Single	Distal hydrophilic coating	2.2	135–150	Rotation in both directions	Lower distal shaft profile than standard Turnpike Increased flexibility Excellent for navigating tortuous vessels (150 cm for retrograde; 135 cm for antegrade)
Turnpike Spiral	Teleflex	Single	Distal hydrophilic coating	2.9	135	Clockwise rotation	Great support 2 cm outer nylon coil to improve rotational advancement Used for antegrade approach mainly with fibrotic or calcific lesions
Turnpike Gold	Teleflex	Single	Distal hydrophilic coating	2.9	135	Clockwise rotation	Gold-plated tip for additional guidewire support Used for antegrade approach with highly calcific lesions
SuperCross	Teleflex	Single	Distal hydrophilic coating	1.8 (Straight, flexible) 2.4 (45°, 90°, 90° XT, 120°)	130–150	Forward push Rotation (in both directions) possible for SuperCross straight tip.	Straight tip or angled tip with multiple tip degree options: 45°, 90°, 120° Provides increased pushability Flexible tip provides increased trackability Excellent torqueability and flexibility (dual coil design) Used as workhorse and for tortuous anatomy Specific use of angled tip design to access sharp angles
Mamba	Boston Scientific	Single	Distal hydrophilic coating	2.4	135	Rotation in both directions	Three coil taper zones that provide excellent pushability and support Used to increase support during antegrade approach
Mamba Flex	Boston Scientific	Single	Distal hydrophilic coating	2.1	135–150	Rotation in both directions	Five coil taper zones for enhanced flexibility Used to cross tortuosity and collateral channels
Caravel	Ashai Intecc	Single	Distal hydrophilic coating	1.9	135–150	Forward push (no rotation at all)	Very low distal profile Developed to advance through tortuous vessels
FineDuo	Terumo	Dual	Distal hydrophilic coating	2.9	140	Forward push	Increased tip flexibility Excellent trackability and strong penetration force Used for guidewires placement, parallel guidewire technique and wiring CTO with side branch at the level of proximal or distal cap
Twin Pass	Vascular solutions	Dual	Distal hydrophilic coating	3.5	135	Forward push	Proximal embedded stainless steel rod for support and pushability Used for guidewire placement, parallel guidewire technique and wiring CTO with side branch at the level of proximal or distal cap

CTO = chronic total occlusion.



The third element is the body: this is the part of the guidewire that surrounds the core. It may be composed entirely of spring coils or a combination of spring coils and polymers (plastic). Polymer-jacketed guidewires provide advanced slip performance and good deliverability.

Fourth, the coating: the guidewires can be coated with hydrophobic or hydrophilic material. Hydrophobic coating (silicone based) gives the advantage of greater tactile feedback and a lower risk of unintentionally ending up in the subintimal space. Hydrophilic-coated guidewires are more slippery and are suitable to cross microchannels, tortuous vessels and small collaterals. Sometimes guidewires are coated with hydrophilic material with the exception of the tip, which is hydrophobic, providing at the same time slipperiness and optimal tactile feedback.<sup>45</sup>

Table 3 summarizes the main properties and indications of the guidewires most used in the treatment of CTOs.

### Microcatheters

Microcatheters are an essential tool in the treatment of CTOs. Basically, these are used in order to increase guidewire support and penetration power, to allow easy guidewire exchange and to perform selective contrast injection. Microcatheters have several features that differentiate them from each other, making them specific for precise situations. In general, large-diameter microcatheters are used to increase guidewire tip stiffness during the AWE technique. Conversely, small microcatheters are more useful in the case of tortuosity. Dual lumen microcatheters are used to perform the parallel guidewire technique and wire escalation when the side branch originates near the proximal cap, to wire the side branch of a bifurcation and to gain the main distal vessel when the guidewire achieves the side branch located near the distal cap. In the latter case, the pullback performed in order to redirect the guidewire from the side branch to the main vessel could lead to loss of the path already gained.<sup>46</sup>

Table 4 summarizes the main properties of and indications for the microcatheters most used in the treatment of CTOs.

### Role of Intravascular Ultrasound in Chronic Total Occlusion

In the treatment of CTOs, IVUS may be a useful tool to deal with some complex scenarios. One of its main uses is in the case of proximal cap ambiguity. In this condition, if a good-sized collateral branch originates near the lesion, the IVUS catheter can be inserted in the proximal segment of the side branch, thereby visualizing the exact location of the CTO cap. This allows correct puncture of the proximal cap, reducing the risk of inadvertent advancement of the guidewire into the subintimal space or even outside the vessel structure. Sometimes during AWE techniques, the guidewire can accidentally end up in the subintimal space, creating a large dissection and leading to collapse of the distal true lumen. For this reason, the distal part of the vessel cannot be seen on simple angiography, making the following part of the procedure dangerous. In this situation, the IVUS catheter may help to identify the distal true lumen and allow safe and successful re-entry. The operator, after pre-dilation of the subintimal space with a small balloon (1.5 mm), advances the IVUS catheter into the false lumen, identifying the point of re-entry proximal to the distal cap. Then, under the guidance of IVUS, a second guidewire with high penetration support is advanced to gain the true lumen. IVUS can be

particularly useful to tackle ostial lesions with the RDR technique. In this situation the IVUS catheter is placed proximal to the occluded ostium, at the level of the bifurcation, guiding the retrograde passage of the guidewire from the subintimal space to the proximal true lumen. Finally, IVUS is widely used for stenting optimization. Although the randomized studies conducted so far have not shown clear advantages of IVUS-guided revascularization compared with angiography alone, the use of this technique could reduce the risk of complications, especially in selected complex settings.<sup>47,48</sup>

### Algorithm for Crossing Chronic Total Occlusions

Although the antegrade approach is generally preferred because it is associated with a lower risk of complications, the retrograde technique is necessary to achieve successful PCI in many procedures. Sometimes retrograde techniques may represent the first strategy in the presence of a complex anatomy or ambiguity of the proximal cap. Several algorithms have been proposed to simplify the revascularization and to choose the best approach. The most frequently used are the hybrid approach and the Asia Pacific algorithm.<sup>5,49</sup>

The hybrid approach consists of positioning two guide catheters in the right and left coronary arteries for complete assessment of the CTO, by doing simultaneous double injection with two guiding catheters. The main criteria to assess the CTO are: type of proximal CTO cap (well defined or ambiguous), length of the CTO segment (less or more than 20 mm), presence of collaterals that can be used for retrograde procedures (so called "interventional collaterals"), and quality of the distal vessel after the CTO (diseased distal vessel, distal CTO cap at bifurcation). According to all possible combinations of these four parameters, one of the four techniques (AWE, ADR, RWE or RDR) is chosen as the first strategy. Having the set up with double guiding catheters allows the switch from one technique to another during the procedure in the case of failure of the previous one. Thus the CTO is tackled from every perspective possible. Several registries have highlighted the importance of the hybrid algorithm, which has a high PCI success rate (86–91%) and a relatively low percentage of procedural complications (1.7–2.6%).<sup>50,51</sup>

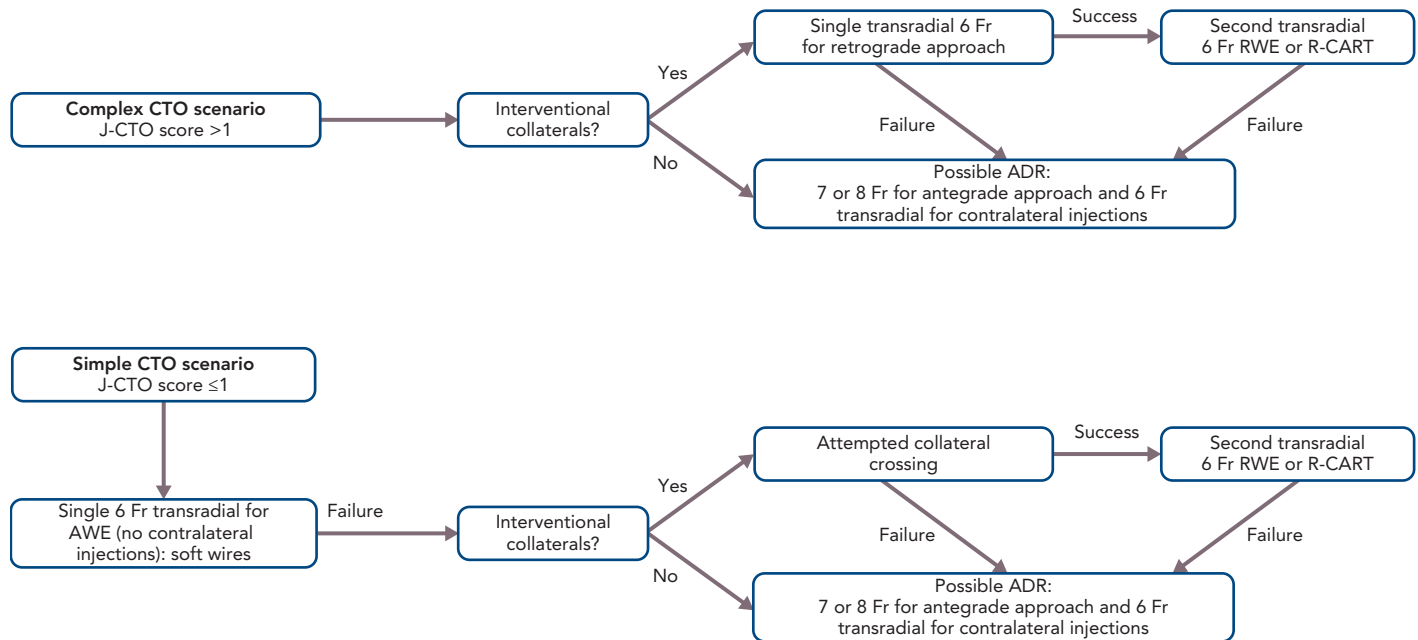
The Asia Pacific algorithm maintains some common features with the hybrid algorithm such as the evaluation of the proximal cap, the quality of the distal vessel and the presence of collaterals. In contrast, the length of the occlusive stenosis is not considered. Furthermore, it is recommended to use the CrossBoss catheter (Boston Scientific) in the presence of intrastent occlusive restenosis, the Stingray system (Boston Scientific) in the case of failure of the antegrade approach, and the parallel guidewire technique and IVUS-guided wiring as a bail-out strategy in the antegrade arm.

### Complications of Chronic Total Occlusion Percutaneous Coronary Intervention

Recent advances in the field of CTO have increased the rate of successful revascularization and reduced periprocedural complications. A report from the National Cardiovascular Data Registry showed that the incidence of MACE in CTO percutaneous procedures, although decreasing over time, is still higher compared with non CTO PCI.<sup>4</sup> Furthermore, the development of procedural complications has also been associated with a worse long-term health status that has further discouraged

# Complex Coronary Intervention

Figure 4: Minimalistic Hybrid Algorithm for Crossing a Chronic Total Occlusion



ADR = antegrade dissection and re-entry; AWE = antegrade wire escalation; CTO = chronic total occlusion; R-CART = reverse controlled antegrade and retrograde tracking; RWE = retrograde wire escalation. Source: Zivelonghi et al. 2019.<sup>60</sup> Reproduced with permission from Elsevier.

Interventional cardiologists from actively dealing with CTO percutaneous revascularization. Registry data show a total complication rate ranging from 2.6% to 9.7%.<sup>52-54</sup> Several complications may occur during CTO PCI, including coronary perforation, periprocedural MI, arrhythmias, cardiogenic shock, stroke, major bleeding, donor vessel thrombosis, contrast-induced nephropathy, radiation damage and death.<sup>53</sup> These have been independently associated with a retrograde approach, advanced age and lesion complexity defined according to the J-CTO score.

One of the most frequent and feared complications of CTO PCI is coronary perforation.<sup>55</sup> This usually occurs as a result of collateral channel damage during a retrograde crossing attempt or due to an accidental exit of the guidewire during wire escalation (both antegrade and retrograde) using high penetration force guidewires. Perforation can occur at the level of epicardial vessels, with an increased risk of cardiac tamponade, or at the level of septal collaterals, and is usually self-limited and does not require specific treatment. In the presence of coronary perforation that is not self-limited, it is crucial to stop the bleeding promptly.

The first step should involve the placement of a balloon close to the perforation. In the majority of cases this may be enough to resolve the complication and prevent cardiac tamponade. However, if it is not sufficient, it becomes necessary to implement additional strategies such as positioning a covered stent or coils or injecting autologous fat, thrombin or microbeads at the level of the perforation.<sup>56</sup> Of note, the injection of these substances should never be performed in the case of connection between the perforation and the left chamber, because of the high risk of embolization and stroke. Pericardiocentesis is needed in cases of cardiac tamponade. However, in most cases coronary perforations do not cause hemodynamically significant pericardial

effusion.<sup>57</sup> Finally, cardiac surgery may be required as a bailout option for percutaneously unresolvable bleeding.

Another complication due to coronary perforation is the intramural hematoma, also called 'dry tamponade'.<sup>58</sup> Vessel perforation may occasionally lead to an important blood extravasation within the myocardial wall or in localized structures next to the heart itself (typically in post-CABG patients in whom the pericardium has several adhesions), causing ventricular or atrial compression and stiffening and subsequent risk of cardiogenic shock. The treatment of this complication is complex: the first step is to stop the bleeding; second, the blood extravasation should be decompressed, but these localized blood collections may be difficult to reach percutaneously. Sometimes only supportive measures to generate increased intracardiac pressure (such as hydration) in order to compensate for the external pressure, are sufficient to bridge the patient to a stable situation that then allows the hematoma to reabsorb by itself. In the case of development and persistence of hemodynamic compromise, ventricular assist device could be used to stabilize the patient as a bridge to recovery.

Periprocedural infarction still represents one of the feared complications of CTO PCI. This can occur as a consequence of collateral branch occlusion (in particular during uncontrolled dissection and re-entry technique) or in the case of thrombotic occlusion of the donor vessel. The former may be avoided through the use of more controlled re-entry systems, the latter by means of excellent anticoagulation with an activated clotting time >300-350 seconds. Finally, of the most frequent extra-cardiac periprocedural complications, those related to vascular access are notable. In recent years, attention has been paid to the type of access, with the aim of minimizing the use of femoral access and of large introducer sheaths (8 Fr).<sup>24</sup>

## Importance of Access and the Minimalistic Hybrid Algorithm

The choice of arterial access plays an important role in the procedure. The type of access depends on operator preference and on the anatomical characteristics of the CTO. In general, complex lesions, such as those with a very resistant proximal cap, require large guide catheters (7 or 8 Fr) for greater passive support. Consequently, femoral access is usually preferred. In contrast, radial access, which is now increasingly used for CTO PCI, is associated with similar procedural success but with a lower risk of major bleeding compared with femoral access.<sup>59</sup> We recently proposed an approach based on the use of all four possible hybrid strategies to cross the CTO, but with the aim of reducing the rate of femoral approach, double access and periprocedural complications.<sup>60</sup> This approach, called the minimalistic hybrid algorithm, has shown promising results, ensuring a high revascularization success rate using the radial approach in 90% of cases and a single catheter approach in nearly 60% of procedures (Figure 4).<sup>61</sup>

## Conclusion

CTO treatment represents one of the most challenging and complex procedures in the field of interventional cardiology. International guidelines based on the results of the available randomized controlled trials (RCTs), support CTO revascularization only in selected cases. It is a generally accepted opinion that in patients with refractory angina, CTO PCI improves QoL. Its effect on ventricular function and other hard endpoints such as mortality and MACE, however, is still debated; although RCTs and observational studies have consistently suggested the possible advantages of CTO PCI when compared with optimal medical treatment in some subgroups of patients, for instance in those with depressed EF and/or evidence of myocardial hibernation. Therefore, despite improvement in technique and greater operator skill, CTO PCI remains a complex procedure with a non-negligible incidence of complications. For this reason, accurate selection of patients who may benefit from this procedure is needed, and specific algorithms leading to a systematic approach to this type of procedure, are welcome. ■

- Di Mario C, Werner GS, Sianos G, et al. European perspective in the recanalisation of chronic total occlusions (CTO): consensus document from the EuroCTO Club. *EuroIntervention* 2007;3:30-43. PMID: 19737682.
- Fefer P, Knudtson ML, Cheema AN, et al. Current perspectives on coronary chronic total occlusions: the Canadian Multicenter Chronic Total Occlusions Registry. *J Am Coll Cardiol* 2012;59:991-7. <https://doi.org/10.1016/j.jacc.2011.12.007>; PMID: 22402070.
- Jeroudi OM, Alomar ME, Michael TT, et al. Prevalence and management of coronary chronic total occlusions in a tertiary Veterans Affairs hospital. *Catheter Cardiovasc Interv* 2014;84:637-43. <https://doi.org/10.1002/ccd.25264>; PMID: 24142769.
- Brilakis ES, Banerjee S, Karpaliotis D, et al. Procedural outcomes of chronic total occlusion percutaneous coronary intervention: a report from the NCDR (National Cardiovascular Data Registry). *JACC Cardiovasc Interv* 2015;8:245-53. <https://doi.org/10.1016/j.jcin.2014.08.014>; PMID: 25700746.
- Maeremans J, Walsh S, Knaepen P, et al. The hybrid algorithm for treating chronic total occlusions in Europe: The RECHARGE Registry. *J Am Coll Cardiol* 2016;68:1958-70. <https://doi.org/10.1016/j.jacc.2016.08.034>; PMID: 27788851.
- Azzalini L, Dautov R, Ojeda S, et al. Procedural and long-term outcomes of percutaneous coronary intervention for in-stent chronic total occlusion. *JACC Cardiovasc Interv* 2017;10:892-902. <https://doi.org/10.1016/j.jcin.2017.01.047>; PMID: 28412256.
- Li KHC, Wong KHG, Gong M, et al. Percutaneous coronary intervention versus medical therapy for chronic total occlusion of coronary arteries: a systematic review and meta-analysis. *Curr Atheroscler Rep* 2019;21:42. <https://doi.org/10.1007/s11883-019-0804-8>; PMID: 31399762.
- Khariton Y, Airhart S, Salisbury AC, et al. Health status benefits of successful chronic total occlusion revascularization across the spectrum of left ventricular function: insights from the OPEN-CTO Registry. *JACC Cardiovasc Interv* 2018;11:2276-83. <https://doi.org/10.1016/j.jcin.2018.07.058>; PMID: 30466826.
- Barbarawi M, Kheiri B, Zayed Y, et al. Meta-analysis of percutaneous coronary intervention versus medical therapy in the treatment of coronary chronic total occlusion. *Am J Cardiol* 2019;123:2060-2. <https://doi.org/10.1016/j.amjcard.2019.03.032>; PMID: 30967287.
- Singh M, Bell MR, Berger PB, Holmes DR. Utility of bilateral coronary injections during complex coronary angioplasty. *J Invasive Cardiol* 1999;11:70-4. PMID: 10745484.
- Srivatsa S, Holmes Jr D. The histopathology of angiographic chronic total coronary artery occlusions: changes in neovascular pattern and intimal plaque composition associated with progressive occlusion duration. *J Invasive Cardiol* 1997;9:294-301. PMID: 10762917.
- Karacsonyi J, Alaswad K, Jaffer FA, et al. Use of intravascular imaging during chronic total occlusion percutaneous coronary intervention: insights from a contemporary multicenter registry. *J Am Heart Assoc* 2016;5:e003890. <https://doi.org/10.1161/JAHA.116.003890>; PMID: 27543800.
- Kim B-K, Cho I, Hong M-K, et al. Usefulness of intraprocedural coronary computed tomographic angiography during intervention for chronic total coronary occlusion. *Am J Cardiol* 2016;117:1868-76. <https://doi.org/10.1016/j.amjcard.2016.03.032>; PMID: 27134060.
- Lee S-W, Lee PH, Ahn J-M, et al. Randomized trial evaluating percutaneous coronary intervention for the treatment of chronic total occlusion. *Circulation* 2019;139:1674-83. <https://doi.org/10.1161/CIRCULATIONAHA.118.031313>; PMID: 30813758.
- Werner GS, Martin-Yuste V, Hildick-Smith D, et al. A randomized multicentre trial to compare revascularization with optimal medical therapy for the treatment of chronic total coronary occlusions. *Eur Heart J* 2018;39:2484-93. <https://doi.org/10.1093/eurheartj/ehy220>; PMID: 29722796.
- Obedinskiy AA, Kretov EI, Boukhris M, et al. The IMPACTOR-CTO Trial. *JACC Cardiovasc Interv* 2018;11:1309-11. <https://doi.org/10.1016/j.jcin.2018.04.017>; PMID: 29976368.
- Hirai T, Grantham JA, Saponits J, et al. Quality of life changes after chronic total occlusion angioplasty in patients with baseline refractory angina. *Circ Cardiovasc Interv* 2019;12:e007558. <https://doi.org/10.1161/CIRCINTERVENTIONS.118.007558>; PMID: 30871356.
- Joyal D, Afialio J, Rinfret S. Effectiveness of recanalization of chronic total occlusions: a systematic review and meta-analysis. *Am Heart J* 2010;160:179-87. <https://doi.org/10.1016/j.ahj.2010.04.015>; PMID: 20598990.
- Yeh RW, Tamez H, Secemsky EA, et al. Depression and angina among patients undergoing chronic total occlusion percutaneous coronary intervention: the OPEN-CTO Registry. *JACC Cardiovasc Interv* 2019;12:651-8. <https://doi.org/10.1016/j.jcin.2018.12.029>; PMID: 30878475.
- Henriques JPS, Hoebels LP, Råmunddal T, et al. Percutaneous intervention for concurrent chronic total occlusions in patients with STEMI: the EXPLORE Trial. *J Am Coll Cardiol* 2016;68:1622-32. <https://doi.org/10.1016/j.jacc.2016.07.744>; PMID: 27712774.
- Bondarenko O, Beek AM, Twisk JWR, et al. Time course of functional recovery after revascularization of hibernating myocardium: a contrast-enhanced cardiovascular magnetic resonance study. *Eur Heart J* 2008;29:2000-5. <https://doi.org/10.1093/eurheartj/ehn266>; PMID: 18556713.
- Mashayekhi K, Nührenberg TG, Toma A, et al. A randomized trial to assess regional left ventricular function after stent implantation in chronic total occlusion: the REVASC Trial. *JACC Cardiovasc Interv* 2018;11:1982-91. <https://doi.org/10.1016/j.jcin.2018.05.041>; PMID: 30219327.
- Kirschbaum SW, Baks T, van den Ent M, et al. Evaluation of left ventricular function three years after percutaneous recanalization of chronic total coronary occlusions. *Am J Cardiol* 2008;101:179-85. <https://doi.org/10.1016/j.amjcard.2007.07.060>; PMID: 18178403.
- Megaly M, Saad M, Tajti P, et al. Meta-analysis of the impact of successful chronic total occlusion percutaneous coronary intervention on left ventricular systolic function and reverse remodeling. *J Interv Cardiol* 2018;31:562-71. <https://doi.org/10.1111/joic.12538>; PMID: 29974508.
- Nombela-Franco L, Mitroi CD, Fernández-Lozano I, et al. Ventricular arrhythmias among implantable cardioverter-defibrillator recipients for primary prevention: impact of chronic total coronary occlusion (VACTO Primary Study). *Circ Arrhythm Electrophysiol* 2012;5:147-54. <https://doi.org/10.1161/CIRCEP.111.968008>; PMID: 22205684.
- Tse G. Mechanisms of cardiac arrhythmias. *J Arrhythm* 2016;32:75-81. <https://doi.org/10.1016/j.joa.2015.11.003>; PMID: 27092186.
- Chi WK, Gong M, Bazoukis G, et al. Impact of coronary artery chronic total occlusion on arrhythmic and mortality outcomes: a systematic review and meta-analysis. *JACC Clin Electrophysiol* 2018;4:1214-23. <https://doi.org/10.1016/j.jacep.2018.06.011>; PMID: 30236396.
- Galassi AR, Boukhris M, Toma A, et al. Percutaneous coronary intervention of chronic total occlusions in patients with low left ventricular ejection fraction. *JACC Cardiovasc Interv* 2017;10:2158-70. <https://doi.org/10.1016/j.jcin.2017.06.058>; PMID: 29055762.
- Park JY, Choi BG, Rha S-W, et al. Chronic total occlusion intervention of the non-infarct-related artery in acute myocardial infarction patients: the Korean multicenter chronic total occlusion registry. *Coron Artery Dis* 2018;29:495-501. <https://doi.org/10.1097/MCA.0000000000000630>; PMID: 29688904.
- Choi JJ, Koh Y-S, Lim S, et al. Impact of percutaneous coronary intervention for chronic total occlusion in non-infarct-related arteries in patients with acute myocardial infarction (from the COREA-AMI Registry). *Am J Cardiol* 2016;117:1039-46. <https://doi.org/10.1016/j.amjcard.2015.12.049>; PMID: 26993974.
- Christakopoulos GE, Christopoulos G, Carlino M, et al. Meta-analysis of clinical outcomes of patients who underwent percutaneous coronary interventions for chronic total occlusions. *Am J Cardiol* 2015;115:1367-75. <https://doi.org/10.1016/j.amjcard.2015.02.038>; PMID: 25784515.
- Neumann F-J, Sousa-Uva M, Ahlsson A, et al. 2018 ESC/EACTS guidelines on myocardial revascularization. *Eur Heart J* 2019;40:87-165. <https://doi.org/10.1093/eurheartj/ehy394>; PMID: 30165437.
- Levine GN, Bates ER, Blankenship JC, et al. 2011 ACCF/AHA/SCAI guideline for percutaneous coronary intervention: a report of the American College of Cardiology Foundation/American Heart Association Task Force on Practice Guidelines and the Society for Cardiovascular Angiography and Interventions. *Circulation* 2011;124:e574-651. <https://doi.org/10.1161/CIR.0b013e31823ba622>; PMID: 22064601.
- Morino Y, Abe M, Morimoto T, et al. Predicting successful guidewire crossing through chronic total occlusion of native coronary lesions within 30 minutes: the J-CTO (Multicenter CTO Registry in Japan) score as a difficulty grading and time assessment tool. *JACC Cardiovasc Interv* 2011;4:213-21. <https://doi.org/10.1016/j.jcin.2010.09.024>; PMID: 21349461.
- Szjgyarto Z, Rampat R, Werner GS, et al. Derivation and validation of a chronic total coronary occlusion intervention procedural success score from the 20,000-patient EuroCTO Registry: the EuroCTO (CASTLE) score. *JACC Cardiovasc Interv* 2019;12:335-42. <https://doi.org/10.1016/j.jcin.2018.11.020>; PMID: 30711551.
- Maeremans J, Spratt JC, Knaepen P, et al. Towards a contemporary, comprehensive scoring system for determining technical outcomes of hybrid percutaneous chronic total occlusion treatment: the RECHARGE score. *Catheter Cardiovasc Interv* 2018;91:192-202. <https://doi.org/10.1002/ccd.27092>; PMID: 28471074.
- Alessandrino G, Chevalier B, Lefèvre T, et al. A clinical and angiographic scoring system to predict the probability of successful first-attempt percutaneous coronary intervention in patients with total chronic coronary occlusion. *JACC Cardiovasc Interv* 2015;8:1540-8. <https://doi.org/10.1016/j.jcin.2015.07.009>; PMID: 26493246.
- Karatasakis A, Daneq BA, Karpaliotis D, et al. Comparison of various scores for predicting success of chronic total occlusion

- percutaneous coronary intervention. *Int J Cardiol* 2016;224:50–6. <https://doi.org/10.1016/j.ijcard.2016.08.317>; PMID: 27611917.
39. Christopoulos G, Kandzari DE, Yeh RW, et al. Development and validation of a novel scoring system for predicting technical success of chronic total occlusion percutaneous coronary interventions: the PROGRESS CTO (Prospective Global Registry for the Study of Chronic Total Occlusion Intervention) score. *JACC Cardiovasc Interv* 2016;9:1–9. <https://doi.org/10.1016/j.jcin.2015.09.022>; PMID: 26762904.
40. Bufe A, Haltern G, Dinh W, et al. Recanalisation of coronary chronic total occlusions with new techniques including the retrograde approach via collaterals. *Neth Heart J* 2011;19:162–7. <https://doi.org/10.1007/s12471-011-0091-7>; PMID: 22020996.
41. Colombo A, Mikhail GW, Michev I, et al. Treating chronic total occlusions using subintimal tracking and reentry: the STAR technique. *Catheter Cardiovasc Interv* 2005;64:407–11. <https://doi.org/10.1002/ccd.20307>; PMID: 15789384.
42. Karatasakis A, Danek BA, Karacsonyi J, et al. Mid-term outcomes of chronic total occlusion percutaneous coronary intervention with subadventitial vs. intraplaque crossing: a systematic review and meta-analysis. *Int J Cardiol* 2018;253:29–34. <https://doi.org/10.1016/j.ijcard.2017.08.044>; PMID: 29306468.
43. Konstantinidis NV, Werner GS, Deftereos S, et al. Temporal trends in chronic total occlusion interventions in Europe. *Circ Cardiovasc Interv* 2018;11:e006229. <https://doi.org/10.1161/CIRCINTERVENTIONS.117.006229>; PMID: 30354635.
44. Matsuno S, Tsuchikane E, Harding SA, et al. Overview and proposed terminology for the reverse controlled antegrade and retrograde tracking (reverse CART) techniques. *EuroIntervention* 2018;14:94–101. <https://doi.org/10.4244/EIJ-D-17-00867>; PMID: 29360064.
45. Tóth GG, Yamane M, Heyndrickx GR. How to select a guidewire: technical features and key characteristics. *Heart* 2015;101:645–52. <https://doi.org/10.1136/heartjnl-2013-304243>; PMID: 24939802.
46. Vemou E, Nikolakopoulos I, Xenogiannis I, et al. Recent advances in microcatheter technology for the treatment of chronic total occlusions. *Expert Rev Med Devices* 2019;16:267–73. <https://doi.org/10.1080/17434440.2019.1602039>; PMID: 30929525.
47. Kim BK, Shin DH, Hong MK, et al. Clinical impact of intravascular ultrasound-guided chronic total occlusion intervention with zotarolimus-eluting versus biolimus-eluting stent implantation: randomized study. *Circ Cardiovasc Interv* 2015;8:e002592. <https://doi.org/10.1161/CIRCINTERVENTIONS.115.002592>; PMID: 26156151.
48. Chieffo A, Latib A, Caussin C, et al. A prospective, randomized trial of intravascular-ultrasound guided compared to angiography guided stent implantation in complex coronary lesions: the AVIO trial. *Am Heart J* 2013;165:65–72. <https://doi.org/10.1016/j.ahj.2012.09.017>; PMID: 23237135.
49. Harding SA, Wu EB, Lo S, et al. A new algorithm for crossing chronic total occlusions from the Asia Pacific Chronic Total Occlusion Club. *JACC Cardiovasc Interv* 2017;10:2135–43. <https://doi.org/10.1016/j.jcin.2017.06.071>; PMID: 29122129.
50. Christopoulos G, Karpaliotis D, Alaswad K, et al. Application and outcomes of a hybrid approach to chronic total occlusion percutaneous coronary intervention in a contemporary multicenter US registry. *Int J Cardiol* 2015;198:222–8. <https://doi.org/10.1016/j.ijcard.2015.06.093>; PMID: 26189193.
51. Saponitis J, Salisbury AC, Yeh RW, et al. Early procedural and health status outcomes after chronic total occlusion angioplasty: a report from the OPEN-CTO Registry (Outcomes, Patient Health Status, and Efficiency in Chronic Total Occlusion Hybrid Procedures). *JACC Cardiovasc Interv* 2017;10:1523–34. <https://doi.org/10.1016/j.jcin.2017.05.065>; PMID: 28797429.
52. Danek BA, Karatasakis A, Karpaliotis D, et al. Development and validation of a scoring system for predicting periprocedural complications during percutaneous coronary interventions of chronic total occlusions: the Prospective Global Registry for the Study of Chronic Total Occlusion Intervention (PROGRESS CTO) complications score. *J Am Heart Assoc* 2016;5:e004272. <https://doi.org/10.1161/JAHA.116.004272>; PMID: 27729332.
53. Riley RF, Saponitis J, Kirtane AJ, et al. Prevalence, predictors, and health status implications of periprocedural complications during coronary chronic total occlusion angioplasty. *EuroIntervention* 2018;14:e1199–e1206. <https://doi.org/10.4244/EIJ-D-17-00976>; PMID: 29808821.
54. Konstantinidis NV, Werner GS, Deftereos S, et al. Temporal trends in chronic total occlusion interventions in Europe. *Circ Cardiovasc Interv* 2018;11:e006229. <https://doi.org/10.1161/CIRCINTERVENTIONS.117.006229>; PMID: 30354635.
55. Patel VG, Brayton KM, Tamayo A, et al. Angiographic success and procedural complications in patients undergoing percutaneous coronary chronic total occlusion interventions: a weighted meta-analysis of 18,061 patients from 65 studies. *JACC Cardiovasc Interv* 2013;6:128–36. <https://doi.org/10.1016/j.jcin.2012.10.011>; PMID: 23352817.
56. Azzalini L, Poletti E, Ayoub M, et al. Coronary artery perforation during chronic total occlusion percutaneous coronary intervention: epidemiology, mechanisms, management, and outcomes. *EuroIntervention* 2019;15:e804–11. <https://doi.org/10.4244/EIJ-D-19-00282>; PMID: 31217142.
57. Danek BA, Karatasakis A, Tajti P, et al. Incidence, treatment, and outcomes of coronary perforation during chronic total occlusion percutaneous coronary intervention. *Am J Cardiol* 2017;120:1285–92. <https://doi.org/10.1016/j.amjcard.2017.07.010>; PMID: 28826896.
58. Vetrugno V, Sharma H, Townend JN, Khan SQ. What is the cause of hypotension? A rare complication of percutaneous coronary intervention of a chronic total occlusion: a case report. *Eur Heart J Case Rep* 2019;3:1–5. <https://doi.org/10.1093/ehjcr/ytz184>; PMID: 32123803.
59. Bakker EJ, Maeremans J, Zivelonghi C, et al. Fully transradial versus transfemoral approach for percutaneous intervention of coronary chronic total occlusions applying the hybrid algorithm: insights from RECHARGE Registry. *Circ Cardiovasc Interv* 2017;10:e005255. <https://doi.org/10.1161/CIRCINTERVENTIONS.117.005255>; PMID: 28851720.
60. Zivelonghi C, van Kuijk JP, Suttorp MJ, et al. Implementing a minimally invasive approach (combining radial approach, small guiding catheters and minimization of double access) for coronary chronic total occlusion intervention according to the hybrid algorithm: the minimalistic hybrid algorithm. *Int J Cardiol* 2019;283:84–7. <https://doi.org/10.1016/j.ijcard.2018.11.021>; PMID: 30449693.
61. Zivelonghi C, van Kuijk JP, Poletti E, et al. A “minimalistic hybrid algorithm” in coronary chronic total occlusion revascularization: procedural and clinical outcomes. *Catheter Cardiovasc Interv* 2020;95:97–104. <https://doi.org/10.1002/ccd.28213>; PMID: 30919577.