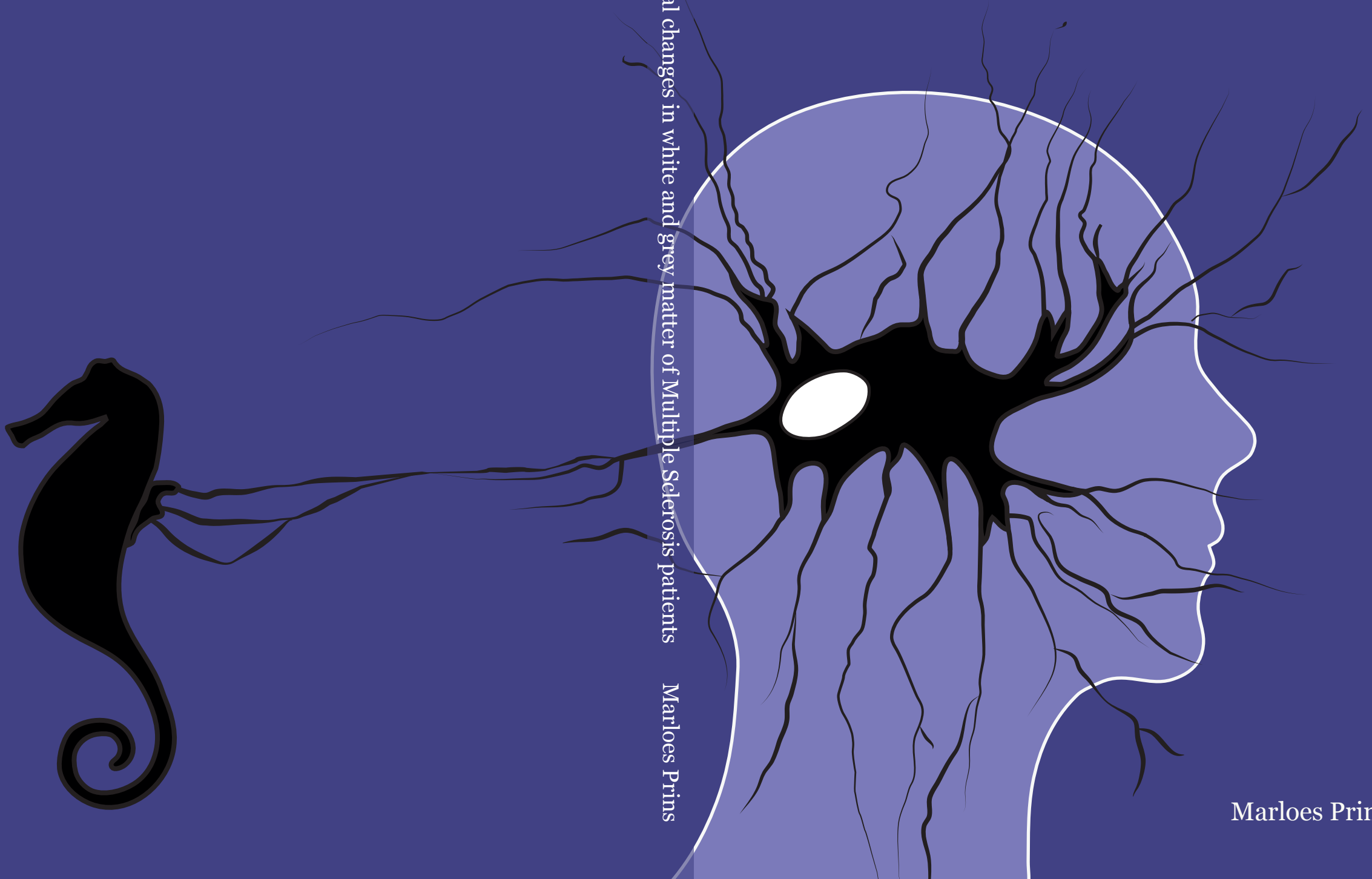


Neuronal and glial changes in white and grey matter of Multiple Sclerosis patients



Neuronal and glial changes in white and grey matter of Multiple Sclerosis patients Marloes Prins

Marloes Prins

Neuronal and glial changes in white and grey matter of Multiple Sclerosis patients

Neuronal and glial changes in white and grey matter of Multiple Sclerosis patients Marloes Prins

