

## D. PEDIATRICS

Dr. Thomas J. Spackman  
Chairman of the Department of Radiology  
University of Connecticut Health Center

There are a couple of things about pediatric radiology that indicate a particularly apt application for a low-dose portable X-ray device such as the Lixiscope.

The actual experience that any of us has had with the Lixiscope in approaching clinical problems and applying it to phantoms has been relatively limited. There is a certain risk in discussing clinical applications in a simplistic or facile fashion because it is not certain what the Lixiscope can or should be in its final configuration. There is another problem when one leaves small dental structure application for larger structures of medical radiographic application, in that the configuration of the Lixiscope as it is now is fairly constraining. Part of the problem is that the device has been given a name and a patent number and one tends to think of it in its current configuration; that is, an isotope source rigidly coupled to a high-gain image intensifier that measures one inch in diameter.

As various medical applications are analyzed, it becomes apparent that a more flexible design approach is needed. The device is a series of components which includes a source of radiation and an input phosphor with some characteristic that will complement the radiation incident upon it. The image intensifier, a competent high-gain intensifier, is really the device that makes this instrument different from existing systems. The use of a radioisotope source for diagnostic imaging is not unique. It has been used for field pack radiographic units in the past with high energy isotope sources.

From the medical standpoint, bigger patients require more flexibility in thinking about the design approach to the whole imaging system.

However, given the present constraints on the instrument, it was convenient to think about using the Lixiscope for a tiny patient. The youngest of the pediatric patients are quite tiny. The application that was most tempting to think about was in the neonatal intensive care unit for premature infants, usually with respiratory distress. Sometimes these tiny little babies are only 800 or 1,000 grams or 1,500 grams. In the Lixiscope evaluation, an experimental rabbit was used which was much larger than a very tiny premature infant.

The other important consideration in pediatrics relates to radiation exposure. This brings up a whole

new problem area regarding radiation effects, and that is not the intent of this paper. It is known, at least as a generalization, that radiation is not good for us, and it should be avoided if possible. There is some indication that the risk of late tumor development may be enhanced in infants that are born to mothers who have had abdominal radiation, pelvimetry, while the baby was in the uterus. That is still controversial, and the data vary, but there is strong concern about what is being done to these babies. Even once they are beyond the *in utero* stage, there is a general acceptance that during the sensitive phases of development, whether *in utero* or in the first months or even years of life, the theoretical risk to the patient is greater than in an adult organism. Thus, the low dose aspects of this device are appealing.

The potential use of the Lixiscope for the infant intensive care unit is very interesting. The neonatal intensive care unit at the University of Connecticut Health Center has some 15 or 18 bassinets. There are 250 or 300 transfers each year of distressed infants from surrounding community hospitals which do not have sophisticated maintenance facilities into the University of Connecticut Health Center. The actual transport mechanism, or vehicle, is affectionately called the "whale." It is a large bus, or superlarge van, that measures about 40 feet in length and is manned by a driver, a physician-nurse team and additional supporting personnel when necessary. It provides numerous support devices for monitoring and maintaining blood pressure and respiration. Some laboratory facilities, including blood gas determinations, are available, and it is really a fairly sophisticated transport vehicle.

The object of this obviously is to get the baby from the referring hospital into the neonatal intensive care unit in as safe and as rapid a way as possible. These are critically ill infants who are very sensitive to temperature changes and changes in ambient oxygen concentration, and the transfer has to be made relatively quickly. Actually, what happens is that the pediatric intern goes with a nursing team to the referring hospital, examines the infant to be transferred, and decides what immediate stabilization must be done in the referring hospital. This often includes obtaining radiographs and placing various tubes. The infant is then put in the transport vehicle and brought to the Medical Center.

There would be some advantage if part of that stabilization time could be avoided. Thus it was tempting to think about the possible use of the Lixiscope in the transport vehicle so that tubes and catheters could be placed and some radiographic evaluations could be made of the infant during transport. Again, the Lixiscope seemed to satisfy some pediatric needs.

It will be necessary to be careful in using this instrument to conform to each institution's human investigation guidelines. One of the concerns the developers of the instrument have had is what it will do to the radiation burden for the entire population. It is nice to think that the dosage or radiation will be cut down by fluoroscoping the tip of a finger to see if the broken needle is still impacted, but it makes one a little bit anxious to think of legions of physicians running around with Lixiscopes in their pockets, screening patients and doing various other evaluations. This could result in a substantial increase in the total population radiation dose and is reminiscent of the old fluoroscope in the shoe store before it went out of vogue.

The following paragraphs describe some of the ideas and the direction of thinking regarding potential applications for the Lixiscope. The figures which are presented fall into three groups. First are some conventional radiographs to illustrate the type of thing that is presently being dealt with in the infant or neonatal population: different things that happen to the babies, where their tubes are, what the tubes are for. Also presented is a series of pictures that illustrate the images that were made with the Lixiscope using an experimental rabbit. Finally, in a very theoretical and speculative frame, some of the other uses appropriate for the Lixiscope or a modification of it are presented.

Figure 1 is a normal chest X-ray in an infant. The heart is in the center and partly surrounded by a mass of tissue which is the thymus gland. The picture shows some faint markings running out to the

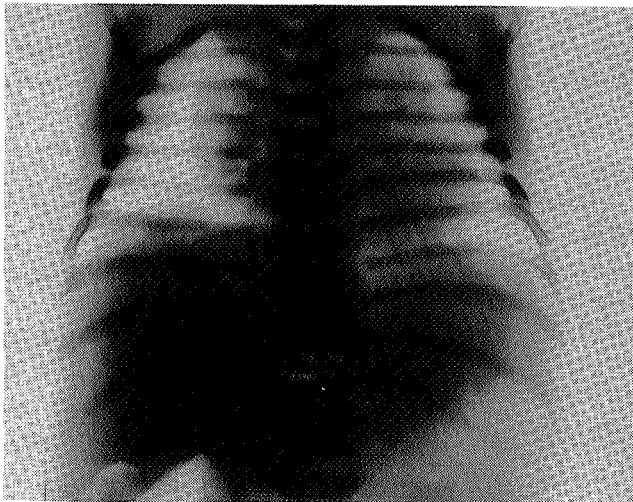


Figure 1. Normal Chest X-Ray of an Infant

periphery of the lungs which represent pulmonary blood vessels, and some of the airways can be seen.

Figure 2 shows one of the problems that might be encountered. The heart is no longer in the center; it has shifted to the patient's right side, and the left lung is very radiolucent. What has happened is that the lung blew out. It was stiff because of underlying pulmonary disease; it required greater airway pressure to maintain oxygenation. It simply popped like a balloon and collapsed when air leaked out. The collection of free air within the chest markedly decreases the ability to oxygenate the baby. If one could recognize this sort of a problem, when an acute change in the clinical status occurs during transport, therapy could be given by tapping the air collection with a needle or tube.

Figure 3 shows the chest tube that was placed in the same patient. The heart has moved back to the midline because the abnormal air collection was successfully drained.

Figure 4 shows some other types of tubes. One is used in an infant who had a gastrointestinal problem, and it is called a hyperalimentation line. It is placed in a vein over the shoulder at the base of the neck, and inserted into the vena cava that runs into the right side of the heart. It is a mechanism for getting high caloric concentrations into an infant, but that can't be done well in the tiny veins of the arms and legs because they will clot. It is not uncommon to see one of these tubes, when placed blindly, directed into the

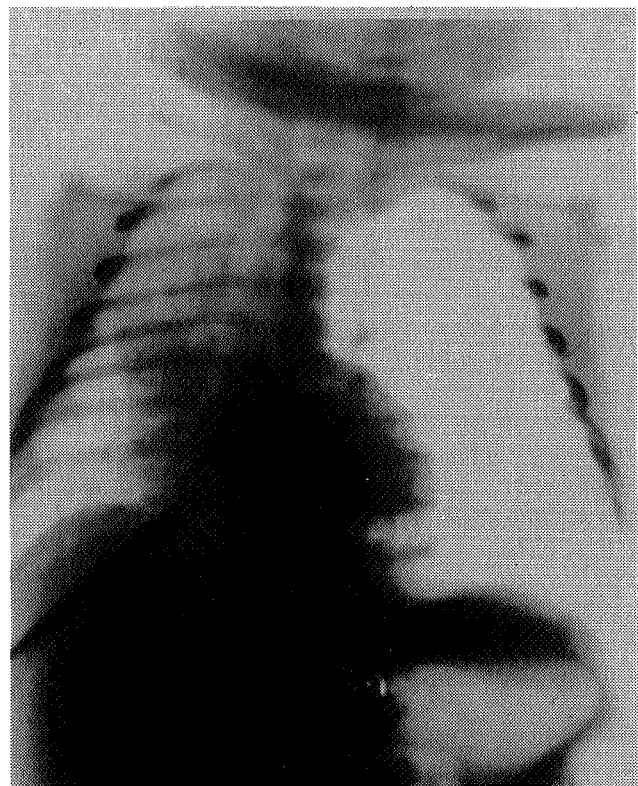
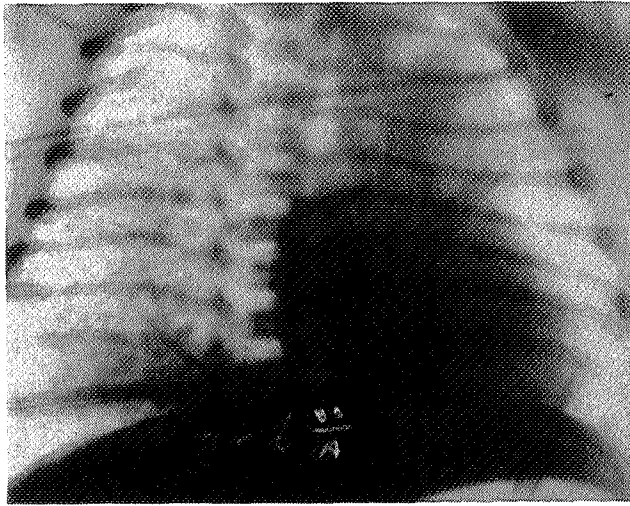
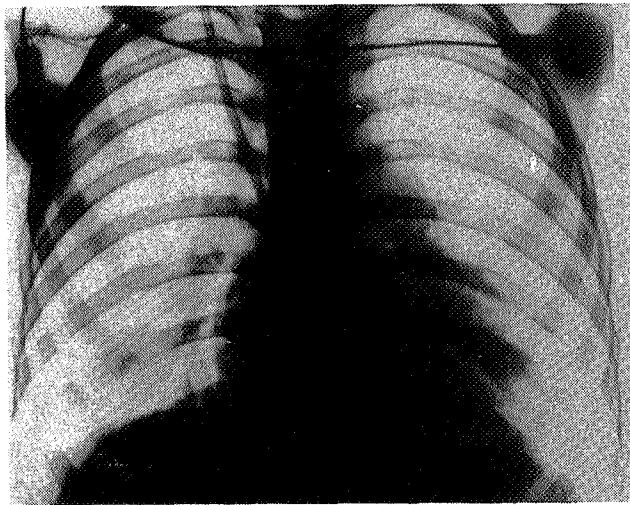


Figure 2. Abnormal Chest X-Ray of an Infant



**Figure 3. Chest X-Ray of Chest Tube in an Infant**

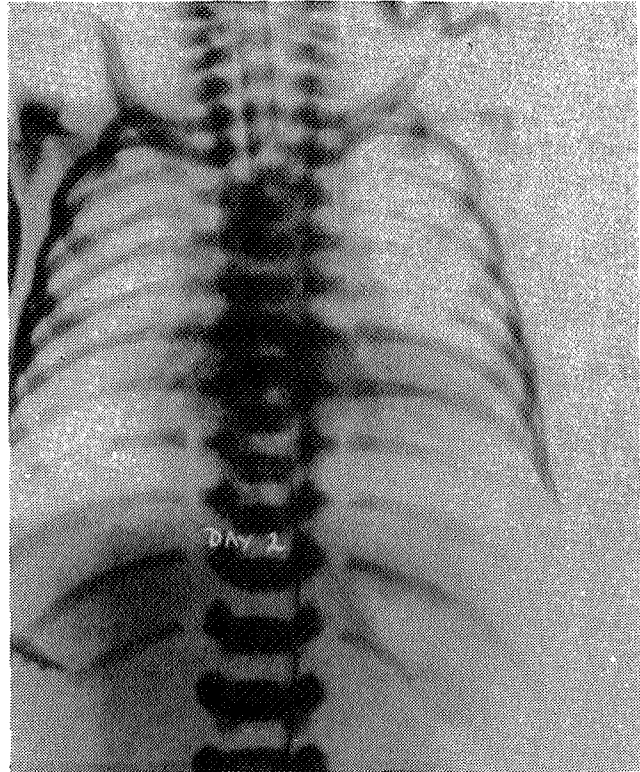


**Figure 4. Chest X-Ray of Other Types of Tubes in an Infant**

head rather than the heart, and that is not a good place to put a very high concentration solution.

Figure 5 shows an endotracheal tube which is used to maintain respiration. It is placed in the upper trachea, and one has to know where the tip of the endotracheal tube is so that it is not wedged in one of the two major airways, one supplying the right and one supplying the left lung. Obviously, if it is wedged in the right one, then the left lung is not going to get aerated very well, so one would like to know fairly accurately what the position of this tube is.

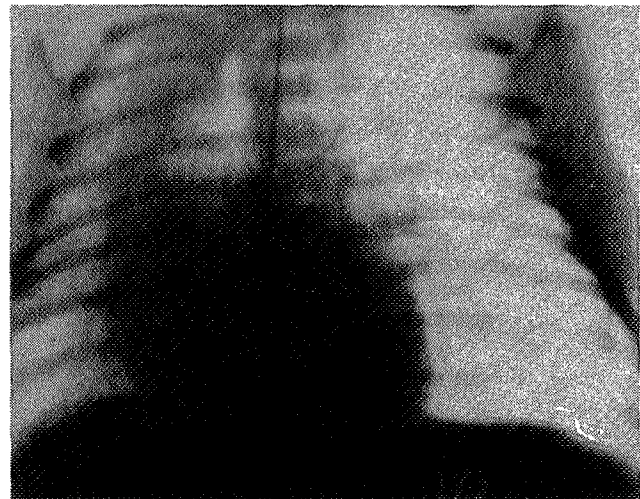
Also on the radiograph is an umbilical vessel catheter. It is fed in through the stump of the umbilical cord into the umbilical artery, and it is advanced into the major artery of the body, the aorta, where it is used for taking blood samples. Again, the position of the tip is fairly critical. It should be kept away from the orifice of the vessels to the kidneys and some other major abdominal organs, and that requires knowing where the tip is.



**Figure 5. Endotracheal Tube Placed in the Upper Trachea of an Infant. Along with the endotracheal tube is an umbilical vessel monitor**

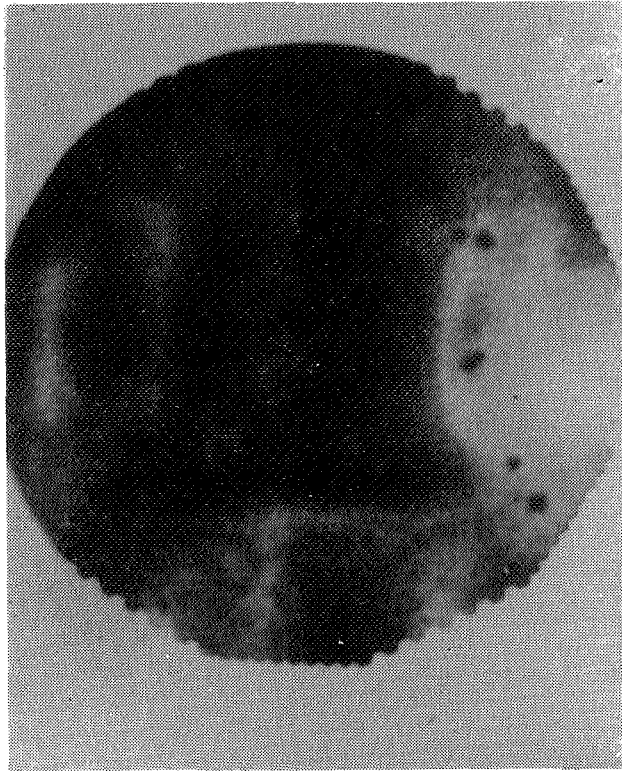
Figure 6 shows a nasogastric tube. This has a radiopaque strip, either lead or barium, impregnated within the wall of the tube. In general, these are some of the things that one is concerned with in the neonate.

Figure 7 is the first in a series of pictures made of the rabbit used in our evaluation. Some of the Lixoscope screen defects mentioned earlier appear. Some of the anatomic studies made on the rabbit are presented. There was interest in seeing whether an



**Figure 6. Nasogastric Tube with a Radiopaque Strip Impregnated within the Wall of the Tube**





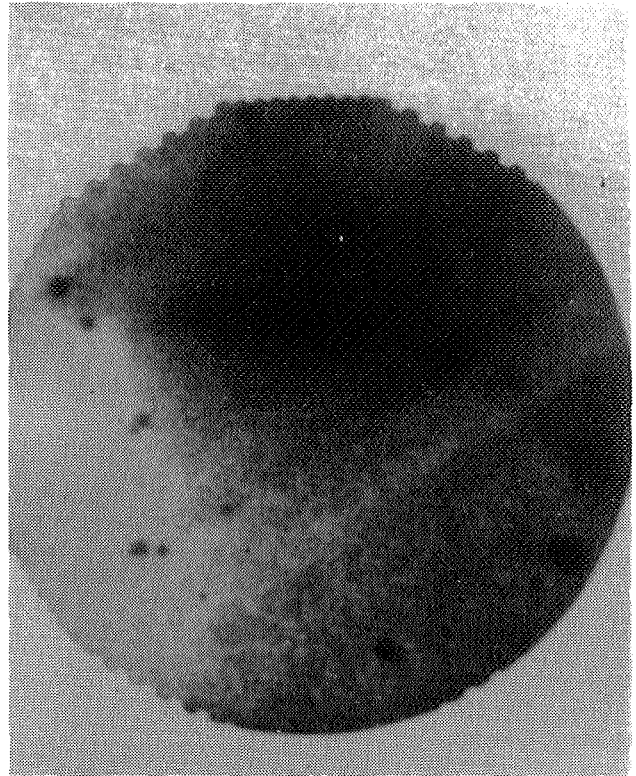
**Figure 7. Image of Interspace between Two Bony Vertebrae of the Spine of a Rabbit**

image could be made of the spine itself or the space between the bodies of the spine for space application. It's fairly crude, but one can distinguish an interspace between two bony vertebrae and can see some of the structures of the vertebral body.

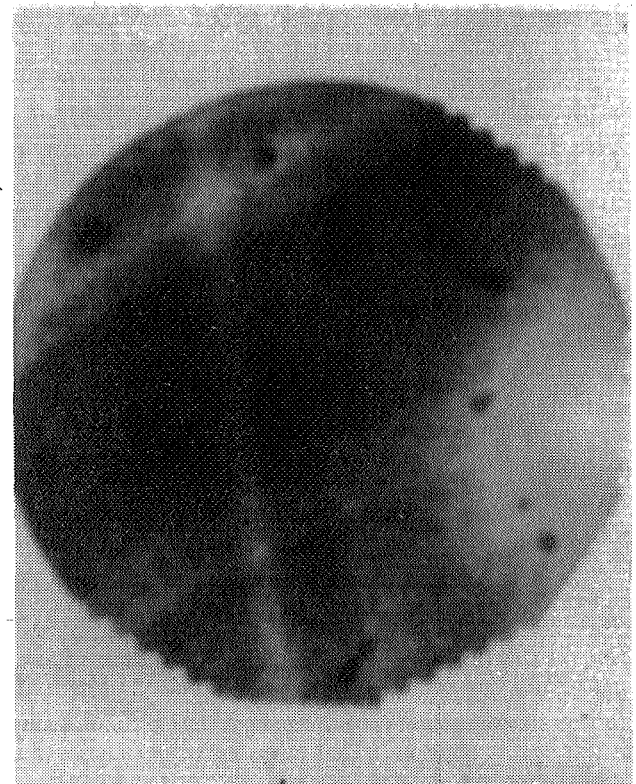
It was also decided to test the Lixiscope to see the diaphragm, the junction between the chest above containing air, and the water density abdomen below. One could see it, but it wasn't easy in the rabbit, as illustrated in Figure 8. Interestingly, even though with the hard-copy image one gets a chance to integrate more information because it's exposed over a period of time, there's a certain advantage in being able to move the fluoroscope over the part that you are looking at or having the part move under it. The diaphragm was clearly recognizable because it could be seen moving up and down and one sometimes gets a three-dimensional concept by being able to observe a structure from a variety of directions.

Figure 9 is a chest tube placed within the esophagus. It is reasonably well-defined, and the ribs are again well-seen against the aerated lungs.

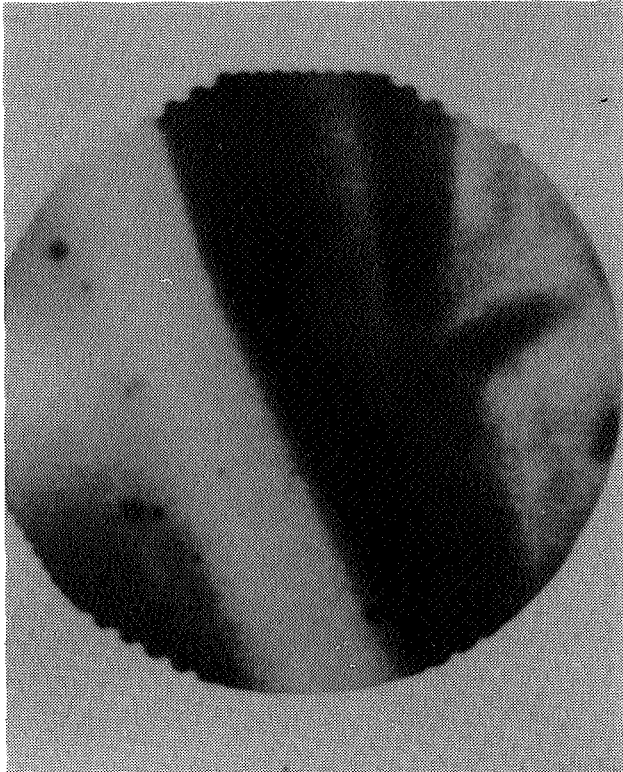
After sacrificing the animal, some iodinated water soluble contrast material, sodium diatrizoate, was placed into the trachea. As shown in Figure 10 it produced very nice imaging. That it has to do with the combination of using an iodinated compound for contrast material and radioiodine as a radiation source. The filled esophagus shows up as a very black



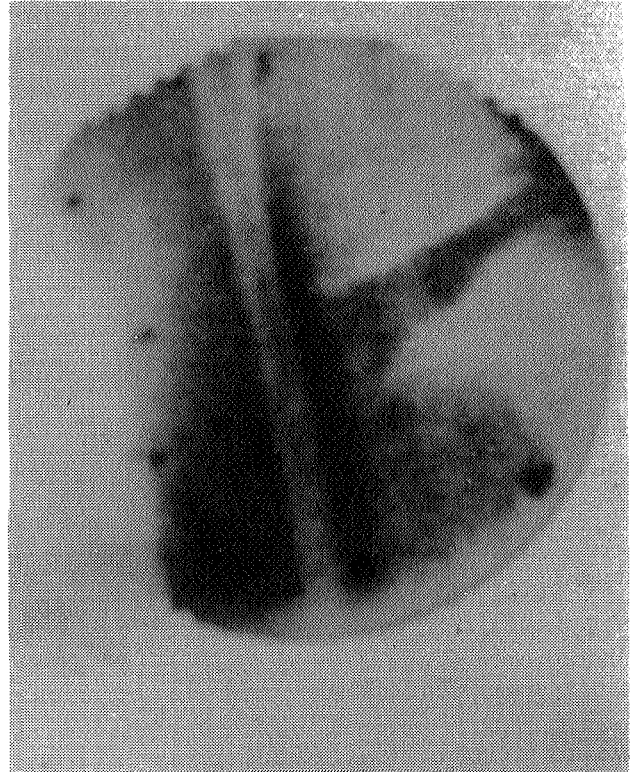
**Figure 8. Diaphragm of a Rabbit**



**Figure 9. Chest Tube Placed within the Esophagus of a Rabbit**



**Figure 10. Sodium Diatrizoate Placed into Trachea of a Rabbit**



**Figure 11. Feeding Tube in the Esophagus Exposed through the Neck of a Rabbit**

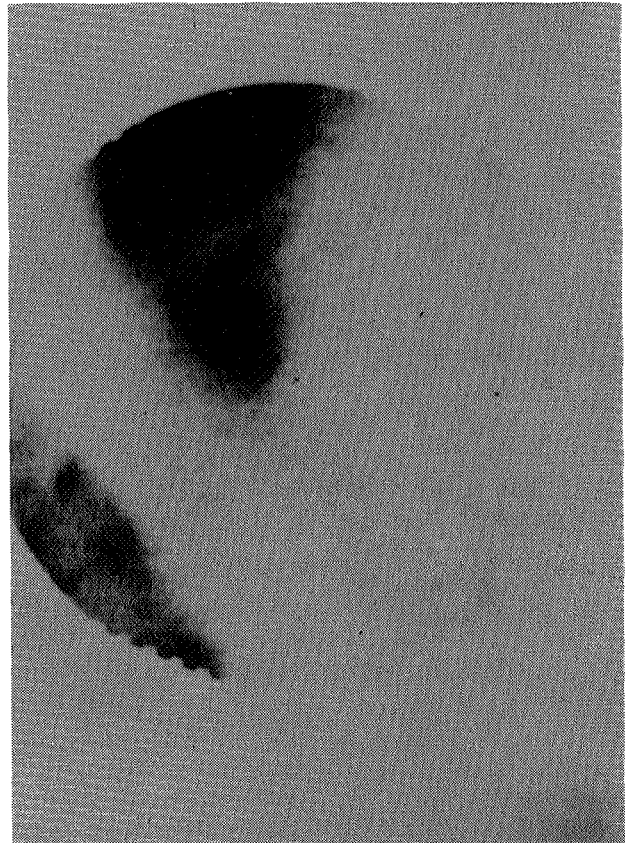
band. This was in the neck, and some of the bodies of the vertebral column in the neck can be seen.

Figure 11 shows a feeding tube that was placed in the esophagus and is also through the neck. Once again the vertebral bodies can be seen and the space between the bony structures, the joint space, is detectable in the picture.

A post-mortem angiogram was made using a needle to place the iodinated contrast material directly in the heart by a blind puncture. In Figure 12, the dark shadow of contrast in the left ventricle and a tubular structure—the major artery or the aorta—coming off the heart can be seen. It is therefore possible to image these deep structures, in a 3,000 gram rabbit, particularly if aided by the use of contrast material.

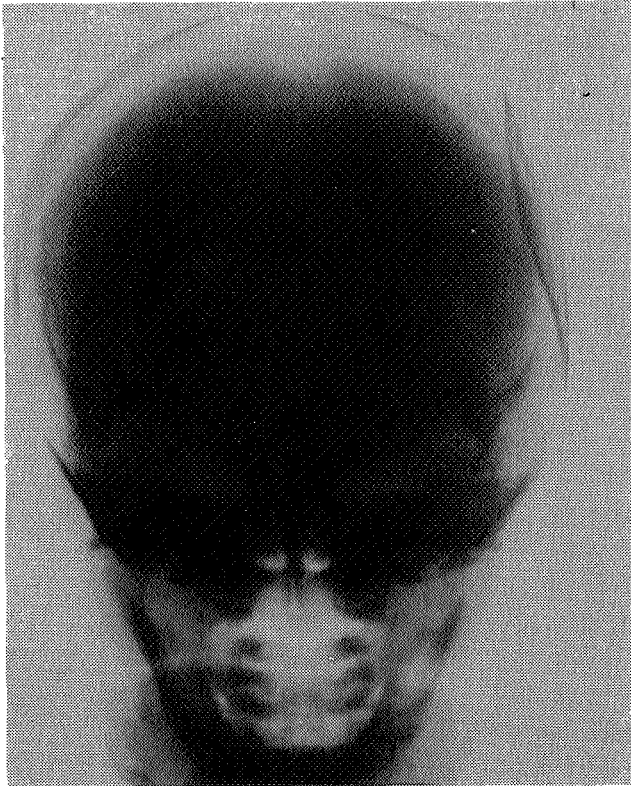In the following discussion some very speculative applications are presented. These are speculative in the sense that it's questionable as to how much will be added to patient care by being able to do these studies, and, secondly, because the equipment in its present configuration is not capable of performing the studies.

Figure 13 is a fracture of the skull in an infant that was born by a forceps delivery; it's pushed in. It is usually not terribly important to know about skull fractures unless they happen to be pressing on the adjacent brain tissue, and this is fairly gross. Normally, it is hard to see the depressed fracture unless you get the patient into exactly the degree of obliquity that



**Figure 12. Left Ventricle and Aorta of the Heart of a Rabbit**





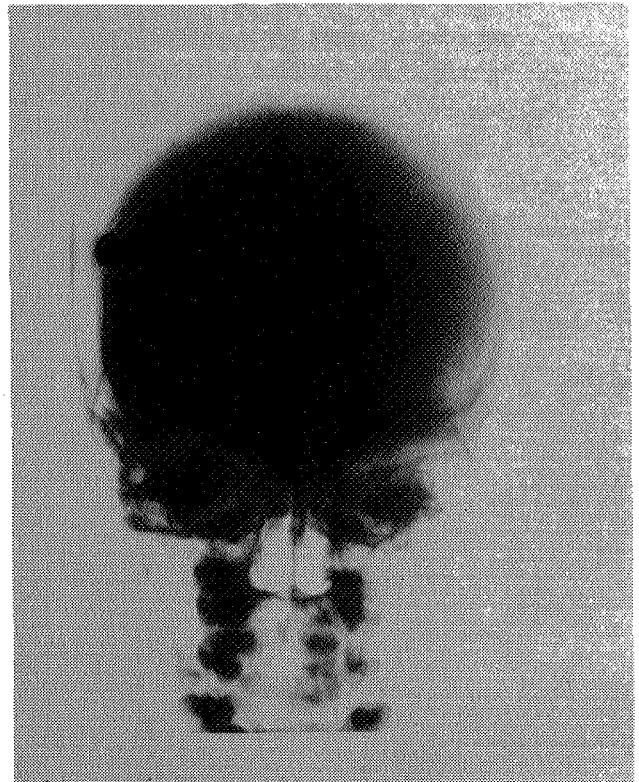
**Figure 13. Fracture of the Skull of an Infant**

will show it in profile, and that's difficult to do with standard views. What is really needed is an infinite number of images or fluoroscopy while rotating the head. It might be possible to use the Lixiscope for preliminary evaluation the same way the dental lab patient might be screened for caries, to at least scout the skull if there is sufficient penetrating power with the instrument.

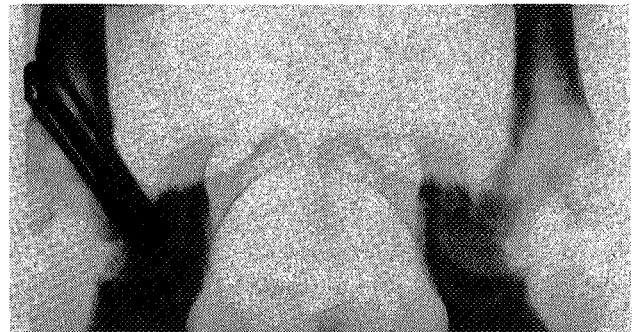A child with hydrocephalus, or water on the brain, is shown in Figure 14. Tubing has been placed within the ventricular system of the brain, to drain the excess fluid, and it is of some interest to the neurosurgeons, as they do this procedure, to determine the location of the tube.

Figure 15 shows a patient with slipped capital femoral epiphysis. The head of the femur has slipped off of its neck and it had to be stabilized by use of these pins. In this situation one would like to be able to see an infinite number of projections to be sure that one of the pins isn't sticking into the joint space. This would be difficult for the Lixiscope because the pelvis and hip are very thick structures requiring high energy for penetration.

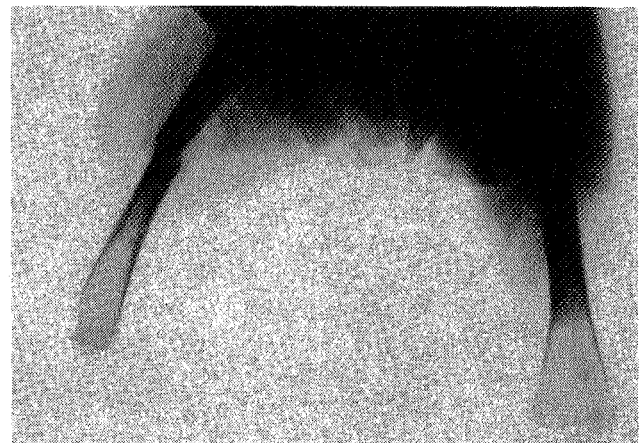
The simple fracture in Figure 16 looks like it is well-aligned when seen from the front. One might be inclined to say, "Well, this is a pretty good reduction of the fracture, and all we have to do is put it in a cast." However, as seen in Figure 17, which was taken from the side, there is marked angulation at the fracture site. Again, the actual geometry is important



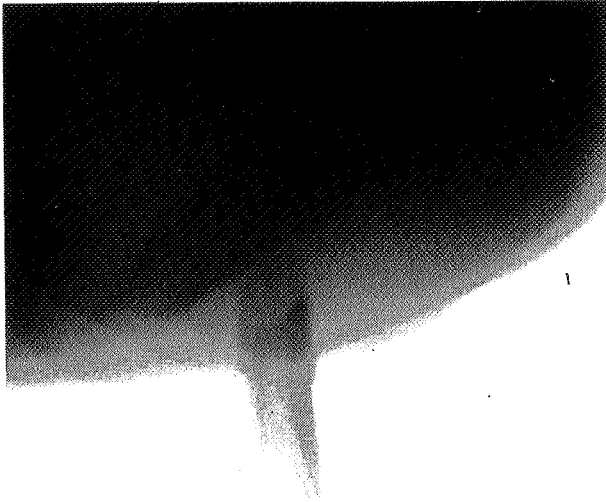
**Figure 14. Tube Placed within the Ventricular System of the Brain of an Infant with Hydrocephalus**



**Figure 15. Patient with Slipped Capital Femoral Epiphysis**



**Figure 16. Front Picture of Simple Fracture**

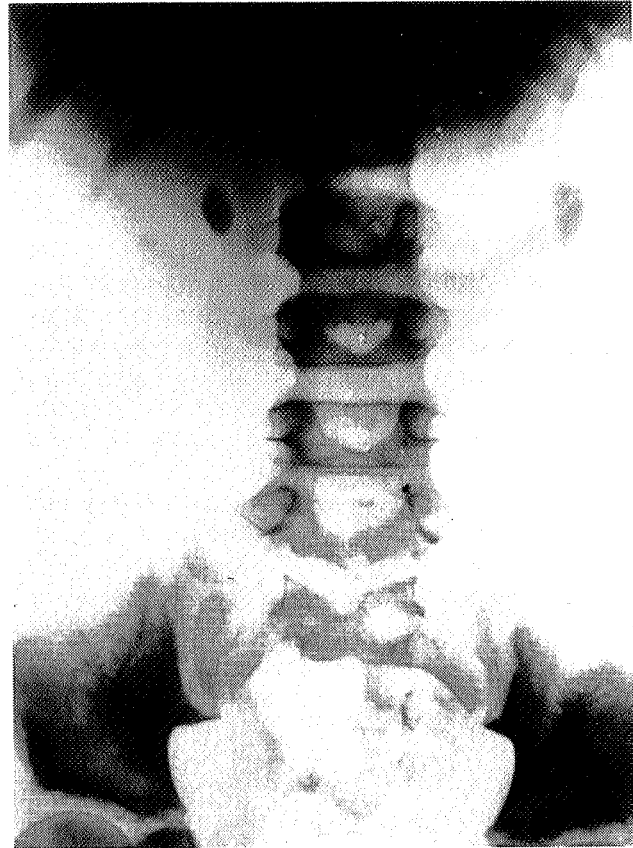


**Figure 17. Side Picture of Simple Fracture**

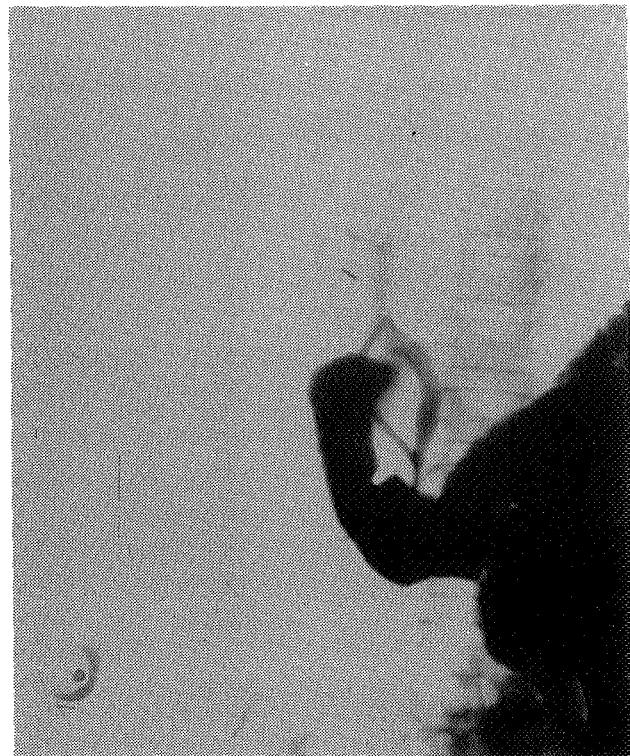and may be difficult to work out using conventional studies.

In Figure 18, a kidney stone is seen in the right kidney as an oval density. At the time of surgical removal of multiple renal stones, it is useful to radiograph the kidney during the operation to be certain all stones have been removed. There are ways of using a sterile film holder behind the kidney or adjacent to the kidney in the surgical wound, and exposing the film with a portable X-ray machine, but there is no theoretical reason why the entire Lixiscope could not be introduced into the surgical site, into the peritoneum. In other words, one could gas sterilize the Lixiscope screen and heat sterilize the radiation source and then just wrap the Lixiscope up after it is sterile and put it into the patient during the surgery to image what is going on—where the stones are.

Figure 19 is an operative cholangiogram. The gall bladder has been removed because of stones, a tube has been placed in the duct that carries bile from the gall bladder and the liver into the bowel. One would like to know at the time of surgery whether all the stones are out or if they are impacted in the duct. If the Lixiscope were introduced into the abdominal cavity,



**Figure 18. Kidney Stone in Right Kidney**



**Figure 19. Operative Cholangiogram with Tube**

it would be interesting to see if better detail imaging or better geometrics of imaging in this type of intra-operative procedure could be obtained.

Figure 20 shows a patient who had a long period of fever and had some ill-defined bone lesions. The figure shows the pelvis, and there is an abnormal lucency in the right iliac bone.

As seen in Figure 21, there was a similar abnormality in one of the ribs, and it was decided to get some tissue by biopsy for diagnosis. The possibilities included a primary or metastatic tumor, an osteomyelitis or infection that had seeded to the ribs, or some other kind of unusual abnormality. It is of obvious importance to have a diagnosis, and this requires getting a biopsy of a piece of the involved tissue.

The surgeons initially went in and did a biopsy of a rib which came back negative. A follow-up radiograph was done on the patient and found that the wrong rib had been removed, an understandable error resulting from difficult orientation at the time of surgery. This raises another theoretical possibility: could the fluoroscopic screen of the Lixiscope be used to image radioisotopes that have been injected in the patient, such as for conventional nuclear medicine studies? Can a bone-scanning agent be injected in the patient at the time of surgery, to expose the bone through the incision and look at it with the Lixiscope to decide whether the abnormality has been identified as indicated by increased radioactivity? If this can be done, and there is no inherent reason why it cannot, this sort of an error might be avoided by accurately localizing the site for bone biopsies.

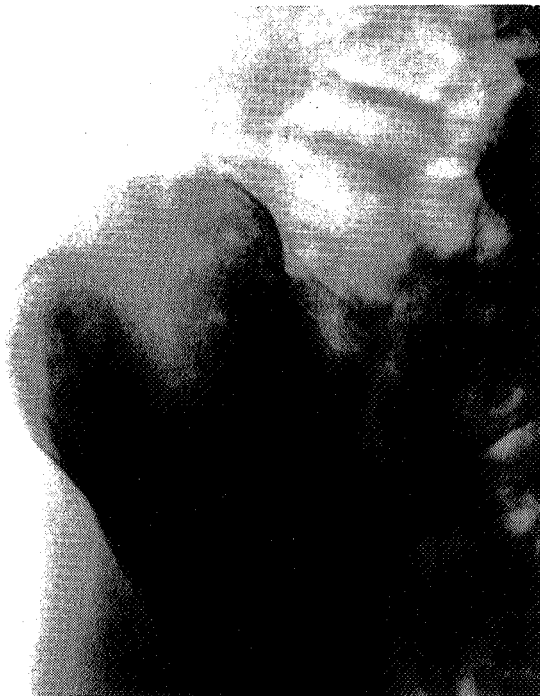

Figure 20. Picture of Pelvis

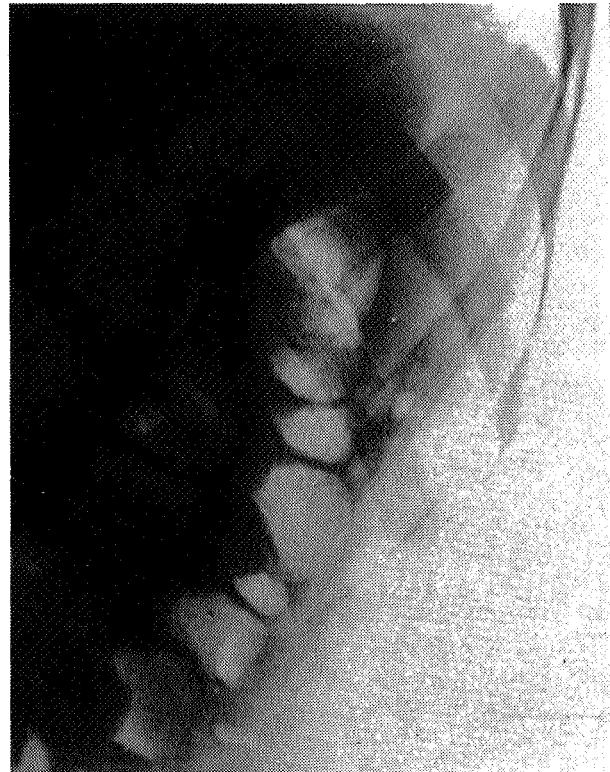

Figure 21. Picture of Ribs with Abnormalities

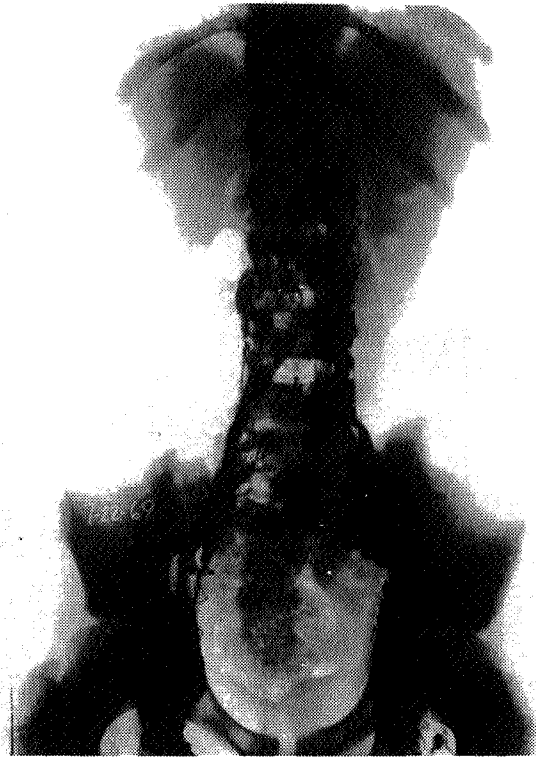Figure 22 is a lymphangiogram, a very tedious study where one makes a skin incision in the foot, finds a tiny little lymphatic channel, half a millimeter in diameter and almost transparent, and sticks a tiny needle into it to instill contrast material that will fill up the lymphatic vessels and then fill the lymph glands. Using this examination, one can see whether there is leukemia or lymphoma or other tumor invading the glands, or at least if there is destruction of the normal glandular architecture by a disease process.

After the needle has been inserted, one is not always sure that contrast material is going where it ought to be going, that is, into the vessel, or whether it is just leaking into the adjacent tissues. It might be possible to use the Lixiscope to identify whether contrast material is beginning to go up the lymphatic channels.

Secondly, there are some radioisotopes presently in use that are useful in identifying tumor tissue or infected or necrotic tissue, and one can occasionally discover hidden foci of tumor or infection by external scanning. It would be interesting, at the time of operation for lymph node biopsy, to have injected some of this material sufficiently ahead of time so that the Lixiscope screen could be used to identify the most abnormal lymph nodes by determining the site of the greatest radioactivity.

In summary, one can get far afield without restraint on imagination. The first group of pictures showed





**Figure 22. Lymphangiogram**

what the problem is; the second group showed what type of images can be obtained now using a rabbit for evaluation purposes. In the third set of photographs, some very speculative applications for the Lixiscope were presented. There are potential benefits in the Lixiscope, but to a medical radiologist the concept of the Lixiscope should be relaxed. It does not have to have the specific form of the present instrument but might be a series of component parts that could be designed in different ways and exchanged in different ways: an isotope source for some applications, a conventional X-ray source for other applications, an input phosphor designed to meet the task at hand, and hard-copy image or simply fluoroscopic real-time viewing depending on the specific information desired.

More clinical experience will be needed with the Lixiscope and it will be necessary to be mindful of the population burden of radiation that may be introduced with the Lixiscope. Certainly the engineering possibilities for the Lixiscope can be very exciting, and seem almost limitless.