

E. PODIATRY

Dr. Stephen Weissman
Department of Radiology
Pennsylvania College of Podiatric Medicine

It should be noted from the outset that this is a "pre-preliminary" report since Dr. Anthony Kidawa and Dr. Gerald Gorecki and I had the Lixiscope for approximately an hour in the foot clinic at a not very busy time.

However, based on this limited evaluation time, the use of the Lixiscope stirs the imagination and the possibilities for its clinical use seem endless.

Podiatry is a very surgically-oriented speciality and a great deal of this surgery is done in an office. Along these lines, a technique of minimal incision surgery has developed in the last few years. It is used primarily for permanent removal of excrescences, commonly called corns, on people's toes or between people's toes. Usually they are caused by small, bony prominences, an exostosis or a hypertrophy of a phalanx. It is quite simple to remove them, and cure the patient's problem, by making approximately a quarter of an inch incision, which is why it is called minimal incision surgery, and remove the offending, bony prominence.

Figure 1 is a drawing of the toe. It has a little red nail on it and three phalanges in it. On the head of the proximal phalanx is a very common place for an increase in bony density, just enough to cause the patient to develop a localized pressure reaction or hyperkeratosis.

However, it often does not show up well on an X-ray and there are limitations in the views that are taken.

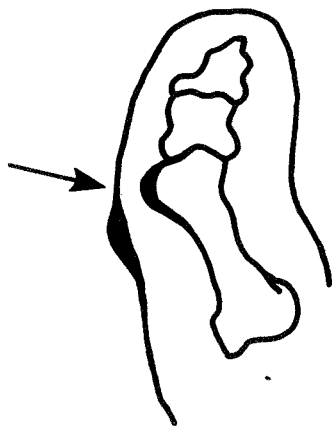


Figure 1. Drawing of a Toe with an Increase in Bony Density

Of course, additional views can be taken, but then the patient is exposed more and more to radiation.

In the surgical procedure a quarter of an inch incision is made, a bone rasp is inserted, and the bony prominence is removed. Thus, the Podiatrist is almost doing the surgery blind or by feel.

However, if the Podiatrist had a small fluoroscopic unit that he could quickly put over the area and take a look to make sure he was in the right place or that he had removed enough bone or had not removed too much bone, the procedure would be much improved. Every Podiatrist would have one of these units in his office.

On a slightly larger scale, the use of such a device on the operating room table would be an advantage. Figure 2 shows the metatarsal bones in a foot. Frequently, the Podiatrist does surgery on the bases of the metatarsals as shown in the Figure.

Obviously, if work is done on the first or the fifth metatarsal, there is very little trouble in properly

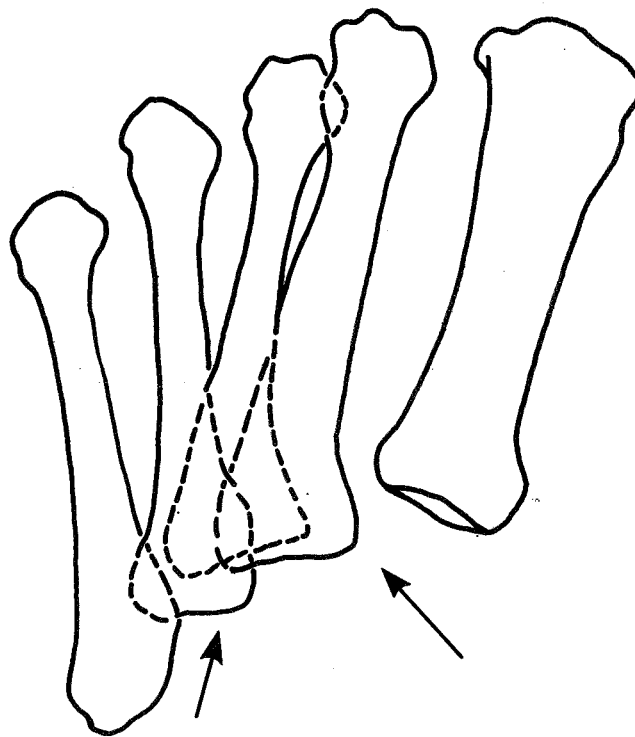


Figure 2. Drawing of the Metatarsal Bones in a Foot

locating these. However, on the base of the second, third and fourth, where the area is primarily bone, it is very difficult to determine whether the Podiatrist is operating on the correct one or not. This is especially true on the third or fourth, which is between all the others.

Again it would be advantageous to have a quick fluoroscopy unit that would be sterile and could be used in the operating room to make sure that the Podiatrist is working on the right one.

Figure 3 is a side view of the heel bones: the ankle bone, or the talus, and the bone in the heel, the calcaneus. There is a little hole in the middle called the sinus tarsi.

In children who have very flat feet, a surgical procedure is done in which either a piece of bone or a piece of medical grade silastic is inserted into the sinus tarsi. It only takes about an inch or an inch-and-a-half incision. It is right underneath the skin and is easy to get to. But grossly it never looks the same as on X-ray with these abnormally shaped bones. This necessitates bringing in an X-ray unit, and taking a picture on the table to make sure it is in the right place. This wastes a half hour and the longer the child is on the table and under the anesthesia, the more morbidity, post-operatively.

Again, a Lixiscope could show this right in the operating room. It would tell the Podiatrist that he is in exactly the right place and has accomplished what he wanted to.

The Lixiscope would have the same applications in treatment of trauma, fracture reductions, and so forth. If the dose is as low as claimed, then it beats a regular fluoroscopy unit, and it is better than doing a closed reduction of a fracture, X-raying it, doing another closed reduction because the site was missed the first time, and then X-raying it again and maybe doing it a third time. The X-ray exposure would be reduced considerably.

Another application that is very desirable is the

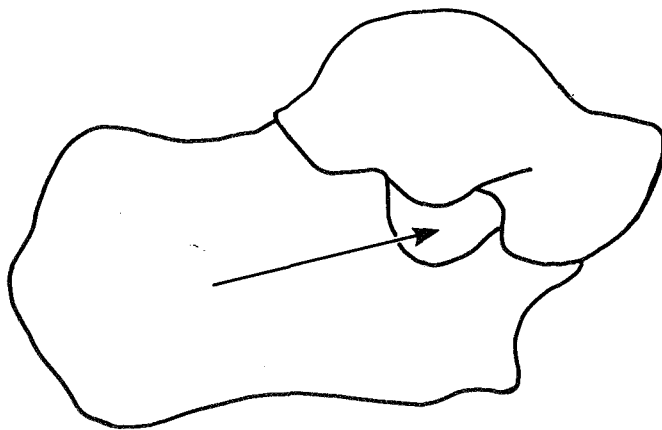


Figure 3. Drawing of the Side View of the Heel Bones

unlimited number of views one can get with a quick sweep with a Lixiscope. The Lixiscope can pass almost 360 degrees around a small joint in a matter of a few seconds, something that would take a considerable number of X-ray views and still not catch exactly what was wanted.

This was demonstrated very neatly in the clinic on a patient with an ulceration on the toe. Osteomyelitis or a bone infection was suspected. The bone infection was not detected with standard X-ray. However, the Lixiscope showed that right around the corner, where the two-plane radiograph could not show, the beginning periosteal reactions to the infection could be seen. Therefore, using the Lixiscope, a case of osteomyelitis was detected two weeks before it showed up on standard radiographs. Again, another great use for the Lixiscope.

The Lixiscope also magnifies. It was found that one of the screens magnified everything by about twice the size. This can also be accomplished on a regular X-ray. It was also found that the resolution was not as great as desired at times.

For foreign body location, the value of the Lixiscope is obvious. Today, a number of implants in the foot are made of metal or silastic. To examine an implant after it is in, the regular or standard X-ray views are taken and a static or nonfunctioning view of the implant is made. To look at it under fluoroscopy, a rather long exposure is needed.

If it could be done quickly with a low-dose Lixiscope, it could be determined if the prosthesis is functioning properly as planned or if it is in the right place during gait.

In the lower part of Figure 3, where the talus and calcaneus can be seen, two of the three joints between these two bones, the posterior and middle facets, are indicated. Occasionally, a tarsal coalition is found in young adults. That means that the two bones that should be separate are fused together. This causes muscle spasticity in the leg because the muscles are not able to function properly, leaving quite a painful foot. It is difficult to diagnose.

If an X-ray view is made of the posterior aspect of the ankle with the right angulation, the middle and the posterior facets can be seen. However, it is very difficult to get that view properly and have it be meaningful.

If the X-ray is off by two or three degrees, the joint space will be missed. That is a problem because in every individual the angulation of those facets is different. To get the proper view, it is necessary to expose them at least three or four times.

If the Lixiscope could penetrate a thick part such as described, it would be a natural; and it would cut down the radiographic exposure considerably.

Sometimes X-rays are taken with a patient's shoe on, since shoes can cause a great deal of pathology.

So a device with good penetrating power is needed. It should be stronger than the Lixiscope is now. But, again, it would be a natural for that use.

Another useful application would be in arthrography, or taking X-rays of joints with dye in the joint. The hardest part is placing the needle in the joint. If the joint is missed, the dye is spilled into the soft tissues, and nothing can be seen. An X-ray or the fluoroscopy unit can be used, but a device that gives a much lower dose and can be used rather quickly is a natural for this application.

The Lixiscope, therefore, seems to have a few features that make it appear quite promising. It is really easy to use and it is fast. It is easy to over-expose a patient because once you start looking, you just keep going from joint to joint and around and around. It also takes a fair amount of experience to be able to pick up what you want to see. It is not the same as looking at an X-ray. Without experience the patient can be over-exposed. However, it does give a low dosage. It is excessively movable, sometimes too movable, and it is a bit difficult to photograph some of the pathology. For example, a foot was placed under the Lixiscope or in the Lixiscope, and the camera was connected. It was difficult to find what had originally been found because everything had been moved. To get a good picture, the patient's leg had to be twisted because the stand would not move properly. To alleviate this problem, the Lixiscope definitely needs a lot of development.

There are also some other negative factors or disadvantages. For instance the resolution was found to be less than adequate at times, especially when trying to examine joint surfaces. Arthritic joint surfaces don't show well. It did, however, show bony impingements. If the two opposing surfaces of the joint were no longer parallel, it could be seen, and when the joint was moved, the bony prominences could be seen impinging. Of course, this could be done under any fluoroscopy unit.

It was a little difficult to get used to the inverted image at times. The Lixiscope does not penetrate a thick part. It is great for toes, but unfortunately it is not so great for the back of the foot and for ankles.

The Lixiscope needs a system for exposure calculation. In its present configuration, you turn it on and maybe time it; although it would be nice if it had a built-in timer. A little beeper like a Polaroid camera would be advantageous.

Figure 4 shows a distal phalanx, the middle phalanx, and the interphalangeal joint space. The resolution is not too good. It is not as good as looking through the actual Lixiscope. Figure 5 again shows an interphalangeal joint. The break in continuity, a minor trauma, can be seen in this picture.

Figure 6 shows the medial aspect of a metatarsal phalangeal joint. The patient had a very small bunion.

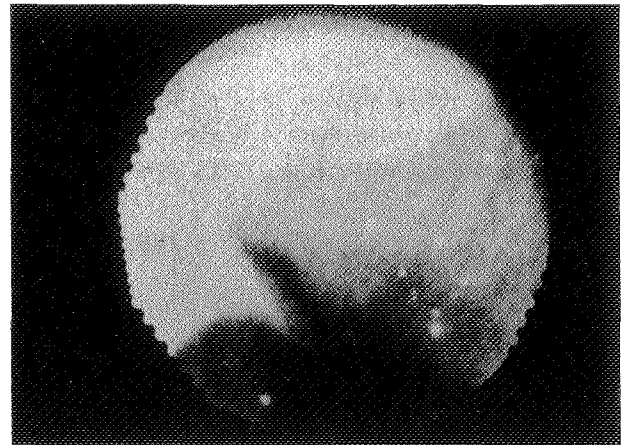


Figure 4. Distal Phalanx, Middle Phalanx, and Interphalangeal Joint Space

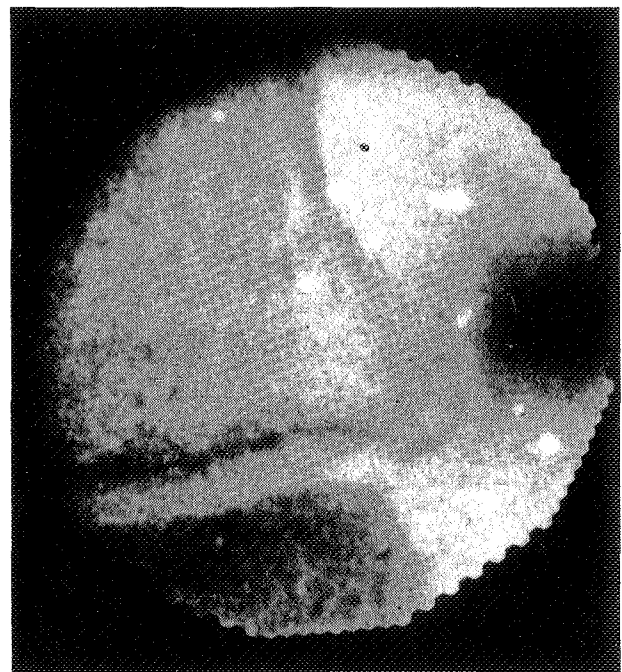


Figure 5. Interphalangeal Joint

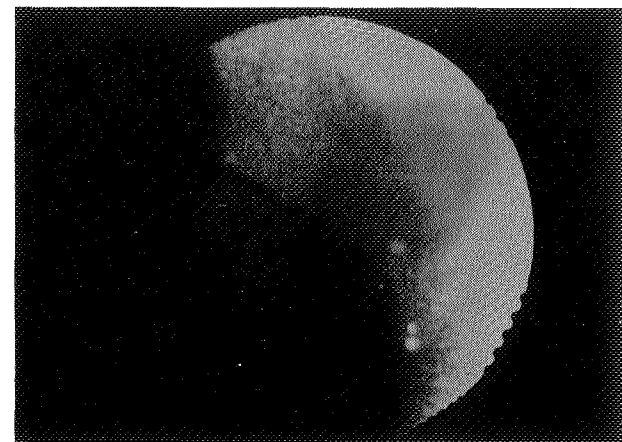


Figure 6. The Medial Aspect of a Metatarsal Phalangeal Joint

The uneven joint space was defined. Unfortunately, the patient moved and the desired picture was not obtained which appears to be another problem with the Lixiscope.

Figure 7 shows a patient's finger with psoriatic arthritis. The little grooves which are characteristic of the disease are on the tip of the phalanx. The picture shows some bony reaction. The patient caught the finger, or injured it, in a lawn mower a week before this was taken.

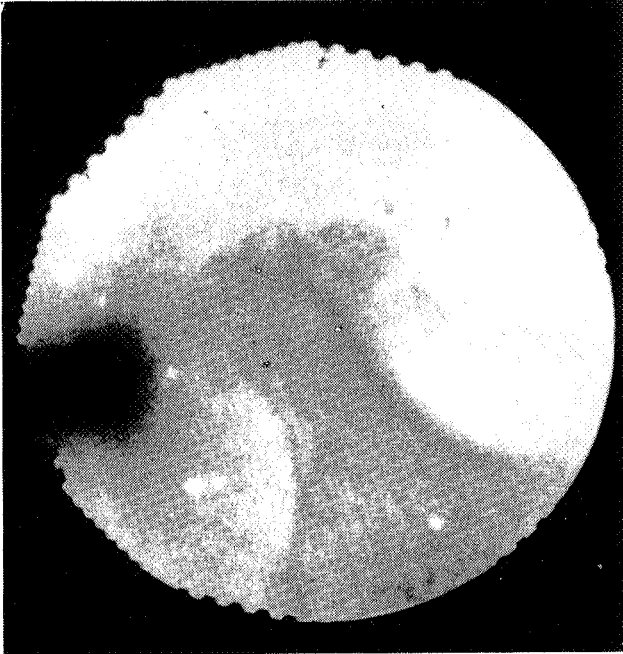

Figure 7. A Patient's Finger with Psoriatic Arthritis

Figure 8 is a lateral view of the distal end of the toe and the distal phalanx. The curve can be seen. This picture is one that is never seen with an X-ray. It is very difficult to take little pieces of film and put them between people's toes and shoot without having them move. This just illustrates one of the unique applications for this Lixiscope. It has a great future with a little bit more development. Eventually, it may be in every Podiatrist's office and quite a few dental offices.

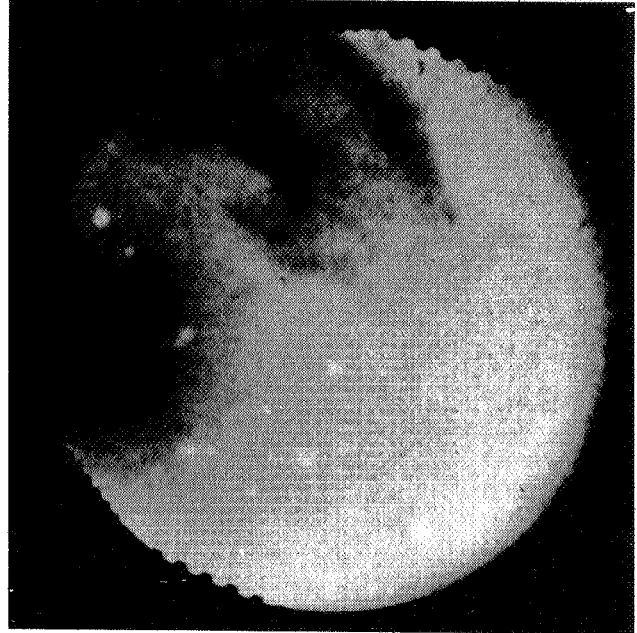


Figure 8. Lateral View of the Distal End of the Toe and the Distal Phalanx