

N O T I C E

THIS DOCUMENT HAS BEEN REPRODUCED FROM
MICROFICHE. ALTHOUGH IT IS RECOGNIZED THAT
CERTAIN PORTIONS ARE ILLEGIBLE, IT IS BEING RELEASED
IN THE INTEREST OF MAKING AVAILABLE AS MUCH
INFORMATION AS POSSIBLE

EXPERIMENTAL JOINT IMMOBILIZATION IN GUINEA PIGS
Effects on the Knee Joint

J. P. Marcondes de Souza, F. F. Machado, A. Sesso, and V. Valeri

(NASA-TM-76067) EXPERIMENTAL JOINT IMMOBILIZATION IN GUINEA PIGS. EFFECTS ON THE KNEE JOINT (National Aeronautics and Space Administration) 32 p HC A03/MP A01
N81-20696
Unclas
CSCL 06C G3/51 41867

Translation of "Imobilizacao Articular Experimental em Cobaios. Efeitos sobre a juntura do joelho", Revista da Associacao Medica Brasileira (Brazil), Vol. 10, No. 7, 1964, pp 159-175



STANDARD TITLE PAGE

1. Report No. NASA TM-76067	2. Government Accession No.	3. Recipient's Catalog No.	
4. Title and Subtitle EXPERIMENTAL JOINT IMMOBILIZATION IN GUINEA PIGS Effects on the Knee Joint		5. Report Date September 1980	
		6. Performing Organization Code	
7. Author(s) J.P. Marcondes de Souza, F.F. Machado A. Sesso and V. Valeri		8. Performing Organization Report No.	
		10. Work Unit No.	
9. Performing Organization Name and Address Leo Kanner Associates Redwood City, CA. 94063.		11. Contract or Grant No. NASW-3199	
		13. Type of Report and Period Covered Translation	
12. Sponsoring Agency Name and Address NASA HEADQUARTERS Washington, D.C. 20546		14. Sponsoring Agency Code	
15. Supplementary Notes Translation of "Imobilizacao Articular Experimental em Cobaios. Efeitos sobre a juntura do joelho", Revista da Associacao Medica Brasileira (Brazil), Vol. 10, No. 7, 1964, pp. 159-175			
16. Abstract The authors studied in young and adult guinea pigs, the aftermath experimentally induced by the immobilization of the knee joint in hyperextended forced position. Joint immobilization which varied from one to nine weeks was attained by plaster. Eighty knee joints were examined macro and microscopically. Alcian Blue (0.5%), Floxine (0.5%) Toluidine Blue (1%) and hematoxylin-eosin dyes were used. The main findings were: 1) muscular hypotrophy and joint stiffness in all animals, directly proportional to the length of immobilization; 2) haemarthrosis in the first weeks time; 3) intra-articular fibrous tissue proliferation ending up with fibrous ankylosis; 4) hyaline articular cartilage erosions; 5) various degrees of destructive menisci changes. The authors offer a tentative explanation of the fibrous tissue proliferation and of the cartilage changes.			
17. Key Words (Selected by Author(s))		18. Distribution Statement Unclassified-Unlimited	
19. Security Classif. (of this report) Unclassified	20. Security Classif. (of this page) Unclassified	21. No. of Pages 30	22.

EXPERIMENTAL JOINT IMMOBILIZATION IN GUINEA PIGS

Effects on the Knee Joint¹

J. P. Marcondes de Souza², F. F. Machado³, A. Sesso⁴, and V. Valeri⁵
Ribeirao Preto, SP

Bibliographic Review

/159*

Cloquet [5] seems to have been the first to describe in 1821, the effects of the immobilization of a joint.

In 1871, Menzel [10] studied, on 2 adult dogs and 6 rabbits, joint immobilization with a cast; he noticed in several cases a muscular contraction which prevented joint movement. The article describes several degrees of joint lesion.

Di Molfetta [6] in 1936 analyzed in 12 rabbits the behavior of the joints in limbs immobilized by casts, assuming that the alterations found by several authors came from sores and not from immobilization.

Bennett and Bauer [1] in 1936 induced surgically, in a classic work, defects of 8 x 2 x 5/10 mm on the femur joint surface of young dogs. After 4 weeks, they observed regeneration, consisting in the multiplication of cartilaginous cells adjacent to the surgical lesion. They concluded that healing is faster in the young dog than in the adult dog and that the proliferative activity

¹Quirino Ferreira Neto Prize of 1963, awarded by the Brazilian Association of Orthopedics and Traumatology.

²Prof. of Clinical Orthopedics, Faculty of Medicine of Ribeirao Preto.

³Assistant in Clinical Orthopedics, Faculty of Medicine of Ribeirao Preto.

⁴Ex-Assistant in the Section of Human Functional and Applied Morphology of the Faculty of Medicine of Ribeirao Preto.

⁵Assistant in the Section of Human Functional and Applied Morphology of the Faculty of Medicine of Rebeirao Preto

*Numbers in the margin indicate pagination in the foreign text.

of the cartilage is more pronounced in the deeper zones.

In 1954, Subha Rao [13] concluded that the experimentally produced cartilage lesion in mice is followed by production of fibrin, granulating tissue, fibrous tissue, and possibly fibrous and hyaline cartilage. He found that the fibrous tissue comes from the perichondrium and the neighboring connective tissue.

Sokoloff [12] studying in 1956 the degenerative joint disease in mice, concluded that the posterior detachment of the joint capsule is accompanied by cartilaginous and osseous fibroblastic proliferation; the tissues of the popliteal region may be subject to trophic disturbances of mechanical origin. The disease is spontaneous in the mouse, and the topographic distribution is consistent with the postural characteristics of the animal.

In 1956, Trueta [15], used for the first time, a constrictor to produce experimentally a joint cartilage lesion in rabbits.

Salter and Field [17] described in 1960 the effects of constant compression on the joint cartilage, suggesting the following hypothesis: when a joint is strongly compressed or immobilized in a forced position, the two opposite areas of the joint cartilage would experience continuous compression. Since the joint cartilage receives its nutrition through the diffusion of the synovial fluid through its intercellular substance, the continuous constriction of a cartilage area would prevent the diffusion of nutrient fluid, which might result in local destruction of the cartilage. The authors studied in three series of experiments, the constriction of the joint surfaces: with a constricting device similar to Charnley's in the first two series, and with joint immobilization by a plaster cast in the third series. The animals suffering continuous constriction showed greater rigidity, more resistant intra-joint adhesions and more intense hyperemia than those immobilized in a forced position with a plaster cast. The authors concluded that the lesions observed in the joint cartilage

of all 87 joints undergoing constriction for more than 6 days prove the hypothesis proposed at the beginning of the study.

Durke Evans, Eggers, Butler and Blumel [3] studied in 1960 the knee joints of rats immobilized in a bending position the result of remobilization with forced abrupt movement, gradual passing movement and pure active movement. The macroscopic findings were: muscular hypotrophy in the animals killed after the first 2 weeks; intercondylar space filled by fatty connective tissue. In those killed after 60 days, among other findings, the following are striking: the thickening of the infrapatellar adipose body and the loss of luster of the cartilage of the femur condyles. Microscopically, they observed proliferations of the subsynovial connective tissue, vascular thickening, and finally adhesions on the surfaces of the femur condyles. In the cartilage, the tangential layer disappeared on the sixtieth day. Thinning of the cartilage joint was also most pronounced at the periphery of the femur condyles. The area of constriction was no longer observed after 30 days, so that the authors estimated that there was probably adaptation of relaxation of the initial forces of constriction. In the study of remobilization, they believed that one of the mechanisms of limited restoration of the joint movement was elongation of the adhesions, a fact they tried to prove by photographs. /160

Trias [14] in 1961 submitted the knee joints of 35 rabbits to constriction in a device similar to Charnley's. In 30 animals, the author had to add a plaster cast to prevent the tendency of the rabbits to bend their knees. The constriction was exerted continuously for 15 animals, and intermittently in 14 cases. After 4 days of constant constriction, the animals suffered severe lesions in the areas of direct contact. The first histological evidence of damage suffered was the loss of nuclear color of the chondrocytes; the next symptom was progressive thinning and disappearance of the cellular boundaries of the chondrocytes; this was followed by fibrillation of the cartilage. Finally the veins

penetrated into the cartilage and there was substitution by fibrous tissue. In 11 animals suffering intermittent pressure, there was no sign of cartilaginous degeneration. The first indications of regeneration were increased mitotic activity and better coloring of the chondrocytes.

Calandruccio and Gilmer [4] studied in 1962 in 18 young dogs the results of the surgical lesions of variable size induced in the cartilage of the femur condyles. The most important data for the repair process in complete lesions was active increase of the granulation tissue coming from the subchondrial bone. The vascular tissue appeared thus to inhibit the formation of new cartilage. In complete lesions not completely filled with fibrous tissue, the embryonic cartilage which seemed to derive from the superficial cellular layers seemed to fill the fissure. In the incomplete fissures, the repair seemed to originate in the superficial layer, and the organized tissue undergoes progressive differentiation.

In 1962, Brower et al. [2] injected different dyes in the joints of rabbits of ages between 2 weeks and 2 years and a half. The injected dyes were neutral red, alizarin red, Evans blue, methylene blue and toluidine blue. Technical difficulties prevented these authors from reproducing the experiments of Salter and Field. The main results were the following: the entire thickness of the joint cartilage of the distal part of the femur was colored 10 to 15 minutes after inter-joint injection with neutral red. Toluidine and methylene blues also diffuse rapidly through the joint cartilage. Neutral red injections in the medullar cavity of the epiphysis did not color the joint cartilage. The perfusion of dye through the aorta did not color the joint cartilage. They concluded that the possibilities of nutritional exchange between the epiphyseal bone and the joint cartilage were extremely slight.

Hall [3] in 1963 tried to immobilize the knee joints of young rats in a non-rigid manner. He killed the animals at intervals varying from 27 to 123 days. He described the following results:

the cartilages of the tibia and femur had always thickened; in the final stages of the experiment, a slight degeneration was beginning to take place in the areas which did not support any load, and vascular invasion from synovial adhesions, was causing peripheral cartilage destruction. In accordance with Trueta's concepts, he concluded that the increase of function caused hypertrophy, while decrease causes atrophy, to the extent that a strong continuous pressure would lead to necrosis.

As we have just seen, the damages induced by joint immobilization and the capacity of the hyaline cartilage to stand abnormal pressures and traumas, also the possibility of regeneration, have been studied by many authors.

We may say that three different methods were adopted in studying this problem.

Thus, a first group of authors (Cloquet, Menzel, Di Molfetta, Salter and Field), using a plaster cast to immobilize the joints, attempted to study the effect of the latter on the various components of the joint.

Another group (Subha Rao, Bennett and Bauer, Calandruccio and Gilmer) investigated the problem of the regeneration of the cartilage traumatized by different agents.

More recently, a third group (Trueta, Salter and Field, Evans et al., Trias, Hall) studied the effect of high pressures on joint cartilages, using a constricting device.

It was the study of Salter and Field which aroused our interest in the knowledge of the effects of immobilization of a joint in a forced position. We therefore decided to reproduce the third series of experiments by these authors, using guinea pigs as test animals (Fig. 1).

We planned to work with young animals and adults, to observe the lesions in each group, and compare these groups with each other.

The age chosen for starting to use the cast in the group of young animals was arbitrarily fixed as 3 months, because we found that it represented satisfactorily the period of most intensive growth in the animals.

We chose the age of 15 months to represent the group of adult animals since, according to Farris [7], guinea pigs increase in body length up to this age; after 15 months, there will only be changes in weight.

Material and Method

A. Material

In this study, we used 87 guinea pigs, divided into 2 groups:

1. Young animals, 46 guinea pigs, 3 to 5 months old, weighing between 310 and 520 grams. Of these 46 animals, 34 were put in plaster casts (see Table I), while 8 were killed at 3 months, 2 at 4 months, and 2 at 5 months to obtain the standard pattern at these different ages. Of the animals in cast, 3 were rejected because of intercurrent complications.

2. Adults: 41 animals between 15 and 17 months old, weighing 161 between 760 and 950 grams. Of these 41 animals, 35 were put in casts (see Table II), all at 15 months. The other 6 animals were not put into cast, and were killed, 2 at 15 months, 2 at 16, and 2 at 17 months, to obtain standards for the different ages. Among the animals in cast, 4 were rejected because of intercurrent complications. For the final analysis we obtained the knee joints of 80 animals, 13 normal and 62 in plaster casts.

B. Method

1. Anesthesia: All the animals who were being put into casts were anesthetized with nembital, injected intraperitoneally.

2. Plaster cast. We tried to follow always the same technique:

one of the authors maintained the forced position of the coxo-femoral joints and extension of the knee-joints, while another author wrapped the plaster bandages, and did the molding with the device (Fig. 1). The feet and the ankles of the animals were protected with a fine layer of cotton.

3. Maintenance. After they were put into casts, the animals were kept in separate cages at room temperature.

4. Diet. The animals were fed with the standard ration of general supplies of the Ribeirao Preto Faculty of Medicine.

5. Sacrifice. The animals were killed with ether, by inhalation or intraperitoneal injection, 1, 2, 3, 4, 5, 6, 7, 8, 9 weeks after being put into casts (see Tables I and II).

6. Examination of the posterior limbs after removal of cast. Though we had restricted ourselves to the histological study of the knee-joint, we inspected and felt the musculature of the thigh and leg, and tested the mobility of the coxofemoral knee and tibio-tarsal joints.

7. Dissection. After removing the soft tissues, the posterior limbs were removed at the joints, while the capsule of the joint of both the knees in different regions and length. Next we proceeded to the macroscopic examination of a joint cavity (Figs. 4 and 5) with the naked eye and with the magnifying glass. In general, the entire ventral region of the joint capsule of the knee was opened; sometimes the ventro-medial or ventro-lateral aperture was extremely small, just sufficient for the penetration of the fixer; in this manner we attempted to prevent the rupture of possible adhesions (Fig. 5). Finally we broke with shears the lower third of the femur, and the top third of the tibia, separating thus the part we wanted.

8. Histological Technique: The joints were fixed in the Bouin agent for 48 hours and then in 70 percent ethanol, after total removal of the picric acid. Decalcification was achieved with trichloroacetic acid at 5% for 2 weeks (the acid solution was renewed every 24 hours).

The parts were washed again with 70% ethanol for 24 hours, and then, maintaining the knee slightly bent, they were cut with razor blades along a frontal plane, which, passing close to the

area of insertion of the crossed ligament of the knee, contains the following structures: in the proximal half, the medial femoral condyle, the crossed ligament and the lateral femoral condyle; in the distal half, the medial tibial tuberosity with the lateral meniscus. Thereafter the pieces were dehydrated and put in paraffin.

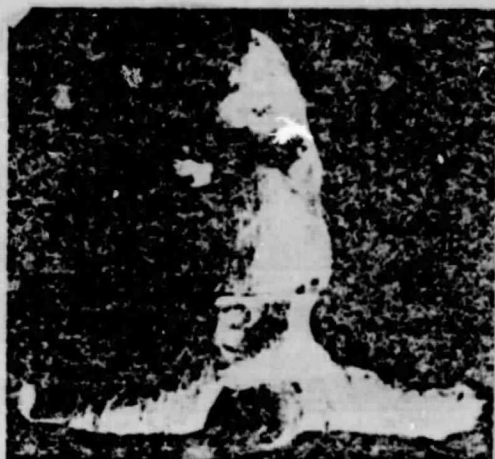

Fig. 1. Animal no. 30 (adult). Shown in forced position with abduction of the coxo-femoral joints and extension of the knees.

The cuts were made with microtome along the frontal plane; for each joint, we obtained 3 sections 6 μ thick, which were colored with 6% floxine and 0.5% alcian blue in 0.5% aqueous solution of acetic acid for 10 minutes, or with hematoxiline-eosine. Other sections were colored with 1% toluidine blue, in aqueous solution acidulated with N HCl, whose acidity was adjusted to pH 4 with phosphate buffer, Lison [2]. Of the 8 normal 3-month old animals, it was decided to obtain series of sections

/162

TABLE I
GROUP OF YOUNG ANIMALS
THREE-MONTH-OLD GUINEA PIGS IN PLASTER CAST

a identificação	b Tempo de imobilização em semanas
1 - 3 - 4	9
2 - 12	8
5 - 6 - 7 - 8	7
9 - 12 - 10 - 11	6
14 - 15 - 16 - 17 - 13	5
19 - 20 - 21 - 22	4
23 - 24 - 25 - 26	3
27 - 28 - 29 - 30	2
31 - 32 - 33 - 34	1

C Animais 10 - 11 - 12 foram desprezados

ORIGINAL PAGE IS
OF POOR QUALITY

Key: a. identification
b. immobilization period, in weeks

c. Animals no. 10, 11, and 13 were rejected

TABLE II
GROUP OF ADULT ANIMALS
GUINEA PIGS PUT IN PLASTER CAST AT 15 MONTHS

a Identificação	b Tempo de imobilização em semanas
1 - 4 - 5	6
9 - 10 - 11 - 25 - 24 - 26	8
6 - 7 - 8 - 12 - 13 - 14	7
16 - 19 - 22 - 28 - 27 - 29	6
21 - 22 - 23	5
1 - 2	4
15 - 16 - 17	3
36 - 31 - 32	2
23 - 34 - 35	1

C Animais 3 - 27 - 28 - 29 foram desprezados

Key: a. identification
b. immobilization period,
in weeks

c. Animals no. 5, 20, 24,
and 26 were rejected

from 4 of them, since it was necessary to obtain additional histological data on the components of the knee-joints of guinea pigs. In this case, the knees were prepared according to the technique already described, with excision of the joint capsule, which in this case was kept intact. We obtained sections of 6 μ along the frontal plane in the anterior-posterior direction, starting near the front face of the knee-cap. To avoid the accumulation of an excessive number of histological sections, we used one out of 10. We studied in some sections the microscopic anatomy with magnifying glass (enlargement 12 x).

9. Documentation. We photographed an animal in plaster cut (Fig. 1), several animals after removing the cast (Figs. 2 and 3) and some parts to show the adhesions. (Fig. 5). The most important parts of the microscopic anatomy were photographed with the Aristophot, Leitz.

Finally, photomicrography was carried out of the most interesting histological aspects with the Zeiss photomicroscope, using Isopan F (17-Din) and Panatomic X (17-Din) films.



Fig. 2. Animal no. 13 (adult), 12 days after removal from the cast. Observe the maximum degrees of abduction of the coxo-femoral joint E, and extension of the knee joint E. A, D, less intensely deformed.



Fig. 3. Animal no. 10 (adult), 10 days after removal from the cast. Observe the abduction postures of the coxo-femoral joints and the absence of bending of the knees.



Fig. 4. Animal no. 38 (adult), Normal. Anatomic preparation of the knee joint D with maximum bending to show the dissected menisci.



Fig. 5. Animal no. 25 (adult), intra-articular adhesion between meniscus and femoral condyle.

ORIGINAL PAGE IS
OF POOR QUALITY




Fig. 6. Panoramic photomicrography taken with Aristophot, Leitz. Animal no. 36, (adult). Normal. Observe the osseous trabeculae of the epiphyses, the thickness of the connecting cartilage and the layout of the menisci. Dye: floxine-alcian blue. Enlargement 12 x.



Fig. 7. Animal no. 10 (adult). Photomicrography with Aristophot. Intra-articular fibroses involving the meniscus and adhering to the joint cartilage of the tibia. Compare the osseous trabecula of the epiphyses and the thickness of the connecting cartilage with those of Fig. 6. Dye: floxine, alcian blue. Enlargement: 12 x.

Results

1. Young Guinea Pigs.

When the cast was removed, we found in all the animals muscular hypotrophy of thighs and legs, and stiffness of the immobilized joints, specifically: coxo-femoral, knee, and tibio-tarsal joints. The degrees of muscular hypotrophy and joint rigidity increased progressively in the animals immobilized over longer periods. When the cast was withdrawn, the animal maintained the coxo-femoral joints in abduction and the knees extended; the attempts at abduction of the coxo-femoral joint or bending of the knee-joint caused pain in the animals.

We observed fairly frequently in animals which had been put into casts for a few weeks, the presence of liquid or coagulated blood inside the joint cavity. Indeed we noted in some cases loss of luster of the cartilaginous joint surface after a week. In the animals remaining immobilized for longer periods, we found intra-joint adhesions, some very thin, rupturing very easily when the knee is bent, and others more resistant, which were less easily ruptured, and remained intact after careful bending. In some cases (animal no. 12), we found edema of the paw, which occasionally reached the level of the tibio-tarsal joint; in others, necrotic areas of the skin, on the leg (animal no. 28).

/164

/165

The microscopic study of the knee joints of animals placed in casts for progressively longer periods, showed the following:

A. The animals immobilized for one or two weeks suffered generally from discrete lesions. We observed in only one animal (Fig. 14), a fibrinoid exudate, indicating a slight adhesion to the surface of the joint cartilage of the tibia. This would be the initial type of lesion, with discrete fibrinoid exudate, which causes no lesions of the chondrocytes of the tangential layer.

B. The animals immobilized for 3 and 4 weeks show the most developed lesions, consisting in the disturbance in the layout of the superficial chondrocytes of the joint cartilage, obvious fibrous proliferation and reduced areas of erosion of the surface of the cartilage. In these erosion areas we observed residues of fibrin among the fine collagen fibers (animal no. 21).

/166

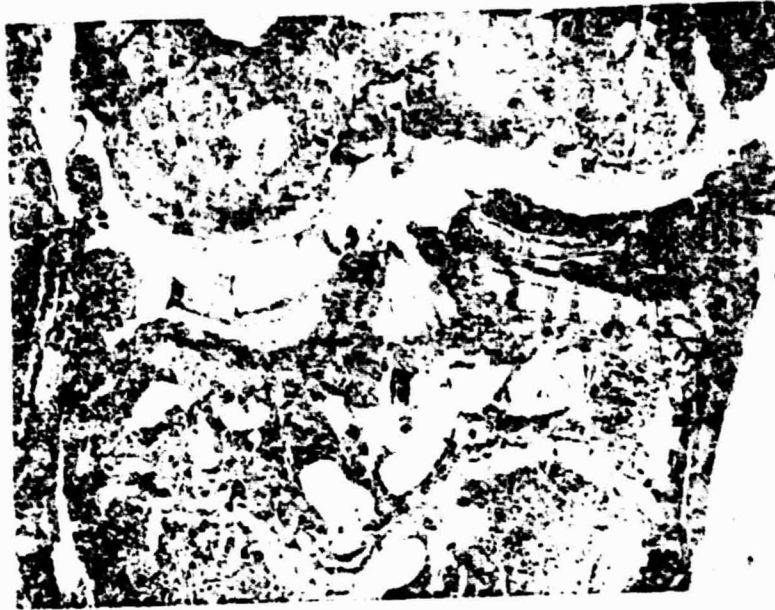

Fig. 8. Animal no. 12 (adult). Photomicrography with Aristophot. Intrajoint fibroses surrounding the meniscus on all sides and adhering to the joint surface of the tibia. On the other side, erosion of the joint surface of the tibia. Compare the osseous trabecula of the epiphyses and the thickness of the connecting cartilage with those of Fig. 6. Dye used: floxine-alcian blue. Enlargement 12 x.



Fig. 9. Animal no. 3 (adult). Photomicrography with Aristophot. Maximum degree of intrajoint fibroses. Compare the osseous epiphyses and the thickness of the connecting cartilages with those of Fig. 6. Dye: floxine-alcian blue. Enlargement 12 x.

ORIGINAL PAGE IS
OF POOR QUALITY



Fig. 10. Animal no. 31 (adult). "Kissing cartilage". Technical artefact. Dye: H. E. Enlargement 12 x.




Fig. 11. Detail of the previous figure, showing integrity of the tangential layer of the joint cartilages. Dye: H. E. Enlargement 12 x.

C. Starting from the fifth week, the degenerative changes in the joint cartilage became more pronounced. These modifications are characterized mainly by a large amount of fibrous tissue, which fills the joint cavity and forms adhesions between tibia and femur (animals nos. 14, 5, and 12). The areas of erosion of the joint surface in these cases were more apparent than in the animals of group B.

2. Adult Guinea Pigs.

We found in all animals, after removing the cast, muscular hypotrophy of thighs and legs and stiffness of the immobilized joints, specifically: the coxo-femoral, knee and tibia-tarsal joints. The degrees of muscular hypotrophy and stiffness were relatively more intense than those observed in the group of young animals (Figs. 2 and 3). The macroscopic examination of the knee-joint showed very often in the animals placed in casts up to 3 weeks, blood inside the joint cavity. Just as in the previous series, we found intra-joint adhesions. They were more frequent, resistant (Fig. 5) and numerous. In some cases we observed adhesions in the femur-knee-joint (animal no. 23).

/167



Fig. 12. Animal no 26 (adult). Normal. Insertion of the meniscus in the crossed ligament. Dye: H. E. Enlargement 30 x.

ORIGINAL PAGE IS
OF POOR QUALITY



Fig. 13. Animal no. 36 (adult). Normal. Other aspects of the meniscus; the section is located posteriorly to its insertion on the crossed ligament. Dye: H. E. Enlargement 30 x.




Fig. 14. Animal no. 28 (young). Fibrinoid exudate adhering to the joint surface of the tibia. Tangential area of the cartilage preserved. Dye: H. E. Enlargement 120 x.

/168



Fig. 15. Animal no. 2 (adult). Fibrous tissue involving the meniscus and adhering to the joint surface of the tibia. Dye: H. E. Enlargement 30 x.

In this group, the adhesions between the femur and the tibia became so pronounced that they caused a real fibrous ankylosis (Fig. 9). In one case, the attempts to mobilize these joints resulted in the fracture of the femoral condyle (animal no. 6). In this group, the loss of luster of the joint surface of the cartilage became more frequent (animals nos. 8 and 19); the areas of greater opacity were located near the margins of the intercondylic sulcus (animal no. 3). We found more frequently scabs on the soft parts of the knees, legs and feet. In some cases, examination with the magnifying glass showed small areas of erosion of the joint cartilage (Figs. 7, 8, 9).

We were also able to detect with the magnifying glass (enlargement 12 x) frequent osteoporosis of the distal epiphyses of the femur and proximal epiphyses of the tibia, also disorganization

and thinning of the proximal connecting cartilage of the tibia (Figs. 7. 8. 9).

The microscopic study of the joints of the animals in cast showed the following:

A. Even with 2 weeks of immobilization, intense fibrosis was observed in some cases in the joint cavity.

B. Starting from the third week, the intense fibrosis was really more frequently observed. At that time the intrajoint fibrous tissue formed adhesions between the meniscus and the tibia joint cartilage (Fig. 15) or between the tibia joint and femoral /169 joint cartilages.

C. In the animals immobilized for 6 weeks, we found the most intense cartilage lesions, characterized by deeper erosions. The intrajoint fibrous reaction was quantitatively greater than the one observed in animals immobilized for a shorter period (Figs. 16 and 17). We found all the variants of fibrous tissue, from flabby (Figs. 16 and 17) to dense (Figs. 19 and 20). This fibrous tissue adhesion on the joint surface implied disarrangement of the chondrocytes of the tangential layer (Figs. 17 and 21). We also found degenerative lesions of the meniscus, which almost disappears at times inside the fibrous mass which occupied the entire joint cavity.



Fig. 16. Animal no.19 (adult). Joint fissure filled with fibrous tissue adhering to the joint surface of the tibia and with limp connective tissue adhering to the anterior surface of the femur. Dye: H. E.; enlargement 30 x.

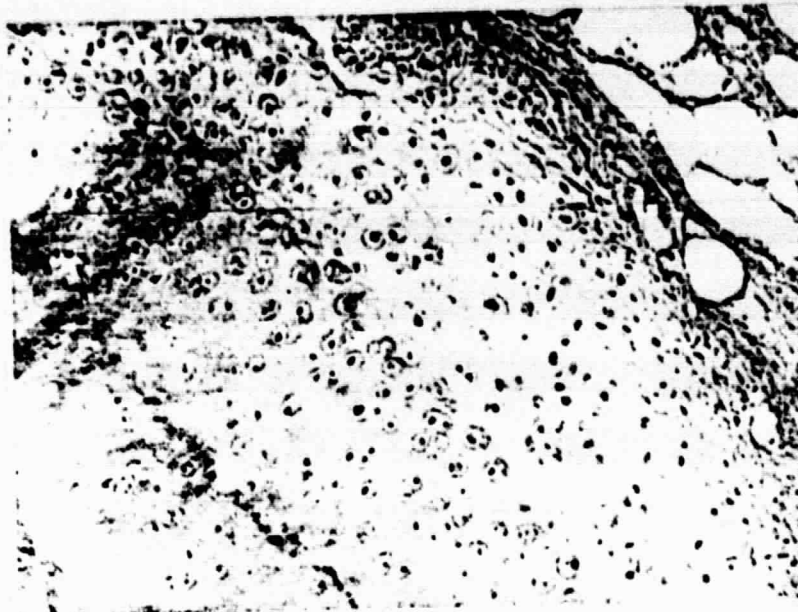


Fig. 17. Animal no. 13 (adult): Adhesion of limp connective tissue to the joint surface of the tibia which underwent disorganization of its tangential layer. Note the differences in coloring capacity in the thickness of the joint cartilage of the tibia. Dye: H.E. Enlargement: 120 x.



Fig. 18. Animal no. 1 (adult): Joint fissure completely filled with fibrous tissue adhering to the joint surfaces of the femur and tibia. Dye: H.E.; enlargement 30 x.

ORIGINAL PAGE IS
OF POOR QUALITY



Fig. 19. Detail of the previous figure. Note the disorganization of the tangential layer of the joint cartilages of the femur and the tibia and the arrangement of the fibrocytes parallel to the joint surfaces. The less intensely colored central portion consists in a less cellular tissue and thicker collagen fibers. Dye: H.E.; Enlargement: 120 x.

D. In all animals immobilized for 7, 8, and 9 weeks, we found the highest degree of intrajoint fibrosis, which formed intimate connections between the joint surfaces of femur and tibia (Figs. 18, 19, 20, and 21). Advanced degrees of destruction of the meniscus were seen, caused by fibrous proliferation, also its intense ossification (Fig. 22). In the sections colored with toluidine blue, we were able to observe decrease to the extent of disappearance of metachromasia of the cells of the superficial layers of joint cartilage (Figs. 24, 25, 26, and 27). The erosions of the joint surfaces occurred less often.

/170

/171

Discussion

Normal Animals

The 18 normal animals permitted the anatomic study of the guinea pig knee. The 4 animals in which series of sections were carried out allowed us to study topographically and understand the different components of the meniscus, which is osteocartilaginous in the

anterior third and fibrous in the remaining two-thirds. The lateral meniscus is C-shaped, with a central fissure adapting /172 itself exactly to the central most convex portion of the lateral tibial tuberosity, which presents in its turn two concave regions, one anterior, the other posterior, which are filled, respectively, with the two horns of the meniscus. The medial meniscus is O-shaped, and fills the entire medial tibial tuberosity, which is slightly convex.



Fig. 20. Animal no. 3 (adult). Another aspect of the joint fissure filled with fibrous tissue, adhering to the joint surfaces of the femur and the tibia. In the central area, residues of the cartilaginous part of the meniscus. Dye: H.E. Enlargement: 120 x.



Fig. 21. Detail of the previous figure, showing intimate adhesion of the fibrous tissue to the joint surface of the tibia, where we find disorganization of the tangential layer. Dye: H.E. Enlargement: 150 x.



Fig. 22. Animal no. 14 (adult). Meniscus with abundant ossification in the central part. Limp connective tissue adhering to the joint surface of the tibia and to the meniscus. Note in the upper part of the figure, the small areas of erosion of the joint surface of the femur. Dye: toluidine blue. Enlargement: 30 x.



Fig. 23. Animal no. 40 (young). Normal strong metachromasia of the joint cartilages of femur and tibia. Dye: toluidine blue. Enlargement: 30 x.



Fig. 24. Animal no. 13 (adult). Joint cartilage of the tibia showing the decrease in metachromasia of the cells of the most superficial layers of the joint cartilages of femur and tibia. Note disorganization of the tangential layer. Dye: toluidine blue. Enlargement: 120 x.





Fig. 25. Animal no. 10 (adult). Fibrous tissue filling joint fissure. Note decrease in metachromasia of the cells of the most superficial layers of the joint cartilages of the femur and tibia. The dislocation of part of the joint cartilage is an artifact. Dye: toluidine blue. Enlargement: 30 x.



173

Fig. 26. Detail of the previous figure. Note the decrease of metachromasia of the cells of the superficial layers of the articular cartilage of the tibia and the intimate adhesion of fibrous tissue to the tangential layer which is disorganized. Dye: toluidine blue. Enlargement: 120 x.



Fig. 27. Animal no. 9 (adult). Erosion of the joint surface of the tibia. Compare with Fig. 23. Dye: toluidine blue. Enlargement: 30 x.

The anterior horns of the menisci are joined with a transversal ligament. The menisci are inserted laterally on the capsule. The lateral meniscus is inserted medially on the femur.

When the two menisci are removed, it is found that there is no perfect congruence between the tibial tuberosities and the femoral condyles. This makes us assume that the menisci are indispensable for perfect functioning of the knee-joint of the guinea pig.

Animals in Plaster Cast

We will now discuss the pathogenesis of the lesions found in the 62 animals in plaster cast.

Immobilization, which impedes muscle and joint function, would result in the production of less synovial fluid. With a reduced supply of synovial fluid, the transport of nutrient substances would be affected. Reduction in the cellular metabolism of the hyaline cartilage would result in its cellular lesion.

In this sense, the decrease in intensity of metachromasia in the most superficial layers of the joint cartilage may be considered as an indication of the decrease or disappearance of the chondroitin sulfate, which would destroy the chondrocytes in the erosive lesions of the joint cartilage.

The fact that we immobilized the joints of the guinea pigs in a forced position should cause additional damage of extension of the capsule-ligament structures (animal no. 25 had its joint capsule thickened to a considerable extent in the macroscopic examination).

/174

The occurrence of hemorrhage in this capsule-ligament joint, only in the animals immobilized for up to 3 weeks, indicates that the cause of this hemorrhage is the exaggerated stretching of these structures, induced by the forced position in a plaster cast.

The association of osteoporosis of the distal femoral and proximal tibial epiphyses, also the joint rigidity would explain the possibility of occurrence of fractures, as was found in one case.

Salter and Field believe it is possible that immobilization in forced position places in contact two opposite areas of the cartilaginous joint surfaces. The region of hyaline cartilage which would be in permanent contact would find its nutrition impaired because of the lack of access to it of the synovial fluid. We think that this hypothesis would be correct only if the authors used a Charnley type of constrictive device. In our two groups, and also in the third series of experiments of Salter and Field, we must admit that there was posterior adaptation to the position in which the animals were immobilized, surely favored by the muscular hypotrophy which we detected in all cases.

Our hypothesis is supported by the findings of Burke Evans et al., who found constriction areas only during the first days, no

longer observing them after 30 days, probably because of adaptation or relaxation of the initial constriction forces.

We believe that in our experiment, two factors were responsible for the development of the lesions (intra-joint fibroses and erosion): the reduction of the production of synovial fluid and the stretching of the joint capsule.

It is accepted by all the authors that the synovial fluid is very important for the nutrition of the joint cartilage, and its decrease, associated with other factors, may be considered as a primary cause of the development of the lesions which we found.

We are compelled to express certain limitations with regard to the absolute importance of the synovial fluid for the nutrition of the joint cartilage, as Salter and Field indicate, because the medical literature does not report joint cartilage lesions after synevectomy in man. Other mechanisms of hyaline cartilage nutrition must certainly be activated under special conditions.

Our data certainly conveyed the impression of most intense lesions in the group of adult animals. This would be consistent with our knowledge of greater vitality, resistance, and regenerative capacity in the structures of young animals.

By extrapolation, if our findings were valid for man, and in this area, Salter and Field documented several examples, joint immobilization in forced position in a plaster cast would not be advisable over long periods.

Conclusions

Studying the knee joints in 80 animals, we were able to draw the following conclusions:

1. The immobilization of the joints in a forced position caused muscular hypotrophy of the thigh and the leg in all cases. Muscular hypotrophy was directly proportional to the period of immobilization,

both in young and adult animals.

2. The immobilization of the joints in a forced position caused joint stiffness not only of the knee, but also the coxo-femoral and tibia-tarsal joints in all the cases. The joint stiffness was directly proportional to the time of immobilization, both in young animals and in adults.

3. The immobilization of the joints in a forced position caused hemoarthrosis, most often during the first weeks in both the young and adult animals.

4. The longer the period of immobilization, the greater the intensity and frequency of the intra-joint fibrous reaction, which occasionally reached a degree of real ankylosis. On the other hand, this reaction was more frequently observed in the group of 15-month old animals than in the 3-month age group.

5. The immobilization of the joints in a forced position caused lesions of the erosive type on the hyaline joint cartilage. In the group of young animals, the erosion was superficial, fairly rare, occurring only in animals immobilized for 7, 8, and 9 weeks. In the group of adult animals, the erosion was deep, rather frequent, and appeared starting from the fifth week of immobilization.

6. The immobilization of the joints in a forced position caused less histological alterations of the meniscus in the group of young animals. As for the adult group, the histological alterations of the meniscus were severe, with many cases of almost total destruction.

Acknowledgement

We thank Professor L. Lison for making available to us the facilities of the Laboratory of the Department of Human Functional and Applied Morphology.

1. Bennett, G. A., Bauer, W., "Further Studies Concerning the Repair of Articular Cartilage in Dog Joints", J. Bone and Joint Surg. 17, 141 (1936).
2. Brower, T. D., Akahoshi, Y., Orlic, P., "The Diffusion of Dyes Through Articular Cartilage in vivo", J. Bone and Joint Surg. 44-A, 456 (1962).
3. Burke Evans, E., Eggers, G. W. N., Butler, J. K., Blumel, J., "Experimental Immobilization and Remobilization of Rat Knee Joints", J. Bone and Joint Surg. 42-A, 737, (1960).
4. Calandruccio, R. A., Gilmer, W. S., "Proliferation, Regeneration, and Repair of Articular Cartilage of Immature Animals", J. Bone and Joint Surg. 44-A, 431 (1962).
5. Cloquet, Cited by Menzel.
6. Di Molfetta, N., "On the Mode of Behavior of Joints in Immobilized Limbs", Arch. Italiano di Chir. 55, 14 (1936).
7. Farris, E. J., The Care and Breeding of Laboratory Animals, New York, John Wiley and Sons, Inc., 1950.
8. Hall, M. C., "Cartilage Changes After Experimental Immobilization of the Knee Joint of the Young Rat", J. Bone and Joint Surg. 45,
9. Lison, L., Animal Histochemistry and Cytochemistry, Third Edition, Paris, Gauthier-Villars, 1960.
10. Menzel, A., "On the Disease of Joints in Cases of Their Long Immobilization", Arch. fur Klinisches Chirurgie 12, 990 (1871).
11. Salter, R. B., Field, P., "The Effects of Continuous Compression on Living Articular Cartilage", J. Bone and Joint Surg. 42-A, 31 (1960).
12. Sokoloff, L., "Natural History of Degenerative Joint in Small Laboratory Animals", A. M. A. Arch. of Pathology 62, 118 (1956).
13. Suhba Rao, K. V., "An Experimental Study of Regeneration in Cartilage", J. Path. Bact. 67, 455 (1954).
14. Trias, A., "Effect of Persistent Pressure on the Articular Cartilage. An Experimental Study", J. Bone and Joint Surg. 43-B, 376 (1961).
15. Trueta, J., "Osteoarthritis; An Approach to Surgical Treatment", Lancet 1, 585 (1956).
16. Trueta, J., "Considerations of the Pathology of Osteoarthritis of the Hip. Soc. Int. Chir. Orth. et de Traum.", Septime Congres

International de Chirurgie Orthopedique, Barcelone 16,
1957.