

# **THE EFFECTS OF CRUDE AQUEOUS AND ALCOHOL EXTRACTS OF *ALOE VERA* ON THE GASTROINTESTINAL TRACT AND ACCESSORY ORGANS OF SUCKLING RATS**

**Ben Beya wa Beya**

A dissertation submitted to the Faculty of Health Sciences, University of the Witwatersrand, School of Physiology in fulfilment of the requirements for the degree of Master in Medicine.

Johannesburg, South Africa.

2010

The copy right of the above mentioned described thesis rests with the author or the university to which it was submitted. No portion of the text derived from it may be published without the prior written consent of the author or University (as may be appropriate). Short quotations may be included in the text of thesis or dissertation for purposes of illustration, comment or criticism, provided full acknowledgement is made of the source, author and University.

## DECLARATION

I declare that this dissertation is my own work, except where others have helped as indicated in the acknowledgements and the reference list. This dissertation is being submitted for the degree of Master in Medicine in the Faculty of Health Sciences at the University of the Witwatersrand, Johannesburg, South Africa. It has not been submitted before for any degree or examination in this or any other University.

.....

Ben Beya wa Beya

..... day of .....2010

Furthermore, I certify that the procedures used in this dissertation were approved by the Animal's Ethics Screening Committee of the University of the Witwatersrand (AESC number 2008/37/03).

## **DEDICATION**

*This research is dedicated to my major supervisor Associate Professor Kennedy Erlwanger and the Head of School of Physiology Professor David Gray for their unlimited guidance, support and motivation without which none of this would have been possible. In everybody's life there comes a time when someone influences the path of one's life.*

*To my parents, Beya Mwepu Shambuyi and Buambavi wa Ngindu for lovingly and patiently giving me direction in my life, I would not have come this far if it weren't for you, thank you for your unconditional love and steadfast support in all of my endeavours.*

## **ACKNOWLEDGMENTS**

I would like to express my sincere gratitude to my co-supervisor Prof. Bruce Davidson for his valuable assistance and guidance in both the execution and preparation of the laboratory work.

Many thanks to Eliton Chivandi, I am indebted to you for your invaluable help and guidance in the preparation of this manuscript, acknowledged authority in this field of biochemistry and nutrition by giving me an intrinsic understanding of the subject.

I would like to extend my sincere and heartfelt thanks to Phiko Mgandela for his encouragement and patience in the face of impetuosity and for his invaluable advice so freely given.

Thanks to Margaret Badenhorst for her technical assistance with the processing of tissues for histology, and for running the ELISAs for IGF-1 hormonal assays as well as for technical assistance with the preparation of some of the reagents I used in the study.

I would like to express my gratitude to Dr. Oluwafolajini and Trevor Nyakudya for their assistance with the Statistics done during this research.

I would like to express my heartfelt gratitude to Thapelo Rammabi for her constant encouragement and support.

I would like to take this opportunity to express my gratitude to Dr. Mulunda Mwanza for the orientation and support throughout the preparation of this dissertation.

This material is based upon work supported financially by the National Research Foundation and the University of the Witwatersrand, Faculty of Health Sciences Research Committee grants and the School of Physiology, South Africa.

Last but not least, to my friends and colleagues in the School of Physiology who aided this study in many ways by providing both stimulating discussion and advice.

## ABSTRACT

For centuries *Aloe vera* has been exploited for several verified and unverified medicinal uses such as wound healing, treatment of gastrointestinal ulcers and for its many biological effects including anti-microbial, laxative, anti-inflammatory and immunostimulatory activities. Studies have generally focused on its effects *in vitro* and in adults. When nursing mothers use *Aloe vera* extracts, their suckling infants are at risk of indirect exposure to *Aloe vera* *via* breast feeding or directly as dietary/health supplements. The gastrointestinal tract (GIT) of the neonate is sensitive to dietary manipulations during the suckling period with long lasting effects that can be irreversible. Thus babies may be at risk if administered *Aloe vera* extracts directly as dietary supplements or indirectly *via* breast milk.

The main objectives of this study were to evaluate the effects of orally administered aqueous and alcohol extracts of *Aloe vera* on growth performance, the morphometry and morphology of the gastrointestinal tract and accessory organs, and liver function of suckling rats. Suckling Sprague-Dawley rats (77), males (n=38) and females (n=39) of 6 days old were randomly assigned to one of five treatment groups and given once daily by oral gavage a suspension of lyophilized crude alcohol or aqueous extracts of *Aloe vera* suspended in distilled water. Group I (control) was gavaged with distilled water (vehicle). Group II received a low dose of the aqueous extract (AqL) at 50mg. kg<sup>-1</sup>; Group III received a high dose of the aqueous extract (AqH) at 500mg. kg<sup>-1</sup>; Group IV received a low dose of the alcohol extract (AlcL) at 50mg. kg<sup>-1</sup> whilst Group V received a high dose of the alcohol extract (AlcH) at 500mg. kg<sup>-1</sup>. The extracts and distilled water were administered at a volume of 10ml.kg<sup>-1</sup>. The pups remained with their dams for the

duration of the study and after 8 days on the treatments, the pups were humanely killed to harvest their tissues for measurements and physiological analysis. All data were expressed as mean  $\pm$  SD and analyzed by one way ANOVA, the values were considered statistically significant when  $p < 0.05$  and then a Bonferroni *Post hoc* test was applied.

The suckling rats fed respectively with high doses of AlcH and AqH had a significantly higher body mass gain than the other groups ( $p < 0.05$ , one way ANOVA). Linear growth as measured by tibial length was significantly increased in the AqH group compared to the other groups. There was no significant difference in the mass and relative density of the tibia bones of the rats from the different treatment groups. The differences in growth could not be attributed to circulating concentrations of the somatotrophic hormone, Insulin-like growth factor-1 (IGF-1) which was not significantly different between the groups.

The treatments did not result in any significant differences in lengths, and mass of the small and large intestine, however the caecum was significantly enlarged (hypertrophy of muscularis, submucosa and mucosa) in the rats that received the *Aloe vera* extracts.

Although, there was no significant difference in the mass of the rats' livers, the lipid and glycogen content were significantly higher ( $p < 0.001$ ) for the AqH group compared to the other groups. Histologically, the hepatocytes showed enlarged nuclei, granular cytoplasm and dilated sinusoids for AqH and AlcH as compared to the control group. An indirect assessment of liver function by measurement of blood concentrations of alkaline phosphatase (ALP) and alanine amino transaminase (ALT) did not reveal a significant



difference between the groups. The non fasting concentration of metabolic substrates (glucose and triglycerides) was also not significantly different between the groups.

The pups given high doses of the extracts had a significantly greater ( $p < 0.05$ ) thymus mass (hyperplastic) than the other groups.

The short term administration of *Aloe vera* extracts has shown a growth promoting effect, enhanced hepatic storage of metabolic substrates and hypertrophy of the caecum and thymus of neonatal rats. These effects need to be explored further to enhance animal production and health.

<b>TABLE OF CONTENTS</b>	<b>Page</b>
DECLARATION.....	i
DEDICATION.....	ii
ACKNOWLEDGEMENTS.....	iii
ABSTRACT .....	v
TABLE OF CONTENT .....	viii
LIST OF FIGURES .....	xi
LIST OF TABLES .....	xii
LIST OF ABBREVIATIONS .....	xiii
Chapter 1- Introduction .....	1
1.1 Introduction .....	2
1.1.1 <i>Aloe vera</i> .....	2
1.1.2 Biochemistry .....	3
a) Vitamins .....	3
b) Enzymes .....	4
c) Minerals .....	4
d) Sugars .....	4
e) Anthraquinones .....	5
1.1.3 Pharmacology and Therapeutic effects of <i>Aloe vera</i> .....	6
a) Skin and wound healing .....	6
b) Diabetes mellitus and metabolism .....	7

c) Anticancer .....	7
d) Cardiovascular system .....	7
e) Gastrointestinal system.....	9
f) Musculoskeletal System .....	10
g) Immune system .....	10
1.1.4 The gastrointestinal tract .....	11
1.1.5 Growth and nutrition in neonates .....	15
1.1.6 Justification of study.....	17
1.1.7 Aims and objectives .....	18
a) The morphometry and morphology of the GIT and accessory organs of suckling rats.....	18
b) Growth performance .....	19
c) Liver function (enzymes and storage of glycogen and lipids).....	19
d) Metabolic substrates (blood glucose and triglyceride concentrations).....	20
Chapter 2 – Materials and methods .....	21
2.1 Study setting .....	22
2.1.1 Study design .....	22
2.2 Materials.....	23
2.2.1 Plant collection .....	23
2.3 Methods .....	23
2.3.1 Preparation of <i>Aloe vera</i> extracts .....	23

2.3.2 Dry matter determination .....	24
2.3.3 Housing of animals .....	24
2.3.4 Experimental animals .....	24
2.3.5 Blood sampling and plasma processing .....	25
2.3.6 Blood measurement for glucose and triglyceride concentration .....	26
2.3.7 Determination of liver enzymes (total ALT and ALP).....	26
2.3.8 Measurements of insulin-like Growth Factor (IGF-1).....	27
2.3.9 Morphometry and morphology of abdominal viscera .....	28
2.3.10 Determination of liver lipid content.....	29
2.3.11 Determination of liver glycogen storage .....	29
2.3.12 Femur, tibia lengths and mass .....	30
2.3.13 Statistical analysis .....	30
Chapter 3 – Results .....	31
3.1 Mortality and morbidity of the animals.....	32
3.2 The effects of <i>Aloe vera</i> extracts on the body mass .....	31
3.3 Visceral of organ mass and histology.....	31
3.4 The effects of <i>Aloe vera</i> extracts on the tibia and femur length and mass.....	33
3.5 The effects of <i>Aloe vera</i> extracts on liver lipid content and glycogen.....	33
Chapter 4 – Discussion .....	48
Chapter 5 – Conclusion and recommendations .....	56
Chapter 6 – References .....	59

## LIST OF FIGURES

Figure 1: Effect of <i>Aloe vera</i> extracts on the body mass gain (%) of suckling rats after 8 days of treatment.....	34
Figure 2: Effect of <i>Aloe vera</i> extracts on the relative mass of the thymus (% body mass) after 8 days of treatment.....	36
Figure 3: Liver lipid yield (%)......	38
Figure 4: Effect of 8 days of feeding suckling rats with <i>Aloe vera</i> extracts on the liver glycogen storage expressed as glucose equivalents of liver homogenate.....	39
Figure 5a: Digital photograph showing the histology of the caecum 40X .....	43
Figure 5b: Digital photograph showing the histology of the caecum 400X .....	44
Figure 6a: Digital photograph showing the histology of the thymus 40 X.....	44
Figure 6b: Digital photograph showing the histology of the thymus 400X .....	45
Figure 7: Digital photograph showing the histology of the liver 400 X .....	42

## LIST OF TABLES

Table 1: Effect of <i>Aloe vera</i> extracts on the body mass, absolute (g) and relative mass (%) and lengths (cm) of viscera of suckling rats.....	35
Table 2: Effect of <i>Aloe vera</i> on the absolute and relative length and mass of tibia and femurs of rats.....	37
Table 3: Effect of <i>Aloe vera</i> extracts on non fasting blood concentrations of glucose, Triglycerides ALT, ALP and IGF-1.....	40
Table 4: Effect of 2 different doses of Aqueous and Alcohol extracts of <i>Aloe vera</i> on the microscopic measurements of intestines of suckling rats.....	41
Table 5: Effect of <i>Aloe vera</i> extracts on the morphometry of the ceacum of suckling rats.....	42

## LIST OF ABBREVIATIONS

Alanine-amino Transferase	ALT
Alcohol high dose	AlcH
Alcohol low dose	AlcL
Alkaline Phosphatase	ALP
Aqueous high dose	AqH
Aqueous low dose	AqL
Body mass	BM
Enzyme-Linked Immunosorbent assay	ELISA
Gastrointestinal tract	GIT
Insulin-like growth hormone	IGF-1
Tumour Necrosis Factor alpha	TNF- $\alpha$

# **Chapter 1 – Introduction**



## **1.1 Introduction**

For centuries, numerous plants have been used for medicinal properties and as key ingredients for dietary supplements (Massimo, 2003). Although many have been superseded by conventional pharmaceutical approaches, there is currently a resurgence in interest in the use of natural products by the general public world-wide. As a result of scientific efforts aimed at improving the understanding of their effect on human physiology, some plants have been thoroughly characterized and their mechanism of action is now well understood. A myriad of plants although used as pharmacological agents, are yet to be characterised and undergo scientific testing on their proposed efficacy against disease. *Aloe vera* is a plant with many reputed health benefits and has many references in many cultures: Ancient Egyptians, Greeks, Romans, Indians and Chinese (Cheney, 1970).

### **1.1.1 *Aloe vera***

The plant *Aloe vera* with origins in the eastern and southern regions of Africa is also known as *Aloe barbadensis* and *Aloe vera ferox* (Cheney, 1970). It was originally classified in the family Liliaceae, but according to Reynolds, it has now been designated its own family, known as Aloaceae (Wallander *et al.*, 2000). It is well adapted to growth in arid and semi arid regions (Paeza *et al.*, 2009). *Aloe vera* can reach heights of 10 to 20 meters with stems ranging up to 3 meters in circumference. The flowers appear annually, are bright red-orange and, are arranged in an erect position with terminal spikes in candle-shaped clusters, whilst the capsules contain numerous angular seeds.

When grown in pots, *Aloe vera* does not like crowded roots and the use of standard potting soil mixed with sharp sand will help the plant growth (Johnson, 1999; Leffers *et al.*, 2003). When grown under low light intensity, the leaves lose their grayish cast and become just plain green. *Aloe vera* is tolerant of dry air and prefers temperatures of 21degrees Celsius in the day time and night ( Paeza *et al.*, 2009).

### **1.1.2 Biochemistry**

Most of the biologically active constituents of *Aloe vera* are found in the leaves which are composed of the rind, juice and a gel like substance (Ramachandra and Srinivasa, 2008). The plant *Aloe vera*, being a cactus contains up to 80 per cent water with an average pH of 4.5 (Bryant,1970).

It has been shown that some constituents of *Aloe vera* have similar biological activities to amino acids, vitamin C, polysaccharides, anthraquinones, barbaloins (glucosides) and growth factors (Davis *et al.*, 1994). *Aloe vera* also contains several potentially bioactive compounds such as salicylates, magnesium lactate, acemannan, lupeol, campesterol,  $\beta$ -sitosterol,  $\gamma$ -linolenic acid, aloctin A, anthraquinones, *Aloe*-emodin, resins, and chromone derivatives (Wichtl and Bisset, 1994; Bruneton, 1995; Esua and Rauwald, 2006).

The remaining solid material contains over 75 different ingredients which include:

#### **a) Vitamins**

*Aloe vera* contains most vitamins including Vitamin D, A (the antioxidant beta-carotene), C, E, B<sub>1</sub>, B<sub>2</sub>, B<sub>6</sub> and even traces of B<sub>12</sub> and is one of the very few plant sources of this

vitamin (Yaron, 1991). It also has beta carotene, niacinimide, folic acid and choline (Matsuda *et al.*, 2008).

***b) Enzymes***

*Aloe vera* contains lipases and proteases which aid in digestion (Fermentia *et al.*, 1999). It also contains bradykinase which is thought to help reduce excessive inflammation and pain when applied to the skin and also stimulate the immune system (Reuter *et al.*, 2008).

***c) Minerals***

*Aloe vera* contains several minerals including calcium, sodium, potassium, manganese, magnesium, copper, zinc, chromium and the anti-oxidant selenium (Zang, 2006). Nutritionally, these minerals are trace elements and only needed in very small quantities in the diet. They are essential for the proper functioning of various enzyme systems in different metabolic pathways.

***d) Sugars***

These are derived from the mucilage layer of the plant which surrounds the inner gel. The sugars are mainly mucopolysaccharides. *Aloe vera* contains both mono and polysaccharides including the long chain sugars involving glucose and mannose, the gluco-mannans (Hart *et al.*, 2009). Some of these sugars can be absorbed whole from the gastrointestinal tract and appear in the bloodstream in exactly the same form as when ingested (Lairon *et al.*, 2007). Once in the blood stream they are able to exert their biological effects such as immunoregulation. These polysaccharides can also adhere to epithelial cells in the gut and form a barrier preventing absorption of unwanted material

(Huggins *et al.*, 2003). In topical preparations the sugars are thought to be the main moisturisers (Chandan *et al.*, 2007).

*e) Anthraquinones*

These are phenolic compounds that are found exclusively in the plant sap. In small quantities, when they do not exert their purgative effect, they aid in absorptive processes in the GIT and have anti-microbial and analgesic effects (Panda, 2000). Aloin and emodin found in *Aloe vera* can act as analgesics and have been shown to have antimicrobial effects (Chung *et al.*, 1997).

The rich chemical composition of *Aloe vera* has resulted in it being exploited as a medicinal plant with a wide range of uses in the different body systems.

### **1.1.3 Pharmacology and therapeutic effects of *Aloe vera***

Many therapeutic properties of *Aloe vera* have been described (Grindlay *et al.*, 1986):

#### ***a) Skin and wound healing***

*Aloe vera* has been shown to aid in the healing of various kinds of skin wounds and burns including the speeding of incision wound repair after surgery (Yates *et al.*, 1992, Heggers *et al.*, 1996). It is also used for the treatment of blisters, insect bites, rashes and sores (Dold and Cocks 2000). *Aloe vera* usage helps to protect the outer layers of the skin following cuts by reorganizing the skin cells (Crouch and Symmonds 2006). Studies have also shown improved wound healing in diabetic individuals (Robert *et al.*, 1979). Several *in vitro* studies have shown that *Aloe vera* extracts can stimulate fibroblast and epithelial cell growth and induce lectin-like responses in immune cells involved in skin wound repair processes (healing and sealing) of the cells (Arnold *et al.*, 2002). *Aloe vera* also stimulates collagen synthesis and fibroblast activity *in vitro* and *in vivo*, as part of its wound healing properties and it also has anti-inflammatory properties (Robert *et al.*, 1979, Heggers *et al.*, 1996, Moon *et al.*, 1999). The large polysaccharides, unique to fresh raw *Aloe vera*, have been found to stimulate the release of Tumor Necrosis Factor alpha (TNF- $\alpha$ ) by the immune cells, which stimulates the production of new tissue.

In the cosmetic and toiletry industry, *Aloe vera* is used as part of the base material for the production of creams, lotions, soaps, shampoos and cleansers (Stepanova *et al.*, 2007). Pharmaceutically, it has been used for the manufacturing of topical products such as ointments and gels.

### ***b) Diabetes mellitus and metabolism***

Studies have suggested that extracts of *Aloe vera* have a significant anti-hyperglycaemic effect and may be useful in treating diabetes mellitus by reducing the levels of fasting blood sugar and glycated hemoglobin (Boudreau, 2006; Panda, 2000; Tanaka *et al.*, 2006). In streptozotocin-induced type –I diabetic rats, the oral administration of *Aloe vera* significantly reduced the fasting blood glucose, hepatic transminases, plasma and tissue cholesterol, triglycerides, free fatty acids and phospholids and in addition, it also significantly increased plasma insulin levels (Ghannam *et al.*, 1986). Similar positive effects have been noted in type-II diabetic models (Can *et al.*, 2004). The antidiabetic effect of *Aloe vera* is thought to be mediated in part by compounds such as mannans and anthraquinones (Reynolds and Dweck, 1999; Can *et al.*, 2004).

### ***c) Anti Cancer***

The chemicals contained in *Aloe vera* extracts such as lectins, arginine, germanium and beta carotene are powerful anti-tumor agents and immune modulators. They were shown to retard the growth of tumor cells and increase the number of T-4 and T-8 lymphocytes which destroy microbes and cancer cells (particularly leukaemia) (Amusan *et al.*, 2002). Aloe-emodin has shown anti-neoplastic activity against some human cancer cell lines (Yu *et al.*, 2006). *Aloe vera* is also rich in antioxidants which remove free radicals thus preventing damage to the cells in body (Steenkamp and Stewart 2007).

However, recent studies have demonstrated the ability of *Aloe vera* products to cause a proliferative effect on some cells, and thus could be associated with a greater risk for carcinogenicity (Susana, 2010).

#### ***d) Cardiovascular system***

The cardiovascular system transports food, hormones, metabolic wastes and gases to and from cells. Oral administration of *Aloe vera* extracts improves cardiovascular system functioning.

*Aloe vera* has been shown to have angiogenic activity which is mediated *via* beta-sitosterol (Choi *et al.*, 2002). Beta-sitosterol derived from *Aloe vera* also enhanced the expression of proteins related to angiogenesis eg vascular endothelial growth factor (VEGF) and blood vessel matrix laminin (Choi *et al.*, 2002). *Aloe vera* (gel applied topically) dilates capillaries, increasing blood circulation to the skin and alleviates frostbite (Ajabnoor, 1990).

Aloe-emodin, aloin A, elgonica dimer A and bisbenzopyran derived from *Aloe vera* have been shown to have hypotensive effects in rats (Saleem *et al.*, 2001). Of the four chemical constituents of *Aloe vera* tested, aloemodin was found to be the most potent hypotensive (Saleem *et al.*, 2001).

It has also been demonstrated that *Aloe vera* extracts extended the survival time of rats subjected to lethal haemorrhage (Sakai *et al.*, 2006).

***e) Gastrointestinal system***

*Aloe vera* extracts have been documented by Leffers *et al.*, 2003 for the treatment of ailments of the digestive system. In rat experimental models, *Aloe vera* has been shown to decrease gastric acid secretion and confer gastro-protection from mucosal injury due to hydrochloric acid (Yusuf *et al.*, 2004). *Aloe vera* has also been shown to protect against and/or cure gastric ulcers in humans (Kandil and Gobran, 1982) and rats (Mahattanadul, 1996 and Suvitayavat *et al.*, 2004) *via* mechanisms which may include antioxidant and immunosuppressive effects. The glycoprotein, Aloctin A is thought to be one of the constituents of Aloes which inhibit the formation of indomethacin-induced gastric ulcers when administered to rats (Saito *et al.*, 1989). *Aloe vera* may also have a therapeutic effect on inflammatory bowel disease (Langmead *et al.*, 2004). The extracts from *Aloe vera* reportedly have laxative and purgative properties when used for medicinal purposes and relieve digestive disorders in animals (Hutchings *et al.*, 1996). *Aloe vera* is hydrolyzed in the gut to form *Aloe*-emodin anthrone which auto-oxidizes to a quinone, *Aloe*-emodin. The anthraquinones which are poorly absorbed from GIT are cleared by gut bacteria to produce *Aloe* emodin, which is more readily absorbed and responsible for the purgative properties of *Aloe vera* preparations (Blumenthal *et al.*, 1998). *Aloe vera* also contains 1,8-dihydroxyanthracene derivatives which have a laxative effect.

Studies on rats have shown that *Aloe vera* can significantly extend the life span of rats (Davis, 1993). Rats fed with *Aloe vera* extracts as a dietary supplement showed lesser damage of the vital organs at an older age than control rats (Kallaya *et al.*, 2006).



### ***f) Musculoskeletal System***

The use of *Aloe* has been recorded for the therapeutic management of depressed fontanel in infants and for arthritis in the elderly (Gelfand *et al.*, 1985). Literature also reports that leaves of *Aloe vera* have been placed on broken limbs of animals to treat fractures (Reynolds, 1950; Watt and Brandwijk 1962).

### ***g) Immune system***

*Aloe vera* contains biological response modifiers. These biological response modifiers have also been shown to stimulate peritoneal macrophages, splenic T- and B- cell proliferation, and to activate these cells to secrete TNF-alpha, IL-1, INF-, IL-2 and IL-6 (Leung *et al.*, 2004; Sa *et al.*, 2005). Studies on Aloe-emodin derived from *Aloe vera* have shown that it increased the levels of tumor necrosis factor (TNF) alpha and interleukin beta from leucocytes *in vitro* (Yu *et al.*, 2006). A mannose rich purified polysaccharide from *Aloe vera* has also been shown to have potent tumoricidal activity against murine cells (Leung *et al.*, 2004). Acemannan, (a complex carbohydrate) isolated from *Aloe vera*, has been used effectively as an adjuvant in vaccination against some avian viral diseases (Djeraba and Quere, 2000). *In vitro*, macrophages exposed to acemannan, have shown an upregulated respiratory burst, phagocytosis and increased candidicidal activity (Stuart *et al.*, 1997). Acemannan also has tumoricidal activity (Peng *et al.*, 1991). The antifungal activity of *Aloe vera* has been further confirmed by Ali *et al* (1999).

Early studies on *Aloe vera* showed some potential as a therapeutic tool in the fight against Human Immunodeficiency Virus (HIV) & Acquired Immune Deficiency Syndrome (AIDS), with reports that the virus became undetectable in some patients who used it on a regular basis (Maliehe, 1997). However there has not been much further investigation on this aspect of *Aloe vera*.

#### **1.1.4. The gastrointestinal tract**

A review of the literature on the use of *Aloe vera* and its extracts reveals that it is generally administered *per os* the implications of which are that its first point of contact with an organism exposed to it would be the gastrointestinal tract (GIT). The Gastrointestinal system is the portal through which nutrients and fluids enter the body. Physical digestion of ingesta commences in the mouth by action of the teeth and some chemical digestion can also occur in the mouth as a result of the enzymes contained in saliva (eg amylase) (Marini, 2004). However there generally is not enough time for chemical digestion to occur in the mouth as the ingesta is rapidly swallowed and passed on to the stomach. The stomach functions in the early stages of digestion and prepares the ingesta for further processing in the small intestine. The stomach is also involved in the physical and chemical digestion of food. Gastric juice with its acidic pH (due to hydrochloric acid) and rich content of proteases (pepsin) and gastric lipase effect the chemical digestion of the ingesta which then passes on to the small intestine. The small intestine is an important anatomical structure in the digestion of food and its size varies from one animal species to another (Lahey, 2009). Three anatomical sites are recognised in the small intestine, namely the duodenum, jejunum and ileum. The GIT is directly

exposed to environmental factors as result of daily dietary intake and adapts its structure and function in response to variations in diet (Sorensen, 2009). Food processed in the GIT induces a series of physiologic responses including the release of regulatory and trophic hormones, stimulation of the enteric nervous system and the activation of motility, digestive and absorptive functions of the GIT (Heneghan, 1984).

The GIT is a major source of peptides that regulate local and whole body metabolism and function (Sorensen, 2009). The GIT supplies the hypothalamus with various satiety and adiposity signals which convey information concerning the body's energy stores. The information is then used to determine the type and amount of food which should be eaten in order to restore the body's energy balance to an optimal level (Wilding *et al.* 1997; Woods *et al.* 2004; Wynne *et al.* 2005). Hormonal and paracrine substances which serve as peripheral signals released from the gastrointestinal tract include, among others ghrelin, leptin, PYY, oxyntomodulin and cholecystokinin, and these are released by enteroendocrine cells in the GIT in response to the different physical and chemical properties of the ingested food passing along the GIT (Strader and Woods, 2005; Wynne *et al.* 2005).

The exocrine pancreas also contributes to the digestive process in the small intestines. The exocrine pancreas makes up about 95% of the total pancreatic cell mass and consists of two major functional parts namely, the ductal cells (5%) and acinar cells (90%). Together these exocrine cells are responsible for the secretion of the pancreatic juice which is released in response to the presence of acidic chyme and digestive products within the duodenum, as well as a variety of cephalic and gastric signals. The rate of

secretion and the composition of pancreatic juice can be adapted to the composition of different diets (Buddington and Lepine, 1999).

Although internal programming mechanisms remain in control of the development of GIT function during early developmental stages, external factors, including diet, hormones and growth factors, play a role in the development of normal GIT function through transcriptional pathways (Strasburger, 2004). Studies on suckling and weanling rodents have shown that shifts in the activities of different intestinal enzymes and transporters are genetically programmed and relatively less influenced by dietary factors or hormones (Wieringa *et al.*, 2004). Diets rich in digestible carbohydrates result in lower levels of lipases secreted by both the gastric mucosa and the pancreas, whereas diets rich in indigestible carbohydrates or dietary fibre have been shown to cause increased lipase levels and output into the duodenum (Lairon *et al.*, 2007). Thus a number of factors affect the digestive process in as far as the dietary components are concerned. In particular the amount of nutrients ingested within the diet (i.e. the amount of carbohydrates, lipids, proteins etc.) as well as the form in which they are ingested play an important role.

Significant changes of diet occur during early developmental stages of individuals, with two key phases being immediately *postpartum* and the weaning period. The developmental patterns of the GIT at these stages are controlled by both genetic and dietary factors (Baumann, 1991). Dietary manipulations during the suckling period might have long lasting and possibly irreversible effects on some transport mechanisms in the GIT (Pacha, 2000). The ingestion of *Aloe vera* extracts by suckling babies either

directly through supplements or indirectly *via* their mothers milk might have effects on the GIT.

### **1.1.5. Growth and nutrition in neonates**

Human growth, viewed as a long term process, is reasonably regular and is characterised by a pattern of changing height velocity from infancy to adulthood (Ranke, 2003). In order for growth to take place within the lifespan of the individual, the millions of cells making up the individual's body must be supplied with sufficient nutrient material to enable them to multiply and reproduce new cells. Growth is not only characterised by an increase in cell number (hyperplasia) it also involves an increase in cell size (hypertrophy) (Gore *et al.*, 1994). The chemicals required by the cells to accomplish their various activities are referred to as "essential foods" and must be ingested in the diet of the individual to ensure that the growth process does not fail or become distorted. If however, for some reason the individual experiences a period of malnutrition, the growth of that specific individual will be transiently inhibited (Washburn, 1950). With respect to the "essential foods" required in order for growth to take place, some studies have demonstrated the importance of specific nutrients for infant growth such as protein, fat and carbohydrate from maternal milk to solid diet. The breast milk from a well nourished mother can supply adequate amounts of most vitamins and minerals during the suckling period.

Growth patterns differ from species to species such that rats continue to grow although at a declining rate throughout life whereas in humans two phases of rapid growth occur (Tisi *et al.*, 2005).

The body is regulated by many internal factors, such as hormones and enzymes. The key hormones involved in the regulation of growth are the androgens and oestrogens, thyroid hormones, insulin, glucocorticoids and growth hormone which interact with the

somatomedins namely, insulin-like growth factor I (IGF-I) and insulin-like growth factor II (IGF-II) (Tisi *et al.*,2005).

These hormones are all regulated by the hypothalamus (Ranke, 2003). The hypothalamus produces the releasing hormones which in turn stimulate the anterior pituitary to release one of six hormones (thyroid stimulating hormone (TSH), adrenocorticotrophic hormone (ACTH), growth hormone (GH), luteinizing hormone (LH), follicle stimulating hormone (FSH) and prolactin (PRL). Other than prolactin, the other five hormones are tropic and stimulate other endocrine glands to release hormonally active substances.

TSH from the pituitary stimulates the thyroid gland to secrete two hormones of primary importance in growth, thyroxine (T4) and triiodothyronine (T3). T3 is frequently considered the physiologically active hormone (Dunn, 2002).

Growth hormone mediates its growth promoting effects directly by stimulating protein deposition in the body and stimulating bone and visceral growth (Tisi *et al.*, 2005). It also works indirectly *via* interaction with the somatomedins (IGF-I and IGF-II) which are closely related to insulin (Mills *et al.*, 1986). The indirect action of growth hormone is thought to be its major mechanism for its effects (Millis *et al.*, 1986). These hormones promote long bone and tissue growth, cardiovascular maturation and function, and work with other hormonal systems to maintain homeostasis in the body (Guyton, 2006 and Sonntag *et al.*, 2005).

Glucose is the major energy source for the foetus and neonate. The newborn brain depends upon glucose almost exclusively. Up to 90% of total glucose used is consumed by the brain (Butler, 1995). Ketones and lactate are produced in very low quantities (Butler, 1995). Glucose regulatory mechanisms are sluggish at birth. Thus the infant is

susceptible to hypoglycaemia when glucose demands are increased or when exogenous or endogenous glucose supply is limited (Butler, 1995).

Nutritional support for the neonate presents unique challenges because of high metabolic demands for growth and body development. Early and appropriate nutritional support is warranted to meet nutrient requirements without expending body reserves, especially for preterm neonates in whom energy stores are considerably less when compared with term neonates.

#### **1.1.6. Justification of study**

The expense of conventional medications, especially in developing countries, has pushed researchers to focus on the healing potential of plants and plant extracts which are readily available in the communities (Blumenthal *et al.*, 1998). One plant that has received a lot of attention for centuries and in different cultures is *Aloe vera*. As reviewed earlier, *Aloe vera* has many tested and untested medicinal attributes affecting all the body systems.

Generally the route of administration of the plant extracts is *per os*. Thus their first point of contact is with the gastrointestinal tract (GIT). The GIT is a major source of peptides that regulate metabolism and function. Dietary manipulations during the suckling period might have long lasting and possibly irreversible effects on some transport mechanisms in the GIT (Gama & Alvares, 2000; Pacha, 2000). Given its many biologically active compounds, *Aloe vera* and its metabolites may have trophic effects and modulate tissue function and structure (Githens, 1979). Some plants/extracts have been shown to cause



precocious maturation of the GIT (Pari and Venkateswaran, 2004; Linderoth *et al.*, 2005, 2006).

Parents may expose their babies to *Aloe vera* either by giving *Aloe vera* extracts to their suckling babies or the biologically active metabolites of *Aloe vera* may pass to the infant *via* the mother's milk if the mother uses *Aloe vera* prenatally during pregnancy and postnatally during the nursing period. There is thus need to further study the effects of *Aloe vera* on the GIT which would be its first point of contact with the body. The suckling rat is an ideal model for neonatal studies (Pari and Venkateswaran, 2004).

#### **1.1.7 Aims and objectives**

The aims and objectives of this study were to evaluate the effects of Aqueous and Alcoholic extracts of *Aloe vera* on:

##### **a) The morphometry and morphology of the GIT and accessory organs of suckling rats**

The GIT is the first point of contact with dietary substances and is sensitive to dietary manipulations (which can change morphology) (Vazquez *et al.*, 1999). *Aloe vera* has been shown to contain growth factors, whose effects on the GIT *in vivo* have not been fully investigated.

##### **b) Growth performance**

Given its many constituents, some of which could have trophic effects, *Aloe vera* extracts may cause precocious maturation of the GIT which would result in improved digestion and absorption of nutrients resulting in improved growth rates of the rats as

reflected in body mass changes and linearly as measured by the change in length of the extremities (tibia and femur). In an attempt to explain any growth differences between the different treatment groups, it would be essential to assay the plasma concentrations of IGF-I a key hormone with growth promoting effects.

**c) Liver function (enzymes and storage of glycogen and lipids)**

The liver plays an important role in the metabolism of fat (synthesis, storage and transport) and is a major organ involved in the synthesis and storage of glycogen. Liver tissue also participates in the uptake, oxidation and metabolism of lipids, the synthesis of cholesterol and phospholipids and the secretion of specific classes of serum lipoproteins. The quantity of glycogen stored is significantly affected by dietary nutritional intake, thus any changes in GIT function could result in changes in glycogen stored.

By nature of its numerous constituents, hepatotoxicity is a potential complication of the use of plant extracts. It is thus important to evaluate the potential toxicity of the *Aloe vera* in the neonate. Alkaline phosphatase and alanine aminotransferase are important markers of liver damage hence their concentration in plasma can be used to assess possible hepatotoxicity of the *Aloe vera* extracts (Bain *et al.*, 2003). This would complement the morphological studies (histopathology).

**d) Metabolic substrates (blood glucose and triglyceride concentrations)**

Dietary nutrients and water are absorbed from the GIT, metabolised and either catabolised to provide energy or used anabolically in growth. The tissues of the vertebrate

brain can use glucose as their source of energy. The concentration of metabolic substrates is an indicator of homeostasis in the body. The concentration of glucose in the blood remains nearly constant and this is achieved by a complex set of interactions which include regulation by a number of hormones including insulin, glucagon and cortisol. Determination of triglycerides level in the blood could help to determine the disorders of lipid metabolism (hyperlipidemia or hypolipidemia).

## **Chapter 2 - Materials and Methods**

## **2.1 Study setting**

The study was conducted in the Central Animal Services animal facility and the School of Physiology at the Faculty of Health Sciences, University of Witwatersrand, Johannesburg, South Africa from 2008-2009.

The study was approved by the Animal Ethics Screening Committee of the University of Witwatersrand and awarded an Ethical clearance certificate number 2008/37/03.

### **2.1.1 Study design**

The study was undertaken with a total of 77 suckling, 6 day old Sprague Dawley rats (38 males and 39 females received from different batches with different dams during the research period and according to their availability in the Central Animal Service). The suckling rats were randomly allocated to five treatment groups (group I: served as a control and was administered normal saline (0.9%), group II + III which were given low ( $50 \text{ mg.kg}^{-1}$ ) and high dose ( $500 \text{ mg.kg}^{-1}$ ) respectively of Alcoholic extracts of *Aloe vera* and group IV + V which received low ( $50 \text{ mg.kg}^{-1}$ ) and high doses ( $500 \text{ mg.kg}^{-1}$ ) of Aqueous extracts of *Aloe vera* daily respectively. All of the solutions were administered at a volume of  $10 \text{ ml.kg}^{-1}$  body mass by gavage with an orogastric tube attached to a 1 ml syringe containing the requisite amounts of the different solutions.

## **2.2 Materials**

### **2.2.1 Plant collection**

Fresh *Aloe vera* plants, from which test extracts were made, were sourced from a commercial plant nursery, Flora farm in Boksburg, Gauteng Province, South Africa. The farm is on longitude of 28 ° 24' 15 and latitude 26 ° 82' 10 with a mean annual minimum temperature of 14 °C, mean annual maximum temperature of 30 °C, mean annual minimum rainfall of 450mm and mean annual maximum rainfall of 500mm. The University of the Witwatersrand Herbarium research manager Mr Donald McCallum verified the identity of the *Aloe vera* plants using established procedures for plant identification and taxonomy. A sample of *Aloe vera* plant was dried using a wooden press and stored in the University Herbarium with voucher number: Ben Beya 1.

## **2.3 Methods**

### **2.3.1 Preparation of *Aloe vera* extracts**

The Aqueous and Alcohol (ethanol) extracts were prepared from fresh *Aloe vera* leaves as described by Brian and Turner (1975). Briefly, 370g of freshly cut leaves of *Aloe vera* were either mixed with 100 ml of 70% ethanol (Univ AR®, Gauteng, South Africa) or 100 ml of distilled water and crushed in a blender (Waring®, Isec SA Company, USA) for one minute. The crushed mixtures were then agitated on a shaker incubator (Chaker RPM®, Lab design company, Vervaarding, South Africa), for 12 hours. The resulting suspension was then filtered through filter paper (Albert®, Pore 7-11, size 185mm, England). The filtrate was frozen at -70 °C and then lyophilized in a lyophiliser (Vacuum

Gauge, USA). The resultant powder was weighed using a balance (Precisa@310M, Switzerland) to determine the yield of extracts. The yield for alcohol extracts was 1.5% and for the aqueous extracts 1.2% powder from 370g fresh *Aloe vera*. The extracts were stored in tightly sealed dark containers in a freezer at -20°C for later use.

### **2.3.2 Dry matter determination**

Dry matter of the *Aloe vera* was determined by weighing fresh leaves and placing them in an oven at 40°C for 5 days until a consistent mass was reached. The difference in fresh mass and dry mass represented the moisture content. The moisture content of the *Aloe vera* was 92%.

### **2.3.3 Housing of animals**

Each dam and its respective pups were housed in separate cages with beddings of hard wood shavings mixed with pieces of paper for environmental enrichment. The rats were kept for 9 days in the Central Animal Service multipurpose animal rooms during experiments. They were housed in a controlled environment with 12 hour light-dark cycles (lights on 07.00-19.00) and constant room temperature of 22-24 °C.

### **2.3.4 Experimental animals**

Seven adult Sprague –Dawley female rats (Central Animal Services, University of the Witwatersrand, Johannesburg, South Africa) that had given birth to a total of 77 suckling pups (males and females) were used in the study. The 7 dams were kept with their own

pups and supplied with mice cubes (Epol®, Johannesburg, South Africa) and tap water *ad libitum* (provided in 500ml water bottles with nipple tips). The dams did not receive any treatment during the study, they were just weighed every third day as part of routine husbandry to monitor their general health and growth performance.

When the pups in each litter were received at 6 days of age, they were randomly assigned to each treatment group and identified by colour codes marked on their tails with a non invasive, non toxic superficial permanent ink marker.

The pups in each treatment group received *Aloe vera* extracts at the two different doses every morning between 09h00-10h00 over a period of 8 days pups were then anaesthetised and subsequently killed with Sodium Pentobarbitone (150mg.kg<sup>-1</sup>) (Euthanase®, Centaur labs, Johannesburg, South Africa) injected intraperitoneally. The dams were returned to stock.

### **2.3.5 Blood sampling and plasma processing**

Following administration of anaesthesia to the pups, blood samples were obtained by cardiac puncture using 21G needles on 1ml syringes flushed with heparin (Heparin Novo®, Novo Nordisk Company, Johannesburg, South Africa). The blood samples were used for determination of glucose, triglycerides and liver enzymes. The samples were transferred to plain blood tubes (Greiner Bio-one GnebH, Austria) and then centrifuged at 3000G at 4°C (SorvallRT®6000B) for 15min and the plasma was collected and stored at -70°C until hormonal assays were performed.



### **2.3.6 Determination of glucose and triglyceride concentration in blood**

The blood glucose and blood triglyceride concentrations were determined by colorimetric enzyme reactions using a glucometer (Glucometer Elite® 3947, Bayer Company, Japan) and triglyceride meter (Accutrend triglycerides, Roche Company, Mannheim, Germany) respectively. The instruments were calibrated and used according to the manufacturer's instructions. During tissue harvesting, a drop of blood collected from cardiac puncture was drawn on the test strip into the reagent chambers of each of the Glucometer and the triglyceride meter and results for the metabolic substrates were then read off the meters' display unit.

### **2.3.7 Determination of liver enzymes (total alkaline phosphatase and alanine aminotransaminase)**

The enzyme activity (U.L<sup>-1</sup>) was determined using the Reflotron machine (Reflotron®, Roche diagnostics LTD, Burgess Hill west Sussex, RH159RY, United Kingdom). After calibration of the machine according to the manufacturer's instructions, drops of blood were placed on test strips which were then placed into the Reflotron machine which performed the assays and gave a print out of results. The test strips for the alanine aminotransaminase were Reflotron® GPT (ALT) (Roche Diagnostics GmbH, Mannheim, Germany). The test strips for the alkaline phosphatase were Reflotron® Alkal. Phosphatase (Roche Diagnostics GmbH, Mannheim, Germany).

### **2.3.8 Measurement of insulin-like growth factor (IGF-1)**

The hormone IGF-1 was determined by enzyme linked immunosorbent assay (ELISA) using a Mouse IGF-I kit (Quantikine<sup>®</sup>, Mouse IGF-I, R&D Systems Europe) according to manufacturer instructions. The kit also recognises rat IGF-1 which shares 99% amino acid sequence identity with mouse IGF-1. According to the manufacturers, the kit has been validated for the determination of rat IGF-I. All the reagents and plates were supplied in the kit. The assay employed the quantitative sandwich enzyme immunoassay technique. Fundamentally the method utilised a monoclonal antibody specific for rat IGF-1 which was pre-coated into 96 well polystyrene microplates. Standards, controls and samples were pipetted into the 8 wells coated with monoclonal antibody specific for mouse IGF-1 present that could bind by the immobilization of the antibody. After washing away any unbound substances with buffer, an enzyme-linked polyclonal antibody against rat IGF-1, conjugated to horseradish peroxidase, with preservatives, was added to the wells. Following a wash with buffer concentrate to remove any unbound antibody-enzyme reagent, a substrate solution was added to the wells. The intensity of the colour measured was in proportion to the amount of rat IGF-1 bound in the initial step. The sample values were then read on a plate reader machine (Multiskan Ascent, Lab system, model n° 354, Helsinki, Finland) at 450nm with a second correction wavelength measurement at 540nm. A standard curve was constructed and the concentrations of the IGF-I in the samples was determined with reference to the standard curve. According to the manufacturers, the kit has a mean minimum detectable dose of 3.5 pg. ml<sup>-1</sup>.

### **2.3.9 Morphometry and morphology of abdominal viscera**

After anaesthesia, the abdomen and thorax were opened carefully and all viscera removed and weighed. The intestines were gently stretched out on a board for gross and macroscopic measurements. Lengths of emptied large and small intestines were determined and the mass of the accessory and abdominal organs were evaluated. After weighing the livers, they were frozen at -20°C for later analysis of lipid content and glycogen.

During dissection, samples of the intestine, liver, caecum and thymus were collected for histological evaluation. Sections of the small intestine (from the proximal and distal halves), 1cm long were collected together with sections of the liver and thymus and preserved in 10% phosphate buffered formalin and then embedded in paraffin. They were then sectioned and stained with haematoxylin and eosin. The stained histological specimen was covered with a glass cover slip.

Morphometric parameters, in both the proximal and distal small intestine, in well-oriented cross-sections, villus heights and crypt depth for the small intestine, were measured *via* a light microscope using an eye piece micrometer (Reichert®, Austria). Similarly, measurements of the caecum were made. An assessment of morphometry of the thymus was also done under light microscopy. The microscope had a camera mounted linked to a computer which ran a program for image capturing and assessment (motic images plus 2.0ML, Software, China group Co. Ltd, China).

### **2.3.10 Determination of liver lipid content**

Standard procedures were used for lipid extraction (Bligh and Dyer, 1959). In summary, 1-2g of liver samples was mixed in 100 ml of chloroform – methanol mixture (2:1) and left to extract overnight at 4°C. The samples were then filtered through filter paper (Albert®, Pore 7-11 , Size 185 mm) and 30 ml 0.9% saline added, mixed, and allowed to stand overnight at 4°C to allow separation into two phases.

The bottom (chloroform) phase was collected and reduced to dryness under vacuum at 37°C using a water bath (Labex®, vervaardigdeur, Krugersdorp, Transvaal, South Africa) and then made up to 20 ml with chloroform. An aliquot of 2ml of the extracts were placed in dried, pre-weighed vials, and re-dried at 50°C for 30 minutes, cooled and then reweighed to determine the lipid content. The livers were also dried and their dry matter content determined.

### **2.3.11 Determination of liver glycogen storage**

The glycogen content of the liver was determined indirectly by acid hydrolysis to glucose as described by Passoneau and Lauderdale (1974). Briefly, 0.1g of the liver was placed in 1ml of 0.03M hydrochloric acid and homogenised with an ultra turrex homogeniser for 20 seconds. To hydrolyse the glycogen, 1ml of 1M hydrochloric acid was added, liver samples of suckling rats were sealed and placed in a boiling water bath for 2 hours. One ml of 1M sodium hydroxide was then added to neutralise the samples before glucose determination. Glucose concentration of the hydrosylate was determined with a glucose

(glucose oxidase) assay kit (Sigma catalogue, GAGO-20) and a spectrophotometer (LKB Ultrospec II, LKB Biochrom Ltd., England). The glycogen was expressed as glucose equivalents.

### **2.3.12 Femur and tibial lengths and masses**

The right femoral head was removed gently from the acetabulum at the hip joint, the muscles and soft tissues were removed from the bones (tibia and femur) and the length of the bones was measured with a ruler. The bones were then dried in an oven (Salvis ®) at 40°C for 7 days (until constant mass) and then weighed to determine their dry mass.

### **2.3.13 Statistical analysis**

All data are expressed as mean  $\pm$  SD. A one way analysis of variance (ANOVA) was used to assess the effects of *Aloe vera* extracts on the parameters measured between groups followed by a Bonferroni test. The level of significance was set at  $p < 0.05$ . All the statistical analysis were performed using Graph Pad Prism version 5.0 (Graph Pad software, San Diego, C.A).

## **Chapter 3 - Results**

### **3.1 Mortality and morbidity of the animals**

During the study all of the animals remained healthy and consequently no incidental or iatrogenic rat mortalities were recorded.

### **3.2 The effect of *Aloe vera* extracts on body mass**

Figure 1 shows the body mass gain of the suckling rats after administration of the *Aloe vera* extracts. There was no significant difference in the initial mass of the suckling rats after allocation to different groups (Table1). After 8 days on the various treatments, all groups body mass increased significantly (Table 1) with the greatest percentage body mass gain noted in the groups given the high doses of the aqueous (AqL) and alcohol (AlcL) *Aloe vera* extracts (Figure 1).

### **3.3 Visceral organ mass and histology**

A significant increase was observed ( $p < 0.05$ , ANOVA) in the absolute mass of the caecum and thymus of suckling rats fed with high doses of the alcohol and the aqueous extracts of *Aloe vera* (Table 1) and (Figure 2) compared to the control group which received normal saline. When considering individually all of the other organs as a percentage of body mass (relative to body mass), there were no significant differences observed ( $p > 0.05$ , ANOVA) between the groups, however the relative mass of the caecum was increased. The increase in caecal mass could be attributed to an increased thickness of muscularis, submucosa and mucosa layers (Table 5) and (Figure 6).

Supplementation with *Aloe vera* extracts had no significant effect on the small intestinal villus height and crypt depth ( $p > 0.05$ , ANOVA) (Table 4).

Microscopic examination did not reveal any severe histopathology of the liver (Figure 9).

### **3.4 The effect of *Aloe vera* extracts on the tibia and femur length and mass**

There was no significant difference in linear growth of the femur amongst the different treatment groups ( $p > 0.05$ ). Although the rats fed with a high dose of the aqueous extracts had significantly ( $p < 0.05$ ) longer tibias than the controls, there was no difference observed in the tibial masses or densities of the bones from the different treatment groups. The bone density was calculated using the following formula:

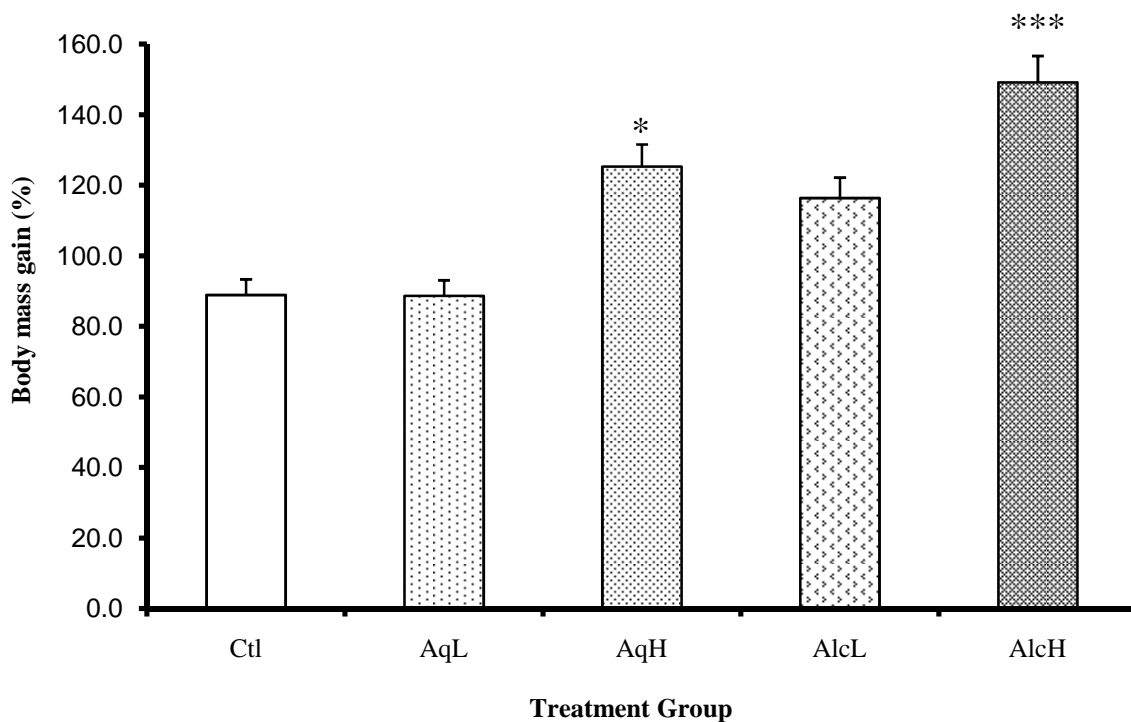
$$\text{Bone density (mg.mm}^{-1}\text{)} = \text{Mass of the bone (mg)} / \text{length of the bone (mm)}$$

### **3.5 The effects of *Aloe vera* extracts on liver lipid content and glycogen**

Hepatic content of lipids (Figure 3) and glycogen (Figure 4) was significantly increased in the suckling rats given the high dose of the aqueous extracts of *Aloe vera* ( $p < 0.001$ ).



### Effect of *Aloe vera* extracts on body mass gain



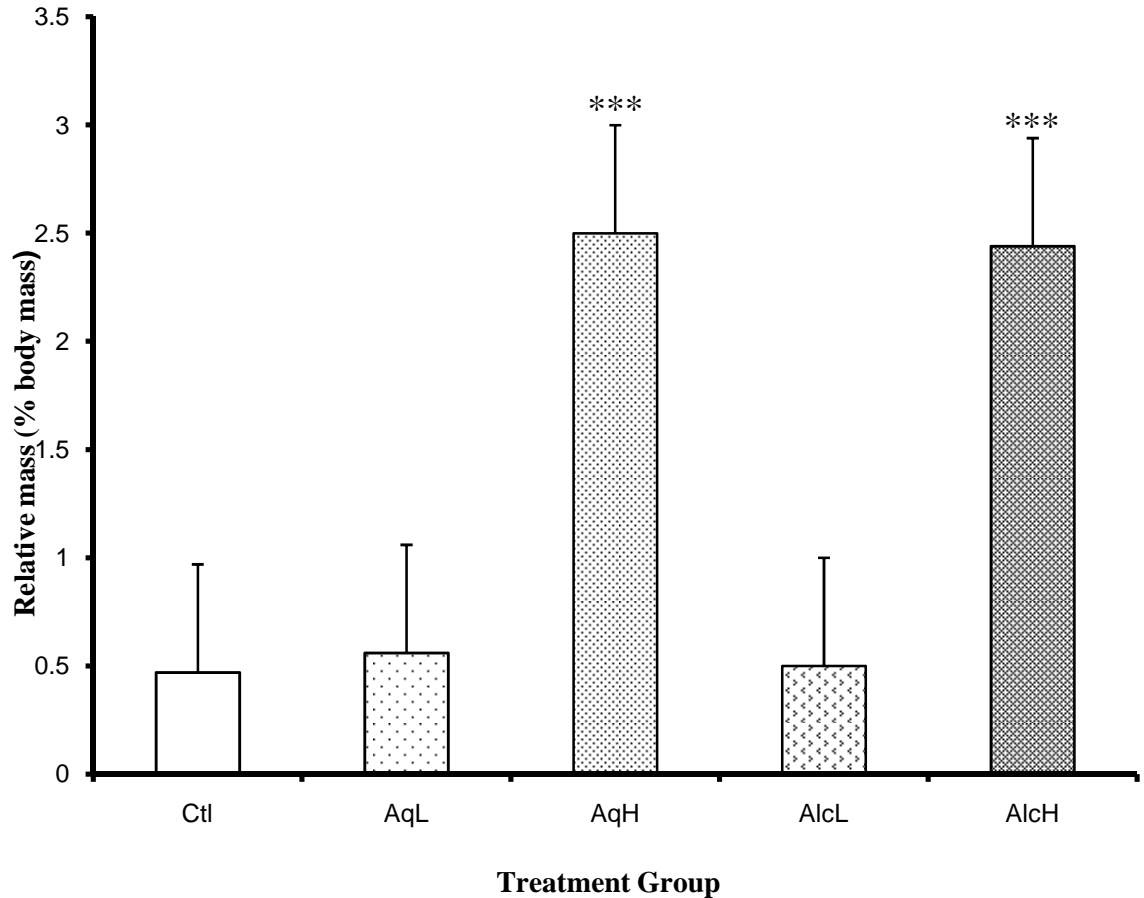
**Figure 1. Key:** Ctl=Control group of rats; AqL= low dose ( $50\text{mg. kg}^{-1}$ ) aqueous extract group; AqH= high dose ( $500\text{mg. kg}^{-1}$ ) aqueous extract group; AlcL= low dose ( $50\text{mg. kg}^{-1}$ ) alcohol extract group; AlcH= high dose( $500\text{mg. kg}^{-1}$ ) alcohol extract group. The results from figure 1 show that the high doses of the *Aloe vera* extracts significantly increased the body mass gain (expressed as a percentage of the initial mass) of suckling rats after 8 days of treatment (mean  $\pm$ SD). \* $p < 0.05$  for aqueous high (AqH =  $151 \pm 9\%$ ) vs control (Ctl =  $89 \pm 6\%$ ); aqueous low (AqL=  $87 \pm 7\%$ ) and alcohol low (AlcL=); \*\*\* $p < 0.001$  alcohol high (AlcH= $151 \pm 9$ ) vs all groups.

**Table 1: Effect of *Aloe vera* extracts on the body mass, the absolute (g) and relative mass (% body mass) of viscera and, length (cm) of viscera of suckling rats.**

	Ctl (n=11)	AqL (n=12)	AqH (n=12)	AlcL (n=12)	AlcH (n=12)
Initial BM(g)	16 ± 1.50	16.33 ± 1.19	16.46 ± 1.51	14.63 ± 1.77	16.33 ± 1.9
End BM(g)	30.09 ± 2.30	30.75 ± 2.67	37.75 ± 3.71*	31.21 ± 3.11	40.25 ± 1.97*
S.I (cm)	502.50 ± 57.01	526.67 ± 60.55	542.00 ± 128.82	513.33 ± 23.38	517.50 ± 36.96
Absolute S.I (g)	0.03 ± 0.00	0.03 ± 0.00	0.03 ± 0.00	0.03 ± 0.00	0.03 ± 0.00
Relative S.I (%)	0.09 ± 0.00	0.09 ± 0.00	0.07 ± 0.00	0.09 ± 0.00	0.07 ± 0.00
L.I (cm)	74.67 ± 6.87	73.57 ± 8.52	76.67 ± 13.29	75.71 ± 11.70	75.00 ± 10.22
Absolute L.I (g)	0.14 ± 0.06	0.12 ± 0.02	0.13 ± 0.03	0.11 ± 0.04	0.12 ± 0.03
Relative L.I (%)	0.46 ± 0.09	0.39 ± 0.05	0.34 ± 0.06	0.35 ± 0.07	0.29 ± 0.05
Caecum (g)	0.07 ± 0.01	0.08 ± 0.03	0.10 ± 0.06***	0.08 ± 0.03	0.96 ± 0.08***
Liver (g)	0.87 ± 0.13	0.87 ± 0.11	1.20 ± 0.30	0.99 ± 0.10	1.27 ± 0.22
Liver (%)	2.91 ± 0.52	2.83 ± 0.33	3.25 ± 0.63	3.16 ± 0.24	3.15 ± 0.51
Stomach (g)	0.21 ± 0.06	0.22 ± 0.06	0.22 ± 0.44	0.19 ± 0.03	0.21 ± 0.04
Stomach (%)	0.69 ± 0.17	0.70 ± 0.18	0.59 ± 0.12	0.61 ± 0.12	0.53 ± 0.09
Spleen (g)	0.15 ± 0.03	0.17 ± 0.03	0.18 ± 0.03	0.16 ± 0.02	0.16 ± 0.03
Spleen % BM	0.51 ± 0.12	0.54 ± 0.12	0.48 ± 0.09	0.51 ± 0.08	0.40 ± 0.08

**KEY:** BM= body mass; LI= large intestine; SI= small intestine; cm= centimetre; g= gram; Ctl= Control group of rats; AqL= low dose (50mg. kg<sup>-1</sup>) aqueous extract group; AqH= high dose (500mg. kg<sup>-1</sup>) aqueous extract group; AlcL= low dose (50mg. kg<sup>-1</sup>) alcohol extract group; AlcH= high dose (500mg. kg<sup>-1</sup>) alcohol extract group. Data in the same row indicate significant difference (\*p<0.05 and \*\*\*p<0.001). The results in this table indicate that the rats fed the high doses of the extracts had a significant body mass gain and heavier caeca than the rats in the other groups.

### Effect of *Aloe vera* extracts on the relative mass of thymus



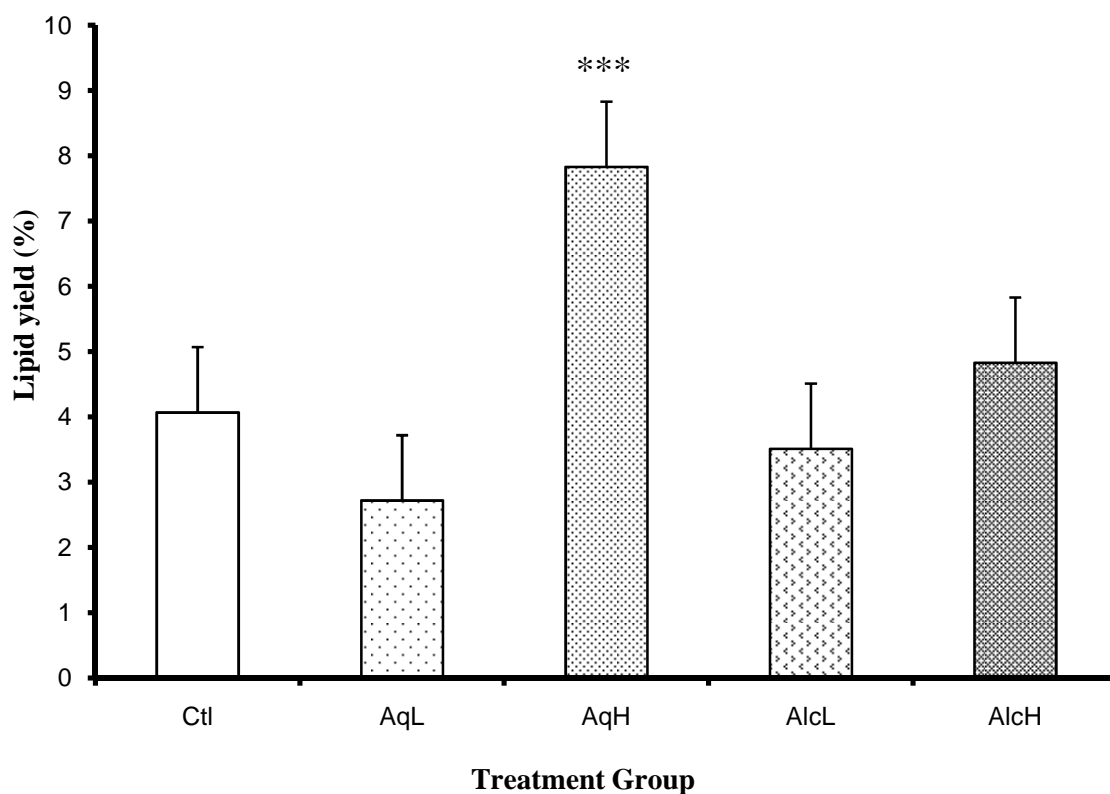
**Figure 2.** Key: Ctl=Control group of rats; AqL= low dose (50mg. kg<sup>-1</sup>) aqueous extract group; AqH= high dose (500mg. kg<sup>-1</sup>) aqueous extract group; AlcL= low dose (50mg. kg<sup>-1</sup>) alcohol extract group; AlcH= high dose(500mg. kg<sup>-1</sup>) alcohol extract group. The results from figure 2 show that after 8 days of treatment the relative mass (mean ± SD) of the thymus (expressed as a percentage body mass) of the rats given the high doses of the *Aloe vera* extracts was significantly greater than that of rats in the other groups (\*\*\*)p < 0.001 AqH (2.51±0.95), AlcH( 2.48±1.07) vs. Ctl(0.49±0.62±), AqL(0.55±0.80) and AlcL(0.48±0.71)). n= 12 per group except Ctl where n= 11.

**Table 2: Effect of *Aloe vera* on the absolute and relative length and mass of the tibias and femurs of the rats**

	Ctl (n = 11)	AqL (n=12)	AqH (n=12)	AlcL (n=12)	AlcH (n=12)
<b>Tibia</b>					
Length (mm)	15.00 ± 0.89	15.66 ± 1.07	18.91 ± 1.31***	16.75 ± 0.96	16.75 ± 1.05
Mass (mg)	4.10 ± 0.07	4.20 ± 0.07	4.60 ± 0.06	4.20 ± 0.09	4.20 ± 0.06
Density (mg.mm <sup>-1</sup> )	0.27 ± 0.78	0.26 ± 0.06	0.20 ± 0.04	0.25 ± 0.09	0.25 ± 0.05
<b>Femur</b>					
Length (mm)	12.09 ± 0.94	12.25 ± 0.86	13.5 ± 0.52	12.33 ± 0.65	12.91 ± 0.79
Mass (mg)	4.30 ± 0.10	4.20 ± 0.50	4.00 ± 0.10	4.20 ± 0.70	4.00 ± 0.60
Density (mg.mm <sup>-1</sup> )	0.35 ± 0.10	0.34 ± 0.05	0.20 ± 0.19	0.34 ± 0.10	0.30 ± 0.07
<b>T</b>					

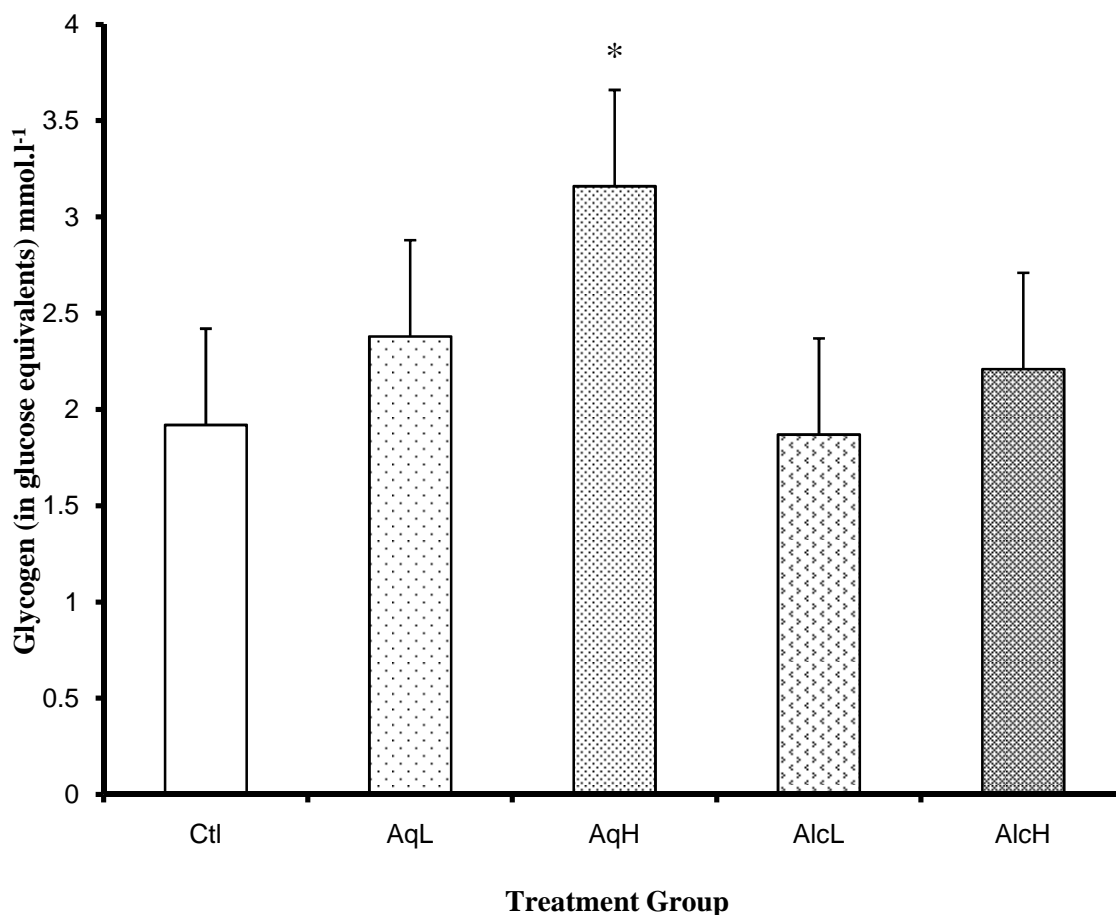
**Key:** Ctl=Control group of rats; AqL= low dose (50mg. kg<sup>-1</sup>) aqueous extract group; AqH= high dose (500mg. kg<sup>-1</sup>) aqueous extract group; AlcL= low dose (50mg. kg<sup>-1</sup>) alcohol extract group; AlcH= high dose (500mg. kg<sup>-1</sup>) alcohol extract group. The results in this table indicate that the rats administered with the high dose of aqueous extracts for 8 days had significantly longer tibias (\*\*\*p < 0.001) compared to the control group. Data are expressed as mean ± SD.

**Effect of *Aloe vera* extracts on the hepatic lipid content of the of the suckling rats**



**Figure 3. Key:** Ctl=Control group of rats; AqL= low dose (50mg. kg<sup>-1</sup>) aqueous extract group; AqH= high dose (500mg. kg<sup>-1</sup>) aqueous extract group; AlcL= low dose (50mg. kg<sup>-1</sup>) alcohol extract group; AlcH= high dose (500mg. kg<sup>-1</sup>) alcohol extract group. The results in this figure show that the rats administered the high doses of the extracts had significantly greater hepatic lipid yield (% liver mass) on a dry matter basis (mean ± SD). \*\*\*p < 0.001 AqH (7.8 ± 1.2%) vs all th other groups, ie AlcL (3.7±1.0), AqL (2.8±0.9), Ctl (4.0±1.2). n= 12 per group except Ctl where n= 11.

### Effect of *Aloe vera* extracts on the glycogen content of livers from suckling rats



**Figure 4. Key:** Ctl=Control group of rats; AqL= low dose (50mg. kg<sup>-1</sup>) aqueous extract group; AqH= high dose (500mg. kg<sup>-1</sup>) aqueous extract group; AlcL= low dose (50mg. kg<sup>-1</sup>) alcohol extract group; AlcH= high dose(500mg. kg<sup>-1</sup>) alcohol extract group. The results in figure 4 show that after 8 days of feeding suckling rats with *Aloe vera* extracts the liver glycogen storage expressed as glucose equivalents in mmol.l<sup>-1</sup> of liver homogenate (mean ± SD) was significantly increased (\*p < 0.05) in the AqH (3.3±0.5) vs Ctl (1.8±0.4), AqL (2.4±0.6), AlcL(1.8±0.4) and AlcH(2.2±0.5). all groups. n= 12 per group except Ctl where n= 11.

**Table 3: Effect of *Aloe vera* extracts on non fasting blood concentrations of glucose, Triglycerides, ALT, ALP and IGF-1.**

	Ctl (n = 11)	AqL (n = 12)	AqH (n = 12)	AlcL (n = 12)	AlcH (n = 12)
NF Glucose (mmol.l <sup>-1</sup> )	4.27 ± 1.16	5.93 ± 0.79	5.98 ± 0.49	5.28 ± 1.50	5.98 ± 0.50
NF TG (mmol.l <sup>-1</sup> )	4.27 ± 1.16	3.68 ± 0.52	3.79 ± 1.27	4.32 ± 1.03	4.36 ± 1.65
Mouse IGF-I equivalent (Pg.ml <sup>-1</sup> )	140.5 ± 40	141.4 ± 25	118.6 ± 34	103.3 ± 13	151.8 ± 44
ALT (U. l <sup>-1</sup> )	9.5 ± 5.8	11.9 ± 6.9	10.7 ± 8.1	11.9 ± 7.9	10.3 ± 5.5
ALP (U. l <sup>-1</sup> )	357 ± 16	355 ± 64	432 ± 13	413 ± 12	474 ± 14***

**Key:** Ctl=Control group of rats; AqL= low dose (50mg. kg<sup>-1</sup>) aqueous extract group; AqH= high dose (500mg. kg<sup>-1</sup>) aqueous extract group; AlcL= low dose (50mg. kg<sup>-1</sup>) alcohol extract group; AlcH= high dose (500mg. kg<sup>-1</sup>) alcohol extract group, NF TG= Non fasting triglycerides; IGF-1= insulin- like growth factor-1; ALT= alanine-amino-transaminase; ALP= alkaline phosphatase. Data are expressed as mean ± SD.

The results in table 3 indicate that the after 8 days of feeding suckling rats aloe vera extracts, the rats exposed to the high dose had significantly higher (\*\*\*) ALP levels than the other groups. The metabolic substrates, liver enzymes and the hormone IGF-I were not significantly different between the different groups of rats.

**Table 4: Effect of 2 different doses of Aqueous and Alcohol extracts of *Aloe vera* on the microscopic measurements of small intestines of suckling rats (mean  $\pm$  SD)**

Group	Villus Height ( $\mu\text{m}$ )	Crypt Depth ( $\mu\text{m}$ )	$VH/CD$ ratio
Ctl	40.06 $\pm$ 2.25	9.38 $\pm$ 0.83	4.27 $\pm$ 2.71
AqL	37.62 $\pm$ 6.36	8.43 $\pm$ 0.90	4.46 $\pm$ 7.06
AqH	39.69 $\pm$ 1.34	9.88 $\pm$ 0.66	4.01 $\pm$ 2.03
AlcL	40.00 $\pm$ 0.54	8.75 $\pm$ 0.74	4.57 $\pm$ 0.72
AlcH	38.81 $\pm$ 3.10	9.13 $\pm$ 0.75	4.25 $\pm$ 4.13

**Key:** Ctl=Control group of rats; AqL= low dose (50mg.  $\text{kg}^{-1}$ ) aqueous extract group; AqH= high dose (500mg.  $\text{kg}^{-1}$ ) aqueous extract group; AlcL= low dose (50mg.  $\text{kg}^{-1}$ ) alcohol extract group; AlcH= high dose (500mg.  $\text{kg}^{-1}$ ) alcohol extract group; VH= villus height; CD= crypt depth  $VH/CD$ . n= 8 per group. The results in table 4 indicate that the mophometry of the small intestinal villi and crypts was not significantly affected after 8 days of feeding *Aloe vera* extracts.

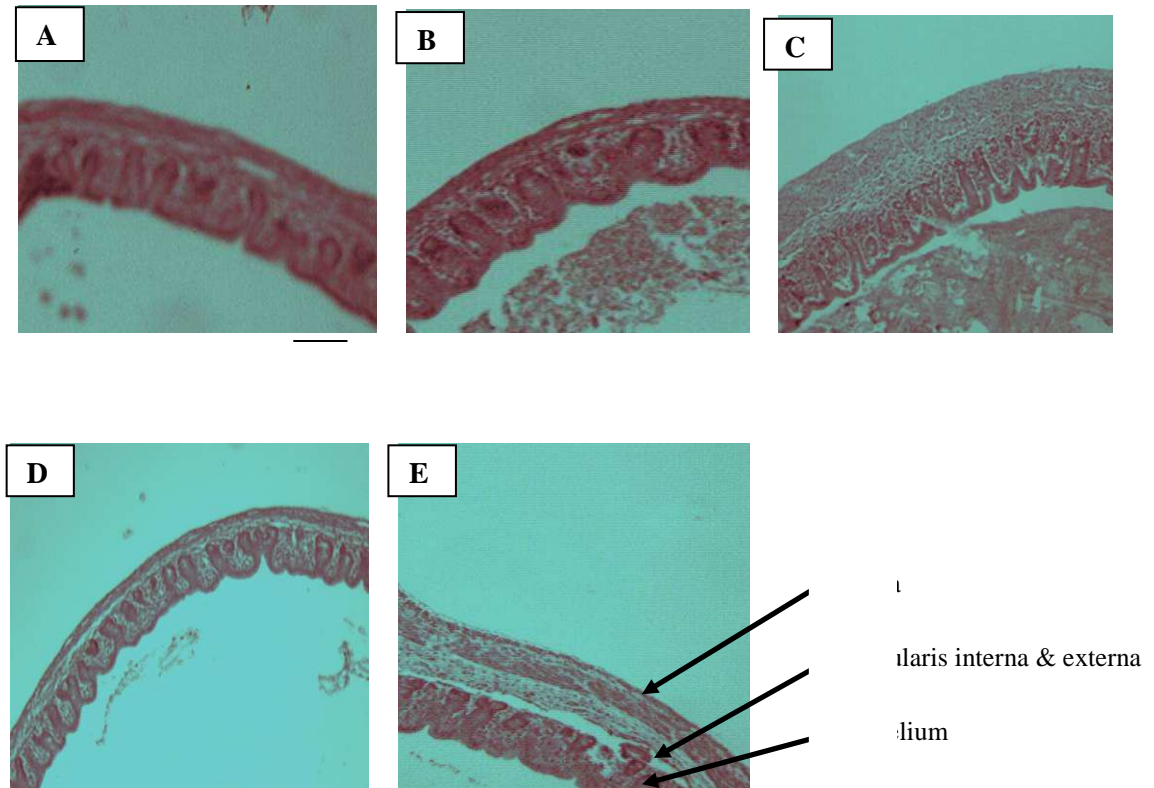


**Table 5: Effect of *Aloe vera* extracts on the morphometry of the caecum of suckling rats (mean  $\pm$  SD)**

	Ctl	AqL	AqH	AlcL	AlcH
Serosa	1.4 $\pm$ 0.21	2.04 $\pm$ 0.43	5.0 $\pm$ 0.83*	1.58 $\pm$ 0.23	2.06 $\pm$ 0.20
Muscularis	8.26 $\pm$ 0.65	8.26 $\pm$ 0.81	35.6 $\pm$ 7.19**	8.06 $\pm$ 1.07	20.76 $\pm$ 0.81*
Submucosa	8.48 $\pm$ 0.87	13.5 $\pm$ 4.02	9.8 $\pm$ 6.61	12.82 $\pm$ 3.6	12.12 $\pm$ 3.23
+Mucosa					
Epithelium	2.80 $\pm$ 0.52	3.62 $\pm$ 0.48	3.76 $\pm$ 0.51	3.96 $\pm$ 0.40	3.59 $\pm$ 0.25
Total thickness	20.94 $\pm$ 2.25	30.72 $\pm$ 5.74	67.16 $\pm$ 15.14***	30.42 $\pm$ 5.30	41.93 $\pm$ 4.49***

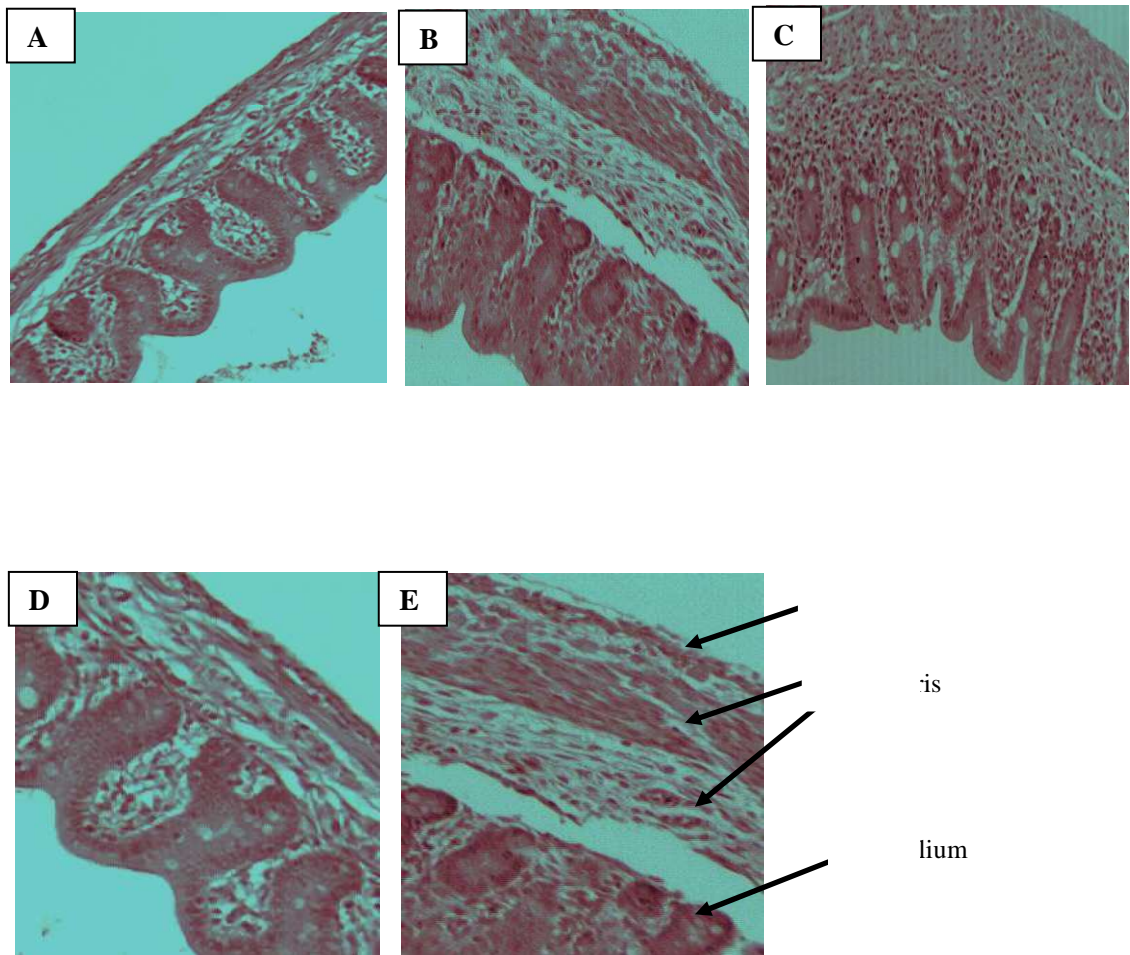
**Key:** Ctl=Control group of rats; AqL= low dose (50mg. kg<sup>-1</sup>) aqueous extract group; AqH= high dose (500mg. kg<sup>-1</sup>) aqueous extract group; AlcL= low dose (50mg. kg<sup>-1</sup>) alcohol extract group; AlcH= high dose (500mg. kg<sup>-1</sup>) alcohol extract group. Data in the same row with different superscripts indicate significant difference (\*\*\*p < 0.001, \*\*p < 0.01, \*p < 0.05) between control group and treatments groups. n= 8 per group. The results in table 5 indicate that the rats exposed to high doses of the *Aloe vera* extracts had an increased thickness of the caecum wall with the significant increases being in the Muscularis (in both the AlcH and AqH groups) and serosal layer (only AlcH group).

## Histology of the caecum (low magnification)



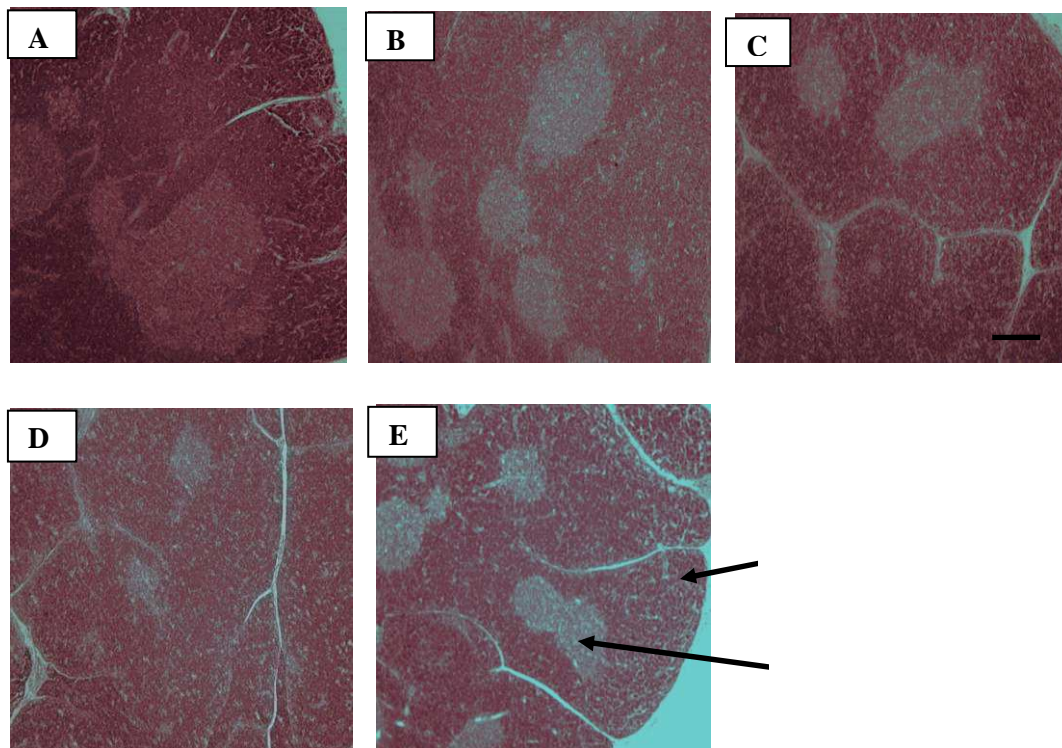
**Figure 5a. Key:** A= Control group of rats; B = low dose ( $50\text{mg. kg}^{-1}$ ) aqueous extract group; C= high dose ( $500\text{mg. kg}^{-1}$ ) aqueous extract group; D= low dose ( $50\text{mg. kg}^{-1}$ ) alcohol extract group; E= AlcH= high dose ( $500\text{mg. kg}^{-1}$ ) alcohol extract group. This figure is a digital photograph of Hematoxylin and eosin stained sections (40X magnification) of the caecum of suckling rats (14 days old) following the various treatments. The thickened muscularis and serosal layers are notable in the rats on the high doses of the extracts. The Bar =  $20\ \mu\text{m}$ .

### Histology of the caecum (high magnification)



**Figure 5b. Key:** A= Control group of rats; B = low dose (50mg. kg<sup>-1</sup>) aqueous extract group; C= high dose (500mg. kg<sup>-1</sup>) aqueous extract group; D= low dose (50mg. kg<sup>-1</sup>) alcohol extract group; E= AlcH= high dose (500mg. kg<sup>-1</sup>) alcohol extract group. This figure is a high magnification digital photograph of Hematoxylin and eosin stained sections (40X magnification) of the caecum of suckling rats (14 days old) following the various treatments. The thickened muscularis and serosal layers are notable in the rats on the high doses of the extracts.

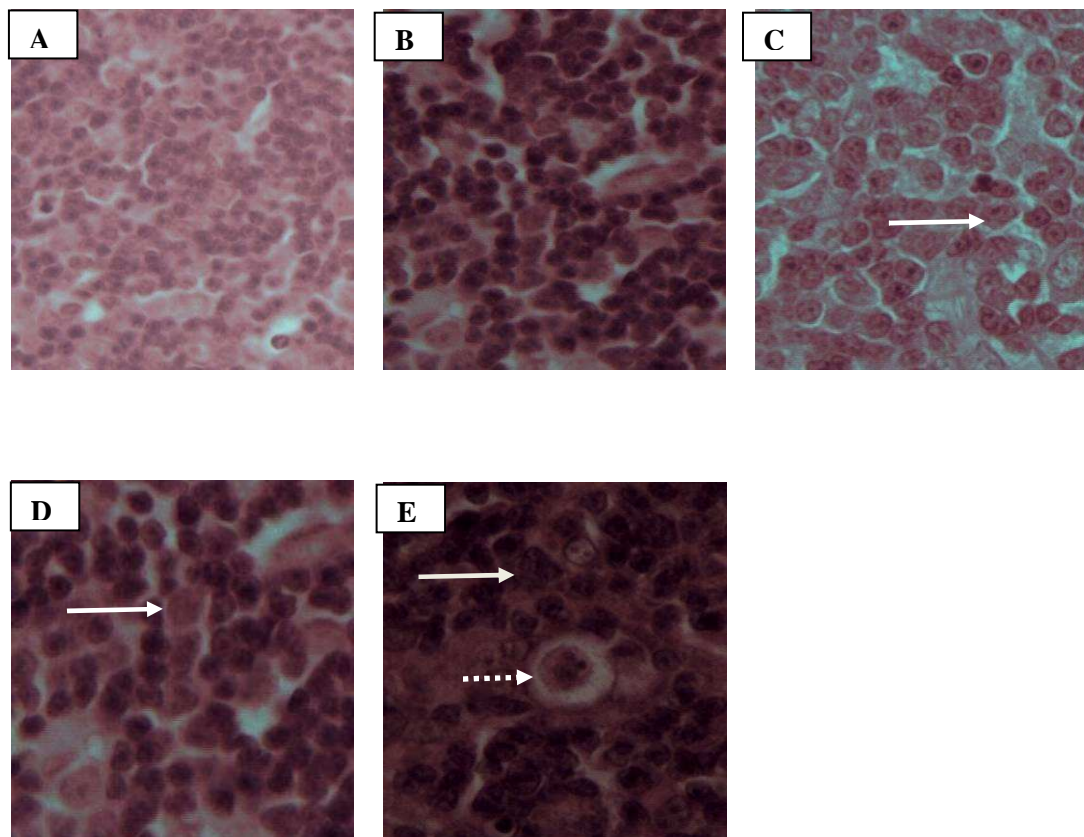
### Histology of the thymus: low magnification



**Figure 6a. Key: Key:** A= Control group of rats; B = low dose ( $50\text{mg. kg}^{-1}$ ) aqueous extract group; C= high dose ( $500\text{mg. kg}^{-1}$ ) aqueous extract group; D= low dose ( $50\text{mg. kg}^{-1}$ ) alcohol extract group; E= AlcH= high dose ( $500\text{mg. kg}^{-1}$ ) alcohol extract group. This figure is a digital photograph of Hematoxylin and eosin stained sections (40X magnification) of the thymus of suckling rats (14 days old) following the various treatments. The reduction in the size of the cortex is notable in the rats administered the *Aloe vera* extracts (B-E) compared to the control (A).

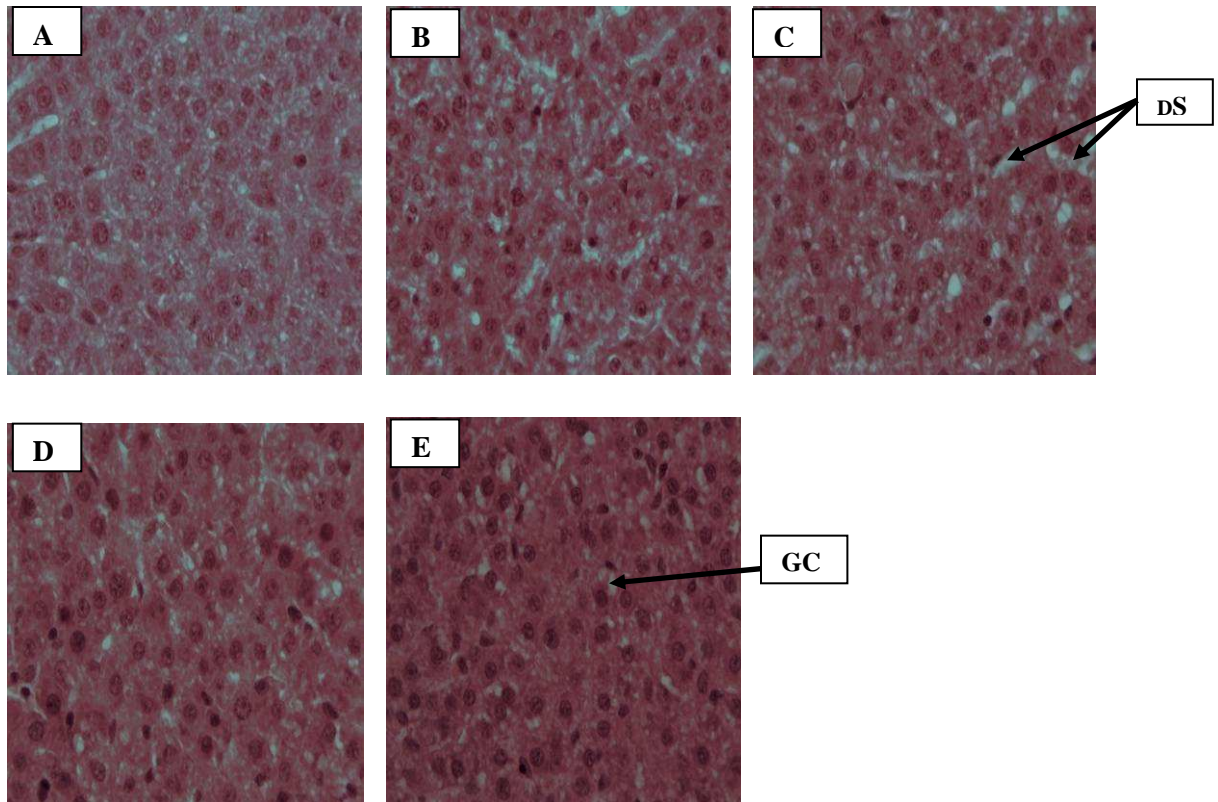
— Bar =100  $\mu\text{m}$

## Histology of the thymus: high magnification



**Figure 6b. Key:** A= Control group of rats; B = low dose ( $50\text{mg. kg}^{-1}$ ) aqueous extract group; C= high dose ( $500\text{mg. kg}^{-1}$ ) aqueous extract group; D= low dose ( $50\text{mg. kg}^{-1}$ ) alcohol extract group; E= AlcH= high dose ( $500\text{mg. kg}^{-1}$ ) alcohol extract group. This figure is a digital photograph of Hematoxylin and eosin stained sections (400X magnification) of the thymus suckling rats (14 days old) following the various treatments. The arrows (solid ) show the significant increase in cell size in the rats administered *Aloe vera* compared to control, and the presence of Hassall's corpuscles in the rats administered high dose of the extracts (dashed arrow).

## Histology of the liver



**Figure 7.** Key: **Key:** A= Control group of rats; B = low dose ( $50\text{mg. kg}^{-1}$ ) aqueous extract group; C= high dose ( $500\text{mg. kg}^{-1}$ ) aqueous extract group; D= low dose ( $50\text{mg. kg}^{-1}$ ) alcohol extract group; E= AlcH= high dose ( $500\text{mg. kg}^{-1}$ ) alcohol extract group. This figure is a digital photograph of Hematoxylin and eosin stained sections (400X magnification) of liver sections from suckling rats (14 days old) following 8 days of the various treatments. The presence of hepatocytes with clear cells membranes and enlarged nuclei, granular cytoplasm ( $\rightarrow\text{GC}$ ) and dilated sinusoids ( $\rightarrow\text{DS}$ ) is notable in the rats exposed to the *aloe vera*.

# **Chapter 4 – Discussion**

This study investigated the effects of *Aloe vera* extracts administered for 8 days orally as a dietary supplement to suckling rats. It was found that *Aloe vera* extracts had an effect on the growth performance (as measured by body mass gain and tibial length), the caecum and the thymus of the rats.

These results showed that orogastrically administered *Aloe vera* extracts for a period of 8 days, had a strong growth promoting effect in suckling rats. Heidi *et al.*, 1984 found that the rate of growth and development of rat pups can be greatly altered by varying supplements administered to them during the suckling period.

The tibial length has been used in a number of studies as a more accurate indicator of linear growth instead of the body mass which may be influenced by various factors including food intake and hydration status thus making body mass a less reliable measure (Eshet *et al.*, 2004).

The increased tibial length could be as a result of an increase in metaphyseal bone tissue and mineralization (Cho *et al.*, 2001). An increase in bone mineralisation should have resulted in an increased bone density of the tibias from the rats exposed to the high doses of *Aloe vera* extracts; however I found that the tibial mass was not significantly affected by the exposure to *Aloe vera* extracts.

To further explore the growth effects the plasma was assayed for the hormone IGF-1 which plays an important role in the regulation of bone homeostasis throughout life and mediates most of the effects of growth hormone on skeletal metabolism (Baroncelli *et al.*, 2003). The results did not reveal any significant difference between the groups. Thus the mechanisms underlying the increased growth performance of the rats exposed to the *Aloe*



*vera* need to be explored further, by microscopic examination of the bone growth plates and assay of other growth promoting hormones.

The GIT of neonates is relatively immature and still requires morphological and functional changes. In the neonatal period, pups have to adapt to the new stressful environments and subsequently have to face the transition from a milk diet to solid feed diet at weaning. During this time, the GIT and skeletal systems among others, undergo changes that are induced by a number of factors (Baintner *et al.*, 2007). Among them, nutrients play a crucial role in the development and adaptation of the GIT which determines its proper functioning (Luckey *et al.*, 1954). At weaning, the GIT function is often disturbed and diarrhoea develops thus causing body weight losses and in some cases the pups die hence the intestinal requirements and cellular demands for metabolic energy supply increases during this period. The intestine undergoes an array of adaptative changes during post natal development which is similar to other organs. In the intestinal mucosa, these changes occur in structures related to the exchange and absorption processes such as villi, crypts, enterocytes and microvilli. Assessment of morphological changes can be used in the diagnosis and assessment of intestinal pathology (Weser and Tawil 1976, Isukura *et al.*, 1992).

In this study, it has also been found that no significant changes occurred in the gross morphometry of the small and large intestines other than the caecum. Histologically, the intestinal morphology appeared to be normal with no evidence of pathophysiological changes. The villus length was not different between rats which received the *Aloe vera* treatment, compared to the control group. Due to the rapid turnover of epithelial cells in the GIT, dietary manipulations rapidly manifest in morphological changes (Pacha,2000),

thus the effects of *Aloe vera* on the small intestine if any should have been visible. I did not however test the function of the intestine in terms of its absorptive and secretory capacity. So although there was no effect on the morphology, the function of the GIT could have been affected. Future studies should also investigate the effects of *Aloe vera* on apoptosis in the GIT. Intestinal maturation has also been related to either bacterial flora or the presence of food antigens and it may be followed by a period of immune-suppression leading to a final stabilization of cell production at adult levels (Pacha, 2000).

The caecum mass was significantly increased in the rats exposed to *Aloe vera*, the increase in mass was as a result of hypertrophic and hyperplastic changes in the various layers of the caecal wall. Erlwanger and Cooper (2008), in a study in which suckling rats were administered extracts from the African potato (*Hypoxis hemerocallidea*) also found an increased caecal mass as the only morphological change in the GIT of the suckling pups. Dietary manipulation as well as the presence of osmotically active or fermentable substances that are not absorbed from the small intestine may affect the GIT flora and influence caecum weight (Baltrop and Brueton, 1990). An increase in caecal volume could be also have been due to the presence of complex carbohydrates in the Aloe extracts resulting in the development of the flora which affects the production of volatile fatty acids and pH and improved divalent cation digestibility in rats (Reddy, 1971). The role of growth factors in cell proliferation and in cell migration (Podolsky, 1993; Dignass and Lynch-Devaney, 1995) should not be excluded as an explanation for the increased caecal mass.

The liver is the primary site of detoxification of many substances in the body and the major site of intense metabolism, and is therefore prone to various disorders as a consequence of exposure to toxins of extrinsic as well as intrinsic origin (Gaskill *et al.*, 2004). In the liver, ALT and ALP are enzymes that help to metabolize proteins. When the liver is damaged, ALT and ALP are increased and released into the bloodstream. There was no significant difference in the circulating concentrations of ALT in the different group of rats, suggesting an absence of liver damage. Previous studies have suggested that Aloe-emodin could be responsible for the hepato-protection in rats as shown by reduction in the elevation of ALT in rats exposed to emodin (Woo *et al.*, 2002). However, the ALP levels were significantly elevated in the rats exposed to the high dose of alcohol extracts of *Aloe vera*. ALP elevations are usually associated with bile duct damage/bile stasis. The decreased sinusoids in the rats exposed to the high dose of *Aloe vera* extracts could have resulted in bile stasis.

ALP is a non hepatic specific enzyme also released from bone following pathology or excessive remodelling as during rapid growth. I used growing rats, and the rats given the high dose of alcohol extracted extracts showed the greatest bone growth, which could help explain the high ALP levels in their blood. The ALP activity in rat serum is well known to be higher than other mammalian species, and to be further increased after fat feeding (Iwao *et al.*, 1987). Most of the serum ALP in adult rats originates from the duodenal mucosa which appears to contain two isoforms of the enzyme (Koyama *et al.*, 1987). The ALP in the plasma can also be elevated by the introduction of milk feeding which has been shown to induce activity of a specific isoenzyme (Dziedziejko *et al.*,

2005). Due to unavailability of equipment, it was now possible to identify the specific isoenzyme(s) of ALP in the rat blood that was assayed.

The increase in mass of the thymus may reflect it having been stimulated. *Aloe vera* extracts reportedly have beneficial effects in the management of HIV&AIDS where they serve as an immune booster for those who are unable to afford the anti-retroviral medication (Kim *et al.*, 2007). This is attributed to anti-viral and immuno-modulating properties of acemannan (mucopolysaccharides) which have direct effects on cells of the immune system, activating and stimulating macrophages, monocytes, antibodies and T-cells. Acemannan acts as a bridge between foreign proteins, such as virus particles, and macrophages and facilitates phagocytosis (Anderson, 1983).

The thymus can also atrophy during conditions of nutritional stress. Pallaro *et al.* (2001) regarded the thymus as an “early critical barometer of nutrition” and reported the effects of different degrees of malnutrition on the thymolymphatic organs. Dourov (1986) was the first to describe the severe atrophy of the thymus seen at autopsies of children who had died of Kwashiorkor and noted the replacement of normal tissue by interlobular and perilobular connective tissues infiltrated with large lipid cells. The lack of protein or calories seem to be essential in this pathogenesis. Rats that consume legumes as their only source of protein have also been shown to develop atrophy of the lymphoid organs (thymus and spleen) with altered histology, decreased organ weight, fewer rosette-forming cells and splenic lymphocyte responses to mitogens (Huisman *et al.*, 1990; Toro *et al.*, 2004). In my study the thymus was increased in mass in rats exposed to *Aloe vera* and in high doses the increased presence of Hassall’s corpuscles was observed. Hassall’s

corpuscles are lymphocytes that may be interpreted as an expression of a changing thymic growth pattern in confined spaces and seem to have little immunological function.

The liver also plays an important role in metabolism to maintain energy levels (Aitken *et al.*, 2001). The blood concentration of glucose in young rats is maintained fairly at a fairly constant level from 2 to 20 days after birth. This is probably due to the difference in floral colonization of the gut between the 18-day-old suckling rat, whose diet is predominately milk and different to the adults whose diet contains both milk and solid high-carbohydrate rat diet (Innis, 1985). The glucose level in non fasting blood after 8 days of treatment with *Aloe vera* extracts did not show any significant differences between the groups. This may be the evidence that the *Aloe vera* extracts did not alter the endocrine pancreatic function, which has an indirect influence on the blood glucose levels.

It has been shown that the amount of free fatty acids taken up by the liver of rats (Poli *et al.*, 1987) is directly proportional to the concentration of free fatty acids in the plasma. Fatty acids will accumulate unless compensatory increases in rates of outputs of fatty acids in plasma lipoprotein or rates of oxidation to CO<sub>2</sub> and ketone bodies occur (Erol *et al.*, 2003). Fatty liver is a metabolic disorder that occurs when the rate of fatty acid uptake and esterification exceeds the rate of fatty acid depletion either through oxidation or export as triglyceride within very low density lipoproteins. The rats exposed to the high dose of alcohol *Aloe vera* extracts showed the greatest accumulation of lipids in the

liver, however the lipids were not profiled so the metabolic processes underlying the increased accumulation could not be fully ascertained.

The results of this study on suckling rats concur with findings from other studies which revealed the beneficial effects of *Aloe vera* extracts administration over a short period of time. There is however a need to explore further the mechanisms of improved growth performance, the significance of the increased thymus mass and the changes in caecal morphology noted as a result of exposure of the suckling rats to the *Aloe vera* extracts.

# **Chapter 5 – Conclusion and recommendations**

## **Conclusion and recommendations**

Herbal medicines are widely used in almost all sectors of the population. This study has shown that *Aloe vera* extracts administered orally to suckling rats had a positive effect on the body mass, caecum and bones. These positive effects could be useful in preventing weight loss during the weaning period of pups and bone disturbances during the development of fast growing animals. The present study's findings confirm that *Aloe vera* extracts could have a beneficial effect at least in the short term.

Further studies should be undertaken for a longer period of time in order to determine the reversibility and functional significance of the significant findings observed in the rats.

The increased growth of the animals exposed to the *Aloe vera* extracts should be explored further, by assaying for other growth promoting hormones and microscopic examination of the growth plates. The degree of bone mineralization and density should also be evaluated using DEXA-scans.

The increased body mass gain observed in the rats given *Aloe vera* could be exploited commercially in animal production to improve growth in farm animals. This study involved the use of crude extracts, future studies should be undertaken to identify the specific chemical components of *Aloe vera* which produced the significant differences such as caecal and thymic enlargement. Future studies should also make use of sugar solutions with mineral and vitamin supplements as a control solution to match the nutritional composition of plant extracts so that any differences can be attributed to the phytochemicals in the extracts. Herbal medicines although being



widely used, should be used cautiously and after thorough scientific interrogation of their active constituents as they can contain harmful compounds and metabolites.

# Chapter 6 – References

# References

- Aitken, M.M., Hall, E., Scott, L., Davot, J.L., Allen, W.M. (2001) Liver-related biochemical changes in the serum of dogs being treated with phenobarbitone. *Veterinary Record*, 153: 13-16.
- Ajabnoor, M.A. (1990) Effect of *Aloes* on the blood glucose levels in normal and alloxan diabetic mice. *Journal of Ethnopharmacology*, 28: 215-220.
- Ali, M.I., Shalaby, N.M., Elgamal, M.H., Mousa, A.S. (1999) Antifungal effects of different plant extracts and their major components of selected *Aloe* species. *Phytotherapy Research*, 13: 401-7.
- Anderson, B.C. (1983). *Aloe vera* juice: A veterinary medicament? *The compendium on continuing Education for the practicing Veterinarian*, 5: 364-368.
- Amusan, P.S., Dlamini, J.D., Msonthi, Makhubu, L.P. (2002) Some herbal remedies from Manzini region, Swaziland. *Journal of Ethnopharmacology* 79, 109-112.
- Arnold, Koldosky, O., Palanch, A.C. (2002) Medicinal and magical plants of Southern Africa: An annotated checklist, National Botanical Institute, Pretoria.
- Bain, P.J., Latimer, K.S., Mahaffey, E.A., Prasse, K.W., Duncan and Prasse's, (2003) Liver. *Veterinary Laboratory Medicine: Clinical Pathology*, fourth edition. Ames, Iowa State Press 193-214.
- Baintner, K., Zabielski, R., Gregory, P.C., Westrom, B. ( 2007) Vacuolation in the young and the intestine in Growing Animals, first edition, Amsterdam: Elsevier Science, 70, 55-110.

- Baltrop and Brueton, T. M. (1990) The gastrointestinal tract and short term toxicity tests.  
In: P. J., Bordeau, Editor, Short-term Toxicity Tests for non-genotoxic  
Effects, John Wiley and Sons Ltd 99-110.
- Baroncelli, G.I., Bertelloni, S., Sodini, F., Saggese, G. (2003) Acquisition of bone mass  
in normal individuals and in patients with growth hormone deficiency.  
*Journal of Pediatrics and Endocrinology Metabolism* 16: 327-335.
- Baumann, G., (1991) Growth Hormone heterogeneity. Genes, Isohormones, variants and  
binding protein. *Endocrine Reviews*, 12: 424-449.
- Beppu, H., Shimpo, K., Kutchuno, M. (2006) Antidiabetic effects of dietary  
administration of *Aloe arborescens* Miller components on multiple low-  
dose streptozotocin- induced diabetes in mice: investigation on  
hypoglycaemic action and systemic absorption dynamics of *Aloe*  
components. *Journal of Ethnopharmacology*, 103: 468-477.
- Bligh, E.G. and Dyer, W.J. (1959) A rapid method of total lipid extraction and  
purification. *Canadian Journal of Biochemistry and Physiology* 37: 911-  
917.
- Blumenthal, M., Gruenwald, J., Hall, T., Rister, R.S. (1998) The complete German  
Commission E Monographs. Austin, Texas: American Botanical Council  
111: 556-569.
- Blumenthal, M., Busse, W.R., Goldberg, A. (1998) The complete commission  
monograph: therapeutic guide to herbal medicine. Integrative Medical  
Commission, Boston 80-87.

- Boudreau, M.D. (2006) An evaluation of biological and toxicological proprieties of *Aloe Barbadensis* (Miller), *Aloe vera*. *Journal of Environmental Sciences Health* 24: 103-154.
- Brian, K.R., Turner, T.D. (1975) The practical evaluation of phytopharmaceuticals. Wright-Scientechnica, Bristol, first edition, 90.
- Bruneton, J. (1995) Pharmacognosy, Phytochemistry, Medical Plants; 434-436. England, Intercept, Hampshire.
- Bryant, A.T. (1970) Zulu medicine and medicine men. *Annals of the Natal Museum*, 2: 1-103.
- Buddington, R.K., Lepine, A.J. (1999) Exocrine Pancreatic Functions of Carnivores. In: Biology of Pancreas in Growing Animals. Pierzynowski, S.G. and R.Zabielski (Eds.). Elsevier Science BV 409-422.
- Butler, L.K. (1995) Regulation of blood glucose levels in normal and diabetic rats, *in* tested studies for the laboratory teaching volume 16. Proceedings of the 16th Workshop/Conference of the Association for Biology Laboratory Education (ABLE), Austin, Texas. 181-202.
- Can, A., Akev, N., Ozsoy, N., Bolkent, S., Arda, B.P., Yanardag, R., Okyar, A. (2004) Effect of *Aloe vera* leaf gel and pulp extracts on the liver in type-II diabetic rat models. *Biological and Pharmaceutical Bulletin*, 27: 694-8.
- Chandan, B.K., Saxena, A.K., Shukla, S., Sharma, N., Gupta, (2007) Hepatoprotective potential of *Aloe Barbadensis* Mill, against carbon tetrachloride induced hepatotoxicity. *Journal of Ethnopharmacology*, 111: 560-566.

Cheney, R.H. (1970) *Aloe vera* Drug in Human therapy. Quarterly. *Journal Crude Drug Resources*, 10: 1523-15.

Choi,S., Kim, K.W., Choi, J.S, Han,S.T., Park,Y.I., Lee,S.K., Kim, J.S. and Chung, M.H.(2002) Angiogenic activity of beta-sitosterol in the ischaemia/ reperfusion-damaged brain of Mongolian gerbil.Department of pharmacology, Seoul National University college of medicine, Seoul, Korea. *Planta Medica*, 68: 330-5.

Cho, I .H, Ahn, J.H., Chung, C.Y., Yoo, W.J., Sung, H.Y. (2001) Expression of vasculoendothelial growth factor in distraction osteogenesis of rat tibia. *Journal of Korean Orthopeutic Resources*, 4: 114-20.

Chung, J.H., Cheong J.C., Lee, J.Y., Roh, H.K., Cha, Y.N. (1997) Acceleration of the alcohol oxidation rate in the rats with aloin, a quinine derivative of *Aloe*. *Bio-Pharmacology* 52: 1461-1468.

Crouch, N., Symmonds, R., Spring, W., Diederichs, N. (2006) Fact sheets for growing popular medicinal plant species. In: N. Diederichs, Editor, *Commercialising Medicinal Plants—A Southern African Guide*, Sun Press, Stellenbosch. 97–142.

Cummins, A .G., Steele, T.W., Labrooy, J.T., Shearman, D.J.C. (1988) Maturation of the rat small intestine at weaning: Changes in epithelial cell kinetics, bacterial flora and mucosal immune activity. *Gut*, 29: 1672-9.

Davis, H.R. (1993) Biological activity of *Aloe vera*. *The SOFW-Journal*, 119: 647-649.

- Davis, R.H., Donate, J.J., Hartman, G.M. (1994) Anti-inflammatory and wound healing activity of growth substance in *Aloe vera*. *Journal of the American Podiatric Medical Association* 84: 77-81.
- Dignass, A.V., Lynch-Devaney, K. (1995) Hepatocyte growth factor/Scatter factor modulates intestinal epithelial cell proliferation and migration. *Biochemical and Biophysical Research Communication*, 202: 701-709.
- Djeraba, A., Quere, P. (2000) In vivo macrophage activation in chickens with Acemannan, a complex carbohydrate extracted from *Aloe vera*. *International Journal Immunopharmacology*, 22: 365-72.
- Dold, T., Cocks, M. (2000) The iNtelezi plants of the Eastern Cape: traditional and contemporary medicines. *Aloe*, 37: 10-13.
- Dourov, N. (1986) Thymic atrophy and immune deficiency in malnutrition In: Muller H.K, first edition. The human thymus. Histopathology and pathology. Berlin; Springer-verlag: 127.
- Dunn, J.T. (2002): Editorial: guarding our nation's thyroid health. *Journal of Clinical Endocrinology and Metabolism* 87: 486-488.
- Dziedziejko, V., Safranow, K., Slowik-Zylka, D., Machoy-Mokrzynska, M., Machoy, Z., Chlubek, D.(2005) Comparison of rat and human alkaline phosphatase isoenzymes and isoforms using HPLC and electrophoresis. *Biochimica et Biophysica Acta (BBA) - Proteins & Proteomics*. 1752: 26-33.
- Erol, E., Kumar, L.S., Cline G.W., Shulman, G.L., Kelly, D.P., Binas, B. (2004) Liver fatty acid-binding protein is required for high rates of hepatic fatty acid

oxidation but not for the action of PPAR- $\alpha$  in fasting mice. *The FASEB Journal*, 18: 347-349.

Erlwanger, K.H., Cooper, R.G. (2008) The effects of orally administered crude alcohol and aqueous extracts of African potato (*Hypoxis hemerocallidea*) corm on the morphometry of viscera of suckling rats. *Food and Chemical Toxicology*, 46: 136-139.

Eshet, R., Maor, G., Ari, B.T., Eliezer, B.M., Gatyablonski, G., Phillip, M. (2004) The aromatase inhibitor letrozole increases epiphyseal growth plate height and tibial length in peripubertal male mice. *Journal of Endocrinology* 182: 165-172.

Esua, M.F., Rauwald, J.W. (2006) Novel bioactive maloyl glucans from *Aloe vera* gel: isolation, structure elucidation and in vitro bioassays. *Carbon Resource* 27: 355-364.

Fermentia, A., Sanchez, E.S., Simal, S., Rosselo, C. (1999) Compositional features of polysaccharides from *Aloe vera* (*Aloe vera barbadensis* Miller) plant tissues. *Carbohydrates Polymerases*, 39: 109-17.

Fulton, J.E.J.R., (1990) The stimulation of post dermabration wound healing with stabilized *Aloe vera* Gel-poly ethylene oxide dressing. *Journal of Dermatology and Surgical Oncology*. 16: 460-467.

Gaskill, C.L., Hoffmann, W.E., Cribb, A.E. (2004) Serum alkaline phosphatase isoenzyme profiles in Phenobarbital-treated epileptic dogs. *Veterinary Clinical Pathology*. 33: 215-222.



- Gama, P., Alvares, E.P. (2000) Early weaning and prolonged nursing induce changes in cell proliferation in the gastric epithelium of developing rats. *American Society for Nutrition Sciences*. 130: 2594-2598.
- Gelfand, R.B., Drummond, S., Madera, B. (1885) The traditional medical practitioner in Zimbabwe: Principles of practice and pharmacopolia, Mambo Press, Gweru.
- Ghannam, N., Kingston, M., Al-Mechaal, I.A. (1986) The antidiabetic activity of *Aloe vera* L, Juice.II.Clinical trail in diabetes mellitus patients in combination with glibenclamide. *Phytomedicine*. 3: 245-248.
- Githens, T.S. (1979) Drug plants of Africa, University of Pennsylvania Press, Philadelphia.
- Gore, M.T, Young, R. B., Claeys, M. C., Chromiak, J. A., Rahe, C. H., Marple, D. N., J.D., Hough, Griffin, J. L., Mulvaney, D. R. (1994) Growth and development of bovine fetuses and neonates representing three genotypes *Journal of Animal Sciences*. 72: 2307-2318.
- Grindlay, D., Reynolds, T. (1986) The *Aloe vera* Phenomeno: A review of the proprieties and modern uses of the leaf parenchyma gel. *Journal of Ethnopharmacology*, 16: 117-151.
- Guyton, A, C., J, E., Hall and Jackson, (2006) Text book of Medical Physiology, 11<sup>th</sup> edition, Elsevier, USA.

- Hart, L.A., van Enkevort, P.H., van Dijk, H., Zaat, R., de Silva, K.T., Labadie, R.P. (2009) Two functionally and chemically distinct immunomodulatory compounds in gel of *Aloe vera*. *Journal of Ethnopharmacology*, 23: 61-71.
- Heggens, J.P., Robson, M.C., Manavalan, K. (1996) Experimental and clinical observations on frostbite. *Annals of Emergency Medicine*, 16: 1056-1062.
- Heidi, H., Swanson, Bolwerk, E., Bremmer, E. (1884) Effects of couling in infant rats on growth, maturation, sleep patterns and responses to food deprivation. *British Journal of Nutrition*, 52: 139-148.
- Heneghan, J.B. (1984) Physiology of the alimentary tract. In: *The germ-free Animal in Biomedical Research* (Coates ME, Gustafsson BE, eds). London. Laboratory Animals Ltd 169-92.
- Hochberg, Z., Bick, T., Harel, Z. (1990) Alterations of human growth hormone binding by rat liver membranes during hypo- and hyperthyroidism. *Journal of Endocrinology*, 126: 325-9.
- Huisman, J., vander Pod, A., Mouwen, J., Van weerden, E. (1990) Effect of variable protein contents in diets containing *Phaseolus vulgaris* beans on performance, organ weights and blood variables in piglets, rats and chickens. *British Journal of Nutrition*, 64:755.
- Huggins, K.W., Camarota, L.M., Howles, P.N. and Hui, D.Y. (2003) Pancreatic triglyceride lipase deficiency minimally affects dietary fat absorption but dramatically decreases cholesterol absorption in mice. *The Journal of Biological Chemistry*, 278: 42899-42905.

- Hutchings and Robson, M.C. (1996) Zulu medicinal plants: An inventory, University of natal press, Pietermaritzburg, University of Zululand/National Botanical Institute, Pietermaritzburg/ Kwa Dlangezwa/Cape town.
- Innis, S.M. (1985) The role of diet during development on the regulation of adult cholesterol homeostasis. *Canadian Journal of Physiology and Pharmacology*, 63: 557-564.
- Isukura, M., Evers, M., Parikh, D. (1992) Neurotensin augments intestinal regeneration after small bowel resection in the rat. *Annals of Surgery*, 125:520-5.
- Iwao, K., Kyoko, A., Yoshikatsu, S., Hiroh, I., Tsugikazu, K. (1987) Blood appearance of rat alkaline phosphatase originating from duodenum in vitro. *The Journal of Chromatography*, 420: 275-286.
- Johson T. (1999) *Rc Ethno Botany* Desk reference, C.R.C, Press, Bocca Raton.
- Kallaya, E., Suthiluk, P., Naruemon, V., Duangporn, Thong-N. (2006) Effects of *Aloe vera* and sucralfate on gastric microcirculatory changes, cytokine levels and gastric ulcer healing in rats. *World Journal of Gastroenterology* 12: 2034-2039.
- Kandil, A., Gobran, W. (1982) Protection of gastric mucosa by *Aloe vera*. *Bulletin of Islamic Medicine*, 2: 503-511.
- Kim E.J., Kim, H.J., Kim, S.G., Lee, Y.S., Oh, J.E., Seo, J.W., Koo, J.R., Noh, J.W., (2007). *Aloe* induced Henoch-Schonlein Purpura. *Nephrology (Carlton)*, 12: 109.

- Koyama, I.K., Arai, Y., Sakagishi, H., Ikezawa, T., Komoda, (1987) Blood appearance of rat Alkaline phosphatase originating from the duodenum in vitro, *Journal of Chromatography*, 420: 275-286.
- Lahey, J. (2009) "Digestion- how the small intestine digests food." 16 Aug. Ezine Articles.com.
- Langmead, L., Makins, R.J., Rampton, D.S. ( 2004) Anti-inflammatory effects of *Aloe vera* gel in human colorectal mucosa in vitro. *Aliment of Pharmacology Therapy*, 19: 521-527.
- Lairon, D., Play, B., Jourdeuil-Rahmani, D. (2007) Digestible and indigestible carbohydrates: interactions with postprandial lipid metabolism. *Journal of Nutritional Biochemistry*, 18: 217-227.
- Leffers, A., Gembok, B., Kalahari, T. (2003) Traditional plant use by the Jul'hoansi in Northern-Eastern Namibia, Gamsberg Macmillan, Windhoek.
- Leung, M.Y., Liu, C., Koon, J.C., Zhu, L.F., Hui, Y.Z, Yu, B., Fung, K.P. (2004) Macrophage activation by polysaccharide biological response modifier isolated from *Aloe vera* L. Var. *Chinensis* (Haw.) Berg. *International Journal of Immunopharmacology*, 6: 1634-41.
- Linderoth, A., Prykhod'ko, O., Pierzynowski, S.G., Weström, B.R. (2006) Enterally but not Parenterally Administered *Phaseolus vulgaris* Lectin Induces Growth and Precocious Maturation of the Gut in Suckling Rats. *Biology of the Neonate*. 89:60-68.
- Luckey, T.D., Mende, T.J., Pleasants, J. (1954) The physical and chemical

- characterisation of rat milk *Journal of Nutrition* 54, 345-359.
- Lynch, C.D., Lyons, D., Khan, A., Bennett, S.A., Sonntag, W.E. (2001) Insulin-like growth factor-1 selectively increases glucose utilization in brains of aged animals. *Endocrinology*. 142: 506-9.
- Mahattanadul, (1996) Antigastric ulcer properties of *Aloe vera*. *Songklanakarinn Journal of Sciences and Technology* 18, 49-57.
- Maliehe, E.B. (1997) Medicinal plants and herbs of Lesotho. Mafeteng Development Project, Maseru.
- Marini, I. (2004) Discovering an Accessible Enzyme: Salivary  $\alpha$ -Amylase. *Biochemistry and Molecular Biology Education*, 33: 112-116.
- Massimo, M. (2003) Dietary supplements of plant origin: a nutrition and health approach. Taylor Francis, London, 9-12.
- Matsuda, Y., Yokohira, M., Suzuki, S. (2008) One –year chronic toxicity study of *Aloe arborensiens Miller var. natalensis* Berger in Wistar Hannover rats. A pilot study. *Food Chemistry and Toxicology*, 46: 733-739.
- Matsuo, K., Yamashita, S., Niwa, M., Kurihara, M., Harakawa, S., Izumi, M., Nagataki, S., Melmed, S. (1990) Thyroid hormone regulates rat pituitary insulin-like growth factor-1 receptors. *Journal of Endocrinology*, 126: 550-4.
- Mills, N.C., D'ercole, A.J., Underwood, L.E and Ilan., J. (1986) Synthesis of somatomedin C/insulin-like growth factor I by human placenta. *Molecular Biology Reports*, 11: 231-236.

- Moon, E.J., Lee, Y.M., Lee, O.H. (1999) A novel angiogenic factor derived from *Aloe vera* gel: beta- sitosterol, a plant sterol. *Angiogenesis* 3, 117-123.
- Pacha,J. (2000) Development of intestinal transport function in mammals. *Physiology Reviews*, 80: 1633-1667.
- Paeza, A., Michael Gebreb, G., Gonzaleza, M.E., Tschaplinski, T.J. (2009) Growth, soluble carbohydrate and aloin concentration of *Aloe vera* plants exposed to three irradiance levels. *Environmental and Experimental Biology*, 44: 133-139.
- Pallaro, A.N., Roux, M.E., Slobodianik, N.H. (2001) Nutrition disorders and immunologic parameters: study of thymus in growing rats. *Nutrition*, 17: 972-973.
- Panda, H., 2000 *Aloe vera* hand book cultivation, research findings, products, formulation, extraction and processing. Asia Pacific Business Press, India. .
- Pari, L., Venkateswaran, S. (2004) Protective Role of Phaseolus vulgaris on Changes in the Fatty Acid Composition in Experimental Diabetes. *Journal of Medicinal Food* 7, 204-209.
- Passonneau, J.V., Lauderdale, V.R. (1974) A comparison of three methods of glycogen measurement in tissue. *Analytical Biochemistry*, 60: 405-412.
- Peng, S.Y., Norman, J., Curtin, G., Corrier, D., Mc Daniel, H.R., Busbee, D. (1991) Decreased mortality of norman murine sarcoma in mice treated with the immunomodulator, Acemannan. *Molecular Biotherapy*, 3:79-87.

- Pierzynowski, S.G., Botermans, J.A.M. (1999) Relations between body live weight, feed intake, daily weight gain and pancreatic exocrine secretion in growing pigs. *Journal of Animal Sciences*, 77: 450-456.
- Poli, G., Albano, E., Dianzani, M.U. (1987) The role of lipid peroxidation in liver damage. *Chemistry and Physics of Lipids*, 45: 117-142.
- Podolsky, D.K. (1993) Regulation of intestinal epithelial proliferation: a few answers, many question. *American Journal of Physiology*, 264: G179-G186.
- Ramachandra, C.T., Srinivasa, R. P. (2008) Processing of *Aloe vera* leaf Gel: A review *American Journal of Agricultural and Biological Sciences*, 3: 502-510.
- Ranke, M.B. (2003) Diagnosis of growth hormone deficiency and growth hormone stimulation tests. In; *Diagnostics of endocrine function in children and adolescents* (third edition) Basel, Karger , pp107-128.
- Reddy, B.S. (1971) Calcium and magnesium absorption: role of intestinal microflora-feeding. *Federation Proceedings*, 30: 1815-1821.
- Reuter, J., Jocher, A., Stump, J., Grossjohann, B., Franke, G., Schempp, C.M. (2008) Investigation of the anti-inflammatory potential of *Aloe vera* Gel (97.5%) in the ultraviolet erythema test. *Skin Pharmacology and Physiology* 21: 106-110.
- Reynolds, T., Dweck, A.C. (1999) *Aloe vera* leaf gel: a review up date. *Journal of Ethnopharmacology*, 15: 3-37.
- Reynolds, J.W. (1950) *The Aloes of South Africa*. The Trustees of Aloes of South Africa book fund, Johannesburg, South Africa.

- Robert, A., Nezamis, J.E, Lancaster, C, Hamchar, A.J. (1979) Cytoprotection by prostaglandins in rats. *Gastroenterology*, 77: 433-443.
- Sa, I.M., Oh, S.T., Song, S., Kim, M.R., Kim,D.S., Woo, S.S., Jo, T.H., Park, Y.I., Lee, C.K. (2005) Identification of optimal molecular size of modified Aloe polysaccharides with maximum immunomodulatory activity. *International Immunopharmacology*, 5 : 271-9.
- Saito, H., Imanishi, K., Okabe, S. (1989). Effects of *Aloe* extracts, Aloctin A, on gastric secretion and on experimental gastric lesions in rats. *Yakugaku Zasshi*, 109: 335-9.
- Sakai, T., Repko, B.M., Griffith, B.P., Waters, Kameneva, M.V. (2006) Infusion of a drag-reducing polymer extracted from *Aloe vera* prolonged survival time in a rat model of acute myocardial ischaemia, *British Journal of Anaesthesia*, 98 : 23-8.
- Saleem,R., Faizi, S., Siddiqui, B.S., Ahmed, M.,Hussain, S.A., Qazi, A., Dar, A.,Ahmad, S.I., Qazi, M.H., Akhtar, S., Hasnain, S.N. (2001) Hypotensive effect of chemical constituents from *Aloe barbadensis*. *Planta Medica*, 67: 757-60.
- Shah,A.H., Qureshi, S., Tariq, M., Angeel, A.M. (1989) Toxicity studies on six plants used in the tarditional arab system of medicine. *Phytotherapy Reactions*, 3: 25-29.
- Sorensen, A., Mayntz, D., Simpson, S.J., Raubenheimer, D. (2009) Dietary ration of protein to carbohydrate induces plastic responses in the gastrointestinal tract of mice. *Journal of Physiology*, 180: 259-266.



- Steenkamp, V., Stewart, M.J. (2007) Medicinal applications and toxicological activities of *Aloe* Products. *Pharmaceutical Biology*, 45: 411-420.
- Stepanova, O.S., Prudnick, N.Z., Soloviera V.P., Golovchenko G.A., Svischchuk, A.A., Dubkova, O.M. (2007) Chemical composition and biological activity of dry *Aloe* leaves. *Fiziologicheski Aktivnye Veshchestva*, 9: 94-97.
- Strasburger, C.J. (2004) Commentary: Taking one step at a time. *Clinical Endocrinology*, 60: 540-.
- Strader, A.D., Woods, S.C. (2005) Gastrointestinal Hormones and food intake . *Journal of Gastroenterology*, 128: 175-91.
- Stuart, R.W., Lefkowitz, D.L., Lincoln, J.A., Howard, K., Gelderman, M.P., Lefkowitz, S.S. (1997) Up regulation of phagocytosis and Candidicidal activity of macrophages exposed to the immunostimulant acemannan. *International Journal of Immunopharmacology*, 19: 75-82.
- Susana, A. (2010) *Aloe vera* juice: A Natural source of vitamins and minirals. Ezine Articles.com ([Http// ezine articles.com/ Aloe vera juice –a natural source of vitamins and minerals &id=3691- 620](http://ezinearticles.com/Aloe-vera-juice-a-natural-source-of-vitamins-and-minerals&id=3691-620)).
- Suvitayavat, W., Sumrongkit, C., Thirawarapan, S.S., Bunyaphatsara, N. (2004) Effects of *Aloe* preparation on the histamine-induced gastric secretion in rats. *Journal of Ethnopharmacology*, 90: 239-247.
- Tanaka, M., Matsuda, M.A. (2006) Identification of five phytosterols from *Aloe vera* gel as antidiabetic compounds. *Biological and Pharmaceutical Bulletin*, 29: 1418-22.

- Tisi, D.K., Liu, X.J., Wykes, L.J., Skinner, C.D., Koski, K.G. (2005) Insulin-Like Growth Factor II and Binding Proteins 1 and 3 from Second Trimester Human Amniotic Fluid Are Associated with Infant Birth Weight. *Journal of Nutrition*, 135: 1667-1672.
- Toro, F., Benshimol, A., Soyano, A. (2004) Spleen and thymus histology and proliferative response of splenic cells in rats fed raw and cooked phaseolus vulgaris beans. *Archivos Latinamericanos de Nutricion*, 42: 395-402.
- Vazquez, I.A., Gomez –de-Segura, A.G., Grade, (1999) Protective effect of enriched diet plus growth hormone administration on radiation-induced intestinal injury and on its evolutionary pattern in the rat. *Digestive Diseases and Sciences*, 44: 2350-2358.
- Wallander, E., Albert, V.A. (2000) Phylogeny and classification of Oleaceae based on rps 16 and trnL-F sequence data. *American Journal of Botany*, 87: 1827-1841.
- Washburn, A.H. (1950) Growth: its significance in medicine viewed as human biology. *Pediatrics* 5, 765-770.
- Watt, J.M., Breyer-Brandwijk, M.G. (1962) Medicinal and poisonous plants of Southern and Eastern Africa. Second edition, Edinburgh.
- Weser, E., Tawil, T. (1976) Epithelial cell loss in remaining intestine after small bowel resection in the rat. *Gastroenterology* 71: 412-15.

- Woo, S.W., Nan, J.X., Lee, S.H., Park, E.J., Zhao, Y.Z., Sohn, D.H. (2002) Aloe-emodin suppresses myofibroblastic differentiation of rat hepatic stellate cells in primary culture. *Pharmacology and Toxicology*, 90: 193-198.
- Woods, S.C, Benoit, C.S., Clegg, D.J., Seeley, R.J. (2004) Blocking carbohydrate absorption and weight loss: A clinical trial using phase 2<sup>TM</sup> brand proprietary fractioned white bean extract. *Alternative Medicine Review* 9: 63-69.
- Wichtl, M., Bisset, N.G. (1994) *Herbal Drugs and Phytopharmaceuticals*. Third edition. MedPharm Scientific Publishers, Stuttgart. Pp 25- 29.
- Wilding, J., Wowson, P.W., Williams, G. (1997) Memory of specific foods to control and restoration of body energy. *British Medical Bulletin*, 2: 286-306.
- Sonntag, W.E., Ramsey, M., Carter, C.S. (2005) Growth hormone and insulin-like growth factor-1 (IGF-1) and their influence on cognitive aging. *Ageing Research Reviews*, 4: 195-212.
- Wieringa, G.E., Barth, J.H., Trainer, P.J. (2004) Growth Hormone assay standardization: a biased view? *Clinical Endocrinology*, 60: 538-539.
- Wynne, K., Stanley, S., Bloom, S.,( 2005) The gut and regulation of body weight. *Journal of Clinical Endocrinology Metabolism* 89:2576–2582.
- Yaron A., (1991) *Aloe vera*: Chemical and physical properties and stabilization. *Journal of Botany* 40:270.
- Yates, K.M, Rosenberg, L.J., Harris, C.K., Bronstand, D.C., King,G.K., Bichle, G.A., Walker, B., Ford, C.R., Hall, J.E., Tizard,I.R. (1992) Pilot study of effect of

acemannan in cats infected with feline immunodeficiency virus. *Veterinary Immunology and Immunopathology*, 35: 177-189.

Yeh, G.Y., Eisenberg, D.M., Kaptchuk, T.J., Phillips, R.S. (2003) Systematic review of herbs and dietary supplements for glycemic control in diabetes. *Diabetes Care*, 26: 1277-1294.

Yu, C.S., Yu, F.S., Chan, J.K., Li, T.M., Lin, S.S., Chen, S.C., Hsia, T.C., Chang, Y.H., Chung, J.G. (2006) Aloe-emodin affects the levels of cytokines and functions of leucocytes from Sprague-Dawley rats. *In vivo*, 20: 505-9.

Yusuf, S., Agunu, A., Diana, M. (2004) The effect of *Aloe vera* A. Berger (Liliaceae) on gastric acid secretion and acute gastric mucosal injury in rats. *Journal of Ethnopharmacology*, 93: 33-7.

Zang, X.F., Wang, H.M., Song, Y.L. (2006) Isolation, structure elucidation, antioxidative and immunomodulatory proprieties of two novel dihydrocoumarins from *Aloe vera*. *Bioorganic and Medicinal Chemistry Letters*, 16: 949-953.