

ISSN: 1988-2688

<http://www.ucm.es/BUCM/revistasBUC/portal/modulos.php?name=Revistas2&id=RCCV&col=1>

Revista Complutense de Ciencias Veterinarias 2010 4(2): 41-52



**SURGERY TECHNIQUE FOR OVINE RUMINAL CANNULATION.
PROCEDIMIENTO QUIRÚRGICO PARA LA IMPLANTACIÓN DE UNA FISTULA
PERMANENTE EN OVEJAS.**

¹Elices Mínguez R., ²Revuelta Rueda L., ²Martínez-Darve J. and ¹Miguélez Fernández S.

¹Animal Nutrition. Department of Animal Production. Faculty of Veterinary Medicine (U.C.M.). Spain. ²Animal Physiology. Department of Animal Physiology. Faculty of Veterinary Medicine (U.C.M.). Spain. Corresponding author: elices@vet.ucm.es

ABSTRACT

The study of the ruminants' digestive system is of great interest to improve their productive efficiency. From 1928, in which Schalk and Amadon described the technique of cannulation *in one stage* for bovine and ovine, are developed numerous modifications of that technique as well as new others. A common problem is that can appear complications as movements of the cannula, increases in size of the fistula by necrosis of the tissue or ruminal fluid leak. The developed technique provides a simplification to the surgery, minimizes the complications and lengthens functional life of the cannula.

KEYWORDS: Sheep, small ruminants, fistula, cannula, degradability, carbohidratos, fibre, nutrition, *in vivo*, *in sacco*, bolsas de nylon, rumen, surgery, surgery technique, one stage.

RESUMEN

El estudio del sistema digestivo de los rumiantes es de gran interés para conseguir mejorar su eficiencia productiva. Desde 1928, año en el que Schalk y Amadon describieron la técnica de canulación en una fase para su utilización en bovino y ovino, se desarrollan numerosas modificaciones de esta técnica así como otras nuevas. Un problema común es que pueden aparecer complicaciones como movimientos de la cánula, aumentos de tamaño de la fístula por necrosis o fugas de líquido ruminal. La técnica desarrollada aporta una simplificación a la cirugía, minimiza las complicaciones y alarga vida funcional de la cánula.

PALABRAS CLAVE: Ovejas, ovino, pequeños rumiantes, fistula, cánula, degradabilidad, hidratos de carbono, fibra, nutrición, *in vivo*, *in sacco*, nylon bags, rumen, cirugía, técnica quirúrgica, un tiempo.

INTRODUCTION

For many years in research, we have been using cannulated animals to allow access to the gastrointestinal tract and to obtain digestive samples, to collect high-nutrient solutions, to study digestibility and degradability, and as a result, to know about digestive physiology.

The permanent cannulation of the different regions of the gastrointestinal tract are experimental techniques used frequently in different animals, like pigs (Laplace and Borgida, 1976; Landers *et al.*, 1989; Pluske *et al.*, 1995), rabbits (Carman and Waynforth, 1984), cattle (Shalk and Amadon, 1928; Ward *et al.*, 1950), buffalos (Mogha and Bhargava, 1979), goats (Cabrera *et al.*, 1980), South American camels –lama and alpaca- (Carcelén, F. and San Martin, F., 1999; Cabrera *et al.*, 2000) ponies (Peloso *et al.*, 1994) and dogs (Walker *et al.*, 1994).

Ruminants' complex digestive system offers us multiple opportunities to research the digestive physiology of these species. Most of the investigations working with cannulated animals have been directed to increase knowledge of a certain minerals' nutritive values, mostly in protein and carbohydrate degradability processes, and then to make predictions of the productive parameters of ruminants (AFRC, 1993; NRC 1985, 2000 and 2001).

The techniques used for the ruminal physiology study are divided in two categories: “*in vitro*” studies and “*in vivo*” studies. In both cases the animals have cannulas and act like ruminal liquid donors – “*in vitro*” – (Song, 1989; Song and Kennedy, 1989) or we work inside the chamber directly – “*in vivo* or *in situ*” - (nylon bags technique described by Meherez and Orskov, 1977).

The researchers have used two surgical procedures to make the ruminal fistulation and cannulation. The first technique described is from 1928, the year that Schalk and Amadon described a surgical procedure, *in one stage*, for its use in bovine and ovine; later a new technique *in two* stages would be described for its use in ovine mainly (Jarret, 1948). Through

years new modifications of these techniques and new ones have been developed (Dougherty, 1955; Driedger *et al.*, 1970; Hecker, 1974; Dougherty, 1981; Komarek, 1981; Mc Gilliard, 1982; Gay and Heavner, 1986; Bristol, 1990; Harrison, 1995).

Even though, the use of permanent cannulas may, sometimes, have some inconvenients. The main inconvenient is ruminal fluid leak between the surgical wound edges like a scarring process consequence (Komarek, 1981), by irritation and posterior necrosis of the tissue (Harrison *et al.*, 1957) or by the quality damage of the material used (rubber cannulas – Dougherty, 1955; Kondos, 1967). Generally, is more accused this effect when is rigid the cannula material (synthetic or metallic polymers), because the surgical incision must have a big size to let its layout (Harmon and Richards, 1997).

Another fact to consider is the changes in the ruminal motility although they haven't detail significant differences in the nutrient digestibility (Hayes *et al.*, 1964; MacRae, 1975). Leng, R. A. (not published data – Preston, 1986 -) has described a fall, between 0,5 to 1 point percentage variable, of the consumption (expressed like % of the animal live weigh) the surgical intervention day.

In this work we describe a modification of the *one stage* surgical technique described by Shalk and Amadon in 1928, and changed by Komarek lately, successfully used in 10 sheep, whose objective is to minimize the post surgical complications.

METHODS AND MATERIALS



The cannulas were built with synthetic material, polyvinyl chloride (PVC), a bit reactive to the surrounding tissue, rumen environmental conditions tolerant and sterilizable by all ways. The cannula has 64 mm length, 50 mm nut thread and with 40 mm internal diameter. Moreover there is a sealing external nut that fixes the nut thread; two sealing discs with 120 mm in the external diameter and 42 mm in the internal diameter; and a stopper (Figure 1).

We used 10 adult sheep, female, “*Rubia del Molar*” breed; with a 45 kg mean body, which were subject to a 24 hours fast period before the surgery.

All the work was made according the rules established by the Directive 86/609/CE of the Council, of November 24th 1986, relative to the legal, statutory and administrative resolutions with regard to the protection of the animals that are used for experimentation and other scientific ends (MAPA, 1988).

The day before the intervention, we proceeded to shave and clean the area with a soap solution and alcohol to take out the wool’s fat. They were in fast to decrease the ruminal volume and avoid this way possible complication during the surgery act.

Same day of surgery, 15 minutes before it, animals were premedicated with atropine 1% (Atropine Braün 1%; 0,04mg/kg) to inhibit the salivation, the ruminal musculature motility and increase the cardiac and respiratory efficiency. We used a mix of Chlorhydrate ketamine (Ketaminol, 10-20 mg/kg IM) and Xylazine (Rompun, 2%; 0,25-0,5 mg/kg IM) as anaesthetic agent. Also we used Flunixin Meglumine (Fynadine; 2,2 mg/kg deep IM) as presurgical anaesthetic agent. Since one of the ketamine’s effects determinates that the animals have the eyes open during the intervention, we used Polyacrylic acid (Viscotears) as an ophthalmic lubricant to prevent corneal dryness.

We did a regional and local anaesthetic with Lidocaine (Xilocaina Ovejero 2%) by paravertebral infiltration of the lumbar nerves, ahead of transverse apophysis from T₁₃ to L₂, and a local inverted “L” infiltration directly in the surgical incision zone. We put 10 ml of medicine in each point of injection.

We administrated fluid therapy to all the animals, based in Ringer Lactate with a 10 ml/Kg/hour dose, during the intervention and during their recovery, through a jugular vein catheter.

All the sheep were placed in right lateral recumbency (Figure 2). The surgery table was elevated in the anterior portion allowing the animal head and thorax were higher than the abdomen. This position allows that the saliva and digesta go to the digestive system posterior portions, so won’t go to the trachea making an aspiration pneumonia, and that abdominal

internal organs go to the more caudal abdominal portions releasing the pressure against the diaphragm.

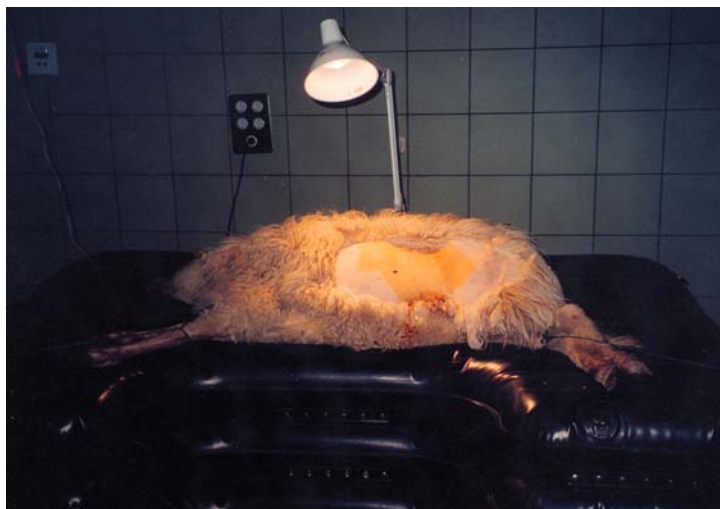


Figure 2: All the sheeps were placed in right lateral recumbency.

dissection of the abdominal muscular group (*external abdominal oblique, internal abdominal oblique, transversus abdominus and transverse fascia*) and at last open the peritoneum making an open similar to the skin one and fixed it with simple suture points, that will be taken later (Figure 4 and 5).

The access to the rumen was made by left paracostal laparotomy, previous disinfection of the zone with antiseptic foam and povidone-iodine. First we made an incision in the skin 25 cm from the last rib and with amplitude enough to enter the cannula through it (Figure 3). Once the skin is cut we continued with a blunt

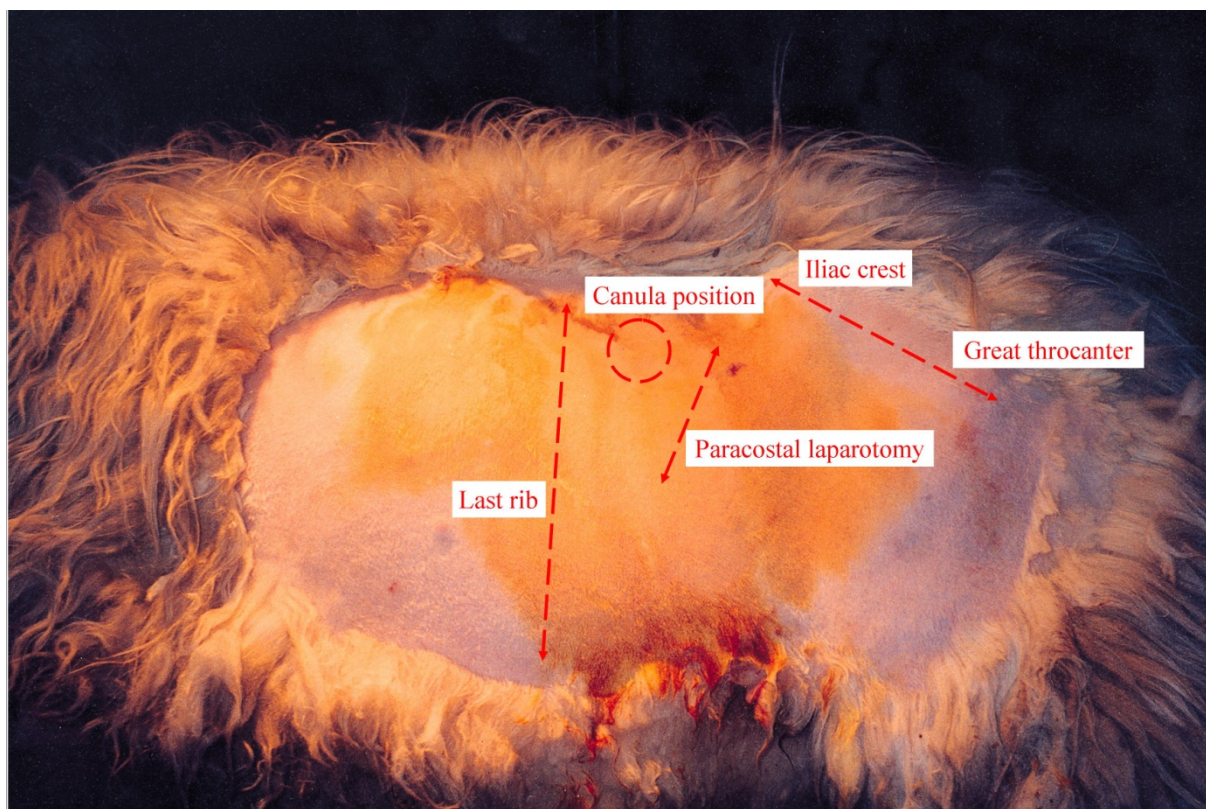
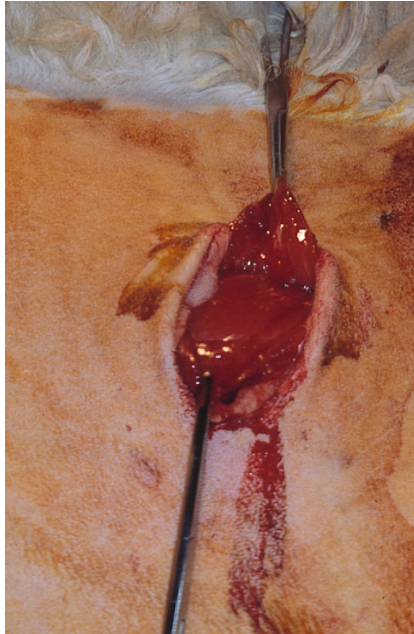
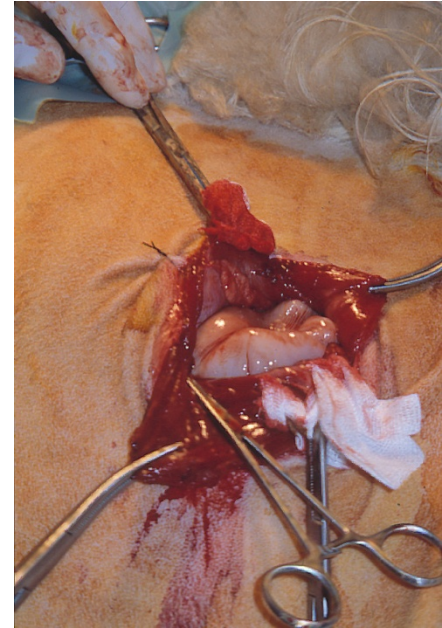


Figure 3: First we made an incision in the skin 25 cm from the last rib and with amplitude enough to enter the cannula through it.



F. 4

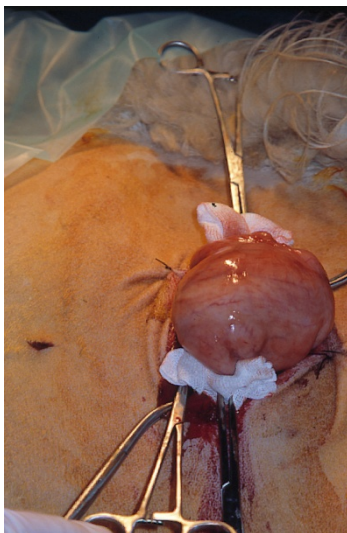


F. 5

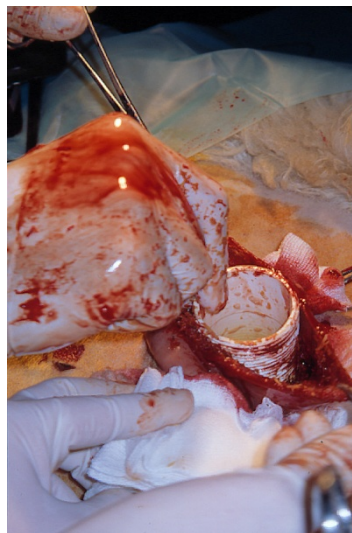
Figure 4: Once the skin is cut we continued with a blunt dissection of the abdominal muscular group.

Figure 5: At last open the peritoneum making an open similar to the skin one and fixed it with simple suture points, that will be taken later.

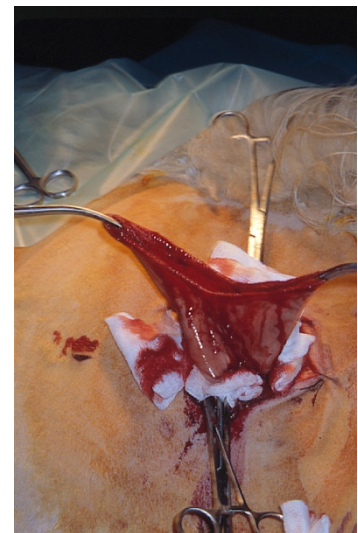
Once made the laparotomy, we protect the exposed tissues and the peritoneum with sterile lines and we made a rumenotomy in the dorsal sac of the rumen, trying to cut in a not much vascularized area, showing the dorsal sac (Figure 6). This incision will have an amplitude strictly enough to allow us to insert the cannula, the internal disc and the surgeon's hand. We will raise the dorsal sac with hemostasis tongs or with suture points to prevent ruminal liquid reflow (Figure 7). Next, we introduce the cannula in the rumen and we take it to a more craniodorsal area clearly separated of the incision zone (Figure 8).



F. 6



F. 7



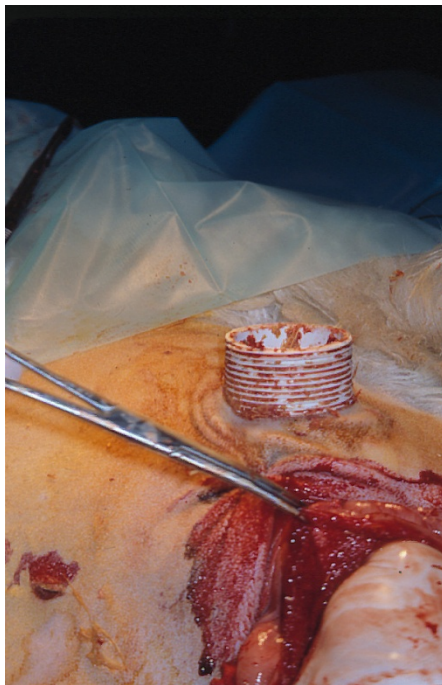
F.8

Figure 6: We made a rumenotomy in the dorsal sac of the rumen, trying to cut in a not much vascularized area, showing the dorsal sac.

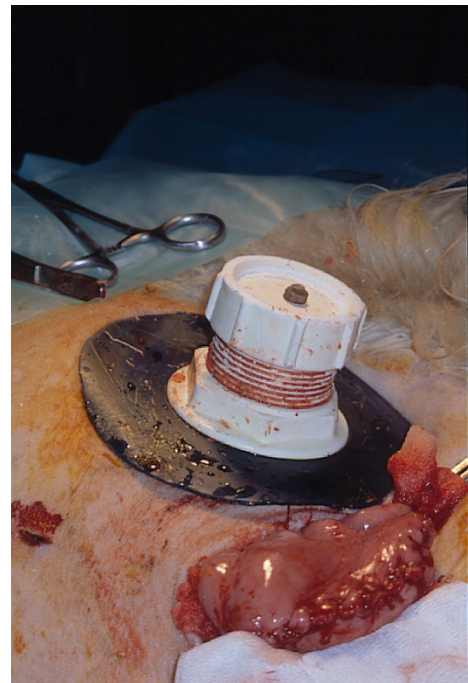
Figure 7: We will raise the dorsal sac with hemostasis tongs or with suture points to prevent ruminal liquid reflow.

Figure 8: Introduce the cannula in the rumen.

From this position, we press from the rumen interior to the animal chest wall, making that the shape formed guide us to make a little incision with a diameter similar to the cannula's one and by little turns, from right to left –clockwise –, the cannula nut thread will go through all the cut tissues (Figure 9). By this proceeding the cannula nut thread fits perfectly in all the cut tissues. Once we had passed the cannula, we could put the external disc and the cannula external sealing nut. That way the cannula will be fixed without any kind of suture (Figure 10).



F. 9



F. 10

Figure 9: We move it to a more craniodorsal area clearly separated of the incision zone. Then we press from the rumen interior to the animal chest wall, making that the shape formed guide us to make a little incision with a diameter similar to the cannula's.

Figure 10: That way the cannula will be fixed without any kind of suture.

At last, we proceed to close the paracostal laparotomy bound with suture points each tissue layer, using a 0 caliber reabsorb material. We finish closing the skin with simple suture points with monofilament material non absorb from 0 to 1, that will be removed after 7 to 10 days after surgery (Figure 11).



Figure 11: We finish closing the skin with simple suture points with monofilament material non absorb from 0 to 1, that will be removed after 7 to 10 days after surgery.

After anaesthesia recovery the animals were returned to the flock, to don't disturb the sheep herd instinct.

As analgesia, we injected Flunixin Meglumine IM every eight hours for three days after surgery. We also used an antibiotic therapy, consisting of a mix of procaine penicillin and dihydrotetracycline (Procastrep[®]), administered IM every 48 hours for ten days.

During all the animal observation period, the cannula surrounding area was kept shaved, clean and we used arthropod repellent products, (Deltametrine, Butox[®]) to avoid miasis (Figure 12).



Figure 12: During all the animal observation period, the cannula surrounding area was kept shaved, clean and we used arthropod repellent products.

RESULTS

The animals responded well to the surgical procedure, without complications like important haemorrhages when we skin, the muscular, peritoneum and rumen. Cannulas were adjusted without problems to the fistulas we made without any contamination of the

abdominal cavity from ruminal content in the implant moment. In this way, the sheeps' recovery after surgery was quick, consuming all them food and water in a 12 hours' time after surgery.

The ten cannulated sheep with this technique were controlled for a 12 months period after surgery, and they were done nutritive valuation studies of different prime materials and animal physiology in this period. At this time the animals didn't have complications: didn't change their behaviour, been the same as non fistulated animals, none fistula got a bigger size, and none cannula was rejected, or had to be reimplanted.

In the other hand, it didn't have a ruminal content leak through the space between the fistula and the cannula, and we didn't observed necrosis of the surruounding tissue.

CONCLUSIONS

The success of the techniques we used for ruminal cannulation it is based in obtaining a perfect sealing of the fistula we made with the cannula implantation and to avoid, therefore, complications after the surgery like ruminal content leak which give infectious process, and also a bigger size of the fistula after surgery and cannula movements that produce lacerations. The technique described in this work allowed us to minimize to the maximum the ruminal content leaks that are inevitable when we used the techniques we mentioned before.

As an advantage, is important to point that this technique is less labourius, faster and easier to do it than traditional *two stages* techniques, in which ones we had to do a second ruminotomy to implant the cannula.

REFERENCES

- AFRC (1993) Nutritive requirements for ruminants animals: Protein. *Nutrition Abstracts and Reviews (serie B)*. 62: 787-835.
- Bristol, D. G. (1990). Surgery of bovine digestive tract. *The Veterinary Clinics of North America*. W. B. Saunders Co., Philadelphia, PA.
- Cabrera, R., L. Opazo, E. González. (1980). Fistulación permanente del rumen del caprino. *Arch. Med. Vet.* 12: 249-251.

- Cabrera, R., M. V., López, A., Morales, S., Salazar, H. y Fuentes A. M. (2000). Fistulación y canulación permanente del compartimento 1 (rumen) en Llamas (*Lama glama*). *Arch. Med. Vet.* 32, 1: 1-9.
- Carcelén, F. y San Martín, F. (1999) Cánulas para el primer compartimento estomacal en alpacas. *Rev. Inv. Vet. Perú.* 10 (1): 105-107.
- Carman, R. J. and Waynforth, T. B. (1984) Chronic fistulation and cannulation of the rabbit caecum. *Lab. Anim.* 16: 307-309.
- Dietz, Schaetz, Schleiter, Teuscher. Operaciones y Anestesia de los Animales Grandes y Pequeños. Ed. Acribia. 1975.
- Dougherty, R. W. (1955) Permanent stomach and intestinal fistulas in ruminants: some modifications and simplifications. *Cornell Vet.* 45: 331-356.
- Dougherty, R. W. (1981) Experimental surgery in farm animals. Iowa State University Press, Ames.
- Driedger, A., Condon, R. J., Nimrick, K. O. And Hatfield, E. E. (1970) A modified technique for abomasal and rumen cannulation. *J. Anim. Sci.* 28:772-775.
- Gay, W. J. and Heavner, J. E. (1986) Methods of animal experimentation. Vol VII. Research surgery and care of the research animal. Part A. Patient care, vascular access and telemetry. Academic Press. Orlando, Florida.
- Harmon D. L. And Richards, C. J. (1997) Considerations for Gastrointestinal Cannulations in ruminants. *J. Anim.* 75: 2248-2255.
- Harrison, P. A. (1995) Surgical techniques in experimental farm animals. Oxford University Press. New York.
- Harrison, J. H., Swanson, D. S. and Lincoln, A. F. (1957) A comparison of the tissue reactions to plastic materials. *Arch. Surg.* 74: 139.
- Hayes, B. W., Little, C. O. and Mitchell, G. L. (1964) Influence of ruminal, abomasal and intestinal fistulation on digestion in steers. *J. Anim. Sci.* 23: 764 766.
- Hecker, J. F. (1974) Experimental surgery in small ruminants. Butterworth & Co. London.
- Jarret, J. C. (1948) The production of rumen and abomasal fistulas in sheep. *J. Counc. Sci. Ind. Res.* 21: 311-315.
- Johnson, R. R. (1966) Techniques and procedures for *in vitro* and *in vivo* rumen studies. *J. Anim. Sci.* 25:855.
- Komarek, R. J. (1981) Rumen and abomasal cannulation of sheep with specially designed cánulas and a cannula insertion instrument. *J. Ani. Sci.* Vol 53, No. 3, 1981.

- Komarek, R. J. (1981) Rumen and abomasal cannulation of sheep with specially designed cannulas and a cannula insertion instrument. *J. Anim. Sci.* Vol. 53, 3: 790-795.
- Kondos, A. C. (1967) A new method for the cannulation of the abomasum in sheep. *Aust. Vet. J.* 43: 149-151.
- Landers, B. R., Devitt, P. G., and Jamieson, G. G. (1989) A modified Thomas cannula for duodenal cannulation in pigs. *Aust. Vet. J.* 66: 182-184.
- Laplace, J. P. and Borgida, P. (1976) Problemas fisiológicos poses par la fistulation reentrante chronique de l'ileon chez le porc. *Ann. Zootech.* 25:361-371.
- McGilliard, A. D. (1982). Surgical techniques-advances and cautions. In F. N. Owens (Ed.) *Protein requirements for cattle: symposium*. MP109: 31-36. Oklahoma State Univ. Stillwater.
- McRae, J. C. (1975) The use of re-entrant cannulae to partition digestive function within gastrointestinal tract of ruminants. In: I. W. McDonald and A. C. I. Warner (Ed.) *Digestion and Metabolism in the Ruminant. Proc. IV Int. Symp. Ruminat Physiol.*, Sydney, Australia. pp 261-276.
- Mehrez, A. Z. And Orskov, E. R. (1977) A study of the artificial fibre bag technique for determining the digestibility of feeds in the rumen. *J. Agric. Sci. Camb.* 88: 645-650.
- Ministerio de Agricultura, Pesca y Alimentación. Real Decreto 223/1988, de 14 de marzo, sobre Protección de los animales utilizados para la experimentación y otros fines científicos. BOE 18/03/1988.
- Mogha, I. V. and Bhargava, A. K. (1979) Rumen fistula tecnique and utility. *Indian Vet. J.* 56: 10, 885-887.
- NRC (2001) Nutrient requirements of Dairy Cattle. National Academy Press. Washington, DC
- NRC (2000) Nutrient requirements of Beef Cattle. National Academy Press. Washington, DC
- NRC (1985) Nutrient requirements of Sheep. National Academy Press. Washington, DC
- Peloso, J. G., Schumacher, J., McClure, S. R., Crabill, M. R., Danelka, D. V., Householder, D. D. and Porter, G. D. (1994). Technique for long-term ileal cannulation in ponies. *Can. J. Vet. Res.* 58: 181-184.
- Phillipson A. T., Innes, J. R. M. (1939) Permanent stomach fistulae. *Q. J. Exp. Physiol.* 29: 333-340.
- Pluske, J. R., Williams, T., Cegielski, A. C. and Aherne, F. X. (1995) Stomach cannulation of pregnant gilts for nutrition studies during lactation. *Can. J. Anim. Sci.* 75: 497-500.
- Preston, T. R. (1986) Better utilization of crop residues and by-products in animal feeding: research guidelines. 2. A practical manual for research workers. *FAO Production and*

Health Paper 50/2. Food and Agriculture Organization of the United Nations. Rome. pp 1-32.

Shalk, A. F. and Amadon, R. S. (1928) Physiology of the ruminant stomach (bovine) – Study of the dynamic factors. *N. Dak. Agr. Exp. Sta. Bull.* 216.

Song, M. K. (1989) Influence of soluble protein extraction and defaunation in *in vitro* degradation of dietary protein. *J. Anim. Nutr. Feed.* 13 (6): 308-313.

Song, M. K. And Kennedy, J. J. (1989). *In situ* degradation of feed ingredients fermentation pattern and microbial population as influenced by ruminal ammonia concentration. *Can. J. Anim. Sci.* 69: 999-1006.

Walker, J. A., Harmon, D. L., Gross, K. L. And Collings, C. (1994). Evaluation of nutrient utilization in the dog using the ileal cannulation technique. *J. Nutr.* 124: 2672-2676 (S).

Ward, G. M., Young, F. W. and Huffman, C. F. (1950) A duodenal fistula for physiological studies in the bovine. *J. Dairy Sci.* 33: 384-385.