



<b>Title</b>	<b>Assessment of median nerve mobility by ultrasound dynamic imaging in carpal tunnel syndrome diagnosis</b>
<b>Author(s)</b>	<b>Kuo, TT; Lee, MR; Liao, YY; Lee, WN; Hsu, YW; Chen, JP; Yeh, CK</b>
<b>Citation</b>	<b>The 2013 IEEE International Ultrasonics Symposium (IUS 2013), Prague, Czech Republic, 21-25 July 2013. In IEEE Ultrasonics Symposium Proceedings, 2013, p. 876-879</b>
<b>Issued Date</b>	<b>2013</b>
<b>URL</b>	<b><a href="http://hdl.handle.net/10722/189858">http://hdl.handle.net/10722/189858</a></b>
<b>Rights</b>	<b>IEEE Ultrasonics Symposium Proceedings. Copyright © IEEE.</b>

# Assessment of median nerve mobility by ultrasound dynamic imaging in carpal tunnel syndrome diagnosis

Tai-Tzung Kuo<sup>1,2</sup>, Ming-Ru Lee<sup>2</sup>, Yin-Yin Liao<sup>2</sup>, Wei-Ning Lee<sup>3</sup>, Yen-Wei Hsu<sup>4</sup>,  
 Jiann-Perng Chen<sup>5</sup>, and Chih-Kuang Yeh<sup>2</sup>

<sup>1</sup>Department of Neurosurgery, Hsin-chu Mackay Memorial Hospital, Taiwan

<sup>2</sup>Department of Biomedical Engineering and Environmental Sciences, National Tsing Hua University, Hsinchu, Taiwan

<sup>3</sup>Department of Electrical and Electronic Engineering, The University of Hong Kong, Hong Kong

<sup>4</sup>Department of Neurology, Hsin-chu Mackay Memorial Hospital, Hsinchu, Taiwan

<sup>5</sup>Department of Physical, Hsin-chu Mackay Memorial Hospital, Hsinchu, Taiwan

*Abstract*—Carpal tunnel syndrome (CTS) is a common entrapment neuropathy. Nerve conduction studies (NCS) have been used as a standard for CTS diagnosis. Complementing NCS, ultrasound imaging provides anatomic information on pathologic changes of the median nerve, such as the reduced median nerve mobility. Motion of median nerve is dependent on mechanical characteristics, and body movements. The purpose of this study was therefore to measure transverse sliding patterns of the median nerve during fingers flexion and extension in ultrasound B-mode images for distinguishing healthy from CTS subjects, and to investigate any correlation between NCS severity and median nerve motion. Transverse ultrasound images were acquired from 19 normal, 15 mild, and 10 severe CTS subjects confirmed by NCS. In two-second acquisition, their fingers were initially in natural position; the median nerve was then moved toward the ulnar side and radius side in fingers flexion and extension, respectively. The displacements of the median nerve were calculated by the multilevel block-matching pyramid algorithm and averaged. All the average displacements at different acquisition times were then accumulated to obtain cumulative displacements, which were curve-fitted by polynomial function. To differentiate the normal from CTS cases, the R-squared, curvature, and amplitude of the fitted curves were computed, to evaluate the goodness, variation, and maximum value of the fit, respectively. Compared to the CTS patients, the normal subjects had higher R-square, curvature, and amplitude estimates. The three parameters were then inputted to a fuzzy c-means algorithm to classify normal cases and CTS ones. The diagnostic efficiency had an accuracy of 93.2%, a specificity of 100%, and a sensitivity of 88%. Further study includes measuring mechanical strain and stress at different neural sites to provide elasticity of the median nerve.

*Keywords*—Median nerve mobility; Ultrasound dynamic imaging; Carpal tunnel syndrome

## I. INTRODUCTION

Carpal tunnel syndrome (CTS) is a common entrapment neuropathy resulting from the impairment of the median nerve dysfunction [1]. The carpal tunnel is bounded by

transverse carpal ligament (TCL) on the volar side, and eight carpal bones on the dorsal side. Nine flexor digital tendons and the median nerve pass through the carpal tunnel at the wrist level. For CTS, the main symptoms are an uncomfortable numbness, tingling, and painful in the median nerve distribution of the hands. The nerve conduction study (NCS) has been regarded as a gold standard to diagnose CTS, but it may be invasive and painful, and thus not readily suitable to all patients. The ultrasound imaging has been frequently used as a first step in the clinical diagnosis of CTS [2, 3], because it is noninvasive, offers high temporal and spatial resolutions, and can provide dynamic anatomical information regarding structure and kinesiology. Several studies have demonstrated that the cross sectional area and flattening ratio of the median nerve in the transverse ultrasound image were the most effective parameters for identifying the swelling of median nerve caused by CTS [4]. However, these measured parameters were highly dependent on personal cofactors and scanning protocols.

It is known that the median nerve is subject to compression against the TCL by tensed overlying flexor digital tendons within the carpal tunnel, during wrist and fingers movements [5]. During fingers flexion, the normal median nerve is subjected displacement toward the ulnar side, while it slides toward the radius side during fingers extension [2, 6]. On the other hand, in CTS patients, this kinematic behavior of the median nerve is restricted by the narrower volume and increased pressure in the carpal tunnel. Several studies presented that the longitudinal excursion and transverse sliding of the median nerve during wrist or fingers flexion were greater in healthy subjects than in CTS patients [7, 8]. However, motion of the median nerve is likely a non-uniform pattern due to differences in local anatomy, mechanical characteristics, and limb movements.

Therefore, the purpose of this study was to measure transverse sliding patterns of the median nerve during fingers flexion and extension in ultrasound B-mode images for distinguishing healthy from CTS subjects, and to investigate any correlation between NCS severity and median nerve motion.

## II. MATERIALS AND METHODS

### A. Data collection

This study was approved by the Institutional Review Board (IRB #11MMHIS084) of Hsin-chu Mackay Memorial Hospital. The subjects with cervical radiculopathy, diabetes mellitus, hypothyroidism, rheumatoid arthritis, and wrist osteoarthritis were excluded. The normal group comprised 19 wrists with no clinical signs or symptoms of CTS (range of age, 32–51 years; mean  $\pm$  standard deviation of BMI,  $23.6 \pm 2.47$  m<sup>2</sup>/kg). The CTS group comprised 25 wrists with confirmed CTS by NCS (range of age, 22–79; mean  $\pm$  standard deviation of BMI,  $24 \pm 2.77$  m<sup>2</sup>/kg). Moreover, based on the American Academy of Neurology summary statement, the severity of CTS can be classified and used to create diagnostic subgroups. Abnormal criteria were referenced to previous literature [9]: sensory conduction velocity (SCV) slower than 40 m/s, distal sensory latency (DSL) longer than 2.5 ms, and distal motor latency (DML) longer than 4.0 ms. Then, the mild CTS was defined as a SCV of 30 to 40 m/s, a DSL of 3.0 to 3.5 ms and a DML of 3.8 to 4.5 ms, and severe CTS was defined as a SCV of less than 30 m/s, a DSL longer than 4.5 ms and a DML longer than 6.0 ms. Thus, 15 mild and 10 severe CTS wrists were included in the CTS group.

### B. Ultrasound imaging

The ultrasound transverse scans at the carpal tunnel inlet (i.e., wrist level) were performed by a musculoskeletal physician with more than 10-year experience of musculoskeletal ultrasound. A commercial ultrasound scanner (Model t3000, Terason, MA, USA) with a 10-MHz linear array probe (Model 12L5A, Terason) was used, and its frame rate was 25 fps. The settings of this scanner were identical in each patient examination. The subjects' wrists were examined with their arms supine resting on a flat surface. Ultrasound frames of the transverse wrist were acquired for approximately two seconds, during which their fingers were initially in natural position (Fig. 1(a)); the median nerve was then moved toward the ulnar side in fingers flexion (Fig. 1(b)) and finally the radius side in fingers extension (Fig. 1(c)).

### C. Motion pattern estimation using speckle tracking algorithm

We used the multilevel block-matching pyramid algorithm [10, 11], which included the multilevel block-matching algorithm and the block-sum pyramid (BSP) algorithm, to measure displacements of the median nerve. This algorithm contained matching and searching steps. The matching blocks were 32 pixels by 32 pixels (2.88 mm  $\times$  2.88 mm) and the searching blocks were 21 pixels by 21 pixels (1.89 mm  $\times$  1.89 mm) in all cases. The displacement was estimated by searching for the best-matched pixel in the

comparison image (i.e., the  $i$ th frame) that was most similar to the original pixel in the original image (i.e., the first frame). This process continued until the displacements for all pixels in the original image were acquired. Finally, the median nerve motions toward the ulnar and radial directions were defined as the positive and negative lateral displacements, respectively. The greater the fingers flexed, the greater the median nerve moved, but there was nonlinear correlation between the angle of fingers flexion and the displacements of median nerve. A fingers flexion angle of 60 degrees resulted in the highest displacement of the median nerve, while the angle in excess of 60 degrees caused slight movement. We assumed that the sliding displacements in fingers flexion and extension were symmetric. Therefore, all the average lateral displacements for the median nerve at different acquisition times were then accumulated to obtain cumulative lateral displacements (denoted as blue dots in Fig. 1(d)), which were curve-fitted by a quadratic function (denoted as red line in Fig. 1(d)).

Note that the fitted curve was selected based on the transverse sliding pattern of the median nerve during fingers flexion and extension. To differentiate the normality for CTS cases, the R-squared, curvature, and amplitude three parameters derived from the fitted curves were computed. The R-squared indicated the similarity between the fitting and the cumulative lateral displacements. The curvature and amplitude represented the variation and maximum values of the fitting curve, respectively. The Student's  $t$ -test was used to assess the statistical significance of differences in values of each parameter between normal and CTS cases. A difference was assumed to be statistically significant when its probability value ( $p$  value) was less than 0.05. The performances of each parameter in discriminating between normal and CTS groups were evaluated using the receiver operating characteristic (ROC) curve, each point on which represents a sensitivity/specificity pair corresponding to a particular decision cut-off point. In addition, we applied the fuzzy c-means (FCM) clustering algorithm, an unsupervised clustering method, to divide a group of data points into two clusters/classes, representing the correlations between the different parameter attributes.

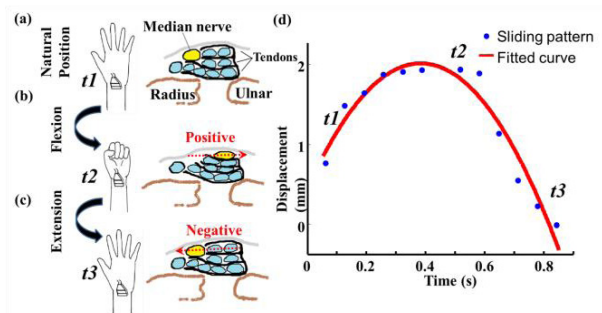


Fig. 1. Median nerve motion during fingers motion from (a) a natural position to (b) a clenched fist (i.e., fingers flexion) and then to (c) an open palm (i.e., fingers extension). (d) All the average lateral displacements for the median nerve at different acquisition times were then accumulated to obtain cumulative lateral displacements (blue dots), which were curve-fitted by polynomial function (red line)

### III. RESULTS AND DISCUSSION

Figure 2 shows the ultrasound images of median nerves during fingers motion from different subjects. The transverse sliding of the median nerve during fingers flexion or extension was greater in a normal subject (Fig. 2(a)) than in either mild (Fig. 2(b)) or severe (Fig. 2(c)) CTS patients. In addition, the lesser the median nerve moved, the more severe the NCS results were. This implied that the decreasing median nerve mobility was correlated with the blocked median nerve conduction velocity.

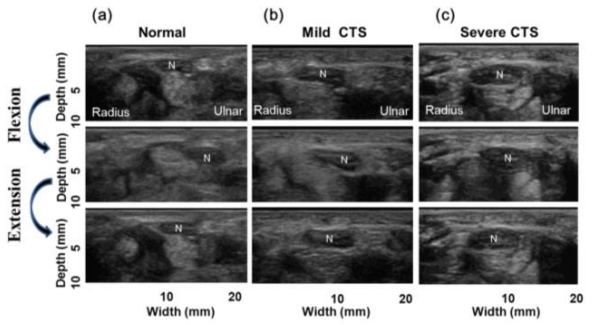


Fig. 2. The ultrasound images of median nerves during fingers motion from different subjects: (a) a normal subject, (b) a mild CTS patient, and (c) a severe CTS patient. N indicates the median nerve.

Then, the transverse sliding patterns of the median nerves during fingers flexion and extension from these subjects were presented in Fig. 3. Compared to the normal median nerve, the median nerve with CTS was subjected to an internal compressive load due to the increased carpal tunnel pressure, resulting in reduced mobility when fingers motion. Therefore, the CTS patients had significantly lower R-square, curvature, and amplitude estimates of the fitted curves respectively representing more dissimilar to a quadratic curve, lesser variation, and lower the maximum value of the estimated displacements, as shown in Fig. 4.

The  $p$  values of the three parameters for normal and CTS groups were smaller than 0.05. However, the difference between the mild and severe CTS patients was not significant for all parameters. Subsequently, we calculated the diagnostic performances of these parameters using the ROC curves. Table 1 illustrates the accuracy, sensitivity, specificity, and area (AUC) of the different parameters assessed by the ROC curves. The curvature had the best performance with a specificity of 94.7%, a sensitivity of 88%, an accuracy of 90.9%, and an AUC of 0.93. Nevertheless, the three parameters indicated different characteristics of the fit associated with different kinematic representations of the sliding pattern. In addition, lower correlations among different parameter sets implied that the classification performance could be further improved, so we combined the three parameters in FCM clustering.

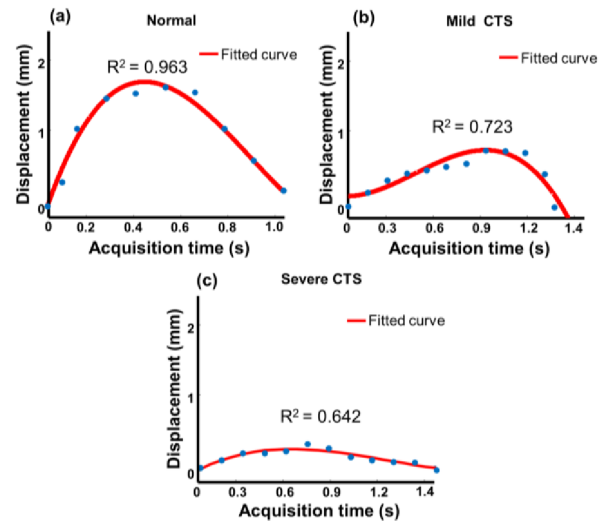


Fig. 3. The transverse sliding patterns (i.e., the fitted curves) of the median nerves during fingers flexion and extension from different subjects: (a) a normal subject, (b) a mild CTS patient, and (c) a severe CTS patient. Blue dots represent cumulative lateral displacements at different acquisition times, and red lines represent fitted curves.

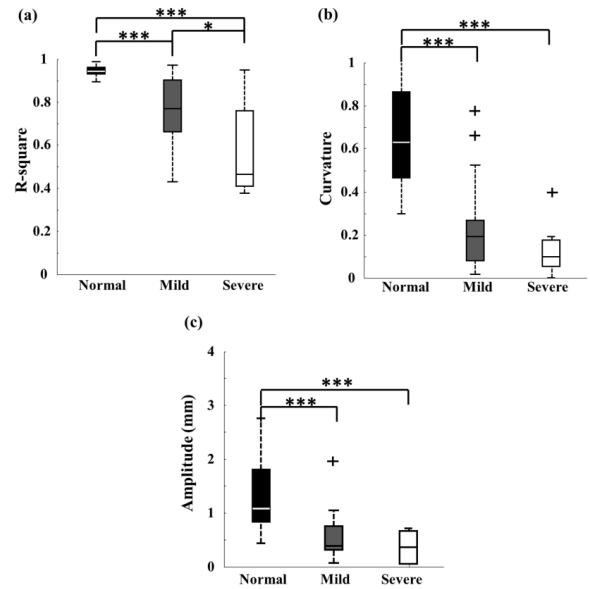


Fig. 4. Box plots showing the distributions of (a) R-square, (b) curvature, and (c) amplitude estimates of the fitted curves in the normal, mild, and CTS groups, respectively.

Representative results were shown in Fig. 5. The data points were separated into two clusters: (1) a normal cluster (blue solid line) and (2) a CTS cluster (red dashed line). Then, we calculated the numbers of normal and CTS data points therein to estimate the accuracy, sensitivity, and specificity of using three parameters to classify normal and CTS cases. Combining the R-square, curvature, and amplitude can improve the accuracy compared to only using

TABLE I. The different parameter analyzed with the ROC curve.

Parameters	R-square	Amplitude	Curvature
<b>Performances</b>			
<b>Specificity</b>	<b>89.5%</b>	<b>84.2%</b>	<b>94.7%</b>
<b>Sensibility</b>	<b>84.0%</b>	<b>84.0%</b>	<b>88.0%</b>
<b>Accuracy</b>	<b>86.4%</b>	<b>84.1%</b>	<b>90.9%</b>
<b>AUC</b>	<b>0.89</b>	<b>0.89</b>	<b>0.93</b>

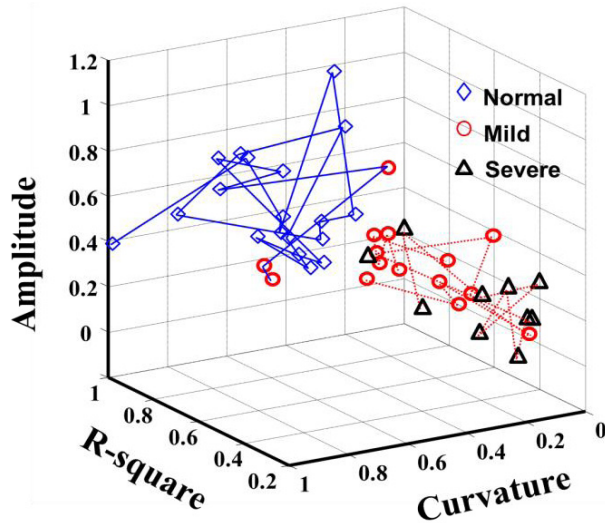


Fig. 5. Representative results of combining three parameters in three-dimensional FCM clustering. Blue solid line indicates an estimated normal cluster, and red dashed line indicates an estimated CTS cluster.

one feature. The performance had an accuracy of 93.2%, a specificity of 88.0%, and a sensitivity of 100.0%. However, some mild CTS patients were not identified using this method. The possible reasons were that the database in this study was not suitable for characterizing the severity of CTS, the FCM clustering method was not robust, and the static and dynamic features of the median nerve should be considered simultaneously.

#### IV. CONCLUSION

This study demonstrated that the transverse sliding pattern was capable of quantifying the dynamic mechanical behavior of the median nerve during fingers motion. The scanning protocol and hand positions of subjects will be standardized to ensure that this technique can be applied reproducibly by other researchers. In future, the static features such as cross sectional area and the dynamic characteristics of the median nerve will be combined by a supervised classifying method to diagnose the severity of peripheral neuropathy.

#### REFERENCES

- [1] I. Duncan, P. Sullivan, and F. Lomas, "Sonography in the diagnosis of carpal tunnel syndrome," *American Journal of Roentgenology*, , 173 681-6841999.
- [2] E. Erel, A. Dilley, J. Greening, V. Morris, and B. Cohen, "Longitudinal sliding of the median nerve in patients with carpal tunnel syndrome," *Journal of Hand Surgery (British and European Volume)*, vol. 28, pp. 439-443, October 2003.
- [3] B.S. Cigali, H.M. Buyruk, C.J. Snijders, J.S. Laméris, W.P.J. Holland, R. Mesut, and H.J. Stam, "Measurement of tendon excursion velocity with colour doppler imaging: a preliminary study on flexor pollicis longus muscle," *European Journal of Radiology*, vol. 23, issue. 3, pp. 217-221, November 1996.
- [4] H.B. Hammer, I.A.H. Hovden, E.A. Haavardsholm, and T.K. Kevin, "Ultrasonography shows increased cross-sectional area of the median nerve in patients with arthritis and carpal tunnel syndrome," *Rheumatology*, vol. 45, pp. 584-588, 2006.
- [5] Y. Yoshii, H.R. Villarraga, J. Henderson, C. Zhao, K.N. An, and P.C. Amadio, "Speckle tracking ultrasound for assessment of the relative motion of flexor tendon and subsynovial connective tissue in the human carpal tunnel," *Ultrasound in Medicine & Biology*, vol. 35, issue. 12, pp. 1973-1981, December 2009.
- [6] M.W. Coppieters, and A.M. Alshami, "Longitudinal excursion and strain in the median nerve during novel nerve gliding exercises for carpal tunnel syndrome," *Journal of Orthopaedic Research*, vol. 25, issue. 7, pp. 972-980, July 2007.
- [7] M.H.M. van Margriet, J. Henderson, A.B.M. van der Molen, K.N. An, and P.C. Amadio, "Transverse plane tendon and median nerve motion in the carpal tunnel: ultrasound comparison of carpal tunnel syndrome patients and healthy volunteers," *Public Library of Science Journal*, vol. 7, issue. 5, pp. 1, May 2012.
- [8] U.C. Ugbohue, W.H. Hsu, R.J. Goitz, and Z.M. Li, "Tendon and nerve displacement at the wrist during finger movements," *Clinical Biomechanics*, vol. 20, issue. 1, pp. 50-56, January 2005.
- [9] J. D. P. Bland, "A neurophysiological grading scale for carpal tunnel syndrome," *Muscle & Nerve*, vol. 23, pp. 94-100, 1999.
- [10] Y.Y. Liao and C.C. Wu, T.T. Kuo, J.P. Chen, Y.W. Hsu, and C.K. Yeh, "Carpal tunnel syndrome diagnosis by a self-normalization process and ultrasound compound imaging," *Medical physics*, vol. 39, issue, 12, pp. 7402-7411, December 2012.
- [11] P.C. Li, and W.N. Lee, "An efficient speckle tracking algorithm for ultrasonic imaging," *Ultrasonic imaging*, vol. 24, pp. 215-228, 2002.