



**Universidade de São Paulo**

**Biblioteca Digital da Produção Intelectual - BDPI**

---

Sem comunidade

Scielo

---

2012

# Case for diagnosis

---

An. Bras. Dermatol.,v.87,n.3,p.489-490,2012

<http://www.producao.usp.br/handle/BDPI/39563>

*Downloaded from: Biblioteca Digital da Produção Intelectual - BDPI, Universidade de São Paulo*

## Case for diagnosis

### Caso para diagnóstico

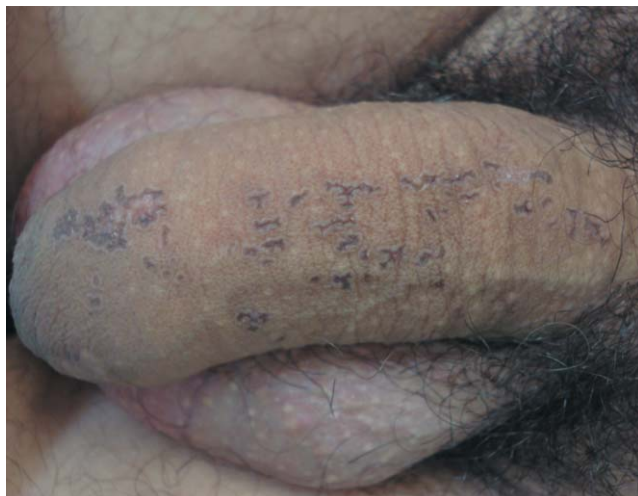Sheila Viana Castelo Branco Gonçalves<sup>1</sup>  
José Vitor de Oliveira Junior<sup>3</sup>

Neusa Yuriko Sakai Valente<sup>2</sup>  
Daniele Loureiro Manguera Paiva<sup>1</sup>

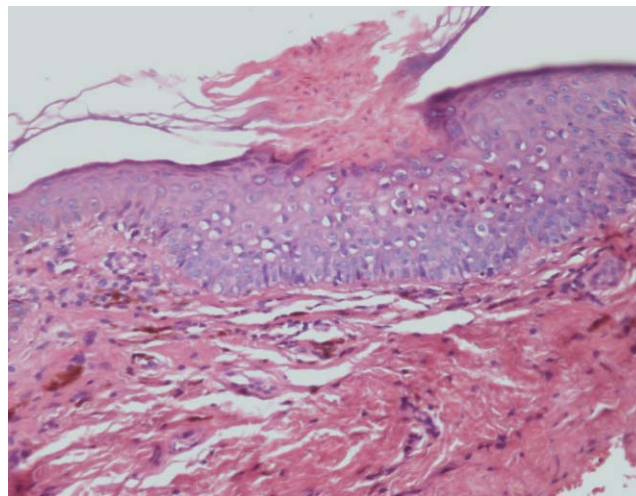
#### CASE REPORT

A 39-year old Caucasian male presented with a 15-year history of asymptomatic lesions on his penis. Physical examination revealed linear lesions with fine keratotic walls and an atrophic, violaceous center on the dorsum of the penis (Figure 1). No other lesions were identified on any area of his body. There was no family history of any similar skin disorders and the patient was not on any drugs. Histopathological examination showed findings consistent with porokerato-

sis: hyperkeratotic and parakeratotic stratum corneum (cornoid lamella) and underlying diskeratosis (Figure 2). The patient was treated with topical liquid-nitrogen cryotherapy for five sessions over a 6-month period. Over the 2-year follow-up period, the lesion improved and there is no evidence of recurrence or malignant transformation. The patient's informed consent was obtained for this report.



**FIGURE 1:** Linear lesions with fine keratotic walls and atrophic, violaceous center on the dorsal shaft of the penis



**FIGURE 2:** Cornoid lamella and underlying diskeratosis (HE, 200x)

Received on 24.05.2011.

Approved by the Advisory Board and accepted for publication on 20.08.2011.

\* This study was conducted at the São Paulo State Civil Servants' Hospital (HSPE), Moema - São Paulo (SP), Brazil.

Conflict of interest: None

Financial funding: None

<sup>1</sup> Dermatologist - São Paulo (SP), Brazil.

<sup>2</sup> PhD awarded by the Department of Dermatology, Medical School, University of São Paulo (FMUSP). Head, Dermatopathology Department, São Paulo State Civil Servants' Hospital (HSPE), Moema - São Paulo (SP), Brazil.

<sup>3</sup> Master's student in Dermatology, Medical School, University of São Paulo (FMUSP) - São Paulo (SP), Brazil.

## DISCUSSION

Porokeratosis is an uncommon epidermal keratinization disorder of unknown etiology and unpredictable course. It is characterized by the presence of centrifugally enlarging hyperkeratotic plaques associated with the histopathological hallmark of cornoid lamellae.<sup>1</sup> Porokeratosis can be classified into six different clinical forms: porokeratosis of Mibelli; disseminated superficial porokeratosis; disseminated superficial actinic porokeratosis; porokeratosis plantaris, palmaris et disseminata; linear porokeratosis and punctate porokeratosis.<sup>2</sup> The first case of genital porokeratosis was described by Helfman in 1985.<sup>3</sup> Since then, there have been no more than thirty reports in the literature. Only one of these cases describes linear porokeratosis.<sup>4</sup> Because of its rarity, evidence-based medicine largely relies on case reports. The largest series available to date reported on ten cases in Taiwan. All the patients were male with a mean age of 46 years at initial diagnosis.<sup>5</sup>

Differential diagnosis includes condylomata acuminata, lichen planus, chronic eczema, psoriasis and Bowen's disease.<sup>4,5</sup> Treatment options are cryotherapy, surgery, CO2 laser, topical 5-fluorouracil

cream and imiquimod cream.<sup>6,7</sup> In this case, the patient was successfully treated with cryotherapy.

Much controversy remains with respect to the malignant transformation of porokeratosis. Although there are collateral data from other forms of porokeratosis describing conversion rates to epithelial tumors as high as 23.8%, not a single case of malignant transformation of genital porokeratosis has been reported in the literature. The pooled mean follow-up of all reported cases, including the present one, is 5.6 years (range 0.3-13 years). Therefore, more studies with longer follow-up are still needed in order to adequately evaluate the association between genital porokeratosis and malignancy.<sup>8</sup>

Genital porokeratosis is a rare dermatological disorder of unknown etiology and unpredictable course. This case report describes a patient with linear porokeratosis of the genital area, who was successfully treated with cryotherapy. During two years of follow-up, the lesion improved and there was no evidence of recurrence or malignant transformation. All cases of genital porokeratosis should be followed up regularly in view of the potential for malignant transformation. □

**Abstract:** Porokeratosis is a primary keratinizing disorder of unknown etiology. This disorder is characterized by the presence of centrifugally enlarging hyperkeratotic plaques, associated with the histopathological hallmark of cornoid lamellae. Genital porokeratosis is extremely rare. No more than thirty cases have been reported in the literature, including only one case of linear porokeratosis confined to the genital area. This case report describes a patient with genital linear porokeratosis, who was successfully treated with cryotherapy. Over two years of follow-up, the lesion improved and there was no evidence of recurrence or signs of malignant transformation. Nevertheless, there is a need for long-term follow-up data on recurrence and malignant transformation.

**Keywords:** Cryotherapy; Genitalia; Male genitalia; Porokeratosis

**Resumo:** A poroceratose é uma desordem primária de queratinização, de etiologia desconhecida. Apresenta-se com lesões eritemato-acastanhadas com crista periférica e centro normal ou atrófico, e está associada ao achado anatomopatológico de lamela corneide. O envolvimento genital nessa doença é extremamente raro. Não mais que trinta casos têm sido descritos na literatura, sendo um desses casos de poroceratose linear localizado na área genital. Descrevemos um caso de poroceratose linear genital tratado com crioterapia. Durante dois anos de seguimento, houve melhora do aspecto das lesões, sem recorrência ou sinais de transformação maligna. Entretanto, um acompanhamento a longo prazo se faz necessário.

**Palavras-chave:** Crioterapia; Genitália; Genitália masculina; Poroceratose

## REFERENCES

- Schamroth JM, Zlotogorski A, Gilead L. Porokeratosis of Mibelli. Overview and review of the literature. *Acta Derm Venereol.* 1997;77:207-13.
- Torres T, Velho GC, Selores M. Poroceratose superficial disseminada num doente com colangiocarcinoma: manifestação paraneoplásica? *An Bras Dermatol.* 2010;85:229-31.
- Helfman RJ, Poulos EG. Reticulated porokeratosis. A unique variant of porokeratosis. *Arch Dermatol.* 1985;121:1542-3.
- Kienast AK, Hoeger PH. Penile linear porokeratosis in a child: a case report. *Pediatr Dermatol.* 2009;26:216-7.
- Chen TJ, Chou YC, Chen CH, Kuo TT, Hong HS. Genital porokeratosis: a series of 10 patients and review of the literature. *Br J Dermatol.* 2006;155:325-9.
- Levell NJ, Bewley AP, Levene GM. Porokeratosis of Mibelli on the penis, scrotum and natal cleft. *Clin Exp Dermatol.* 1994;19:77-8.
- Tangoren IA, Weinberg JM, Ioffreda M, Werth VP, James WD. Penile porokeratosis of Mibelli. *J Am Acad Dermatol.* 1997;36:479-81.
- Sasson M, Krain AD. Porokeratosis and cutaneous malignancy. A review. *Dermatol Surg.* 1996;22:339-42.

## MAILING ADDRESS:

*Sheila Viana Castelo Branco Gonçalves*  
*Avenida Ibirapuera, 981, Moema*  
*04029-000 São Paulo, SP, Brazil*  
*E-mail: sheilacastelo@hotmail.com*

How to cite this article: Gonçalves SVCB, Valente NYS, Oliveira Jr JV, Paiva DLM. Case for diagnosis. Linear porokeratosis of the genital area – Case report. *An Bras Dermatol.* 2012;87(3):489-90.