



Universidade de São Paulo

Biblioteca Digital da Produção Intelectual - BDPI

Sem comunidade

Scielo

2012

Open bite: diagnosis, treatment and stability

Braz. Dent. J.,v.23,n.6,p.768-778,2012

<http://www.producao.usp.br/handle/BDPI/39303>

Downloaded from: Biblioteca Digital da Produção Intelectual - BDPI, Universidade de São Paulo

Open Bite: Diagnosis, Treatment and Stability

Mírian Aiko Nakane MATSUMOTO
Fábio Lourenço ROMANO
José Tarcísio Lima FERREIRA
Rodrigo Alexandre VALÉRIO

Department of Pediatric Clinic, Ribeirão Preto Dental School, University of São Paulo, Ribeirão Preto, SP, Brazil

Open bite has fascinated Orthodontics due to the difficulties regarding its treatment and maintenance of results. This anomaly has distinct characteristics that, in addition to the complexity of multiple etiological factors, have aesthetic and functional consequences. Within this etiological context, several types of mechanics have been used in open bite treatment, such as palatal crib, orthopedic forces, occlusal adjustment, orthodontic camouflage with or without extraction, orthodontic intervention using mini-implants or mini-plates, and even orthognathic surgery. An accurate diagnosis and etiological determination are always the best guides to establish the objectives and the ideal treatment plan for such a malocclusion. This report describes two cases of open bite. At the end of the treatment, both patients had their canines and molars in Class I occlusion, normal overjet and overbite, and stability during the posttreatment period.

Key Words: open bite, anomaly, diagnosis, treatment, stability.

INTRODUCTION

Open bite is an anomaly with distinct characteristics that are easily recognized, present in 25% to 38% of the orthodontically treated patients (1). Several etiological factors are involved in this type of malocclusion, such as facial growth pattern, sucking habits, tongue-thrusting, mouth breathing, adenoid hypertrophy, syndromes, occlusal and eruptive forces, dental ankylosis, and postural mandibular imbalance. Other factors like severity and time of initial treatment can make open bite correction and stability more difficult to achieve (2).

Various mechanical alternatives are available in the literature: palatal crib (2), orthodontic camouflage with premolars or first molars extraction (3), magnets (4), mini-implants (5), mini-plates (6) and orthognathic surgery (7). However, appropriate diagnosis and treatment plan are needed before deciding for the most suitable approach (8,9). This report describes the procedures relative to diagnosis, orthodontic treatment planning and stability based on a 2-year treatment of two cases of open bite (antero-lateral and lateral).

CASE REPORT

Case 1 (Antero-Lateral Open Bite)

Diagnosis and Etiology

A 14-year-old white female patient was referred to orthodontic treatment by her dentist, with indication “to correct the maxillary right lateral incisor erupted lingually and crowding of mandibular incisors”. The patient reported that she underwent adenotonsillectomy at the age of 5 and orthodontic treatment at the age of 10 with split-plate maxillary expansion removable appliance for 4 years. The patient was in the permanent dentition stage and had good general health.

Physical examination revealed an increased lower third of the face, slightly convex facial profile, mid-face deficiency appearance and normal nasolabial angle (Fig. 1). On intraoral examination, it was observed low caries risk, healthy gingival tissues, Angle’s Class I posterior crossbite due to narrow maxilla, 5 mm open bite extending to the region of premolars, maxillary right lateral incisor erupted lingually and 6 mm overjet.

The maxillary arch-length deficiency was 8.0 mm and mandibular arch-length deficiency was 6.5 mm. The upper midline was shifted to the right by 4 mm, and lower midline coincident with facial midline (Fig. 1). Functionally, the patient presented mouth breathing, tongue thrusting and abnormal swallowing and speech.

Panoramic radiograph showed all permanent

teeth, with third molars exhibiting their developing crowns, maxillary right first molar and mandibular left first molar with endodontic treatment (Fig. 2). Cephalometric analysis revealed retruded maxilla and downward rotation of the mandible in relation to the skull, Class III skeletal malocclusion, dolicofacial pattern and increased vertical growth, skeletal open bite, the

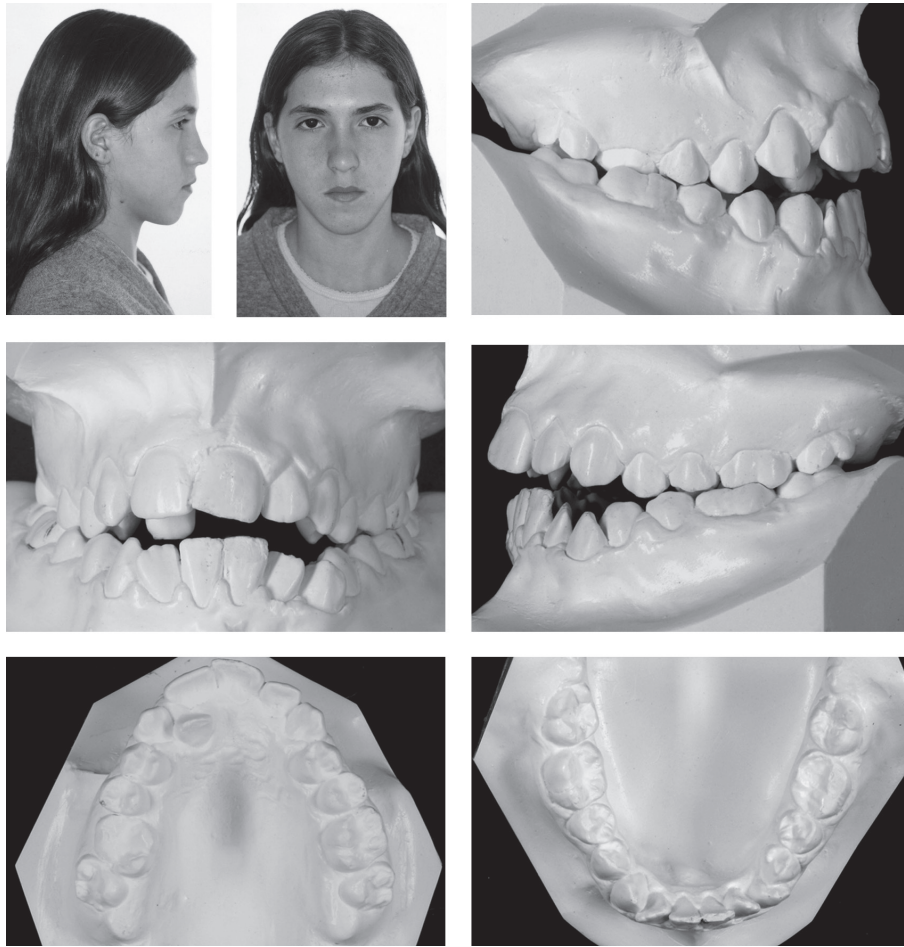


Figure 1. Pretreatment extraoral photographs and dental casts.

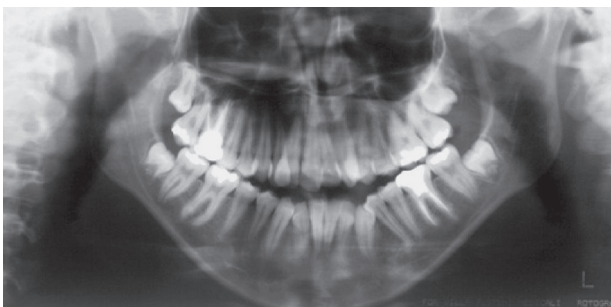

Figure 2. Pretreatment panoramic radiograph.

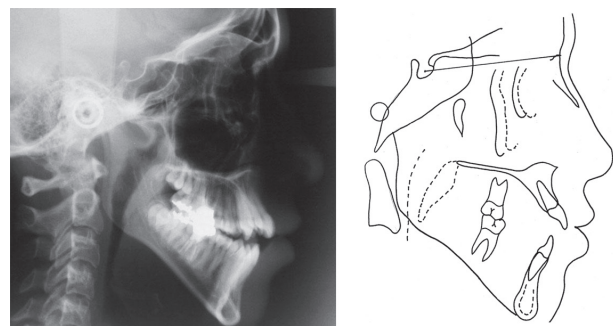


Figure 3. Pretreatment lateral cephalogram and tracing.

maxillary incisors were labially tipped and protruded, and the mandibular incisors were lingually tipped and protruded (Fig. 3 and Table 1).

Treatment Objectives

The treatment aimed to eliminate the tongue-thrusting habit, correct overjet, open bite and posterior crossbite, reduce mandibular vertical growth, align and level the teeth and correct the midline by using fixed orthodontic appliance in the permanent dentition.

Treatment Planning

A chin cup therapy and extraoral force (vertical direction of pull) was installed to control the mandibular vertical growth, thus allowing counter-clockwise rotation of the mandible. A Haas palatal expander was incorporated with slow activation at the rate of 1 mm/week. Treatment started with a standard edgewise appliance (0.022 x 0.028-inch slot) in mandibular and maxillary arches. The four maxillary and mandibular first molars were extracted. During the corrective mechanics, both alignment and leveling were performed with 0.014 to 0.020-in stainless steel archwire. Next, a 0.019 x 0.025-in archwire was used for retraction of canines and incisors, to close extraction sites by moving the posterior teeth forward without control of posterior anchorage loss. At the end of malocclusion correction, intermaxillary elastics were used in rectangular arch wires in order to improve intercuspation.

Table 1. Cephalometric evaluation: pretreatment and posttreatment.

Cephalometric measures	Pretreatment	Posttreatment
SNA	77.5°	78°
SNB	78°	76.5°
ANB	-0.5°	1.5°
NAPg	-2°	3°
SNGoGn	45°	46°
NSGn	74°	74°
Y axis	61°	66°
1.NA	36°	17°
1-NA	11 mm	7 mm
1.NB	22°	30°
1-NB	5.5 mm	7 mm

Treatment Outcomes

The aims of treatment were achieved, since crossbite, open bite and maxillary and mandibular incisor crowding were corrected. The chin cup therapy and extraoral force controlled the mandibular vertical growth and correction of crossbite was achieved by using Haas palatal expander. The posterior crossbite due to a narrow maxilla was corrected by slower activation of the expansion appliance. At the end of the corrective orthodontic treatment following extraction of the four maxillary and mandibular first molars, good lip posture and improved facial profile were observed (Fig. 4). Occlusion was very favorable (Fig. 4), with adequate overjet and overbite and the dental arches were in good form with no side effects on the periodontium (Fig. 5). Some cephalometric measures changed significantly (Fig. 6 and Table 1). A maxillary removable retainer was placed to be used for 2 years and a 3 x 3 lingual retainer (0.7 mm wire) was bonded to the lower arch for undetermined length of time. Cephalometric superposition of the treatment phases is shown in Figure 7.

Post-Retention Evaluation

Two years posttreatment, the facial aspect, cephalometric measures and the occlusion obtained with orthodontic treatment remained stable (Fig. 8).

Case 2 (Lateral Open Bite)

Diagnosis and Etiology

A Caucasian male patient aged 8 years and 11 months came to the initial visit complaining of “space between the upper teeth and lower teeth”. The patient reported bottle feeding until 3 years old and chewing difficulty, eating predominantly pasty or chopped food. The patient often suffered tonsillitis, but had low caries risk, healthy gingival tissues and predominantly nasal breathing. He also presented lateral tongue thrusting and abnormal swallowing and speech. Clinical examination of the face revealed an increased lower third, good lip posture, straight facial profile and acute nasolabial angle (Fig. 9).

On intraoral examination, the patient had low caries risk, healthy gingival tissues, Angle’s Class II,

deep overbite, 2 mm overjet, 10 mm lateral open bite, the lower midline was shifted to the right side by 3 mm and upper midline coincident with facial midline, ankylosed primary molars in infra-occlusion and mesially tipped permanent first molars (Fig. 9).

Panoramic radiograph showed all the permanent teeth and third molars in development as well as confirmation of ankylosed primary molars (Fig. 10). Cephalometric analysis revealed retruded maxilla and mandible in relation to skull, Class III skeletal

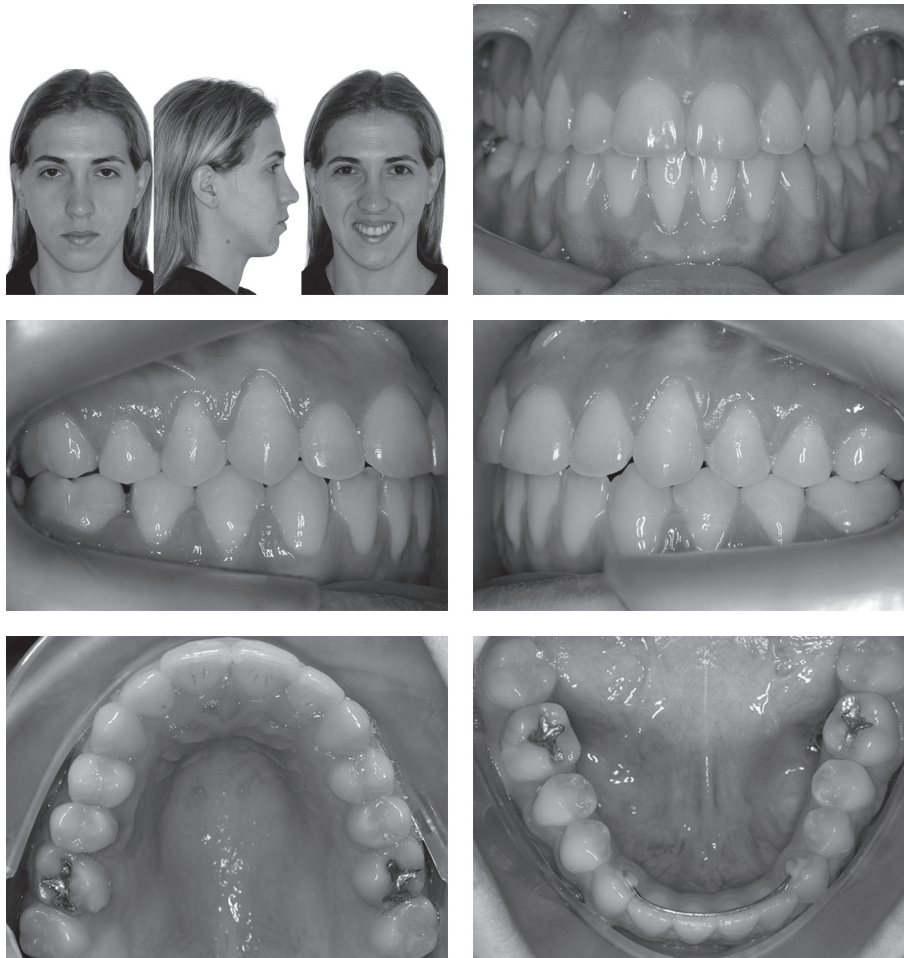

Figure 4. Posttreatment extraoral and intraoral photographs.

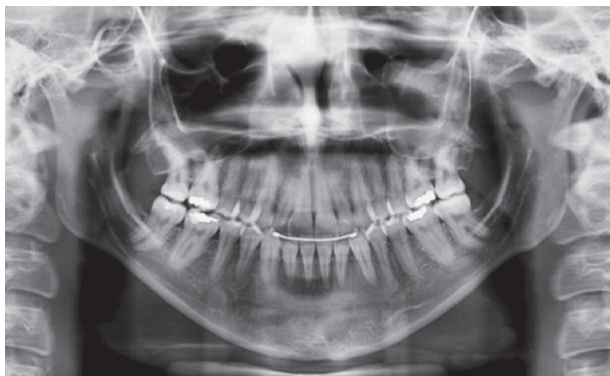

Figure 5. Posttreatment panoramic radiograph.

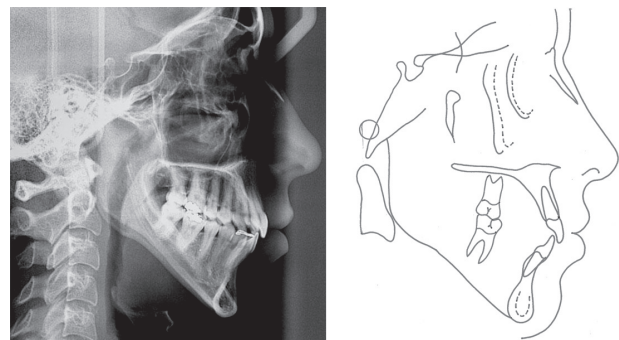


Figure 6. Posttreatment lateral cephalogram and tracing.

malocclusion, mesofacial pattern with mandibular horizontal growth tendency, protruded and labially tipped maxillary incisors and well-positioned mandibular incisors (Fig. 11 and Table 2).

Treatment Objectives

The orthodontic treatment aimed to eliminate the abnormal tongue thrust, close the lateral open bite, stimulate exfoliation of primary molars to promote premolars eruption, control mandibular growth, achieve Class I molar and normal overbite, correct midline, and align and level the teeth with a fixed appliance in the permanent dentition.

Treatment Planning

A chincup therapy was planned to control the mandibular growth and a removable appliance with

acrylic splint was installed in the region of the ankylosed primary molars in order to promote contact between these teeth and stimulate the physiological root resorption process, leading to the exfoliation of primary molars and

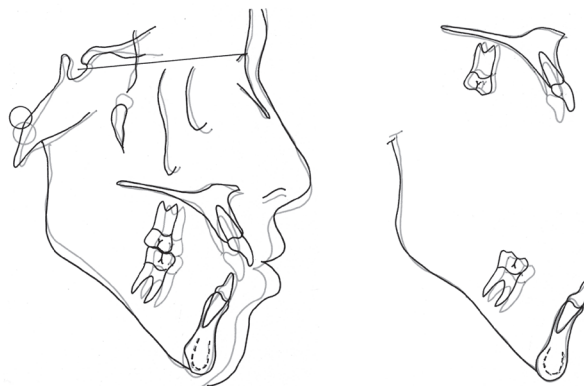


Figure 7. Cephalometric superposition - initial and final tracings.

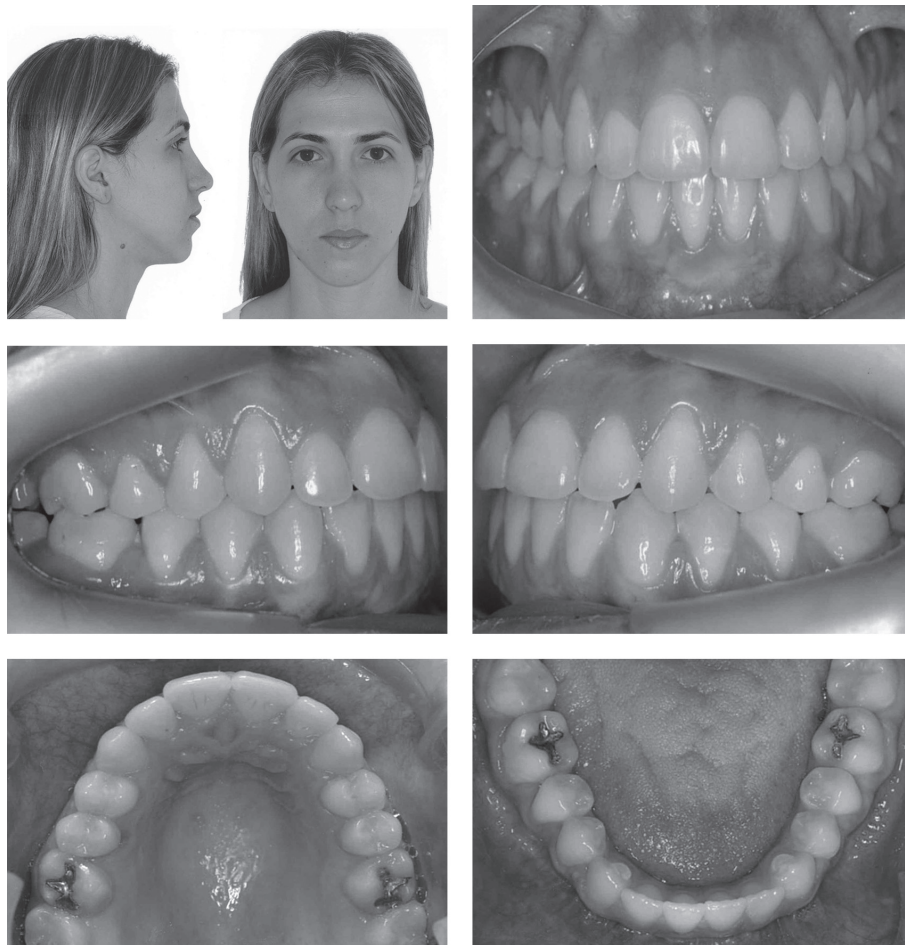


Figure 8. Two-year posttreatment extraoral and intraoral photographs.

eruption of the premolars. Myofunctional therapy was recommended. The orthodontic treatment started with a standard edgewise appliance (0.022 x 0.028-in slot). Stainless steel archwires (from 0.014 to 0.020-in) were used for alignment and leveling. Additionally, sliding jig associated with intermaxillary Class II elastics was used to upright the maxillary first molar in order to obtain space for second molar eruption. Chincup was maintained to control the mandibular growth during the pubertal growth spurt. Mandibular spaces were closed by distalization of the canines and retracting the incisors without control of anchorage so that a Class I molar relationship could be achieved. After this phase, a 0.019 x 0.025-in wire was used for application of ideal torques to improve intercuspation and finish the treatment.

Treatment Outcomes

After the use of chincup and removable appliance, it was observed an increase in overbite and significant closure of the lateral open bite due to the premolar and molar eruption. Maxillary arch showed impaction of the right premolar due to rotation and mesial tipping of the first molar, besides severe rotations of premolars and canines (Fig. 12). Although the first permanent molars still had a class II relationship, the cephalometric measures were changed (Fig. 13 and Table 2).

At the end of the corrective treatment, it was possible to observe good lip posture and convex facial profile (Fig. 14). The resulting occlusion was found to be quite favorable, class I molar and canine relationships,

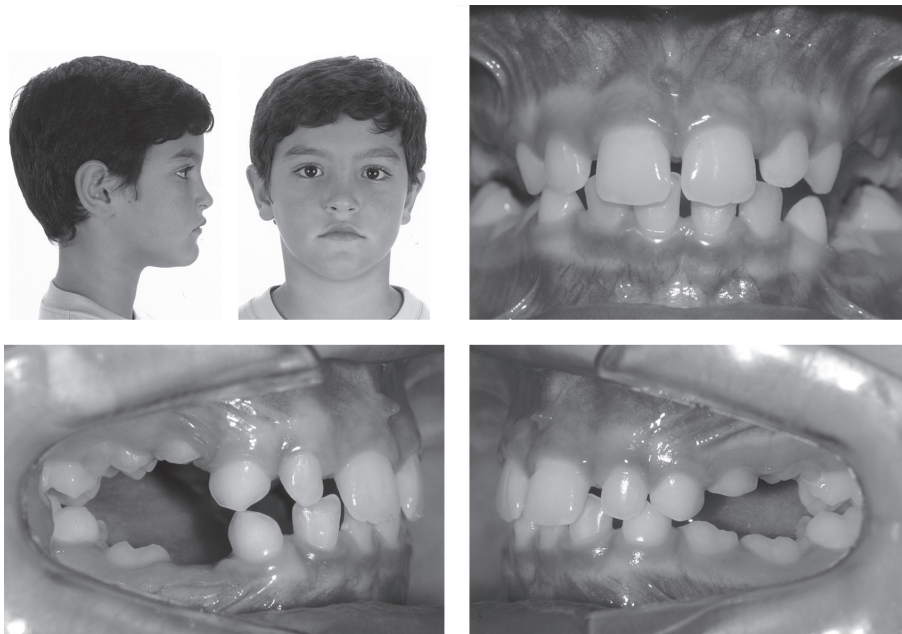


Figure 9. Pretreatment extraoral and intraoral photographs.

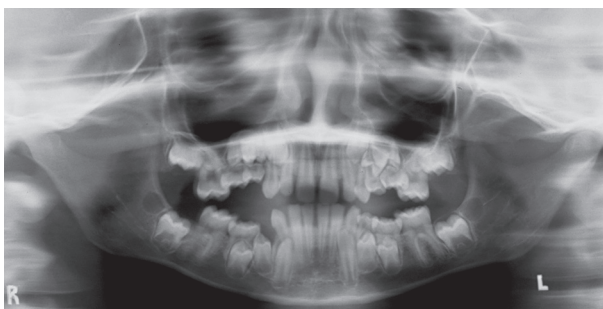

Figure 10. Pretreatment panoramic radiograph.

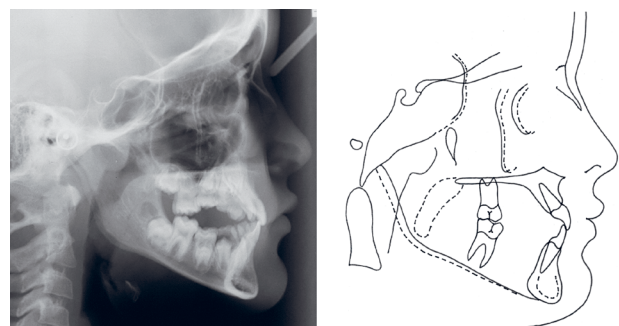


Figure 11. Pretreatment lateral cephalogram and tracing.

adequate overjet and overbite, good form of dental arches, coincident midlines (Fig. 14) and no periodontal damage (Fig. 15). New values were found for cephalometric measures (Fig. 16 and Table 2), meaning that, despite the mandibular growth control, there was a reduction in the convexity angle. Upper removable retainer was

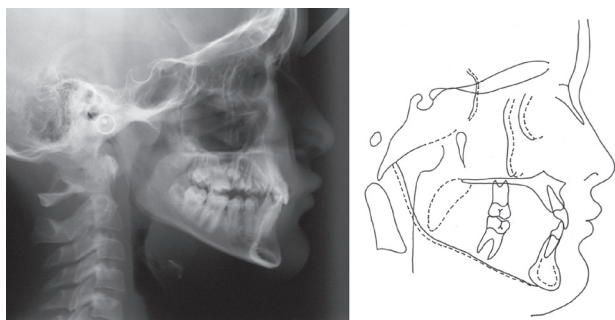


Figure 13. Intermediate lateral cephalograms and tracing.

Table 2. Cephalometric evaluation: pre-treatment, intermediate phase, posttreatment and post-retention.

Cephalometric measures	Pre-treatment	Interm.	Post-treatment	Post-retention
SNA	75°	76.5°	75°	75°
SNB	76°	76.5°	76.5°	77°
ANB	-1°	0°	-1.5°	-2°
NAPg	-4°	-5°	-11.5°	-11.5°
SNGoGn	35°	33°	35°	32°
NSGn	64°	64°	66°	65°
Facial axis	90.5°	92°	93°	93°
1.NA	32.5°	27.5°	30°	33°
1-NA	5.5 mm	5.5 mm	6.5 mm	6.5 mm
1.NB	26°	18°	18°	15°
1-NB	3 mm	3 mm	2 mm	2.5 mm

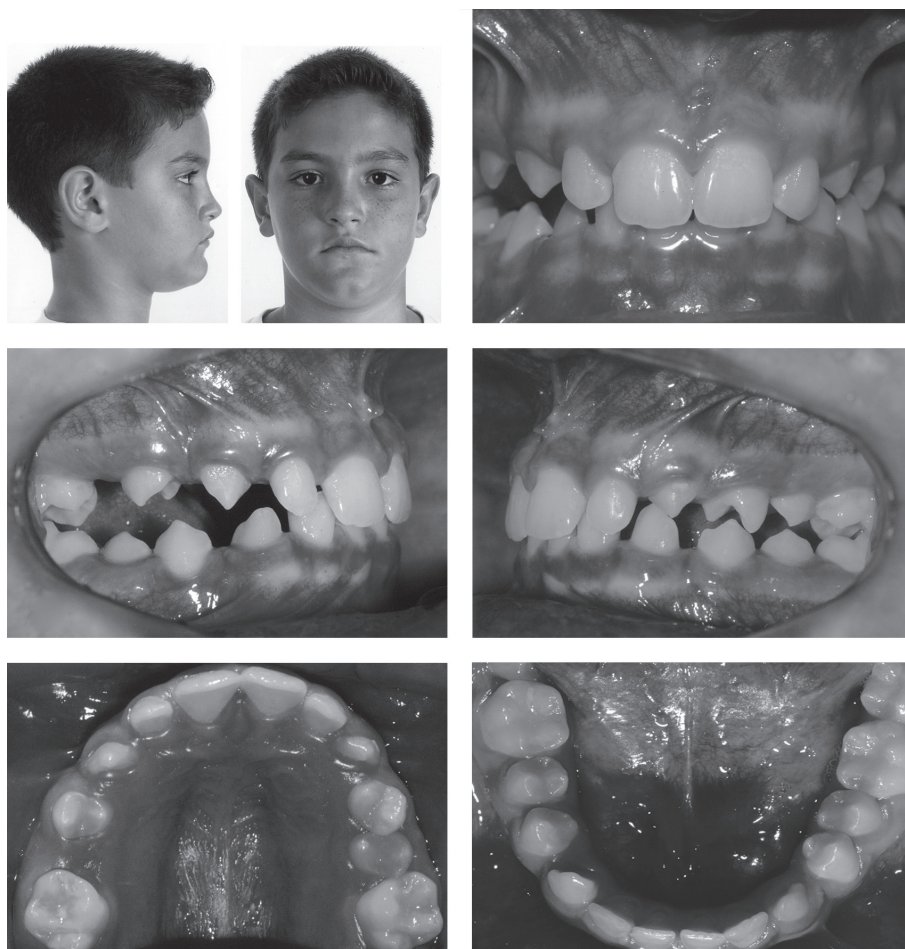


Figure 12. Intermediate extraoral and intraoral photographs.

used during 2 years, and a 3 x 3 lingual retainer (Twist wire 0.032-in) was bonded onto the mandibular arch for undetermined length of time. Extraction of the ectopic maxillary and mandibular third molars was indicated. Cephalometric superposition regarding the treatment phases is shown in Figure 17.

Post-Retention Evaluation

Two years and four months posttreatment, the cephalometric measures changed significantly (Table 2) and occlusion remained stable (Figs. 18 and 19).

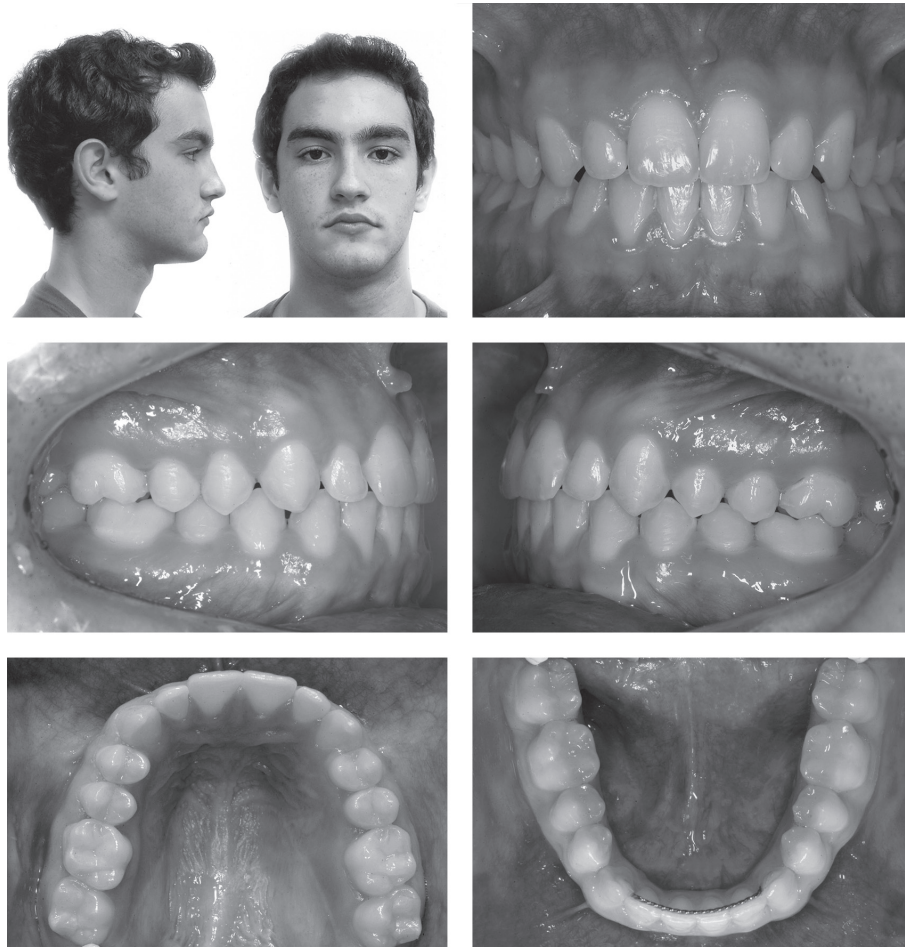


Figure 14. Posttreatment extraoral and intraoral photographs.

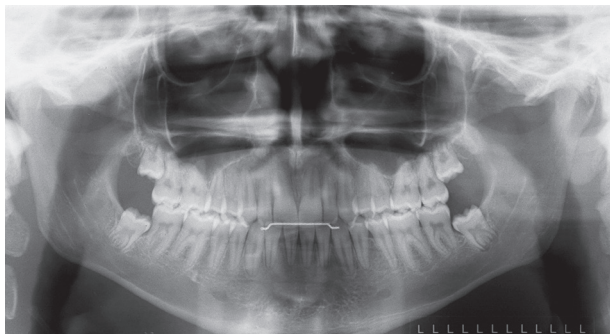


Figure 15. Posttreatment panoramic radiograph.

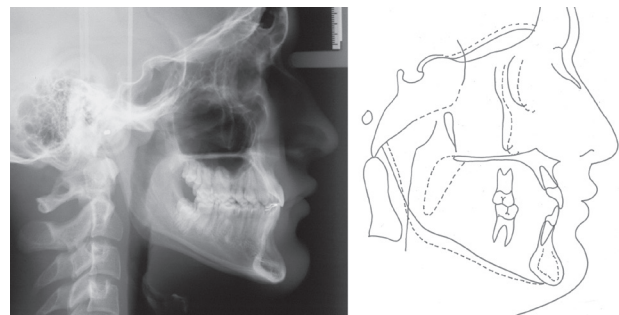


Figure 16. Posttreatment lateral cephalogram and tracing.

DISCUSSION

Open bite treatment is not an exclusively orthodontic intervention, mainly when excessive vertical growth and harmful habits are associated. Nevertheless,

despite the advanced surgical techniques and high popularity of mini-implants (6,9), many patients with skeletal anterior open bite are not inclined to undergo any surgical procedure, thus opting for orthodontic camouflage therapy, as this patient did (10).

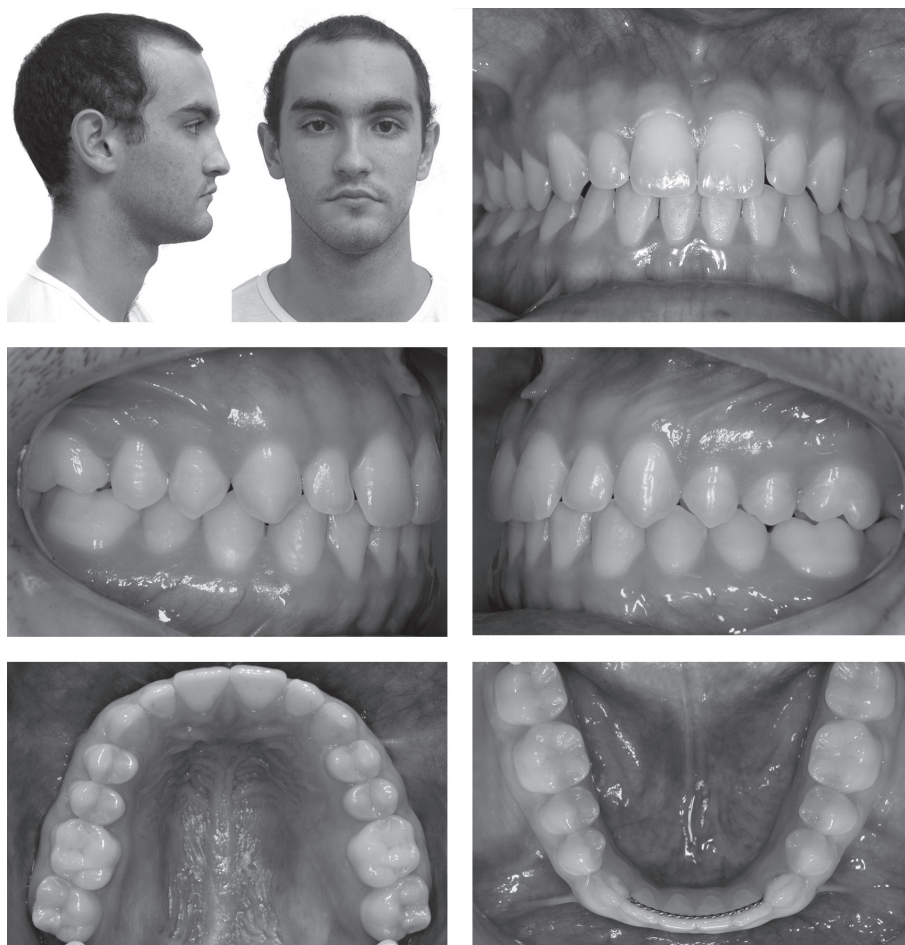


Figure 18. Two-year posttreatment extraoral and intraoral photographs.

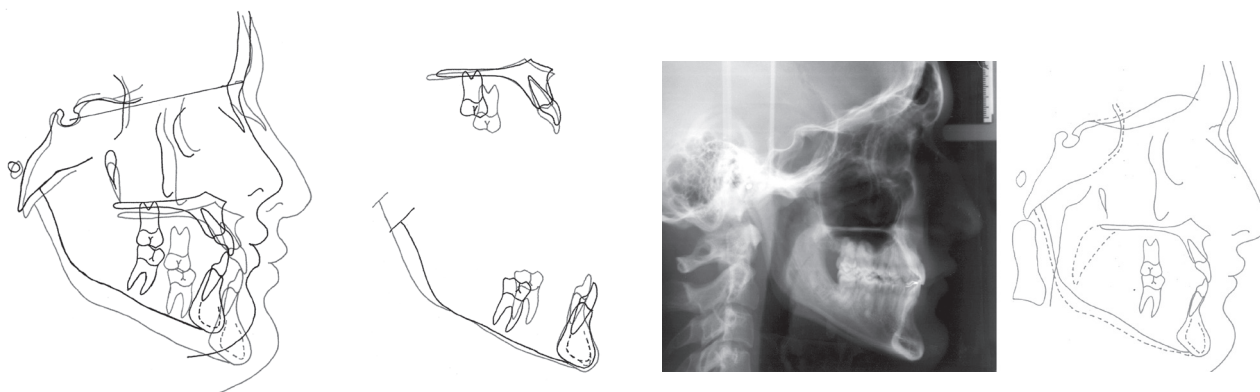


Figure 17. Cephalometric superposition - initial and final tracings.

Figure 19. Two-year posttreatment lateral cephalogram and tracing.

When the surgical choice is rejected, the treatment needs more time and patient cooperation (3). Some authors (2,11) have stated that palatal cribs cannot correct open bite at all, except in those cases of growing patients presenting Class I malocclusion with balanced facial pattern. In Case 1, tongue thrusting was treated by myofunctional therapy after open bite correction. The chincup therapy and extraoral force (vertical direction of pull) is aimed to control the mandibular vertical growth, thus promoting a counter-clockwise rotation of the mandible.

In general, stability is the most important criterion for choosing the open bite treatment method, since this type of malocclusion is difficult to retain. Authors like Goto et al. (12) believe that treatments involving extractions cannot provide stability because the retraction of anterior teeth violates the tongue space. On the other hand, several authors (13-16) have stated that treatment with extraction allows greater stability, since the retraction associated with anchorage loss promotes bite closure, thus decreasing the need of vertical elastics and correction by extrusion of anterior teeth. In addition, tooth extractions can sometimes help obtaining good lip posture (9) as they allow uprighting the mandibular incisors and retracting the maxillary and mandibular incisors (15).

The orthodontic camouflage therapy is a treatment option, but it obviously has indications and counter-indications. Factors such as age, skeletal maturation, and facial profile and pattern should be considered before choosing this method (9,16). In Case 1, it was possible to achieve successful orthodontic results by extracting maxillary and mandibular first molars, since Class I canine and molar relationships, normal overjet and normal overbite were obtained. It should be emphasized that occlusal characteristics at the end of the treatment were achieved by controlled orthodontic mechanics, including the use of intermaxillary elastics only with rectangular finishing arch wires for a short time. The limited use of vertical elastics was aimed to avoid extrusions, unleveling of the teeth and periodontal damage such as gingival retractions and recessions.

In Case 2, the patient reported bottle feeding and had tongue-thrust problems. This, in turn, was considered a secondary habit owing to an adaptation to the pre-existing space, further aggravating and maintaining the open bite instead of being the cause itself (17).

The treatment of choice to correct the lateral open bite depends on the acting etiological factor, since

various factors may be involved in this malocclusion. Clinically, it is important to distinguish whether the failure of eruption is due to disturbance of the eruption mechanism or primary failure. In this case, the main etiological factor is the failure of permanent tooth eruption caused by ankylosed primary molars and consequent lateral tongue thrust.

In an attempt to accelerate the exfoliation of primary teeth instead of extracting the primary molars, which might lead to tipping of the adjacent permanent molar and consequent loss of space (18,19), a removable appliance with acrylic splint in the region of molar was used to provoke the occlusal trauma. This trauma, if not eliminated, leads to an osseous tissue reaction over time and the bone no longer absorbs part of the occlusal forces, which gradually concentrate onto the periodontal ligament. From this moment on, an increasing and direct aggression occurs towards the periodontal structures, with probable damage to the layer of cementoblasts that protect the roots from resorption. Microareas of root resorption spread over these surface regions, leading to total root resorption. For this reason, exfoliation of primary teeth and eruption of premolars occurred in this case. The chincup was also used. This treatment results in significant skeletal changes and brachyfacial patients can benefit from quicker outcomes compared to dolichofacial ones (20). This study is in accordance with these authors, since cooperation on the part of the patient regarding to the use of chincup promoted significant skeletal changes. The patient was also instructed to go on using the chincup (21) to redirect the mandibular growth during pubertal growth spurt. In addition, myofunctional therapy enabled a correct positioning of the tongue, eliminating its interference on primary molars.

Following establishment of the permanent dentition, an orthodontic camouflage therapy for Class III malocclusion with compensation of axial inclinations was used, that is, keeping mandibular incisors retruded with decreased axial inclination and mandibular incisors protruded with increased axial inclination. The lateral open bite was not corrected at the expense of tooth extraction, since eruption of canines and premolars caused vertical growth of alveolar bone and then the vertical elastics were not needed (22). It may be stated that the orthodontic treatment chosen for eliminating the lateral open bite was adequate, since Class I occlusion of canines and molars, as well as normal overjet and overbite were obtained.

In conclusion, regarding the open bite, it is fundamental to identify harmful oral habits and factors that can interfere with the treatment in order to achieve stability and therapeutic success. Knowing that borderline cases require special attention, the decision for the treatment method should be carefully taken and factors such as age, skeletal maturation, facial profile, and growth pattern should be considered before opting for either orthodontic camouflage therapy or orthosurgical treatment. Similar to the case of anterior open bite, a correct diagnosis is required for a successful treatment of the lateral open bite, since each circumstance requires a different approach. In the above-described cases, it was possible to correct the open bite by using an interceptive treatment and then orthodontic camouflage, promoting adequate occlusion at the end of the therapy without causing periodontal damage.

RESUMO

A mordida aberta tem fascinado enormemente a Ortodontia devido à dificuldade de tratamento e manutenção da estabilidade. É uma anomalia com características distintas que, além da complexidade dos múltiplos fatores etiológicos traz consequências estéticas e funcionais. De acordo com a etiologia, muitas mecânicas têm sido utilizadas no tratamento da mordida aberta, entre elas, grades palatinas, forças ortopédicas, ajuste oclusal, terapia de camuflagem com ou sem exodontias, intervenção ortodôntica com auxílio de mini-implantes ou mini-placas até a cirurgia ortognática. Considerando que um diagnóstico apropriado e a determinação da etiologia sempre serão os melhores guias para conduzir os objetivos e o plano de tratamento ideal desta maloclusão, dois casos de mordida aberta foram apresentados. Ao final do tratamento ambos os casos apresentaram oclusão de Classe I de caninos e molares, trespasse horizontal (*overjet*) e trespasse vertical (*overbite*) normais e na avaliação pós-contenção, mostraram estabilidade.

REFERENCES

1. Espeland L, Dowling PA, Mobarak KA, Stenvik A. Three-year stability of open-bite correction by 1-piece maxillary osteotomy. *Am J Orthod Dentofacial Orthop* 2008;134:60-66.
2. Subtelny JD, Sakuda M. Openbite: Diagnosis and treatment. *Am J Orthod* 1964;50:337-358.
3. Stuani MBS, Stuani AS. Modified Thurow appliance. A clinical alternative for correcting skeletal open bite. *Am J Orthod Dentofacial Orthop* 2005;128:118-125.
4. Cabrera MC, Cabrera CAG, Freitas KMS, Janson G, Freitas MR. Lateral open bite: treatment and stability. *Am J Orthod Dentofacial Orthop* 2010;137:701-711.
5. Melsen B, McNamara JA Jr, Hoenie DC. The effect of bite blocks with and without repelling magnets studied histomorphometrically in the rhesus monkey (*Macaca mullata*). *Am J Orthod Dentofacial Orthop* 1995;108:500-509.
6. Park YC, Lee HA, Choi NC, Kim DH. Open bite correction by intrusion of posterior teeth with miniscrews. *Angle Orthop* 2008;78:699-710.
7. Sugawara J, Baik UB, Umemori M, Takahashi J, Kawamura H, Mitani H. Treatment and posttreatment dentoalveolar changes following intrusion of mandibular molars with application of a skeletal anchorage system (SAS) for open bite correction. *Int J Adult Orthodon Orthognath Surg* 2002;17:243-253.
8. Denison TF, Kokich VG, Shapiro PA. Stability of maxillary surgery in open bite versus nonopen bite malocclusions. *Angle Orthod* 1898;59:5-10.
9. Denny JM, Weiskircher MA, Dorminey JC. Anterior open bite and overjet treated with camouflage therapy. *Am J Orthod Dentofacial Orthop* 2007;131:670-678.
10. Nielsen IL. Vertical malocclusions: etiology, development, diagnosis and some aspects of treatment. *Angle Orthod* 1991;61:247-660.
11. Epker BN, Fish LC. Surgical orthodontic corrections of openbite deformity. *Am J Orthod* 1977;71:278-299.
12. Goto S, Boyd RL, Nielsen IL, Lizuka T. Case report: nonsurgical treatment of an adult with severe anterior open bite. *Angle Orthod* 1994;64:311-318.
13. Janson GRP, Valarelli FP, Beltrão RTS, de Freitas MR, Henriques JFC. Stability of anterior open bite non-extraction treatment in the permanent dentition. *Am J Orthod Dentofacial Orthop* 2003;124:265-276.
14. Chang YI, Moon SC. Cephalometric evaluation of the anterior open bite treatment. *Am J Orthod Dentofacial Orthop*. 1999;115:29-38.
15. Vaden JL. The vertical dimension: the "low-angle" patient. *World J Orthod* 2005;6:115-124.
16. Janson GRP, Valarelli FP, Beltrão RTS, de Freitas MR, Henriques FC. Stability of anterior open-bite extraction and non-extraction treatment in the permanent dentition. *Am J Orthod Dentofacial Orthop* 2006;129:768-774.
17. Subtelny JD, Subtelny MK. Oral Habits: studies in form, function and therapy. *Angle Orthod* 1973;43:347-383.
18. Proffit WR, Vig KWL. Primary failure of eruption; a possible cause of posterior open-bite. *Am J Orthod* 1981;80:173-190.
19. Kuroi J, Koch G. The effect of extraction of infraoccluded deciduous molars: a longitudinal study. *Am J Orthod* 1985;87:46-55.
20. Lida Y, Deguchi ST, Kageyama T. Chin cup treatment outcomes in skeletal Class III dolicho- versus non-dolichofacial patients. *Angle Orthod* 2005;75:576-583.
21. Torres FC, Almeida RR, Almeida-Pedrin RR, Pedrin F, Paranhos LR. Dentoalveolar comparative study between removable and fixed cribs, associated to chincup, in anterior open bite treatment. *J Appl Oral Sci* 2012;20:531-537.
22. Bilodeau JE. Nonsurgical treatment of a Class III patient with a lateral open-bite malocclusion. *Am J Orthod Dentofacial Orthop* 2011;140:861-868.

Received November 1, 2011
Accepted December 3, 2012