



Universidade de São Paulo

Biblioteca Digital da Produção Intelectual - BDPI

Departamento de Ortodontia e Odontopediatria - FO/ODO

Artigos e Materiais de Revistas Científicas - FO/ODO

2012

Effects of active and passive lacebacks on antero-posterior position of maxillary first molars and central incisors

Braz. Dent. J.,v.23,n.4,p.433-437,2012

<http://www.producao.usp.br/handle/BDPI/39287>

Downloaded from: Biblioteca Digital da Produção Intelectual - BDPI, Universidade de São Paulo

Effects of Active and Passive Lacebacks on Antero-Posterior Position of Maxillary First Molars and Central Incisors

Ricardo Cesar MORESCA^{1,2}
Julio Wilson VIGORITO³
Gladys Cristina DOMINGUEZ³
André TORTAMANO³
Danielle Rodrigues MORAES¹
Alexandre MORO^{1,2}
Gisele Maria CORRER¹

¹Master's Program in Clinical Dentistry, Positivo University, Curitiba, PR, Brazil

²Department of Orthodontics, Dental School, UFPR - Federal University of Paraná, Curitiba, PR, Brazil

³Department of Orthodontics, Dental School, USP - University of São Paulo, São Paulo, SP, Brazil

The purpose of this study was to compare the effects of active and passive lacebacks on antero-posterior position of maxillary first molars and central incisors during leveling phase. Twenty-three subjects with Class I and Class II malocclusion were treated with first premolars extraction using preadjusted appliances (MBT 0.022-inch brackets). The leveling phase was performed with stainless steel archwires only. The sample was divided into 2 groups: 14 subjects received active lacebacks (Group 1) and 9 subjects received passive lacebacks (Group 2). Lacebacks were made from 0.008-inch ligature wire. Lateral cephalometric radiographs were taken pre- and post-leveling phase. Student's t-test was applied to determine the differences between pre- and post-leveling mean values and to determine the mean differences between groups. In Group I, the first molars showed a significant mesial movement, whereas no change was observed in Group 2. In both groups, maxillary central incisor crowns moved to lingual side. In conclusion, active laceback produced anchorage loss of maxillary first molars whereas passive laceback did not affect the position of these teeth. Active and passive lacebacks were effective in preventing central incisor proclination.

Key Words: corrective orthodontics, orthodontic anchorage procedure, cephalometry.

INTRODUCTION

In an attempt to prevent anterior teeth from tipping forward during the initial stages of orthodontic treatment because of the tip built into the anterior preadjusted brackets, McLaughlin et al. (1) recommended the use of the lacebacks, which are figure-eight 0.010-inch ligature wires, from the most distally banded molar to the canine bracket in each quadrant.

Active lacebacks may be especially used in premolar extraction cases to provide distal cuspid movement, opening space for the alignment of crowded incisors. Lacebacks may also be indicated in their passive form in premolar extraction cases to prevent canine

mesial movement or in non-extraction cases.

There are still few studies in the literature evaluating the effects of the lacebacks and the focus has mainly been on the antero-posterior position of maxillary (2) and mandibular incisors (3). The effectiveness of lacebacks on canine distalization has also been investigated (4).

As far as the effects of the lacebacks on posterior tooth position, only two studies are found in the literature. The study by Robinson is cited by McLaughlin et al. (1) but no reference is made about the methodology used and that study was not published. The investigation of Irvine et al. (3) evaluated the position of the mandibular first molar only and concluded that the use of lacebacks

increased anchorage loss. Nevertheless, no study was found regarding a comparative evaluation of the effects of active and passive lacebacks on posterior anchorage.

The objective of this study was to compare the effects of active and passive lacebacks on antero-posterior position of maxillary first molars and central incisors. The hypothesis of this study was that there is a significant difference in antero-posterior position of molars and incisors for both types of lacebacks.

MATERIAL AND METHODS

Twenty-three subjects (16 females and 7 males) aged between 12 and 18 years (mean age = 15 years and 5 months) were enrolled in this study. All subjects had Class I or Class II malocclusion and orthodontic treatment was planned with extractions of maxillary first premolars. The sample was divided in 2 groups: Group 1, with 14 subjects with active lacebacks and Group 2, with 9 subjects with passive lacebacks. Considering all subjects, the mean of pre-treatment crowding was of 4.25 mm.

All subjects were treated with fixed preadjusted appliances using MBT prescription, including second molars (Victory 0.022-inch brackets; 3M Unitek, Monrovia, CA, USA). To avoid superposition of nickel-titanium archwires' effects (5,6), the leveling phase was performed using stainless steel archwires only (0.014, 0.016, 0.018, 0.020 and 0.019x0.025-inch). The leveling phase was started with 0.014-inch and 0.016-inch archwires adapted passively to bracket slots, introducing first and second order bends that were progressively undone during the appointments. No bends were introduced in the subsequent archwires. Round

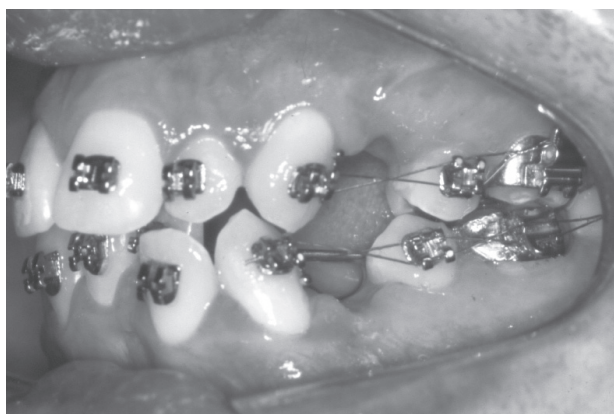


Figure 1. Patient with active lacebacks.

archwires were bent distally to the second molar tubes and the 0.019x0.025-inch archwire ligature wires were extended from the hooks of the second molar tubes to hooks soldered between the lateral and canine brackets. The leveling phase was considered finished when the last archwire was passively engaged. The average time of this phase was 11 months in Group 1 and 10 months in Group 2.

Lacebacks were made of 0.10-inch ligature wire (Morelli, São Paulo, SP, Brazil). In Group 1, lacebacks were reactivated monthly until the canines were retracted, allowing incisors alignment (Fig. 1). In Group 2, lacebacks were installed passively (no retraction force over canine brackets) and were changed just in case of wire fractures.

Lateral cephalometric radiographs were obtained in the pre- and post-leveling phase and were scanned (300 dpi) and traced by a single operator using the software Radioceph (Radiomemory, Belo Horizonte, MG, Brazil).

To evaluate dental changes, coordinate systems were set up. The ANS-PNS plane represented the x-axis and a perpendicular to the ANS-PNS plane through KR (key ridge) point represented the y-axis. Linear

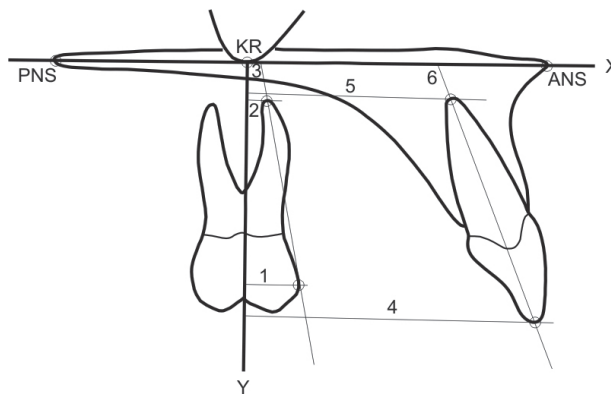


Figure 2. Linear and angular measurements on the pre-leveling and post-leveling lateral cephalometric films. (1) CU6-y, distance (mm) between the most anterior point of the crown of the maxillary first molar and y-axis; (2) RU6-y, distance (mm) between the most apical point of the mesiobuccal root of the maxillary first molar and y-axis; (3) U6.x, angle ($^{\circ}$) between long axis (CU6-RU6) of the maxillary first molar and x-axis; (4) CU1-y, distance (mm) between incisal edge of the maxillary central incisor and y-axis; (5) RU1-y, distance (mm) between the most apical point of the root of the maxillary central incisor and y-axis; (6) U1.x, angle ($^{\circ}$) between long axis (CU1-RU1) of the maxillary central incisor and x-axis.

measurements from the incisal edge or the most anterior point of the molars' crowns and from the most apical point of the incisors' roots or mesiobuccal molars' roots, were obtained perpendicular to the y-axis. The tip of the incisors and first molars to the x-axis were also obtained (Fig. 2).

To perform the analysis of errors, the cephalometric method was repeated in all subjects of the sample, by the same operator, with a minimum interval of 15 days between the measurements. Systematic errors were evaluated by paired Student's t-test and casual errors were accessed using Dahlberg formula (7). The results revealed that the observed variations were compatible with the estimates of operational errors in cephalometric studies (7-10).

Paired Student's t-test was used to determine differences between pre- and post-leveling mean values and independent Student's t-test was used to determine the mean differences between the groups. A significance level of 5% was adopted for all analyses.

Ethical approval for this study was obtained from the institutional Ethics Committee.

RESULTS

Results obtained in Groups 1 and 2, including mean and standard deviation of the studied variables, as well as difference and comparison between pre- and post-leveling mean values within each group, are presented

in Table 1. Comparisons of mean differences between Groups 1 and 2 are shown in Table 2.

There was a statistically significant mesial movement of the crown of the maxillary first molars (CU6-y, -1.31 mm; $p < 0.01$) and a lingual movement of the crown (CU1-y, 1.47 mm) and of the root (RU1-y, 1.12 mm) of the maxillary central incisors were also found statistically significant ($p < 0.05$).

In this group there was no change in the position of the maxillary first molars. The crown of the maxillary central incisors moved lingually (CU1-y, 2.03 mm;

Table 2. Comparison (p) of mean differences between Groups 1 and 2.

Variable	Group 1		Group 2		p
	Mean	SD	Mean	SD	
First molar					
CU6-y (mm)	-1.31	1.16	0.30	0.83	0.002**
RU6-y (mm)	-0.85	1.64	0.28	1.18	0.086
U6.x (°)	-1.94	4.18	-0.74	2.94	0.462
Central incisor					
CU1-y (mm)	1.47	2.20	2.03	1.21	0.502
RU1-y (mm)	1.12	1.82	0.10	1.57	0.185
U1.x (°)	1.68	6.04	5.59	3.50	0.094

* $p < 0.05$; ** $p < 0.01$ (Independent Student's t-test).

Table 1. Mean and standard deviation (SD) of variables in the maxillary arch to Groups 1 and 2, difference (D) and comparison (P) between pre- and post-mean values.

Variable	Group 1				D	P	Group 2				D	P
	Pre-leveling		Post-leveling				Pre-leveling		Post-leveling			
	Mean	SD	Mean	SD			Mean	SD	Mean	SD		
First Molar												
CU6-y (mm)	1.81	2.85	3.12	2.89	-1.31	0.001**	3.03	3.39	2.73	3.99	0.30	0.320
RU6-y (mm)	2.20	2.97	3.05	2.76	-0.85	0.073	1.94	3.34	1.66	4.11	0.28	0.490
U6.x (°)	91.10	5.04	93.04	5.72	-1.94	0.105	94.03	4.64	94.77	4.64	-0.74	0.478
Central Incisor												
CU1-y (mm)	34.40	4.30	32.93	4.26	1.47	0.027*	35.96	3.59	33.93	4.20	2.03	0.001**
RU1-y (mm)	24.19	3.27	23.07	3.41	1.12	0.040*	23.75	3.79	23.65	4.18	0.10	0.853
U1.x (°)	113.44	6.72	111.76	6.83	1.68	0.316	120.98	5.73	115.39	5.34	5.59	0.001**

* $p < 0.05$; ** $p < 0.01$ (Paired Student's t-test).

$p < 0.05$), leading to a lingual tip of this tooth (U1.x, 5.59°; $p < 0.01$).

Comparing Groups 1 and 2, a statistically significant difference ($p < 0.01$) was only found in mesial movement of the crown of the maxillary first molars.

DISCUSSION

Lacebacks have been widely used as auxiliary during the leveling phase, with the main purpose of performing initial retraction of the canines in extraction cases with anterior crowding providing space to incisors alignment and avoiding incisors proclination. This indication may be recognized as active laceback. Another use, which can be termed as passive laceback, refers to cases in which the objective of its use is just to avoid incisors proclination. These situations may include non-extraction cases or extraction cases associated with facial protrusion.

This investigation did not evaluate the effectiveness of lacebacks on canine retraction although they are effective in this indication (4). In a study comparing superelastic NiTi closed coil springs (150 gf) and lacebacks made from 0.010-inch ligature wire for canine distalization, it was observed that although the coil group showed a bigger rate of distalization, the rotation of canines showed a statistically significant difference between groups. In the laceback group, the canine rotated distobuccally (2.68°), whereas in the coil group, the canine rotated distopalatally (7.75°) (4).

In this study, in Groups 1 and 2, the crown of the maxillary central incisor moved palatally, 1.47 mm and 2.03 mm, respectively. In Group 1, the root moved in the same direction quite the same amount of movement (1.12 mm) and the inclination to the palatal plane was not affected. In Group 2, the root remained unchanged and a lingual tip of the central incisor was observed. The reciprocal alignment force among teeth transferred to anterior teeth bending the archwire distally to the second molar tube may explain this palatal movement of the maxillary central incisors. This finding confirms the results of Usmani et al. (2) that lacebacks can prevent maxillary incisors' proclination in the order of 1 mm, but disagrees with Fleming et al. (11) that after a meta-analysis about the effectiveness of laceback ligature concluded that there is no evidence to support the use of lacebacks for the control of the sagittal position of the incisors during initial orthodontic alignment.

Regarding maxillary first molars position, there

was a loss of anchorage when active lacebacks were applied (Group 1). There only was a mesial movement of the crown (1.31 mm). There was no significant change in the position of maxillary first molars when passive lacebacks were used (Group 2). Other studies have also shown that lacebacks can provoke loss of anchorage (3,4). Irvine et al. (3) investigated the effectiveness of lacebacks ligatures in a randomized clinical trial in 62 adolescents with mean age of 13.7 years treated with first premolar extractions. Final records were taken after 6 weeks with the 0.018-inch stainless steel archwire. Laceback ligatures were tied from the first molar tube to the canine bracket. They concluded that the use of laceback ligatures created a statistically and clinically significant increase in the loss of posterior anchorage. Despite authors have used passive lacebacks, they should be considered as active once they were tightened to take up any apparent reduction in tension in the laceback at routine visits.

In another investigation (4), 15 subjects (mean age of 14 years and 11 months) were submitted to orthodontic treatment with fixed appliances and extraction of first premolars to solve crowding in the maxillary and lower arches. For canine distalization, superelastic NiTi close-coil spring was placed from the first molar to the canine generating 150 g of force on one side. Lacebacks made from 0.010-inch ligature wire were applied on the contralateral side. The coil or laceback allocations were randomly decided. No reference was found if active or passive lacebacks were used, but it could be consider that active lacebacks were tested since canines were distalized to allow incisors alignment, and lacebacks were reapplied at each appointment. Those authors concluded that posterior teeth moved anteriorly in both groups. However, the anchorage loss for the coil group (1.93 mm) was significantly different from the laceback group (0.70 mm).

Another point to be discussed regarding the force produced by lacebacks is the operator's experience and skills. A wide range of forces can be applied by different clinicians, considering different systems of space closure, and less experienced orthodontists tend to apply quite heavy forces (12). Khambay et al. (13) studied the magnitude and reproducibility of forces generated by clinicians during laceback placement, using a force-measuring typodont. The forces generated by clinicians ranged from 0 to 1131.88 gf, and the authors concluded there was a large inter-operator variation in the forces produced during laceback placement and few

operators applied similar forces when placing lacebacks on two separate occasions.

Considering now passive lacebacks, it was observed in the present study that the position of maxillary first molars remained unchanged, as observed in a previous clinical investigation (2). Analyzing the passive laceback group in the present study, it was possible to observe in some cases a space opening between canine and lateral incisor despite lacebacks having just been replaced in cases of ligature wire fractures. One hypothesis to explain this finding is the continuous reactivation of lacebacks with food pressure during mastication.

Based on this information, it should be considered that active and passive lacebacks need more specific definitions. Despite lacebacks having been found to be an effective method to retract canines, the force produced by active lacebacks can produce anchorage loss that must be considered in treatment planning when its use is indicated. Clinicians should also consider using 0.008-inch ligature wire in laceback placement.

Within the limitation of this study, it may be concluded that active laceback produced a mesial movement of the maxillary first molars that can be understood as anchorage loss during the leveling phase, and that passive laceback did not affect the position of these teeth. Also, active and passive lacebacks were effective in preventing incisors' proclination.

RESUMO

O objetivo deste estudo foi comparar os efeitos dos *lacebacks* ativos e passivos na posição ântero-posterior dos primeiros molares e dos incisivos centrais superiores durante a fase de nivelamento. Vinte e três indivíduos com má oclusão de Classes I e II foram tratados com extrações dos primeiros pré-molares utilizando aparelhos fixos pré-ajustados (bráquetes MBT 0,022"). A fase de nivelamento foi realizada somente com arcos de aço inoxidável. A amostra foi dividida em 2 grupos: 14 pacientes receberam *lacebacks* ativos (Grupo 1) e 9 pacientes receberam *lacebacks* passivos (Grupo 2). Os *lacebacks* foram feitos com fio de ligadura de 0,008" (0,20 mm). Telerradiografias laterais foram realizadas antes e após a fase de nivelamento. O teste t de Student foi aplicado para determinar as diferenças entre as médias de deslocamento entre os períodos pré e pós-nivelamento e para determinar as diferenças entre os grupos. No Grupo 1, o primeiro molar mostrou uma movimentação mesial significativa enquanto nenhuma alteração foi observada no Grupo 2. Em ambos os grupos, os incisivos centrais superiores foram lingualizados. Em conclusão, os *lacebacks* ativos produziram perda de ancoragem nos primeiros molares superiores enquanto que os *lacebacks* passivos não afetaram a posição destes dentes. *Lacebacks* ativos e passivos foram efetivos para prevenir a vestibularização dos incisivos centrais superiores.

REFERENCES

1. McLaughlin RP, Bennett JC, Trevisi HJ. Systemized orthodontic treatment mechanics. 1st ed. Saint Louis: Mosby International Ltd; 2001.
2. Usmani T, O'Brien KD, Worthington HV, Derwent S, Fox D, Harrison S, et al.. A randomized clinical trial to compare the effectiveness of canine lacebacks with reference to canine tip. *J Orthod* 2002;29:281-286.
3. Irvine R, Power S, McDonald F. The effectiveness of laceback ligatures: a randomized controlled clinical trial. *J Orthod* 2004;31:303-311.
4. Sueri MY, Turk T. Effectiveness of laceback ligatures on maxillary canine retraction. *Angle Orthod* 2006;76:1010-1014.
5. Wang Y, Jian F, Lai W, Zhao Z, Yang Z, Liao Z, et al.. Initial arch wires for alignment of crooked teeth with fixed orthodontic braces. *Cochrane Database Syst Rev* 2010;14:CD007859.
6. Wook H, Seung-Hak B. Friction properties according to vertical and horizontal tooth displacement and bracket type during initial leveling and alignment. *Angle Orthod* 2011;81:653-661.
7. Leonardi R, Annunziata A, Caltabiano M. Landmark identification error in posteroanterior cephalometric radiography. A systematic review. *Angle Orthod* 2008;78:761-765.
8. Batagel J. A comparative assessment of cephalometric errors. *Eur J Orthod* 1993;15:305-314.
9. Trpkova B, Major P, Prasad N, Nebbe B. Cephalometric landmarks identification and reproducibility: a meta analysis. *Am J Orthod Dentofacial Orthop* 1997;112:165-170.
10. Ferreira JTL, Telles CS. Evaluation of the reliability of computadorized profile cephalometric analysis. *Braz Dent J* 2002;13:201-204.
11. Fleming PS, Johal A, Pandis N. The effectiveness of laceback ligatures during initial orthodontic alignment: a systematic review and meta-analysis. *Eur J Orthod*. 2012 [Epub ahead of print].
12. Natrass C, Ireland AJ, Sherriff M. An investigation into the placement of force delivery systems and the initial forces applied by clinicians during space closure. *Br J Orthod* 1997;24:127-131.
13. Khambay BS, McHugh S, Millett DT. Magnitude and reproducibility of forces generated by clinicians during laceback placement. *J Orthod* 2006;33:270-275.

Received December 2, 2011

Accepted May 2, 2012