



**Universidade de São Paulo**

**Biblioteca Digital da Produção Intelectual - BDPI**

---

Departamento de Odontopediatria , Ortodontia e Saúde Coletiva - Artigos e Materiais de Revistas Científicas - FOB/BAO  
FOB/BAO

---

2013

# Evaluation of facial esthetics in rehabilitated adults with complete unilateral cleft lip and palate

---

ISRN Plastic Surgery, New York, v. 2013, p. 357568, 2013  
<http://www.producao.usp.br/handle/BDPI/33339>

*Downloaded from: Biblioteca Digital da Produção Intelectual - BDPI, Universidade de São Paulo*

## Clinical Study

# Evaluation of Facial Esthetics in Rehabilitated Adults with Complete Unilateral Cleft Lip and Palate: A Comparison between Professionals with and without Experience in Oral Cleft Rehabilitation

Araci Malagodi Almeida,<sup>1</sup> Leopoldino Capelozza Filho,<sup>2</sup> Flavio Mauro Ferrari Junior,<sup>3</sup> Rita de Cassia Moura Carvalho Lauris,<sup>1</sup> and Daniela Gamba Garib<sup>4</sup>

<sup>1</sup> Department of Orthodontics, Hospital for Rehabilitation of Craniofacial Anomalies, University of São Paulo (HRAC/USP), Bauru, SP, Brazil

<sup>2</sup> Universidade do Sagrado Coração, Bauru, SP, Brazil

<sup>3</sup> Private Practice, Bauru, SP, Brazil

<sup>4</sup> Hospital for Rehabilitation of Craniofacial Anomalies (HRAC/USP) and Bauru Dental School, University of São Paulo, Bauru, SP, Brazil

Correspondence should be addressed to Araci Malagodi Almeida; [amalagodi@yahoo.com.br](mailto:amalagodi@yahoo.com.br)

Received 14 October 2012; Accepted 30 October 2012

Academic Editors: A. S. Halim, Z. Panthaki, and D. D. Park

Copyright © 2013 Araci Malagodi Almeida et al. This is an open access article distributed under the Creative Commons Attribution License, which permits unrestricted use, distribution, and reproduction in any medium, provided the original work is properly cited.

**Objectives.** The aim of this study was to evaluate the facial esthetics of White-Brazilian adults with complete unilateral cleft lip and palate (UCLP) rehabilitated at a single center. **Design.** 30 patients (13 females; 17 males; mean age of 24.0 years), rehabilitated at a single center, were photographed and evaluated by 25 examiners, 5 orthodontists, and 5 plastic surgeons dealing with oral clefts, 5 orthodontists and 5 plastic surgeons with no experience in the cleft treatment, and 5 laymen. Their facial profiles were classified into esthetically unpleasant, esthetically acceptable, and esthetically pleasant. **Results.** Orthodontists dealing with oral clefts classified the majority of the sample as esthetically pleasant. Plastic surgeons dealing with oral cleft, orthodontists, and plastic surgeons without experience with oral clefts classified most of the sample as esthetically acceptable. Laymen evaluation also considered the majority of the sample as esthetically acceptable. **Conclusions.** The facial profiles of rehabilitated adults with UCLP were classified mostly as esthetically acceptable, with variations among the categories of examiners. The examiners dealing with oral clefts gave higher scores to the facial esthetics when compared to professionals without experience in oral clefts and laypersons, probably due to their knowledge of the limitations involved in the rehabilitation process.

## 1. Introduction

Cleft lip and palate is the most common type of craniofacial anomalies [1]. Among the different types of cleft, complete cleft lip and palate (CLP) is the most severe manifestation. It affects the facial esthetics, the speech, and hearing function, contributing to psychosocial problems [2–4]. The global rehabilitation of individuals with CLP is extremely important for social inclusion and psychological health; therefore, one of the main goals of rehabilitation is reaching good facial esthetics and speech intelligibility.

As far as facial beauty is concerned, orthodontists and plastic surgeons have long searched for the appropriate achievement of facial esthetics in the rehabilitation of oral clefts. Many features contribute to facial beauty such as maxillomandibular relation, facial proportions and symmetry, the skin aspect, the color of the eyes, and teeth shape and position, to mention just a few [5–7]. Besides the shape of the nose and lips, maxillary growth deficiency also contributes to esthetic impairment in individuals with CLP [8–10]. The concept of beauty varies according to the observer's opinion, ethnicity, age, and cultural patterns suitable for a given

population at a given time [11]. Additionally, professionals and laypersons may evaluate facial esthetics differently. Chetpakdechit et al. [12] evaluated the facial esthetic of patients with complete bilateral cleft lip and palate after the orthodontic treatment, comparing professional and non-professional examiners. A web-based questionnaire with 12 photo sets was answered by 25 orthodontists and 20 young adults. They had to address the first three unpleasant features in each photograph and classified the facial esthetics as bad, good, fairly good, or excellent. The three features first noticed by the orthodontists were: the upper lip, the nose, and the scar, while the young adults reported the teeth, the upper lip, and occlusion/alignment of the teeth. The authors concluded that orthodontists were generally less critical than laypersons in their evaluations. One of the hypotheses of their study was that professionals related and not related to cleft rehabilitation may assess facial esthetics differently.

The rehabilitation protocol for CLP varies among different centers. The World Health Organization recommends that the protocol for CLP rehabilitation be rational and efficient, containing only procedures with positive long term impact [13]. The assessment of the final facial esthetics of patients with CLP contributes to the evaluation of the quality of treatment delivered in a single center. Therefore, the aim of this study was to subjectively evaluate the pleasantness of the facial profile in rehabilitated adults with complete unilateral cleft lip and palate. Additionally, this study aimed at comparing the facial assessment of professionals related and not related to cleft rehabilitation.

## 2. Materials and Methods

This project was approved by the Ethical Committee at the Hospital for Rehabilitation of Craniofacial Anomalies, University of São Paulo (HRCA-USP) and informed consent was obtained. The study sample comprised 30 rehabilitated adults with unilateral complete cleft lip and palate (UCLP), consecutively selected at the HRCA-USP. The inclusion criteria were: White-Brazilians, absence of syndromes, complete rehabilitation performed only at the HRCA-USP. The sample included males ( $n = 17$ ) and females ( $n = 13$ ) with a mean age of 24 years (range: 17.2 to 30.7 years). The cleft was present more commonly in the left side, with a proportion of 3 : 1.

All patients were operated by the plastic surgeon team, composed of 12 surgeons, following the current protocol adopted by the institution which includes the lip repair with Millard technique at 3 to 6 months of age and the palate repair with Von Langenback technique at 12 months of age. The protocol also includes the secondary bone graft procedure at 10 to 11 years of age and orthognathic surgery at 18 years of age for cases classified as Goslon 4 and 5. Secondary lip repair is performed around 7 years of age and the secondary rhinoplasty is performed with 14 years of age or after the orthognathic surgery. Nine out of 30 patients of the sample were submitted to orthognathic surgery and the remaining 21 had only the orthodontic treatment.

TABLE 1: Kendall's coefficient of concordance ( $W$ ) of the judges in the evaluation of photographs of the cleft side.

Category	$W$	$P$
ODC	0,75	0,000*
ONC	0,74	0,000*
PSDC	0,55	0,000*
PSNC	0,70	0,000*
L	0,63	0,000*

\*Statistically significant correlation ( $P < 0.05$ ); ODC: orthodontists dealing with cleft; ONC: orthodontists with no experience cleft; PSDC: plastic surgeons dealing with cleft; PSNC: plastic surgeons with no experience on cleft; L: laymen.

The photographs were taken using a standardized method. The patients were positioned standing in a cephalostat with the natural head position, in front of a white background. An umbrella type flash with photocell [14] was placed 1.3 m from the cephalostat and 0.51 m above the ground. The distance between the light source and the cephalostat was 0.80 m. A Nikon Coolpix 995 digital camera was placed 0.87 centimeters away from the wall and its support for height adjustment ranged 1 : 02 to 2 : 18 meters.

Patients were instructed to have the teeth occluded and the lips relaxed. Images of the facial profile on the right and left side were performed for each patient. The images obtained were transferred to a Hewlett Packard model Brio/Intel Pentium II MMX 300 MHz with 64 MB of RAM and printed with a 10 × 15 cm size.

The photographs were evaluated by twenty-five examiners divided into 5 groups: 5 orthodontists with experience in the rehabilitation of oral clefts (ODC), 5 orthodontists with no experience in the cleft treatment (ONC), 5 plastic surgeons with experience in oral cleft (PSDC), 5 plastic surgeons with no experience in cleft (PSNC) and 5 laymen (1 veterinarian, 1 engineer, two lawyers and 1 agronomist). All the professionals with experience in oral cleft worked at HRCA-USP.

In order to evaluate the facial profile, each examiner received a photo album with the sample of 60 photographs. Facial profiles photographs of each patient were positioned in a same page for simultaneous visualization. No identification of the side of the cleft was provided. The raters were instructed to perform the assessment within approximately 30 seconds for each photograph, assigning a score from 1 to 9 according to Reis et al. [15].

Esthetically unpleasant profile—scores 1, 2, and 3

Esthetically acceptable profile—scores 4, 5, and 6

Esthetically pleasant profile—scores 7, 8, and 9

When the score assigned was 1 to 3, the examiner was requested to identify the facial structures responsible for the unpleasant aspect. The photographs were evaluated twice by the 25 examiners, with an interval of 30 days between both evaluations.

TABLE 2: Kendall's coefficient of concordance ( $W$ ) of the judges for the evaluation of the photographs of noncleft side.

Category	$W$	$P$
ODC	0,74	0,000*
ONC	0,67	0,000*
PSDC	0,47	0,000*
PSNC	0,70	0,000*
L	0,61	0,000*

\*Statistically significant concordance ( $P < 0.05$ ); ODC: orthodontists dealing with cleft; ONC: orthodontists with no experience cleft; PSDC: plastic surgeons dealing with cleft; PSNC: plastic surgeons with no experience on cleft; L: laymen.

TABLE 3: Comparison between the evaluation of the cleft and noncleft sides (Wilcoxon test).

Category	$T$	$Z$	$P$
ODC	13,5	0,630	0,529 ns
ONC	3,5	1,468	0,142 ns
PSDC	23,0	1,572	0,116 ns
PSNC	23,0	0,000	1,000 ns
L	19,5	2,508	0,012*

\*Statistically significant difference ( $P < 0.05$ ); Ns: no statistically significant difference.

$T$ : the Wilcoxon test statistic;  $Z$ : normal distribution of probabilities. ODC: orthodontists dealing with cleft; ONC: orthodontists with no experience cleft; PSDC: plastic surgeons dealing with cleft; PSNC: plastic surgeons with no experience on cleft; L: laymen.

### 3. Data Analysis

The mean, median, and quartiles of the scores were calculated for each patient. The Wilcoxon Test was used for comparing the evaluation of the cleft and noncleft sides. Kendall Coefficient of Concordance was used to evaluate the interexaminer agreement. Friedman test and Student-Newman-Keuls Test for multiple comparisons were used for evaluating differences between the categories of examiners. The significance level regarded was 5%.

### 4. Results

Tables 1 and 2 show the interobserver agreement for the cleft side and noncleft side, respectively. Kendall coefficients of concordance ( $W$ ) varied from 0.47 to 0.75 and showed a statistically significant agreement.

Figures 1 and 2 show the scores for facial esthetics obtained for each category of examiners, respectively, for the cleft side and noncleft side profile. Orthodontists and plastic surgeons with experience in oral clefts assigned the highest scores for facial esthetics compared to the other examiners.

Table 3 shows the comparison between the cleft and noncleft sides for the first evaluation. No difference between the scores of the cleft and noncleft sides was observed for all the categories of examiners, with the exception of laypersons. Laypersons gave a slightly worse score for the cleft side (mean = 4.9) compared to noncleft side (mean = 5.3).

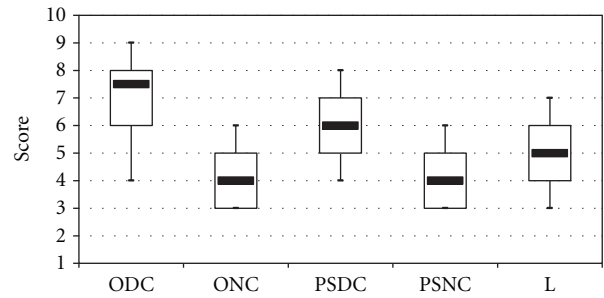


FIGURE 1: Mean, first quartile, third quartile, minimum, and maximum of the scores for each category of raters, in the cleft side profile. (ODC: orthodontists dealing with cleft; ONC: orthodontists with no experience cleft; PSDC: plastic surgeons dealing with cleft; PSNC plastic surgeons with no experience on cleft; L: laymen.).

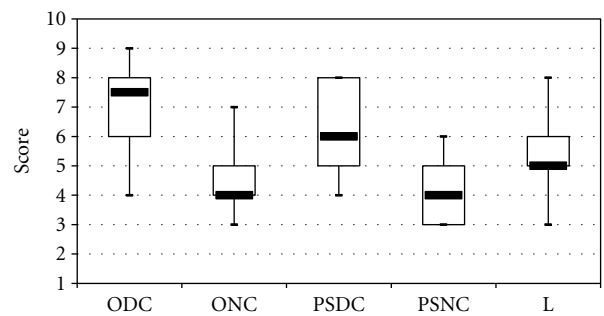


FIGURE 2: Mean, first quartile, third quartile, minimum, and maximum of the scores for each category of raters, in the noncleft side profile. (ODC: orthodontists dealing with cleft; ONC: orthodontists with no experience cleft; PSDC: plastic surgeons dealing with cleft; PSNC plastic surgeons with no experience on cleft; L: laymen.).

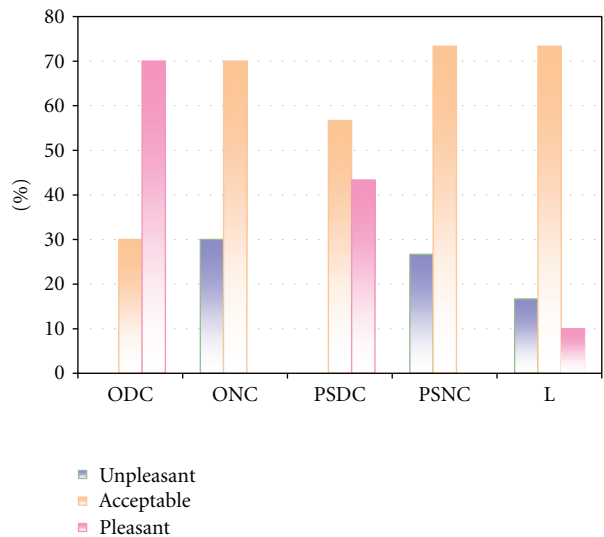


FIGURE 3: Distribution of the classification of facial esthetics for the sample for each category of raters.

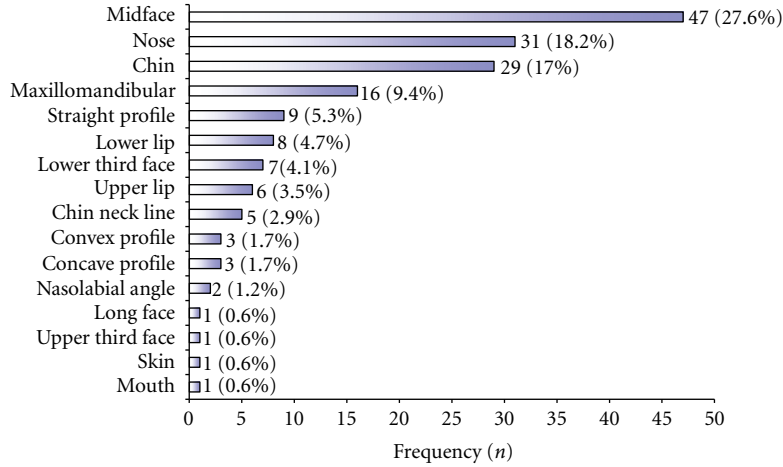


FIGURE 4: Facial structures cited by raters as responsible for the esthetically unpleasant profiles.

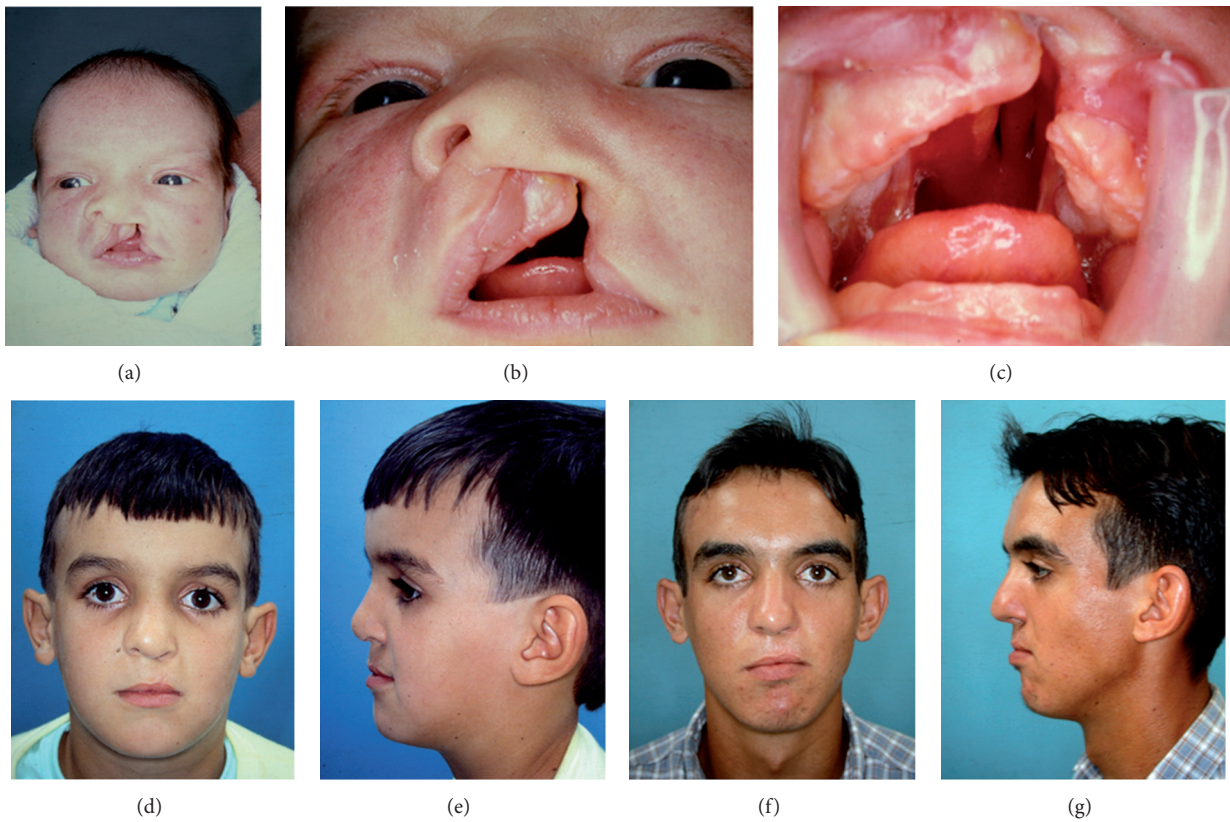

FIGURE 5: Patient considered esthetically acceptable. (a), (b), and (c) Before the primary surgeries; (d) and (e) before orthodontic treatment; (f) and (g) at the end of the rehabilitation.

There was a statistical significant difference between the categories of examiners for the evaluation of facial esthetics (Friedman test,  $\chi^2 = 96,13$ ;  $P = 0,000$ ). The Student-Newman-Keuls test for multiple comparisons identified significant differences between all the categories of examiners, except for the plastic surgeons (PSNC) and orthodontists (ONC) with no experience with oral clefts.

Figure 3 shows the classification of facial esthetics for the sample according to Reis et al. [15], for each category of examiners. Esthetically acceptable profile was the most prevalent classification in the sample for all the category of examiners, with the exception of orthodontists with experience in cleft rehabilitation, who considered the profile esthetically pleasant for the majority of the patients.

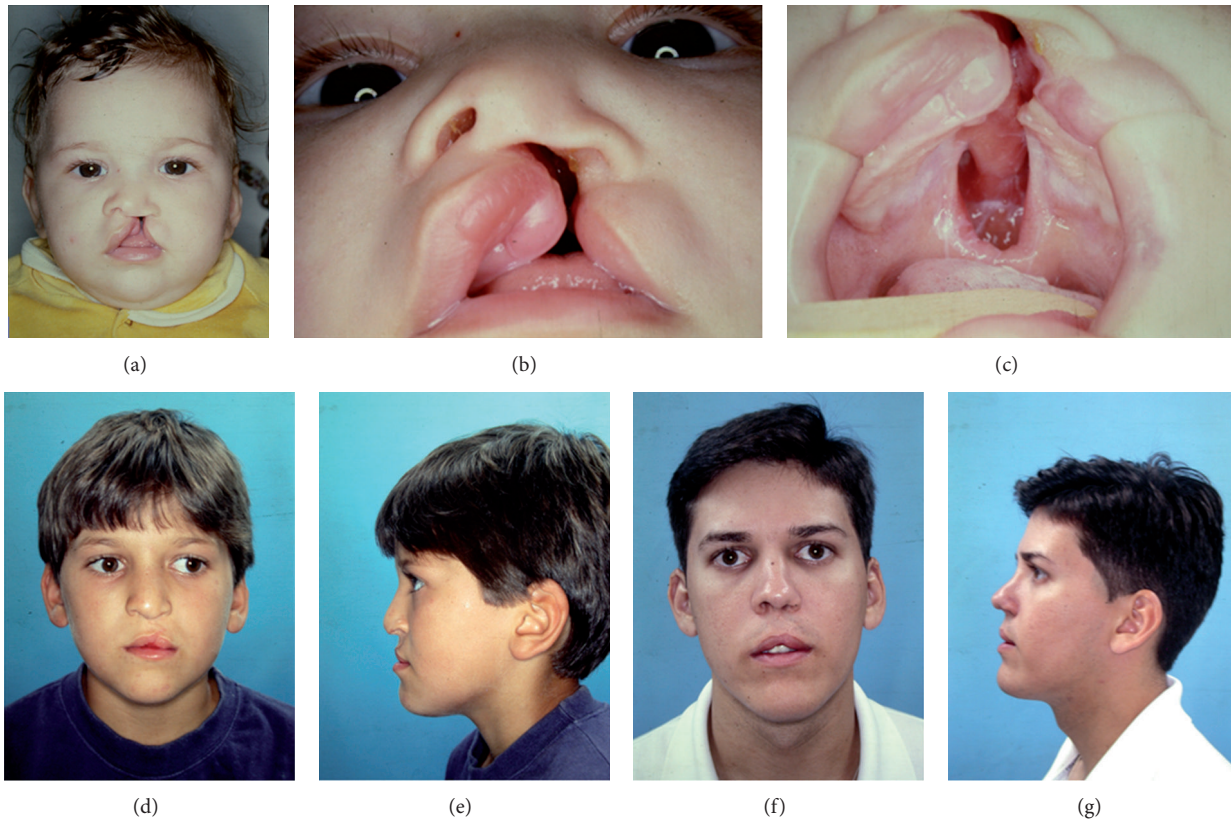

FIGURE 6: Patient considered esthetically pleasant. (a), (b) and (c) Before the primary surgeries; (d) and (e) before orthodontic treatment; (f) and (g) at the end of the rehabilitation.

The midface and nose were frequently cited as the facial structure responsible for the esthetically unpleasant profiles (Figure 4).

## 5. Discussion

The concept of beauty is very subjective and varies individually. The evaluation of facial esthetics varies depending on the examiner [11]. When evaluating the facial esthetics of patients with cleft lip and palate, besides the field of the professional, the experience in cleft rehabilitation also might have an influence. Despite being a subjective evaluation process, there was an agreement among the examiners regarding the concept of beauty in the first and second evaluation in this study.

The results showed a similar esthetic evaluation of the facial profile of the cleft and noncleft sides (Table 3). Although the cleft was unilateral, the facial esthetics at the end of the rehabilitation is similar on both sides of the face. With the exception of the laypersons, most of the examiners have not capture differences between the sides with and without cleft. On the other hand, laypersons have scored the cleft and noncleft side differently. Maybe that's the most important opinion because it reflects the way in which society evaluates the rehabilitation of patients with cleft. Actually, the facial structure commonly cited as responsible for unpleasant profiles was the midface (Figure 4). The maxillary deficiency

is commonly observed in patients with unilateral complete cleft lip and palate and is apparent on both sides of the face [16, 17]. Regarding the cephalometric aspect, the maxilla is smaller and presents a clockwise rotation. Although not as dramatically as the maxilla, the mandible is also smaller, with its base and ramus decreased, increased gonial angle and posterior displacement. The profile can become straight or concave during the growth phase. Maxillary sagittal deficiency influences the nasolabial angle, the nasal apex, and the zygomatic projection. During the evaluation of the facial profile, the maxillary deficiency seems to overcome the presence of the lip scar. Laypersons were the only category of examiners who assigned statistically different scores for the cleft and noncleft sides. Laypersons were sensitive to the presence of the cleft attributing lower scores to the cleft side profile.

The professionals experienced in the rehabilitation of cleft lip and palate had an influence on the evaluation of the final facial esthetics. Orthodontists and plastic surgeons dealing with cleft lip and palate assigned the highest scores for the profile esthetics (means of 7.5 and 6.0, resp.; Figures 1 and 2). Laypersons assigned an intermediary score (mean of 5.0). The lowest scores were assigned by orthodontists and plastic surgeons without experience in the rehabilitation of oral clefts, who assigned a mean score of 4.0. Professionals dealing with the rehabilitation of CLP are aware of the limitations of the treatment. This explains the higher scores

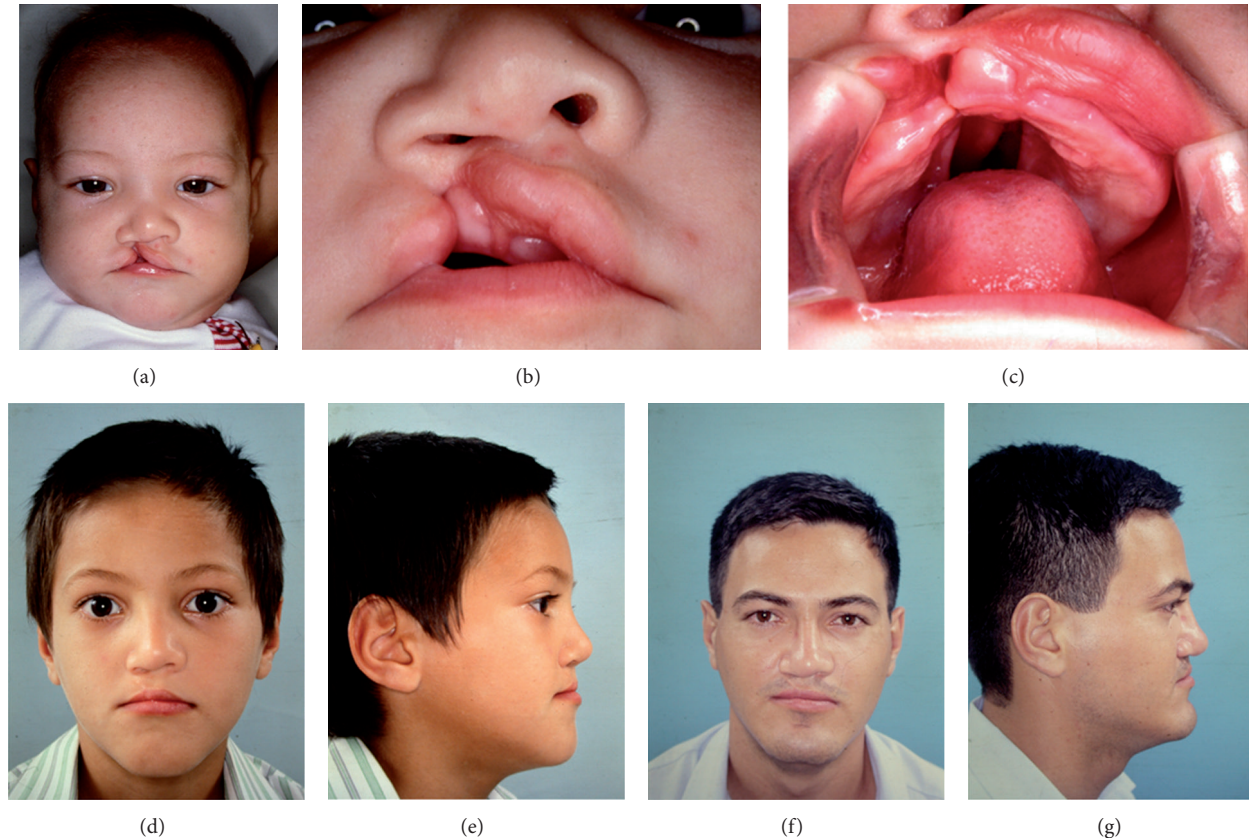

FIGURE 7: Patient considered esthetically unpleasant. (a), (b) and (c) Before the primary surgeries; (d) and (e) before orthodontic treatment; (f) and (g) at the end of the rehabilitation.

attributed by CLP professionals when evaluating the final facial esthetics.

Interestingly, plastic surgeons of the hospital (PSDC) were more demanding in their assessment than the hospital orthodontists (Figures 1 and 2). The possible explanation is that the orthodontists follow facial growth and are more familiar with the midface deficiency. The orthodontists with experience in CLP, particularly, were more lenient with the esthetic judgment. In a study of the satisfaction of professionals with the treatment results of patients with CLP [18], plastic surgeons had a lesser frequency (39%) of satisfaction when compared to orthodontists (58.5%). In our study, Orthodontists and plastic surgeons without experience in cleft rehabilitation were equally more strict than laypersons in their appreciation of facial esthetics. These professionals were pursuing perfection at the end of rehabilitation of patients with CLP.

When considering the classification of Reis et al. [15], most of the sample was classified as esthetically acceptable for most of the examiners including laypersons and professionals with no experience in the rehabilitation of CLP (Figures 3 and 5). The orthodontists dealing with CLP were the only group of examiners who classified most of the sample as esthetically pleasant (Figures 3 and 6) for the reasons previously discussed, while one third of the sample was classified as esthetically unpleasant for professional not related to CLP

(Figure 7). Laypersons evaluated the profiles as esthetically unpleasant only in 20% of the sample. On the other hand, professionals related to CLP did not evaluate any profile as unpleasant (Figure 3). In comparison with a study with noncleft patients [15], the facial esthetics of 100 young adults without orthodontic treatment was classified as esthetically unpleasant, esthetically acceptable, and esthetically pleasant in 8%, 89%, and 3% of the sample, respectively.

Laypersons assessment may correspond to the society view of our rehabilitated patients with CLP. The majority of the sample was evaluated as esthetically acceptable (73.3%) for laypersons (Figure 3). Patients with complete unilateral cleft lip and palate rehabilitated within the contemporary possibilities, including alveolar bone graft and orthognathic surgery, still show a distinct facial profile morphology compared to noncleft individuals. The orthodontist related to CLP seems to be aware of these differences in their evaluation of esthetics.

It is important to highlight that beauty is influenced by numerous subjective factors such as color and texture of the skin, the thickness of the upper and lower lips, morphology and color of the eyes and hair style [5, 6]. These features completely independent of the presence of the cleft and at the same time might have an influence in the assessment of beauty of individuals with CLP. Different facial structures were cited as responsible for the esthetically unpleasant

profiles including midface, nose, and chin (Figure 4). These findings suggest that maxillary and chin advancement with the orthognatic surgery would be highly desirable procedures in patients with moderate/severe maxillary deficiency and mandibular retrusion. Additionally, secondary rhinoplasty would be a very important procedure in the esthetical point of view.

Future studies should also consider the evaluation of esthetics in the facial frontal view. Additionally, the evaluation of facial esthetics should be conduct in patients with rehabilitated complete bilateral cleft lip and palate.

## 6. Conclusion

The facial profiles of rehabilitated adults with UCLP were classified mostly as esthetically acceptable, with variations among the categories of examiners. The examiners dealing with oral clefts classified the facials esthetics with higher scores compared to professional without experience in oral clefts and layperson, probably, due to their knowledge of the limitations involved in the rehabilitation process.

## References

- [1] W. H. O. H. Programme, "Global strategies to reduce the health-care burden of craniofacial anomalies," in *Report of WHO Meetings on International Collaborative Research on Craniofacial Anomalies*, World Health Organization, Geneva, Switzerland; Human Genetics Programme, Management of Noncommunicable Diseases, Park City, Utah, USA, 2002.
- [2] E. Clifford, E. C. Crocker, and B. A. Pope, "Psychological findings in the adulthood of 98 cleft lip-palate children," *Plastic and Reconstructive Surgery*, vol. 50, no. 3, pp. 234–237, 1972.
- [3] J. Garcia, C. Neme, and M. Chinelatto, "Bodyimage in adult patients with cleft lip palate: an analysis through human figure drawing," *Brazilian Journal of Dysmorphology and Speech-Hearing Disorders*, vol. 2, no. 2, pp. 17–26, 1999.
- [4] A. Heller, W. Tidmarsh, and I. B. Pless, "The psychosocial functioning of young adults born with cleft lip or palate. A follow-up study," *Clinical Pediatrics*, vol. 20, no. 7, pp. 459–465, 1981.
- [5] G. W. Arnett and R. T. Bergman, "Facial keys to orthodontic diagnosis and treatment planning. Part I," *American Journal of Orthodontics and Dentofacial Orthopedics*, vol. 103, no. 4, pp. 299–312, 1993.
- [6] G. William Arnett and R. T. Bergman, "Facial keys to orthodontic diagnosis and treatment planning—part II," *American Journal of Orthodontics and Dentofacial Orthopedics*, vol. 103, no. 5, pp. 395–411, 1993.
- [7] G. Janson, N. C. Branco, T. M. Fernandes, R. Sathler, D. Garib, and J. R. Lauris, "Influence of orthodontic treatment, midline position, buccal corridor and smile arc on smile attractiveness," *The Angle orthodontist*, vol. 81, no. 1, pp. 153–161, 2011.
- [8] Z. Q. Chen, J. Wu, and R. J. Chen, "Sagittal maxillary growth pattern in unilateral cleft lip and palate patients with unrepaired cleft palate," *Journal of Craniofacial Surgery*, vol. 23, no. 2, pp. 491–493, 2012.
- [9] Y. T. Chiu and Y. F. Liao, "Is cleft severity related to maxillary growth in patients with unilateral cleft lip and palate?" *The Cleft Palate-Craniofacial Journal*, vol. 49, no. 5, pp. 535–540, 2010.
- [10] P. J. P. M. Nollet, A. M. Kuijpers-Jagtman, A. Chatzigianni et al., "Nasolabial appearance in unilateral cleft lip, alveolus and palate: a comparison with Eurocleft," *Journal of Cranio-Maxillofacial Surgery*, vol. 35, no. 6-7, pp. 278–286, 2007.
- [11] W. Morris, "An orthodontic view of dentofacial esthetics," *Compendium*, vol. 15, no. 3, pp. 378–382, 1994.
- [12] W. Chetpakdeechit, J. Wahss, T. Woo, M. Hugander, B. Mohlin, and C. Hagberg, "Esthetic views on facial and dental appearance in young adults with treated bilateral cleft lip and palate (BCLP). A comparison between professional and non-professional evaluators," *Swedish Dental Journal*, vol. 35, no. 3, pp. 151–157, 2011.
- [13] W. C. Shaw, V. Brattström, K. Mølsted, B. Prah-Andersen, C. T. Roberts, and G. Semb, "The eurocleft study: intercenter study of treatment outcome in patients with complete cleft lip and palate. Part 5: discussion and conclusions," *Cleft Palate-Craniofacial Journal*, vol. 42, no. 1, pp. 93–98, 2005.
- [14] J. N. Chitarra, L. G. Matos, E. M. F. Melo, and E. B. Leite, "O uso da fotocélula para eliminação de sombra nas fotografias faciais para documentação odontológica. The use of the photocell to eliminate the shadow in facial photographs for dental documentation," *Revista Dental Press de Ortodontia e Ortopedia Maxilar*, vol. 8, no. 4, pp. 59–62, 2003.
- [15] S. A. B. Reis, J. Abrão, L. C. Filho, and C. A. A. Claro, "Análise facial subjetiva," *Revista Dental Press de Ortodontia e Ortopedia Maxilar*, vol. 11, no. 5, pp. 159–172, 2006.
- [16] L. Capelozza Filho, O. Silva Filho, and E. Petrelli, "Fissuras lábio-palatais," in *Ortodontia para Fonoaudiologia*, E. Petrelli, Ed., pp. 195–239, Lovise, Curitiba, Brazil, 1992.
- [17] O. G. da Silva Filho, A. L. Ramos, and R. C. Abdo, "The influence of unilateral cleft lip and palate on maxillary dental arch morphology," *Angle Orthodontist*, vol. 62, no. 4, pp. 283–290, 1992.
- [18] J. H. Noar, "A questionnaire survey of attitudes and concerns of three professional groups involved in the cleft palate team," *The Cleft Palate-Craniofacial Journal*, vol. 29, no. 1, pp. 92–95, 1992.