



**Universidade de São Paulo**

**Biblioteca Digital da Produção Intelectual - BDPI**

---

Departamento de Oftalmologia, Otorrinolaringologia e Cirurgia da Cabeça e Pescoço - FMRP/ROO    Artigos e Materiais de Revistas Científicas - FMRP/ROO

---

2012

# Sulcus anatomy and diameter in pseudophakic eyes and correlation with biometric data: Evaluation with a 50 MHz ultrasound biomicroscope

---

JOURNAL OF CATARACT AND REFRACTIVE SURGERY, NEW YORK, v. 38, n. 6, pp. 986-991, JUN, 2012

<http://www.producao.usp.br/handle/BDPI/42343>

*Downloaded from: Biblioteca Digital da Produção Intelectual - BDPI, Universidade de São Paulo*

# Sulcus anatomy and diameter in pseudophakic eyes and correlation with biometric data: Evaluation with a 50 MHz ultrasound biomicroscope

Katrin Petermeier, MD, FEBO, Daniela Suesskind, MD, FEBO, Elke Altpeter, MD, Andreas Schatz, MD, André Messias, MD, Florian Gekeler, MD, Peter Szurman, MD

**PURPOSE:** To evaluate the sulcus anatomy and possible correlations between sulcus diameter and white-to-white (WTW) diameter in pseudophakic eyes, data that may be important in the stability of add-on intraocular lenses (IOLs).

**SETTING:** University Eye Hospital, Tuebingen, Germany.

**DESIGN:** Case series.

**METHODS:** In pseudophakic eyes, the axial length (AL) and horizontal WTW were measured by the IOLMaster device. Cross-sectional images were obtained with a 50 MHz ultrasound biomicroscope on the 4 meridians: vertical, horizontal (180 degrees), temporal oblique, and nasal oblique. Sulcus-to-sulcus (STS), angle-to-angle (ATA), and sclera-to-sclera (ScTSc) diameters were measured. The IOL optic diameter (6.0 mm) served as a control. To test reliability, optic measurements were repeated 5 times in a subset of eyes.

**RESULTS:** The vertical ATA and STS diameters were statistically significantly larger than the horizontal diameter ( $P=.0328$  and  $P=.0216$ , respectively). There was no statistically significant difference in ScTSc diameters. A weak correlation was found between WTW and horizontal ATA ( $r = 0.5766$ ,  $P<.0001$ ) and between WTW and horizontal STS ( $r = 0.5040$ ,  $P=.0002$ ). No correlation was found between WTW and horizontal ScTSc ( $r = 0.2217$ ,  $P=.1217$ ).

**CONCLUSIONS:** The sulcus anatomy had a vertical oval shape with the vertical meridian being the largest, but it also had variation in the direction of the largest meridian. The WTW measurements showed a weak correlation with STS. In pseudophakic eyes, Soemmerring ring or a bulky haptic may affect the ciliary sulcus anatomy.

**Financial Disclosure:** No author has a financial or proprietary interest in any material or method mentioned.

*J Cataract Refract Surg* 2012; 38:986–991 © 2012 ASCRS and ESCRS

In 1993, Gayton and Sanders<sup>1</sup> first described the piggyback technique to provide adequate intraocular lens (IOL) power in a case of microphthalmos. In their technique, both IOLs are placed in the capsular bag. The technique was then extended to correct pseudophakic spherical<sup>2</sup> or astigmatic<sup>3,4</sup> refractive errors. Because of the position of both IOLs in the capsular bag, complications such as interlenticular opacification<sup>5–7</sup> and changes in refractive results due to shift of the second IOL<sup>8,9</sup> were observed. Thus, the authors recommended implanting the second IOL in the ciliary sulcus. In the past, even multifocal IOLs were

implanted in the sulcus to provide uncorrected near visual acuity.<sup>8,9</sup> However, these IOLs were not designed to be placed in the sulcus, and iris capture of the second IOL<sup>10</sup> or pupillary block with consequent glaucoma<sup>11</sup> have been reported.

In the past few years, thinner IOLs with a wider haptic diameter and small dioptric power to be placed in the sulcus in cases of pseudophakia became available.<sup>12</sup> Most of the new IOLs are called add-on IOLs to differentiate them from the former piggyback IOLs, which were not specifically designed for the sulcus. Add-on IOLs are now available not only to correct

spherical errors but also to correct astigmatism using toric designs and to provide near visual acuity without glasses using multifocal designs.<sup>12-14</sup> These IOLs have become part of refractive surgery and are accompanied by high patient expectations. To meet these expectations, correct IOL power calculation, IOL rotational stability, and a predictable IOL position without unexpected vault are necessary. These can be achieved only if the anatomic structures of the sulcus, especially the sulcus-to-sulcus (STS) diameter in pseudophakic eyes, are known. The IOL must fit perfectly to prevent it from rotating or shifting forward or backward due to insufficient sulcus support.

The only accurate and commonly available method to measure sulcus diameter is 50 MHz or 35 MHz ultrasound biomicroscopy (UBM). Surprisingly, to our knowledge, no data on the STS diameter in pseudophakic patients have been published. In contrast, many studies<sup>15-21</sup> report the sulcus anatomy in young phakic patients with the goal of optimizing the sizing and vault of posterior chamber phakic IOLs. Other studies<sup>22,23</sup> report the sulcus anatomy in aphakic eyes with a scleral-fixated IOL to evaluate and optimize the IOL position.

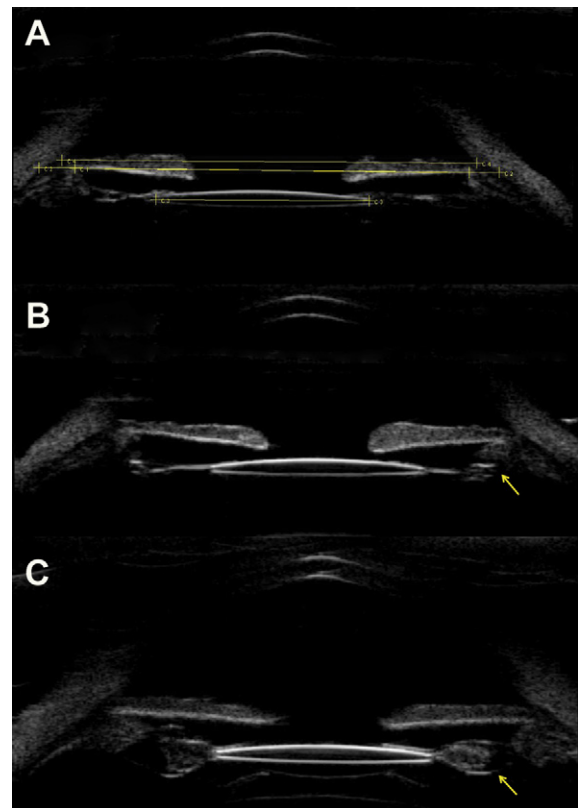
The aim of this study was to evaluate the sulcus anatomy, especially its diameter, in pseudophakic eyes and assess a possible correlation with biometry data, such as the white-to-white (WTW) diameter and axial length (AL). For this, we used a 50 MHz UBM system (Aviso, Quantel Medical), which shows the full view of the anterior chamber but has a higher resolution than 35 MHz UBM.

## PATIENTS AND METHODS

Pseudophakic eyes with no other ocular disease were evaluated. The AL and horizontal WTW distances were measured with the IOLMaster device (Carl Zeiss Meditec AG). Topical oxybuprocaine hydrochloride (Conjuncain) was instilled to anesthetize the cornea before measurement. An eyelid

retractor was placed, and a visco ophthalmic gel (carbomer) was applied to protect the cornea before the ultrasound gel was applied.

All eyes were examined by the same experienced physician (K.P.). The patient, in a reclined position, was asked to fixate with the fellow eye on a ceiling target (approximate height 4 m) to maintain fixation and avoid accommodation; pupils were left undilated. Diameters of the ciliary sulcus were measured using a UBM system equipped with a 50 MHz transducer. The probe of the 50 MHz transducer enables an exploration width of 16.0 mm with up to 35  $\mu\text{m}$  of axial resolution and 60  $\mu\text{m}$  of lateral resolution in the anterior segment and penetration of 9.0 to 11.0 mm. Cross-sectional images were obtained on the following 4 meridians: vertical (up-down 90 degrees), horizontal (nasal-temporal 180 degrees), nasal oblique (temporal down-nasal up: 45 degrees left eye; 135 degrees right eye), and temporal oblique (temporal up-nasal down: 135 degrees left eye; 45 degrees right eye). The STS, angle-to-angle (ATA), and sclera-to-sclera (ScTSc) diameters were measured offline in the images with the widest pupil diameter (Figure 1, A). The ScTSc diameter was measured at the level of the ciliary sulcus to determine the maximum inner diameter at the sulcus level. The diameter of the IOL optic served as control to ensure centration of the measurement. In a subset of eyes, measurements of the IOL diameter were performed 5 independent times to assess the accuracy and repeatability of this method.



**Figure 1.** A: Example of a pseudophakic eye with the ATA, STS, and ScTSc diameters and diameter of the IOL optic. B: Bulky haptic affecting the anatomy of the ciliary sulcus. C: Fifty MHz UBM of an eye with Soemmerring ring.

Submitted: June 13, 2011.

Final revision submitted: December 18, 2011.

Accepted: December 20, 2011.

From the University Eye Hospital (Petermeier, Suesskind, Altpeter, Schatz, Gekeler, Szurman), Centre for Ophthalmology, Eberhard-Karls University, Tuebingen, and Knappschaft Eye Hospital (Petermeier, Szurman), Sulzbach/Saar, Germany; the School of Medicine of Ribeirão Preto (Messias), USP, Department of Ophthalmology, Otorhinolaryngology and Head and Neck Surgery, Ribeirão Preto, Brazil.

Corresponding author: Katrin Petermeier, MD, FEBO, Department of Ophthalmology, Eberhard-Karls University of Tuebingen, Schleichstrasse 12, 72076 Tuebingen, Germany. E-mail: [katrin.petermeier@med.uni-tuebingen.de](mailto:katrin.petermeier@med.uni-tuebingen.de).

**Table 1.** Patient characteristics.

| Parameter      | Result           |
|----------------|------------------|
| Age (y)        |                  |
| Mean $\pm$ SD  | 72.15 $\pm$ 8.4  |
| Range          | 53, 86           |
| Follow-up (mo) |                  |
| Mean $\pm$ SD  | 18.8 $\pm$ 26.08 |
| Range          | 0.57, 104.1      |
| AL (mm)        |                  |
| Mean $\pm$ SD  | 23.29 $\pm$ 1.18 |
| Range          | 20.69, 26.43     |
| WTW (mm)       |                  |
| Mean $\pm$ SD  | 11.82 $\pm$ 0.35 |
| Range          | 11.2, 12.5       |
| K1 (mm)        |                  |
| Mean $\pm$ SD  | 7.74 $\pm$ 0.28  |
| Range          | 7.22, 8.86       |
| K2 (mm)        |                  |
| Mean $\pm$ SD  | 7.58 $\pm$ 0.29  |
| Range          | 8.74, 6.91       |

AI = axial length; K1 = flat keratometry; K2 = steep keratometry; WTW = white-to-white diameter

All calculations and statistical analyses were performed using JMP IN software (version 9, SAS Institute, Inc.). One-way analysis of variance with a subsequent Tukey HSD (honestly significant difference) test was used to compare the different directions of measurement. A *P* value less than 0.05 was considered a statistically significant difference. Pearson correlation coefficients (*r*) were calculated to assess correlations between biometric data and UBM measurements. Test-retest evaluation was analyzed computing the coefficient of variation (CoV), normalized by each individual mean.

## RESULTS

The study evaluated 50 pseudophakic eyes. Table 1 shows the patient characteristics. Table 2 shows types of IOL used. All implanted IOLs had a 6.0 mm optic.

Table 3 shows the STS, ATA, and ScTSc diameters. The vertical ATA diameter was statistically significantly larger than the horizontal diameter (*P* = .0328) (Figure 2), while the oblique diameters were not statistically significantly different. This was also true for the

**Table 2.** Types of IOL used.

| IOL Implanted*       | Eyes (n) |
|----------------------|----------|
| Alcon SN60AT/SA60AT  | 25       |
| Alcon SN60WF         | 9        |
| AMO Tecnis ZCB00     | 8        |
| Polytech H62         | 2        |
| Ophtec Oculaid PC510 | 2        |
| Zeiss Acri.Lisa      | 2        |
| Zeiss Acri.Smart     | 1        |
| Visionflex Sofcryn   | 1        |

IOL = intraocular lens  
\*As noted in the medical records

STS diameter; that is, the vertical diameter was larger than the horizontal diameter (*P* = .0216) while the oblique diameters were not statistically significantly different (Figure 2). The ATA and STS thus had a vertical oval shape, with the vertical diameter larger than the horizontal and the oblique diameters in between the two. There was no statistically significant difference in the ScTSc diameters.

The vertical ATA diameter was the largest in 31 eyes (62%), while the horizontal diameter was the largest in 9 eyes (18%). In 10 eyes (20%), 1 of the oblique diameters was the largest.

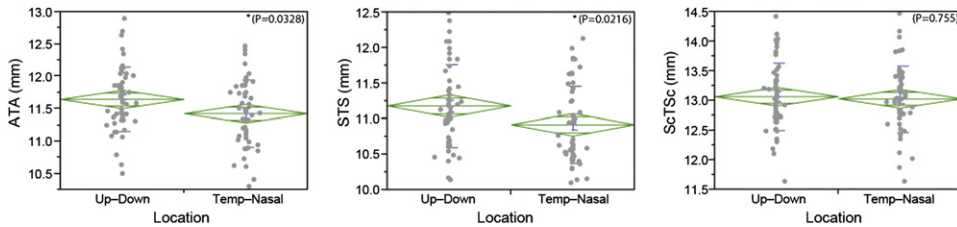
The vertical STS diameter was the largest in 36 eyes (72%), while the horizontal diameter was the largest in 3 eyes (6%). In 11 eyes (22%), 1 of the oblique diameters was the largest.

A well-defined weak correlation was found between WTW and horizontal ATA (*r* = 0.5766, *P* < .0001) and between WTW and horizontal STS (*r* = 0.5040, *P* = .0002), while no correlation was found between WTW and horizontal ScTSc (*r* = 0.2217, *P* = .1217) (Figure 3). The AL and keratometric reading were also weakly correlated with STS diameter; the correlation coefficients for keratometry (K) 1 (steep), K2 (flat), and AL were 0.4985 (*P* = .0002), 0.5165 (*P* = .0001), and 0.5181 (*P* = .0001), respectively.

Test-retest was performed repeating the measurement 5 times in 11 eyes. The mean IOL optic diameter was 6.01 mm  $\pm$  0.03 (SD), 6.01  $\pm$  0.03 mm, 6.00  $\pm$  0.03 mm, 5.98  $\pm$  0.03 mm, and 6.00  $\pm$  0.03 mm for

**Table 3.** Angle-to-angle, sulcus-to-sulcus, and sclera-to-sclera diameters in the 4 measurement directions.

| Parameter        | Measurement Directions, Mean (mm) $\pm$ SD |                        |                  |                        |
|------------------|--------------------------------------------|------------------------|------------------|------------------------|
|                  | Nasal–Temporal                             | Temporal Up–Nasal Down | Up–Down          | Temporal Down–Nasal Up |
| Angle-to-angle   | 11.43 $\pm$ 0.50                           | 11.47 $\pm$ 0.51       | 11.65 $\pm$ 0.49 | 11.49 $\pm$ 0.49       |
| Sulcus-to-sulcus | 10.91 $\pm$ 0.53                           | 10.98 $\pm$ 0.58       | 11.18 $\pm$ 0.57 | 11.04 $\pm$ 0.57       |
| Sclera-to-sclera | 13.03 $\pm$ 0.55                           | 12.97 $\pm$ 0.56       | 13.06 $\pm$ 0.55 | 12.97 $\pm$ 0.55       |



**Figure 2.** The vertical (up-down) ATA and STS diameter was statistically significantly larger than the horizontal (nasal-temporal) diameter; there was no statistically significant difference for the STS diameter.

the 5 measurements, respectively. To compute the CoV, each result was subtracted from the mean of the 5 results in each eye. The highest negative difference between 1 measurement in 1 eye and the mean of the 5 measurements in this eye was  $-0.058$  mm, or 0.97% of the mean in this eye. The highest positive difference was  $-0.052$  mm, or 0.87% of the mean in this eye. The overall CoV was 0.31%. Thus, in 55 measurements, the highest deviation of 1 measurement to the mean was below 1.0% of the mean.

## DISCUSSION

To our knowledge, this is the first study reporting the sulcus diameter in vivo in pseudophakic eyes. Li et al.<sup>24</sup> showed in cadaver eyes that 50 MHz UBM offers high accuracy and good repeatability for measuring the ciliary sulcus diameter. In our study, the pseudophakic eyes came with a “built-in” caliper; that is, the IOL optic, which was known to be 6.0 mm in all cases. The accuracy and repeatability may be limited by the centration of the cross-sectional images. The Aviso UBM device does not have an internal camera, as other devices do (eg, Artemis, Arcscan, Inc.). In this study, measurement was performed using the images with the widest pupil diameter. The diameter of the IOL optic served as control to ensure the centration of the measurement. Our accuracy and repeatability in vivo are in accordance with the results of Li et al.<sup>24</sup> in cadaver eyes and well suited to perform the assessments outlined in the previous sections.

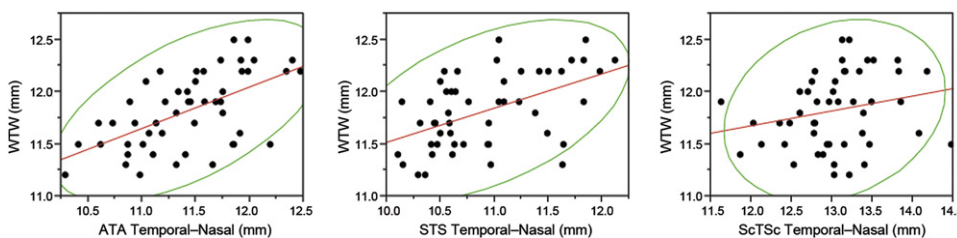
No power calculation was performed in advance because the distribution and the expected standard deviation (SD) were unknown. The number of 50 eyes was our estimation. However, a power calculation was

performed retrospectively. Considering an SD of 0.5 mm and a minimum difference to be detected of 0.5 mm, the sample size for a 1-mean analysis would be 10 eyes for an 80% power. Thus, 50 eyes guaranteed an 80% power in our study.

Several studies<sup>15-19</sup> have evaluated the relationship between WTW and STS diameters in an effort to select adequately sized posterior phakic IOLs. Using different devices to measure the STS and the WTW, they showed a weak correlation ( $r = 0.406$  to  $r = 0.597$ ) between these 2 values. In our study of pseudophakic eyes, it was sometimes difficult to identify the sulcus; Soemmerring ring (Figure 1, C) or a bulky haptic (Figure 1, B) of a single-piece IOL might compress the structures constituting the ciliary sulcus. Nevertheless, we also found a weak correlation between WTW and STS ( $r = 0.5040$ ,  $P = .0002$ ), similar to results in the previous studies of phakic eyes.

Kim et al.<sup>16</sup> found a high negative correlation ( $r = -0.865$ ) between K readings (in diopters) and the sulcus diameter; however, the study was limited by the number of patients ( $n = 14$ ), that accommodation was not excluded, and that most of the patients were highly myopic. In our study of pseudophakic eyes, K readings and AL showed a weak correlation with sulcus diameter. The correlation was 0.4985 ( $P = .0002$ ) for K1, 0.5165 ( $P = .0001$ ) for K2, and 0.5181 ( $P = .0001$ ) for AL.

We found a larger vertical diameter than horizontal diameter for the sulcus and the anterior chamber. These 2 structures appeared to be oval, while the scleral diameters in different orientations were not different. It is unclear whether horizontal orientation of IOLs may have an impact on the ciliary sulcus and the anterior chamber, making them oval. In this study, the eyes were operated on at University Eye Hospital Tuebingen, where a temporal incision and horizontal



**Figure 3.** Relationship between WTW and ATA, STS, and ScTSc diameters. The ellipses represent the bivariate 95% confidence intervals. Only a weak correlation was found for WTW and ATA nasal temporal ( $r = 0.5766$ ,  $P < .0001$ ) and for WTW and STS nasal-temporal ( $r = 0.5040$ ,  $P = .0002$ ); no correlation was found for WTW and ScTSc nasal-temporal ( $r = 0.2217$ ,  $P = .1217$ ).

orientation of the IOL are standard; however, the orientation of the IOLs has not been explicitly evaluated. Baikoff et al.<sup>25</sup> evaluated the shape of the anterior chamber in 107 phakic eyes with optical coherence tomography (OCT). They also found the anterior chamber to be vertically oval; it was not possible to evaluate the sulcus diameter with OCT. However, by taking a closer look at every case, they found that the vertical diameter was smaller than the horizontal diameter in 15% of eyes, which reflects a variation that should be taken into account when planning phakic IOL implantation. In our study, the vertical anterior chamber diameter was the largest in 31 eyes (62%), while the horizontal diameter was the largest in 9 eyes (18%). In 10 eyes (20%), 1 of the oblique diameters was the largest. Rondeau et al.<sup>17</sup> measured the sulcus diameter and calculated the orientation of the largest diameter. They found a trend toward the horizontal meridian being the largest, but they also found high variation. Oh et al.<sup>18</sup> also found a vertical oval posterior chamber in 28 phakic eyes using 35 MHz UBM.

In our study, the vertical sulcus diameter was the largest in 36 eyes (72%), while the horizontal diameter was the largest in 3 eyes (6%). In 11 eyes (22%), 1 of the oblique diameters was the largest. Werner et al.<sup>19</sup> evaluated the sulcus diameter with the Artemis device in postmortem eyes and in a clinical trial. In the postmortem eyes, the mean vertical diameter was larger than the horizontal diameter, while in the clinical study the horizontal diameter was larger than the vertical diameter. The authors propose that each eye should be evaluated for the largest meridian preoperatively.

We conclude from our results that the anatomy of the ciliary sulcus in pseudophakic eyes may be affected by bulky haptics or Soemmerring ring. Thus, when planning an add-on IOL in such cases, the patient should be informed that secondary fixation of the add-on IOL to the iris or sclera might be necessary to avoid rotation. Second, the ciliary sulcus is not a perfectly symmetrical round structure but rather a vertically longer oval, which might result in rotational instability of add-on IOLs with C-loop haptics. One might speculate add-on IOLs could self-rotate postoperatively into the position of least resistance, which is mostly the vertical meridian. Nevertheless, in some eyes, even the horizontal or oblique meridian might be the largest; thus, without evaluation of the sulcus, the rotational stability of an add-on IOL would be unpredictable. Individual sizing is not possible with the available add-on IOLs; however, implantation of a Visian Implantable Collamer Lens (Staar Surgical Co.) as an add-on IOL has been described.<sup>26</sup> This lens is a so-called phakic IOL and not designed to be implanted in pseudophakic eyes; however, it is available in different sizes and results in small case series are promising.<sup>26</sup> Eventually,

new designs other than C-loop haptics or more than 2 haptics may be able to fit the oval shape of the sulcus. In conclusion, eyes planned for add-on IOL implantation should be evaluated preoperatively with UBM.

#### WHAT WAS KNOWN

- While several studies have evaluated the relationship between white-to-white diameters and sulcus diameters in an effort to select adequately sized posterior phakic IOLs, no study has evaluated the sulcus diameter in pseudophakic eyes. This evaluation is important for implantation of add-on IOLs to prevent rotating or shifting.

#### WHAT THIS PAPER ADDS

- White-to-white was only weakly correlated with the sulcus diameter in pseudophakic eyes. Vertical diameter was larger than horizontal diameter. The sulcus diameter had a vertical oval shape with the vertical meridian being the largest; however, it also had a variation of the direction of the largest meridian. In pseudophakic eyes, Soemmerring ring or a bulky haptic may affect the ciliary sulcus anatomy.
- Eyes planned for add-on IOL implantation should be evaluated preoperatively with UBM.

#### REFERENCES

1. Gayton JL, Sanders VN. Implanting two posterior chamber intraocular lenses in a case of microphthalmos. *J Cataract Refract Surg* 1993; 19:776–777
2. Paul RA, Chew HF, Singal N, Rootman DS, Slomovic AR. Piggyback intraocular lens implantation to correct myopic pseudophakic refractive error after penetrating keratoplasty. *J Cataract Refract Surg* 2004; 30:821–825
3. Gills JP, Van der Karr MA. Correcting high astigmatism with piggyback toric intraocular lens implantation. *J Cataract Refract Surg* 2002; 28:547–549
4. Till JS. Piggyback silicone intraocular lenses of opposite power. *J Cataract Refract Surg* 2001; 27:165–168
5. Gayton JL, Apple DJ, Peng Q, Visessoon N, Sanders V, Werner L, Pandey SK, Escobar-Gomez M, Hoddinott DSM, Van Der Karr M. Interlenticular opacification: clinicopathological correlation of a complication of posterior chamber piggyback intraocular lenses. *J Cataract Refract Surg* 2000; 26:330–336
6. Shugar JK, Schwartz T. Interpseudophakos Elschnig pearls associated with late hyperopic shift: a complication of piggyback posterior chamber intraocular lens implantation. *J Cataract Refract Surg* 1999; 25:863–867
7. Baumeister M, Kohnen T. Scheimplug measurement of intraocular lens position after piggyback implantation of foldable intraocular lenses in eyes with high hyperopia. *J Cataract Refract Surg* 2006; 32:2098–2104
8. Akaishi L, Tzelikis PF, Gondim J, Vaz R. Primary piggyback implantation using the Tecnis ZM900 multifocal intraocular lens; case series. *J Cataract Refract Surg* 2007; 33:2067–2071
9. Alfonso JF, Fernández-Vega L, Baamonde MB. Secondary diffractive bifocal piggyback intraocular lens implantation. *J Cataract Refract Surg* 2006; 32:1938–1943

10. Gayton JL, Sanders V, Van Der Karr M. Pupillary capture of the optic in secondary piggyback implantation. *J Cataract Refract Surg* 2001; 27:1514–1515
11. Kim SK, Lanciano RC Jr, Sulewski ME. Pupillary block glaucoma associated with a secondary piggyback intraocular lens. *J Cataract Refract Surg* 2007; 33:1813–1814
12. Sauder G. Sekundäre torische Intraokularlinsenimplantation in pseudophake Augen. Das “Add-on”-IOL-System [Secondary toric intraocular lens implantation in pseudophakic eyes. The add-on IOL system]. *Ophthalmologe* 2007; 104:1041–1045
13. Kahraman G, Amon M. New supplementary intraocular lens for refractive enhancement in pseudophakic patients. *J Cataract Refract Surg* 2010; 36:1090–1094
14. Gerten G, Kermani O, Schmiedt K, Farvili E, Foerster A, Oberheide U. Dual intraocular lens implantation: Monofocal lens in the bag and additional diffractive multifocal lens in the sulcus. *J Cataract Refract Surg* 2009; 35:2136–2143
15. García-Feijó J, Hernández-Matamoros JL, Méndez-Hernández C, Castillo-Gómez A, Lázaro C, Martín T, Cuiña-Sardiña R, García-Sánchez J. Ultrasound biomicroscopy of silicone posterior chamber phakic intraocular lens for myopia. *J Cataract Refract Surg* 2003; 29:1932–1939
16. Kim K-H, Shin H-H, Kim H-M, Song J-S. Correlation between ciliary sulcus diameter measured by 35 MHz ultrasound biomicroscopy and other ocular measurements. *J Cataract Refract Surg* 2008; 34:632–637
17. Rondeau MJ, Barcsay G, Silverman RH, Reinstein DZ, Krishnamurthy R, Chabi A, Du T, Coleman DJ. Very high frequency ultrasound biometry of the anterior and posterior chamber diameter. *J Refract Surg* 2004; 20:454–464
18. Oh J, Shin H-H, Kim J-H, Kim H-M, Song J-S. Direct measurement of the ciliary sulcus diameter by 35-megahertz ultrasound biomicroscopy. *Ophthalmology* 2007; 114:1685–1688
19. Werner L, Lovisolo C, Chew J, Tetz M, Müller M. Meridional differences in internal dimensions of the anterior segment in human eyes evaluated with 2 imaging systems. *J Cataract Refract Surg* 2008; 34:1125–1132
20. Kawamorita T, Uozato H, Kamiya K, Shimizu K. Relationship between ciliary sulcus diameter and anterior chamber diameter and corneal diameter. *J Cataract Refract Surg* 2010; 36:617–624
21. Reinstein DZ, Archer TJ, Silverman RH, Rondeau MJ, Coleman DJ. Correlation of anterior chamber angle and ciliary sulcus diameters with white-to-white corneal diameter in high myopes using Artemis VHF digital ultrasound. *J Refract Surg* 2009; 25:185–194
22. Kamal AM, Hanafy M, Ehsan A, Tomerak RH. Ultrasound biomicroscopy comparison of ab interno and ab externo scleral fixation of posterior chamber intraocular lenses. *J Cataract Refract Surg* 2009; 35:881–884
23. Vasavada AR, Raj SM, Karve S, Vasavada V, Vasavada V, Theoulakis P. Retrospective ultrasound biomicroscopic analysis of single-piece sulcus-fixated acrylic intraocular lenses. *J Cataract Refract Surg* 2010; 36:771–777
24. Li D-J, Wang N-L, Chen S, Li S-N, Mu D-P, Wang T. Accuracy and repeatability of direct ciliary sulcus diameter measurements by full-scale 50-megahertz ultrasound biomicroscopy. *Chin Med J (Engl)* 2009; 122:955–959. Available at: <http://www.cmj.org/Periodical/PDF/200941950564840.pdf>. Accessed February 8, 2012
25. Baikoff G, Jodai HJ, Bourgeon G. Measurement of the internal diameter and depth of the anterior chamber: IOLMaster versus anterior chamber optical coherence tomographer. *J Cataract Refract Surg* 2005; 31:1722–1728
26. Hsuan JD, Caesar RH, Rosen PH, Rosen ES, Gore CL. Correction of pseudophakic anisometropia with the Staar Collamer implantable contact lens. *J Cataract Refract Surg* 2002; 28:44–49