



Universidade de São Paulo

Biblioteca Digital da Produção Intelectual - BDPI

Departamento de Prótese - FOB/BAP

Artigos e Materiais de Revistas Científicas - FOB/BAP

2012

Newly forming bone graft: a novel surgical approach to the treatment of denuded roots

JOURNAL OF APPLIED ORAL SCIENCE, BAURU, v. 20, n. 3, pp. 392-398, MAY-JUN, 2012
<http://www.producao.usp.br/handle/BDPI/42525>

Downloaded from: Biblioteca Digital da Produção Intelectual - BDPI, Universidade de São Paulo

Newly forming bone graft: a novel surgical approach to the treatment of denuded roots

Adriana Campos Passanezi SANT'ANA¹, Bruna F. Rahal FERRAZ², Maria Lúcia Rubo de REZENDE¹, Sebastião Luiz Aguiar GREGHI¹, Carla Andreotti DAMANTE³, Euloir PASSANEZI⁴

1- DDS, PhD, Associate Professor, Discipline of Periodontics, Department of Prosthodontics, Bauru School of Dentistry, University of São Paulo, Bauru, SP, Brazil.

2- DDS, MSD, Graduate student, Discipline of Periodontics, Department of Prosthodontics, Bauru School of Dentistry, University of São Paulo, Bauru, SP, Brazil.

3- DDS, PhD, Assistant Professor, Discipline of Periodontics, Department of Prosthodontics, Bauru School of Dentistry, University of São Paulo. Bauru, SP, Brazil.

4- DDS, PhD, Head of the Discipline of Periodontics, Department of Prosthodontics, Bauru School of Dentistry, University of São Paulo, Bauru, SP, Brazil.

Corresponding address: Adriana Campos Passanezi Sant'Ana - Faculdade de Odontologia de Bauru - USP - Departamento de Prótese - Disciplina de Periodontia - Al. Otávio Pinheiro Brisolla 9-75 - 17012-901 - Bauru - SP - Brazil - Phone: 00 55 (14) 3235-8278 - Fax: 00 55 (14) 3227-5105 - e-mail: acpsantana@usp.br

Received: October 13, 2010 - Modification: July 14, 2011 - Accepted: August 15, 2011

ABSTRACT

Many techniques have been proposed for root coverage. However, none of them presents predictable results in deep and wide recessions. Objective: The aim of this case series report is to describe an alternative technique for root coverage at sites showing deep recessions and attachment loss >4 mm at buccal sites. Material and Methods: Four patients presenting deep recession defects at buccal sites (≥ 4 mm) were treated by the newly forming bone graft technique, which consists in the creation of an alveolar socket at edentulous ridge and transferring of granulation tissue present in this socket to the recession defect after 21 days. Clinical periodontal parameters, including recession depth (RD), probing depth (PD), clinical attachment level (CAL), bleeding on probing (BOP), plaque index (PI) and keratinized gingiva width (KGW) were evaluated by a single examiner immediately before surgery and at 1, 3, 6 and 9 months postoperatively. Results: All cases showed reduction in RD and PD, along with CAL gain, although no increase in KGW could be observed. These findings suggest that the technique could favor periodontal regeneration along with root coverage, especially in areas showing deep recessions and attachment loss.

Key words: Gingival recession. Guided tissue regeneration. Citric acid. Grafts.

INTRODUCTION

Coverage of denuded roots has been a main concern for both professionals and patients. Many surgical techniques have been proposed to cover denuded roots, showing varying rates of success depending on factors related to the surgical technique and anatomical features of the lesions^{13,14,17,26}. A greater reduction in recession depth and width as well as a greater increase in the width of keratinized gingiva are obtained by subepithelial connective tissue graft (SCTG) associated to coronally positioned flap^{5,13,19}. However, the success of such technique is limited in wide recession defects presenting interproximal bone and soft tissue loss¹⁷.

To overcome these problems, the use of barrier membranes positioned over exposed root

surface (GTR) warranting a space for regeneration to occur along with root coverage has been suggested^{7,20,23,26,27}. This technique resulted in gain of attachment level, reduction of probing depth, bleeding on probing and recession depth^{19,23,26} in single, large, deep, localized marginal tissue recessions showing ≥ 5 mm of depth²⁷, in the presence of hypersensitivity⁷, cervical caries lesions or restorations^{23,28}. Histological studies demonstrated that wound healing proceeded with the formation of new cementum, periodontal ligament and alveolar bone coronal to the pre-existent level, suggesting that root coverage was accomplished by regeneration of periodontal tissues^{7,20}. In turn, it is contra-indicated for the treatment of multiple and shallow recessions^{18,30} or in areas of thin gingival tissue¹¹.

To further improve these results, the use of allogenic bone grafts associated to GTR for

root coverage was proposed^{8,12,24,25} to support the membrane and to act as an osteoinductive/osteoconductive biomaterial, resulting in improved reduction of recession and probing depth and gain of attachment level compared to the use of barrier membranes alone^{8,12}, as well as a slightly smaller - but not significant - reduction in recession depth compared with subepithelial connective tissue graft²⁴.

Recently, the use of growth factors or stem cells under membranes has been proposed to treat denuded areas¹⁵ or missing papillae¹⁶, with promising results. Passanezi, et al.²¹ (1989) proposed a surgical technique based on the transfer of osteogenic cells to treat infrabony periodontal defects with high rates of clinical success. The technique consists in the transfer of healing bone from a surgically created alveolar socket to infrabony periodontal defects approximately 21 days after. A substantial quantity of a relatively mature newly forming bone containing a vast amount of osteoblasts with osteogenic potential is observed in alveolar socket 4-12 weeks after tooth extraction⁹. This material shows positive staining against collagen I, osteocalcin, bone sialoprotein and alkaline phosphatase activity²², which are considered as markers of mesenchymal stem cells^{3,6}, resulting in regeneration of periodontal tissues in animal and human studies²¹.

The treatment of wide recession defects by the newly forming bone graft (NFBG) technique would then be favored by the formation of a new periodontal attachment apparatus, even in the presence of attachment loss or thin keratinized tissue. Considering that, the aim of this case series report is to propose a new technique for coverage of denuded roots in order to achieve root coverage along with successful regeneration of bone, cementum and periodontal ligament, especially at deep and wide recession defects.

CASE SERIES REPORT

Case 1

Patient #1 was a 44-year-old systemically healthy never-smoker female who presented for treatment at the Clinics of the Discipline of Periodontics at Bauru School of Dentistry, University of São Paulo, Brazil. Patient reported no use of antibiotics or other medicines in the previous 6-month period. Treatment plan involved extraction of the mandibular left central incisor and root coverage of the mandibular right second premolar, which showed a 5 mm-deep and 4 mm-wide recession at baseline examination. No tooth mobility was present. Clinical and radiographic examination suggested a slight loss of soft and hard tissues at distal sites compatible with a Miller class III

recession defect, since the mandibular right second premolar was adjacent to an edentulous ridge.

Case 2

Patient #2 presented for treatment at the Periodontics Clinics complaining of recession at the mandibular left first premolar. Clinical examination revealed a 5 mm-deep recession defect. Patient reported no systemic disease, no smoking, no use of antibiotics or any other medications or periodontal treatment in the 6-month period previous to baseline examination. No tooth mobility was present. Clinical and radiographic examination suggested a Miller's class III recession defect.

Case 3

Patient #3, a 35 year-old female, presented a deep recession defect (5 mm) at the mandibular right second premolar. Patient was systemically healthy, never smoker, and reported no use of any medication or periodontal treatment in the 6-month period previous to baseline examination. There was no clinical sign of trauma from occlusion or tooth mobility. Clinical and radiographic examination suggested a Miller's class III recession defect.

Case 4

Patient #4 was a 32-year-old female with a 4-mm-deep recession defect at the mandibular right second premolar. No tooth mobility was present, and there was no clinical sign of trauma from occlusion. Patient reported to be systemically healthy and never smoker. Additionally, patient reported no regular use of medications or periodontal treatment during the past 6 months. Clinical and radiographic examination suggested a Miller's class III recession defect.

Phase I therapy

All patients were submitted to a phase I therapy, which included removal of caries and endodontic lesions, oral hygiene instruction and scaling and root planning aiming at plaque control. Surgical treatment was performed after active treatment, when resolution of inflammation was achieved, as observed by absence of bleeding on probing and clinical signs of gingival health.

Clinical examination

Clinical examinations were performed by a single trained examiner immediately before surgery and at 1, 3, 6 and 9 months post-operatively. Depth of marginal tissue recession (DR), probing depth (PD), clinical attachment level (CAL), bleeding on probing (BOP) and keratinized gingiva width (KGW) were determined using a millimeter manual probe (HuFriedy, Chicago, IL, USA). DR was determined by the distance from cementum-enamel junction to

gingival margin. PD was determined by the distance from gingival margin to the bottom of the sulcus. CAL was defined as the distance from cementum-enamel junction to the bottom of sulcus (DR+PD). KGW was determined by the distance from gingival margin to the mucogingival junction. The presence of bleeding upon probing was recorded as 1 and its absence as 0. Plaque index was recorded as the presence (1) or absence (0) of plaque after staining of tooth surface with a plaque-evidencing solution. Percentage of root coverage was determined by the application of the formula¹¹:

$$\% \text{ root coverage} = \frac{(\text{RD}_{\text{initial}} - \text{RD}_{\text{final}}) \times 100}{\text{RD}_{\text{initial}}}$$

Description of NFBG for root coverage

-Surgical creation of the alveolar socket

The alveolar socket was created by perforation of alveolar bone ridge with a diamond bur, as previously described²¹ (Figure 1A-B). A bovine type 1 collagen membrane (GenDerm, Baumer, Bauru, SP, Brazil) was positioned over the socket (Figure 1C) to prevent ingrowth of connective tissue or epithelial cells. Flaps were sutured without tension with silk 4-0 (Ethicon, Johnson & Johnson, São Paulo, SP, Brazil), as shown in Figure 1D. Patients were prescribed antibiotics (Amoxicilin, 1500 mg, t.i.d, 7 days) and non-steroidal anti-inflammatory (Nimesulide, 100 mg, b.i.d., 3 days) and instructed not to rinse during the first 48 h. Sutures were removed after 7 days, with clinical evidence of uneventful wound healing.

-Surgical technique for root coverage

Root coverage procedure was carried out 21 days after (Figure 2A, B). After appropriate anesthesia, a trapezoidal flap⁷ was performed and a full thickness flap was raised (Figure 2C). After debridement and scaling and root planning, root surface was conditioned with a citric acid (pH 1) and a 50% tetracycline solution (Discipline of Biochemistry, School of Dentistry at Bauru-USP) during 3 minutes, followed by vigorous rinsing with saline solution. Afterwards, a full thickness flap was raised at donor site (Figure 2D). The healing tissue was removed from the alveolus with a Lucas curette (Chinelatto, Ribeirão Preto, SP, Brazil) and transferred to the receptor site (Figure 2E). Flaps were displaced coronally and sutured at cemento-enamel junction (Figure 2F). A periodontal dressing (CoePack, GC America INC, Alsip, IL, U.S.A) protected the area for 14 days. Patient was prescribed a non-steroidal anti-inflammatory and instructed not to rinse during the first 48 h. Sutures were removed after 14 days. Patient was advised to carry out routine oral hygiene procedures with dental floss and soft brush for the next 30 days. Postoperative controls were performed at 1, 3, 6 and 9 months and included instruction of oral hygiene and supra and subgingival plaque control, when necessary.

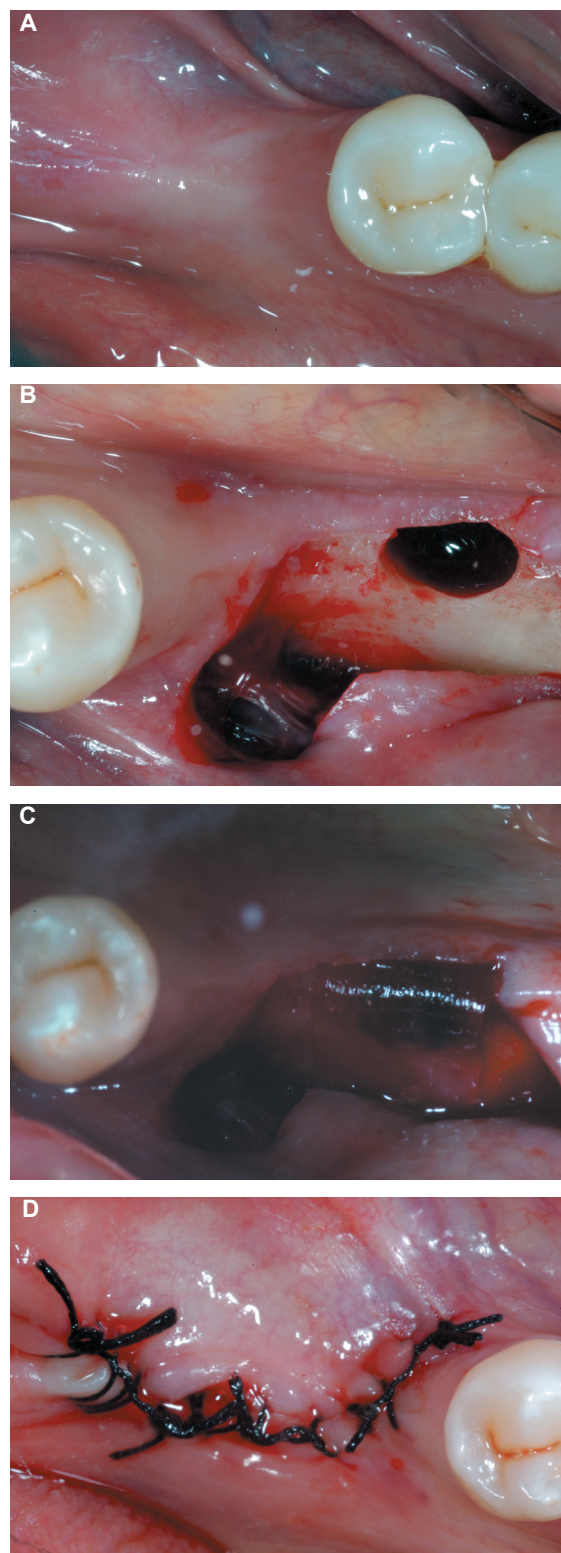


Figure 1- Prepare of donor site. (A) Occlusal view from edentulous ridge selected for the creation of a surgical alveolus; (B) Rising of a full thickness flap and creation of a surgical socket by perforation of alveolar ridge with a diamond bur in high speed with vigorous irrigation; (C) Bovine type 1 collagen barrier membrane trimmed to overlap defects margins in 2-3 mm positioned over the defect; (D) Primary closure of the flaps without tension with 4-0 silk

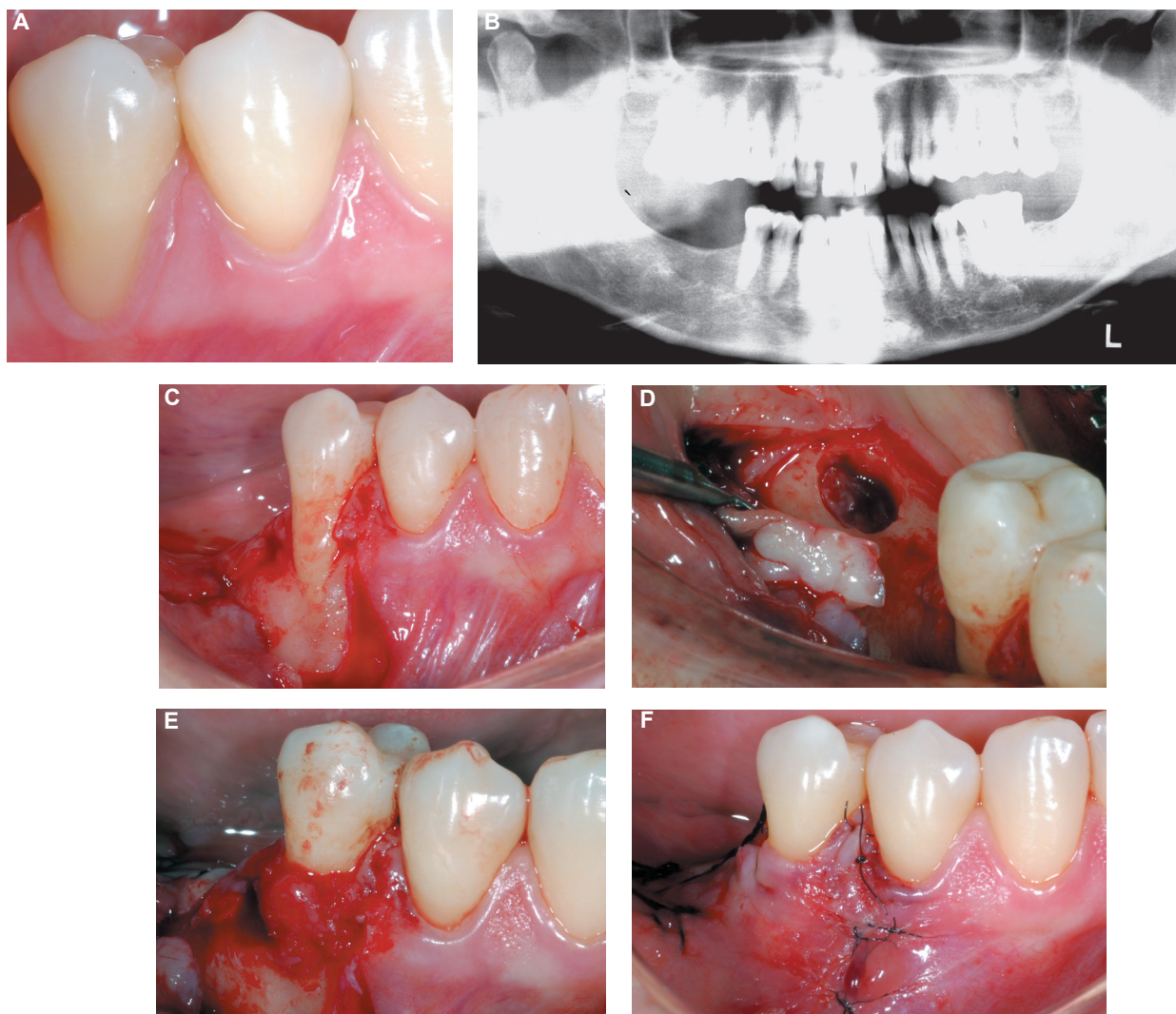


Figure 2- Treatment of recession defect by the newly forming bone technique. A: Buccal view of the 5-mm-deep and 4-mm wide recession defect at the mandibular right second premolar; B: Panoramic x-ray view of the area. A slight loss of interproximal bone at distal site of the mandibular right second premolar can be noticed; C: Trapezoidal full thickness flap at receptor site 21 days after surgical creation of alveolar socket; D: Occlusal view of donor site containing the healing tissue after rising of a full-thickness flap; E: Positioning of the newly forming bone at the receptor site. A slight compression with saline solution embedded gauze warranted a close contact between the graft material and the root surface; F: Flaps displaced coronally and sutured at the level of cemento-enamel junction without tension

RESULTS

Table 1 describes RD, PD, CAL, BOP, PI, KGW and the percentage of root coverage observed at buccal sites at baseline and at the postoperative examinations for all cases described. A reduction in RD was observed for all cases after 9 months, although Cases 2 and 3 showed a slight relapse from 3-month to 6- and 9-month examinations. All cases resulted in CAL gain and reduction or stability of PD measures, as well as absence of plaque accumulation and BOP. Cases 2, 3 and 4 showed a slight increase in KGW, while no change was observed in Case 1. Figure 3 shows the results obtained in Case 1, in which CAL gain was observed at interproximal and buccal sites, along

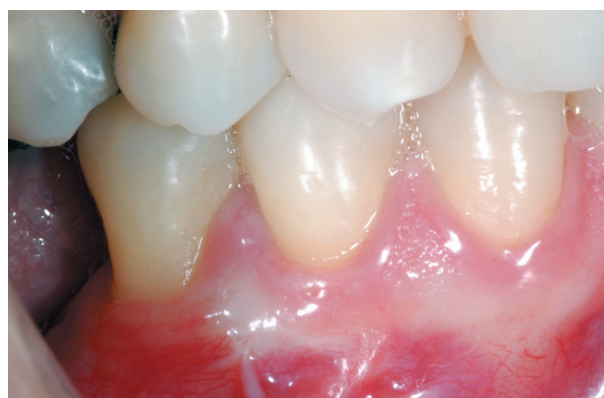

Figure 3- Buccal view of the area 9 months after treatment, suggesting gingival health and reduction of recession

Table 1- Probing depth (PD), clinical attachment level (CAL), bleeding on probing (BOP), plaque index (PI), recession depth (RD), keratinized gingiva width (KGW) and percentage of root coverage (%RC) observed at baseline and postoperative examinations

Case	Examination	PD	CAL	BOP	PI	RD	KGW	%RC
Case 1	Baseline	2	7	0	1	5	2	-
	3 months	1	3	0	0	2	2	60
	6 months	1	3	0	0	2	2	60
	9 months	1	3	0	0	2	2	60
	Difference	-1	4	-	-	-3	0	-
Case 2	Baseline	2	7	1	1	5	1	-
	3 months	2	4	0	0	2	2	60
	6 months	2	5	1	0	3	2	40
	9 months	2	5	0	0	3	2	40
	Difference	0	2	-	-	-2	1	-
Case 3	Baseline	2	7	0	0	5	2	-
	3 months	1	4	0	0	2	3	60
	6 months	1	4	0	1	3	3	40
	9 months	1	4	0	0	3	3	40
	Difference	-1	3	-	-	-2	1	-
Case 4	Baseline	3	7	0	0	4	1	-
	3 months	1	2	0	0	1	2	75
	6 months	1	2	0	0	1	2	75
	9 months	1	2	0	0	1	2	75
	Difference	-2	5	-	-	-3	1	-

with reduction of RD from 5 mm at baseline to 2 mm after 9 months.

DISCUSSION

The aim of this case series report is to present a new surgical technique that could favor both root coverage and periodontal regeneration, especially at sites showing deep recession defects and attachment loss. The primary results obtained showed reduction of PD, BOP and plaque index and gain of CAL after 9 months of follow-up. A slight increase in KGW was observed after treatment.

These results are in agreement with other studies^{1,5,7,8,19,23,24-29} which suggested reduction of probing depth and gain of attachment level in wide and deep recession defects treated by GTR associated to a coronal positioned flap. Similar results were obtained by the use of β -TCP and 0.3 ng/mL rhPDGF-BB under a collagen membrane for treatment of denuded roots, resulting in the formation of new cementum, periodontal ligament and alveolar bone along with root coverage¹⁵.

The main advantage of this novel technique is the use of autograft material containing osteogenic cells^{9,22} capable of regenerating periodontal tissues²¹ even in horizontal defects. Disadvantages of the

technique include the necessity of performing two surgical procedures in a short period of time, as well as the existence of two surgical sites at the graft surgery. Besides, patient is required to present at least one condemned tooth or an alveolar ridge that allows the surgical creation of an alveolar socket.

An important issue was the difficulty in stabilizing the graft on the root surface, due to the convexity of roots and the absence of remaining walls to support the graft. This was at least partially solved by performing suture of apical portions of the flaps prior to positioning of the graft, which allowed more stability of the graft.

The aim of the present technique is to achieve periodontal regeneration coronal to the preexistent level along with root coverage. This is especially important at sites showing deep recession and dehiscence defects, when conventional soft tissue grafts show limited results^{23,29}. Many studies^{1,5,19,29} indicate that subepithelial connective tissue results in greater complete and mean root coverage, and a greater increase in KGW than GTR techniques, with long-term stability of the results obtained. However, at sites showing interproximal bone loss or deep dehiscence defects and severe attachment loss, regeneration of periodontal tissues may be required to improve attachment support and, consequently,

reduce recession depth^{7,26,29} without the formation of a long junctional epithelium, as observed when defects with such features are treated by SCTGs¹⁰.

Periodontal regeneration can only be evaluated at the histologic level, which was not performed at the present study. However, previous histological studies performed in animal models showed that NFBG is capable of forming new alveolar bone, cementum and periodontal ligament coronal to the base of the pre-existent defect²¹.

Since the healing tissue present at fresh alveolar sockets shows positive staining for collagen I, osteonectin, bone sialoprotein and alkaline phosphatase activity⁹, it is possible that mesenchymal stem cells are available at the material, as suggested by other studies investigating the presence of mesenchymal stem cells in periodontal ligament by using the same panel of markers^{3,6}. Considering that one of the main features of mesenchymal stem cells is plasticity³ and the healing tissue removed from alveolar sockets and transferred to periodontal defects are able to form bone, periodontal ligament and cementum²¹, it seems reasonable to believe that mesenchymal stem cells are present at the newly forming bone granulation tissue, which could explain its osteogenic properties^{9,21,22}.

The use of regenerative techniques to achieve root coverage has been used for many years²⁶. Trombelli, et al.²⁷ (1995) showed that areas of 4-6 mm recessions treated by guided tissue regeneration resulted in greater reduction of recession and probing depth, as well as greater gain of attachment level than sites treated by free gingival grafts and coronally advanced flap. Other researchers have also demonstrated that the treatment of large recession defects by GTR results in the formation of new alveolar bone, cementum and periodontal ligament coronal to the base of the defect^{5,7,13,27,28}, although unsatisfactory results were observed in shallow recession defects¹⁸.

The percentage of root coverage obtained by GTR varies from 16.7%-100%^{4,5,7,8,20,23,26,27}, which are in agreement with results presented in this case report. In comparison with subepithelial connective tissue grafts, GTR shows better results in reduction of probing depth and gain of attachment level, especially in areas showing ≥ 5 mm of recession, and similar or slightly smaller reduction of recession^{1,19,24,29}. The main factors associated with incomplete root coverage are related to early exposition of the membrane and wide recessions^{2,4}. These problems are overcome with the present technique, since the use of barrier membranes is unnecessary due to the osteogenic properties of the material²¹.

The use of allografts in combination with barrier membranes improves the results obtained by the

use of barrier membranes alone^{8,12} or subepithelial connective graft^{1,24,29} in wide recession defects. Cases treated by bone grafts and GTR showed decreased probing depth at post-operative evaluations, suggesting a reconstitution of biological width, without the formation of long junctional epithelium^{1,8,12,24,29}. Considering that in the present case a histological evaluation was not performed, reduction of probing depth and gain of attachment are suggestive of regeneration of periodontal tissues.

The primary results obtained in the present case series suggest that the technique is able to cover denuded areas, along with reconstitution of biological width and gain of attachment level, especially in wide recession areas. Predictable and long-term well succeeded cases of root coverage by the NFBT require a strict selection of patients and sites to be treated. Further studies are necessary to compare the results obtained by the proposed technique with other conventional reconstructive periodontal plastic surgeries, such as subepithelial connective tissue grafts and guided bone regeneration.

CONCLUSIONS

The results obtained in the present clinical case series suggest that NFBT can be an alternative to the treatment of deep and wide recession defects.

REFERENCES

- 1- Al-Hamdan K, Eber R, Sarment D, Kowalski C, Wang HL. Guided tissue regeneration-based root coverage: meta-analysis. *J Periodontol.* 2003;74:1520-33.
- 2- Baldi C, Pini-Prato G, Pagliaro U, Nieri M, Saletta D, Muzzi L, et al. Coronally advanced flap procedure for root coverage. Is flap thickness a relevant predictor to achieve root coverage? A 19-case series. *J Periodontol.* 1999;70:1077-84.
- 3- Bartold PM, Shi S, Gronthos S. Stem cells and periodontal regeneration. *Periodontol* 2000. 2006;40:164-72.
- 4- Boltchi FE, Allen EP, Hallmon WW. The use of a bioabsorbable barrier for regenerative management of marginal tissue recession. I. Report of 100 consecutively treated teeth. *J Periodontol.* 2000;71:1641-53.
- 5- Chambrone L, Sukekava F, Araújo MG, Pustiglione FE, Chambrone LA, Lima LA. Root coverage procedures for the treatment of localized recession-type defects: a Cochrane systematic review. *J Periodontol.* 2010;81:452-78.
- 6- Chen SC, Marino V, Gronthos S, Bartold PM. Location of putative stem cells in human periodontal ligament. *J Periodontol Res.* 2006;41:547-53.
- 7- Cortellini P, Clauser C, Pini-Prato GP. Histologic assessment of new attachment following the treatment of a human buccal recession by means of a guided tissue regeneration procedure. *J Periodontol.* 1993;64:387-91.
- 8- Dodge JR, Greenwell H, Drisko C, Wittwer JW, Yancey J, Rebitski G. Improved bone regeneration and root coverage using a resorbable membrane with physically assisted cell migration and DFDBA. *Int J Periodontics Restorative Dent.* 2000;20:398-411.
- 9- Evian CI, Rosenberg ES, Coslet JG, Corn H. The osteogenic activity of bone removed from healing extraction sockets in humans. *J Periodontol.* 1982;53:81-5.

- 10- Goldstein M, Boyan BD, Cochran DL, Schwarz Z. Human histology of new attachment after root coverage using subepithelial connective tissue graft. *J Clin Periodontol.* 2001;28:657-62.
- 11- Harris RJ. A comparative study of root coverage obtained with guided tissue regeneration utilizing a bioabsorbable membrane versus the connective tissue with partial-thickness double pedicle graft. *J Periodontol.* 1997;68:779-90.
- 12- Kimble KM, Eber RM, Soehren S, Shyr Y, Wang HL. Treatment of gingival recession using a collagen membrane with or without the use of demineralized freeze-dried bone allograft for space maintenance. *J Periodontol.* 2004;75:210-20.
- 13- Langer B, Langer L. Subepithelial connective tissue graft technique for root coverage. *J Periodontol.* 1985;56:715-20.
- 14- Matter J. Free gingival graft and coronally repositioned flap. A 2-year follow-up report. *J Clin Periodontol.* 1979;6:437-42.
- 15- McGuire MK, Scheyer ET, Schupbach P. Growth factor-mediated treatment of recession defects: a randomized controlled trial and histologic and microcomputed tomography examination. *J Periodontol.* 2009;80:550-64.
- 16- McGuire MK, Scheyer ET. A randomized, double-blind, placebo-controlled study to determine the safety and efficacy of cultured and expanded autologous fibroblast injections for the treatment of interdental papillary insufficiency associated with the papilla priming procedure. *J Periodontol.* 2007;78:4-17.
- 17- Miller PD Jr. A classification of marginal tissue recession. *Int J Periodontics Restorative Dent.* 1985;5:8-13.
- 18- Müller HP, Stahl M, Eger T. Failure of root coverage of shallow gingival recessions employing GTR and a bioresorbable membrane. *Int J Periodontics Restorative Dent.* 2001;21:171-81.
- 19- Nickels K, Ratka-Krüger P, Neukranz E, Raetzke P, Eickholz P. Ten-year results after connective tissue grafts and guided tissue regeneration for root coverage. *J Periodontol.* 2010;81:827-36.
- 20- Parma-Benfenati S, Tinti C. Histologic evaluation of new attachment utilizing a titanium-reinforced barrier membrane in a mucogingival recession defect. A case report. *J Periodontol.* 1998;69:834-9.
- 21- Passanezi E, Janson WA, Nahas D, Campos Júnior A. Newly forming bone autografts to treat periodontal infrabony pockets: clinical and histological events. *Int J Periodontics Restorative Dent.* 1989;9:141-53.
- 22- Penteado R, Romito GA, Pustiglioni FE, Marques MM. Morphological and proliferative analysis of the healing tissue in human alveolar sockets covered or not by an e-PTFE membrane: a preliminary immunohistochemical and ultrastructural study. *Braz J Oral Sci.* 2005;4:664-9.
- 23- Pini Prato GP, Tinti C, Vincenzi G, Magnani C, Cortellini P, Clauser C. Guided tissue regeneration versus mucogingival surgery in the treatment of human buccal recession. *J Periodontol.* 1992;63:919-28.
- 24- Rosetti EP, Marcantonio RA, Rossa C Jr, Chaves, ES, Goissis G, Marcantonio E Jr. Treatment of gingival recession: comparative study between subepithelial connective tissue graft and guided tissue regeneration. *J Periodontol.* 2000;71:1441-7.
- 25- Shih SD, Allen EP. Use of guided tissue regeneration to treat a mucogingival defect associated with interdental bone loss: a case report. *Int J Periodontics Restorative Dent.* 1994;14:552-61.
- 26- Tinti C, Vicenzi G, Cortellini P, Pini Prato G, Clauser C. Guided tissue regeneration in the treatment of human facial recession. A 12-case report. *J Periodontol.* 1992;63:554-60.
- 27- Trombelli L, Schincaglia GP, Scapoli C, Calura G. Healing response of buccal gingival recessions treated with expanded polytetrafluoroethylene membranes. A retrospective report. *J Periodontol.* 1995;66:14-22.
- 28- Urbani G, Lombardo G, Castellarin M, Santi E, Abtibol T. Surgical correction of gingival recessions associated with radicular carious lesions. *Compend Contin Educ Dent.* 1996;17:330-2.
- 29- Wang H-L, Bunyaratavej P, Labadie M, Shyr Y, MacNeil RL. Comparison of 2 techniques for treatment of gingival recession. *J Periodontol.* 2001;72:1301-11.
- 30- Zucchelli G, Clauser C, De Sanctis M, Calandriello M. Mucogingival versus guided tissue regeneration procedures in the treatment of deep recession type defects. *J Periodontol.* 1998;69:138-45.