



Universidade de São Paulo

Biblioteca Digital da Produção Intelectual - BDPI

Departamento de Ortopedia e Traumatologia - FM/MOT

Artigos e Materiais de Revistas Científicas - FM/MOT

2012

Patellar Tendon Healing With Platelet-Rich Plasma A Prospective Randomized Controlled Trial

AMERICAN JOURNAL OF SPORTS MEDICINE, THOUSAND OAKS, v. 40, n. 6, pp. 1282-1288, JUN, 2012

<http://www.producao.usp.br/handle/BDPI/42748>

Downloaded from: Biblioteca Digital da Produção Intelectual - BDPI, Universidade de São Paulo

The American Journal of Sports Medicine

<http://ajs.sagepub.com/>

Patellar Tendon Healing With Platelet-Rich Plasma : A Prospective Randomized Controlled Trial

Adriano Marques de Almeida, Marco Kawamura Demange, Marcel Faraco Sobrado, Marcelo Bordalo Rodrigues, André Pedrinelli and Arnaldo José Hernandez

Am J Sports Med 2012 40: 1282 originally published online April 2, 2012

DOI: 10.1177/0363546512441344

The online version of this article can be found at:

<http://ajs.sagepub.com/content/40/6/1282>

Published by:



<http://www.sagepublications.com>

On behalf of:



[American Orthopaedic Society for Sports Medicine](#)

Additional services and information for *The American Journal of Sports Medicine* can be found at:

Email Alerts: <http://ajs.sagepub.com/cgi/alerts>

Subscriptions: <http://ajs.sagepub.com/subscriptions>

Reprints: <http://www.sagepub.com/journalsReprints.nav>

Permissions: <http://www.sagepub.com/journalsPermissions.nav>

>> [Version of Record](#) - Jun 1, 2012

[OnlineFirst Version of Record](#) - Apr 2, 2012

[What is This?](#)

Patellar Tendon Healing With Platelet-Rich Plasma

A Prospective Randomized Controlled Trial

Adriano Marques de Almeida,^{*†} MD, MS, Marco Kawamura Demange,[†] MD, PhD, Marcel Faraco Sobrado,[‡] Marcelo Bordalo Rodrigues,[†] MD, André Pedrinelli,[†] MD, PhD, and Arnaldo José Hernandez,[†] MD, PhD
Investigation performed at the Department of Orthopedics and Traumatology, São Paulo University Medical School, São Paulo, Brazil

Background: The patellar tendon has limited ability to heal after harvesting its central third. Platelet-rich plasma (PRP) could improve patellar tendon healing.

Hypothesis: Adding PRP to the patellar tendon harvest site would improve donor site healing and improve clinical outcome at 6 months after anterior cruciate ligament (ACL) reconstruction with a patellar tendon graft.

Study Design: Randomized controlled trial; Level of evidence, 1.

Methods: Twenty-seven patients were randomly divided to receive ($n = 12$) or not receive ($n = 15$) PRP in the patellar tendon harvest site during ACL reconstruction. The primary outcome was magnetic resonance imaging (MRI) assessment of patellar tendon healing (gap area) after 6 months. Secondary outcomes were questionnaires and isokinetic testing of ACL reconstruction with a patellar tendon graft comparing both groups.

Results: Patellar tendon gap area was significantly smaller in the PRP group ($4.9 \pm 5.3 \text{ mm}^2$; 95% confidence interval [CI], 1.1-8.8) than in the control group ($9.4 \pm 4.4 \text{ mm}^2$; 95% CI, 6.6-12.2; $P = .046$). Visual analog scale score for pain was lower in the PRP group immediately postoperatively (3.8 ± 1.0 ; 95% CI, 3.18-4.49) than in the control group (5.1 ± 1.4 ; 95% CI, 4.24-5.90; $P = .02$). There were no differences after 6 months in questionnaire and isokinetic testing results comparing both groups.

Conclusion: We showed that PRP had a positive effect on patellar tendon harvest site healing on MRI after 6 months and also reduced pain in the immediate postoperative period. Questionnaire and isokinetic testing results were not different between the groups at 6 months.

Keywords: platelet-rich plasma; patellar ligament; tendon; growth factors; healing; sports

Platelet-rich plasma (PRP) has been shown experimentally to improve tendon and ligament healing because of the presence of an increased concentration of growth factors.³⁸ In rats, PRP injection improved Achilles tendon healing.⁴

*Address correspondence to Adriano Marques de Almeida, MD, MS, Department of Orthopedics and Traumatology, São Paulo University Medical School, FIFA Medical Centre of Excellence, R. Dr. Ovidio Pires de Campos, 333, Cerqueira César, 05403-010 São Paulo, Brazil (e-mail: adrianoalmeida@usp.br).

[†]Department of Orthopedics and Traumatology, São Paulo University Medical School, São Paulo, Brazil.

[‡]São Paulo University Medical School, São Paulo, Brazil.

One or more of the authors has declared the following potential conflict of interest or source of funding: Criogenesis and Haemonetics Corp provided the personnel support and platelet-rich plasma separation system used in this study.

The American Journal of Sports Medicine, Vol. 40, No. 6
DOI: 10.1177/0363546512441344
© 2012 The Author(s)

In rabbits, PRP injection increased ultimate strength and stiffness when applied to the patellar tendon.²⁷

In sports medicine, some studies have shown that PRP can enhance the recovery of athletes with ligament and tendon injuries.¹⁵ After anterior cruciate ligament (ACL) reconstruction, PRP achieved a complete homogeneous graft in half of the time compared with a control group.³¹ A level III study has shown that PRP hastened the recovery of athletes with an Achilles tendon injury.³² Moreover, studies have shown better outcomes in chronic patellar tendinopathy with PRP.^{17,24} The use of PRP in the patellar tendon harvest site reduced donor site morbidity after ACL reconstruction.⁹

However, other high-level evidence studies have not shown benefits in the use of PRP. A level I study found PRP to be as efficient as saline in Achilles tendinopathy treatment.¹⁶ In ACL reconstructions with allografts, Achilles tendon ruptures, and rotator cuff lesions, PRP did not improve surgical treatment results.^{8,30,33}

Concerning traumatic sports injuries, one might consider the heterogeneity of these lesions, making them

TABLE 1
Descriptions of the 2 Groups

	Platelet-Rich Plasma	Control	P Value
No. of patients	12	15	—
Mean age (range), y	25.8 (18-44)	23.1 (15-34)	.309 ^b
Men/women, n	10/2	14/1	.569 ^c
Associated lesions, ^a n	7	9	>.99 ^c

^aPatients with meniscal or chondral lesions (grade IV) associated with anterior cruciate ligament injury.

^bStudent *t* test.

^cFisher exact test.

difficult to compare in prospective randomized trials.¹⁴ The patellar tendon is often used as a graft donor site for ACL reconstruction. This procedure creates a standard and well-defined defect, or gap, in the patellar tendon central third. Several studies assessed harvest site defect healing with magnetic resonance imaging (MRI), showing that this healing is usually partial, even after many years.^{7,21-23,29}

In animal studies, patellar tendon defects have been used as an experimental model to assess the effect of growth factors and PRP. Basic fibroblast growth factor used in a patellar tendon defect increased fibroblast proliferation and collagen type III synthesis in rats.^{10,11} Application of transforming growth factor- β 1 increased the mechanical properties of the regenerated tissue in the rabbit's patellar tendon after resection of the central portion.³ Also, PRP improved the mechanical properties of the rabbit's patellar tendon after resection of its central portion.²⁷

In this study, we used the patellar tendon harvest site as an experimental model to assess the effect of PRP on patellar tendon healing in humans in a prospective, randomized, evaluator-blinded study. The hypothesis was that adding PRP to the patellar tendon harvest site would improve tendon healing and improve clinical outcome at 6 months after ACL reconstruction with a patellar tendon graft.

MATERIALS AND METHODS

Approval by the local ethics committee and written informed consent were obtained. Recruitment started in November 2008 and was completed in February 2010. Inclusion criteria were ACL injury, bone maturity, and age less than 45 years. Exclusion criteria were complex ligament lesions, osteoarthritis, previous surgeries in the same joint, postoperative infection, arthrofibrosis, reoperation, inadequate follow-up, and thrombocytopenia.

Twenty-eight patients met the inclusion criteria; one refused to participate. Twenty-seven patients were randomized using a computer-generated sequence into 2 groups: PRP ($n = 12$) and control ($n = 15$). The resulting demographics are summarized in Table 1. In the PRP group of patients, PRP was added to the patellar tendon defect after harvesting its central third for an ACL reconstruction graft; in the control group of patients, nothing was added. All patients received the allocated treatment (Figure 1).

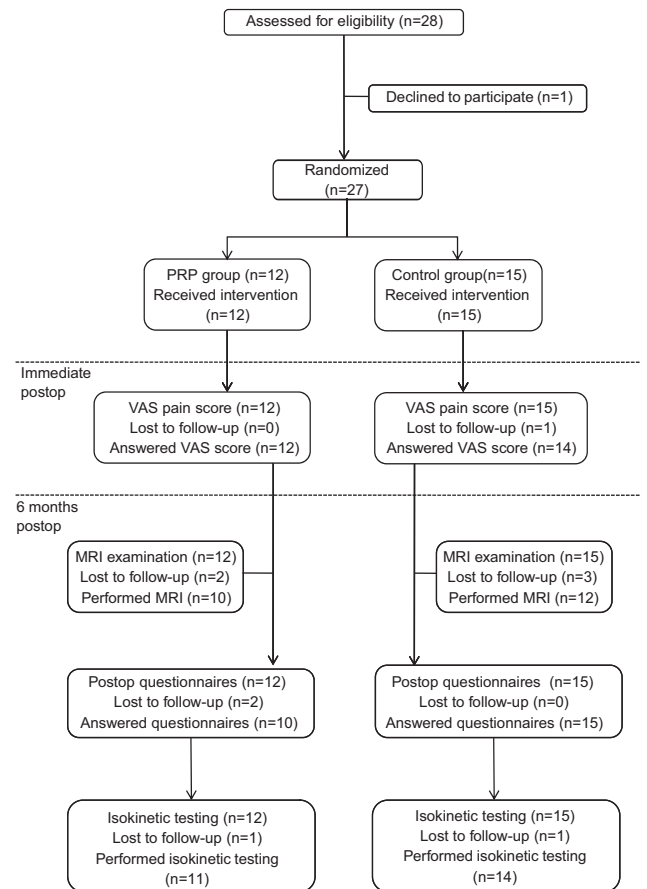


Figure 1. CONSORT flow diagram.

Outcomes

The primary outcome was magnetic resonance imaging (MRI) assessment of patellar tendon harvest site healing. On MRI, we also evaluated tendon thickness and length. Secondary outcomes were functional and clinical evaluations of ACL reconstruction with a patellar tendon graft to examine whether adding PRP to the harvest site affects the clinical and functional outcomes of the procedure. We determined postoperative pain, specific questionnaires of knee function, and isokinetic testing. Any complication was reported whether related to the procedures or not. Our hypotheses were that PRP would increase patellar tendon defect healing and improve clinical outcome at 6 months after the surgery.

PRP Gel Preparation

Platelet-rich plasma was obtained from each patient from the PRP group during anesthesia. A Haemonetics MCS+ 9000 cell separator with a specific kit for platelet apheresis 995-E (Haemonetics Corp, Braintree, Massachusetts) was used in the operating room simultaneously with ACL reconstruction. This cell separator withdraws 450 mL of autologous whole blood through a peripheral venous catheter. Citrate (10%) was used as anticoagulant. Platelet-rich

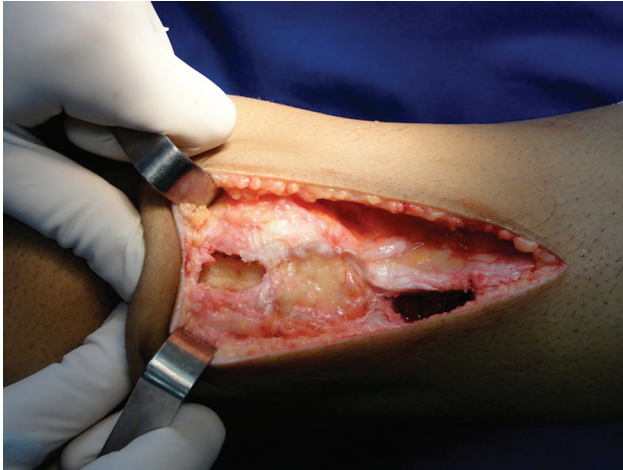

Figure 2. Patellar tendon harvest site prepared to receive (or not) platelet-rich plasma.

plasma was separated from platelet-poor plasma (PPP) and red blood cells in different sterile collection bags. The red blood cells and PPP (up to 400 mL) were returned to the patient from their collection bags through the peripheral venous access. With this system, we could obtain 30 to 50 mL of PRP. So, in fact, the total amount of blood collected from the patient is up to 50 mL.

The PRP obtained was divided into 10-mL tubes. To the first tube, 0.8 mL of calcium chloride (CaCl_2) was added to allow clot formation and separate it from the plasma, which contains autologous thrombin. We added 1 mL of the resulting plasma with thrombin plus 0.8 mL of CaCl_2 to another tube to generate the PRP gel. The average concentration of platelets in PRP was $1,185,166/\text{mm}^3 \pm 404,472/\text{mm}^3$ and represented an average increase of 7.65 times (range, 3.82-26.03) related to basal levels. Average white blood cell concentration was $0.91/\text{mm}^3 \pm 0.81/\text{mm}^3$.

Surgical Technique

A single surgeon performed all surgical procedures. Under tourniquet control, a longitudinal incision was made in the anterior aspect of the knee. The peritendon was open longitudinally and separated from the underlying patellar tendon. We obtained a bone–patellar tendon–bone graft with 1-cm width, measured with a ruler. The ACL reconstruction was performed arthroscopically using the trans-tibial drilling technique, and the graft was fixed with a transverse double pin absorbable system (Rigidfix, Depuy Orthopaedics, Warsaw, Indiana) in the femur and an absorbable interference screw in the tibia.

The harvest site was prepared in both groups with absorbable 3-0 sutures at the patellar tendon margins to the underlying fat pad to avoid the gel entering the knee joint through the fat pad (Figure 2). In the PRP group, the patellar tendon defect was completely filled with 20 to 40 mL of PRP gel (Figure 3), and in the control group, nothing was added. The peritendon was closed with absorbable 3-0 sutures without closing the tendon itself.

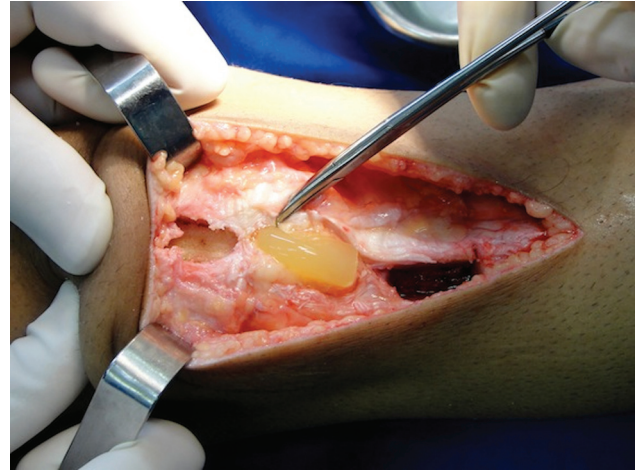


Figure 3. Platelet-rich plasma gel being added to the patellar tendon harvest site.

Postoperative Period and Visual Analog Scale

Suction drains were used inside the knee joint and removed before the patient was discharged, 24 hours after the operation. No drains were used in the subcutaneous tissue. During this period, postoperative analgesia was carefully monitored, and all patients received the same medications (ketoprofen, tramadol, sodium dipyrone) with the same dosage at the same intervals. A visual analog scale (VAS) was used to evaluate pain level at the first postoperative day. We allowed early range of motion and progressive weightbearing with crutches for 3 weeks. All patients followed the same rehabilitation protocol.

Magnetic Resonance Imaging

Patients were requested to have an MRI examination after 6 months to assess patellar tendon harvest site healing. All MRI studies were performed with a 1.5-T magnetic resonance system (Signa Excite HDXT, GE Healthcare, Waukesha, Wisconsin) by using a dedicated 8-channel knee coil. In all patients, axial T2-weighted fat-saturated fast spin-echo sequences (repetition time [TR]/echo time [TE], 3500-4467/65-70 milliseconds; echo train length, 8; 32 sections; number of signals acquired, 3; acquisition time, 4:35 minutes; bandwidth, 31.25 kHz) and sagittal T2-weighted fat-saturated (TR/TE, 3600-4100/84-88; echo train length, 10; 23 sections; number of signals acquired, 2; acquisition time, 3:50 minutes; bandwidth, 31.25 kHz) and intermediate-weighted (TR/TE, 2000-2300/14-18; echo train length, 6; 23 sections; number of signals acquired, 2; acquisition time, 3:10 minutes; bandwidth, 41.67 kHz) fast spin-echo sequences were performed. Sequence parameters included 3.5-mm section thickness, 256 to 512 \times 192 to 256 matrix size, and 140 \times 140-mm field of view. An independent, experienced musculoskeletal radiologist performed all blinded evaluations.

Using the MRI reconstruction program and computerized distance measurements, the following parameters

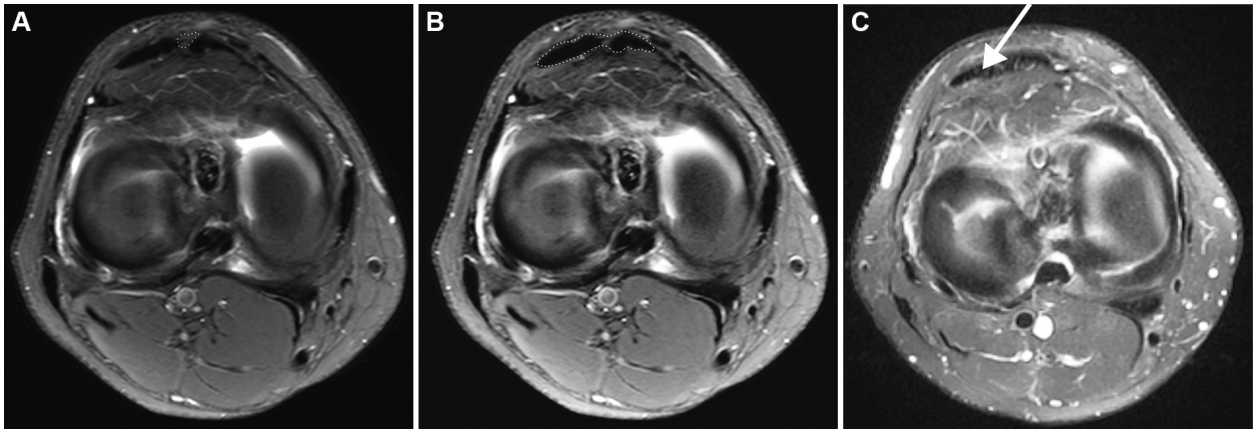

Figure 4. Using magnetic resonance imaging (MRI), (A) the gap area of the patellar tendon harvest site and the cross-sectional area of the patellar tendon (B) were calculated through the midpoint along the length of the tendon from the apex of the patella to the insertion at the tibial tubercle, as shown in this control group patient. (C) An MRI scan of a platelet-rich plasma group patient, showing a smaller gap (arrow).

were considered based on previously published data (Figure 4).^{7,21-23,29}

1. Gap area of the patellar tendon harvest site (mm^2): in the axial direction, the gap size was evaluated in the donor site corresponding to non-tendinous-like tissue signal. Measurement was performed at the midpoint through the length of the tendon from the apex of the patella to the insertion at the tibial tubercle.
2. Cross-sectional area of the patellar tendon (mm^2): in the axial direction, at the same point, the cross-sectional area of the entire ligament, including the defect, was determined to assess ligament thickness.
3. Patellar height was assessed in the sagittal view with the Insall-Salvati index, determined by the patella length and patellar tendon length ratio.

Isokinetic Testing and Questionnaires

Before the surgical procedure, patients answered knee function questionnaires (Lysholm, subjective International Knee Documentation Committee, Kujala, and Tegner) and submitted to isokinetic testing. These procedures were repeated 6 months after surgery. Isokinetic strength measurements of the quadriceps and hamstring muscles were performed on a Biodex System 3 Pro (Biodex Medical Systems Inc, Shirley, New York) at 60 and 240 deg/s. We compared the quadriceps peak torques of the injured and noninjured leg to calculate the quadriceps peak torque deficit.

Statistical Analysis

Magnetic resonance imaging data, patient age, and VAS score were analyzed with the Student *t* test. For VAS score, patient age was controlled with analysis of variance

(ANOVA). Statistical analysis of associated chondral or meniscal lesions and patient gender were performed using the Fisher exact test. Questionnaire and isokinetic testing data were compared with the Student *t* test or the Mann-Whitney *U* test, depending on distribution. All *P* values were 2-sided. A *P* value of .05 indicated a statistically significant difference.

RESULTS

No adverse effects occurred in these patients. Detailed descriptions of the demographics of the 2 groups are shown in Table 1. No differences were found between groups related to age, gender, or meniscal and chondral lesions related to ACL injury.

Magnetic Resonance Imaging

Magnetic resonance imaging was performed after surgery at an average of 208 days in PRP group patients and 212 days in control group patients, with no statistical difference. Patellar tendon harvest site nonregenerated area (gap area) in the PRP group patients was $4.9 \pm 5.4 \text{ mm}^2$ (95% confidence interval [CI], 1.1-8.8) and in the control group patients was $9.4 \pm 4.4 \text{ mm}^2$ (95% CI, 6.6-12.2). Statistical analysis showed a significant difference between groups ($P = .046$). There were no differences between the groups in the cross-sectional area of the patellar tendon or patella height, as reported in Table 2.

VAS Score

Postoperative average VAS pain score in the PRP patients was 3.8 ± 1.0 (95% CI, 3.18-4.49) compared with 5.1 ± 1.4 (95% CI, 4.24-5.90) in the control group. The difference was

TABLE 2
Magnetic Resonance Imaging (MRI) Measurements

	Platelet-Rich Plasma	Control	P Value ^a
Days to perform MRI, mean (range)	208 (170-266)	212 (170-285)	.83
Gap area, mean \pm SD, mm ²	4.9 \pm 5.4	9.4 \pm 4.4	.046 ^b
Cross-sectional area, mean \pm SD, mm ²	173.0 \pm 30.5	176.3 \pm 48.6	.856
Insall-Salvati index, mean \pm SD	1.0 \pm 0.1	1.1 \pm 0.2	.806

^aStudent *t* test.

^bStatistically significant ($P < .05$).

TABLE 3
Preoperative and Postoperative Results of Isokinetic Testing and Questionnaires^a

	PRP			Control			PRP \times Control ^c	
	Preoperative	Final	<i>P</i> ^b	Preoperative	Final	<i>P</i> ^b	Preoperative	Final
Peak torque deficit at 60 deg/s ^d	27.3 \pm 34.4	44.7 \pm 18.0	.03	18.2 \pm 14.2	40.8 \pm 12.3	<.001	.86	.82
Peak torque deficit at 240 deg/s ^d	16.8 \pm 28.7	30.6 \pm 21.9	.08	11.4 \pm 15.8	30.9 \pm 10.8	<.001	.77	.57
Lysholm ^e	63.5 (45-88)	91.5 (64-100)	.001	58.0 (25-75)	89 (69-100)	<.001	.2	.56
IKDC ^e	54.3 (25.3-83.9)	79.3 (50.6-96.6)	.02	55.2 (25.3-93.1)	73.5 (52.9-98.9)	<.001	.83	.61
Kujala ^e	62.5 (32-98)	88.5 (70-98)	.002	69 (51-91)	86 (72-95)	<.001	.81	.33
Tegner ^e	9 (7-10)	5 (4-7)	<.001	7 (5-10)	4 (4-9)	<.001	.07	.21
VAS ^e	—	4 (2-6)	—	—	5 (2-7)	—	—	.02 ^f

^aPRP, platelet-rich plasma; IKDC, International Knee Documentation Committee; VAS, visual analog scale.

^bStudent *t* test (paired).

^cMann-Whitney test, *P* values.

^dPercentage deficit from the noninjured side; mean \pm standard deviation.

^eMedian (range).

^fStudent *t* test with ANOVA.

statistically significant, indicating that PRP patients had less postoperative pain ($P = .02$).

Questionnaires and Isokinetic Testing

Comparing preoperative and postoperative results on subjective tests, we found that 6 months after arthroscopic ACL reconstruction surgery, both groups improved all scores except for the Tegner. On the Tegner questionnaire, both groups had worse results. When comparing the questionnaire scores of the 2 groups, there was no statistically significant difference. Comparing preoperative and postoperative quadriceps isokinetic testing results, both groups had an increased quadriceps peak torque deficit 6 months after ACL reconstruction. There was no statistically significant difference in quadriceps peak torque deficit between groups (Table 3).

DISCUSSION

Harvesting the patellar tendon surgically creates a standardized defect, or gap, in the tendon central third. We

used it as an experimental model to assess the effect of PRP on patellar tendon healing.

Platelet-rich plasma has been used to improve the recovery of ligament and tendon injuries in athletes, in spite of a lack of definite clinical evidence.^{12,18,26} Previous experimental data have shown an improvement in patellar tendon healing in rabbits with PRP, with increased force at failure, ultimate stress and stiffness, and collagen synthesis.²⁷ Application of PRP gel at the patellar tendon donor site level significantly reduced knee pain after ACL reconstruction with patellar tendon grafts.⁹ In that study, the authors showed no difference in the MRI signal of the tendon donor site compared with a control group, but their evaluation was only qualitative and not quantitative.

Previous studies have used MRI to evaluate quantitatively the natural outcome of the patellar tendon after harvesting its central third, showing a progressive gap reduction, with a plateau after 2 years,^{7,21-23} and a persistent defect even after many years.^{28,34,35} Previous histochemical and ultrastructural study of the patellar tendon donor site showed that it does not normalize over time.^{6,25,35}

We showed that the patellar tendon had a significantly smaller gap size in the PRP group than in the control cases

after 6 months. It indicates that PRP enhanced tendon healing. To verify the possibility of thickening or shortening of the patellar tendon, we also evaluated tendon thickness and length and showed no difference between the groups.

As secondary objectives, we evaluated the clinical and functional outcomes of ACL reconstruction comparing both groups. The VAS pain scores were lower in the PRP group than in the control group in the immediate postoperative period. This analgesic effect of PRP was also shown in other applications, such as knee arthroplasty¹⁹ and periodontal surgery.² This may be because of the presence of substances in PRP other than the growth factors, such as serotonin, dopamine, and catecholamines.¹²

The exact mechanisms of action of PRP are not fully understood. Mechanical load is essential to tendon healing. One experiment in rats³⁷ evaluated the effect of PRP and botulinum toxin in the Achilles tendon. They found that the paralyzation of the gastrocnemius muscle with this toxin reduced the positive effect of PRP in tendon healing. They concluded that there is an interplay between PRP action and mechanical load, with PRP-treated tendons responding earlier to this stimulus. However, many *in vitro* studies have shown a positive effect of growth factors and PRP without mechanical load.^{1,5,10} Therefore, we believe that both mechanisms, direct and indirect, are involved.

After 6 months, knee function scores were improved in both groups, except the Tegner results, where the findings worsened in both groups. This is expected because Tegner questionnaires address sports activities,³⁶ and at 6 months, most patients are beginning to return to strenuous sports after ACL reconstruction.²⁰ Regarding the quadriceps isokinetic testing, both groups had an increased quadriceps peak torque deficit at 6 months compared with preoperative levels. This was also expected according to the literature.¹³ These instruments of evaluation are not specific for donor site morbidity and determine the results of ACL rupture treatment, in which harvest site morbidity is just a part of the outcome.

Strengths of this study are that it is a prospective, randomized, and evaluator-blinded study, in which all parameters were evaluated independently. Another strength is the injury pattern, which creates a standard defect in the central portion of the patellar tendon. Through this experimental model, we could assess and compare patellar tendon harvest site healing after a standardized and well-established procedure.

This study has provided some interesting insights but also has some limitations. A weakness in this study is the small number of patients. We had no previously published data to estimate the difference between the groups to calculate the sample size. Second, VAS pain was measured only within the first 24 hours after the surgery, so the duration of the difference in pain is unknown. However, pain is one query of the knee function scores used in this study, which showed no difference between the groups after 6 months.

This clinical follow-up period is considered short for ACL surgery outcomes, but our purpose was not to assess

the final outcomes of ACL reconstruction surgery but to evaluate whether there was any clinical difference between the groups. Despite better healing of the patellar tendon harvest site in PRP group patients, we did not find any difference in the score results. We also made a power analysis for these variables and found that, to show a significant difference between the groups, the sample size would need to be huge. We believe that the need for a large sample size in an ACL surgical study may translate in a low clinical significance of the intervention. Finally, a biopsy of the tissue was not performed, and therefore, we cannot comment on whether the structure, composition, or mechanical properties of the patellar tendon were improved by PRP.

In conclusion, we confirmed the hypothesis that PRP could improve tissue healing at the patellar tendon harvest site. Platelet-rich plasma also reduced pain in the immediate postoperative period. With the clinical and functional evaluation instruments used in this study, we were not able to find any difference in the outcome of the procedure, and therefore, PRP did not seem to improve patients' early recovery after ACL reconstruction with a patellar tendon graft.

ACKNOWLEDGMENT

The authors thank Luiz César Spirandelli, Nelson Tatsui, Marcia Maria de Camargo, and Criogenesis for providing the personnel support and platelet-rich plasma separation system equipment used in this study.

REFERENCES

1. Abrahamsson SO, Lundborg G, Lohmander LS. Long-term explant culture of rabbit flexor tendon: effects of recombinant human insulin-like growth factor-I and serum on matrix metabolism. *J Orthop Res.* 1991;9(4):503-515.
2. Alissa R, Esposito M, Horner K, Oliver R. The influence of platelet-rich plasma on the healing of extraction sockets: an explorative randomized clinical trial. *Eur J Oral Implantol.* 2010;3(2):121-134.
3. Anaguchi Y, Yasuda K, Majima T, Tohyama H, Minami A, Hayashi K. The effect of transforming growth factor-beta on mechanical properties of the fibrous tissue regenerated in the patellar tendon after resecting the central portion. *Clin Biomech.* 2005;20(9):959-965.
4. Aspenberg P, Virchenko O. Platelet concentrate injection improves Achilles tendon healing in rats. *Acta Orthop Scand.* 2004;75(1):93-99.
5. Bagnaninchi PO, Yang Y, El Haj AJ, Maffulli N. Tissue engineering for tendon healing. *Br J Sports Med.* 2007;41(8):e10.
6. Battlehner CN, Carneiro Filho M, Ferreira Junior JM, Saldiva PH, Montes GS. Histochemical and ultrastructural study of the extracellular matrix fibers in patellar tendon donor site scars and normal controls. *J Submicrosc Cytol Pathol.* 1996;28(2):175-186.
7. Bernicker JP, Haddad JL, Lintner DM, DiLiberti TC, Bocell JR. Patellar tendon defect during the first year after anterior cruciate ligament reconstruction: appearance on serial magnetic resonance imaging. *Arthroscopy.* 1998;14(8):804-809.
8. Castricini R, Longo UG, De Benedetto M, et al. Platelet-rich plasma augmentation for arthroscopic rotator cuff healing: a randomized controlled trial. *Am J Sports Med.* 2011;39(2):258-265.
9. Cervellini M, de Girolamo L, Bait C, Denti M, Volpi P. Autologous platelet-rich plasma gel to reduce donor-site morbidity after patellar tendon graft harvesting for anterior cruciate ligament reconstruction:

- a randomized, controlled clinical study. *Knee Surg Sports Traumatol Arthrosc.* 2012;20(1):114-120.
10. Chan BP, Chan KM, Maffulli N, Webb S, Lee KK. Effect of basic fibroblast growth factor: an in vitro study of tendon healing. *Clin Orthop.* 1997;342:239-247.
 11. Chan BP, Fu S, Qin L, Lee K, Rolf CG, Chan K. Effects of basic fibroblast growth factor (bFGF) on early stages of tendon healing: a rat patellar tendon model. *Acta Orthop Scand.* 2000;71(5):513-518.
 12. Creaney L, Hamilton B. Growth factor delivery methods in the management of sports injuries: the state of play. *Br J Sports Med.* 2008;42(5):314-320.
 13. Dauty M, Tortellier L, Rochcongar P. Isokinetic and anterior cruciate ligament reconstruction with hamstrings or patella tendon graft: analysis of literature. *Int J Sports Med.* 2005;26(7):599-606.
 14. Demange MK, Fregni F. Limits to clinical trials in surgical areas. *Clinics.* 2011;66(1):159-161.
 15. de Vos RJ, van Veldhoven PL, Moen MH, Weir A, Tol JL, Maffulli N. Autologous growth factor injections in chronic tendinopathy: a systematic review. *Br Med Bull.* 2010;95:63-77.
 16. de Vos RJ, Weir A, van Schie HT, et al. Platelet-rich plasma injection for chronic Achilles tendinopathy: a randomized controlled trial. *JAMA.* 2010;303(2):144-149.
 17. Filardo G, Kon E, Della Villa S, Vincentelli F, Fornasari PM, Marcacci M. Use of platelet-rich plasma for the treatment of refractory jumper's knee. *Int Orthop.* 2010;34(6):909-915.
 18. Foster TE, Puskas BL, Mandelbaum BR, Gerhardt MB, Rodeo SA. Platelet-rich plasma: from basic science to clinical applications. *Am J Sports Med.* 2009;37(11):2259-2272.
 19. Gardner MJ, Demetrakopoulos D, Klepchick PR, Moar PA. The efficacy of autologous platelet gel in pain control and blood loss in total knee arthroplasty: an analysis of the haemoglobin, narcotic requirement and range of motion. *Int Orthop.* 2007;31(3):309-313.
 20. Gobbi A, Mahajan S, Zanazzo M, Tuy B. Patellar tendon versus quadrupled bone-semi-tendinosus anterior cruciate ligament reconstruction: a prospective clinical investigation in athletes. *Arthroscopy.* 2003;19(6):592-601.
 21. Kartus J, Lindahl S, Kohler K, Sernert N, Eriksson BI, Karlsson J. Serial magnetic resonance imaging of the donor site after harvesting the central third of the patellar tendon: a prospective study of 37 patients after arthroscopic anterior cruciate ligament reconstruction. *Knee Surg Sports Traumatol Arthrosc.* 1999;7(1):20-24.
 22. Kartus J, Movin T, Papadogiannakis N, Christensen LR, Lindahl S, Karlsson J. A radiographic and histologic evaluation of the patellar tendon after harvesting its central third. *Am J Sports Med.* 2000;28(2):218-226.
 23. Kartus J, Rostgard-Christensen L, Movin T, Lindahl S, Ejerhed L, Karlsson J. Evaluation of harvested and normal patellar tendons: a reliability analyses of magnetic resonance imaging and ultrasonography. *Knee Surg Sports Traumatol Arthrosc.* 2000;8(5):275-280.
 24. Kon E, Filardo G, Delcogliano M, et al. Platelet-rich plasma: new clinical application. A pilot study for treatment of jumper's knee. *Injury.* 2009;40(6):598-603.
 25. Liden M, Movin T, Ejerhed L, et al. A histological and ultrastructural evaluation of the patellar tendon 10 years after reharvesting its central third. *Am J Sports Med.* 2008;36(4):781-788.
 26. Lopez-Vidriero E, Goulding KA, Simon DA, Sanchez M, Johnson DH. The use of platelet-rich plasma in arthroscopy and sports medicine: optimizing the healing environment. *Arthroscopy.* 2010;26(2):269-278.
 27. Lyras DN, Kazakos K, Verettas D, et al. The effect of platelet-rich plasma gel in the early phase of patellar tendon healing. *Arch Orthop Trauma Surg.* 2009;129(11):1577-1582.
 28. Matava MJ. Patellar tendon ruptures. *J Am Acad Orthop Surg.* 1996;4(6):287-296.
 29. Meisterling RC, Wadsworth T, Ardill R, Griffiths H, Lane-Larsen CL. Morphologic changes in the human patellar tendon after bone-tendon-bone anterior cruciate ligament reconstruction. *Clin Orthop Relat Res.* 1993;289:208-212.
 30. Nin JR, Gasque GM, Azcarate AV, Beola JD, Gonzalez MH. Has platelet-rich plasma any role in anterior cruciate ligament allograft healing? *Arthroscopy.* 2009;25(11):1206-1213.
 31. Radice F, Yanez R, Gutierrez V, Rosales J, Pinedo M, Coda S. Comparison of magnetic resonance imaging findings in anterior cruciate ligament grafts with and without autologous platelet-derived growth factors. *Arthroscopy.* 2010;26(1):50-57.
 32. Sanchez M, Anitua E, Azofra J, Andia I, Padilla S, Mujika I. Comparison of surgically repaired Achilles tendon tears using platelet-rich fibrin matrices. *Am J Sports Med.* 2007;35(2):245-251.
 33. Schepull T, Kvist J, Norrman H, Trinks M, Berlin G, Aspenberg P. Autologous platelets have no effect on the healing of human Achilles tendon ruptures: a randomized single-blind study. *Am J Sports Med.* 2011;39(1):38-47.
 34. Svensson M, Kartus J, Ejerhed L, Lindahl S, Karlsson J. Does the patellar tendon normalize after harvesting its central third? A prospective long-term MRI study. *Am J Sports Med.* 2004;32(1):34-38.
 35. Svensson M, Movin T, Rostgard-Christensen L, Blomen E, Hultenby K, Kartus J. Ultrastructural collagen fibril alterations in the patellar tendon 6 years after harvesting its central third. *Am J Sports Med.* 2007;35(2):301-306.
 36. Tegner Y, Lysholm J. Rating systems in the evaluation of knee ligament injuries. *Clin Orthop Relat Res.* 1985;198:43-49.
 37. Virchenko O, Aspenberg P. How can one platelet injection after tendon injury lead to a stronger tendon after 4 weeks? Interplay between early healing and mechanical stimulation. *Acta Orthop.* 2006;77(5):806-812.
 38. Weibrich G, Kleis WK, Hafner G, Hitzler WE. Growth factor levels in platelet-rich plasma and correlations with donor age, sex, and platelet count. *J Craniomaxillofac Surg.* 2002;30(2):97-102.

For reprints and permission queries, please visit SAGE's Web site at <http://www.sagepub.com/journalsPermissions.nav>