



Universidade de São Paulo

Biblioteca Digital da Produção Intelectual - BDPI

Departamento de Cirurgia - FM/MCG

Artigos e Materiais de Revistas Científicas - FM/MCG

2012

Modified technique to increase nostril cross-sectional area after using rib and septal cartilage graft over alar nasal cartilages

ACTA CIRURGICA BRASILEIRA, SAO PAULO, v. 27, n. 10, pp. 713-719, OCT, 2012
<http://www.producao.usp.br/handle/BDPI/36350>

Downloaded from: Biblioteca Digital da Produção Intelectual - BDPI, Universidade de São Paulo

Modified technique to increase nostril cross-sectional area after using rib and septal cartilage graft over alar nasal cartilages¹

Técnica modificada para aumentar a área seccional externa da narina após o uso de enxerto cartilaginoso de costela e septo sob as cartilagens alares nasais

Marcelo Wulkan^I, Alvaro Julio de Andrade Sá^{II}, Nivaldo Alonso^{III}

^IFellow PhD degree, Postgraduate Program in Medicine (Surgical Clinic), USP, Sao Paulo-SP, Brazil. Conception, design, intellectual and scientific content of the study; acquisition and interpretation of data; manuscript writing.

^{II}MD, Resident, Plastic Surgery Division, Surgery Department, School of Medicine, USP, Sao Paulo-SP, Brazil. Conception, design, intellectual and scientific content of the study; acquisition and interpretation of data; manuscript writing.

^{III}PhD, Assistant Professor, Head of Craniomaxilofacial Surgery Unit, Plastic Surgery Division, Surgery Department, School of Medicine, USP, Sao Paulo-SP, Brazil. Analysis and interpretation of data, manuscript writing, critical revision.

ABSTRACT

PURPOSE: Describe a modified technique to increase nostril cross-sectional area using rib and septal cartilage graft over alar nasal cartilages.

METHODS: A modified surgical technique was used to obtain, carve and insert cartilage grafts over alar nasal cartilages. This study used standardized pictures and measured 90 cadaveric nostril cross-sectional area using Autocad[®]; 30 were taken before any procedure and 60 were taken after grafts over lateral crura (30 using costal cartilage and 30 using septal cartilage). Statistical analysis were assessed using a model for repeated measures and ANOVA (Analysis of Variance) for the variable “area”.

RESULTS: There’s statistical evidence that rib cartilage graft is more effective than septal cartilage graft. The mean area after the insertion of septal cartilage graft is smaller than the mean area under rib graft treatment (no confidence interval for mean difference contains the zero value and all P-values are below the significance level of 5%).

CONCLUSIONS: The technique presented is applicable to increase nostril cross section area in cadavers. This modified technique revealed to enhance more nostril cross section area with costal cartilage graft over lateral crura rather than by septal graft.

Key words: Rhinoplasty. Nasal Cartilages. Ribs. Cadaver.

RESUMO

OBJETIVO: Descrever uma técnica modificada para se aumentar a área seccional externa da narina com cartilagem septal e costal acima das cartilagens alares nasais.

MÉTODOS: Utilizou-se uma técnica cirúrgica modificada para obter, esculpir e inserir enxertos de cartilagem sobre as cartilagens alares. Realizou-se fotos padronizadas e mensuração de 90 áreas seccionais externas de narina em cadáveres com Autocad[®]; 30 antes sem procedimento; 60 após a inclusão de enxertos sob a cruz lateral (30 usando cartilagem costal e 30 usando cartilagem septal). A análise estatística foi feita com um modelo de medidas repetidas e ANOVA para a variável “área”

RESULTADOS: Existe evidência estatística de que o enxerto de cartilagem costal é mais efetivo que o enxerto de cartilagem septal. A área média após a inclusão do enxerto de septo é menor que a observada após a inclusão de enxerto de costela (intervalo de confiança para a diferença de médias não inclui o valor de zero e todos os valores de P são abaixo do nível significativo de 5%).

CONCLUSÕES: A técnica descrita é aplicável em cadáveres para aumento da área seccional externa da narina. Esta técnica modificada revelou ser mais efetiva com o uso de cartilagem costal do que septal.

Descritores: Rinoplastia. Cartilagens Nasais. Costelas. Cadáver.

Introduction

Aesthetic and functional rhinoplasty has been undergoing a fine-tuning process for several decades. While there are many techniques that the modern plastic surgeon can perform during a nasal surgery, there remains a significant gap concerning the external nasal valve¹⁻¹³.

The nostril cross-sectional area (NCSA) is commonly confused with the external nasal valve (ENV). These are closely related but not the same.

Clinically, lateral crural support is critical in the efficiency of the ENV, because it prevents nostril collapse during inspiration^{1,2}. Understanding nasal physiology and the causes that can change NCSA is crucial to planning a treatment if ENV collapse occurs.

The medial component, which may affect the NCSA, presents many good treatment options such as the columellar strut and columelloplasty³.

This study will focus on the benefits that can be achieved through a modified technique of cartilage graft situated on the lateral component of the NCSA, comparing costal and septal cartilage grafts used on fresh cadavers.

Methods

Fifteen fresh cadavers were randomly selected without taking into consideration sex, age and race. This study was approved by the Ethics Committee of the Sao Paulo University (protocol 0454/09).

After positioning the cadaver, the first thing done was to take a standardized photograph of the basal view: using a Nikon D60 camera and AF-S Micro Nikkor lens (60 mm 1: 2.8g ED), the object was photographed from a fixed distance of 15 cm and the same angle, in order to assess the nostril base located perpendicular to the sagittal plane. Figure 1 shows the nostril cross sectional area. For comparison purposes, an initial shot of each cadaver was taken prior to any operation (placement of cartilage graft).

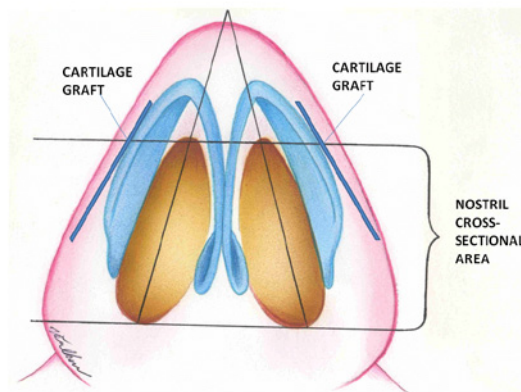


FIGURE 1 - Placement of cartilage grafts and nostril cross-sectional area (brown area).

Septal harvesting technique

The nasal septum was injected with saline solution in a subperichondrial plane in order to promote hydrostatic dissection to help elevate the mucoperichondrial flap from the underlying cartilage. A number 15 blade scalpel was used to make a 1 cm incision on the left caudal end of the septum and a closed dissection was made. A small piece of cartilage (with or without ethmoid) was taken, leaving 1 cm caudal and dorsal struts to allow for adequate support postoperatively.

Rib harvesting technique

The 5th Rib cartilage on the right side of the cadaver was taken using a 4 cm long incision right over the rib on men and at the inframammary crease on women. The incision was deepened through the subcutaneous tissue passing through muscular tissue and fascia. The muscle was separated in the direction of its fibers and using a fine scissor and scalpel, the rib was taken out from its medial and lateral bony/cartilaginous junction. The perichondrium was partially incised to allow its elevation with a Freer elevator that continuous to the deep aspect of the rib. A number 15 blade incised halfway of the rib medially and laterally and then a Freer elevator continuous a harmless dissection of the deep perichondrium layer. A 4cm rib cartilage was taken out and the remaining rib edges were smoothed using a Takahashi forceps. Then, the muscle and fascia were repaired with a 2-0 absorbable suture. When possible, the Scarpa's fascia was closed by a separate layer of vertical mattress suture using a 2-0 absorbable suture. Finally, the skin was closed with a running 5-0 non-absorbable suture.

Rib and septal carving

The rib cartilage was carved into three pieces using a number 22 blade scalpel. The outer layers were the anterior and posterior surfaces of the rib (Figure 2). The inner piece was carved till it reached two 30x 0.1x 0.5cm size graft. Then the costal graft was left into a saline solution for 45 minutes. The septal cartilage was carved more easily using a 15 blade scalpel till it reached two 3.0x 0.1x 0.5cm size graft. Grafts being carved can be seen on Figure 3.

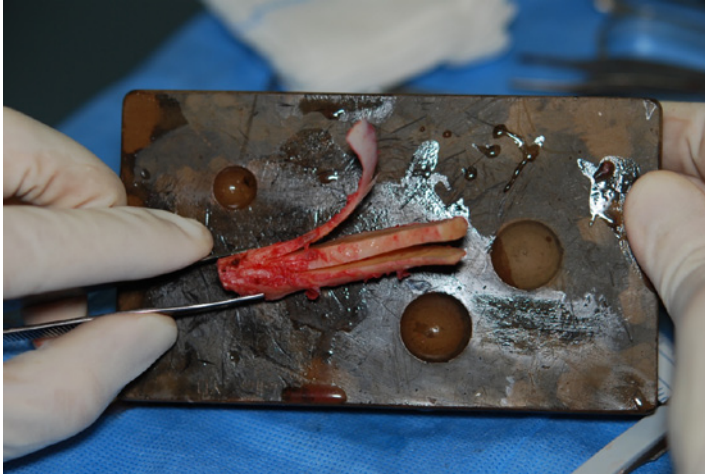


FIGURE 2 - Rib carving technique used only the central aspect of the cartilage because it's straighter.

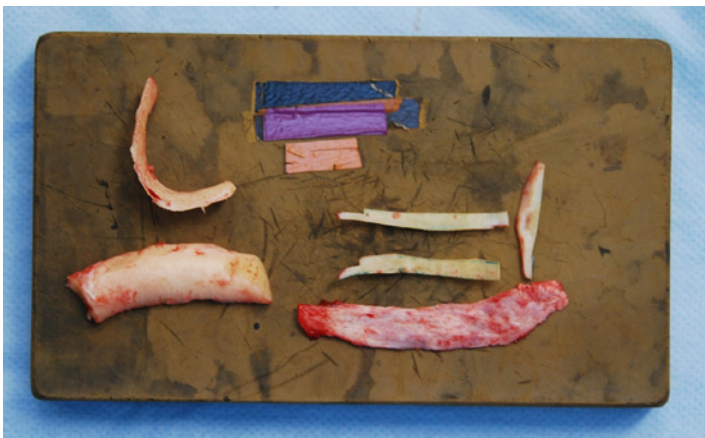

FIGURE 3- Costal cartilage grafts can become deviated (left side). Septum grafts are straighter (right side). The outer layer of the rib (perichondrium) can be seen below as a thin strip.

The grafts were completely beveled and it's medial aspect was oblique (Figure 4).

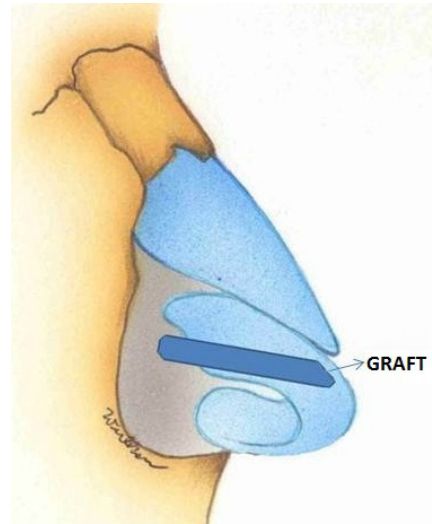


FIGURE 4 - The final aspect of the modified graft: it is completely beveled and it's medial aspect is oblique. Observe its position parallel to the nostril's margin.

Grafts insertion and post-operative pictures

Bilateral marginal incisions of the nostril were made in order to dissect a tight pocket above each lateral crura. The pocket size was approximately 3.1 x 0.6 cm. The manufactured flat grafts were inserted with a random sequence and fixed by stitches (6-0 nylon) next to the marginal incisions, followed by standardized photography as described above.

Nostril cross-section area evaluation and statistical analysis

Three standardized pictures were taken of each cadaver: before the insertion of the cartilage graft ("pre"), after the insertion of bilateral costal cartilage graft ("costal") and after the insertion of bilateral septal cartilage graft ("septal"). The 90 nostrils area measurements (30 "pre", 30 "septal" and 30 "costal") were made by a single expert in a Computer Aided Design (CAD) software application for 2D and 3D design and drafting (Autocad®). This expert was blind to the study and did not know whether the area he was measuring was "pre", "septal" or "costal".

In this study, we considered the following treatments applied in the right and left nostril of the same experimental unit (corpse): pre-cartilage graft ("pre") representing the intact nostril without any procedure performed, septal cartilage graft ("septal") and costal cartilage graft ("costal").

The 30 nostrils were considered to be a random sample from the population of possible nostrils, while the three treatments are of interest in themselves. Hence, a single-factor repeated

model was expected to be appropriate, with the effects of nostrils considered random and the effects of treatments considered fixed. The use of a single-factor repeated model for analyzing the data is justified noting that the three treatments were applied in the same nostril¹⁴⁻¹⁷.

The “nostril” factor was responsible for capturing the variability among cadavers, which is typical of this type of experiment. In other words, the nose served as its own control since it received all treatments. Including the nostril factor in the model allowed for control of the variability of the response variable area among different cadavers. These characteristics of the repeated measures model allowed the comparisons among the means of the response variable under the different treatments to be highly accurate¹⁴⁻¹⁷.

The model used is given by constants, the effect of nostril, the effect of each treatment and the random errors. Table 1 shows the ANOVA (Analysis of Variance) for the area data.

We’ve tested the treatments effects with $F^* = 0.157/0.007 = 21.98$. As the P -value for this test is 0+ (below the level of significance $\alpha = 0.05$), we conclude H_{a^*} , that the mean areas for the three treatments differ.

TABLE 1 – ANOVA. Area variable.

Source of Variation	Degrees of Freedom	Sum of Squares	Mean Square	F Statistic	P-value
Treatment	2	0.313	0.157	21.98	<0.0001
Nostril	29	8.640	0.298	41.81	<0.0001
Error	58	0.413	0.007	-	-

To compare all treatment means pairwise, with a 95 percent family confidence coefficient, the Tukey procedure¹⁸⁻²⁰ was utilized.

Results

The results obtained for the right nostril can be considered independent from those obtained for the left nostril. We note that although the average area is, descriptively, greater on the left side, the difference between the two sides appears to be constant throughout the treatments. Because of this result, the comparison between treatments is not affected by joining the observations of the area variable from both nostrils.

Considering the observations from both nostrils, the sample mean and sample standard deviation¹⁷ of the variable area under each treatment were analyzed. We note that the sample

mean of this variable for the “costal” and “septal” treatments are higher than the “pre” treatment and that the largest sample mean is under “costal” treatment. Table 1 shows the ANOVA (Analysis of Variance) for the area data.

A plot of the area values for each nostril is shown in figure 5. We see that the curves for the nostrils do not appear to exhibit substantial departures from being parallel. Hence, an additive model appears to be appropriate.

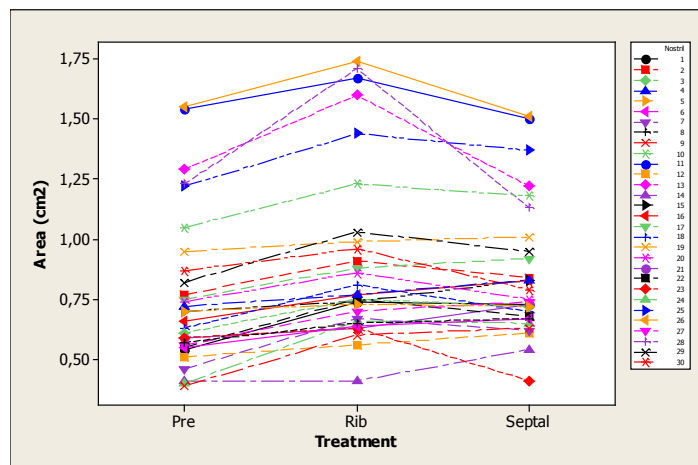


FIGURE 5 - Plot of the area values for each nostril.

To compare all treatment means pairwise, the Tukey procedure¹⁸⁻²⁰ was utilized.

Let the estimated pairwise mean difference be denoted by \hat{L} . The variance of \hat{L} was estimated by $0.007(1/30 + 1/30) = 0.00047$.

Table 2 shows the confidence intervals and respective P -values of the tests of the differences between each pair of means. The results of this table are similar to the results of the descriptive analysis.

TABLE 2 - Tests and Confidence Intervals (Tukey procedure with a 95 percent family confidence coefficient for the pairwise comparisons of mean areas).

Difference	Confidence Interval	P-value
$Mean_{Septal} - Mean_{Pre}$	(0.033 ; 0.138)	0.0007
$Mean_{Costal} - Mean_{Pre}$	(0.091 ; 0.196)	< 0.0001
$Mean_{Costal} - Mean_{Septal}$	(0.006 ; 0.111)	0.0258

There is statistical evidence that the mean area under the variable “pre” treatment is lower than under the “septal”, which in turn is smaller than under the “costal” treatment (no confidence interval for mean difference contains the zero value and all

P-values are below the level of significance $\alpha = 0.05$). Moreover, we note that the difference between the mean area under variable “costal” and “septal” treatments, respectively, varies from 0.006 cm² to 0.111 cm². Figure 6 represents an example of the results using both septal and cartilage modified graft.

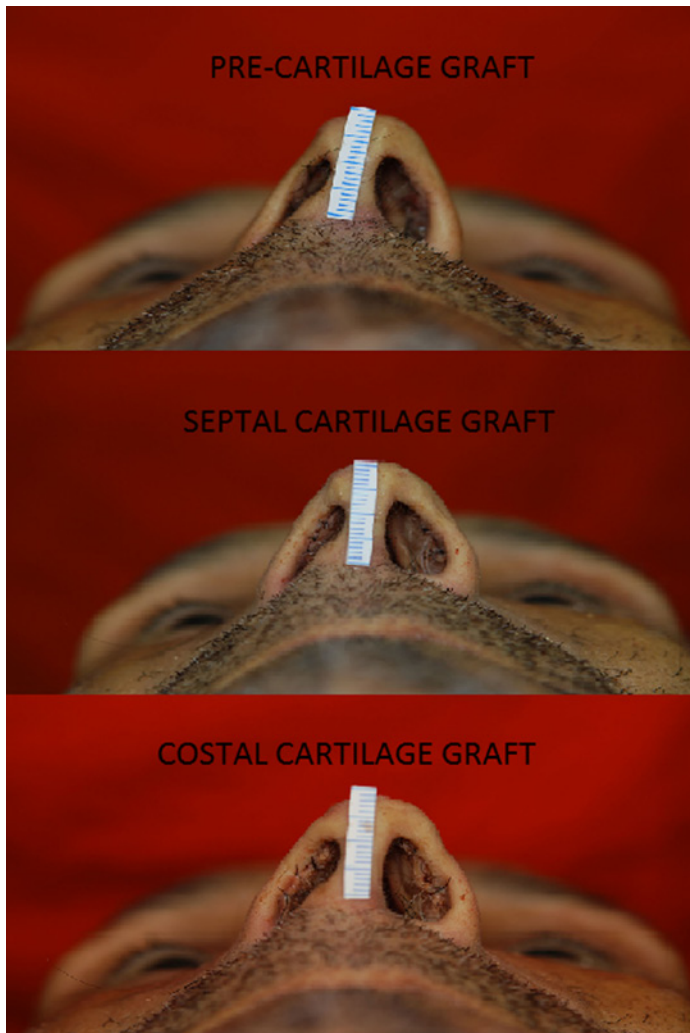


FIGURE 6 - Pictures of the nostrils before the insertion of grafts (“pre”) and after the inclusion of “septal”/“costal” grafts.

Discussion

Collapse of the lateral wall of the nasal vestibule during inspiration is caused by negative pressure under the influence of Bernoulli forces.

Many surgical options have been proposed for correcting the ENV insufficiency and to enhance the NCSA. Among them, Constantian¹⁻³ plays a major role for the endonasal techniques. Using an open approach of rhinoplasty, Gunter *et al.*^{4,5} proposed a lateral crural strut graft measuring 3 to 4 mm wide and 18 to 25mm long, to support the lateral wall and the pyriform aperture lobe under lateral crura. Also, Toriumi^{6,7} proposed a similar type

of graft, as described by Gunter *et al.*^{4,5}, differing mostly in its position, which could be located over the lateral crura except in cases where the nasal skin is extremely thin. In our study, we chose to insert the grafts above de lateral crura because some cadavers had a very friable nasal mucosa and during our pilot study a few dissections lead to mucosal perforation. Also our technique differed from others because we’ve beveled all the edges of grafts and carved the medial aspect of it in an oblique way. Therefore, our modification made it easier to insert the grafts into such a tight pocket (the pocket was only 1 mm bigger than the graft in all dimensions).

There are also different approaches with respect to the graft donor site; Gunter, Toriumi^{6,7} and Constantian¹⁻³ use septum and costal cartilage in different ways. Gunter *et al.*^{4,5} and Toriumi^{6,7} use the fifth and sixth rib to hide the scar beneath the breast crease; Constantian³ prefers the ninth rib because it is more rectilinear. Another difference pertains to the process by which the costal cartilage graft is carved: Gunter *et al.*⁵ makes multiple grafts in the rectilinear axis of the rib and perpendicular to the plane of the same rib cage; Toriumi⁷ does the same, but cuts parallel to the plane above. Constantian³ indicates the greater importance of the central rib in patients over 40 years; due to increased calcification in this region and therefore are less likely to buckle the graft obtained at the recipient area.

One of the problems during rhinoplasty for those who prefer a structural approach may be the small amount of usable cartilage available. During septoplasty, the surgeon can face an inadequate amount and quality of graft; e.g., sometimes there is more ethmoid and vomer than septal cartilage, which makes it more difficult to carve an appropriate graft. Auricular cartilage can be an option, but its curvature may not give the structural support that an incompetent ENV needs.

Therefore, rib cartilage grafting has become a good option, not only for those who don’t have enough/adequate septum but also because ear cartilage may not have the structural force that one may need. In this study, we’ve standardized the procedure using the 5th rib (right side), but there is no medical evidence that this is the better rib to use. It seems mostly a matter of individual choice as to which rib is going to be selected as the donor site. Although inner core calcification of the rib may lead to a more breakable graft, it is known that it helps to avoid bending or warping of the cartilage³⁻⁷.

Consideration of the various advantages and disadvantages involved in the use of either septal or rib cartilage leads to the question of which is the best donor site to increase NCSA and/or treat an incompetent ENV. In this study, we were able to prove

with statistically relevant outcomes that costal cartilage is better than septal cartilage to increase NCSA. We cannot extend this conclusion to say that it also treats ENV collapse/incompetence. Our study used fresh cadaver that allowed only a static evaluation of the NCSA; in order to extend these findings to a dynamic level, we recommend further studies using rhinomanometry and other functional tests with patients and long-term follow-up.

It is noteworthy that in this study the bias that may have arisen due to the photographs and the measurements of nostrils' areas were minimized. The photographs were taken in a standardized way in order to assess the nostril base located perpendicular to the sagittal plane. Measurement of the nostrils areas ("pre", "septal" and "costal") were made by a single expert in Autocad®. Although these two possible biases have been minimized, the random error term of the statistical model took into account any bias that may yet have occurred, without prejudging the statistical conclusions.

Although our statistical analysis proved the benefit of this modified technique for both septal and costal cartilage grafting, the following considerations must be kept in mind:

-The thicker the nostril skin, the less it can be pushed out by the grafts. Even though, costal cartilage is more effective than the septal cartilage graft to push out the lateral aspect of the nostrils.

-The thinner the nostril and vestibular skin, the more the graft may become palpable and visible. This may not decrease the NCSA but may compromise the flow of air as it passes through the internal and external nasal valve. To avoid this, we suggest that the caudal aspect of the graft should be beveled and trimmed along its inferior margin.

-Nostril shape and symmetry were not taken into account, since we evaluated right and left nostril independently. Therefore, this study does not recommend the use of these grafts on all patients, as they may not lead to the best lobular size/nostril ratio.

-We do not recommend performing this approach on patients who already have a good nostril size, e.g. some African American patients. This will increase its size and there is no need to do so. The surgeon will need to operate accordingly, to achieve an ethnically appropriate outcome taking into account the patient's desire.

-In patients with very thin nasal tip skin, the graft could become visible and palpable next to the domus area. This was not the focus of our study and we recommend further surgical refinement for those who plan to use this graft (e.g., making the graft smaller and/or beveling the upper medial aspect of the cartilage graft and/or covering the tip area with perichondrium/

fascia^{6,7}).

This study proved statistically that costal cartilage is better than septal cartilage to increase NCSA. This does not mean that we recommend using costal cartilage with every patient that may need NCSA enhancement. We believe it should be considered depending of the degree of ENV collapse, skin thickness and in the absence of sufficient septal cartilage for grafts. The rib cage usually supplies sufficient length as donor site for most grafts that a surgeon may use during rhinoplasty²¹⁻³⁰.

During rib dissection, we have observed that the ribs in older cadavers had more calcification at their core than in the younger. It is known that rib cartilage calcification can overcome perichondrial and internal forces that may avoid further distortion of the graft²².

It should be noted that the width of the septal graft is usually not greater than 1-2mm. Therefore, if a thicker graft is needed for any reason, it is recommended that the surgeon use 2-3 slices of septal cartilage, or carve the desired width using the rib as donor site.

Conclusions

The technique presented is applicable to increase nostril cross section area in cadavers. This modified technique revealed to enhance more nostril cross section area with costal cartilage graft over lateral crura rather than by septal graft.

References

1. Constantian MB. Functional effects of alar cartilage malposition. *Ann Plast Surg.* 1993; 30:487-91.
2. Constantian MB. The boxy nasal tip, the ball tip, and alar cartilage malposition: variations on a theme- a study of 200 consecutive primary and secondary rhinoplasty patients. *Plast Reconstr Surg.* 2005;116:268-74.
3. Constantian MB. The incompetent external nasal valve: pathophysiology and treatment in primary and secondary rhinoplasty. *Plast Reconstr Surg.* 1994;93:919-24.
4. Gunter JP, Friedman RM. Lateral crural strut graft: technique and clinical applications in rhinoplasty. *Plast Reconstr Surg.* 1997;99:943-51.
5. Gunter JP, Landecker A, Cochran CS. Frequently used grafts in rhinoplasty: nomenclature and analysis. *Plast Reconstr Surg.* 2006;118:14-23.
6. Toriumi DM. New concepts in nasal tip contouring. *Arch Facial Plast Surg.* 2006; 8:156-185.
7. Toriumi DM. Structure approach in rhinoplasty. *Facial Plast Surg Clin North Am.* 2005;13:93-113.
8. Shaida AM, Kenyon GS. The nasal valves: changes in anatomy and physiology in normal subjects. *Rhinology.* 2000;38(1):7-12.
9. Mink PJ. Le nez comme voie respiratoire. *Presse Otolaryngol Belg.* 1903;5:481-96.

10. Bridger GP. Physiology of the nasal valve. *Ach Otolaryngol.* 1970;92:543-53.
11. Cottle MH. The role of the rhinologist in rhinoplasty. *Laryngoscope.* 1953;63(7):608-18.
12. Goode RL. Surgery of the incompetent nasal valve. *Laryngoscope.* 1985;95:546-55.
13. Fomon S, Gilbert JG, Caron AL. Collapsed ala: Pathological physiology and management. *Arch Otolaryngol.* 1950;51:465-84.
14. Baguley T. Calculating and graphing within-subject confidence intervals for ANOVA. *Behav Res Methods.* 2012;44(1):158-75.
15. Du P, Jiang Y, Wang Y. Smoothing spline ANOVA frailty model for recurrent event data. *Biometrics.* 2011;67(4):1330-9.
16. Bondell HD, Reich BJ. Simultaneous factor selection and collapsing levels in ANOVA. *Biometrics.* 2009;65(1):169-77.
17. McHugh ML. Multiple comparison analysis testing in ANOVA. *Bioch Med.* 2011;21(3):203-9.
18. Ciminera JL, Heysse JF, Nguyen HH, Tukey JW. Evaluation of multicentre clinical trial data using adaptations of the Mosteller-Tukey procedure. *Stat Med.* 1993;12(11):1047-61.
19. Gelman A, Price PN, Lin CY. A method for quantifying artefacts in mapping methods illustrated by application to headbanging. *Stat Med.* 2000;19(17-18):2309-20.
20. Chuang-Stein C, Tong DM. Multiple comparisons procedures for comparing several treatments with a control based on binary data. *Stat Med.* 1995;14(23):2509-22.
21. Camirand A, Doucet J, Harris J. Nose surgery: how to prevent a middle vault collapse--a review of 50 patients 3 to 21 years after surgery. *Plast Reconstr Surg.* 2004;114(2):527-34.
22. Horton CE, Matthews MS. Nasal reconstruction with autologous rib cartilage: a 43-year follow-up. *Plast Reconstr Surg.* 1992;89(1):131-5.
23. Ghidini A, Dallari S, Marchioni D. Surgery of the nasal columella in external valve collapse. *Arch Otol Rhinol Laryngol.* 2002;11:701-3.
24. Fanous N. Columelloplasty for the wide obstructing columella. *Laryngoscope.* 1990;100:203-5.
25. Stone A. The incompetent external nasal valve. *Plast Reconstr Surg.* 1995;95(5):931-2.
26. Rohrich RJ, Raniere J Jr, Ha RY. The alar contour graft: correction and prevention of alar rim deformities in rhinoplasty. *Plast Reconstr Surg.* 2002;109(7):2495-505.
27. Daniel RK. Rhinoplasty: Large nostril/small tip disproportion. *Plast Reconstr Surg.* 2001;107:1874-82.
28. Ellenbogen R, Blome DW. Alar rim raising. *Plast Reconstr Surg.* 1992;90:28-36.
29. Guyuron B, Ghavami A, Wishneck SM. Components of the short nostril. *Plast Reconstr Surg.* 2005;116(5):1517-24.
30. Sen C, Iscen D. Use of the spring graft for prevention of midvault complications in rhinoplasty. *Plast Reconstr Surg.* 2007;119(1):332-6.

Acknowledgment

To thank Denise Aparecida Botter from the Mathematics and Statistics Institute, USP, for the statistical analysis.

Correspondence:

Marcelo Wulkan
Alameda Joaquim Eugênio de Lima, 1674/casa 2
01403-002 São Paulo – SP Brasil
Tel.: (55 11)3885-4511
mawulkan@yahoo.com

Received: May 14, 2012

Review: July 16, 2012

Accepted: August 15, 2012

Conflict of interest: none

Financial source: none

¹Research performed at Division of Postmortem Inspection of Sao Paulo, Surgery Department, School of Medicine, Sao Paulo University (USP), Brazil. Part of PhD thesis, Postgraduate Program in Medicine (Surgical Clinic). Tutor: Prof. Nivaldo Alonso.