



Universidade de São Paulo

Biblioteca Digital da Produção Intelectual - BDPI

Departamento de Biologia Celular e do Desenvolvimento -
ICB/BMC

Artigos e Materiais de Revistas Científicas - ICB/BMC

2012

MicroRNAs miR-146-5p and let-7f as prognostic tools for aggressive papillary thyroid carcinoma: a case report

ARQUIVOS BRASILEIROS DE ENDOCRINOLOGIA E METABOLOGIA, SÃO PAULO, v. 56, n. 8,
pp. 552-557, NOV, 2012
<http://www.producao.usp.br/handle/BDPI/36762>

Downloaded from: Biblioteca Digital da Produção Intelectual - BDPI, Universidade de São Paulo

MicroRNAs *miR-146-5p* and *let-7f* as prognostic tools for aggressive papillary thyroid carcinoma: a case report

MicroRNAs miR-146-5p e let-7f como ferramenta de prognóstico para o carcinoma papilífero de tireoide: relato de caso

Murilo Vieira Geraldo^{1*}, Cesar Seigi Fuziwara^{1*}, Celso Ubirajara Moretto Friguglieti², Ricardo Borges Costa³, Marco Aurélio Vamondes Kulcsar², Alex Shimura Yamashita¹, Edna Teruko Kimura¹

SUMMARY

Papillary thyroid cancer (PTC) is the most incident histotype of thyroid cancer. A certain fraction of PTC cases (5%) are irresponsive to conventional treatment, and refractory to radioiodine therapy. The current prognostic factors for aggressiveness are mainly based on tumor size, the presence of lymph node metastasis, extrathyroidal invasion and, more recently, the presence of the *BRAF*^{T799A} mutation. MicroRNAs (miRNAs) have been described as promising molecular markers for cancer as their deregulation is observed in a wide range of tumors. Recent studies indicate that the over-expression of *miR-146b-5p* is associated with aggressiveness and *BRAF*^{T799A} mutation. Furthermore, down-regulation of *let-7f* is observed in several types of tumors, including PTC. In this study, we evaluated the *miR-146b-5p* and *let-7f* status in a young male patient with aggressive, *BRAF*^{T799A}-positive papillary thyroid carcinoma, with extensive lymph node metastases and short-time recurrence. The analysis of *miR-146b-5p* and *let-7f* expression revealed a distinct pattern from a cohort of PTC patients, suggesting caution in evaluating miRNA expression data as molecular markers of PTC diagnosis and prognosis. Arq Bras Endocrinol Metab. 2012;56(8):552-7

SUMÁRIO

O carcinoma papilífero (PTC) é o histotipo mais prevalente de câncer de tireoide. Cerca de 5% dos casos são refratários ao tratamento convencional e à radioiodoterapia. Os fatores prognósticos para agressividade mais utilizados atualmente são o tamanho do tumor, a presença de metástases linfonodais ao diagnóstico, a presença de invasão extratiroideana e, mais recentemente, a presença da mutação *BRAF*^{T799A}. A análise de perfil de expressão de microRNAs (miRNA) mostra que esses pequenos RNAs são marcadores moleculares promissores para o câncer, por apresentarem desregulação de sua expressão em uma ampla gama de tumores, incluindo o PTC. Estudos recentes revelam a associação entre o aumento da expressão do miRNA e *miR-146b-5p* e a presença da mutação *BRAF*^{T799A} como um fator de pior prognóstico no PTC. Além disso, observa-se a diminuição da expressão de *let-7f* em diversos tipos de tumores, incluindo tumores tiroideanos. Neste relato de caso, realizamos a quantificação da expressão de *miR-146b-5p* e *let-7f* em um paciente jovem, de sexo masculino, apresentando PTC positivo para a mutação *BRAF*^{T799A} com extensas metástases linfonodais ao diagnóstico e recidiva precoce. A análise da expressão de *miR-146b-5p* e *let-7f* mostrou um padrão diferente do observado em um grupo de pacientes PTC, sugerindo a necessidade de cautela na interpretação da expressão de miRNAs como marcador molecular no diagnóstico e prognóstico de PTC. Arq Bras Endocrinol Metab. 2012;56(8):552-7

¹ Department of Cell and Developmental Biology, Institute of Biomedical Sciences, University of Sao Paulo, Sao Paulo, SP, Brazil
² Santa Catarina Hospital, Sao Paulo, SP, Brazil
³ Ferdinando Costa Laboratory, Sao Paulo, SP, Brazil
*These authors contributed equally to this work.

Correspondence to:
Edna Teruko Kimura
Av. Prof. Lineu Prestes, 1524, sala 414
Instituto de Ciências Biomédicas,
Universidade de São Paulo
05508-900 – São Paulo, SP, Brazil
etkimura@usp.br

Received on Aug/14/2012
Accepted on Oct/4/2012

INTRODUCTION

Papillary thyroid cancer (PTC) is the most incident histotype of thyroid cancer, accounting for more than 80% of the 35,000 annual cases in the USA. To date, prediction of PTC outcome is mainly based on tumor size, gender, age of patient at time of diagnosis, presence lymph node metastasis, capsular invasion, and extra-thyroidal extension. Although most PTCs cases display overall good prognosis, a certain fraction of PTC cases (5%) are irresponsive to conventional treatment and refractory to radioiodine therapy (1). Thus, a number of cases diagnosed as low-risk PTCs eventually recur locally and as lymph node metastases, leading to death (2), indicating the lack of current reliable outcome predictors. Indeed, no consensus has been achieved regarding the clinical application of molecular markers to predict the outcome of PTC patients (3).

More recently, several studies suggest that the presence of mutation in *BRAF* oncogene is associated with a poor outcome due to frequent extra-thyroidal invasion, recurrence, and lower survival rate (4-6). In this context, microRNAs (miRNAs) arise as interesting markers for cancer, as their deregulation affects innumerable cell processes, such as proliferation and apoptosis (7). MiRNAs negatively regulate protein levels by binding to 3'UTR of target mRNA and impairing protein translation (8). The potential of miRNAs as PTC molecular markers is highlighted, once their expression may be detected from formalin-fixed paraffin-embedded (FFPE) tissue, fine needle aspiration cytology (FNAC), as well as serum samples (9).

Recent studies have explored the use of several miRNAs as cancer diagnostic tools (10). In the last 4 years, several studies have demonstrated the potential of miRNAs in PTC diagnosis. Although *miR-146b-5p* is down-regulated in other types of cancer (11-13), this miRNA is highly overexpressed in PTCs (14,15), reliably distinguishing this type of cancer from follicular carcinoma (FTC), and from benign lesions (16,17). Moreover, Schwertheim and cols. have shown that a set of miRNAs that includes *miR-146b-5p*, distinguishes well-differentiated from undifferentiated thyroid tumors (18). Recent studies suggested that miRNA expression may be used as a thyroid cancer prognostic tool. The expression levels of *miR-146b-5p*, along with other two miRNAs, *miR-221* and *-222*, were significantly higher in high-risk PTC patients who showed extra-thyroidal invasion (19). Moreover, among

BRAF^{T1799A}-positive PTCs, the aggressive subset presents high *miR-146b-5p* expression levels (20). *Let-7f* down-regulation was firstly described by Takamizawa and cols. (21) in lung cancer with poor prognosis, and rapidly arose as a promising cancer molecular marker (22). Although *let-7f* down-regulation has been described in PTC, its usefulness as a diagnostic and prognostic marker for PTC is uncertain.

In this study, we present a case report of a young male patient presenting an aggressive, *BRAF^{T1799A}*-positive papillary thyroid carcinoma, displaying lymph node metastases at diagnosis and short-term recurrence after surgery, in whom we evaluated the expression pattern of the miRNAs *miR-146b-5p* and *let-7f*.

SUBJECT AND METHODS

Case report

A 23-year-old caucasian male (named here ABC) with parents bearing Hashimoto's thyroiditis, was submitted to a health checkup, and was diagnosed with hypothyroidism, positive for anti-TPO and anti-TG antibodies. At the ultrasound examination, calcified thyroid nodules of 12 mm and 8 mm were found at the isthmus and right lobe, respectively. The patient ABC also had lymphadenopathy of 33 mm, with calcification at level III of right side, and 9 mm at level III of left side. Fine needle aspiration cytology (FNAC) pattern was compatible with PTC in the thyroid and in the right lateral lymph nodes, but not in the left side. The patient underwent total thyroidectomy, and central compartment and right lateral lymph node dissection (levels II to V). Histopathological examination of the primary tumor confirmed the diagnosis of PTC (Figure 1A) with lymphatic invasion. Metastases were found in right lymph nodes at levels III (2 out of 7), IV (6 out of 6) (Figure 1B), V (2 out of 3), and at the central compartment (3 out of 4). Neither vascular nor peri-neural invasion were detected. According to the American Joint Committee on Cancer Staging System, the tumor was classified as T3N1bM0 and MACIS score was 3.37 (23,24).

Three months after surgery, the patient received 200 mCi of ¹³¹I under Thyrogen® (Genzyme, Cambridge, MA, USA) stimulation (TSH 140 µIU/mL). Thyroglobulin and anti-Tg antibodies levels were 0.15 ng/mL and > 3,000 IU/mL, respectively. Eight months later, ultrasound examination showed lymphadenopathy at levels II, III and IV of the left side, the

largest one with 19 mm, and elevated anti-Tg antibody levels (11,580 IU/m). FNAC revealed PTC and PET-CT examination showed FDG uptake at level II. At the second surgery, lateral lymph node dissection was performed on the left side (levels II to V). Histopathological examination of lymph nodes revealed metastases at levels II (2 out of 4), III (3 out of 17), IV (2 out of 8) and V (9 out of 11). The patient received 200 mCi of ^{131}I under Thyrogen[®] stimulation. Three months after the second surgery, radioiodine uptake was negative.

Patient population

Human PTC and non-tumor paired thyroid tissue samples were collected from patients, including ABC, after the informed consent was signed. This samples belong to the thyroid tumor tissue bank, approved by the ethical committee of the Institute of Biomedical Sciences (no. 1030/CEP), Universidade de Sao Paulo. Thyroid carcinomas were classified according to the last WHO classification (25).

BRAF mutation detection

Genomic DNA was extracted from thyroid tissue using the salting-out protocol. Briefly, after digestion with proteinase K, protein was precipitated with 5 M NaCl, and DNA was isolated with isopropanol. Exon 15 of BRAF, containing the hotspot T1799A mutation, was amplified by PCR using specific primers (FW: 5'-AAACTCTTCATAATGCTTGCTCTG-3'; RV: 5'-GGCCAAAATTTAATCAGTGGA-3'), and the product was purified in QIAquick[®] PCR purification

kit (Qiagen, Valencia, CA, USA). For direct sequencing reaction, the purified product was amplified using BigDye[®] Terminator v3.1 Cycle Sequencing Kit (Life Technologies), forward primer, and injected in multicapillary sequencer MegaBace1000 (GE Healthcare, Little Chalfont, UK) (26). The similarity of the resulting sequence was analyzed and confirmed using BLAST software (<http://www.ncbi.nlm.nih.gov/BLAST/>).

MicroRNA expression

Excised tumor tissues were immediately stored in RNAlater[®]. Total RNA was extracted by phenol-chloroform using TRIzol[®] reagent (Life Technologies, Carlsbad, CA, USA), according to the manufacturer's instructions, and stored at -80°C. Detection of miRNAs *miR-146b-5p*, *let-7f* and *RNU6B* was performed using commercial kits (Life Technologies) according to the manufacturer's specifications. Briefly, cDNA was synthesized from 10 ng of total RNA using specific primers in a stem-loop based technology with TaqMan MicroRNA Reverse Transcription Kit (Life Technologies). Expression was analyzed by qPCR using specific Taqman miRNA Assay (Life Technologies) and TaqMan[®] Master Mix no AmpErase[®] UNG (Life Technologies).

Statistical analysis

Quantification of miRNA expression is presented as mean \pm S.E., and data were submitted to Student's t-test to compare results between the two groups. Differences were considered significant at $p < 0.05$.

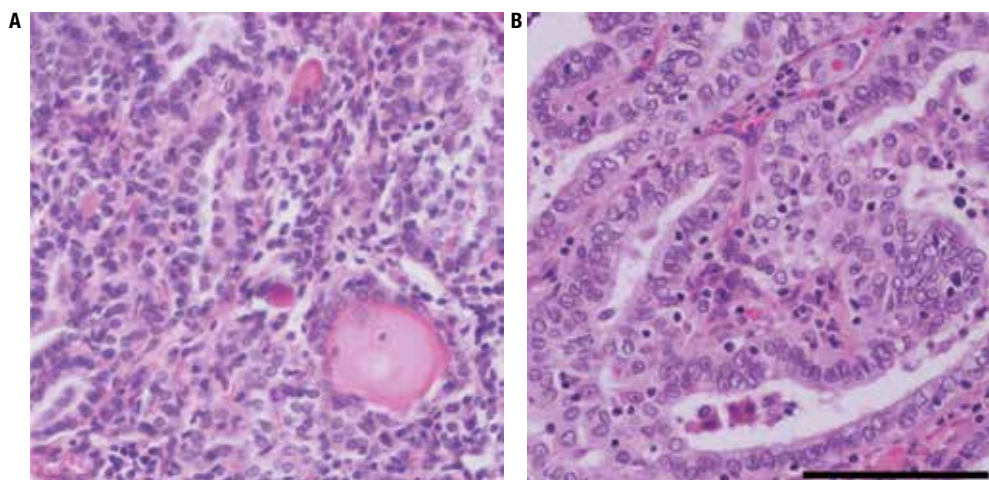


Figure 1. Histopathological slides of the resected differentiated PTC and lymph node metastasis. (A) Primary PTC. (B) Level IV lymph node metastasis. Hematoxylin-eosin, the black bar represents 100 µm.

RESULTS

Analysis of genomic DNA from a set of PTC samples and paired contra-lateral thyroid tissue revealed *BRAF*^{T1799A} mutation in 41% of patients, including the patient ABC (7/17).

MiR-146b-5p is substantially up-regulated in the cohort of PTCs from our tissue bank when compared with their matched contra-lateral samples, irrespective of their *BRAF*^{T1799A} status (Figure 2A). Interestingly, both the primary tumor and metastatic tissue of ABC exhibited lower *miR-146b-5p* fold-change levels compared with the cohort of PTC samples (Figure 2A), and no statistical differences compared with its paired normal thyroid tissue ($P = 0.773$).

On the other hand, the *BRAF*^{T1799A} tumors showed no significant changes in *let-7f* expression levels, while *BRAF*-wild type tumors exhibit increased *let-7f* levels in comparison with matched contra-lateral thyroid tissue (Figure 2B). ABC primary tumor, which was *BRAF*^{T1799A}-positive, exhibited a slight increase in *let-7f* levels (31%, $P < 0.01$) (Figure 2B). However, the metastatic tissues, also positive for *BRAF*^{T1799A}-, displayed decreased *let-7f* levels (Fig 3B).

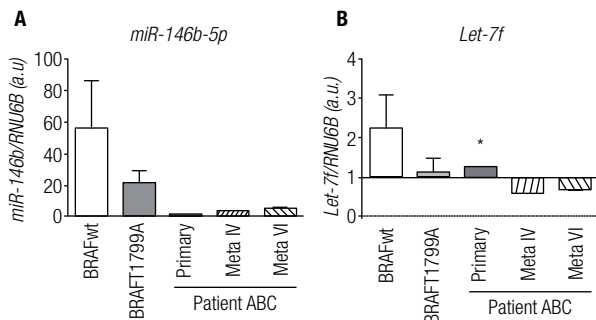


Figure 2. *MiR-146b* and *let-7f* levels in PTC samples. Expression of *miR-146b-5p* (A) and *let-7f* (B) in PTC samples in comparison with contra-lateral thyroid tissue. Values are represented as mean \pm SE of expression fold-change matched to contra-lateral thyroid tissue. *RNU6B* gene expression was used as an internal control. ABC, patient ABC; Meta IV, lymph node metastasis at level IV; Meta VI, lymph node metastasis at level VI. (*) $P < 0.01$, against matched thyroid contra-lateral tissue.

DISCUSSION

MiRNAs have been described as markers for diagnosis and prognosis, once their expression pattern may classify tumor types and aggressiveness accurately (10). Recent studies showed that molecular screening of miRNA expression in thyroid tumors is important

in distinguishing malignant from benign tumors, and that different thyroid cancer histotypes display distinct miRNA expression (17,27). However, in patient ABC, the expression pattern of *miR-146b-5p* and *let-7f* levels could not be associated with aggressiveness and poor prognosis, as previously described in the literature.

It is not clear whether the overexpression of *miR-146b-5p* is associated to *BRAF*^{T1799A} status. While initial studies showed no correlation between this miRNA and oncogenic activation (9), recent studies have demonstrated a positive correlation between the overexpression of *miR-146b-5p* and aggressive *BRAF*^{T1799A} tumors (19). Moreover, in the literature, high expression of *miR-146b-5p* is associated with *BRAF*-mutated tumors that display more aggressive phenotypes (20). Conversely, our cohort of patients did not show any correlation regarding *BRAF* status and *miR-146b-5p* expression. *MiR-146b-5p* is associated with the deregulation of NF κ B and TGF β pathways, while the blockage of *miR-146b-5p* action restores TGF β signal transduction in thyroid cells *in vitro* (28). Non-thyroid tumors frequently exhibit reduced levels of *miR-146b-5p* (11,29). We have previously shown that activation of MAPkinase pathway in normal thyroid cells increases *miR-146b-5p* levels *in vitro* (28). Therefore, the overexpression of *miR-146b-5p*, only observed in thyroid tumors, could be related with a thyroid-specific oncogenic activation, which might include the MAPK pathway.

The association between *BRAF*^{T1799A} and *let-7f* expression also remains poorly understood. Classically, the main target of *let-7* is RAS oncogene, an important transducer for the MAPK pathway. Interestingly, a functional study revealed that the reinforced expression of *let-7f* in a PTC cell line blocks ERK phosphorylation without affecting RAS protein levels (30). On the other hand, we have previously shown that activation of RET/PTC rearrangement in rat normal thyroid cell line, but not of *BRAF* mutation, decreases *let-7f* levels. In our cohort of patients, *BRAF*^{T1799A}-positive tumors showed no change in *let-7f* levels, in comparison with contra-lateral thyroid tissue, while *BRAF* wild type tumors displayed increased levels of this miRNA. Interestingly, the patient ABC, which was *BRAF*^{T1799A}-positive, showed slightly increased *let-7f* expression, even though his metastatic tissue, also *BRAF*^{T1799A}-positive, showed decreased levels of *let-7f*. Little is known about the targets regulated by *let-7f* in PTC. Different mRNA targets might be regulated by *let-7f* to promote matrix remodeling, vascular infiltration, and the colonization

of the metastatic site. Functional studies are needed to elucidate whether the loss of *let-7f* by primary tumor is implicated in thyroid tumor progression and what is the clinical significance of this data.

To date, clinical and histological features, such as age, gender, extra-thyroidal invasion, and, vascular invasion, histotype, and more recently, *BRAF*^{T1799A} status, are still the indicated parameters for accurate PTC outcome prediction. Furthermore, recent lines of evidence have shown that the number of lymph node metastases is also important to predict the patient's outcome, and may be used as an independent prognostic factor for aggressiveness (31), which corroborate the clinical characteristics of patient ABC.

This case showed to be interesting because of the discordance of two widely studied PTC miRNA markers in this index patient and our cohort of patients. Our data indicate that the expression pattern of *miR-146b-5p* and *let-7f* genes may not reproduce the clinical features of the tumor, clearly illustrating that outcome prediction based on the analysis of the expression of a single or few miRNA genes should be viewed with caution.

Acknowledgments: the authors would like to thank Dr. Kelly Cristina Saito for her technical assistance, and Fundação de Amparo à Pesquisa do Estado de São Paulo (Fapesp), Conselho Nacional de Desenvolvimento Científico e Tecnológico (CNPq), and Coordenação de Aperfeiçoamento de Pessoal de Nível Superior (Capes) for the financial support.

Disclosure: no potential conflict of interest relevant to this article was reported.

REFERENCES

- Mazzaferri EL, Jhiang SM. Long-term impact of initial surgical and medical therapy on papillary and follicular thyroid cancer. *Am J Med.* 1994;97(5):418-28.
- Mazzaferri EL, Kloos RT. Clinical review 128: current approaches to primary therapy for papillary and follicular thyroid cancer. *J Clin Endocrinol Metab.* 2001;86(4):1447-63.
- Cooper DS, Doherty GM, Haugen BR, Hauger BR, Kloos RT, Lee SL, et al. Revised American Thyroid Association management guidelines for patients with thyroid nodules and differentiated thyroid cancer. *Thyroid.* 2009;19(11):1167-214.
- Nikiforova MN, Kimura ET, Gandhi M, Biddinger PW, Knauf JA, Basolo F, et al. BRAF mutations in thyroid tumors are restricted to papillary carcinomas and anaplastic or poorly differentiated carcinomas arising from papillary carcinomas. *J Clin Endocrinol Metab.* 2003;88(11):5399-404.
- Xing M. BRAF mutation in papillary thyroid cancer: pathogenic role, molecular bases, and clinical implications. *Endocr Rev.* 2007;28(7):742-62.
- Lupi C, Giannini R, Ugolini C, Proietti A, Berti P, Minuto M, et al. Association of BRAF V600E mutation with poor clinicopathological outcomes in 500 consecutive cases of papillary thyroid carcinoma. *J Clin Endocrinol Metab.* 2007;92(11):4085-90.
- Esquela-Kerscher A, Slack FJ. Oncomirs – microRNAs with a role in cancer. *Nat Rev Cancer.* 2006;6(4):259-69.
- Bartel DP. MicroRNAs: genomics, biogenesis, mechanism, and function. *Cell.* 2004;23;116(2):281-97.
- Nikiforova MN, Tseng GC, Steward D, Diorio D, Nikiforov YE. MicroRNA expression profiling of thyroid tumors: biological significance and diagnostic utility. *J Clin Endocrinol Metab.* 2008;93(5):1600-8.
- Lu J, Getz G, Miska EA, Alvarez-Saavedra E, Lamb J, Peck D, et al. MicroRNA expression profiles classify human cancers. *Nature.* 2005;435(7043):834-8.
- Bhaumik D, Scott GK, Schokrpur S, Patil CK, Campisi J, Benz CC. Expression of microRNA-146 suppresses NF-kappaB activity with reduction of metastatic potential in breast cancer cells. *Oncogene.* 2008;27(42):5643-7.
- Kanaan Z, Rai SN, Eichenberger MR, Barnes C, Dworkin AM, Weller C, et al. Differential microRNA expression tracks neoplastic progression in inflammatory bowel disease-associated colorectal cancer. *Hum Mutat.* 2012;33(3):551-60.
- Man YG, Fu SW, Liu AJ, Stojadinovic A, Izzadjoo MJ, Chen L, et al. Aberrant expression of chromogranin A, miR-146a, and miR-146b-5p in prostate structures with focally disrupted basal cell layers: an early sign of invasion and hormone-refractory cancer? *Cancer Genomics Proteomics.* 2011;8(5):235-44.
- He H, Jazdzewski K, Li W, Liyanarachchi S, Nagy R, Volinia S, et al. The role of microRNA genes in papillary thyroid carcinoma. *Proc Natl Acad Sci U S A.* 2005;102(52):19075-80.
- Pallante P, Visone R, Ferracin M, Ferraro A, Berlingieri MT, Troncone G, et al. MicroRNA deregulation in human thyroid papillary carcinomas. *Endocr Relat Cancer.* 2006;13(2):497-508.
- Chen YT, Kitabayashi N, Zhou XK, Fahey TJ, 3rd, Scognamiglio T. MicroRNA analysis as a potential diagnostic tool for papillary thyroid carcinoma. *Mod Pathol.* 2008;21(9):1139-46.
- Sheu SY, Grabelius F, Schwertheim S, Worm K, Broecker-Preuss M, Schmid KW. Differential miRNA expression profiles in variants of papillary thyroid carcinoma and encapsulated follicular thyroid tumours. *Br J Cancer.* 2010;102(2):376-82.
- Schwertheim S, Sheu SY, Worm K, Grabelius F, Schmid KW. Analysis of deregulated miRNAs is helpful to distinguish poorly differentiated thyroid carcinoma from papillary thyroid carcinoma. *Horm Metab Res.* 2009;41(6):475-81.
- Chou CK, Chen RF, Chou FF, Chang HW, Chen YJ, Lee YF, et al. miR-146b is highly expressed in adult papillary thyroid carcinomas with high risk features including extrathyroidal invasion and the BRAF(V600E) mutation. *Thyroid.* 2010;20(5):489-94.
- Yip L, Kelly L, Shuai Y, Armstrong MJ, Nikiforov YE, Carty SE, et al. MicroRNA signature distinguishes the degree of aggressiveness of papillary thyroid carcinoma. *Ann Surg Oncol.* 2011;18(7):2035-41.
- Takamizawa J, Konishi H, Yanagisawa K, Tomida S, Osada H, Endoh H, et al. Reduced expression of the let-7 microRNAs in human lung cancers in association with shortened postoperative survival. *Cancer Res.* 2004;64(11):3753-6.
- Fuziwarra CS, Geraldo MV, Kimura ET. Let-7 and Cancer. MicroRNA let-7: role in human diseases and drug discovery. *DNA and RNA: Properties and Modifications, Functions and Interactions, Recombination and Applications Genetics – Research and Issues: Nova Science Publishers;* 2012. p. 109-24.
- Edge SB, Compton CC. The American Joint Committee on Cancer: the 7th edition of the AJCC cancer staging manual and the future of TNM. *Ann Surg Oncol.* 2010;17(6):1471-4.
- Hay ID, Bergstralh EJ, Goellner JR, Ebersold JR, Grant CS. Predicting outcome in papillary thyroid carcinoma: development of a reliable prognostic scoring system in a cohort of 1779 patients surgically treated at one institution during 1940 through 1989. *Surgery.* 1993;114(6):1050-7; discussion 7-8.

25. DeLellis RA, Lloyd RV, Heitz PU, Eng C. Pathology and Genetics of Tumours of Endocrine Organs. Lyon: IARC Press; 2004.
26. Kimura ET, Nikiforova MN, Zhu Z, Knauf JA, Nikiforov YE, Fagin JA. High prevalence of BRAF mutations in thyroid cancer: genetic evidence for constitutive activation of the RET/PTC-RAS-BRAF signaling pathway in papillary thyroid carcinoma. *Cancer Res.* 2003;1;63(7):1454-7.
27. Shen R, Liyanarachchi S, Li W, Wakely PE Jr, Saji M, Huang J, et al. MicroRNA signature in thyroid fine needle aspiration cytology applied to "atypia of undetermined significance" cases. *Thyroid.* 2012;22(1):9-16.
28. Geraldo MV, Yamashita AS, Kimura ET. MicroRNA miR-146b-5p regulates signal transduction of TGF-beta by repressing SMAD4 in thyroid cancer. *Oncogene.* 2012;12;31(15):1910-22.
29. Xia H, Qi Y, Ng SS, Chen X, Li D, Chen S, et al. microRNA-146b inhibits glioma cell migration and invasion by targeting MMPs. *Brain Res.* 2009;7;1269:158-65.
30. Ricarte-Filho JC, Fuziwara CS, Yamashita AS, Rezende E, da-Silva MJ, Kimura ET. Effects of let-7 microRNA on Cell Growth and Differentiation of Papillary Thyroid Cancer. *Transl Oncol.* 2009;2(4):236-41.
31. Ricarte-Filho J, Ganly I, Rivera M, Katabi N, Fu W, Shaha A, et al. Papillary thyroid carcinomas with cervical lymph node metastases can be stratified into clinically relevant prognostic categories using oncogenic BRAF, the number of nodal metastases, and extra-nodal extension. *Thyroid.* 2012;22(6):575-84.