



Universidade de São Paulo

Biblioteca Digital da Produção Intelectual - BDPI

Departamento de Genética e Biologia Evolutiva - IB/BIO

Artigos e Materiais de Revistas Científicas - IB/BIO


2013-08-02

Variable expressivity of osteogenesis imperfecta in a Brazilian family due to p.G1079S mutation in the COL1A1 gene

GENETICS AND MOLECULAR RESEARCH, RIBEIRAO PRETO, v. 11, n. 3, supl. 1, Part 3, pp. 3246-3255, 42156, 2012

<http://www.producao.usp.br/handle/BDPI/36148>

Downloaded from: Biblioteca Digital da Produção Intelectual - BDPI, Universidade de São Paulo



Variable expressivity of osteogenesis imperfecta in a Brazilian family due to p.G1079S mutation in the *COL1A1* gene

M.V.D. Moraes^{1,2}, M. Milanez¹, B.V.P. Almada¹, V. Sipolatti³,
M.R.G.O. Rebouças³, V.R.R. Nunes³, A.N. Akel Jr.³, M. Zatz⁴,
F.I.V. Errera^{2,5}, I.D. Louro^{1,2} and F. Paula^{1,2}

¹Núcleo de Genética Humana e Molecular,
Departamento de Ciências Biológicas, Centro de Ciências Humanas e Naturais,
Universidade Federal do Espírito Santo, Vitória, ES, Brasil

²Programa de Pós-Graduação em Biotecnologia, Centro de Ciências da Saúde,
Universidade Federal do Espírito Santo, Vitória, ES, Brasil

³Hospital Infantil Nossa Senhora da Glória, Vitória, ES, Brasil

⁴Centro de Estudos do Genoma Humano, Instituto de Biociências,
Universidade de São Paulo, São Paulo, SP, Brasil

⁵Escola Superior de Ciências da Santa Casa de Misericórdia de Vitória,
Faculdade de Ciências da Saúde, Vitória, ES, Brasil

Corresponding author: F. Paula

E-mail: flapvit@yahoo.com.br

Genet. Mol. Res. 11 (3): 3246-3255 (2012)

Received October 31, 2011

Accepted June 2, 2012

Published September 12, 2012

DOI <http://dx.doi.org/10.4238/2012.September.12.7>

ABSTRACT. Osteogenesis imperfecta (OI) is a Mendelian disease with genetic heterogeneity characterized by bone fragility, recurrent fractures, blue sclerae, and short stature, caused mostly by mutations in *COL1A1* or *COL1A2* genes, which encode the pro- α 1(I) and pro- α 2(I) chains of type I collagen, respectively. A Brazilian family that showed variable expression of autosomal dominant OI was identified and characterized. Scanning for mutations was carried out using SSCP and DNA sequence analysis. The missense mutation c.3235G>A was identified within exon 45 of the *COL1A1* gene in a 16-year-old girl diagnosed as having OI

type I; it resulted in substitution of a glycine residue (G) by a serine (S) at codon 1079 (p.G1079S). The proband's mother had the disease signs, but without bone fractures, as did five of nine uncles and aunts of the patient. All of them carried the mutation, which was excluded in four healthy brothers of the patient's mother. This is the first description in a Brazilian family with OI showing variable expression; only one among seven carriers for the c.3235G>A mutation developed bone fractures, the most striking clinical feature of this disease. This finding has a significant implication for prenatal diagnosis in OI disease.

Key words: *COL1A1* gene mutations; c.3235G>A; Genetic counseling; Intrafamilial variability; Osteogenesis imperfecta

INTRODUCTION

Osteogenesis imperfecta (OI) is a Mendelian disorder of connective tissue characterized by fragile bones and increased susceptibility to fracture. The traditional classification of Sillence et al. (1979), based on clinical and radiographic findings that include types I (MIM# 166200), II (MIM# 166210), III (MIM# 259420), and IV (MIM# 166220), has been expanded (Glorieux et al., 2000, 2002; Ward et al., 2002; Morello et al., 2006; Cabral et al., 2007; Van Dijk et al., 2009; Alanay et al., 2010; Forlino et al., 2011). The clinical phenotype ranges in severity from perinatal lethal, with multiple intrauterine fractures, to mild disease, with relatively few fractures and normal mobility (Chang et al., 2010).

Because collagen is the major matrix protein of all connective tissues (skin, ligament, cartilage, bone, and tendon), defects in type I procollagen synthesis or structure are responsible for the majority of clinical OI outcomes. Most OI cases are due to mutations in type I collagen genes, *COL1A1* and *COL1A2*, encoding the pro- α 1(I) and pro- α 2(I) chains, respectively. Nevertheless, it has been reported that mutations in prolyl 3-hydroxylation complex [*CRTAP* (MIM# 605497), *LEPRE1* (MIM# 610339), and *PPIB* (MIM# 123841)] and non-collagen related genes [*FKBP10* (MIM# 607063), *PLOD2* (MIM# 601865), *SERPINF1* (MIM# 172860), *SERPINH1* (MIM# 600943), and *SP7* (MIM# 606633)] lead to defective bone development and collagen helix formation associated with a clinical spectrum of recessive OI (Forlino et al., 2011). Although a decreased amount of structurally normal type I collagen in particular is the cause of mild disease (OI type I), in patients heterozygous for a nonfunctional *COL1A1* allele, a structurally abnormal type I collagen protein can be seen in mild to lethal/severe and moderate phenotypes (Galicka et al., 2003).

The type I collagen triple helix consists of a supercoiled assembly of 3 extended polyproline II-like chains. The folding of the 3 chains restricts every third residue to being a Gly, generating a repeating (Gly-X-Y)_n sequence pattern (Fraser et al., 1979). The most frequent tripeptide unit (triplet) is Gly-Pro-Hyp, which constitutes 10% of all triplets and also contributes the maximum possible stability to the triple helix (Bhate et al., 2002). Missense mutations in either the pro- α 1(I) or pro- α 2(I) chain, which lead to the substitution of Gly in the ubiquitous Gly-X-Y with bulky amino acids such as Arg, Asp, Glu, Cys, Ser, Ala, or Val, result in reduced collagen secretion, disruptive folding of the triple helix, decreased thermal stability, and increased post-translational modification, depending on the substitution (Bateman et al., 1992; Gauba and Hartgerink, 2008).

OI type I is the mildest and least deforming disease condition within significant inter-

familial and intrafamilial heterogeneity, suggesting that factors other than pattern and site of collagen gene mutation can influence the clinical phenotype (Primorac et al., 2001). Whereas the diagnosis of OI is commonly based on fracture rate, family history, and typical clinical signs, the rarity of the condition and its large spectrum of phenotypes can lead to misdiagnosis in asymptomatic members of families with mild OI (Deodhar and Woolf, 2000; Primorac et al. 2001).

In this study, we identified the c.3235G>A (p.G1079S) mutation in the *COL1A1* gene in an OI familial case showing phenotypic variability: a 16-year-old girl diagnosed with OI type I with repeated fractures of both femora, and 6 related carriers who presented mild features of OI but had no bone fractures. This report highlights the importance of a molecular diagnosis in OI to allow for appropriate genetic counseling and disease prevention.

MATERIAL AND METHODS

All protocols were approved by Hospital Infantil Nossa Senhora da Glória (HINSG) Committee on Ethics of Research Involving Human Subjects (protocol 37/05; approval date October 3, 2006). Blood samples and clinical data were obtained with written informed consent from all participants. The study comprised an OI type I patient who was seen at HINSG, located in Vitória, State of Espírito Santo, Brazilian Southeastern, and 10 of her relatives. The diagnosis and classification of OI type I were established by a clinical geneticist according to the clinical presentation, which included family history, fracture rate, and clinical and radiographic findings (Sillence et al., 1979).

Genomic DNA was extracted from peripheral blood samples and stored at 4°C until processing. The exons and flanking regions from the *COL1A1* gene of the affected patient (Figure 1) were amplified using a polymerase chain reaction (PCR) technique with previously published primers (Körkkö et al., 1998). The PCR was carried out in a 20-µL reaction volume containing 40 ng genomic DNA, 0.20 mM Illustra™ dNTP set (GE Healthcare, UK), 1X PCR buffer (Invitrogen™, Brazil), 0.50 mM of each the forward and reverse primers (Invitrogen™), and 1 U Taq DNA Polymerase (Invitrogen™). The PCR conditions were an initial denaturation at 94°C for 10 min, followed by 95°C for 30 s, 55-76°C for 30 s (each fragment was amplified at a specific temperature), and 72°C for 30 s, up to 35 cycles, in a GeneAmp® 9700 or Veriti® thermal cycler (Applied Biosystems, USA).

The c.3235G>A mutation was localized within the exon 45 of the patient's *COL1A1* gene. To investigate the presence of the mutation in 10 relatives of the patient, PCR amplification was performed for the fragment of exon 45 and flanking sequences under optimal conditions using 5% dimethyl sulfoxide (Amresco Inc., USA) and 2.50 mM MgCl₂ (Invitrogen™). The PCR products were checked on a 7% acrylamide gel to verify the quality of the products. The search for mutations was performed with single-strand conformation polymorphism (SSCP) analysis using 5-7% acrylamide gels and commercial version MDE® Mutation Detection Enhancement Gel (Lonza Group Ltd., USA). The mobility pattern of DNA fragments on SSCP gels was analyzed after silver staining. Altered PCR products were processed and sequenced according to the manual provided by the manufacturer of the ABI PRISM® 3100 Genetic Analyzer (Applied Biosystems). To analyze the raw chromatogram sequencing data and the accuracy of the nucleotide composition of codons and exon/intron junctions, we aligned the sequence traces using GenBank sequences of the *COL1A1* gene (AF017178 for genomic and NM_000088.3 for complementary DNA) and compared them

to the Database of Collagen Mutations (Dalglish, 1998; <http://www.le.ac.uk/genetics/collagen> [accessed January 24, 2012]).

RESULTS

A 16-year-old Brazilian girl diagnosed with OI type I and having a history of 5 femoral fractures (2 on the right and 3 on the left) was studied to identify the genetic cause of her disease. The first and last fractures were reported at ages 7 and 16, respectively. At the time of the study, the patient weighed 51 kg and had a height of 154 cm. The radiograph of the spinal column showed compensatory scoliosis owing to a 1.2-cm shortening in the length of the right leg, although the patient walked normally and had no deformities of the long bones (absence of intramedullary rods). The hearing of the patient was normal, but blue sclerae and dental manifestations of OI were present. Bisphosphonate treatment had been initiated at the time of the first fracture and stopped when the patient was 16 years old. The most significant outcome related by the patient after the start of treatment was a decrease in bone pain and frequency of fracture. Bone mineral density (BMD) in the lumbar spine (LSBMD) and whole body (WBBMD) was evaluated. An increasing in LSBMD (from 0.446 g/cm² to 1.188 g/cm²) and WBBMD (from 0.67 to 1.061 g/cm²) was observed.

SSCP screening for mutations in the *COL1A1* gene of the patient (Figure 1) detected an aberrant migration pattern for exon 45 (Figure 2). The DNA sequencing for this abnormal fragment revealed a heterozygous p.G1079S mutation (Figure 3), which was also detected in 6 of the patient's relatives who presented short stature (average = 156.82 ± 16.55 cm), dental manifestations including teeth fragility, blue sclerae, and hearing loss (auditory device users) but no fractures (Table 1). The mutation and clinical aspects described were absent in 3 maternal uncles and the maternal grandmother of the patient. The maternal grandfather of the patient was deceased (not analyzed), but family members reported that he had short stature, blue sclera, and teeth abnormalities, which suggested that he showed signs of OI. Owing to ethical issues, 12 maternal cousins of the patient - 7 of their children from carrier individuals - were not analyzed (not represented in Figure 1). Their relatives reported that the cousins showed no signs of OI. Although the high miscegenation of Brazilian population, this family showed Caucasian features. The p.G1079S mutation was not observed in 100 unrelated normal controls selected from the community of the studied family.

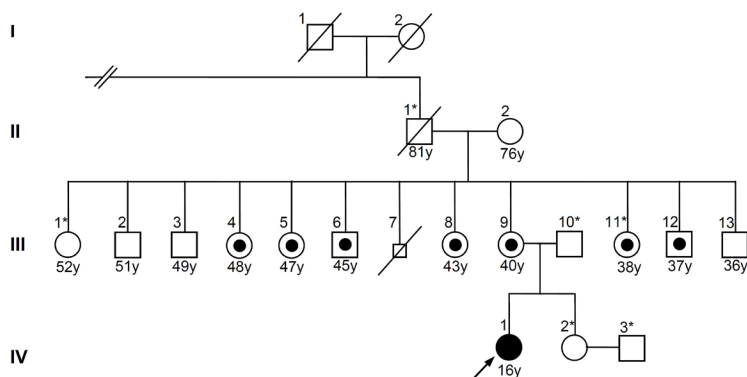


Figure 1. Heredogram of the family with the affected osteogenesis imperfecta patient (black), normal parents (white) and parents with blue sclerae, lower stature, fragile teeth, hearing loss, and no fractures (black circle in middle). Asterisks indicate that DNA sample is not available for our studies.

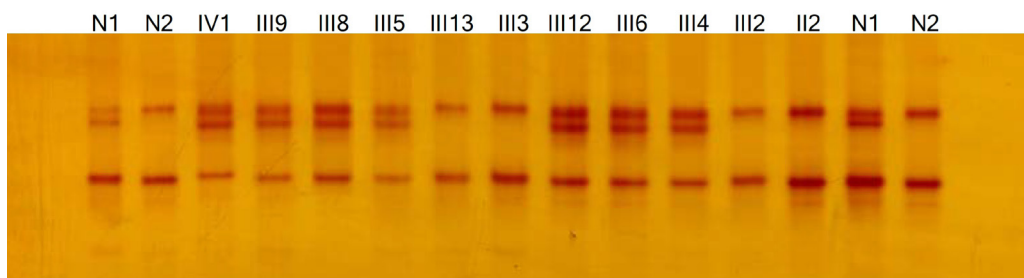


Figure 2. Screening for mutation by single-strand conformation polymorphism. The fragment comprising exon 45 of the *COL1A1* gene from the affected proband (IV-1) and some relatives revealed a subtle difference in the mobility when compared to controls (N1-N2).

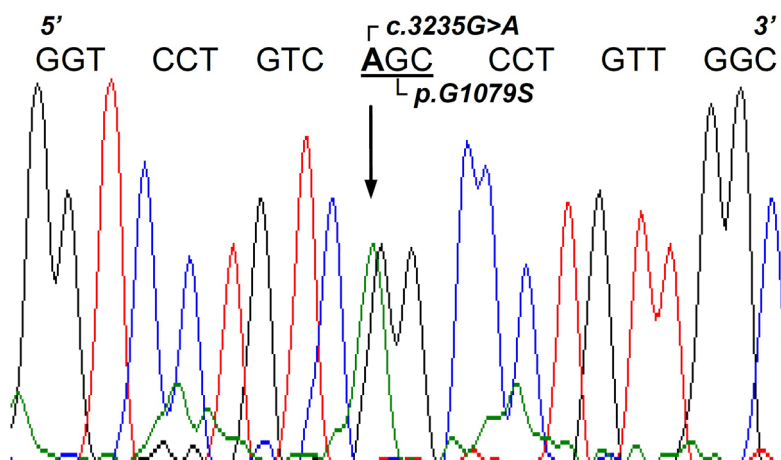


Figure 3. Schematic view of the $\alpha 1(I)$ c.3235G>A (p.G1079S) missense mutation. The arrow signals the mutation point at the electropherogram from the affected proband (IV-1). Normal sense cDNA strand surrounding the mutation site indicating a guanine for adenine in the triplet first nucleotide position (underlined).

Table 1. Clinical and genetic descriptions of family members.

Family members	Gly901Ser	Age (years)	Height (cm)	Blue sclerae	Dental manifestations	Hearing loss	Bone fractures
IV-1 ^a	+	16	155	+	+	-	5
II-2	-	76	170	-	-	-	-
III-2	-	51	174	-	-	-	-
III-3	-	49	173	-	-	-	-
III-4	-	48	124	+	+	+	-
III-5	+	47	145	+ light	+	+	-
III-6	+	45	160	+ light	+	+	-
III-8	+	43	144	+ light	+	+	-
III-9	+	40	144	+ light	+	+	-
III-12	+	37	158	+ light	+	+	-
III-13	-	36	178	-	-	-	-

^aAffected proband; (+) = presence; (-) = absence.

DISCUSSION

In this study, we identified the c.3235G>A (p.G1079S) mutation in the *COL1A1* gene of a 16-year-old Brazilian girl diagnosed with OI type I who presented repeated bone fractures and in 6 of her relatives showing abnormalities in stature, teeth, sclerae, and hearing but no bone fractures. These individuals characterize a differential intrafamilial phenotypic expression of OI.

Although many descriptions of the association of OI patients with an absence of bone fractures have been presented in the literature, this report is the first of a large Brazilian OI familial study (11 relatives) in which 6 individuals who carry a known *COL1A1* gene mutation have no bone fractures. Six of the 10 studied siblings had the c.3235G>A mutation, a rare genetic change recognized as a pathogenic variant in the etiology of OI, whereas the remaining 4 siblings were not carriers of the mutation. Moreover, one of them had a daughter carrier for the mutation who developed repeated bone fractures, which demonstrates the intrafamilial phenotypic variability of the disease.

The genetic change observed in 7 distinct individuals and absent in the remaining 4 of the 11 studied individuals - detected using SSCP analysis (a technique of screening for mutations) followed by sequencing of independent amplicons generated with PCR - suggests that this finding does not originate from a PCR/SSCP artifact band, which can confuse the interpretation of the results. The p.G1079S mutation is outlined as the cause of OI in patients. In the present study, this relationship is also supported by the absence of this genetic change in 100 unrelated normal controls selected from the community of the studied family and by the identification of carriers for this mutation who show signs or symptoms of the disease.

The first description of the p.G1079S mutation was reported in an OI type I Italian boy and his mother. The 8-year-old patient had repeated fractures of both femora, and his mother, 44 years old at the time of his birth, had never experienced bone fractures but showed short stature, mild hypoacusis, and moderate osteoporosis (Mottes et al., 1992). Other p.G1079S carriers have been reported in a Japanese family with juvenile-onset hyperuricemia cosegregated with OI. In this family, 2 affected brothers had more than 10 fractures before the age of 13 years, and one of them also developed hearing loss and hip joint deformities owing to repeated femoral fractures. Their father and brother, also carriers for the same mutation, had no fractures but showed blue sclerae, dentinogenesis imperfecta, and joint laxity (Kaneko et al., 2011). Other p.G1079S carriers have developed OI type I in familial cases; however, little information about the other family members is available in these cases (Hartikka et al., 2004; Roschger et al., 2008; Zhang et al., 2012). The majority of reported cases of the p.G1079S mutation describe mild forms of the disease (OI type I); however, a few reports of patients with OI type IV, a moderate form of the disease, have been published (Dalglish, 1998; Marini et al., 2007).

Although only a small number of mild OI familial descriptions appear in the literature, an analysis of those cases and of that reported in the current study generally suggests that mutations may become more severe in subsequent generations: the parent of a carrier may show abnormalities in sclerae, teeth, and stature without experiencing bone fractures, whereas the next generation of carriers may develop bone fractures, mainly in the femora. However, we cannot discard that this deduction could be an ascertainment bias because individuals with recurrent fractures require medical care, and those in whom this symptom is absent may not be identified because they do not request medical assistance and, thus, remain undiagnosed as OI patients. The difference in the severity of the disease can also reflect the effect of treatments, for example, bisphosphonate

therapy can reduce the frequency of bone fractures and improve the symptoms of OI.

The occurrence of somatic mosaicism has been proposed to explain the interfamilial and intrafamilial variability in the number of fractures and degree of disability in OI (Cohen-Solal et al., 1996). However, the inheritance pattern observed in our familial study suggests an autosomal dominant form instead of somatic mosaicism, because we observed at least 2 generations and perhaps a third, with individuals showing signs and symptoms of OI (the patient, her mother, and possibly her maternal grandfather).

Some molecular evidence suggests that the p.G1079S mutation causes OI, although some carriers do not display bone fractures. This genetic variation results in a glycine (GGC) to serine (AGC) missense change in codon 901 of the *COL1A1* gene. The most common qualitative mutations in OI are single-nucleotide changes that result in the substitution of Gly residues within the Gly-X-Y repeats of the triple helix of the $\alpha 1(I)$ and $\alpha 2(I)$ chains (Dalglish, 1998). Nearly 100 Gly residue substitutions in the triple-helical domain of the *COL1A1* gene are due to Ser substitutions. Substitutions of a single Gly by the same residue in different individuals frequently have different clinical outcomes. A wide spectrum of phenotypes with Ser for Gly substitutions can occur, with outcomes ranging from lethal to nonlethal (Dalglish, 1998).

The c.3235G>A mutation (p.G1079S) is located in a cluster that was previously linked with nonlethal phenotypes and is surrounded by 2 lethal clusters (Namikawa et al., 1995; Witecka et al., 2008). Missense mutations in either the pro- $\alpha 1(I)$ or pro- $\alpha 2(I)$ chains lead to local interference with the folding of the triple helix through the substitution of Gly in the ubiquitous Gly-X-Y repeat with bulky amino acids (side chains are larger than that of Gly) such as Arg, Asp, Glu, Cys, Ser, Ala, or Val. The disruption in folding in turn causes decreased thermal and helical stability, helix propagation delay, increased levels of lysine post-translational modification, and reduced secretion owing to collagen degradation, which causes poor bone mineralization and, consequently, the phenotypic expression of the disease (Bateman et al., 1992; Cabral et al., 2003). The degree of disruption based on the amino acid replacement of Gly can be represented as $\text{Ala} \leq \text{Ser} < \text{Cys} < \text{Arg} < \text{Val} < \text{Glu} \leq \text{Asp}$ (Beck et al., 2000; Buevich et al., 2004). The relative clinical severity for various residues replacing Gly shows that the more destabilizing Asp, Val, and Arg residues lead to more severe phenotypes than the less disruptive Ser, Cys, and Ala residues (Beck et al., 2000).

A 50% loss of triple helix content and a decrease in thermal stability with effects on the folding rate of residues involved in nucleation near the p.G1079S (Ser-901) substitution site have been reported (Baum and Brodsky, 1997). Ser-901 might result in a slower folding of the protein and extend the time that hydroxylases have to modify lysyl residues in both chains of the triple helix (Witecka et al., 2008). Once the triple helix conformation is propagated - in a zipper-like mechanism from the C- to N-terminus at a rate limited by cis-trans isomerization of amino acid bonds - local sequences N-terminal to the mutation site can also influence the propensity for renucleation if the Gly substitution has interrupted the C- to N-terminal propagation of the triple helix. The C- to N-terminal propagation stops at the mutation site with the triple helix structured only C-terminal to the mutation site, and independent nucleation events N-terminal to the mutation site may be facilitated at Hyp-rich sequences farther downstream in the collagen sequence for full-length collagen formation (Buevich et al., 2004).

It has been proposed that Gly substitutions toward the C-terminus of the $\alpha 1(I)$ chains result in more clinically severe disease than those toward the N-terminus. Because helix formation propagates from the C- to the N-terminus, mutations toward the C-terminus are more

disruptive to helix formation. The best evidence to support this hypothesis comes from the $\alpha 1(I)$ Gly to Cys mutations that disrupt the close packing of the 3 chains and triggers events that lead to defective mineralization of bones (Bateman et al., 1992). Additional evidence shows that the effects of type I collagen on thermal unfolding are position-specific such that local sequences flanking the Gly substitution and their consequences for collagen structure reflect the model of regional effects along the collagen molecule (Westerhausen et al., 1990).

OI type I is the mildest and least deforming condition of the disease within significant interfamilial and intrafamilial heterogeneity. The diagnosis of OI is commonly based on fracture rate, family history, and typical clinical signs, but the rarity of the condition combined with the subtle signs of mild OI owing to large phenotypic variability can lead to missed and misdiagnosed cases in asymptomatic members of a family with mild OI (Deodhar and Woolf, 2000; Primorac et al., 2001). The present study finds more evidence that p.G1079S mutation is associated with mild OI characterized by short stature, blue sclerae, hypoacusis, dentinogenesis imperfecta, and bone fragility, among other features. However, bone fracture is not a remarkable symptom likely owing to some maintenance of bone integrity. Thus, a bone densitometry evaluation is needed to determine whether a real impairment of bone structure is present. The intrafamilial variable expressivity due to p.G1079S in the C-terminal region of the collagen triple helix might be explained by a possibly less destructive effect of the mutation on collagen fibril performance in some individuals.

In conclusion, strong evidence supports p.G1079S as the cause of OI symptoms. The observed phenotypic variability can be explained by environmental factors, such as pharmacological treatment (bisphosphonates) that improve the symptoms of the disease, by differences in the genetic background of patients that can influence bone metabolism and tissue, or perhaps by the presence of an unknown locus that can modulate the phenotype. The phenotypic expression in OI depends not only on the nature and position of the mutation but also on a combination of multifactorial patterns that determine variability. This study shows that the clinical and genetics aspects of OI must be analyzed with caution. The variability in clinical expression can make the determination of an accurate prognosis difficult in affected patients, but it must be considered for genetic counseling to prevent new OI cases.

ACKNOWLEDGMENTS

We are grateful to Hospital Infantil Nossa Senhora da Glória for clinical support and the Brazilian institutions ArcelorMittal Tubarão, Fundação de Apoio ao Hospital Universitário Cassiano Antônio Moraes, Conselho Nacional de Desenvolvimento Científico e Tecnológico, Fundo de Apoio à Ciência e Tecnologia de Vitória, and Fundação de Amparo à Pesquisa do Espírito Santo for financial support. We also thank Clara Barbirato, Márcio Germello, Geise Quirino, and Thaísa Oliveira for laboratory help.

Conflict of interest

The authors declare no conflicts of interest.

REFERENCES

Alanay Y, Avaygan H, Camacho N, Utine GE, et al. (2010). Mutations in the gene encoding the RER protein FKBP65

- cause autosomal-recessive osteogenesis imperfecta. *Am. J. Hum. Genet.* 86: 551-559.
- Bateman JF, Moeller I, Hannagan M, Chan D, et al. (1992). Characterization of three osteogenesis imperfecta collagen $\alpha 1(I)$ glycine to serine mutations demonstrating a position-dependent gradient of phenotypic severity. *Biochem. J.* 288: 131-135.
- Baum J and Brodsky B (1997). Real-time NMR investigations of triple-helix folding and collagen folding diseases. *Fold. Des.* 2: R53-R60.
- Beck K, Chan VC, Shenoy N, Kirkpatrick A, et al. (2000). Destabilization of osteogenesis imperfecta collagen-like model peptides correlates with the identity of the residue replacing glycine. *Proc. Natl. Acad. Sci. U. S. A.* 97: 4273-4278.
- Bhate M, Wang X, Baum J and Brodsky B (2002). Folding and conformational consequences of glycine to alanine replacements at different positions in a collagen model peptide. *Biochemistry* 41: 6539-6547.
- Buevich AV, Silva T, Brodsky B and Baum J (2004). Transformation of the mechanism of triple-helix peptide folding in the absence of a C-terminal nucleation domain and its implications for mutations in collagen disorders. *J. Biol. Chem.* 279: 46890-46895.
- Cabral WA, Merts MV, Makareeva E, Colige A, et al. (2003). Type I collagen triplet duplication mutation in lethal osteogenesis imperfecta shifts register of alpha chains throughout the helix and disrupts incorporation of mutant helices into fibrils and extracellular matrix. *J. Biol. Chem.* 278: 10006-10012.
- Cabral WA, Chang W, Barnes AM, Weis M, et al. (2007). Prolyl 3-hydroxylase 1 deficiency causes a recessive metabolic bone disorder resembling lethal/severe osteogenesis imperfecta. *Nat. Genet.* 39: 359-365.
- Chang W, Barnes AM, Cabral WA, Bodurtha JN, et al. (2010). Prolyl 3-hydroxylase 1 and CRTAP are mutually stabilizing in the endoplasmic reticulum collagen prolyl 3-hydroxylation complex. *Hum. Mol. Genet.* 19: 223-234.
- Cohen-Solal L, Zolezzi F, Pignatti PF and Mottes M (1996). Intrafamilial variable expressivity of osteogenesis imperfecta due to mosaicism for a lethal G382R substitution in the *COL1A1* gene. *Mol. Cell Probes* 10: 219-225.
- Dalgleish R (1998). The Human Collagen Mutation Database 1998. *Nucleic Acids Res.* 26: 253-255.
- Deodhar AA and Woolf AD (2000). Fragile without fractures. *Ann. Rheum. Dis.* 59: 166-171.
- Forlino A, Cabral WA, Barnes AM and Marini JC (2011). New perspectives on osteogenesis imperfecta. *Nat. Rev. Endocrinol.* 7: 540-557.
- Fraser RDB, MacRae TP and Suzuki E (1979). Chain conformation in the collagen molecule. *J. Mol. Biol.* 129: 463-481.
- Galicka A, Wolczynski S, Gindzienski A, Surazynski A, et al. (2003). Gly511 to Ser substitution in the *COL1A1* gene in osteogenesis imperfecta type III patient with increased turnover of collagen. *Mol. Cell Biochem.* 248: 49-56.
- Gauga V and Hartgerink JD (2008). Synthetic collagen heterotrimers: structural mimics of wild-type and mutant collagen type I. *J. Am. Chem. Soc.* 130: 7509-7515.
- Glorieux FH, Rauch F, Plotkin H, Ward L, et al. (2000). Type V osteogenesis imperfecta: a new form of brittle bone disease. *J. Bone Miner. Res.* 15: 1650-1658.
- Glorieux FH, Ward LM, Rauch F, Lalic L, et al. (2002). Osteogenesis imperfecta type VI: a form of brittle bone disease with a mineralization defect. *J. Bone Miner. Res.* 17: 30-38.
- Hartikka H, Kuurila K, Korkko J, Kaitila I, et al. (2004). Lack of correlation between the type of *COL1A1* or *COL1A2* mutation and hearing loss in osteogenesis imperfecta patients. *Hum. Mutat.* 24: 147-154.
- Kaneko H, Kitoh H, Matsuura T, Masuda A, et al. (2011). Hyperuricemia cosegregating with osteogenesis imperfecta is associated with a mutation in *GPATCH8*. *Hum. Genet.* 130: 671-683.
- Körkkö J, Ala-Kokko L, De PA, Nuytink L, et al. (1998). Analysis of the *COL1A1* and *COL1A2* genes by PCR amplification and scanning by conformation-sensitive gel electrophoresis identifies only *COL1A1* mutations in 15 patients with osteogenesis imperfecta type I: identification of common sequences of null-allele mutations. *Am. J. Hum. Genet.* 62: 98-110.
- Marini JC, Forlino A, Cabral WA, Barnes AM, et al. (2007). Consortium for osteogenesis imperfecta mutations in the helical domain of type I collagen: regions rich in lethal mutations align with collagen binding sites for integrins and proteoglycans. *Hum. Mutat.* 28: 209-221.
- Morello R, Bertin TK, Chen Y, Hicks J, et al. (2006). CRTAP is required for prolyl 3-hydroxylation and mutations cause recessive osteogenesis imperfecta. *Cell* 127: 291-304.
- Mottes M, Sangalli A, Valli M, Gomez LM, et al. (1992). Mild dominant osteogenesis imperfecta with intrafamilial variability: the cause is a serine for glycine $\alpha 1(I)$ 901 substitution in a type-I collagen gene. *Hum. Genet.* 89: 480-484.
- Namikawa C, Suzumori K, Fukushima Y, Sasaki M, et al. (1995). Recurrence of osteogenesis imperfecta because of paternal mosaicism: Gly862→Ser substitution in a type I collagen gene (*COL1A1*). *Hum. Genet.* 95: 666-670.
- Primorac D, Rowe DW, Mottes M, Barisic I, et al. (2001). Osteogenesis imperfecta at the beginning of bone and joint decade. *Croat Med. J.* 42: 393-415.
- Roschger P, Fratzl-Zelman N, Misof BM, Glorieux FH, et al. (2008). Evidence that abnormal high bone mineralization in growing children with osteogenesis imperfecta is not associated with specific collagen mutations. *Calcif. Tissue*

Int. 82: 263-270.

- Sillence DO, Senn A and Danks DM (1979). Genetic heterogeneity in osteogenesis imperfecta. *J. Med. Genet.* 16: 101-116.
- Van Dijk FS, Nesbitt IM, Zwikstra EH, Nikkels PG, et al. (2009). PPIB mutations cause severe osteogenesis imperfecta. *Am. J. Hum. Genet.* 85: 521-527.
- Ward LM, Rauch F, Travers R, Chabot G et al. (2002). Osteogenesis imperfecta type VII: an autosomal recessive form of brittle bone disease. *Bone* 31: 12-18.
- Westerhausen A, Kishi J and Prockop DJ (1990). Mutations that substitute serine for glycine alpha 1-598 and glycine alpha 1-631 in type I procollagen. The effects on thermal unfolding of the triple helix are position-specific and demonstrate that the protein unfolds through a series of cooperative blocks. *J. Biol. Chem.* 265: 13995-14000.
- Witecka J, Augusciak-Duma AM, Kruczek A, Szydło A, et al. (2008). Two novel *COL1A1* mutations in patients with osteogenesis imperfecta (OI) affect the stability of the collagen type I triple-helix. *J. Appl. Genet.* 49: 283-295.
- Zhang ZL, Zhang H, Ke YH, Yue H, et al. (2012). The identification of novel mutations in *COL1A1*, *COL1A2*, and *LEPRE1* genes in Chinese patients with osteogenesis imperfecta. *J. Bone Miner. Metab.* 30: 69-77.