



**Universidade de São Paulo**

**Biblioteca Digital da Produção Intelectual - BDPI**

---

Outros departamentos - FM/Outros

Artigos e Materiais de Revistas Científicas - FM/Outros

---

2012-12

# Into the Island: A new technique of non-invasive cortical stimulation of the insula

---

NEUROPHYSIOLOGIE CLINIQUE-CLINICAL NEUROPHYSIOLOGY, PARIS, v. 42, n. 6, pp. 363-368, DEC, 2012


<http://www.producao.usp.br/handle/BDPI/33499>

*Downloaded from: Biblioteca Digital da Produção Intelectual - BDPI, Universidade de São Paulo*



Disponible en ligne sur  
**SciVerse ScienceDirect**  
www.sciencedirect.com

Elsevier Masson France  
**EM|consulte**  
www.em-consulte.com/en



ORIGINAL ARTICLE/ARTICLE ORIGINAL

# Into the Island: A new technique of non-invasive cortical stimulation of the insula

*Une nouvelle technique de stimulation corticale non invasive de l'insula*

D. Ciampi de Andrade<sup>a,b,c,\*</sup>, R. Galhardoni<sup>a,c</sup>, L.F. Pinto<sup>a,c</sup>, R. Lancelotti<sup>c</sup>,  
J. Rosi Jr<sup>a</sup>, M.A. Marcolin<sup>c</sup>, M.J. Teixeira<sup>a,b,c</sup>

<sup>a</sup> Pain Center, Department of Neurology, School of Medicine, University of São Paulo, São Paulo, Brazil

<sup>b</sup> Pain Center, Instituto do Câncer do Estado de São Paulo, São Paulo, Brazil

<sup>c</sup> Transcranial Magnetic Stimulation Laboratories, Psychiatry Institute, University of São Paulo, São Paulo, Brazil

Received 22 March 2012; accepted 12 August 2012

Available online 3 September 2012

## KEYWORDS

Transcranial magnetic stimulation;  
Insula;  
Neuronavigation;  
Pain;  
Analgesia

## MOTS CLÉS

Stimulation magnétique transcrânienne ;

## Summary

*Study aim.* – We describe a new neuronavigation-guided technique to target the posterior-superior insula (PSI) using a cooled-double-cone coil for deep cortical stimulation.

*Introduction.* – Despite the analgesic effects brought about by repetitive transcranial magnetic stimulation (TMS) to the primary motor and prefrontal cortices, a significant proportion of patients remain symptomatic. This encouraged the search for new targets that may provide stronger pain relief. There is growing evidence that the posterior insula is implicated in the integration of painful stimuli in different pain syndromes and in homeostatic thermal integration.

*Methods.* – The primary motor cortex representation of the lower leg was used to calculate the motor threshold and thus, estimate the intensity of PSI stimulation.

*Results.* – Seven healthy volunteers were stimulated at 10 Hz to the right PSI and showed subjective changes in cold perception. The technique was safe and well tolerated.

*Conclusions.* – The right posterior-superior insula is worth being considered in future studies as a possible target for rTMS stimulation in chronic pain patients.

© 2012 Elsevier Masson SAS. All rights reserved.

## Résumé

*But de l'étude.* – Nous décrivons une nouvelle technique de stimulation non invasive de l'insula postéro-supérieure basée sur la SMTr profonde guidée par neuronavigation.

*Introduction.* – Même si la stimulation magnétique transcrânienne rapide (SMTr) des cortex moteur et préfrontal possède des effets antalgiques incontestables, elle s'avère inefficace dans une proportion significative de patients présentant des douleurs chroniques. Il existe par

\* Corresponding author.

E-mail address: [ciampi@usp.br](mailto:ciampi@usp.br) (D. Ciampi de Andrade).

Insula ;  
Stimulation  
magnétique  
transcrânienne  
profonde ;  
Neuronavigation ;  
Douleur ;  
Analgésie

ailleurs des arguments de plus en plus forts suggérant que l'insula postérieure n'est pas uniquement impliquée dans les processus d'intégration homéostatique thermique, mais également dans l'intégration de la perception de la douleur.

*Méthodes.* – La représentation corticale motrice de membres inférieurs a été utilisée pour estimer l'intensité de stimulation de l'insula.

*Résultats.* – Sept volontaires sains ont été stimulés à 10 Hz sur l'insula postérieure et ont montré des changements subjectifs de la perception du froid. La technique s'est avérée non dangereuse pour les paramètres choisis.

*Conclusions.* – Cette étude préliminaire suggère qu'une évaluation plus approfondie des effets de la SMT de l'insula postérieure pourrait apporter de nouvelles possibilités dans le traitement des douleurs chroniques.

© 2012 Elsevier Masson SAS. Tous droits réservés.

## Introduction

Despite the advent of new drugs and therapeutic regimens, a significant proportion of chronic pain patients remain symptomatic despite best pharmacological treatment [8]. Several lines of research have looked for new strategies to control refractory pain, among which non-invasive brain stimulation (NIBS) techniques [10]. Since seminal reports [11], primary motor cortex (M1) was the most frequently studied target in all rapid transcranial magnetic stimulation (rTMS) studies, more recently followed by the prefrontal cortex, and rarely, the primary sensory cortex (S1). Despite some encouraging results, in many instances, the effect of rTMS on pain reduction is not long-lasting enough to cause clinically significant pain relief and does not work in all pain syndromes as efficiently. There have been significant efforts to improve its efficacy. There is a growing body of evidence suggesting that other cortical areas are implicated in the integration of painful stimuli and display functional alterations in chronic pain patients. In particular, the role of the parietal insular cortex operculum (PICO) in the integration of somatosensory information has been suggested by experimental studies and more recently, by laser-evoked potentials [19], functional neuroimaging [4], and in neuropathic pain patients with cold allodynia [7,17].

The insula is one of the most frequently-activated regions across different functional neuroimaging studies in chronic pain conditions [17]. It is composed of three different cytoarchitectural areas based on the degree of granulation of cortical layers II and IV [3,15]. The agranular region is located more anterior and inferior in the insular cortex, followed posteriorly by the dysgranular cortex. The granular area is located in the more superior aspect of the posterior insula, where layers II and IV are filled with granular neurons, and all six layers can be well identified (allocortex). This area is anatomically and functionally similar to the parietal opercular cortex and it has been proposed that these regions compose a functional unit, the PICO [14]. The granular insula receives projections from the posterior complex and VPI thalamic areas. A specific nucleus of the spinothalamic tract going from lamina I in the spinal cord to the posterior part of the ventral medial nucleus of the thalamus (VMpo) that projects to the posterior insula in a somatotopically organized fashion, has been described [1,2]. The role of the PICO in the integration of somatosensory and

pain inputs has been suggested in a huge number of studies [5,9]. A recent study also showed that in this region the threshold to trigger painful stimulations is lower than in the more rostral regions [14].

Recent technical improvements in rTMS, in particular the development of cooled double-cone coils have opened the possibility to stimulate deeper cortical regions, such as the insula. One could hypothesize that high-frequency rTMS to the PICO might change altered central sensitization related to chronic neuropathic pain [6,12,13], thus leading to pain relief.

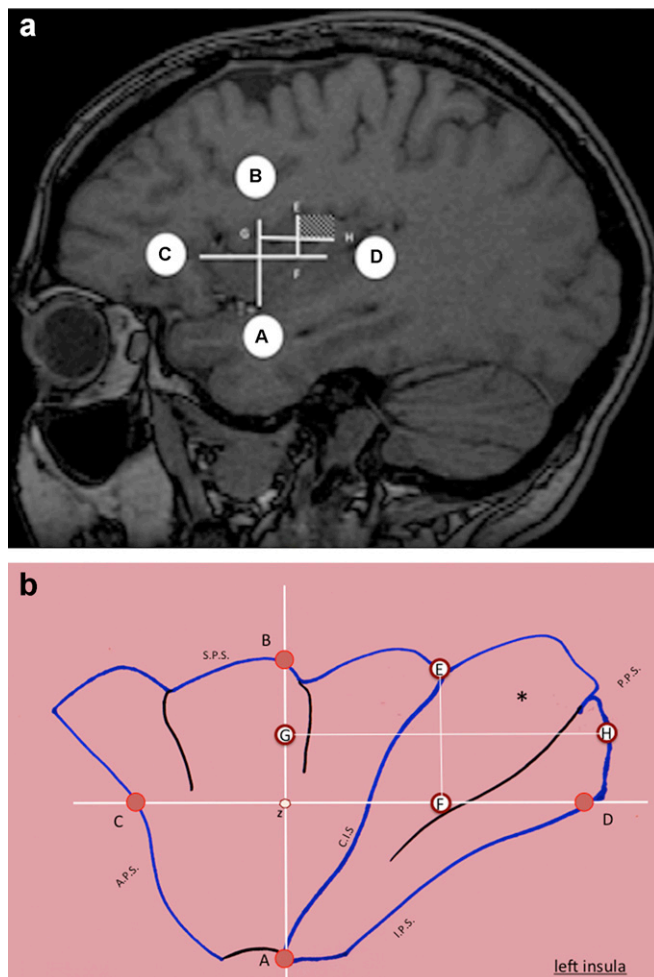
In this study we describe an original technique to stimulate the posterior insula using a double-cone coil under TMS-specific neuronavigation. We first examined how to choose the stimulation intensity and which insular region to target. Then we tested a high-frequency rTMS protocol in healthy volunteers in order to assess the safety of this technique.

## Methods

Seven healthy volunteers (three females,  $27.4 \pm 5.1$  years) were recruited. They gave written informed consent to participate in the protocol, which was approved by our local Ethics Review Board. Participants were healthy and were not taking any psychotropic medications. All participants received real rTMS to the right posterior superior insula and were rTMS-naïve.

### Determination of the insular target

A 3D-image of the head was obtained using volumetric T1-weighted magnetic resonance imaging (MRI) for frameless stereotaxic neuronavigation (Brainsight™, Rogue Research). The use of a neuronavigation system ensured accurate positioning of the coil and, most important, the correct identification of the posterior and superior aspect of the insula (PSI) in the PICO [8]. First, the insula was identified by "peeling" the MRI image until its cortex could be identified [14]. First, the limen of the insula was identified and named point A. A straight line parallel to the coronal plane was drawn and the point where this line reached the upper border of the insula (in the frontal operculum) was named point B. A second line (CD) perpendicular to line AB was drawn



**Figure 1** Identification of the posterior-superior insular region: the “quadrant-within-a-quadrant” method: a: the limen of the insula was identified and named point A. A straight line parallel to the coronal plane was drawn and the point where this line reached the upper border of the insula (in the frontal operculum) was named point B. A second line (CD) perpendicular to line AB was drawn passing by its midpoint and dividing it in two symmetric parts. Line CD ranged the anterior part of the insula (point C) to its posterior aspect (D), reaching its borders anteriorly and posteriorly, respectively. The PSI was then identified by drawing a second pair of symmetrical perpendicular lines (line GH and line EF) inside the upper-posterior quadrant from the AB/CD lines intersection. The putative target was located in the upper-posterior sub-quadrant formed by GH and EF lines; b: schematic representation of the left insula: the “quadrant-within-a-quadrant” method. Point A was located in the insular limen. The limen was identified as the characteristic gap in the peri-insular sulci: the insula is divided from the temporal, parietal and frontal opercula by the inferior-, superior-, anterior, and posterior peri-insular sulci. These sulci form a circular sulcus around the insula that is continuous, except for a small area called insula limen located between the inferior and anterior peri-insular sulci, respectively. Point B is located in the superior peri-insular sulcus (SPS). It is the point where a straight line parallel to the coronal plane reaches the SPS. Point z represents the midpoint of the AB line. Point G is located at the midpoint from the ZB line and point F is located at the midpoint from the ZD line. Points E and H are located in the superior

passing by its midpoint and dividing it in two symmetric parts. Line CD ranged the anterior part of the insula (point C) to its posterior aspect (D), reaching its borders anteriorly and posteriorly, respectively. The PSI was then identified by drawing a second pair of symmetrical perpendicular lines (line GH and line EF) inside the upper-posterior quadrant from the AB/CD lines intersection. The putative target was located in the upper-posterior sub-quadrant formed by GH and EF lines (Fig. 1a and b).

### Determination of stimulation parameters for deep-transcranial magnetic stimulation of the insula

A cooled DB-80 butterfly coil was used for all TMS and rTMS procedures (Magventure® Tonika-Elektronik, Farum, Denmark). This coil creates an induced electric current 4-5 cm underneath the center of the coil [20,21]. The lower-leg representation of the primary motor cortex lies deeply in the medial aspect of the hemispheres. For each volunteer, a blinded neuroradiologist measured the distances (mm) from the scalp to the lower part of M1 [16]. Then we compared these distances to the ones obtained from the scalp to the posterior part of the insula. These two targets had similar distances from the scalp (Table 1 and Fig. 2). We then calculated the rest motor threshold (RMT) of the *tibialis anterior* (TA) muscle as described elsewhere [18]. RMT was expressed as percentage of the maximum stimulator output (MSO).

### Posterior-superior insula-transcranial magnetic stimulation

Intensity of PSI stimulation was set at 80% of TA-RMT. Magnetic stimulation was applied with a MagPROX100 machine (Magventure® Tonika Elektronik, Farum, Denmark), using a butterfly double-cone D-B80 cooled coil oriented at a tangent to the scalp, with the main phase of the induced current in the anterior-to-posterior direction. The stimulation session consisted of 15 series of ten-second trains at 10Hz and inter-train-interval of 50seconds (total of 1500 pulses per session) [13].

### Assessment of sensory changes

Sensory changes were assessed on the left hand (contralateral to the cortical target) before and one hour after the stimulation using a quantitative sensory test protocol that measured cold and warm detection thresholds, and cold and heat pain thresholds as reported elsewhere [13]. Significance was set at  $P < 0.05$  for each test. The Kolmogorov-Smirnoff test was used to assess normality of the distribution and the Wilcoxon Signed Rank Test was used to compare data before against one hour after the stimulation when a normal distribution was not present.

### Safety outcomes

An experienced neurologist unaware of the experimental design observed volunteers for 5 hours after PSI-rTMS and performed a structured interview to assess safety. A

**Table 1** Thermal thresholds measured by quantitative sensory testing and distances from the scalp to targets.

Distances and thresholds	N	Minimum	Maximum	Mean	Std. Deviation	Related samples Wilcoxon's Signed Rank Test (P)
RMT_TA (%MSO)	7	39	83	54.43	16.092	
Distance between skull and insula (mm)	7	43.0	53.7	48.814	4.1755	0.240
Distance between skull and LL M1 (mm)	7	38.3	51.8	47.114	4.8057	
CDT_LUP_B (°C)	7	22.4	30.8	29.214	3.0394	0.396
CDT_LUP_A (°C)	7	26.0	30.7	28.871	1.8200	
WDT_LUP_B (°C)	7	32.9	39.3	34.871	2.1523	0.093
WDT_LUP_A (°C)	7	33.1	36.4	33.900	1.1460	
HPT_LUP_B (°C)	7	39.5	46.8	43.529	2.8582	0.396
HPT_LUP_A (°C)	7	39.8	48.2	44.029	3.1495	
CPT_LUP_B (°C)	7	9.7	25.2	17.957	5.4052	0.061
CPT_LUP_A (°C)	7	3.8	20.3	12.543	6.1321	

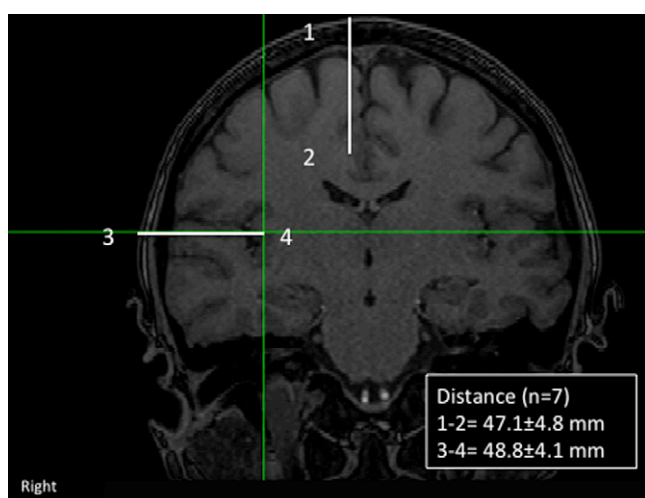
CDT: cold detection threshold; WDT: warm detection threshold; HPT: heat pain threshold; CPT: cold pain threshold; LUP: left upper limb; LL: lower limb; M1: primary motor cortex; B: baseline; A: after; RMT: rest motor threshold; TA: tibialis anterior muscle; MSO: maximal stimulator output.

second evaluation was performed 1 week after the rTMS session.

## Results

### Determination of the posterior-superior insula

In all instances, the “two-perpendicular-lines method” to identify the PSI sub-region was successfully performed. However, since the insula has a trapezoid shape that varies in size from one individual to another, the lengths of the AB, CD, EF and GH lines varied from one individual to another, but the proportions of the quadrants remained the same so



**Figure 2** Distances from the scalp to lower leg area in primary motor cortex (M1) and to the posterior insula. Illustrative image: mean  $\pm$  s.d. from participants. Distances from scalp to the distal part of M1, where the lower leg representation is located, is similar to the distance from the scalp and the posterior insula.

that the posterior-superior aspect of the insula (PSI) was systematically targeted.

### Determination of stimulation parameters for deep transcranial magnetic stimulation of the insula

Left TA-RMT was  $54 \pm 16\%$  of MSO and was determined in all participants.

### Posterior-superior insula stimulation


PSI-rTMS was performed in all participants. We had no reports of local discomfort besides the expected picking sensation during stimulation that occurs during any regular rTMS sessions. The coil orientation and patient position are illustrated in Fig. 3.

### Sensory changes

High-frequency stimulation to the right PSI did not affect thermal detection thresholds or heat pain thresholds when compared to baseline values. Cold pain threshold was decreased (towards analgesia) after 1 hour of stimulation. This change was not statistically significant although there was a trend towards it. QST results are expressed in Table 1.

### Safety outcomes

Participants had no major side effects during the direct observation period after PSI-rTMS. Four volunteers spontaneously reported “feeling cold” for a couple of hours after stimulation. Two of them spontaneously reported they felt as if they were “inside a freezer with no clothes on”. The room temperature was at  $25^\circ\text{C}$  during the whole experimental session. The reported “cold sensation” started right



**Figure 3** Experimental setting. The coil was held with the handle pointing backwards, which was more easily done with the volunteer laid down on lateral decubitus.

after the stimulation, built up for 30 minutes and slowly faded away after 2–3 hours after stimulation. No mood or behavioral changes were reported using these stimulation parameters during the following week. All volunteers worked normally during this period. No other changes were reported or identified during the one-week period after stimulation.

## Discussion

We report, for the first time, a non-invasive neuronavigation rTMS-based technique to target the PSI, using an innovative method to calculate the stimulation intensities based on lower-leg MEPs over M1 as a way to estimate the stimulation intensity for deep rTMS of the insula. High-frequency stimulation of the posterior insula showed to be safe and well tolerated despite the small number of volunteers assessed in this pilot study.

Some clinical effects seemed to exist concerning thermal integration, as four volunteers spontaneously reported intense cold sensation after the stimulation, which was short lasting. This finding has not been described after either real or sham high-frequency stimulation to M1, PFC, or the primary sensory cortex [5]. This may be related to changes in thermal homeostatic changes caused by the rTMS stimulation on the posterior insula [2].

The safety and feasibility of this technique argues for a potential to further evaluate this target and its possible benefit in clinical pain syndromes such as central post-stroke pain.

## Disclosure of interest

The authors declare that they have no conflicts of interest concerning this article.

## Acknowledgements

We would like to thank Mrs. Rita de Cassia Ortega Borges and Mrs. Sandra Falcon for the logistic help in this study.

## References

- [1] Blomqvist A, Zhang E, Craig A. Cytoarchitectonic and immunohistochemical characterization of a specific pain and temperature relay, the posterior portion of the ventral medial nucleus, in the human thalamus. *Brain* 2000;123: 601–9.
- [2] Bud Craig A. A new view of pain as a homeostatic emotion. *Trends Neurosci* 2003;26:303–7.
- [3] Burton H. Second somatosensory cortex and related areas. In: Jones EG, Peters A, editors. *Cerebral Cortex*. New York: Plenum; 1986. p. 31–98.
- [4] Burton H, Videen TO, Raichle ME. Tactile-vibration-activated foci in insular and parietal-opercular cortex studied with positron emission tomography: mapping the second somatosensory area in humans. *Somatos Mot Res* 1993;10: 297–308.
- [5] de Andrade DC, Mhalla A, Adam F, Texeira MJ, Bouhassira D. Neuropharmacological basis of rTMS-induced analgesia: the role of endogenous opioids. *Pain* 2011;152:320–6.
- [6] Desmeules JA, Cedraschi C, Rapiti E, Baumgartner E, Finckh A, Cohen P, et al. Neurophysiologic evidence for a central sensitization in patients with fibromyalgia. *Arthritis Rheum* 2003;48:1420–9.
- [7] Ducreux D. Mechanisms of central neuropathic pain: a combined psychophysical and fMRI study in syringomyelia. *Brain* 2006;129:963–76.
- [8] Gagné M, Héту S, Reilly KT, Mercier C. The map is not the territory: motor system reorganization in upper limb amputees. *Hum Brain Mapp* 2010;32:509–19.
- [9] Hansson PT, Attal N, Baron R, Cruccu G. Toward a definition of pharmacoresistant neuropathic pain. *Eur J Pain* 2009;13:439–40.
- [10] Lefaucheur JP, Antal A, Ahdab R, de Andrade D, Fregni F, Khedr E, et al. The use of repetitive transcranial magnetic stimulation (rTMS) and transcranial direct current stimulation (tDCS) to relieve pain. *Brain Stimul* 2008;1:337–44.
- [11] Lefaucheur JP, Drouot X, Keravel Y, Nguyen JP. Pain relief induced by repetitive transcranial. *NeuroReport* 2001;12: 2963–5.
- [12] Mhalla A, de Andrade DC, Baudic S, Perrot S, Bouhassira D. Alteration of cortical excitability in patients with fibromyalgia. *Pain* 2010;149:495–500.
- [13] Mhalla A, Baudic S, Ciampi de Andrade D, Gautron M, Perrot S, et al. Long-term maintenance of the analgesic effects of transcranial magnetic stimulation in fibromyalgia. *Pain* 2011;152:1478–85.
- [14] Mazzola L, Isnard J, Peyron R, Maugière F. Stimulation of the human cortex and the experience of pain: Wilder Penfield's observations revisited. *Brain* 2012;135: 631–40.
- [15] Mesulam MM, Mufson EJ. Insula of the old world monkey. III: efferent cortical output and comments on function. *J Comp Neurol* 1982;212:38–52.

- [16] Penfield W, Jasper HH. *Epilepsy and the functional anatomy of the human brain*. Boston: Little Brown; 1954.
- [17] Peyron R, Laurent B, Garcia-Larrea L. Functional imaging of brain responses to pain: a review and meta-analysis (2000). *Neurophysiol Clin* 2000;30:263–88.
- [18] Sidhu SK, Hoffman BW, Cresswell AG, Carroll TJ. Corticospinal contributions to lower limb muscle activity during cycling in humans. *J Neurophysiol* 2012;107:306–14.
- [19] Tarkka IM, Treede RD. Equivalent electrical source analysis of pain-related somatosensory evoked potentials elicited by a CO<sub>2</sub> laser. *J Clin Neurophysiol* 1993;10:513–9.
- [20] Taylor JL, Gandevia SC. Noninvasive stimulation of the human corticospinal tract. *J Appl Physiol* 2004;96:1496–503.
- [21] Terao Y, Ugawa Y. Basic mechanisms of TMS. *J Clin Neurophysiol* 2002;19:322–43.