



Universidade de São Paulo

Biblioteca Digital da Produção Intelectual - BDPI

Departamento de Neurologia - FM/MNE

Artigos e Materiais de Revistas Científicas - FM/MNE


2012

Endodermal cyst of the third cranial nerve

CLINICAL NEUROLOGY AND NEUROSURGERY, AMSTERDAM, v. 114, n. 7, supl. 1, Part 3, pp. 1088-1090, SEP, 2012

<http://www.producao.usp.br/handle/BDPI/32594>

Downloaded from: Biblioteca Digital da Produção Intelectual - BDPI, Universidade de São Paulo



Case report

Endodermal cyst of the third cranial nerve

Eberval G. Figueiredo^{a,*}, Hugo Sterman Neto^a, Paulo E. Marchiori^b, Sergio Rosemberg^c, Manoel J. Teixeira^a^a Division of Neurological Surgery, University of São Paulo, School of Medicine, Sao Paulo, Brazil^b Department of Neurology, University of São Paulo, School of Medicine, Sao Paulo, Brazil^c Department of Pathology, University of São Paulo, School of Medicine, Sao Paulo, Brazil

ARTICLE INFO

Article history:

Received 2 October 2010

Received in revised form 6 February 2012

Accepted 9 February 2012

Available online 6 March 2012

Keywords:

Endodermal cyst

Intracranial cyst

Magnetic resonance cisternography

Neurenteric cyst

Third cranial nerve

1. Introduction

Endodermal cysts are congenital lesions constituted by a mucus-secreting epithelium similar to that of the gastrointestinal tract/respiratory epithelium [1–3]. Intracranial endodermal cysts are rare [1–3] and, in these instances, they are found in the midline of the posterior fossa, anterior brainstem, and suprasellar region. Third cranial nerve cysts are an exquisitely rare occurrence with only four cases described so far [4–7]. The authors describe a case of a third cranial nerve endodermal cyst, discuss its clinical picture, radiological nuances and clinical outcome.

2. Case report

A 20 years old female complained of sudden headache, diplopia and left palpebral ptosis. Neurological examination revealed a left ptosis, anisocoria with a fixed dilated pupil and limitations in extraocular muscles movements. Only abduction of the left eye was preserved. No additional abnormalities were noticed. CT scan evidenced enlargement of left oculomotor cistern and compression of the uncus. Angiogram ruled out aneurysms. MRI revealed a cystic lesion associated with a thin rim of enhancement, occupying

the left oculomotor and crural cisterns, with close proximity to the third cranial nerve as it exits from the midbrain (Fig. 1). The lesion exhibited an isointense signal area in the T1-weighted sequence and a markedly hyperintense signal in the T2-weighted sequence. It presented an enhanced rim with a gadolinium injection (Fig. 1).

At surgery, an intrinsic cystic lesion of the third cranial nerve was observed (Fig. 2a). After removal, an enlargement of the third cranial nerve due to the presence of solid adherent tissue was noticed and partially removed, remaining small parts adherent to the nerve and perforators arteries (Fig. 2b).

Pathological findings included columnar epithelial lining over loose smooth muscle cells and fibro-connective tissue (Fig. 3). Glandular structures resembling the gastrointestinal and respiratory epithelial cells were found. Immunohistochemical analysis showed that the epithelial cells reacted predominantly with CK-7, AML and S-100. Some cells in the submucosa were immunoreactive for S-100 protein and glial fibrillary acidic protein (GFAP). It was negative for CK20, CDX-2 and TTF-1. Endodermal cyst was the definitive diagnosis [1,3–7].

Postoperative period was uneventful and patient completely recovered third nerve function after 6 months.

3. Discussion

Endodermal cysts occur most often in the subdural space in the anterior spinal cord and usually at the lower cervical and upper thoracic levels [1–3]. They have also been called neurenteric and

* Corresponding author at: Rua Dr. Eneas de Carvalho Aguiar, 255, 5 Andar, Divisão de Clínica Neurocirúrgica, Instituto Central Hospital das Clínicas, São Paulo, Brazil. Tel.: +55 11 30697152.

E-mail address: ebgadelha@yahoo.com (E.G. Figueiredo).

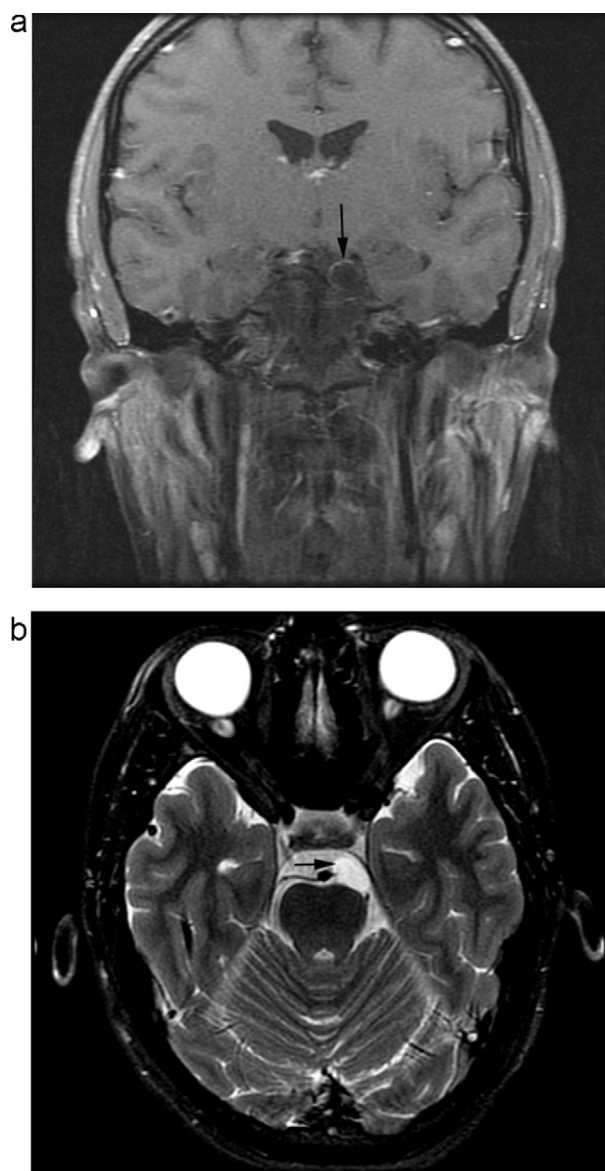


Fig. 1. Magnetic resonance images of the endodermal cyst of the oculomotor nerve. Location, walls and anatomical relationships of the cyst may be precisely appreciated (arrows). (a) Coronal view. (b) Axial view.

enterogenous. Intracranial endodermal cysts are extremely rare, occurring on the ventral surface of the brainstem and exceptionally in the supratentorial compartment, mainly in the suprasellar region [1–5].

Third cranial nerve cysts have been reported in four studies [4–7]. Their pathoembryology still remains unknown and it is generally believed to result from failure of separation of neuroectodermal and endodermal elements in the first 3 weeks of embryogenesis [1–3].

Table 1 summarizes the cases of endodermal oculomotor cysts. Intracranial endodermal cysts present a male predominance (61%) and may occur at any age (birth – 77 years) [2]. Conversely, in the subset of endodermal cysts of the oculomotor nerve, young female preponderance has been observed (Table 1). Most cases of endodermal cysts usually have a long clinical course and become symptomatic due to cyst's enlargement. Sudden headache and acute paresis of the oculomotor nerve was the main clinical presentation. Nonetheless, signs of chronic dysfunction of the third cranial nerve were noticed in two cases (Table 1). Headache is

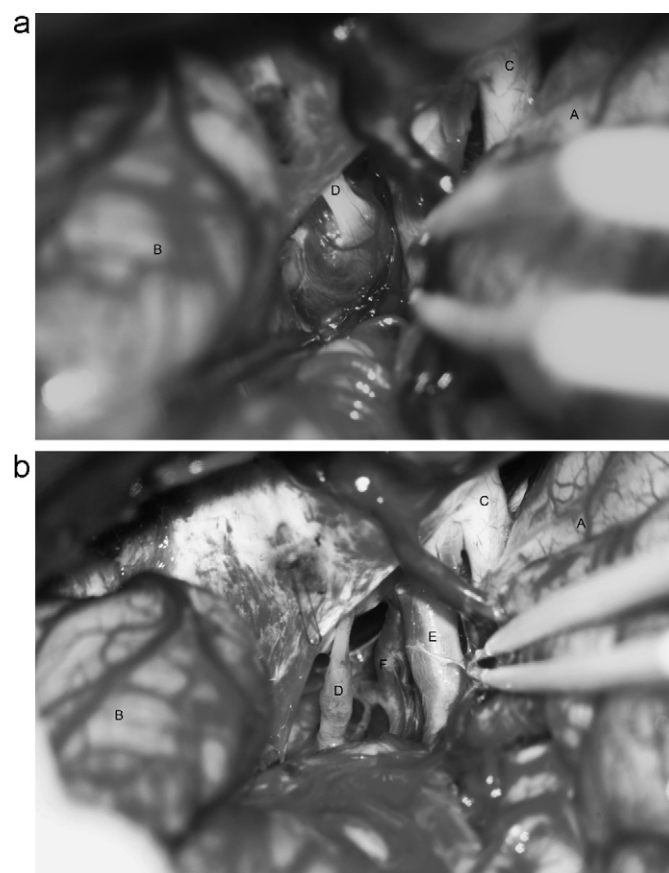


Fig. 2. (a) Microsurgical view. A cystic lesion occupying crural and interpeduncular cisterns has been exposed. Oculomotor nerve is identified closely related to the lesion. (b) Microsurgical view after resection of the cyst. Enlarged third cranial nerve, internal carotid and posterior communicating arteries may be visualized. A – frontal lobe; B – temporal lobe; C – optic nerve; D – oculomotor nerve; E – internal carotid artery; F – posterior communicating artery.

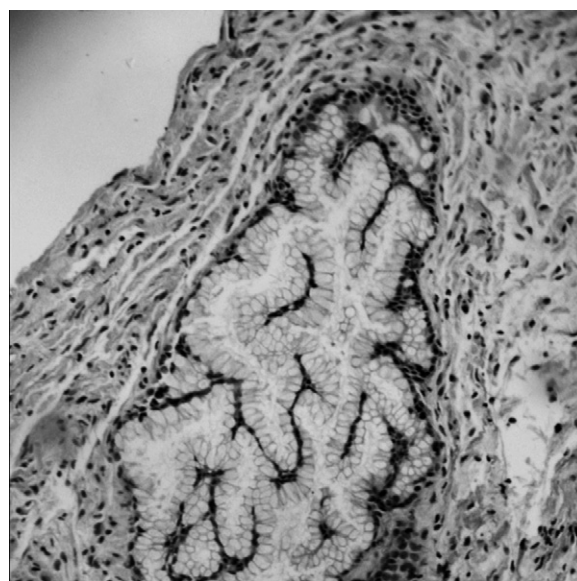


Fig. 3. Microscopic section. Simple epithelium overlying fibro-connective tissue and glandular structures resembling gastric glands may be observed (hematoxylin-eosin 100 \times).

Table 1
Summary of cases of endodermal cysts of the oculomotor nerve.

Report	Age (years)	Gender	Clinical presentation	MRI features	Extent of resection	Function of third cranial nerve
Morgan et al. [4]	30	Female	Chronic III nerve paresis	Cystic lesion with thin rim enhancement after Gadolinium injection T1 weighted image: hypointense lesion T2 weighted image: slightly increased T2 signal relative to CSF MRI cisternography: not performed	Subtotal	Improved
Okunagawa et al. [5]	16	Female	Headache, acute III nerve paresis	Cystic lesion with thin rim enhancement after Gadolinium injection T1 weighted image: mixed-intensity cystic lesion T2 weighted image: hyperintense mass MRI cisternography: cyst located on oculomotor nerve	Subtotal	Improved
Karikari et al. [6]	02	Female	Acute III nerve paresis	Cystic lesion with thin rim enhancement after Gadolinium injection T1 weighted image: mixed-intensity cystic lesion T2 weighted image: hyperintense mass MRI cisternography: cyst located on oculomotor nerve	Subtotal	Improved
Wait et al. [7]	05	Female		Cystic lesion with thin rim enhancement after Gadolinium injection T1 weighted image: mixed-intensity cystic lesion T2 weighted image: hyperintense mass MRI cisternography: not reported	Subtotal	No improvement
Current case	20	Female	Chronic III nerve dysfunction, sudden headache and acute III nerve paresis	Cystic lesion with thin rim enhancement after Gadolinium injection T1 weighted image: mixed-intensity cystic lesion T2 weighted image: hyperintense lesion MRI cisternography: cyst located on oculomotor nerve	Subtotal	Improved

MRI: magnetic resonance image; CSF: cerebrospinal fluid.

believed to occur due to rapid cyst expansion. Several mechanisms have been proposed to explain the growth of cysts, including secretion from the epithelial cells of the cyst, intracystic hemorrhage, hormonal mechanisms, differences in osmotic pressure, and the one-way valve mechanism [2–5].

Because the clinical and radiological findings are not specific, preoperative diagnosis is difficult. Differential includes other cystic lesions, such as dermoid or epidermoid cyst, arachnoid cyst, cystic schwannoma, Rathke's cleft cysts and neurocisticercosis. These lesions may present variable signal intensities on magnetic resonance imaging depending on the protein content. Most of them are usually slightly hypointense relative to cerebrospinal fluid on T1-weighted images and hyperintense on T2-weighted images. Overall, the characteristics of an endodermal cyst are that of a cystic lesion with a light enhanced rim and without nodular areas. Magnetic resonance cisternography was useful to confirm its location and features. Radiological findings of endodermal oculomotor nerve are detailed in Table 1.

Diagnosis requires the correlation of location, radiological findings, histology, and immunohistochemical features. Its rarity precludes an accurate preoperative diagnosis. However, MRI cisternography may constitute a fundamental diagnostic tool. Although the prognosis after total removal is excellent, cysts may recur if a portion of the cyst wall remains after surgery. Total

removal is often impossible when portions densely adhere to the brainstem, major blood vessels, or cranial nerves, as demonstrated in this report. It is noteworthy to say that in the majority of cases, the oculomotor nerve function gradually improved.

Conflict of interest statement

The authors report no conflict of interest concerning the methods and findings specified in this paper.

References

- [1] Basheer N, Kasliwal MK, Suri A, Sharma MC, Arora A, Sharma BS. Lateral extradural, supratentorial neurenteric cyst. *J Clin Neurosci* 2010;17:639–41.
- [2] Brooks BS, Duvall ER, el Gammal T, Garcia JH, Gupta KL, Kapila A. Neuroimaging features of neurenteric cysts: analysis of nine cases and review of the literature. *AJNR* 1993;14:735–46.
- [3] Chavda SV, Davies AM, Cassar-Pullicino VN. Enterogenous cysts of the central nervous system: a report of eight cases. *Clin Radiol* 1985;36:245–51.
- [4] Morgan MA, Enterline DS, Fukushima T, McLendon RE, Cummings TJ. Endodermal cyst of the oculomotor nerve. *Neuroradiology* 2001;43:1063–6, 2001.
- [5] Okunagawa T, Tsutsusumi K, Hayashi T, Nagat I. Endodermal cyst of the oculomotor nerve: case report. *Neurosurgery* 2006;58:994–5.
- [6] Karikari IO, Grant G, Cummings TJ, Petrella J, Fuchs HE. Endodermal cyst of the oculomotor nerve. *Pediatr Neurosurg* 2010;46:155–6.
- [7] Wait SD, Choi LSJ, Teo C. Neurenteric cyst: an unusual cause of third nerve palsy. *Childs Nerv Syst* 2010;27:639–41.