

Evaluation of the efficacy of hydrated sodium aluminosilicate in the prevention of aflatoxin-induced hepatic cancer in rainbow trout¹

Sarah Arana^{2*}, Maria L. Z. Dagli³, Myrna Sabino⁴, Yara A. Tabata⁵, Marcos G. Rigolino⁵ and Francisco J. Hernandez-Blazquez⁶

ABSTRACT.- Arana S., Dagli M.L.Z., Sabino M., Tabata Y.A., Rigolino M.G. & Hernandez-Blazquez F.J. 2011. **Evaluation of the efficacy of hydrated sodium aluminosilicate in the prevention of aflatoxin-induced hepatic cancer in rainbow trout.** *Pesquisa Veterinária Brasileira* 31(9):751-755. Laboratório de Histofisiologia e Histopatologia Experimental em Animais Ectotérmicos, Departamento de Histologia e Embriologia, Instituto de Biologia, Universidade Estadual de Campinas, Cx. Postal 6109, Campinas, SP 13083-970, Brazil. E-mail: aranas@unicamp.br

The use of aluminum silicates for decontaminating animal feed containing aflatoxins has yielded encouraging results in chicken and turkey poult. In contrast, very few studies have tested these substances in aquaculture. In this work, we investigated the efficacy of a trout diet containing 0.5% hydrated sodium aluminosilicate (HSAS) in protecting against contamination with aflatoxin B1. Trout were reared on these diets for one year and the experimental groups were examined monthly for hepatic presumptive preneoplastic and neoplastic lesions. Regardless of the presence of HSAS, all of the fish that received aflatoxin in their diet have shown hepatic lesions indicative of a carcinogenic process, presenting also the development of cancer in some fish. The concentration of HSAS used in this study was ineffective in preventing the onset of hepatic lesions induced by aflatoxin B1 in rainbow trout.

INDEX TERMS: Aflatoxin adsorbents, hepatocarcinogenesis, liver, mycotoxin, teleost.

RESUMO.- [Avaliação da eficácia do aluminossilicato de sódio hidratado na prevenção de câncer hepático induzido por aflatoxina em truta arco-íris.] Resultados encorajadores têm sido observados com o emprego de aluminossilicatos para descontaminação de ração contendo aflatoxina destinada à avicultura. No entanto, raros estudos têm sido destinados a testar essa substância em aquicultura. Assim, no presente trabalho, foi investigada a eficácia do aluminossilicato de sódio hidratado (HSAS, 0,5%) em proteger a truta arco-íris dos danos hepáticos causa-

dos por ração contaminada com aflatoxina B1. Os grupos experimentais foram alimentados com suas respectivas dietas durante 12 meses, mensalmente cada grupo foi amostrado para análises anatomopatológica e histopatológica para verificação da presença de lesões hepáticas. Apesar da presença de HSAS, todos os grupos que receberam dieta contaminada com aflatoxina B1 apresentaram lesões hepáticas indicativas do processo carcinogênico, sendo que exemplares alimentados com essas dietas por mais longo prazo apresentaram hepatocarcinoma ou colangiocarcinoma. Estes resultados indicaram que a concentração de HSAS usada no presente estudo não foi efetiva em prevenir o desenvolvimento de lesões hepáticas induzidas por aflatoxina B1 em truta arco-íris.

TERMOS DE INDEXAÇÃO: Adsorbente de aflatoxina, hepatocarcinogênese, fígado, micotoxina.

INTRODUCTION

The aflatoxins are produced by only a few strains of *Aspergillus flavus* and *Aspergillus parasiticus* that generally just synthesize two or three aflatoxins under a given set of conditions, one of which is always aflatoxin B1 (AFB1), the most potent toxin and carcinogen of the group (Shank 1981).

Aflatoxins represent a serious problem in tropical

¹ Received on April 18, 2011.

Accepted for publication on June 23, 2011.

² Laboratório de Histofisiologia e Histopatologia Experimental em Animais Ectotérmicos, Departamento de Histologia e Embriologia, Instituto de Biologia, Universidade Estadual de Campinas (Unicamp), Cx. Postal 6109, Campinas, SP 13083-970, Brazil. *Corresponding author: aranas@unicamp.br

³ Departamento de Patologia, Faculdade de Medicina Veterinária e Zootecnia (FMVZ), Universidade de São Paulo (USP), Av. Prof. Dr. Orlando Marques de Paiva 87, São Paulo, SP 05508 270, Brazil.

⁴ Núcleo de Contaminantes Orgânicos, Instituto Adolfo Lutz, Secretaria da Saúde do Estado de São Paulo, Av. Dr. Arnaldo 355, São Paulo, SP 01246-902, Brazil.

⁵ Estação Experimental de Salmonicultura Dr. Ascânio de Faria, Agência Paulista de Tecnologia de Agronegócios, Secretaria de Agricultura e Abastecimento de São Paulo, Cx. Postal 361, Campos do Jordão, SP 12.460-000, Brazil.

⁶ Seção de Anatomia do Departamento de Cirurgia, FMVZ-USP, São Paulo, SP.

countries, as their hot and humid climate favors the growth of *Aspergillus*. The feed contamination is responsible for large economic losses in the livestock industry (Rodriguez-Amaya & Sabino 2002).

The binding of AFB₁-oxide to cellular DNA is a trigger for AFB₁-mediated mutagenesis and carcinogenesis. AFB₁ is carcinogenic in a variety of vertebrates, including rats, ducks, monkeys, trout and humans (Bailey et al. 1996, Benford et al. 2010). Several studies have shown that aflatoxicosis is the most common cause of hepatic neoplasia in cultured rainbow trout (Hendricks et al. 1984, Bailey et al. 1996, Arana et al. 2002).

The introduction of aflatoxin adsorbents has been proposed as a means of sequestering this mycotoxin from contaminated food. The hydrated aluminosilicates have proven to be efficient as aflatoxin adsorbents (Phillips et al. 1988), and their efficacy as aflatoxin adsorbents and in preventing the deleterious effects of these toxins on animal health have been tested *in vivo* by adding the silicate to the diets for chickens and turkey (Kubena et al. 1990a,b), pigs (Schell et al. 1993), cows and lambs (Harvey et al. 1991a,b), rats (Mayura et al. 1998, Abdel-Wahhab et al. 2002) and dogs (Bingham et al. 2004).

This way, the use of substances like hydrated sodium aluminosilicate (HSAS) provides new perspectives for controlling intoxication by aflatoxin-contaminated animal and human feed. In aquaculture, specifically fish farming, only a few studies have examined the usefulness of aluminosilicates (Winfree & Allred 1992, Ellis et al. 2000). Due to concerns regarding liver lesions caused by contaminated commercial feed in trout farms in Brazil, we have studied the efficacy of HSAS in preventing aflatoxin-induced liver lesions in these fish.

MATERIALS AND METHODS

Animals. Four hundred and thirty-two rainbow trout (*Oncorhynchus mykiss*, Walbaum), originated from domesticated stock reared at the Experimental Salmon Farm Station, in Campos do Jordão (22° 45' S and 45° 30' W), São Paulo State, Brazil, were used in this study. Six month-old rainbow trout, with a mean weight of 50 g at the beginning of the experiment, were kept in six 1500 L circular fiberglass tanks, under natural photoperiod conditions. Each tank was independently supplied with flow-through surface water (1~2 exchanges/hour). The water temperature varied during 12-month duration of the experiment between 9 and 17°C, and the dissolved oxygen in discharge water was above 5mg L⁻¹.

Diet. Hydrated sodium aluminosilicate ($14SiO_2 \cdot 1Al_2O_3 \cdot 1Na_2O \cdot 4H_2O$ kindly supplied by Rhodia S.A) was added as a powder to a commercial rainbow trout diet (Nutraviv Com. Ind. Ltda., Brazil) as the last component before the pelletization. The pelletization of experimental diet was made using a small pelletizing machine from the Ration Factory of the Faculdade de Zootecnia e Engenharia de Alimentos da USP. AFB₁ (Sigma-Aldrich Fine Chemicals, St Louis, MO, USA) was dissolved in dimethyl sulfoxide (Merck) and added carefully to the ration with a special small industrial mixer at the Experimental Salmon Farm Station, in 4 Kg aliquots. After careful mixing, the commercial rainbow trout, with or without HSAS and/or AFB₁, was kept at -20°C. The various preparations were analyzed by a conventional chromatographic method to verify the levels of AFB₁ on the experimental diet, and to confirm the absence of this mycotoxin in the control diet (Soares & Rodriguez-Amaya 1989). These analyses were done for each new preparation throughout

the experiment, usually once every two months. On that occasion, the residue of the feed prepared previously was also analyzed to check the levels of contamination during the storage period.

Experimental procedure. Six experimental groups were used: Group C - control diet without AFB₁ or HSAS, Group H - diet plus 0.5% HSAS, Group A40 - diet with 40µg of AFB₁/kg; Group AH40 - diet with 40µg of AFB₁/kg plus 0.5% HSAS, Group A80 - diet plus 80µg of AFB₁/kg; Group AH80 - diet with 80µg of AFB₁/kg plus 0.5% HSAS. All groups received their respective experimental diet, supplied by hand twice a day for 12 months. The daily amount of feed distributed corresponded to 2% of the fish biomass per tank per day, based on monthly fish weight data.

Four hundred and thirty-two animals were evaluated at monthly intervals for 12 months, six fish from each group, with the first evaluation commencing 30 days after the beginning of the treatment. The fish were sacrificed by immersion in a solution of benzocaine (100 mg/L). Liver samples were fixed in 10% buffered formalin for 24 h, embedded in paraffin and 6 mm thick sections were stained with haematoxylin-eosin for histopathological examination. The animals were maintained and killed in accordance with the guidelines of the Institutional Committee for Ethics in Animal Experimentation (Unicamp).

The degenerative and presumptive preneoplastic hepatic lesions were characterized based on the criteria defined to rainbow trout by Hendricks et al. (1984) and adapted following the Arana et al. (2002) criteria, which were used to determine the incidence of lesions in the different groups. The criteria described by Arana et al. (2002) were used to define three basic situations that indicated the incidence of these lesions in hepatic sections based on histopathological inspection: 1 = one lesion in the hepatic area analyzed, 2 = two lesions per area, and 3 = three or more lesions per area. A dichotomous classification of absent (0 or no) or present (OK or yes) was applied to the neoplastic lesions.

Statistical analyses. The statistical analyses to compare the effect of the treatment on the occurrence of hepatic lesions were done using the Wald test, with significance corresponding to $P \leq 0.05$.

Statistical analyses were performed using a standard statistical software program (MINITAB version: 15.1, Minitab Inc., State College, USA).

RESULTS

No mortality was verified during the experimental period. The fish in group C and most of those in group H showed the typical anatomical and histological liver structure for rainbow trout throughout the experimental period (Fig. 1A). Two fish in group H developed a presumptive preneoplastic lesion, a basophilic nodule (BN), one of them in the tenth month of experiment and other in the eleventh month. This spherical lesion consisted of small basophilic cells that formed cords which were easily differentiated from the surrounding normal hepatocytes.

In group A40, presumptive preneoplastic lesions were observed as early as the fourth month of treatment. These lesions consisted of basophilic foci (BF) formed by basophilic cells, with round nuclei and evident nucleoli; these cells were smaller than adjacent hepatocytes (Fig. 1B). Figures of mitosis and apoptosis could occasionally be seen between the cells of the basophilic foci. The hepatocytes around the lesion appeared either normal (Fig. 1B) or showed characteristics of anaplastic cells. The occurrence of BF lesions increased with the duration of treatment. After nine months, degenerative lesions, such as acidophilic foci (AF), were found. They consisted of large acidophilic cells with mitotic figures and were usually surrounded by anaplastic cells. Frequently, the AF were

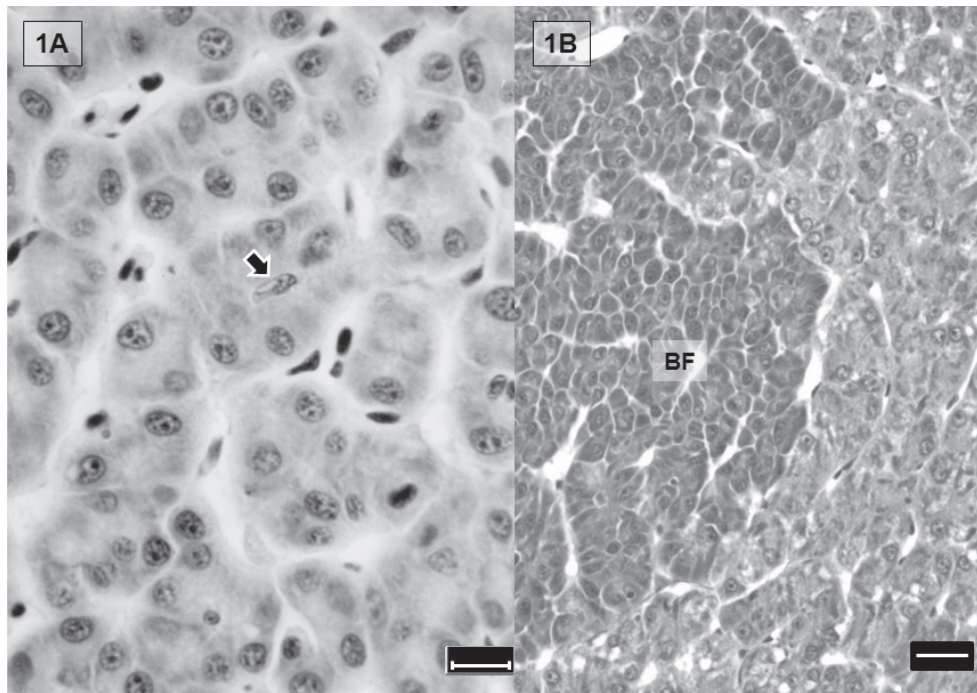


Fig.1. Trout liver, stained by HE. (A) Liver of the trout from control group, showing the typical tubular organization, the nuclei of a preductular cell is noted in the center of one tubule (arrow). Bar: 20µm. (B) Basophilic foci (BF) in liver from trout treated with diet with 40µg of AFB1/kg plus 0.5%, note the limits of the basophilic foci and the parenchyma apparently normal, where there are less intensely stained hepatocytes . Bar: 20µm.

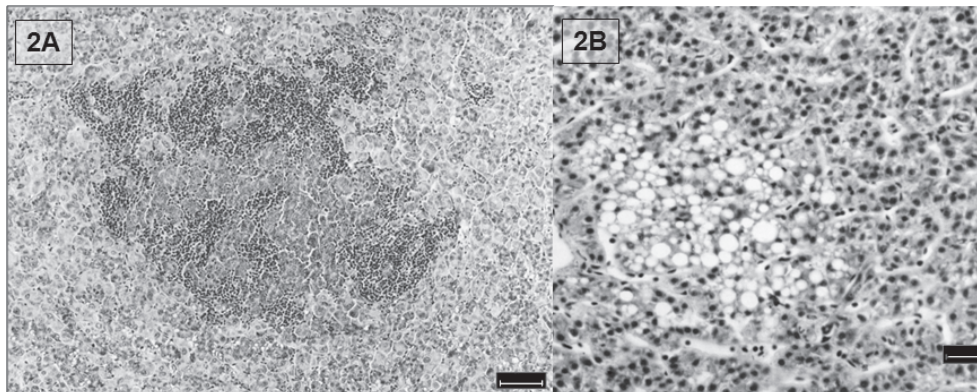


Fig.2. (A) Acidophilic foci intensely infiltrated by leucocytes in liver of trout from group A40. Stain: HE. Barr: 50µm). (B) Vacuolated foci surrounded by liver parenchyma apparently normal in trout from A80. Stain: HE. Bar: 50µm.

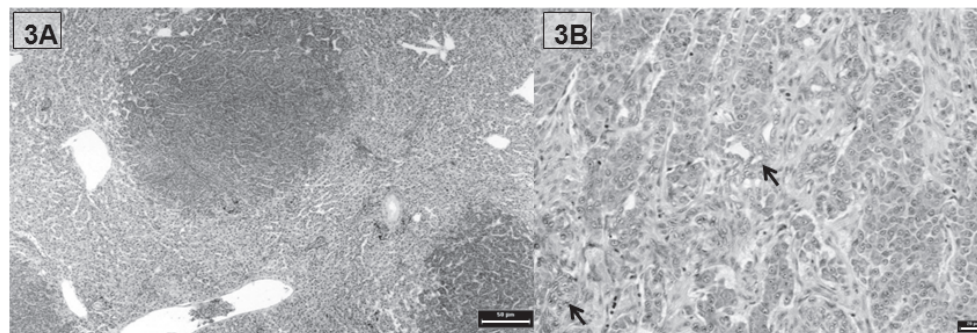


Fig.3. (A) Basophilic nodules in liver of trout from group AH80. Stain: HE. Barr: 50µm. (B) Area of HCC in liver of trout from group AH40 showing mixed pattern characterized by proliferating ductal areas (arrows) surrounded by desmoplastic tissue and micronodules of basophilic cells. Stain: HE. Bar: 20µm.

Table 1. Probability of the occurrence of: degenerative, presumptive preneoplastic and neoplastic lesions, considering the total occurrence of each one in 12 months, in different combinations of treatments

Lesion	Treatment combinations						
	C ^a / H ^b	C/ A40 ^c /A80 ^d	H/AH40 ^e / AH80 ^f	A40/AH40	A80/AH80	A40/A80	AH40/AH80
VF ^g	0.9999	0.0638	0.1786	0.5620	0.8859	0.0772	0.0350*
AF ^h	0.9999	0.1894	0.0007*	0.1196	0.0093*	0.0355*	0.5237
BF ⁱ /BN ^j	0.9999	0.0001*	0.0001*	0.3004	0.7796	0.4732	0.5438
HCC ^k	0.9999	0.0003*	0.0001*	0.4645	0.5670	0.0001*	0.0001*

^a Group C = control, ^b group H = 0.5% HSAS, ^c group A40 = 40µg of AFB1/kg, ^d group A80 = 80µg of AFB1/kg, ^e group AH40 = 0.5% HSAS and 40µg of AFB1/kg, ^f group AH80 = 0.5% HSAS and 80µg of AFB1/kg, ^g VF= vacuolated foci, ^h AF= acidophilic foci, ⁱ BF= basophilic foci, ^j BN= basophilic nodule, ^k HCC= hepatocellular carcinoma. Probability of the test values to be less than χ^2 . Several combinations, the treatment combinations indicated with an asterisk were significantly different ($P \leq 0.05$).

infiltrated and largely destroyed by leucocytes (Fig.2A). In the three last months of the experiment, another degenerative lesion as vacuolated foci (VF) consisting of cells with an intensely vacuolated cytoplasm (micro and macrovacuolization) were also observed (Fig.2B) together with BF and AF. After eight months basophilic nodules (BN) were observed (Fig.3A), alone or in association with BF, VF or AF. Neoplastic lesions classified as hepatocellular carcinoma (HCC) surrounded by anaplastic cells were observed in one fish in this group. HCC showed a mixed pattern characterized by proliferating ductal areas surrounded by desmoplastic tissue and micronodules of basophilic cells (Fig.3B). At the end of the experiment, other fish in this group showed a cholangiocarcinoma, which is characterized by a lesion composed entirely of ductular elements supported by stroma.

The time and frequency of the development of BF, AF, VF and BN were similar in groups A40, AH40 and A80. However, HCC was not observed in group AH40 and developed earlier and was more frequently found in A80 than in the groups that received diet with 40mg of AFB1/kg. Livers from fish in group AH80 showed BF after the third month of treatment, and HCC was seen at the seventh month in one fish. At the end of the experiment, 6 fish showed HCC and one also had cholangiocarcinoma.

Statistical analysis showed that the differences in the incidence of degenerative, presumptive preneoplastic and neoplastic lesions were significant when the results of the aflatoxin-treated groups were compared with those for groups C and H, and when the results of the groups treated with 40µg of AFB1/kg were compared with those for groups treated with 80 µg of AFB1/kg the differences between the aflatoxin-treated groups were not significant whether with HSAS or not (Table 1).

DISCUSSION AND CONCLUSIONS

The normal liver architecture and histological features seen in most of the trout in C and H groups indicated that a concentration of 0.5% HSAS in the feed was not toxic to rainbow trout, as also observed in birds and other animals (Phillips et al. 1988, Harvey et al. 1991a,b, Abdel-Wahhab et al. 2002).

The most commonly used nomenclature for altered foci in fish mimics the system used for rodents, that is, eosinophilic, basophilic and vacuolated foci (Wolf & Wolf 2005), but between these lesions the basophilic foci appear to be precursors of hepatocellular neoplasms (Hendricks et al. 1984). In fact, Hendricks et al. (1984) registered that AF in trout hepatocarcinogenic process is commonly observed

infiltrated by cells of the immune system, predominately lymphocytes, and largely destroyed by these cells. The authors suggested that these foci are recognized as antigenically foreign by the immune system and could be a degenerative lesion, not really involved in carcinogenic process. Our results, where AF were infiltrated by leucocytes and largely destroyed, agree with the observations of Hendricks et al. (1984). Thus, we did not consider AF as presumptive preneoplastic lesion.

In this study vacuolated foci occurred in the three last months of the experiment, with suggest that this type of foci are not involved with the carcinogenic process induced by aflatoxin in trout. This observation is in agreement with Hendricks et al. (1984) which discussed the possibility that this type of foci are not involved in any type of stepwise progression toward neoplasia in trout, but represent another toxic effect of the carcinogenic compounds usually tested on trout.

Considering our results and the notes listed above, only basophilic foci and basophilic nodule could be considered presumptive preneoplastic lesions in hepatocarcinogenic process of trout.

The occurrence of a presumptive preneoplastic lesion in trout in group H was not statistically significant compared to the control group. This lesion was not attributable to feed contaminated with aflatoxin since analysis of the feed in this group revealed no traces of this toxin. A possible explanation for the appearance of this pathologic process could be spontaneous formation of lesions caused by a congenital genetic disorder, such as occurs in mice (Frith et al. 1994).

The histopathological and statistical results indicate that the dose of HSAS employed here was not effective in preventing or reducing the occurrence of preneoplastic and neoplastic lesions induced by AFB1 in the trout. Previous reports have yielded conflicting results regarding the efficacy and potential adverse consequences of adding hydrated aluminosilicates to animal feed. There are a few reports in the literature that analyzed the efficacy of aflatoxin adsorbents using histopathological analyses, actually the majority of reports emphasized analysis of growth performance. Some researchers, using histopathological parameters, reported that the addition of 0.5% HSAS to poultry feed had little effect on liver lesions induced by aflatoxin (Kirby et al. 1990, Kubena et al. 1990a).

The addition of HSAS to feed contaminated with aflatoxin improves the immunological resistance of birds and helps prevent alterations in plasma protein levels frequently caused by this toxin (Kirby et al. 1990, Kubena et al. 1990a). Treat-

ment with HSAS also reduces the presence of AFB1 metabolites in biological samples such as urine (Bingham et al. 2004). In contrast, in trout, the carcinogenic effects of aflatoxin were apparently not inhibited by HSAS, probably because of high fish sensitivity to this toxin (Williams et al. 2009).

In a manner similar to that seen in trout, Mayura et al. (1998) observed in rats treated with AFB1 plus clinoptilolite (a zeolite) the occurrence of more serious liver lesions as nodules of regenerating hepatocytes in addition to massive bile duct proliferation and hepatocellular degeneration also observed in rats treated only with AFB1. These authors suggested that zeolite might interact with dietary components that modulate aflatoxicosis. Furthermore, Huwig et al. (2001) pointed out that the inclusion of aluminosilicates in diet has the disadvantage of potentially interfering with the assimilation of vitamins and minerals.

In the present study, HSAS may have interfered with absorption of some feed components, thereby affecting fish treated with higher doses of AFB1. In fact, Shi et al. (1994) demonstrated in an *in vivo* study on rats that selenium inhibits AFB1-DNA binding and adduct formation. Many other vitamins and anti-oxidants naturally found in diet produced this inhibitor effect (Atroshi et al. 2002). However, the suggestion that the lack of effect against AFB1 in trout can be due to binding of protective components by aluminum silicate depends on confirmation by specific analyses.

Finally, our results reinforce the belief that aflatoxin adsorbents should be rigorously tested individually and *in vivo* characterized. Particular attention should be given to favorable thermodynamic characteristics of sorption, safety and efficacy in multiple animal species, safety and efficacy in long-term studies and negligible interactions with vitamins, iron and zinc (Philips et al. 2008), as well as economic and technical applicability (Galvano et al. 2001).

Acknowledgements. - To Rosana Aparecida da Silva, Luiz Roberto da Silva and Antonio Donizete da Silva (Estação Experimental de Salomicultura Dr. Ascânio de Faria) for excellent maintenance of the fish farm during this study. This research was supported by grants from Fundação de Amparo à Pesquisa do Estado de São Paulo (FAPESP), Conselho Nacional de Desenvolvimento Científico e Tecnológico (CNPq) and Fundo de Apoio ao Ensino, Pesquisa e Extensão da Universidade Estadual de Campinas (Faepe/Unicamp).

REFERENCES

- Abdel-Wahhab M.A., Nada S.A. & Khalil F.A. 2002. Physiological and toxicological responses in rats fed aflatoxin-contaminated diet with or without sorbent materials. *Anim. Feed Sci. Technol.* 97:209-219.
- Arana S., Tabata Y., Sabino M., Rigolino M.G. & Hernandez-Blazquez F.J. 2002. Differential effect of chronic aflatoxin B1 intoxication on the growth performance and incidence of hepatic lesions in triploid and diploid rainbow trout (*Oncorhynchus mykiss*). *Arch. Med. Vet.* 4:253-263.
- Atroshi F., Rizzo A., Tuomas Westermarck T. & Ali-Vehmas T. 2002. Antioxidant nutrients and mycotoxins, *Toxicology* 180:151-167.
- Bailey G.S., Williams D.E. & Hendricks J.D. 1996. Fish models for environmental carcinogenesis: The rainbow trout. *Environ. Health Persp.* 104:5-21.
- Benford D., Leblanc J.C. & Setzer R.W. 2010. Application of the margin of exposure (MoE) approach to substances in food that are genotoxic and carcinogenic Example: Aflatoxin B1 (AFB1). *Food and Chem. Toxicol.* 48:S34-S41.
- Bingham A.K., Huebner H.J., Phillips T.D. & Bauer J.E. 2004. Identification and reduction of urinary aflatoxin metabolites in dogs. *Food and Chem. Toxicol.* 42:1851-1858.
- Ellis R.W., Clements A., Tibbetts A. & Winfree R. 2000. Reduction of the bioavailability of 20mg/kg aflatoxin in trout feed containing clay. *Aquaculture* 183:179-188.
- Frith C.H., Ward J.M. & Turusov V.S. 1994. Tumours of the liver, p.225-227. In: *Ibid.* (Eds), *Pathology of Tumours in Laboratory Animals*. Vol. II. *Tumours of the Mouse*. International Agency for Research on Cancer, Lyon, France.
- Galvano F., Piva A., Ritieni A. & Galvano G. 2001. Dietary strategies to counteract the effects of mycotoxins: A review. *J. Food Prot.* 64:120-131.
- Harvey R.B., Kubena L.F., Phillips T.D., Corrier D.E., Elissalde M.H. & Huff W.E. 1991a. Diminution of aflatoxin toxicity to growing lambs by dietary supplementation with hydrated sodium calcium aluminosilicate. *Am. J. Vet. Res.* 52:152-156.
- Harvey R.B., Phillips T.D., Ellis J.A., Kubena L.F., Huff W.E. & Petersen H.D. 1991b. Effects on aflatoxin M1 residues in milk by addition of hydrated sodium calcium aluminosilicate to aflatoxin-contaminated diets of dairy cows. *Am. J. Vet. Res.* 52:1556-1558.
- Hendricks J.D., Meyers T.R. & Shelton D.W. 1984. Histological progression of hepatic neoplasia in rainbow trout (*Salmo gairdneri*). *J. Natl Cancer Inst. Monogr.* 65:321-336.
- Huwig A., Freidmund S., Käppeli O. & Dutler H. 2001. Mycotoxin detoxication of animal feed by different adsorbents. *Toxicol Lett.* 132:179-188.
- Kirby G.M., Stalker M., Metcalfe C., Kocal T., Ferguson H. & Hayes M.A. 1990. Expression of immunoreactive glutathione S-transferase in hepatic neoplasms induced by aflatoxin B1 or 1,2-dimethylbenzanthracene in rainbow trout (*Oncorhynchus mykiss*). *Carcinogenesis* 11:2255-2257.
- Kubena L.F., Harvey R.B., Huff W.E., Corrier D.E., Phillips T.D. & Rottinghaus G.E. 1990a. Efficacy of a hydrated sodium calcium aluminosilicate to reduce the toxicity of aflatoxin and T-2 toxin. *Poultry Sci.* 69:1078-1086.
- Kubena L.F., Harvey R.B., Phillips T.D., Corrier D.E. & Huss W.E. 1990b. Diminution of aflatoxicosis in growing chickens by dietary addition of high hydrated sodium calcium aluminosilicate. *Poultry Sci.* 69:727-735.
- Mayura K., Abdel-Wahhab M.A.A., McKenzie K.S., Edwards J.F., Naguib K. & Phillips T.D. 1998. Prevention of maternal and developmental toxicity in rats via dietary inclusion of common aflatoxin sorbents: Potential for hidden risks. *Toxicol. Sci.* 41:175-182.
- Phillips T.D., Kubena L.S., Harvey R.B., Taylor B.S. & Heidelbaugh N.D. 1988. Hydrated sodium calcium aluminosilicate: A high affinity sorbent for aflatoxin. *Poultry Sci.* 67:243-247.
- Phillips T.D., Afriyie-Gyawu E., Williams J., Huebner H., Ankrah N.A., Ofori-Adjei D., Jolly P., Johnson N., Taylor J., Marroquin-Cardona A., Xu L., Tang L. & Wang J.S. 2008. Reducing human exposure to aflatoxin through the use of clay: A review. *Food Addit Contam.* 25:134-145.
- Rodriguez-Amaya D.B. & Sabino M. 2002. Mycotoxin research in Brazil: The last decade in review. *Braz. J. Microbiol.* 33:1-11.
- Schell T.C., Lindemann M.D., Kornegay E.T., Blodgett D.J. & Doerr J.A. 1993. Effectiveness of different types of clay for reducing the detrimental effects of aflatoxin-contaminated diets on performance and serum profiles of weanling pigs. *J. Anim. Sci.* 71:1226-1231.
- Shank R.C. 1981. Chemistry and Occurrence, p.4. In: *Ibid.* (Eds), *Mycotoxins and N-nitroso Compounds: Environmental Risks*. Vol.II. CRC Press, Boca Raton, Florida.
- Shi C.Y., Chua S.C., Lee H.R. & Ong C.N. 1994. Inhibition of aflatoxin B1-DNA binding and adduct formation by selenium in rats. *Cancer Lett.* 82:203-208.
- Soares L.M.V. & Rodriguez-Amaya D.B. 1989. Survey of aflatoxins, ochratoxin A, zearalenone and sterigmatocystin in some Brazilian foods by using multi-toxin thin-layer chromatographic methods. *J. Assoc. Offic. Anal. Chem.* 72:22-26.
- Williams D.E., Orner G., Willard K.D., Tilton S., Hendricks J.D., Pereira C., Benninghoff A.D. & Bailey G.S. 2009. Rainbow trout (*Oncorhynchus mykiss*) and ultra-low dose cancer studies. *Comp. Biochem. Physiol. C* 149:175-181.
- Winfree R.A. & Allred A. 1992. Bentonite reduces measurable aflatoxin B1 in fish feed. *Progr. Fish-Cult.* 54:157-162.
- Wolf J.C. & Wolf M.J. 2005. A brief of nonneoplastic hepatic toxicity in fish. *Toxicol. Pathol.* 33:75-85.