



BRAZILIAN JOURNAL
OF MEDICAL AND BIOLOGICAL RESEARCH

www.bjournal.com.br

ISSN 0100-879X
Volume 42 (11) 993-1118 November 2009

BIOMEDICAL SCIENCES
AND
CLINICAL INVESTIGATION

Braz J Med Biol Res, November 2009, Volume 42(11)1027-1034

Modulation of extracellular matrix by nutritional hepatotrophic factors in thioacetamide-induced liver cirrhosis in the rat

R.R. Guerra, M.R. Trotta, O.M. Parra, J.L. Avanzo, A. Bateman, T.P.A. Aloia, M.L.Z. Dagli and F.J. Hernandez-Blazquez

The Brazilian Journal of Medical and Biological Research is partially financed by



Ministério
da Ciência e Tecnologia



Ministério
da Educação



Institutional Sponsors



GE Healthcare

Modulation of extracellular matrix by nutritional hepatotrophic factors in thioacetamide-induced liver cirrhosis in the rat

R.R. Guerra¹, M.R. Trotta¹, O.M. Parra¹, J.L. Avanzo²,
A. Bateman³, T.P.A. Aloia¹, M.L.Z. Dagli² and
F.J. Hernandez-Blazquez¹

¹Departamento de Cirurgia, ²Departamento de Patologia, Faculdade de Medicina Veterinária e Zootecnia, Universidade de São Paulo, São Paulo, SP, Brasil

³Department of Medicine, MUHC, Royal Victoria Hospital, McGill University, QC, Canada

Abstract

Nutritional substances associated to some hormones enhance liver regeneration when injected intraperitoneally, being denominated hepatotrophic factors (HF). Here we verified if a solution of HF (glucose, vitamins, salts, amino acids, glucagon, insulin, and triiodothyronine) can revert liver cirrhosis and how some extracellular matrices are affected. Cirrhosis was induced for 14 weeks in 45 female Wistar rats (200 mg) by intraperitoneal injections of thioacetamide (200 mg/kg). Twenty-five rats received intraperitoneal HF twice a day for 10 days (40 mL·kg⁻¹·day⁻¹) and 20 rats received physiological saline. Fifteen rats were used as control. The HF applied to cirrhotic rats significantly: a) reduced the relative mRNA expression of the genes: Col- α 1 (-53%), TIMP-1 (-31.7%), TGF- β 1 (-57.7%), and MMP-2 (-41.6%), whereas Plau mRNA remained unchanged; b) reduced GGT (-43.1%), ALT (-17.6%), and AST (-12.2%) serum levels; c) increased liver weight (11.3%), and reduced liver collagen (-37.1%), regenerative nodules size (-22.1%), and fibrous septum thickness. Progranulin protein (immunohistochemistry) and mRNA (*in situ* hybridization) were found in fibrous septa and areas of bile duct proliferation in cirrhotic livers. Concluding, HF improved the histology and serum biochemistry of liver cirrhosis, with an important reduction of interstitial collagen and increased extracellular matrix degradation by reducing profibrotic gene expression.

Key words: Liver cirrhosis; Hepatotrophic factors; Collagen; Matrix modulation; Progranulin

Introduction

Liver transplantation is the only definitive treatment in some cases of human chronic cirrhosis (1). Nutritional support has been shown to be helpful in some liver diseases (2,3). In fact, liver proliferation can be modulated by dietary factors that interfere with hepatic regeneration. Studies dealing with nutritional modulation of hepatic regeneration and growth by stimulation of hepatocyte proliferation with hepatotrophic factors (HF) found in food have been published (2-6). Hepatic mass and DNA increase associated with reduction of the fibrotic fraction in the extracellular matrix was observed after 10 days of intraperitoneal treatment with HF in normal rats. The intraperitoneal route may have contributed to liver mass increase and collagen reduction since this route is functionally very close to a portal administration. HF usually consist of vitamins, salts, amino acids,

and hormones (triiodothyronine, insulin and glucagon) (4). Due to previous results obtained for normal liver, we applied HF treatment to cirrhotic livers to investigate if this solution would be effective in reducing the cirrhotic condition and to identify some of the mechanisms of its effect. The relative expression activities of matrix metalloproteinase-2 (MMP-2), transforming growth factor- β 1 (TGF- β 1), tissue inhibitor of metalloproteinase-1 (TIMP-1), collagen- α 1, and plasminogen activator urokinase (Plau) were evaluated by real-time PCR. Total hepatic collagen volumetric proportion and regenerative nodules were measured, and histopathologic and hepatic function analyses were performed. Additionally, we characterized the expression of progranulin protein and mRNA in cirrhotic and non-cirrhotic livers. Progranulin is a growth factor involved in tumorigenesis, wound repair,

Correspondence: R.R. Guerra, Rua Aggeu Silveira Monteiro, 54, Bairro Jardim Las Vegas, 09182-360 Santo André, SP, Brasil.
E-mail: rrguerra@usp.br

Received November 26, 2008. Accepted July 31, 2009. Available online September 28, 2009.

neovascularization, inflammation, cell migration and mitosis (7), and cell survival (8). Progranulin expression was high in a mouse model of early diet-induced non-alcoholic steatohepatitis (9), and was recently identified in cultured primary and immortalized hepatic stellate cells (10), but it is not expressed in normal hepatocytes (11). Given the association of progranulin with fibrosis following injury (12), with early liver disease, and with hepatic stellate cells in culture, we postulated that it may play a role in hepatic fibrosis/cirrhosis *in vivo*.

Material and Methods

Experimental design

Sixty female Wistar rats (185-211 g) were used in accordance with the ethical guidelines of the University of São Paulo. The rats were randomly divided into three groups: control group (15 rats not submitted to any experimental treatment), cirrhotic rats treated with hepatotrophic factors (HF group, N = 25) and cirrhotic rats treated with physiological saline (PS group, N = 20). Cirrhosis was induced by intraperitoneal injections of 200 mg/kg 4% thioacetamide (TAA) in saline, three times a week for 14 weeks with a 20% increase by the 7th week.

Hepatotrophic factor solution was composed of 2 solutions: a) salts, hormones and vitamin solutions containing 104 g glucose, 2 mg pyridoxine, 2 mg calcium pantothenate, 30 mg thiamine, 4 mg riboflavin phosphate, 1.43 g potassium chloride, 1.50 g sodium bicarbonate, 50 mg nicotinamide, 750 mg potassium monophosphate, 500 mg magnesium sulfate, 500 mg vitamin C, 62.5 IU insulin, 0.625 mg glucagon, 2.5 mg folic acid, 31.25 µg vitamin B12, 3.125 mg zinc sulfate, and 300 mL distilled water (q.s.). b) the amino acid solution was composed of 180 mg L-tryptophan, 530 mg L-valine, 1060 mg L-arginine (base), 460 mg L-histidine (base), 1030 mg L-alanine, 380 mg L-asparagine, 270 mg L-aspartic acid, 270 mg L-glutamic acid, 30 mg L-cystine, 260 mg L-ornithine, 840 mg L-proline, 250 mg L-serine, 160 mg L-tyrosine, 800 mg L-glycine, and 200 mL distilled water (q.s.). Both solutions were mixed for a total volume of 500 mL. Triiodothyronine was added to the HF solution just before the use to reach a concentration of 2.26 µg per 200 g of live weight.

All animals were weighed weekly. Ten days after the end of the cirrhosis induction period, a liver biopsy from each rat (2 x 3 x 3 mm) was obtained from the PS and HF groups and the rats were then allowed to rest for 10 days before the beginning of HF or PS treatment.

HF rats received an intraperitoneal injection of HF solution twice a day for 10 days (40 mL·kg⁻¹·day⁻¹) and PS animals were injected with physiological saline. After treatment, the animals of all groups were euthanized and liver samples were collected. Liver weight, liver volume and liver to carcass index were measured. Liver/carcass (LC) index corresponded to liver weight x 100 / carcass weight

(body weight without viscera).

Anesthesia and biopsy surgery

Ten days after the end of the cirrhosis induction period, the animals from the HF and PS groups were anesthetized with isoflurane in 100% oxygen through a Magill circuit and a liver fragment was excised through an abdominal incision. The experimental design was in accordance with the ethical guidelines of the University of São Paulo.

Histopathological examination

Liver samples from biopsies and from the end of treatment with HF or PS were fixed in metacarn and embedded in paraplant. Tissue sections (5 µm) were stained with hematoxylin-eosin and picrosirius (13).

Volumetric proportion of collagen in the liver

Quantitative analysis was performed using the Kontron Zeiss morphometry software KS 400.3 (Carl Zeiss Vision GmbH, Germany). Parenchymal collagen was determined by picrosirius staining. The picrosirius-stained area was measured in 15 microscope fields of the same size from each of 10 animals randomly selected from each group (PS and HF). Data are reported as percent collagen area in the microscopic field, which is equivalent to the volumetric proportion of collagen in the liver.

Determination of regenerative nodules

Quantitative analysis was performed as described above. The number of parenchymal regenerative nodules was counted in 10 rats selected at random from each experimental group (PS and HF). Counts were performed in picrosirius-stained liver sections with a 4X objective, for a total of 15 microscopic fields per rat.

Serum analysis

Blood samples were obtained by cardiac puncture from all animals just before euthanasia. Alanine aminotransferase, aspartate aminotransferase, and gamma-glutamyltransferase were determined with a VetTest Blood Chemistry Analyzer (USA).

RNA purification and real-time PCR

Total RNA was extracted from 40 mg of frozen liver with the Trisol reagent (Invitrogen Life Technologies, USA). Real-time PCR was performed using the ABI Prism® 7000 Sequence Detection System (Applied Biosystems, USA) and the TaqMan Universal Master Mix (Applied Biosystems). The β-actin forward primer (ACCATGAAGATCAAGATCAT), the β-actin reverse primer (AGATTACTGCCCTGGCTCCTA), and the internal β-actin TaqMan probe (FAM-CCACCAATCCACACAGAGTACTT) were used to detect the housekeeping gene β-actin. The primers collagen-α1 (Rn00801649), TGF-β1 (Rn00695755m1), TIMP-1 (Rn00587558m1), MMP-2 (Rn01538167m1), and Plau (Rn0095755m1) were from

Applied Biosystems. Analysis of relative gene expression data was performed by the 2D-DCT method (14).

***In situ* hybridization for progranulin**

Five-micrometer thick tissue sections fixed in metacarn were postfixed with 4% paraformaldehyde, treated with 0.2 M HCl (5 min) and permeabilized with proteinase K (Roche, USA). After washing with 0.5 M sodium citrate solution (SSC), the sections were incubated for 3 h at 42°C with hybridization buffer (5X SSC, 5X Denhardt's solution, 50% deionized formamide and 250 µg/mL progranulin tRNA). Sections were incubated overnight with RNA probes (anti-sense *Bam*H1 and sense *Eco*R1, 1:100) in hybridization buffer containing tRNA as carrier after denaturation of the probe solutions. After hybridization, stringency washes were performed in SSC baths. Immunological detection was carried out with the Dig AP-conjugate (Roche), 1:1000 in 1 M maleic acid, 0.15 M NaCl, pH 7.5, treated DEPC buffer solution. The reaction was visualized with NBT and BCIP (Roche).

Immunohistochemistry

Progranulin. Antigen retrieval was performed by exposing the sections to 10 mM sodium citrate buffer, pH 6.0, in a microwave oven at 900 watts for 20 min. Sections were kept in 5% H₂O₂ for 30 min, followed by 3% bovine serum albumin in 0.1% Tween-20-PBS solution for 3 h to block endogenous peroxidase and nonspecific staining, respectively. Rabbit anti-human progranulin antibody was diluted in antibody diluent (Dako, S0809, USA) and applied to the sections overnight at 4°C. This antibody has been previously demonstrated to cross-react specifically with rat progranulin (Bateman A, unpublished results) and other species (15). The reaction products were visualized with the LSAB2 System-HRP kit (Dako Cytomation, USA) DAB-visualization system.

Bromodeoxyuridine (BrdU). After endogenous peroxidase blocking with 3% H₂O₂, sections were incubated with 0.5 N HCl for 1 h at 37°C. After washing in PBS, the sections were incubated with primary mouse anti-BrdU antibody 1:100 (Amersham Biosciences, USA) for 1 h at 37°C. The Dako EnVision kit (Dako Cytomation) visualization system was used to visualize the DAB reaction. Negative controls (sections processed without the primary or secondary antibody and BrdU-free tissue) were prepared for all immunohistochemistry methods.

Statistical analysis

The mean data for the various groups were compared by ANOVA followed by the Fisher or Newman-Keuls post-test and pairs of means were compared by the Student *t*-test or the paired Student *t*-test for paired samples (biopsy-treatment). The level of significance was set at $P < 0.05$ in all analyses and when a result is reported to be different in any way (higher, lower, more or less) compared with another, they were statistically different.

Results

Macroscopy and animal weight

Rats treated with TAA for 14 weeks developed cirrhosis, which was macronodular in most cases. The average rat weight was 200.2 ± 6.1 g. The HF and PS groups lost weight during TAA administration, regaining it from the 4th to the 7th week, when the dose of TAA was increased by 20%. The weight then dropped again until the 9th week, increasing thereafter until the 14th week when the experiment was terminated.

Hepatic measurements

The final body weight of the liver of rats treated with HF (9.9 ± 1.1 g) was 11.3 and 33.8% higher than that of rats from the PS (8.9 ± 1.1 g) and control (7.4 ± 0.9 g) groups, respectively. Likewise, the liver volume of the HF group (9.2 ± 1 cm³) was 11.3% higher than that of the PS group (8.2 ± 1 cm³) and 34.3% higher than that of the control group (6.8 ± 0.8 cm³). In addition, the LC index was 11.8 and 47.5% (5.9 ± 0.6) higher in the HF group than in the PS (5.3 ± 0.6) and control (4.0 ± 0.6) groups, respectively. In all cases the values were statistically significant.

Histopathology

Rats treated with TAA (HF and PS) showed severe cirrhosis and loss of normal parenchymal architecture, with fibrous septa forming collagen bridges between hepatic triads delineating small and large regenerative nodules of hepatocytes and necrosis. Centrolobular veins were not observed (Figure 1a). Cytoplasmic vacuolization, megalocytosis, bile duct proliferation, and injury to hepatocyte nuclei were observed.

The HF group showed reorganization and restoration of the normal parenchymal architecture, with thinner fibrous septa. There were fewer regenerative nodules of increased size (Figure 1b) and centrolobular veins reappeared. Reduction of cytoplasmic vacuolization, megalocytosis, bile duct proliferation, and nuclei injury were evident, although the microscopic architecture was still different from control (Figure 1c). Bile duct proliferation was found in 62.5% of the liver sections from the PS group and in 38.9% of the sections from the HF group. This difference was statistically significant.

Determination of collagen and regenerative nodules

All comparisons after treatment were paired with the respective biopsies using the paired Student *t*-test ($P < 0.05$). HF-treated rats had 22.1% (2.9 ± 1.2) fewer regenerative nodules per microscopic field following treatment with HF than before the treatment with HF (biopsy; 3.8 ± 1.4). In contrast, in the PS group there was a 51.8% (5.5 ± 1.9) increase in the number of regenerative nodules after PS treatment compared with the biopsy material (3.6 ± 1.5). The total hepatic collagen in the HF group was reduced

by 29.6% ($7.8 \pm 1.9\%$) after treatment compared with the biopsy ($11.1 \pm 2.2\%$). The total collagen in the PS group increased by 8.7% ($12.4 \pm 3.5\%$) after the biopsy ($11.4 \pm 2.4\%$). However, the difference was not statistically significant. All the rats submitted to HF treatment (24 animals) showed reduction of total hepatic collagen. When the mean collagen contents of the unpaired HF group (6.6%) and of the PS group (14.3%) were compared, a 37.1% reduction was observed in the HF group.

Hepatic functions

The concentrations of blood serum marker proteins improved in the HF group, which showed a reduction in γ -glutamyl transferase (GGT; -43.1%, 2.9 ± 2.8 U/L), alanine aminotransferase (ALT; -17.6%, 51.5 ± 12.1 U/L), and aspartate aminotransferase (AST; -12.2%, 132 ± 36.7 U/L) levels when compared with the PS group (GGT: 6.7 ± 5.7 , ALT: 62.45 ± 15.6 , AST: 142.5 ± 26.4 U/L; Figure 2). Mean ALT and AST levels of the HF group were statistically similar to control levels.

Extracellular matrix modulation

The relative expression of profibrotic mRNA (2D-DCT) was lower in the HF group compared with the PS group and similar to the control group, being statistically significant: collagen- $\alpha 1$ (-53%, 2.57 ± 1.86), TGF- $\beta 1$ (-57.7%, 1.07 ± 0.87), TIMP-1 (-31.7%, 1.81 ± 0.85), and MMP-2 (-41.6%, 4.14 ± 1.87). Only mean MMP-2 was higher than the control group. The PS group values were significantly higher for the same genes: collagen- $\alpha 1$ (5.46 ± 2.67), TGF- $\beta 1$ (2.53 ± 1.23), TIMP-1 (2.65 ± 1.32), and MMP-2 (7.09 ± 2.22). All values in this group were higher than control. The relative expression of the profibrinolytic Plau was similar in both treated groups, although higher than control (Figure 3).

Progranulin and cell proliferation

Progranulin protein or mRNA positivity was absent from both cirrhotic and normal livers. However, weak mRNA positivity was found in duodenal intestinal crypts as expected from previous reports (11). PS and HF rats showed progranulin protein and mRNA positivity in pa-

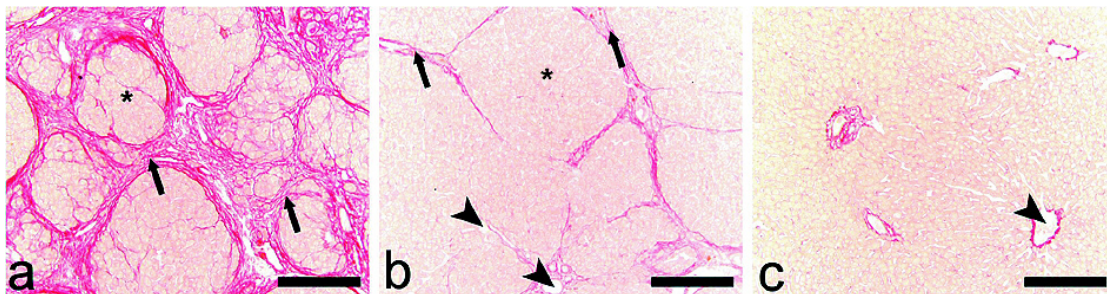


Figure 1. Effect of hepatotrophic factors on thioacetamide-induced liver cirrhosis in rat. *a*, Liver section of a rat receiving physiologic saline. Extensive deposition of collagen is seen (arrows) among the regenerative nodules (star). *b*, Liver section of a rat from the group treated with hepatotrophic factors showing a reduction of inter- and intranodular collagen and thinning of fibrous septa (arrows) and regenerative nodules (star), and the reappearance of a centrolobular vein (arrowheads). *c*, Liver section of a control rat showing the normal parenchymal structure and a central vein (arrowhead). Picrosirius staining. Bar: 200 μ m.

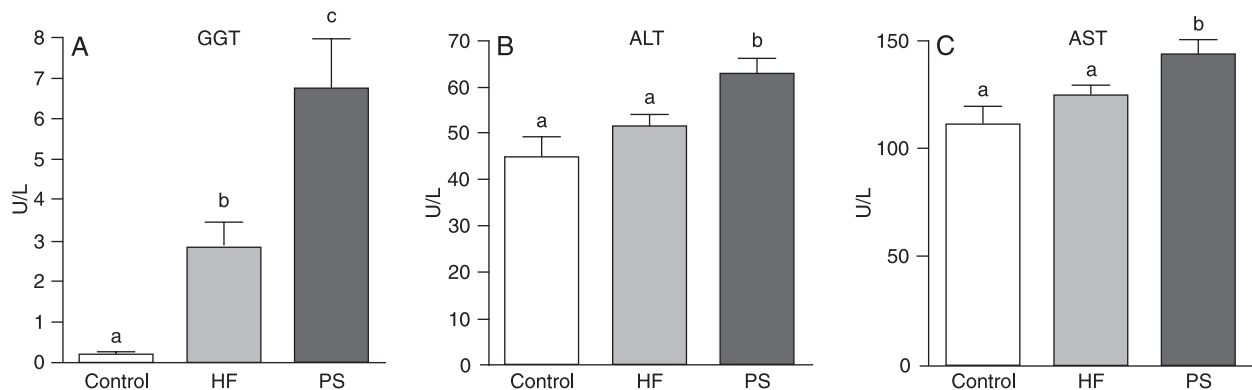


Figure 2. Serological markers of hepatic lesion γ -glutamyl transferase (GGT) (A), alanine aminotransferase (ALT) (B), and aspartate aminotransferase (AST) (C) for the control group and for the groups treated with hepatotrophic factors (HF) and receiving physiologic saline (PS, untreated). The means identified with different letters were significantly different ($P < 0.05$, Tukey test).

renchymal and non-parenchymal hepatic cells, mainly in proliferation zones of bile ducts and fibrous septa (Figure 4b,c,e,f). These areas also had high proliferative activity

(Figure 4a,d). Enterocytes of PS and HF animals were also positive to progranulin mRNA and protein in epithelial cells and, mainly in villi.

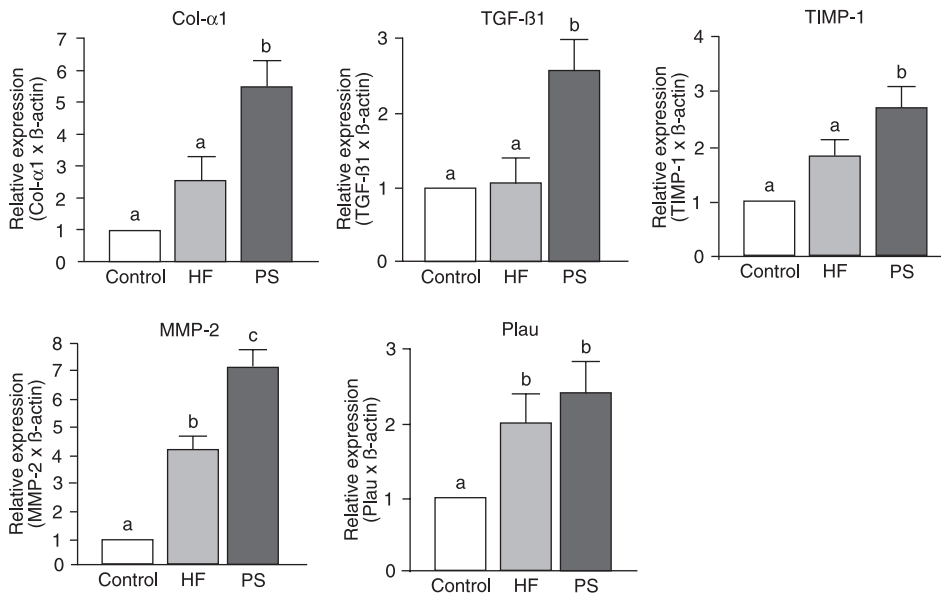


Figure 3. Relative expression activities of genes involved in extracellular matrix modulation in the hepatotrophic factor group (HF, treated), physiologic saline group (PS, untreated), and control group. The means identified with different letters (a, b, c) were significantly different ($P < 0.05$, Newman-Keuls test). Col- α 1 = collagen- α 1; TGF- β 1 = transforming growth factor- β 1; TIMP-1 = tissue inhibitor of metalloproteinase-1; MMP-2 = matrix metalloproteinase-2; Plau = plasminogen activator urokinase.

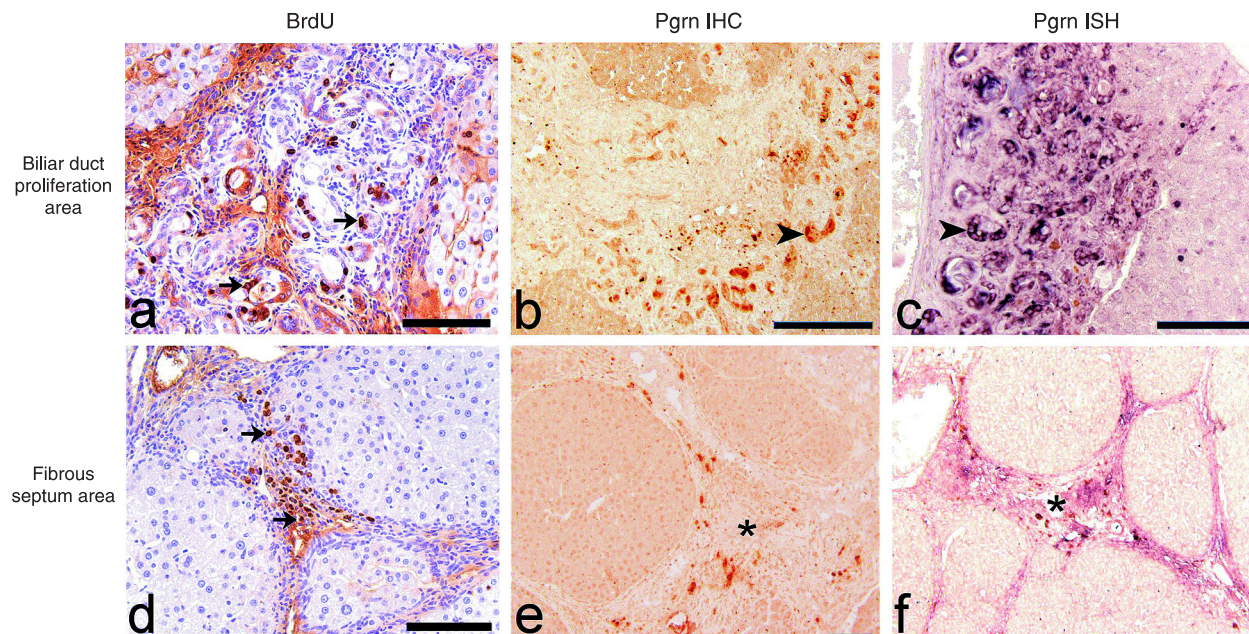


Figure 4. Photomicrographs of a cirrhotic liver from an untreated rat submitted to different techniques. *a*, High proliferation activity of bile duct epithelial cells is seen in the area of bile duct proliferation (arrows). *b*, Bile duct epithelial cells are strongly positive to progranulin (Pgrn) protein in a proliferation area (arrowhead). *c*, Progranulin *in situ* hybridization (ISH) in the area of bile duct proliferation. The bile duct epithelial cells are strongly positive. *d*, Non-parenchymal cells also show high proliferation activity in a fibrous septum area (arrows). *e*, Non-parenchymal cells show progranulin protein positivity (asterisk). *f*, Progranulin ISH in a fibrous septum area, showing high positivity of non-parenchymal cells (asterisk). *Panels a and d* are diaminobenzidine immunostaining and hematoxylin counterstaining. *Panels b and e* are diaminobenzidine immunostaining. BrdU = bromodeoxyuridine; IHC = immunohistochemistry. Bar: 100 μ m.

Discussion

We studied the possible extracellular matrix modulation effects of HF composed by salts, vitamins, glucose, amino acids, and hormones on TAA-induced cirrhosis in rats. The slowly developing TAA cirrhosis model has proven to be morphologically well defined and uniform (16) and to resemble the major features of human cirrhosis, with less mortality than other models of chemical cirrhosis (17). Nevertheless, a problem in the TAA models (18-20) is that apparently the animals become adapted to the drug. After an initial weight loss during the first weeks of TAA administration, the rats began to regain weight. We solved this problem by increasing the TAA dose by 20% after the 7th week. The cirrhosis obtained was well-characterized, with abundant deposition of collagen in hepatic tissue.

The increase of hepatic mass (11.8%) in animals treated with HF for 10 days was associated with the decrease of collagen volumetric proportion (37.1%). Therefore, the increase in mass is derived from functional tissue, such as hepatocytes and the circulatory system. The concomitant increase in the liver weight and LC index supports this theory. In normal rats it was shown that HF promoted a 45% increase in the hepatic mass (4). The values of liver mass, volume and LC index of the control group were lower than those of the PS group (cirrhotic not treated). Liver hypertrophy is normally expected in hepatic diseases, in this case it was probably due to the accumulation of extracellular matrix on the liver, cell proliferation in regenerative nodules and bile cell proliferation.

The serologic tests showed improvements of ALT, GGT, and AST levels after HF treatment. The 43% reduction of GGT, a sensitive indicator of biliary disease, compared to the PS group demonstrates that the HF solution stimulated liver recovery, with benefits to the biliary system. These results agree with the histopathologic findings, which revealed decreased areas of bile duct proliferation after HF treatment. The reduction of ALT (-17.6%) and AST (-12.2%) also points to a reduced hepatocellular necrosis, decreasing the cycles of cell death and fibrotic regeneration that are characteristic of the cirrhotic process. Other treatments also improved hepatic conditions in fibrosis and cirrhosis models with down-regulation of enzymes of hepatic function, such as gliotoxin (21), hepatic growth factor (22), pirfenidone (23), vitamins C and E (24), urokinase plasminogen activator (25), and partial hepatectomy (26).

The 37.1% reduction of parenchymal collagen when the groups were compared or the 29.6% reduction in biopsy-paired comparisons after HF treatment of TAA cirrhosis is a promising finding. It is important to emphasize that the number of regenerative nodules in the cirrhotic liver of the untreated (PS) group increased by 51.9% after the TAA injections were stopped (as could be seen when biopsies were compared with material taken after 20 days), whereas in the HF groups there were 22.1% fewer nodules per

microscopic field. Thus, the treatment of cirrhosis with HF was effective both in stopping the evolution of cirrhosis and mainly in reversing this condition. The reduction of deposition of collagen fibers in the hepatic parenchyma and the reduction in the number of regenerative nodules may contribute to the improvement of liver functions, since the hepatic blood system is favored by these events. Treatment with hepatocyte growth factor also reduced collagen content by 34% in a TAA model (27), in which, however, cirrhosis was induced only for 10 weeks. Virus therapy (adenovirus containing MMP-1) obtained a lower reduction of hepatic collagen (15 to 5%); however, the ALT level increased, indicating hepatocyte damage (19). Other substances have proven to be effective: vitamins C, E and C + E (24), losartan (28), gliotoxin (24), pirfenidone (29), relaxin (30), and Han-Dan-Gan-Lee (31) also reduced fibrosis in rat livers. Hepatic growth factor (22), halofuginone (32) and adenovirus with urokinase plasminogen activator (25) induced collagen reduction in cirrhosis models. It should be pointed out that treatment with pirfenidone reduced 40% of the fibrosis induced by CCl₄ (23).

Since we detected a significant reduction of collagen after just 10 days of treatment, it is very likely that a more prolonged treatment with HF could reduce collagen deposition on the hepatic parenchyma even more, thereby contributing to a greater reversal of the cirrhosis condition, and could also be an important auxiliary treatment of fibrosis. In addition to the quantitative differences in collagen content between the treated and untreated groups, we also detected qualitative differences in liver structure after HF treatment. The HF-treated rats showed partial restoration of the hepatic parenchyma: the lobular architecture was closer to that found in healthy animals, with an easier identification of the portal vessels and centrolobular veins. Although the effect of some components of the HF solution has been previously studied (2-5), the amino acids and other nutritional components seem to act synergistically, providing the additional material and stimulus necessary to the rebuilding of the liver architecture disturbed by the cirrhotic process (6).

Although the antifibrotic effect of HF on cirrhotic livers was well characterized here, it is not possible to conclude that HF was actively profibrinolytic, because Plau, a gene which is directly and indirectly involved in fibrinolysis, was not affected by the treatments. The reduction of profibrotic gene expression by HF is consistent with previous reports on other substances that promoted collagen reduction in liver and that also reduced expression of profibrotic genes or increased profibrinolytic genes. Hepatocyte growth factor down-regulated the expression of collagen- α 1 (46%) and TGF- β 1 (57%) in liver cirrhosis, although the expression of TIMP-1 remained unchanged (26). In our experiment the expression of the profibrotic genes studied (collagen- α 1, MMP-2, TGF- β 1, and TIMP-1) was coherently down-regulated. Experiments with other substances have reported

Table 1. Significant effects of treatment with hepatotrophic factors in thioacetamide-induced liver cirrhosis in the rat.

Liver weight	Increase of 11.3%
Liver volume	Increase of 13.3%
Bile duct proliferation	Reduction
Total hepatic collagen	Reduction of 37.1%
Number of regenerative nodules	Reduction
Serum level of GGT	Reduction of 43.1%
Serum level of ALT	Reduction of 17.6%
Serum level of AST	Reduction of 12.2%
Relative genic expression of collagen- α 1	Reduction of 53.0%
Relative genic expression of TGF- β 1	Reduction of 57.7%
Relative genic expression of TIMP-1	Reduction of 31.7%
Relative genic expression of MMP-2	Reduction of 41.6%
Relative genic expression of Plau	Remained unchanged

GGT = γ -glutamyl transferase; ALT = alanine aminotransferase; AST = aspartate aminotransferase; TGF- β 1 = transforming growth factor- β 1; TIMP-1 = tissue inhibitor of metalloproteinase-1; MMP-2 = matrix metalloproteinase-2; Plau = plasminogen activator urokinase.

variable results with respect to the expression of profibrotic genes, number of genes studied and model of fibrosis or cirrhosis. Sho-saiko-to (a Chinese herb) down-regulated the expression of TIMP-1 and up-regulated MMP-13, but it promoted up-regulation of the profibrotic gene MMP-2 (33). In fibrosis models, interleukin-10 down-regulated TIMP-1 and MMP-2 (34); relaxin down-regulated collagen- α 1 and TIMP-1 (30) and pirfenidone reduced TGF- β 1, TIMP-1, and procollagen α 1(I) production (29). In cirrhotic models, adenovirus with urokinase plasminogen activator, increased gene expression of collagenases (25), and halofuginone reduced gene expression of collagen- α 1 (35).

Progranulin protein and mRNA were found in hepatic and intestinal cells of cirrhotic rats. Although progranulin

expression has been observed in LX-1 and LX-2 cell lines (activated HSC) in culture (10), and is elevated in models of liver steatohepatitis (9) and in hepatocellular carcinoma (36), the present study demonstrates for the first time that this new growth factor is up-regulated in cirrhotic livers *in vivo*. Both progranulin protein and mRNA positivity were strong in hepatic areas of bile duct proliferation and in fibrous septa. These areas coincide with high proliferative activity (demonstrated by BrdU nuclear incorporation), indicative of the involvement of this growth factor in bile duct epithelial cell and non-parenchymal cell proliferation, which contributes to the fibrotic process. As previously reported for other tissues, progranulin may be involved in the regulation of cell growth and in the inflammatory process that occurs in cirrhosis (37-40). Progranulin positivity (mRNA) in intestinal villus macrophages of cirrhotic rats also shows the influence of this protein on the inflammatory process. The expression of progranulin in TAA-treated rats, but not in healthy controls, indicates that it could be a marker of hepatic lesions. However, more studies are needed to establish the role of progranulin in the cirrhotic process.

The present results show that HF treatment can down-regulate the expression of profibrotic genes, collagen- α 1, MMP-2, TIMP-1, and TGF- β 1, with reduction of total hepatic collagen, partial restoration of the parenchymal structure and improvement of the blood levels of hepatic lesion markers (Table 1). These results may provide new insights for the nutritional treatment of cirrhosis.

Acknowledgments

The authors wish to thank F3rmula Medicinal. Research supported by FAPESP (#2004/10971-4) and CNPq (#301761/2005-1). R.R. Guerra was the recipient of a fellowship from CNPq (#140129/2005-7) and M.R. Trotta was supported by a fellowship from FAPESP (#04/10972-0). A. Bateman received an operating grant from the CIHR.

References

- Friedman SL. Mechanisms of disease: Mechanisms of hepatic fibrosis and therapeutic implications. *Nat Clin Pract Gastroenterol Hepatol* 2004; 1: 98-105.
- Okabayashi T, Nishimori I, Sugimoto T, Maeda H, Dabanaka K, Onishi S, et al. Effects of branched-chain amino acid-enriched nutrient support for patients undergoing liver resection for hepatocellular carcinoma. *J Gastroenterol Hepatol* 2008; 23: 1869-1873.
- Charlton M. Branched-chain amino acid enriched supplements as therapy for liver disease. *J Nutr* 2006; 136: 295S-298S.
- Parra OM, de Sousa e Silva RA, da Silva M Jr, Hernandez-Blasquez FJ, Peduto L, Saad WA, et al. Enhancement of liver size by stimulation of intact rat liver with exogenous hepatotrophic factors. *S3o Paulo Med J* 1995; 113: 941-947.
- Parra OM, Hernandez-Blasquez FJ, da Silva M Jr, Sousa Silva RA, Saad WA, Saad Junior WA. Behavior of collagen extracellular liver matrix during regenerative growth after partial hepatectomy or after stimulation by exogenous hepatotrophic factors. Study in rats. *Arq Gastroenterol* 1996; 33: 212-216.
- Holecek M. Nutritional modulation of liver regeneration by carbohydrates, lipids, and amino acids: a review. *Nutrition* 1999; 15: 784-788.
- He Z, Bateman A. Progranulin (granulin-epithelin precursor, PC-cell-derived growth factor, acrogranin) mediates tissue repair and tumorigenesis. *J Mol Med* 2003; 81: 600-612.
- Guerra RR, Kriazhev L, Hernandez-Blasquez FJ, Bateman A. Progranulin is a stress-response factor in fibroblasts subjected to hypoxia and acidosis. *Growth Factors* 2007; 25: 280-285.
- Shiri-Sverdlov R, Wouters K, van Gorp PJ, Gijbels MJ, Noel

- B, Buffat L, et al. Early diet-induced non-alcoholic steatohepatitis in APOE2 knock-in mice and its prevention by fibrates. *J Hepatol* 2006; 44: 732-741.
10. Xu L, Hui AY, Albanis E, Arthur MJ, O'Byrne SM, Blaner WS, et al. Human hepatic stellate cell lines, LX-1 and LX-2: new tools for analysis of hepatic fibrosis. *Gut* 2005; 54: 142-151.
 11. Daniel R, He Z, Carmichael KP, Halper J, Bateman A. Cellular localization of gene expression for progranulin. *J Histochem Cytochem* 2000; 48: 999-1009.
 12. He Z, Ong CH, Halper J, Bateman A. Progranulin is a mediator of the wound response. *Nat Med* 2003; 9: 225-229.
 13. Junqueira LC, Bignolas G, Brentani RR. Picrosirius staining plus polarization microscopy, a specific method for collagen detection in tissue sections. *Histochem J* 1979; 11: 447-455.
 14. Livak KJ, Schmittgen TD. Analysis of relative gene expression data using real-time quantitative PCR and the 2(-Delta Delta C(T)) Method. *Methods* 2001; 25: 402-408.
 15. Desmarais JA, Cao M, Bateman A, Murphy BD. Spatiotemporal expression pattern of progranulin in embryo implantation and placenta formation suggests a role in cell proliferation, remodeling, and angiogenesis. *Reproduction* 2008; 136: 247-257.
 16. Zimmermann T, Muller A, Machnik G, Franke H, Schubert H, Dargel R. Biochemical and morphological studies on production and regression of experimental liver cirrhosis induced by thioacetamide in Uje:WIST rats. *Z Versuchstierkd* 1987; 30: 165-180.
 17. Hatakeyama Y, Ono T, Sato N, Sakuma H, Koyama Y, Inoue N, et al. Usefulness of the tactile sensor for estimating the degree of liver fibrosis and the DNA synthesis activity of remnant liver cells after partial hepatectomy. *Fukushima J Med Sci* 2002; 48: 93-101.
 18. Akahoshi T, Hashizume M, Tanoue K, Shimabukuro R, Gotoh N, Tomikawa M, et al. Role of the spleen in liver fibrosis in rats may be mediated by transforming growth factor beta-1. *J Gastroenterol Hepatol* 2002; 17: 59-65.
 19. Iimuro Y, Nishio T, Morimoto T, Nitta T, Stefanovic B, Choi SK, et al. Delivery of matrix metalloproteinase-1 attenuates established liver fibrosis in the rat. *Gastroenterology* 2003; 124: 445-458.
 20. Mizuno S, Nakamura T. Hepatocyte growth factor: a regenerative drug for acute hepatitis and liver cirrhosis. *Regen Med* 2007; 2: 161-170.
 21. Hagens WI, Beljaars L, Mann DA, Wright MC, Julien B, Lotersztajn S, et al. Cellular targeting of the apoptosis-inducing compound gliotoxin to fibrotic rat livers. *J Pharmacol Exp Ther* 2008; 324: 902-910.
 22. Diaz-Gil JJ, Munoz J, Albillos A, Rua C, Machin C, Garcia-Canero R, et al. Improvement in liver fibrosis, functionality and hemodynamics in CCl4-cirrhotic rats after injection of the liver growth factor. *J Hepatol* 1999; 30: 1065-1072.
 23. Salazar-Montes A, Ruiz-Corro L, Lopez-Reyes A, Castrejón-Gómez E, Armendariz-Borunda J. Potent antioxidant role of pirfenidone in experimental cirrhosis. *Eur J Pharmacol* 2008; 595: 69-77.
 24. Soyulu AR, Aydogdu N, Basaran UN, Altaner S, Tarcin O, Gedik N, et al. Antioxidants vitamin E and C attenuate hepatic fibrosis in biliary-obstructed rats. *World J Gastroenterol* 2006; 12: 6835-6841.
 25. Salgado S, Garcia J, Vera J, Siller F, Bueno M, Miranda A, et al. Liver cirrhosis is reverted by urokinase-type plasminogen activator gene therapy. *Mol Ther* 2000; 2: 545-551.
 26. Hashimoto M, Watanabe G. Functional restoration of cirrhotic liver after partial hepatectomy in the rat. *Hepatology* 2005; 52: 897-902.
 27. Sato M, Kakubari M, Kawamura M, Sugimoto J, Matsumoto K, Ishii T. The decrease in total collagen fibers in the liver by hepatocyte growth factor after formation of cirrhosis induced by thioacetamide. *Biochem Pharmacol* 2000; 59: 681-690.
 28. Ramalho LN, Ramalho FS, Zucoloto S, Castro-e-Silva Junior, Correa FM, Elias JJ, et al. Effect of losartan, an angiotensin II antagonist, on secondary biliary cirrhosis. *Hepatology* 2002; 49: 1499-1502.
 29. Di Sario A, Bendia E, Macarri G, Candelaresi C, Taffetani S, Marzoni M, et al. The anti-fibrotic effect of pirfenidone in rat liver fibrosis is mediated by downregulation of procollagen alpha1(I), TIMP-1 and MMP-2. *Dig Liver Dis* 2004; 36: 744-751.
 30. Williams EJ, Benyon RC, Trim N, Hadwin R, Grove BH, Arthur MJ, et al. Relaxin inhibits effective collagen deposition by cultured hepatic stellate cells and decreases rat liver fibrosis *in vivo*. *Gut* 2001; 49: 577-583.
 31. Li C, Luo J, Li L, Cheng M, Huang N, Liu J, et al. The collagenolytic effects of the traditional Chinese medicine preparation, Han-Dan-Gan-Le, contribute to reversal of chemical-induced liver fibrosis in rats. *Life Sci* 2003; 72: 1563-1571.
 32. Halevy O, Nagler A, Levi-Schaffer F, Genina O, Pines M. Inhibition of collagen type I synthesis by skin fibroblasts of graft versus host disease and scleroderma patients: effect of halofuginone. *Biochem Pharmacol* 1996; 52: 1057-1063.
 33. Sakaida I, Hironaka K, Kimura T, Terai S, Yamasaki T, Okita K. Herbal medicine Sho-saiko-to (TJ-9) increases expression matrix metalloproteinases (MMPs) with reduced expression of tissue inhibitor of metalloproteinases (TIMPs) in rat stellate cell. *Life Sci* 2004; 74: 2251-2263.
 34. Zheng WD, Zhang LJ, Shi MN, Chen ZX, Chen YX, Huang YH, et al. Expression of matrix metalloproteinase-2 and tissue inhibitor of metalloproteinase-1 in hepatic stellate cells during rat hepatic fibrosis and its intervention by IL-10. *World J Gastroenterol* 2005; 11: 1753-1758.
 35. Gnainsky Y, Spira G, Paizi M, Bruck R, Nagler A, Abu-Amara SN, et al. Halofuginone, an inhibitor of collagen synthesis by rat stellate cells, stimulates insulin-like growth factor binding protein-1 synthesis by hepatocytes. *J Hepatol* 2004; 40: 269-277.
 36. Cheung ST, Wong SY, Leung KL, Chen X, So S, Ng IO, et al. Granulin-epithelin precursor overexpression promotes growth and invasion of hepatocellular carcinoma. *Clin Cancer Res* 2004; 10: 7629-7636.
 37. Bateman A, Belcourt D, Bennett H, Lazure C, Solomon S. Granulins, a novel class of peptide from leukocytes. *Biochem Biophys Res Commun* 1990; 173: 1161-1168.
 38. Bateman A, Bennett HP. Granulins: the structure and function of an emerging family of growth factors. *J Endocrinol* 1998; 158: 145-151.
 39. Lu R, Serrero G. Inhibition of PC cell-derived growth factor (PCDGF, epithelin/granulin precursor) expression by antisense PCDGF cDNA transfection inhibits tumorigenicity of the human breast carcinoma cell line MDA-MB-468. *Proc Natl Acad Sci U S A* 2000; 97: 3993-3998.
 40. He Z, Ismail A, Kriazhev L, Sadvakassova G, Bateman A. Progranulin (PC-cell-derived growth factor/acrogranin) regulates invasion and cell survival. *Cancer Res* 2002; 62: 5590-5596.