

# Diagnosis and Treatment of Extraction Sockets in Preparation for Implant Placement: Report of Three Cases

Márcio José Rodrigues BARCELOS<sup>1</sup>  
Arthur Belém NOVAES JÚNIOR<sup>2</sup>  
Marcio Baltazar CONZ<sup>1</sup>  
Nassin David HARARI<sup>1</sup>  
Guaracilei Maciel VIDIGAL JÚNIOR<sup>1</sup>

<sup>1</sup>Department of Oral Implantology, Unigranrio University, Duque de Caxias, RJ, Brazil

<sup>2</sup>Department of Oral and Maxillofacial Surgery and Traumatology and Periodontics,  
Dental School of Ribeirão Preto, University of São Paulo, Ribeirão Preto, SP, Brazil

This article addresses diagnostic parameters that should be assessed in the treatment of extraction sockets with dental implant placement by presenting three case reports that emphasize the relevance of the amount of remaining bone walls. Diagnosis was based on the analysis of clinical and radiographic parameters (e.g.: bone defect morphology, remaining bone volume, presence of infections on the receptor site). Case 1 presents a 5-wall defect in the maxillary right central incisor region with severe root resorption, which was treated with immediate implant placement. Cases 2 and 3 present, respectively, two- and three-wall bone defects that did not have indication for immediate implants. These cases were first submitted to a guided bone regeneration (GBR) procedure with bone graft biomaterial and membrane barriers, and the implants were installed in a second surgical procedure. The analysis of the preoperative periodontal condition of the adjacent teeth and bone defect morphology is extremely important because these factors determine the choice between immediate implant or GBR treatment followed by implant installation in a subsequent intervention.

Key Words: osseointegration, esthetics, implants, tooth loss.

## INTRODUCTION

The treatment with osseointegrated implants was initially designed to solve total edentulism cases by means of a fixed dental prosthesis constructed according to a specific clinical protocol (1). Due to the good results and predictability of the technique, implants have also been used for partially edentulous patients. Therefore, there has been a re-direction on the establishment of diagnostic parameters on more elaborated surgical techniques in order to obtain predictable esthetic results.

A phenomenon that should be understood and awaited is the bone loss occurring after extraction. Among other factors, it also depends on the time elapsed since tooth loss (2) and the type of bone defect created

on the extraction site. The size of such defects is usually related to the cause of tooth loss. This article addresses, by presenting three case reports, diagnostic parameters that should be observed in the treatment of extraction sockets with osseointegrated implants.

## CASE REPORT

### Case 1

A 44-year-old female patient presented to the Department of Oral Implantology at Unigranrio University with a root fracture in the maxillary right central incisor. After tooth extraction, the alveolar bone was carefully examined and a 5-wall defect was observed. A

4.3 x 16 mm implant (Replace Select; Nobel Biocare, Yorba Linda, CA, USA) was installed with 40 N/cm and a zirconia abutment was installed with 20 N/cm, followed by cementation of an immediate temporary crown. A metal-free crown was fabricated and cemented 3 months later (Fig. 1A-D)

### Case 2

A 39-year-old female patient presented to the Department of Oral Implantology at Unigranrio University with bone loss compromising a distal implant. The 2nd molar distal root was also associated with an endoperiodontal lesion. Bone loss involved 2/3 of the distal side at the second implant (Fig. 1A). The initial surgical planning included removal of the 2nd molar root and the distal implant. However, the bone defect pre-

sented only 2 walls (apical and distal) (Fig. 1B). For this reason, a guided bone regeneration (GBR) procedure was performed with the purpose of providing new bone formation at the distal side of the second implant. After a full thickness flap elevation and removal of the compromised elements, the granulation tissue was vigorously curetted and removed. The remaining bone was copiously irrigated with saline. Implant surface was submitted to a 1-min high-pressure sodium bicarbonate blasting followed by application of a citric acid saturated solution for 3 min. After the decontamination treatment, the implant was copiously washed with saline.

Thereafter, autogenous bone was removed from the mandibular ramus with a bone scraper (Mx-Grafter; Maxilon Laboratories, Inc. Hollis, NH, USA) and mixed with Bio-Oss (Osteohealth, Shirley, NY, USA) in order to restore crestal anatomy. A TR4Y Gore-Tex mem-

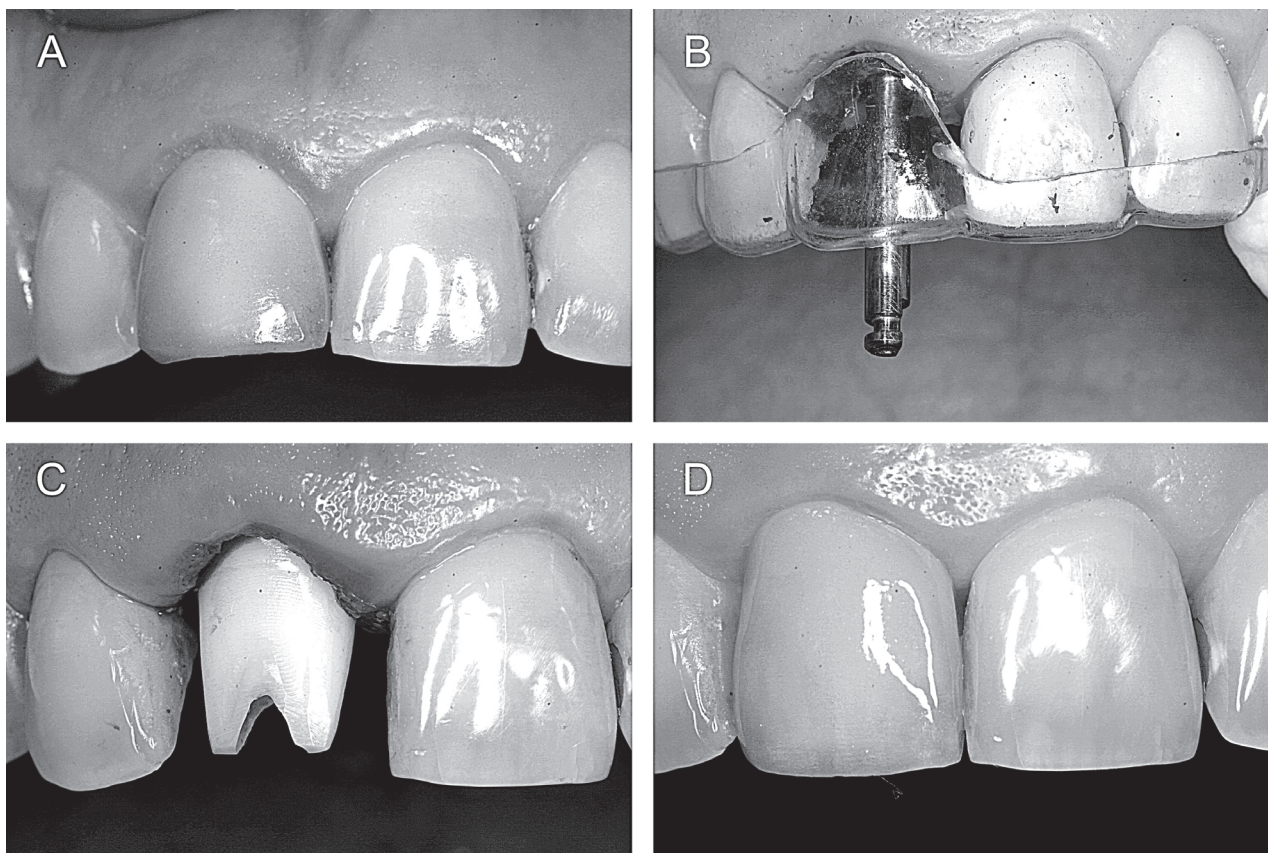


Figure 1. A= Maxillary right central incisor with a fractured root; B= Relationship between the surgical bur and the stent shows an ideal three-dimensional position; C= Definitive zirconia abutment installation; D= Definitive metal-free crown installed after 3 months.

brane (W.L. Gore and Associates, Inc. Flagstaff, AR, USA) was used and fixed with microscrews to protect the graft and prevent the participation of non-osteogenic cells in the healing process. After 13 months, an excellent result on GBR was observed and two-wide platform implants were installed.

**Case 3**

A 47-year-old female patient presented to the Department of Oral Implantology at Unigranrio University with a fractured maxillary right first premolar. Removal of the root revealed a 3-wall bone defect (mesial, distal and apical) suggestive in the radiographic view. The treatment involved two surgical stages. In the first surgical stage, a vigorous curettage was done after tooth extraction in order to remove the inflammatory

tissue, followed by rinsing of the socket with saline. The chosen graft material was Bio-Oss (Osteohealth Co.) and a TR4Y Gore-Tex membrane (W.L. Gore and Associates, Inc.) was fixed with microscrews. After 6 months, success of the GBR procedure was confirmed and a 3.25 x 14 mm implant (Nobel Biocare Inc.) was installed. The definitive crown was installed after a 6-month healing period.

**DISCUSSION**

Dental Implantology offers some advantages for the treatment of edentulous areas. The placement of immediate transalveolar implants is a routine procedure in daily practice since the publication of Schulte and Heinke's work in the 1970's (3). In immediate implant technique, some parameters, such as the presence of

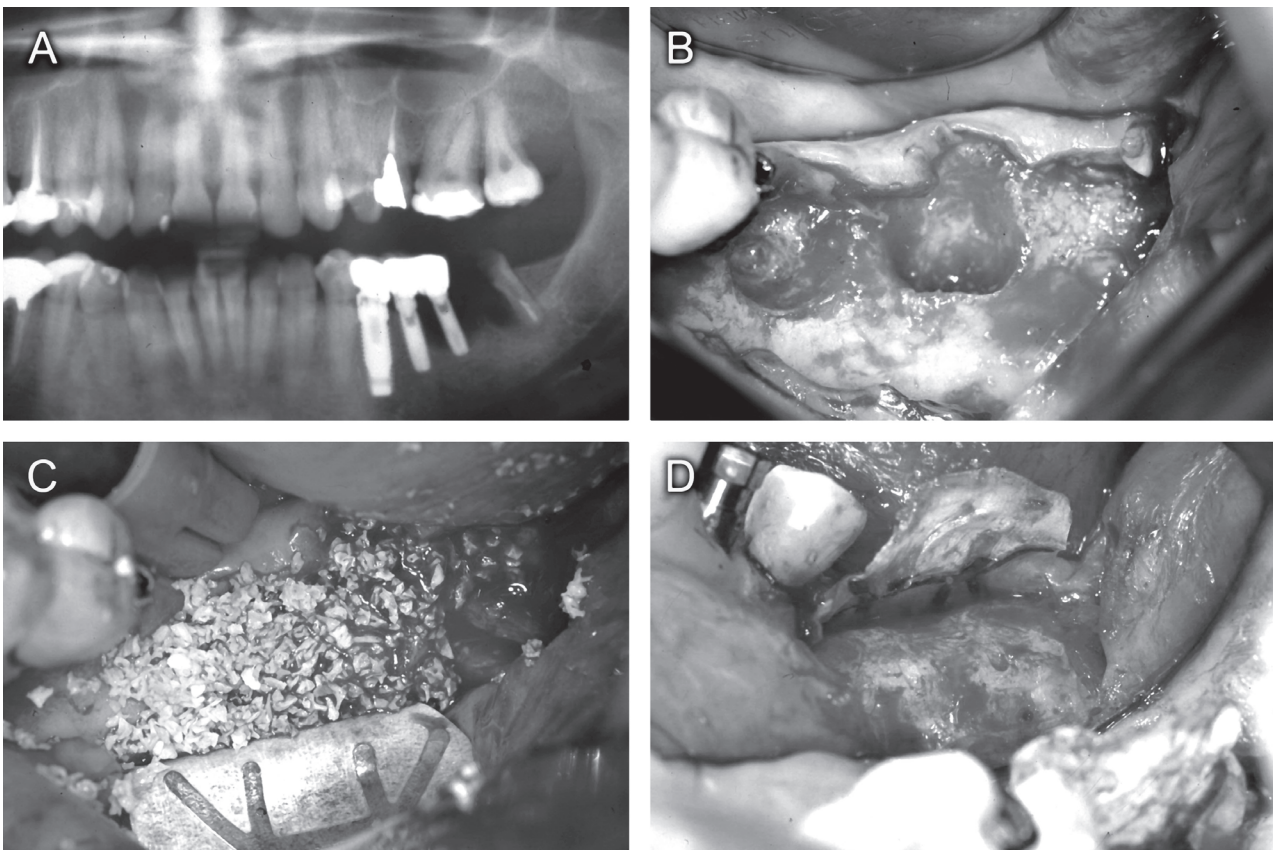


Figure 2. A= Large radiolucent image associated with the implants and distal root of a hemi-sectioned 2nd molar; B= Bone defect after implant removal and tooth extraction; C= Mix of autogenous bone graft and Bio-Oss covered by a TR6W titanium reinforced Gore-Tex membrane placed to restore crestal anatomy; D= New bone formed after 13 months.

infections on the receptor site (4), gingival phenotype (5), remaining bone volume (2), bone defect morphology and correct positioning of implants (6) should be analyzed.

Until the mid 1990's, the therapeutic approach for the extraction socket had been based on Tolman and Keller's study (4), which contraindicated implant placement after extractions in the presence of periapical lesions, supported only by clinical observations. In this way, implant placement was contraindicated in most clinical situations without solid scientific evidences. Novaes Jr. et al. (7) showed that the presence of chronic periapical infections in implant sites does not interfere with the osseointegration process, corroborating the results obtained by Novaes Jr. and Novaes (8) in observations undertaken in human patients. However, in another study of the same research team, Marcaccini et al. (9) observed a delay on the healing process,

indicated by a lesser lamellar bone volume formation in infected periodontal sites, when compared to controls.

Visual inspection of adjacent soft tissue is mandatory in the initial diagnosis of areas that are candidates to the placement of immediate implants. Gingival recession causes a deficiency on the amount of attached gingiva, which might prevent an optimal gingival esthetic result. Under these conditions, the lack of gingival tissue should be corrected by means of a surgical procedure or orthodontic extrusion of the tooth to be extracted. Soft tissue surgery aiming at the alteration of periodontal phenotypes may be applied in the different phases of implant treatment in order to enlarge the zone of attached gingival tissue (10).

Clinically, as far as implant treatment is concerned, it is relatively more difficult to treat the triangular-shaped teeth due to their more evident interdental papilla and the presence of a contact point, rather than

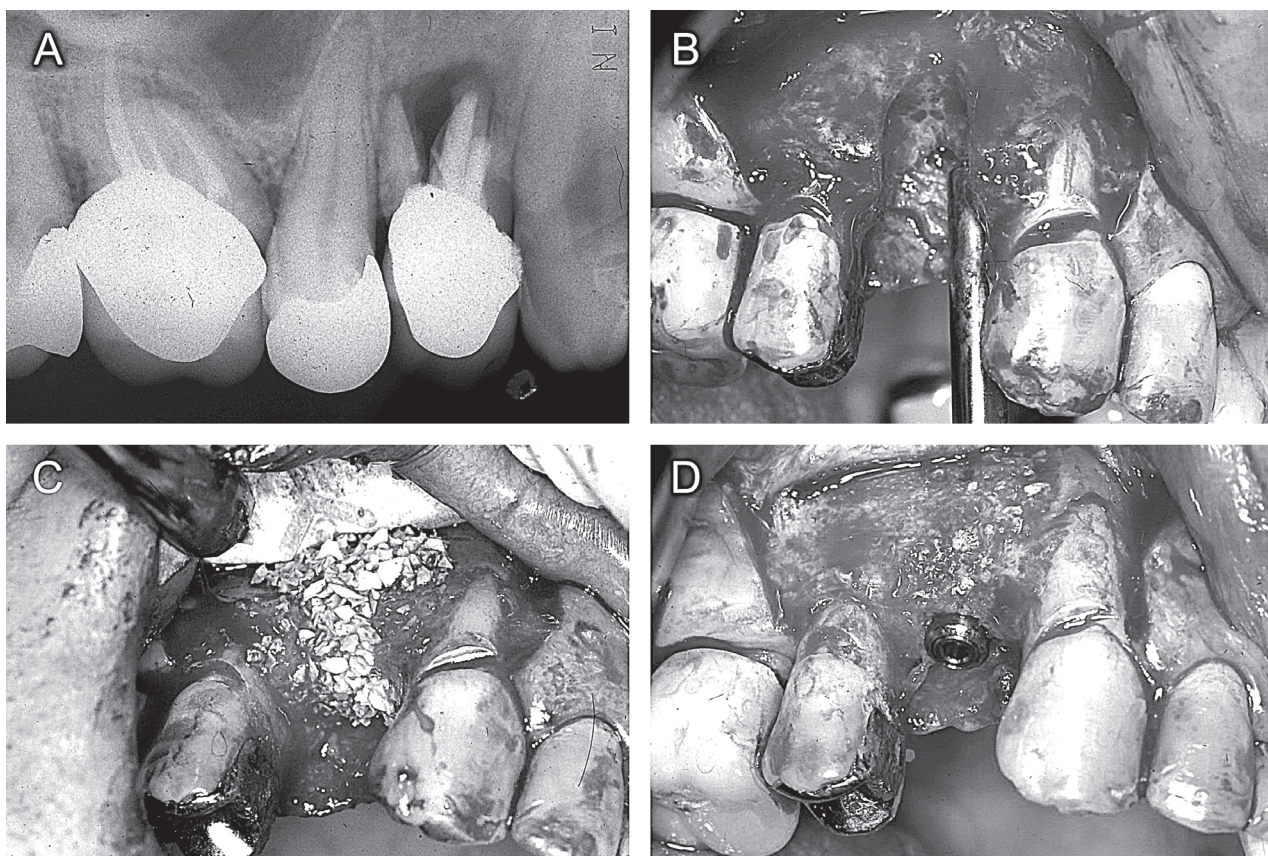


Figure 3. A= Large radiolucent image associated with tooth 14; B= Three-wall defect observed after tooth extraction; C= Guided bone regeneration with Bio-Oss and TR4Y titanium reinforced Gore-Tex membrane; D= Implant installed after 6 months.

a contact surface. There is an association between triangular-shaped teeth and the thin periodontal phenotype (5), which is more sensitive to gingival recessions due to the action of inflammatory infiltrate on junctional and oral epithelia. This promotes the proliferation of both structures and their fusion, resulting in an epithelial bridge, which compromises blood supply to the mucosa margin, causing necrosis. This is the mechanism of gingival recession associated to bacterial biofilm (11).

In case of implant placement between teeth, the presence of interdental papilla shall depend on the bone crest level of the adjacent teeth. It has been described a correlation between the distance of the proximal contact point and the bone crest with the presence of interdental papilla. When this distance was 5 mm, the papilla was present in 98% of the cases. For a 6-mm distance, this percentage was 56%, and for a 7-mm distance it was 27% (12). In addition, bone structure should be previously assessed on the implant site. It is also important to examine the proximal bone crest of the adjacent teeth. The factor that results in the worst prognosis for immediate implants is proximal bone loss in the adjacent teeth because it will prevent complete papilla formation, resulting in a black space on the papilla area (12). A different situation is observed for the papilla between implants. It has been stated that the papilla height between implants is situated approximately 3 mm over the bone crest (13).

The importance of a correct three-dimensional positioning of the implant to obtain an optimal result in esthetic zones has been emphasized (6). In order to obtain a correct positioning in an apical-coronal direction, the implant should be situated 3 mm below the gingival margin (Fig. 1B). A minimal distance of 2 mm must be considered between the implant and the tooth, and 3 mm between implants for maintenance of the interproximal bone septum. In a buccolingual direction, a minimum amount of 2 mm of bone should be preserved on the buccal side of the implant in order to prevent gingival recession (6). It is evident that these measurements have not been determined empirically, but rather resulted from clinical and radiographic observations in a study (14) that established a correlation between the interproximal distance of roots and the prevalence of intrabony pockets. Two intrabony pockets situated in the same interdental zone were present when the distance between the roots was at least 3.1 mm. This occurred due to the lateral effect of biofilm,

which can destroy the bone at the distance of 1.4 mm (14). According to Grunder et al. (15), a horizontal bone loss from 1.3 to 1.4 mm results from bacterial biofilm formation in the microgap existing at the abutment-implant interface (15).

Bone defect morphology shall guide the surgical plan. An extraction socket with all bone walls represents a 5-wall defect (Fig. 1 A-D). However, due to the causes related to tooth loss, one or more bone walls may be lost. In addition to the need of 5 mm of apical bone to allow immediate implant placement, the number of remaining bone walls is determinant to the choice of the surgical technique. Therefore, in a first appointment, the patient should be anesthetized and bone probing should be performed using a periodontal probe in order to verify the dimensions and integrity of the supporting bone of the proximal surfaces of adjacent teeth. In situations of 5- or 4-wall sockets, immediate transalveolar implant is recommended, whereas for sockets with 2 or 3 remaining walls (Figs. 2A-D and 3A-D, respectively), a GBR procedure is indicated as a first step followed by implant placement in the healed bone as a second surgical phase.

For implant placement immediately after tooth extraction, there are two treatment options for 4- or 5-wall defects, depending on the type of bone defect. In 4-wall sockets, GBR shall be performed concomitantly with implant placement, which avoids the placement of a prosthetic provisional crown simultaneously over the implant. In sockets with intact bone walls (5 walls), the best choice of treatment seems to be implant installation with an immediate crown, especially for implants placed on the anterior region. Wöhrle (16) reported 14 consecutive cases of implant placement immediately after tooth extraction. According to this author, the use of this technique provides a better support on the maintenance of bone and gingival tissue architecture in esthetic zones because the gingival structure is preserved (16).

It has been reported that, although defects of around 1.5 mm between bone walls and implants heal spontaneously (17,18), from a clinical standpoint these defects should preferably be filled in order to avoid the collapse of the buccal bone. An effective resource used by the surgeon to fill the gap existent between the bone bed and the implant is the placement of biomaterials, such as bovine mineralized bone associated with an absorbable barrier membrane, with the main goal of preventing loss of buccal bone volume.

The current biological knowledge in Implantology associated to surgical protocols allows treating 4- and 5-wall extraction sockets with immediate implants in a safe and predictable manner. However, an accurate diagnosis (19) and the proper selection of biomaterials to be used (20) are principles that should be observed in the moment of the therapeutic decision, as well as the risks inherent to this procedure.

## RESUMO

Este artigo aborda os parâmetros clínicos que devem ser observados no diagnóstico e tratamento de alvéolos de extração por meio da instalação de implantes através da apresentação de casos clínicos, enfatizando a importância do número de paredes ósseas. O diagnóstico baseou-se na análise de parâmetros clínicos e radiográficos (p. ex: morfologia do defeito ósseo, volume ósseo remanescente, presença de infecção na área receptora). O Caso 1 apresenta um defeito de 5 paredes relacionado a um incisivo central superior direito que apresentava extensa reabsorção radicular e foi tratado através da técnica de implante imediato. Os Casos 2 e 3 consistem em defeitos de 2 e 3 paredes ósseas presentes, respectivamente, que inicialmente não devem ser tratados com implantes imediatos, e, por isso, foram submetidos inicialmente ao procedimento de regeneração óssea guiada, com uso de biomateriais para enxertia e barreiras de membrana, para receberem implantes numa segunda etapa cirúrgica. A avaliação prévia das condições periodontais dos dentes adjacentes e da morfologia do defeito ósseo são extremamente importantes, uma vez que determinam se determinada área será tratada pela técnica de ROG ou pela técnica de implantes imediatos.

## REFERENCES

- Adell R, Eriksson B, Leckholm U. A long-term follow up study of osseointegrated implants in the treatment of totally edentulous jaws. *Int J Oral Maxillofac Implants* 1990;5:347-359.
- Atwood DA. Reduction of residual ridges: a major oral disease entity. *J Prosthet Dent* 1971;26:266-279.
- Schulte W, Heinke G. The Tübingen immediate implant. *Quintessenz* 1976;27:17-23.
- Tolman DE, Keller EE. Endosseous implant placement immediately following dental extraction and alveoloplasty: preliminary report with a 6-year follow-up. *Int J Oral Maxillofac Implants* 1991;2:203-207.
- Müller HP, Eger T. Masticatory mucosa and periodontal phenotype: a review *Int J Periodontics Restorative Dent* 2002;2:173-183.
- Saadoun A, Legall M, Touati B. Selection and ideal three-dimensional implant position for soft tissue aesthetics. *Pract Periodont Aesthet Dent* 1999;11:1063-1072.
- Novaes Jr. AB, Vidigal Jr. GM, Novaes AB, Grisi MF, Polloni S, Rosa A. Immediate implants places into infected sites: a histomorphometric study in dogs. *Int J Oral Maxillofac Implants* 1998;13:422-427.
- Novaes Jr AB, Novaes AB. Immediate implants placed into infected sites: a clinical report. *Int J Oral Maxillofac Implants* 1995;10:609-613.
- Marcaccini AM, Novaes Jr. AB, Souza SL. Immediate placement of implants into periodontally infected sites in dogs: a fluorescence microscopy study. *Int J Oral Maxillofac Implants* 2003;18:812-819.
- Grunder U. Stability of the mucosal topography around single-tooth implants and adjacent teeth: 1-year results. *Int J Periodont Aesthet Dent* 2000;20:11-17.
- Novaes AB, Ruben MP, Kon S, Goldman HM, Novaes AB Jr. The development of the periodontal cleft. *J. Periodontol* 1975;46:701-709.
- Tarnow D. The effect of the distance from the contact point to the crest bone on the presence or absence of the interproximal papilla. *J Periodontol* 1992;63:995-996.
- Novaes Jr. AD, Papalexou V, Muglia V, Taba Jr. M. Influence of interimplant distance on gingival papilla formation and bone resorption: clinical-radiographic study in dogs. *Int J Oral Implants* 2006;21:45-51.
- Tal H. Relationship between the interproximal distance of roots and the prevalence of intrabony pockets. *J Periodont* 1984;55:604-607.
- Grunder U, Gracis S, Capeli M. Influence of the 3D bone-to-implant relationship on esthetics. *Int J Periodontics Restorative Dent* 2005;25:113-119.
- Wöhrle OS. Single-tooth replacement in the aesthetic zone with immediate provisionalization: fourteen consecutive case reports. *Pract Periodont Aesthet Dent* 1998;10:1107-1114.
- Botticelli D, Berglundh T, Buser D, Lindhe J. The jumping distance revisited. An experimental study in the dog. *Clin Oral Impl Res* 2003;14:35-42.
- Akimoto K, Becker W, Person R. Evaluation of titanium implants placed into simulated sockets: a study in dogs. *Int J Oral Maxillofac Implants* 1999;14:351-360.
- Crespi R, Capparè P, Gherlone E, Romanos GE. Immediate occlusal loading of implants placed in fresh sockets after tooth extraction. *Int J Oral Maxillofac Implants* 2007;22:955-962.
- Cafiero C, Annibali S, Gherlone E, Grassi FR, Gualini F, Magliano A et al.. Immediate transmucosal implant placement in molar extraction sites: a 12-month prospective multicenter cohort study. *Clin Oral Impl Res* 2008;19:476-482.

*Accepted April 1, 2008*