

# Quantitative Radiographic Evaluation of Periapical Bone Resorption in Dog's Teeth Contaminated with Bacterial Endotoxin (LPS) Associated or not with Calcium Hydroxide

Léa Assed Bezerra da SILVA<sup>1</sup>  
Raquel Assed Bezerra da SILVA<sup>1</sup>  
Luis Guilherme Siqueira BRANCO<sup>2</sup>  
Valéria Pontelli NAVARRO<sup>1</sup>  
Paulo NELSON-FILHO<sup>1</sup>

<sup>1</sup>*Department of Pediatric, Preventive and Community Dentistry, Dental School of Ribeirão Preto, University of São Paulo, Ribeirão Preto, SP, Brazil*

<sup>2</sup>*Department of Morphology, Stomatology and Physiology, Dental School of Ribeirão Preto, University of São Paulo, Ribeirão Preto, SP, Brazil*

The aim of this study was to quantify radiographically the periapical bone resorption in dogs' teeth contaminated with bacterial endotoxin (LPS), associated or not with calcium hydroxide. After pulp tissue removal, 60 premolars were randomly assigned to 4 groups and were either filled with LPS (group 1), filled with LPS plus calcium hydroxide (group 2) or filled with saline (group 3) for a period of 30 days. In group 4, periapical lesion formation was induced with no canal treatment. Standardized radiographs were taken at the beginning of the treatment and after 30 days and the Image J Program was used for measurement of periapical lesion size. Periapical lesions were observed in groups 1 (average of 8.44 mm<sup>2</sup>) and 4 (average of 3.02 mm<sup>2</sup>). The lamina dura was intact and there were no areas of periapical bone resorption in groups 2 and 3. It may be concluded that calcium hydroxide was effective in inactivating LPS, as demonstrated by the absence of apical periodontitis in the roots that were filled with bacterial endotoxin plus calcium hydroxide.

Key Words: calcium hydroxide, endotoxin, LPS, bone resorption.

## INTRODUCTION

With the advances in microbial culture and molecular biology, it is currently known that anaerobic microorganisms (1-3), especially Gram negative, (4) are highly prevalent in root canals of primary and permanent teeth with pulp necrosis and radiographically visible chronic apical periodontitis. This polymicrobial infection is localized not only in the root canal and dentinal tubules, but also in the areas of cemental resorption and in the entire root canal system (5).

Not only do Gram-negative microorganisms have

different virulence factors and generate products and byproducts that are toxic to apical and periapical tissues, but also contain endotoxin, known as well as LPS due to its lipopolysaccharide constitution. This is particularly important because bacterial endotoxin is released during bacterial multiplication or death, causing a series of biological effects (6) that lead to the occurrence of inflammatory reaction (7) and bone resorption (8,9). Together, these events contribute to the onset and persistence of chronic apical periodontitis (6).

Major efforts have been made to obtain a medication that could inactivate bacterial endotoxin: ex-

Correspondence: Prof. Dr. Paulo Nelson-Filho, Departamento de Clínica Infantil, Odontologia Preventiva e Social, Faculdade de Odontologia de Ribeirão Preto, USP, Av. do Café s/n, 14040-904 Ribeirão Preto, SP, Brasil. Tel: +55-16-3602-4099. Fax: +55-16-3633-0999. e-mail: [nelson@forp.usp.br](mailto:nelson@forp.usp.br)

amples are caustic soda, (10) polymyxin B (11), 1.25% chlorhexidine (12) and sodium hypochlorite (13). However, most of these products have limited usefulness either due to a lack of efficiency or high toxicity, leading to undesirable effects in when contact with tissues.

Due to the lack of information concerning the effect of intracanal dressings on residual LPS that may adhere to mineralized tissues, several *in vitro* and *in vivo* studies (6-9,11,14) have proposed a modification in the concept of intracanal dressing, showing that calcium hydroxide detoxifies bacterial LPS.

Since endotoxin causes a series of adverse biological events that trigger inflammatory response and bone resorption, and considering that calcium hydroxide may inactivate its effects, the aim of this study was to quantify radiographically the periapical bone resorption in dog's teeth contaminated with bacterial endotoxin (LPS), associated or not with calcium hydroxide.

## MATERIAL AND METHODS

All animal procedures performed in this study were in agreement with the regulations of the Animal Care and Use Committee of the University of São Paulo.

In a laminar flow chamber, 100 mg of lyophilised *Escherichia coli* lipopolysaccharide (LPS) (Lipopolysaccharide B E. coli 055:B5 - Lipid A, 9.2%; Difco, Detroit, MI, USA) were suspended in 10 mL of phosphate buffered saline. Half of the 10 mg/mL suspension was kept in sterile Carpule syringes and other half was mixed with 2.75 g of calcium hydroxide p.a. (550 mg/mL; Merck KGaA, Darmstadt, Germany), and also kept in sterile Carpule syringes.

The 2nd, 3rd, and 4th mandibular premolars and the 2nd and 3rd maxillary premolars of 3 dogs (age: 12-18 months; weight: 8-15 kg) were selected for treatment, providing a total of 60 root canals. Twenty roots were allocated to each of the two experimental groups (groups I and II) and 10 roots were allocated to each of the control groups (groups III and IV). The teeth were randomly distributed among the groups.

The animals were anesthetized intravenously with sodium thiopental (Thionembatal; Abbot Laboratories, São Paulo, SP, Brazil; 30 mg/kg body weight) and standardized radiographs were taken. After isolation with a rubber dam and cleaning of the operative field with 2% chlorhexidine, crown occlusal access was made. The working length was determined 2 mm short

of the radiographic apex using a size 30 K-file. The root pulp was removed and the root canal was irrigated with saline (Labormédica Industria Farmacêutica Ltda., São José dos Campos, SP, Brazil) with a minimal volume of 3.6 mL at each instrument change. The apical foramen was enlarged by sequential use of size 15 to 30 K-files (Maillefer, Ballaigues, Switzerland) under constant saline irrigation. Instrumentation was then performed to the working length up to a size 50 K-file. A size 30 K-file was used at the total length of the root to make sure that no dentin chips or other debris were remained inside the apical foramen. After irrigation, the root canals were dried by aspiration and sterile paper points, and were filled with 14.3% buffered EDTA (pH 7.4; Odahcan-Herpo Produtos Dentários Ltda., Rio de Janeiro, RJ, Brazil) for 3 min and then irrigated with saline and dried.

Because all variables should be tested in the same animal and in the different quadrants, each hemiarch was submitted, in an alternate manner, to the experimental protocols. Group I: Twenty root canals were filled with 0.1 mL of the LPS solution by using a threaded syringe (S.S. White Artigos Dentários Ltda., Rio de Janeiro, RJ, Brazil) with a 27 gauge needle (Terumo, Tokyo, Japan); Group II: Twenty root canals were filled with 0.1 mL of the LPS plus calcium hydroxide suspension using a threaded syringe with a Calasept Kit needle (Nordiska Dental, Switzerland); Group III: Ten root canals were filled with saline using a Carpule syringe with a 27 gauge needle. After these procedures, the pulp chambers of groups I, II, and III were filled with a sterile cotton pellet and the teeth were sealed with zinc oxide-eugenol cement (IRM, S.S. White Artigos Dentários Ltda.) for a period of 30 days; Group IV: Ten root canals were exposed to the oral environment for 5 days to allow microbial contamination, after which, under general anesthesia, the pulp chamber was cleared of all debris, and sealed with a cotton pellet and zinc oxide-eugenol cement to induce chronic apical periodontitis.

In a standardized manner, radiographs had been taken at the beginning of the treatment (day 0) and new radiographs were taken 30 days after root canal filling. Custom-made film-holding devices were employed in all radiographic shots. A Heliodont dental x-ray machine (Siemens; Erlanger, Germany) was used with exposure parameters set at 60 kV, 10 mA and 0.4 s. Ultraspeed periapical film (Eastman Kodak, Rochester, NY, USA) was exposed and processed according to the time/

temperature method.

The images were digitized with an optical scanning process for transparencies (Scanjet 7450C; Hewlett-Packard; Palo Alto, CA, USA). The images were transferred to the Image J software (version 1.28 u, National Institutes of Health, Washington, DC, USA) for measurement and recording of results.

For each image pair, the radiolucent areas of apical periodontitis, when present, were demarcated (Fig. 1) and measured by three calibrates examiners. Delineation was performed on the radiographic image to excluded tooth structure, but included the area of bone rarefaction. The examiners were blinded to the groups the teeth belonged to.

### Statistical Analysis

Data are expressed as mean  $\pm$  standard error of

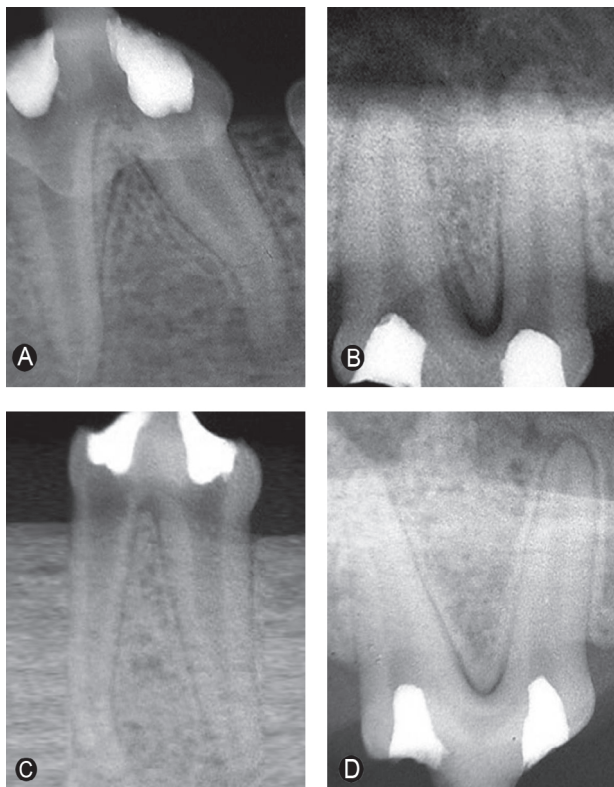


Figure 1. Radiographic images representative of the teeth submitted to the different treatments. A= Tooth filled with LPS (Group I); B= Periapical lesions induced with no canal treatment (Group IV); C= Tooth filled with saline (Group III); D= Tooth filled with LPS plus calcium hydroxide (Group II).

the mean. Statistical analyses were performed by one-way ANOVA followed by Tukey's test. A level of significance of 5% was chosen to denote the difference between group means. Data were analyzed using a GraphPad Prism statistic program (GraphPad Software; San Diego, CA, USA).

### RESULTS

The 20 roots of group I (LPS) presented radiographically visible apical periodontitis with loss of lamina dura integrity and extensive circumscribed areas of periapical bone resorption, with an average size of 8.44 mm<sup>2</sup>.

The lamina dura was intact and no areas of periapical bone resorption (periapical radiolucencies) were observed in any of the the 20 roots of group II (LPS plus calcium hydroxide) and or the 10 roots of group III (saline).

There was radiographically visible apical periodontitis in all 10 roots of group IV (lesion induced experimentally without root canal treatment), with loss of integrity of the lamina dura and extensive diffuse areas of bone resorption. Lesion average size was of 3.06 mm<sup>2</sup> in this group.

Loss of integrity of the lamina dura and periapical bone resorption were statistically similar in groups I and IV ( $p > 0.05$ ) and in groups II and III ( $p > 0.05$ ).

### DISCUSSION

In the present study, calcium hydroxide seemed to be able to preserve the lamina dura and avoid the occurrence of bone resorption 30 days after filling of dog's root canals with LPS associated with calcium hydroxide. Conversely, the control group which received LPS instead calcium hydroxide, a radiographically visible apical periodontitis in roots with loss of integrity of the lamina dura and extensive circumscribed areas of bone resorption was observed.

Although the role of bacteria in the etiology of apical periodontitis has already been established, little research has been done to evaluate the effect of LPS alone on apical and periapical tissues (7,8,10,15-17). The results of this study, using dog's teeth, are in agreement with those of previous investigations using cat teeth (10), monkey teeth (15) and dog's teeth as well (16,17). The present results are also consistent with

previous findings of our research group (7,8). These works (7,8) also found radiographically visible apical periodontitis with loss of lamina dura integrity and extensive circumscribed bone resorption areas 30 days after root canal filling with LPS. After 30 days, the lesions of group IV were not circumscribed (average size of 3.06 mm<sup>2</sup>). This may be due to the fact that lesion formation was caused by bacteria, their products and byproducts, such as hyaluronidase, collagenase, and indole, which act in the dissociation of fibers and the collagen matrix leading to a diffuse lesion. In group I, LPS possibly adhered to mineralized tissues (15), causing more localized extensive periapical bone resorption, with the average of 8.44 mm<sup>2</sup>.

Even after their death, Gram-negative bacteria release endotoxin. Thus, from a clinical viewpoint, the use of an intracanal medication that only cause bacterial death in the treatment of teeth with pulp necrosis and chronic apical periodontitis is not sufficient. Effective intracanal medications must also inactivate bacterial endotoxin. Safavi and Nichols (14) reported that calcium hydroxide hydrolyzes lipid A *in vitro* and that after lipid A hydrolysis, this highly toxic agent releases free-hydroxy fatty acids that are nontoxic (18). In the same research line, Barthel et al. (6) evaluated, *in vitro*, the capacity of endotoxin neutralization by calcium hydroxide and reported that LPS was inhibited by calcium hydroxide. This confirms the capacity of calcium hydroxide to inactivate endotoxin as reported in *in vitro* and *in vivo* studies (6-9,11).

In the present investigation, 30 days after filling the root canals of dog's teeth with a high concentration of LPS plus calcium hydroxide (group II), the lamina dura was intact and there was no bone resorption. Statistically similar results were found for teeth filled with saline (group III). These findings demonstrate that calcium hydroxide detoxifies the bacterial endotoxin *in vivo* and thus should be the medication of choice for intracanal dressings in teeth with pulp necrosis and apical periodontitis. The results of group III (saline) were similar to those reported elsewhere (10,15-17) with an intact lamina dura and absence of apical periodontitis.

Image J software was used for measuring and recording the area of radiographically visible periapical lesions. Several methods have been described to measure the size of periapical radiolucencies. New methods, such as semiautomated technique used in this study, can

be employed to increase the amount of information offered by the radiographs, thus making the evaluation more objective (19,20). Conventional radiographs were digitized to make the periapical radiolucencies more visible. An advantage of using digitized images is the possibility of altering brightness, contrast and gray-scale density, thereby allowing better viewing of the periapical lesion (20).

In conclusion, calcium hydroxide was effective in inactivating LPS, as demonstrated by the absence of apical periodontitis in the roots filled with bacterial endotoxin plus calcium hydroxide.

## RESUMO

O objetivo deste estudo foi quantificar radiograficamente a reabsorção óssea periapical em dentes de cães contaminados com endotoxina bacteriana (LPS), associadas ou não ao hidróxido de cálcio. Sessenta pré-molares foram divididos em 4 grupos e preenchidos com LPS (grupo 1), LPS e hidróxido de cálcio (grupo 2), solução salina (grupo 3), ou lesões periapicais foram induzidas sem tratamento (grupo 4), por um período de 30 dias e o Programa Image J foi empregado para mensuração das lesões, em mm<sup>2</sup>. Radiografias foram realizadas no início do tratamento e após 30 dias. Lesões periapicais foram observadas no grupo 1 (média de 8,44 mm<sup>2</sup>) e 4 (média de 3,02 mm<sup>2</sup>). A lâmina dura estava intacta e não foram observadas áreas de reabsorção óssea periapical nos grupos 2 e 3. Concluindo, a avaliação radiográfica quantitativa do efeito do LPS associado ao hidróxido de cálcio demonstrou que quando juntos a endotoxina bacteriana é inativada, uma vez que não foram observadas lesões periapicais nas raízes deste grupo experimental.

## REFERENCES

1. Sundqvist G. Ecology of the root canal flora. *J Endod* 1992;18:427-430.
2. da Silva LA, Nelson-Filho P, Faria G, de Souza-Gugelmin MC, Ito IY. Bacterial profile in primary teeth with necrotic pulp and periapical lesions. *Braz Dent J* 2006;17:144-148.
3. Siqueira Júnior JF, Rôças IN, Alves FR, Santos KR. Selected endodontic pathogens in the apical third of infected root canals: a molecular investigation. *J Endod* 2004;30:638-643.
4. Assed S, Ito IY, Leonardo MR, Silva LAB, Lopatin D. Anaerobic microorganisms in root canals of human teeth with chronic apical periodontitis detected by immunofluorescence. *Endod Dent Traumatol* 1996;12:66-69.
5. Rocha CT, Rossi MA, Leonardo MR, Rocha LB, Nelson-Filho P, Silva LA. Biofilm on the apical region of roots in primary teeth with vital and necrotic pulps with or without radiographically evident apical pathosis. *Int Endod J* 2008;41:664-669.
6. Barthel CR, Levin LG, Reisner HM, Trope M. TNF-alpha in monocytes after exposure to calcium hydroxide treated *Escherichia coli* LPS. *Int Endod J* 1997;30:155-159.
7. Silva LAB, Nelson-Filho P, Leonardo MR, Rossi MA, Pansani

- CA. Effect of calcium hydroxide on bacterial endotoxin *in vivo*. J Endod 2002;28:94-98.
8. Nelson-Filho P, Leonardo ML, Silva LAB, Assed S. Radiographic evaluation of the effect of endotoxin (LPS) plus calcium hydroxide on apical and periapical tissues of dogs. J Endod 2002;28:694-696.
  9. Jiang J, Zuo J, Chen SH, Holiday LS. Calcium hydroxide reduces lipopolysaccharide-stimulated osteoclast formation. Oral Surg Oral Med Oral Pathol Oral Radiol Endod 2003;95:348-354.
  10. Dwyer TG, Torabinejad M. Radiographic and histologic evaluation of the effect of endotoxin on the periapical tissues of the cat. J Endod 1981;7:31-35.
  11. de Oliveira LD, Jorge AO, Carvalho CA, Koga-Ito CY, Valera MC. *In vitro* effects of endodontic irrigants on endotoxins in root canals. Oral Surg Oral Med Oral Pathol Oral Radiol Endod 2007;104:135-142.
  12. Aibel K, Stevens R. Effect of chlorhexidine on IL-6 induction by LPS. J Endod 1999;25:282.
  13. Buttler TK, Crawford JJ. The detoxifying effect of varying concentrations of sodium hypochlorite on endotoxins. J Endod 1982;8:59-66.
  14. Safavi KE, Nichols FC. Effect of calcium hydroxide on bacterial lipopolysaccharide. J Endod 1993;19:76-78.
  15. Dahlén G, Magnusson BC, Moller A. Histological and histochemical study of the influence of lipopolysaccharide extracted from *Fusobacterium nucleatum* on the periapical tissues in the monkey *Macaca fascicularis*. Archs Oral Biol 1981;26:591-598.
  16. Pitts DL, Williams BL, Morton Jr TH. Investigation of role of endotoxin in periapical inflammation. J Endod 1982;8:10-18.
  17. Mattison GD, Haddix JE, Kehoe JC, Progulske-Fox A. The effect of *Eikenella corrodens* endotoxin on periapical bone. J Endod 1987;13:559-565.
  18. Safavi KE, Nichols FC. Alteration of biological properties of bacterial lipopolysaccharide by calcium hydroxide treatment. J Endod 1994;20:127-129.
  19. Pettiette MT, Delano O, Trope M. Evaluation of success rate of endodontic treatment performed by students with stainless-steel K-files and nickel-titanium files. J Endod 2001;27:124-127.
  20. De Rossi A, Silva LAB, Leonardo MR, Rocha LB, Rossi MA. Effect of rotatory or manual instrumentation, with or without a calcium hydroxide/1% chlorhexidine intracanal dressing, on the healing of experimentally induced chronic periapical lesions. Oral Surg Oral Med Oral Pathol Oral Radiol Endod 2005;99:628-636.

Accepted November 11, 2008