

Genital and lingual warts in small cetaceans from coastal Peru

Marie-Françoise Van Bressem^{1,2}, Koen Van Waerebeek¹, Gérald E. Piérard³,
Christian Desaintes⁴

¹Peruvian Center for Cetacean Research (CEPEC), Casilla 1536, Lima 18, Peru

²Department of Immunology and Vaccinology, Faculty of Veterinary Medicine, University of Liège, B43-R80, Sart Tilman, B-4000 Liège, Belgium

³Department of Dermatopathology, CHU Sart Tilman, B-4000 Liège, Belgium

⁴Department of Molecular Biology, Free University of Brussels, 67 rue des Chevaux, B-1640 Rhode St-Genèse, Belgium

ABSTRACT: We report on genital warts in dusky dolphins *Lagenorhynchus obscurus*, long-snouted common dolphins *Delphinus capensis*, bottlenose dolphins *Tursiops truncatus* and Burmeister's porpoises *Phocoena spinipinnis* caught in fisheries off central Peru. Lesions were observed inside the genital slit, on the skin adjacent to it, on the penis and on the vagina. Macro- and microscopical features of the lesions resemble those of benign genital warts associated with papillomavirus infection in humans. Genital warts from *L. obscurus* and *P. spinipinnis* contained nuclei which stained positive for genus-specific papillomavirus structural antigens, though weakly in the latter species. These data suggest that papillomavirus(es) may be the etiological agent(s) of the disease. The prevalence of the lesions in 130 small cetaceans was high: 66.7% (confidence interval, CI, 57.0 to 74.0%) in *L. obscurus* (n = 78), 50% in *D. capensis* (n = 10), 33% in *T. truncatus* (n = 9) and 48.5% (CI 33.0 to 64.0%) in *P. spinipinnis* (n = 33). This suggests a venereal transmission of the disease, as in humans. Sexual variation in wart prevalence was found in *L. obscurus* and *P. spinipinnis* with males being 2 and 3 times more infected than females, respectively. No correlation was observed between body length (as a measure of age) and wart prevalence, suggesting that no strong and long-lasting immunity was induced in affected animals or that they may have been infected by different types of papillomaviruses. Lingual tumours were seen in 1 *D. capensis*.

KEY WORDS: Papillomavirus · Warts · Venereal disease · Epidemiology · Dusky dolphin · Common dolphin · Bottlenose dolphin · Burmeister's porpoise · SE Pacific · Peru

INTRODUCTION

Warts and papillomas consist of localized epithelial hyperplasia with a defined boundary and an intact basement membrane (Shah & Howley 1990). Widely variable in their clinical appearance, they are often caused by papillomaviruses which are small (typically 55 nm diameter), non-enveloped DNA viruses classified in the family Papovaviridae (for review see Shah & Howley 1990).

In humans, over 70 different types of papillomaviruses (HPVs) have been identified, about one third of them infecting the ano-genital tract and generally venereally transmitted. Ano-genital tumours caused by HPVs are usually benign but may progress to

malignancy if the virus type infecting the cells has a high risk for tumorigenicity (for reviews see Howley 1990, De Villiers et al. 1994).

In other mammals, warts have mostly been observed on the skin although they may occur on the mucosa of the respiratory, digestive and genital tracts (for review see Sundberg 1987, Howley 1990). Genital papillomas have been well documented in colobus monkey *Colobus guereza* and rhesus monkey *Maccaca mulatta* and are venereally transmitted in the latter species (O'Bannon et al. 1987, Ostrow et al. 1990, Reszka et al. 1991).

In cetaceans, penile papillomas associated with papillomavirus-like particles have been observed in 3 of 31 (9.7%) sperm whale *Physeter macrocephalus*

bulls caught off the west coast of Iceland in 1981–1982 (Lambertsen et al. 1987). Ano-genital and buccal papillomas and fibropapillomas (epithelial hyperplasia accompanied by proliferation of the dermal components) have been reported from 3 other species of odontocetes and 1 baleen whale (see Table 1), however the viral etiology has not been confirmed in any of these (Greenwood et al. 1974, Geraci et al. 1987).

Here we report on genital and lingual warts, which resemble papillomavirus infection, in dusky dolphin *Lagenorhynchus obscurus*, long-snouted common dolphin *Delphinus capensis*, bottlenose dolphin *Tursiops truncatus*, offshore stock (sensu Van Waerebeek et al. 1990) and Burmeister's porpoise *Phocoena spinipinnis* caught in direct and incidental fisheries off Peru (Van Waerebeek & Reyes 1994, Van Waerebeek et al. 1994, 1995).

MATERIALS AND METHODS

Seventy-eight dusky dolphins (35 females, 43 males), 10 long-snouted common dolphins (all males), 9 offshore bottlenose dolphins (1 female, 8 males) and 33 Burmeister's porpoises (13 females, 20 males) were examined for genital tumours at the ports of Pucusana and Cerro Azul on the central Peruvian coast, between September 1993 and March 1995. Moreover, 21 dusky dolphins (8 females, 13 males), 2 male common dolphins, 2 male bottlenose dolphins and 6 porpoises (1 female, 5 males) were checked for the presence of lingual warts. The cetaceans typically became entangled in drift or set gillnets and asphyxiated less than 12 h before they were examined.

For epidemiological purposes, a random succession of animals was examined to avoid a possible bias towards positive specimens. Difficult field conditions often made it impossible to check all of the cetaceans landed. Specimens were considered negative for genital tumours only if the entire genital tract (genital slit and adjacent skin, vagina and uterus or penis and penile sheath; Fig. 1) had been examined. Occasionally, dolphins were noted as positive as soon as lesions were seen on the skin or the mucosa of the genital slit, which explains differences in sample sizes between body locations. With 'genital slit' in males we refer to the mucosa of both the slit *sensu stricto* and the contiguous penile sheath. With 'skin or cutaneous warts' we mean the lesions observed on the skin adjacent to the genital slit, while 'mucosal warts' refers to the lesions observed on the mucosa of the genital slit, penis or vagina.

Samples sufficiently large for statistical analysis were available only for *Lagenorhynchus obscurus* and *Phocoena spinipinnis*. Before studying sexual variation

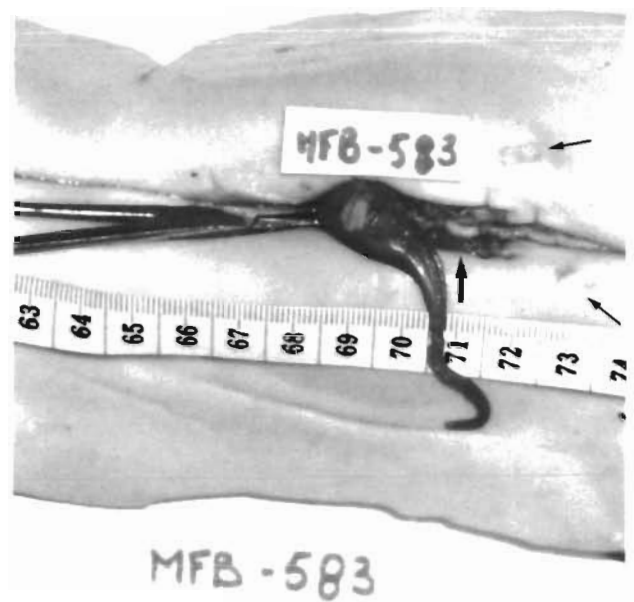


Fig. 1. *Lagenorhynchus obscurus*. Warts inside the genital slit (large arrow), adjacent skin (small arrows), and on the penis of a dusky dolphin (MFB-583)

in wart prevalence, standard length distributions of male and female samples were compared by Kolmogorov-Smirnov 2-sample tests (K-S; Hollander & Wolfe 1973). To determine if the prevalence of warts was linked to standard length (as a measure of age), we divided the animals into 2 (*P. spinipinnis*) or 3 (*L. obscurus*) length classes, depending on the sample size. It is estimated that 50% of *L. obscurus*, in both sexes, attain sexual maturity at 175 cm (Van Waerebeek 1992). Male and female *P. spinipinnis* reach maturity at 155 and 160 cm respectively (Reyes & Van Waerebeek in press). Thus, most animals in the size classes 159 to 174.5 cm (*L. obscurus*) and 129 to 154.5 cm (*P. spinipinnis*) were sexually immature.

To assess sample comparability for interspecific variation in wart prevalence, standard length distributions, adjusted to respective maximum body lengths, were subjected to K-S tests. Maximum recorded lengths in Peruvian populations are: 210 cm for *Lagenorhynchus obscurus* (Van Waerebeek 1992, 1993), 183 cm for *Phocoena spinipinnis* (Reyes & Van Waerebeek 1995) and 258 cm in *Delphinus capensis* (Van Waerebeek et al. 1994).

Exact 95% confidence intervals (CI) for proportions were computed based on a relationship between the *F* and binomial distributions (Fisher & Yates 1963, Zar 1984). Differences in prevalence of infection were verified with chi-squared contingency tests or 2-tailed

Fisher's exact tests (the latter for 2-by-2 matrices with $n < 100$). Statistical significance was set at $\alpha = 0.05$.

Selected lesions were measured and photographed. Typical warts from each species were excised and fixed in 10% formaldehyde, dehydrated in a graded series of ethanol and embedded in paraffin. Tissue sections 5 to 7 μm thick were stained with hematoxylin and eosin for histologic examination. Immunohistochemical staining, to detect papillomavirus group specific antigens, was realized on formal fixed warts by the peroxidase anti-peroxidase (PAP) technique, using a rabbit antiserum against SDS-disrupted bovine papillomavirus-1 virions (Dakopatts, CA, USA), as described by Sundberg et al. (1984). Negative controls consisted of samples of healthy genital mucosa for each species, or of negative rabbit serum used as a primary antibody.

Preparations of fresh genital warts from the 4 species were negatively stained with uranylacetate and post-fixed with osmium tetroxide. Samples were examined with a Siemens 102 transmission electron microscope (Berlin, Germany) at 100 kV.

RESULTS

General clinical features

We found genital warts on the skin bordering the genital, anal and mammary slits, on the mucosa inside the genital slit, the vagina and the penis (Fig. 1), but not on the cervix nor in the uterine horns. Cutaneous lesions were white, light or dark grey, in concordance with the local skin colour. Slightly raised and oval, they sometimes projected inside the genital slit where their morphology resembled mucosal warts. The latter stood out in relief, were oval or circular and generally showed an irregular folded or velvety surface. Their colour was white, gray, black or pinkish. Bicoloured warts were observed in some cases.

The size of the cutaneous warts in 4 animals ranged from 8 \times 4 mm to 20 \times 15 mm ($n = 4$) while that of the mucosal lesions in 24 cetaceans varied between 3 \times 3 mm and 20 \times 15 mm ($n = 46$).

The pinkish, lingual warts were distributed at the base, top and sides of the tongue and measured between 2 \times 2 mm and 26 \times 14 mm ($n = 5$; Fig. 2). The biggest two had wrinkled surfaces while the remaining ones were smooth.

Histological features of the lesions and virus detection

Genital warts

The histological features of the lesions were as follows. A sharply limited epithelial hyperplasia affected the *stratum spinosum* (Fig. 3) in all samples of the 4 species. The *stratum externum* was also thickened in the lesions of *Delphinus capensis*, *Tursiops truncatus*, and *Phocoena spinipinnis* although not in all samples. Some hyperplasia was observed at the tip of the epithelial rete ridges in *P. spinipinnis*. Koilocytosis or cytoplasmic perinuclear vacuolization of the cells, a common feature of many papillomavirus-induced lesions (Shah & Howley 1990), was observed in *Lagenorhynchus obscurus*, *P. spinipinnis* and *T. truncatus* (Fig. 4). In the latter species it was seen in only 1 of the 2 animals examined and at a low density. It was not seen in the lesions of 2 *D. capensis*. No cytoplasmic inclusions were noted. The dermal papillae were elongated but not truly hyperplastic in most samples (Fig. 3). In the 4 species, lymphocyte infiltration occurred in the dermis of the warts in most but not all cases. We refer to the lesions as warts and not papillomas (Table 1), which are characterized by hyperplasia of papillae.

The *strata spinosum* and *externum* contained nuclei which stained positive for genus-specific papillomavirus structural antigens (Fig. 5) in warts from 2 of 3 *Lagenorhynchus obscurus*. The staining was often more intense in the upper layers of the *stratum spinosum* but was absent in the adjacent healthy epithelium. A weak positive staining was discerned in nuclei of warts of 2 of 4 *Phocoena spinipinnis*. Papillomavirus

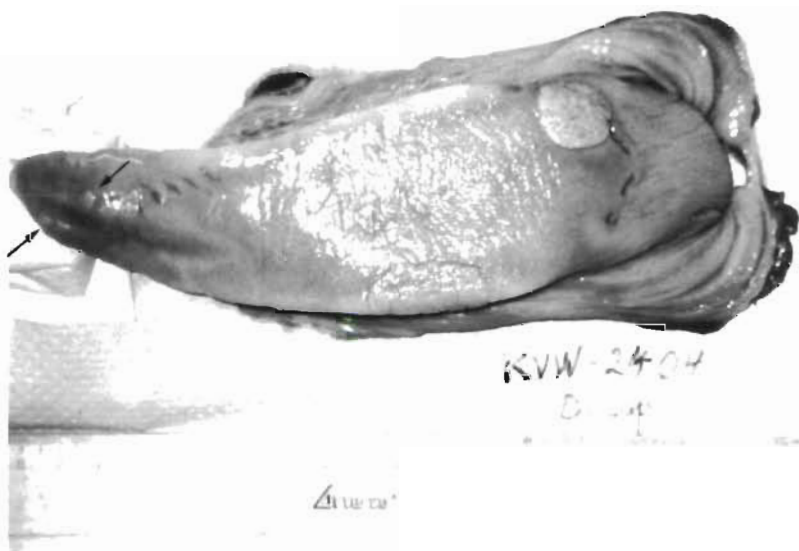

Fig. 2. *Delphinus capensis*. Warts on the tongue of a long-beaked common dolphin (KVV-2404); arrows indicate smaller lesions

Table 1. Overview of reported hyperplastic epithelial and fibroepithelial lesions in cetaceans from the world oceans. Location of the lesions, histology and papillomavirus (PV) detection methods (ICS: immunohistochemical staining; EM: electron microscopy) are indicated. ND: not described or not done; L: lingual; P: pharyngeal; NC: negative contrast preparation; UT: ultrathin preparation

Species Common name	Scientific name	Ocean province	Location		Histology	PV detection		Source
			Genital	Cutaneous		ICS	EM	
Hareour porpoise	<i>Phocoena phocoena</i>	Unknown	x		Undetermined	ND	ND	Landy (1980) cited in Geraci et al. (1987)
Burmeister's porpoise	<i>Phocoena spinipinnis</i>	NW Atlantic	x	x	Papilloma	ND	Yes (UT)	Geraci et al. (1987)
Killer whale	<i>Orcinus orca</i>	SE Pacific	x		Wart	Yes (weak)	No (NC)	This paper
Atlantic white-sided dolphin	<i>Lagenorhynchus acutus</i>	Unknown		x	Papilloma	ND	No	Greenwood et al. (1974)
		Unknown (captive)	x		Undetermined	ND	ND	Uys & Best (1966) cited in Greenwood et al. (1974)
		Unknown (captive)	x		Papilloma	ND	ND	Geraci et al. (1987)
Dusky dolphin	<i>Lagenorhynchus obscurus</i>	NW Atlantic	x		Fibropapilloma	ND	ND	Geraci et al. (1987)
		NW Atlantic			Fibropapilloma	ND	ND	Geraci et al. (1987)
Common dolphin	<i>Delphinus sp.</i>	SE Pacific	x		Wart	Yes	No (NC)	This paper
Long-snouted common dolphin	<i>Delphinus capensis</i>	SE Pacific	x		Wart	No	No (NC)	Sundberg et al. (1984)
		SE Pacific			Wart	No	No (NC)	This paper
Bottlenose dolphin	<i>Tursiops truncatus</i>	SE Pacific	x		Wart	No	No (NC)	This paper
Narwhale	<i>Monodon monoceros</i>	Arctic		x	Papilloma	ND	ND	Geraci et al. (1987)
Sperm whale	<i>Physeter macrocephalus</i>	NE Atlantic	x		Papilloma	No	Yes (UT)	Lambertsen et al. (1987)
Blue whale	<i>Balaenoptera musculus</i>	Unknown			Papilloma	ND	ND	Rawell & Willis (1949) cited in Geraci et al. (1987)

antigens could not be detected in the lesions of 2 *Delphinus capensis* nor of 2 *Tursiops truncatus*.

No viral particles were seen by electron microscopy (EM) in negative contrast preparations of fresh warts (Dr D. Dekegel & G. Van Heule pers. comm.; Table 1).

Lingual warts

The histological structure of the lingual tumours differed somewhat from that of the genital lesions. Epithelial hyperplasia uniformly affected the 3 strata (acanthosis). Neither koilocytosis nor cytoplasmic inclusions were visible. The dermal papillae were short.

Convincing immunoreactivity for genus-specific papillomavirus structural antigens was not detected in these lesions.

Epidemiology

Lagenorhynchus obscurus

Of 78 dusky dolphins examined, 52 (66.7%, CI 57.0 to 74.0%) suffered from genital warts. Body length histograms of male and female samples were fully comparable ($K-S = 0.73$, $DN = 0.17$, $p = 0.66$). Genital tumours were twice as prevalent in males as in females (Table 2), indicating a significant sexual variation (Fisher's test, $p < 0.0001$). Prevalence seemed to be independent of body length, both in females ($\chi^2 = 4.48$, $df = 2$, $p > 0.1$) and males ($\chi^2 = 0.55$, $df = 2$, $p > 0.5$) (Table 3), but we recommend reconfirmation with a larger sample. The smallest dolphin examined, a 159 cm male, was positive but sexually immature (deduced from its size).

The locations of the lesions are presented in Table 4. In males, the lesions occurred more often inside the genital slit (including penile sheath) than on the skin bordering the slit or on the penis ($\chi^2 = 40.1$, $df = 2$, $p < 0.001$). The female sample also suggested a higher incidence inside the genital slit, although not significantly so ($\chi^2 = 2.46$, $df = 2$, $p > 0.1$), possibly due to small sample size. In most dusky dolphins (81% of 11 females, 73% of 26 males), warts developed at a unique location. Some animals showed lesions both inside the genital slit and surrounding skin or in the genital slit and on the penis; one male had warts on the skin, genital slit and penis (Fig. 1).

On the skin around the slit, the modal condition was a single wart (6 males, 3 females) with only 2 males showing 2 lesions. An average of 1.6 (standard deviation, $SD = 0.8$, range 1 to 4) and a median number of 1 (range 1 to 3) mucosal lesions were present in 37 males and 12 females, respectively. We did not find any lingual warts in *Lagenorhynchus obscurus* ($n = 21$).

Fig. 3. *Tursiops truncatus*. Low power view of the border of a penile wart in a bottlenose dolphin (KOS-284) with marked hyperplasia of the 3 epithelial layers and elongation of the dermal papillae. Scale bar = 50 µm




Fig. 4. *Phocoena spinipinnis*. Clustered koilocytes (arrows) in the upper part of the epithelium of a genital lesion in a Burmeister's porpoise (MFB-604). Scale bar = 10 µm

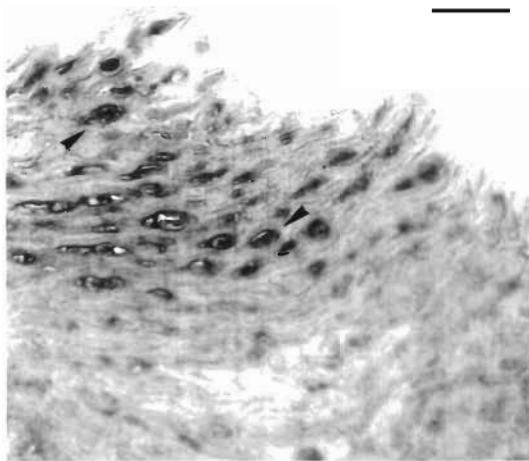
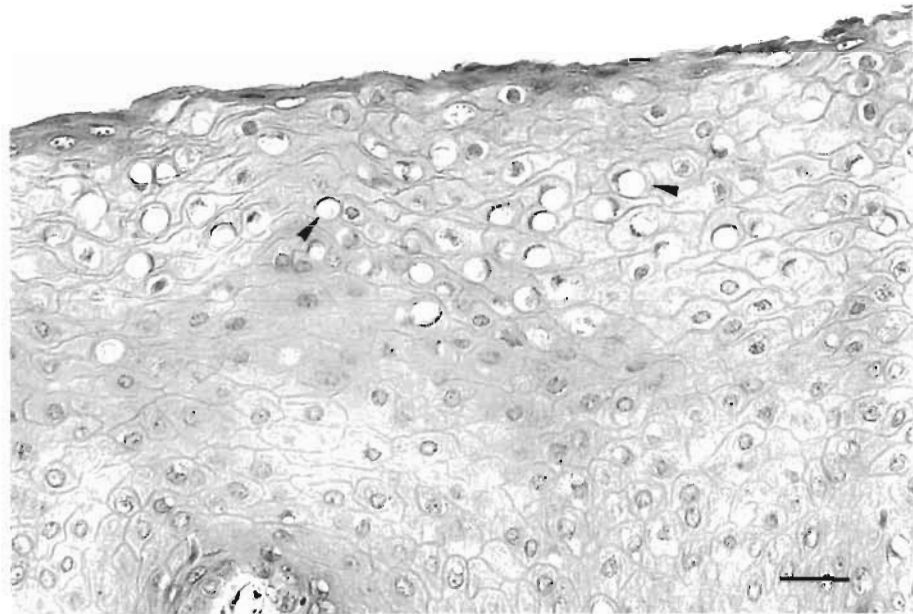


Fig. 5. *Lagenorhynchus obscurus*. Cluster of positively stained cells (arrows), revealed by PAP technique, in the upper part of the epithelium of a genital slit wart in a dusky dolphin. Scale bar = 10 µm

Delphinus capensis

Of 10 male long-snouted common dolphins examined for genital warts, half suffered the disease regardless of sexual maturity (Table 5). One of 2 dolphins examined for lingual warts had 5 lesions on the upper surface of its tongue (Table 5, Fig. 2). That animal was free of warts on the skin adjacent to the genital slit and on the penis.

Tursiops truncatus

Of the 8 male bottlenose dolphins studied, 3 showed penile warts (Table 6). Both sexually mature and immature dolphins were affected. The only female bottlenose dolphin available was free of genital tumours. No lingual lesions were found in 2 dolphins.

Table 2. Sexual variation in prevalence of genital warts in dusky dolphin (*Lagenorhynchus obscurus*) and Burmeister's porpoise (*Phocoena spinipinnis*) from Peru. Number of cetaceans examined (Nex), number with warts (Nw), percentage prevalence (% prev.) and 95% confidence intervals (CI) are indicated

Species	Females				Males			
	Nex	Nw	% prev.	95% CI	Nex	Nw	% prev.	95% CI
<i>Lagenorhynchus obscurus</i>	35	15	42.9	26.2-60.7	43	37	86.0	72.1-94.7
<i>Phocoena spinipinnis</i>	13	3	23.1	5.0-53.8	20	13	65.0	40.8-84.6

Table 3. Prevalence of genital warts according to body size and sex in dusky dolphin (*Lagenorhynchus obscurus*) and Burmeister's porpoise (*Phocoena spinipinnis*) from Peru. Number of cetaceans examined (Nex), number with warts (Nw), percentage prevalence (% prev.) and 95% CI, where meaningful, are indicated

Species	Size class (cm)	Females				Males			
		Nex	Nw	% prev.	95% CI	Nex	Nw	% prev.	95% CI
<i>Lagenorhynchus obscurus</i>	All sizes	35	15	42.9	26.2-60.7	43	37	86.0	72.1-94.7
	159-174.5	8	3	37.5	-	16	14	87.5	61.7-98.5
	175-184.5	12	8	66.67	34.9-90.1	11	10	90.9	58.8-99.8
	>185	15	4	26.67	7.8-55.1	16	13	81.25	50.0-99.5
<i>Phocoena spinipinnis</i>	All sizes	13	3	23.1	5.0-53.8	20	13	65.0	40.8-84.6
	129-154.5	9	3	33.3	-	7	3	42.86	-
	155-176	4	0	0	-	13	10	76.92	-

Table 4. Prevalence of warts on the skin bordering the genital slit, inside the slit, on the vagina or on penis in positive dusky dolphin (*Lagenorhynchus obscurus*) and Burmeister's porpoise (*Phocoena spinipinnis*) from Peru. Number of positive cetaceans examined for a particular location (Nex), number of specimens with warts at this location (Nw), percentage prevalence (% prev.) and 95% CI, where meaningful (usually samples >15), are indicated

Species	Location	Females				Males			
		Nex	Nw	% prev.	95% CI	Nex	Nw	% prev.	95% CI
<i>Lagenorhynchus obscurus</i>	Skin	14	4	28.6	-	33	7	21.2	9.0-39.0
	Genital slit	15	9	60	32.3-83.7	37	33	89.2	74.6-97.0
	Vagina/penis	11	4	36.36	-	30	8	26.7	12.3-45.9
<i>Phocoena spinipinnis</i>	Skin	2	0	-	-	13	1	7.7	0.2-36.0
	Genital slit	3	2	-	-	13	10	76.9	-
	Vagina/penis	2	1	-	-	12	7	58.3	-

Phocoena spinipinnis

Of 33 Burmeister's porpoises examined, 16 (48.5%, CI 33.0 to 64.0%) had genital warts. Male and female samples showed similar standard length distributions (K-S = 1.09, DN = 0.39, $p = 0.19$). The frequency of the lesions was significantly correlated with the sex of the animals (Fisher's test, $p = 0.019$), with males being almost 3 times more prone to the disease than females (Table 2).

Fisher's tests revealed no significant variation in infection between the 2 defined length classes (Table 3), either in males ($p = 0.13$) or females ($p = 0.29$), however, this should be corroborated with a bigger sample. The smallest positive specimen was a 136.5 cm sexually immature female (deduced from body size).

Data on the location of warts are shown in Table 4. A limited sample hinted that in males, lesions may develop more often in the genital slit or on the penis than on the skin ($\chi^2 = 13.4$, $df = 2$, $p < 0.01$). Of 12 positive males, 4 had warts both inside the genital slit and on the penis. Lesions were observed at a single location in 7 of 10 males.

One porpoise had 2 cutaneous warts. A median number of 2 (range 1 to >10) mucosal lesions was observed in 17 males. In 1 of 2 males with numerous penile warts (>10), seaweed was lodged internally in the space between the affected penis and its sheath which almost impeded the penis from being pulled out (Fig. 6).

Six porpoises examined for lingual tumours were negative.

Table 5. *Delphinus capensis*. Presence (Pres) of warts in male long-snouted common dolphins caught off central Peru in 1994, with standard length (SL) and sexual maturity (SM: IMM is immature, MAT is mature) of specimens examined. Location of genital warts on the skin bordering the genital slit (Skin), inside the slit (Slit) or on the penis is indicated. Where known, the number of warts is given otherwise only their confirmed presence. NE: not examined

Number	Locality	Date	SL (cm)	SM	Pres	Genital warts			Lingual warts
						Skin	Slit	Penis	Pres
MFB 676	Cerro Azul	9 June	197	IMM	Yes	Yes	No	No	NE
KOS 306	Cerro Azul	7 July	200	IMM ^a	Yes	NE	1	No	NE
MFB 507	Cerro Azul	17 May	200.5	IMM	No	No	No	No	NE
MFB 675	Cerro Azul	9 June	200.5	IMM	No	No	No	No	NE
KOS 307	Cerro Azul	7 July	203	IMM	Yes	NE	3	No	NE
MFB 511	Cerro Azul	18 May	204.5	IMM	No	No	No	No	NE
MFB 510	Cerro Azul	18 May	207	IMM	No	No	No	No	NE
MFB 508	Cerro Azul	17 May	210.5	IMM	No	No	No	No	NE
KOS 291	Cerro Azul	7 July	212	IMM ^a	Yes	NE	No	1	NE
KVW 2404	Pucusana	31 May	228.5	MAT	NE	No	NE	No	5
MFB 529	Cerro Azul	22 May	240.5	MAT	Yes	1	1	No	NE
KVW 2403	Pucusana	31 May	241	MAT	NE	No	NE	No	No

^aMaturity of specimen deduced from body length

Table 6. *Tursiops truncatus*. Presence (Pres) of genital papillomas in bottlenose dolphins caught off Peru in 1994–1995, with sex, standard length (SL), sexual maturity (SM: IMM is immature, MAT is mature) and date of examination. Location of genital warts on the skin bordering the genital slit (Skin), inside the slit (Slit), on the penis (Pen) or the vagina (vag) is indicated. Where known, the number of papillomas is given, otherwise only their confirmed presence. NE: not examined

Number	Locality	Sex	SL (cm)	SM	Date	Pres	Genital warts			Lingual warts
							Skin	Slit	Pen/vag	Pres
KVW 2417	Pucusana	M	216	IMM ^a	29 Mar 95	Yes	NE	No	2	No
KOS 284	Cerro Azul	M	240	IMM ^a	7 Jul 94	Yes	NE	No	1	NE
MFB 533	Cerro Azul	M	262.5	IMM	26 May 94	No	No	No	No	NE
MFB 702	Cerro Azul	F	272	MAT	10 Jun 94	No	No	No	No	NE
MFB 701	Cerro Azul	M	272.5	IMM	10 Jun 94	No	No	No	No	NE
MFB 532	Cerro Azul	M	294	MAT	26 May 94	Yes	No	No	3	NE
MFB 616	Cerro Azul	M	295	IMM	15 Jun 94	No	No	No	No	NE
MFB 608	Cerro Azul	M	303.5	MAT	15 Jun 94	No	No	No	No	NE
KVW 2412	Pucusana	M	316	MAT ^a	17 Feb 95	No	No	No	No	No

^aMaturity of specimen deduced from body length

Interspecific variation

Pair-wise comparisons in genital wart prevalence between the species discussed below were legitimate because standard length distributions, adjusted to respective maximum lengths, were sufficiently similar (K-S tests, $p > 0.05$).

The male samples suggested a higher prevalence of genital warts in *Lagenorhynchus obscurus* (86%) than in *Delphinus capensis* (50%; Fisher's, $p = 0.023$) and possibly *Phocoena spinipinnis* (65%, Fisher's, $p = 0.09$). In female samples, the trend of higher prevalence in *L. obscurus* (43%) compared to *P. spinipinnis* (23%) was also seen, but could not be confirmed statistically (Fisher's, $p = 0.36$). Given the small samples of *P. spinipinnis* and *D. capensis*, chances are that the observed differences were really significant but failed to be demonstrated (β -error).

The median number of lesions per infected specimen was higher in porpoises than in dusky dolphins (Mann-Whitney U -test, $Z = 2.05$, $p < 0.05$). Furthermore, only in porpoises did we register a high number (>10) of penile tumours.

While sample comparability could not be verified, the overall prevalence of penile papillomas in sperm whales from Iceland (9.7%, $n = 31$), as reported by Lambertsen et al. (1987), appears to be considerably lower than the levels found in dusky dolphins and Burmeister's porpoises ($\chi^2 = 11.1$, $df = 2$, $p = 0.004$).

DISCUSSION

The present epidemiological data indicate that genital warts are widespread in small odontocetes from Peruvian coastal waters. Macro and microscopical fea-

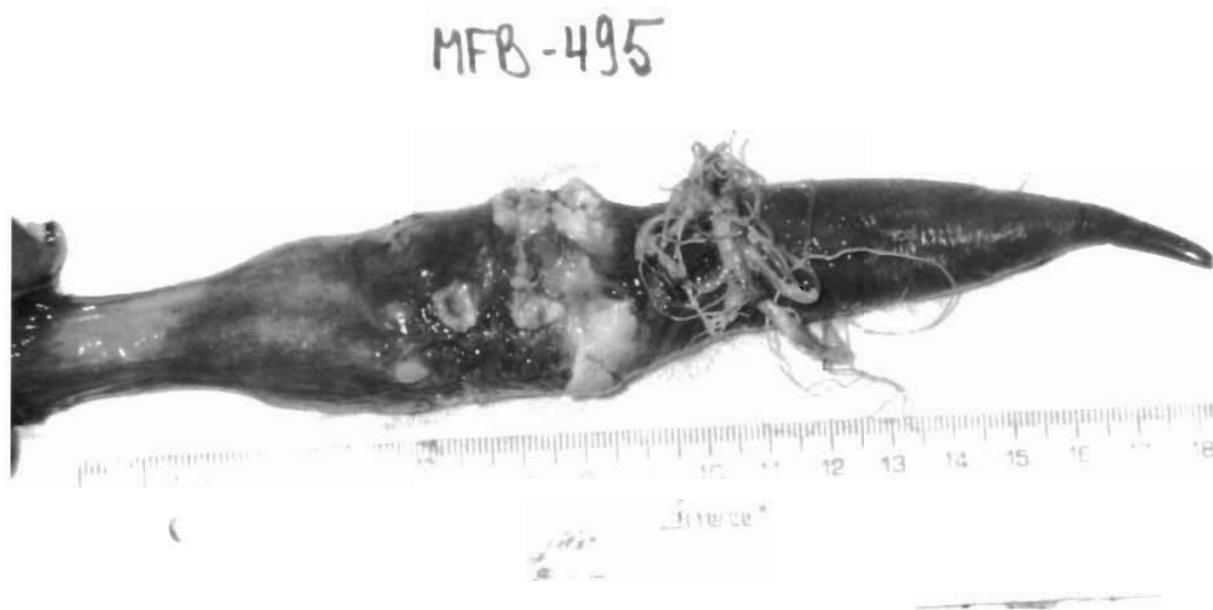

Fig. 6. *Phocoena spinipinnis*. Extensive warty lesions on the penis of a Burmeister's porpoise (MFB-495) with seaweed lodged between the penis and its sheath

tures of the lesions resemble those of benign genital papillomas in humans. The epithelial hyperplasia, the presence of koilocytes and the detection of genus-specific papillomavirus structural antigens in some samples suggest that papillomavirus(es) may be the etiological agent(s) of the disease. A non-productive state of the infection could explain the negative results in the other samples as the immunohistochemical staining for papillomavirus structural antigens only detect productive infection. In humans the antigen is detected in only about 50% of histologically evident lesions (Koutsky et al. 1988). Alternatively, the papillomavirus(es) of these cetacean species could represent (an)other virus type(s) not recognized by the antisera, as described for several HPVs (see Koutsky et al. 1988). Thus, genus-specific papillomavirus antigens were detected in neither cutaneous nor penile papillomas of *Delphinus* sp. (Sundberg et al. 1984) and *Physeter macrocephalus* (Lambertsen et al. 1987) respectively, although intranuclear virus particles were observed by EM in the latter.

The failure to demonstrate virus particles by EM in negatively stained preparations of the warts of Peruvian dolphins and porpoises may be related to a low density of virus particles. In human genital papillomas, viral particles are also notoriously difficult to demonstrate (Shah & Howley 1990). Nevertheless, virological and molecular studies are necessary to further elucidate the etiology of the genital and oral tumours found in Peruvian odontocetes.

The genital location of the warts and their high prevalence in the dolphins and porpoises studied

strongly suggest a venereal transmission of the disease, as is the case in humans (Barrett et al. 1954, Oriol 1971). The remarkably high frequency of genital warts and their occurrence in gonadal immature but sexually active animals may well be related to the high level of sexual activity exhibited by delphinids. This includes homosexual behaviour, wide spread sexual activity by juveniles, and even intergeneric mating (Brown et al. 1966, Würsig & Würsig 1979, Wells et al. 1987, Morris & Lockyer 1988). Vertical transmission, i.e. transmission from the mother to the infant during pregnancy or at birth, is described in humans (Koutsky et al. 1988) and could also account for some lesions observed in very young dolphins and porpoises.

The highest prevalence of genital warts was observed in male dusky dolphins (86%). Interestingly, the mating system of this species has recently been defined as promiscuous, i.e. several males may mate with each female at the same oestrus (Van Waerebeek 1992, Van Waerebeek & Read 1994). Assuming a venereal transmission, such a mating system would favour a high prevalence of genital tumours. In humans, genital papillomas also occur predominantly in promiscuous populations (Oriol 1971, Koutsky et al. 1988).

The lower prevalence (9.7%) of penile papillomas in sperm whales (Lambertsen et al. 1987) could be related to its polygynous mating system where many sexually maturing males are excluded from breeding by older, dominant males which monopolize females (Oshumi 1971, Best 1979). However, it is unclear

whether Lambertsen et al. (1987) examined the genital slit and the adjacent skin of the whales and therefore whether their prevalence of genital lesions, as defined here for the small cetaceans, is comparable.

In *Lagenorhynchus obscurus* and *Phocoena spinipinnis*, the 2 species for which sufficient data were available, males were 2 times more likely to be affected with visible tumours than females. The reasons for this variation are unknown but hormonal and behavioral differences may play a role.

Although the lowest wart prevalence was observed in the largest (oldest) females (*Lagenorhynchus obscurus* and *Phocoena spinipinnis*), there was no evidence of any dependency on length classes (as a measure of age) in any of the 4 species. This may suggest that the infection does not induce a strong, long-lasting immunity and that subsequent reinfections occur due to frequent sexual contacts. Alternatively the lesions could persist for weeks or months possibly because of a minimal immune response to infected cells, as has been advanced for HPV infections in humans (see Shah & Howley 1990). Finally, different types of the same virus could successively infect the dolphins and porpoises, thus circumventing immunity induced against other types. However, further studies encompassing a larger number of specimens should be carried out before any definitive conclusions can be drawn.

The warts were regularly found at several sites in the genital tract of dolphins and porpoises, as in HPV infected humans (Rudlinger et al. 1986). Extensive lesions (>10) were present in 2 porpoises. Similar clinical findings are known from the sperm whale (Lambertsen et al. 1987) and from humans (Oriol 1971). In extreme cases (e.g. MFB-495), the reproductive success of the animals may be compromised.

Acknowledgements. We warmly thank the following persons for their help: Joanna Alfaro, Ruth Bello, Aquiles García-Godos, David Montes and Karina Ontón for field assistance; Mrs Godelieve Van Heule and Dr D. Dekegel for electron microscopic examination of the samples; Dr Jorge Arrese and Stéphane Pierre for technical assistance with histology and immunochemistry; Drs Paul-Pierre Pastoret, Arsène Burny and Gérard Orth for stimulating discussions, the latter also for critical reading of the manuscript.

LITERATURE CITED

- Barrett TJ, Silbar JD, McGinley JP (1954) Genital warts—a venereal disease. *J Am Med Assoc* 154:333–336
- Best PB (1979) Social organization in sperm whales. In: Winn HE, Olla BL (eds) *Behavior of marine animals, Vol 3, Cetaceans*. Plenum Press, New York, p 227–289
- Brown DH, Caldwell DK, Caldwell MC (1966) Observations on the behavior of wild and captive false killer whales, with notes on associated behavior of other genera of captive delphinids. *Contr Mar Sci* 95:1–32
- De Villiers EM (1994) Human pathogenic papillomavirus types: an update. In: zur Hausen H (ed) *Human pathogenic papillomaviruses*. Springer-Verlag, London, p 1–12
- Fisher RA, Yates F (1963) *Statistical tables for biological, agricultural, and medical research*, 6th edn. Hafner, New York
- Geraci JR, Palmer NC, St Aubin DJ (1987) Tumors in cetaceans: analysis and new findings. *Can J Fish Aquat Sci* 44:1289–1300
- Greenwood AG, Harrison RJ, Whitting HW (1974) Functional and pathological aspects of the skin of marine mammals. In: Harrison RJ (ed) *Functional anatomy of marine mammals*. Academic Press, New York, p 73–110
- Hollander M, Wolfe DA (1973) *Nonparametric statistical methods*. Wiley, New York, p 503
- Howley P (1990) Papillomaviruses and their replication. In: Fields BN, Knippe DM, Channock RM, Hirsch MS, Monath TP, Roizman B (eds) *Virology*, 2nd edn. Raven Press, New York, p 1625–1650
- Koutsky LA, Galloway DA, Holmes KK (1988) Epidemiology of genital human papillomavirus infection. *Epidemiol Rev* 10:122–163
- Lambertsen RH, Kohn B, Sundberg JP, Buergelt CD (1987) Genital papillomatosis in sperm whale bulls. *J Wildl Dis* 23:361–367
- Landy RB (1980) A review of neoplasia in marine mammals (Pinnipedia and Cetacea). In: Montali RJ, Migaki G (eds) *The comparative pathologia of zoo animals*. Smithsonian Institution Press, Washington, DC, p 579–584
- Morris RJ, Lockyer C (1988) Twenty-two months in the life of a juvenile wild bottlenose dolphin. *Aquat Mamm* 14: 49–62
- O'Bannon MK, Sundberg JP, Shima AL, Reichmann ME (1987) Venereal papilloma and papillomavirus in a colobus monkey (*Colobus guereza*). *Intervirology* 28:232–237
- Oriol JD (1971) Natural history of genital warts. *Br J Vener Dis* 47:1–13
- Oshumi S (1971) Some investigations on the school structure of sperm whales. *Sci Rep Whales Res Inst Tokyo* 23:1–25
- Ostrow RS, McGlennen RC, Shaver MK, Kloster BE, Houser D, Faras AJ (1990) A rhesus monkey model for sexual transmission of a papillomavirus isolated from a squamous cell carcinoma. *Proc Natl Acad Sci USA* 87:8170–8174
- Reszka A, Sundberg JP, Reichmann E (1991) *In vitro* transformation and molecular characterization of colobus monkey papillomavirus DNA. *Virology* 181:787–792
- Rewell RE, Willis RA (1949) Some tumours found in whales. *J Pathol Bacteriol* 61:454–456
- Reyes JC, Van Waerebeek K (1995) Aspects of the biology of Burmeister's porpoise from Peru. *Rep Int Whal Comm Spec Iss* 16:349–364
- Rudlinger R, Smith IW, Bunney MH (1986) Human papillomavirus infection in a group of renal transplant recipients. *Br J Dermatol* 115:681–692
- Shah KV, Howley PM (1990) Papillomaviruses. In: Fields BN, Knippe DM, Channock RM, Hirsch MS, Monath TP, Roizman B (eds) *Virology*, 2nd edn. Raven Press, New York, p 1651–1676
- Sundberg JP (1987) Papillomavirus infection in animals. In: Syrjanen K, Gissman L, Koss LG (eds) *Papillomaviruses and human disease*. Springer-Verlag, London, p 41–103
- Sundberg JP, Junge EJ, Lancaster WD (1984) Immunoperoxidase localization of papillomaviruses in hyperplastic and neoplastic epithelial lesions of animals. *Am J Vet Res* 45:1441–1446
- Uys C, Best PB (1966) Pathology of lesions observed in whales flensed at Saldanha Bay, South Africa. *J Comp Pathol* 76: 401–412

- Van Waerebeek K (1992) Population identity and general biology of the dusky dolphin *Lagenorhynchus obscurus* (Gray, 1828) in the Southeast Pacific. PhD thesis, University of Amsterdam, p 160
- Van Waerebeek K (1993) External features of the dusky dolphin *Lagenorhynchus obscurus* (Gray, 1828) from Peruvian waters. *Estud Oceanol* 12:37-53
- Van Waerebeek K, Read AJ (1994) Reproduction of dusky dolphins *Lagenorhynchus obscurus* from coastal Peru. *J Mammal* 75:1054-1062
- Van Waerebeek K, Reyes JC (1994) Post-ban small cetacean takes off Peru: a review. *Rep Int Whal Comm Spec Iss* 15: 503-520
- Van Waerebeek K, Reyes JC, Read AJ, McKinnon JS (1990) Preliminary observations of bottlenose dolphins from the Pacific coast of South America. In: Leatherwood S, Reeves RR (eds) *The bottlenose dolphin*. Academic Press, San Diego, p 143-154
- Van Waerebeek K, Van Bressemer MF, Felix F, Alfaro J, García-Godos A, Chavez L, Ontón K, Montes D, Bello R (1995) Preliminary notes on cetacean mortality in fisheries off Peru and Ecuador in 1994. Document SC/47/SM/38, Intl Whaling Comm, Dublin
- Van Waerebeek K, Van Bressemer MF, Reyes JC, García-Godos A, Alfaro J, Ontón K, Bello R, Echegaray M (1994) Illegal exploitation of small cetaceans in Peru. Final report to the United Nations Environment Programme and the Whale and Dolphin Conservation Society, Nairobi, Kenya, p 76
- Wells RS, Scott MD, Irvine AR (1987) The social structure of free-ranging bottlenose dolphins. In: Genoway HH (ed) *Current mammology*. Vol I. Plenum Press, New York, p 519
- Würsig B, Würsig M (1979) Day and night of the dolphin. *Nat Hist* 88:60-67
- Zar JH (1984) *Biostatistical analysis*, 2nd edn. Prentice-Hall, New Jersey, p 718

Responsible Subject Editor: M. D. Dailey, Gunnison, Colorado, USA

Manuscript first received: November 18, 1995
Revised version accepted: January 9, 1996