

# SHORT COMMUNICATIONS

*Journal of Wildlife Diseases*, 29(1), 1993, pp. 109–113  
© Wildlife Disease Association 1993

## Evidence of Poxvirus in Dusky Dolphin (*Lagenorhynchus obscurus*) and Burmeister's Porpoise (*Phocoena spinipinnis*) from Coastal Peru

Marie-Françoise Van Bresse<sup>1,2</sup>, Koen Van Waerebeek<sup>2</sup>, Julio C. Reyes<sup>2</sup>, Daniel Dekegel<sup>3</sup>, and Paul-Pierre Pastoret<sup>1</sup> <sup>1</sup> Department of Virology and Immunology, Faculty of Veterinary Medicine, University of Liège, Institut de Chimie, Batiment B6, Local R80, Sart Tilman, 4000 Liège, Belgium; <sup>2</sup> Centro Peruano de Estudios Cetológicos, c/o Grupo Cetáceos-Asociación de Ecología y Conservación, Casilla 1536, Lima 18, Peru; <sup>3</sup> Department of Electron Microscopy, Pasteur Institute of Brabant, 45 rue Engeland, B-1180 Brussels, Belgium

**ABSTRACT:** In 1990, 74 dusky dolphins (*Lagenorhynchus obscurus*) and 10 Burmeister's porpoises (*Phocoena spinipinnis*) were examined for the presence of hyperpigmented marks and pinhole lesions on the skin (tattoo lesions) at the fishing terminal of Pucusana, central Peru. Prevalences of tattoo lesions were 8.1% and 30% in the dolphins and porpoises, respectively. Intracytoplasmic poxviruses were demonstrated by transmission electron microscopy in ultrathin sections of three of eight samples of infected epidermis from both species. The reason for the negative results in others is unclear but may be related to stages of infection with low virus density or even incorrect classification of some lesions as genuine viral tattoos. An irregular arrangement of tubules on the outer viral membrane, similar to those in orthopoxviruses, was visible in negative contrast preparations for *P. spinipinnis*. This is the first record of poxvirus in porpoises (Phocoenidae) and also the first report for dusky dolphins, and generally for cetaceans of the southern hemisphere.

**Key words:** Dusky dolphin, Burmeister's porpoise, *Lagenorhynchus obscurus*, *Phocoena spinipinnis*, dolphinpox virus, cetacean tattoo lesions.

Among marine mammals, poxviruses infect both pinnipeds and dolphins. Among pinnipeds, pox lesions have been reported from Californian sea lions (*Zalophus californianus*) (Wilson et al., 1969), South American sea lions (*Otaria byronia*) (Wilson and Poglajen-Neuwall, 1971), northern fur seals (*Callorhinus ursinus*) (Haddlow et al., 1980), grey seals (*Halichoerus grypus*) (Hicks and Worthy, 1987; Oster-

haus et al., 1990) and harbor seals (*Phoca vitulina*) (Wilson et al., 1972). In these species, visible lesions consisted mainly of elevated skin nodules.

In dolphins, poxvirus infection is characterized by hyperpigmented marks on the skin, flat or slightly in relief, or by "pinhole" lesions, collectively known as "tattoos" (Dailey, 1985), and has been described from captive and free-ranging bottlenose dolphins (*Tursiops truncatus*) (Geraci et al., 1979; Flom and Houk, 1979), free-ranging common dolphins (*Delphinus delphis*) (Britt and Howard, 1983) and an Atlantic white-sided dolphin (*Lagenorhynchus acutus*) (Geraci et al., 1979). All animals were from the North Atlantic, except the common dolphins (Britt and Howard, 1983).

Here we report the identification and preliminary prevalence levels of poxvirus in the dusky dolphin (*Lagenorhynchus obscurus*) and Burmeister's porpoise (*Phocoena spinipinnis*) from waters off central Peru. In this region, large numbers of small cetaceans are killed incidentally in a coastal gillnet fishery and are sold commercially for human consumption (Read et al., 1988; Van Waerebeek and Reyes, 1990). From 1984 to 1990, skin lesions recognized as tattoos regularly were seen in animals landed at local fish markets. In 1990, an investigation of tattoo skin lesions was started in the context of ongoing research

TABLE 1. Occurrence of tattoo skin lesions and poxvirus in dusky dolphins (*Lagenorhynchus obscurus*) and Burmeister's porpoises (*Phocoena spinipinnis*) from Peruvian coastal waters. Examination by transmission electron microscopy in ultrathin section (UT) and negative contrast preparation (NC).

Species	Necropsy number	Sex	Standard body length (mm)	UT	NC	Description
<i>L. obscurus</i>	MFB-001	M	1,805	+	ND <sup>b</sup>	Numerous tattoo lesions dispersed on head, trunk and flippers
	MFB-012	F	1,555	-	ND	Irregular dark mark showing some red spots in front of the right flipper
	MFB-044	F	1,625	-	ND	Dark mark with pinhole lesions located behind left eye
	MFB-045	F	1,965	-	ND	Small abraded lesion (5 mm) on left side of tail stock
	MFB-046	F	1,860	-	ND	Dark mark (12 by 7 mm) with pinhole lesions on left side of tail stock
	MFB-063	F	1,550	ND	ND	Numerous tattoos, some presenting pinhole lesions and petechia
<i>P. spinipinnis</i>	KVW-2282	F	1,705	-	-	Extensive blackish tattoo marks over entire body; largest (65 by 52 mm) located behind left eye and slightly raised
	KVW-2283	F	1,545	ND	+	Two tattoo lesions on the chin and on right lower lip
	KVW-2291	M	1,460	+	+	One tattoo mark on the left flank at mid-body

+ , presence of poxvirus; - , absence of poxviruses.

<sup>b</sup> ND, this procedure not done on this animal.

on the biology of small cetaceans in the eastern South Pacific.

Seventy-four dusky dolphins (38 females, 30 males, 6 of unknown sex) and 10 Burmeister's porpoises (5 females, 5 males) were carefully examined for the presence of tattoo lesions at the fishing terminal of Pucusana (12°30'S, 76°44'W), Peru, in August, September and December 1990. The mean standard body length (SBL) of all dolphins was 1,738 mm (SE = 19 mm); the range was 1,415 to 2,030 mm. The mean SBL for the porpoises was 1,525 mm (SE = 38 mm), and the range was 1,355 to 1,725 mm. The animals either drowned or asphyxiated after gillnet entanglement, and were sampled 6 to 18 hr post-mortem. Although necropsies were not permitted by fishmongers, a rough indication of their general health status was derived from external clues, in particular signs of emaciation.

About 1 cm<sup>2</sup> of skin, including epi-

dermis and dermis, was excised from animals with tattoo lesions and fixed in 5% glutaraldehyde buffered with 0.1M cacodylate (pH 6.8) (Millonig, 1976). An additional set of porpoise skin samples was soaked in 40% glycerin (McIlvaine buffer) (Hodgman, 1946) and frozen at -10 C for posterior negative contrast preparation and virus isolation. Samples were prepared for electron microscopy according to the procedures of Glauert (1975): preparations of skin lesion kept in glycerin were negatively stained with uranyl acetate and post-fixed with osmium tetroxide; glutaraldehyde fixed samples were stained with uranyl acetate and embedded in a mixture of Epon and Spurr resin (Glauert, 1975). Semi-thin sections (2 μm) were examined with an anoptal phase contrast microscope (Reichert, Vienna, Austria) to localize tissues, and ultra-thin sections (Reichert Ultracut microtome, Vienna, Austria) were stained with lead citrate. All prepa-

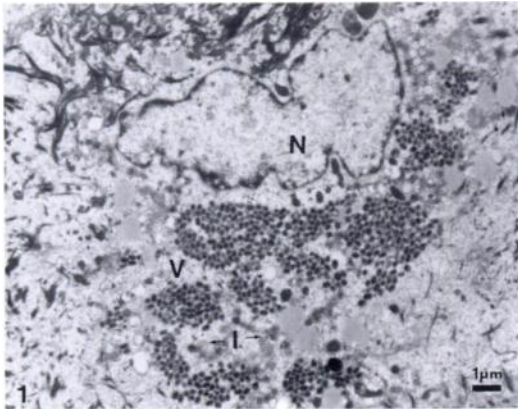


FIGURE 1. Cluster of mature (V) and immature (I) poxvirus particles in cytoplasm of infected epithelial cell of a dusky dolphin from Peru (MFB-001). Note irregular membrane of the nucleus (N) and margination of chromatin.

rations were examined with a Siemens 102 transmission electron microscope (Siemens, Berlin, Germany) at 100 kV.

Confidence levels (CL: 95%) were calculated according to the normal approximation rule for proportions (Wonnacott and Wonnacott, 1990).

Skin lesions resembling tattoos (Flom and Houck, 1979; Geraci et al., 1979) were observed in six (8.1%) of the 74 dusky dolphins (CL: 1.8 to 14.4%) and three of the ten Burmeister's porpoises (Table 1). Two dusky dolphins and one porpoise had numerous tattoo marks dispersed over their head, trunk and flippers; in the others, marks were few and isolated (Table 1). Lesions included hyperpigmented rings and black stippled patterns. Petechia were observed on the dark outline of some rings in two dolphins. None of the affected animals was emaciated, nor were there any other signs of reduced body condition.

Well-defined, dense clusters of intracytoplasmic poxviruses were revealed by transmission electron microscopy (TEM) in the ultrathin sections of the epidermis in one (MFB-001) of five dusky dolphins and one (KVV-2291) of two porpoises examined (Table 1). Viral particles, about 250 by 200 nm, were morphologically identical in both cetaceans (Figs. 1, 2).

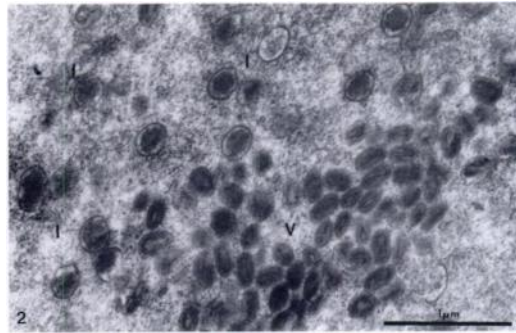


FIGURE 2. Section through mature (V) and immature (I) particles. Dumb-bell shaped core surrounded by two lateral bodies and enclosed by an outer membrane is visible in mature virions.

Poxviruses visible by TEM in negative contrast preparations in two (KVV-2283, KVV-2291) of three porpoises (Table 1) had an irregular arrangement of tubules on the outer membrane (Fig. 3).

Although further characterization is necessary, the poxviruses described here were morphologically similar to orthopoxviruses (Fenner et al., 1987). They were readily distinguished from the classical sealpox virus, which has a regular spiral arrangement of tubules and belongs to the parapoxviridae (Fenner et al., 1987). Therefore, the pox disease encountered in South American sea lions of Peru (Wilson and Poglayen-Neuwall, 1971) probably was not etiologically related to the poxvirus infection in the dusky dolphin and Burmeister's porpoise from the same waters. So far, orthopoxvirus associated with para-

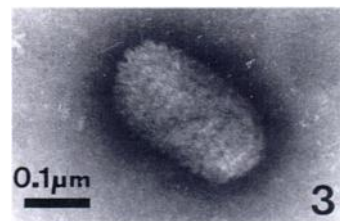


FIGURE 3. Poxviruses in negatively stained preparations of tattoos in Burmeister's porpoises (KVV-2283) showing an irregular arrangement of tubules on the outer viral membrane, as in orthopoxviruses.

poxvirus has been reported only in skin lesions of grey seals (Osterhaus et al., 1990).

It is unclear why viruses were found in TEM preparations of tattoo lesions from only three animals. Possibly different stages of infection vary widely in density of virus clusters; perhaps some tattoo-like lesions collected were not of poxvirus origin.

The present sample size of Burmeister's porpoises was too small to compare prevalences between this species and dusky dolphins. Nevertheless, earlier opportunistic observations by two coauthors (KVV and JCR) seemed to coincide with a higher prevalence in porpoises as suggested by the present data. Future work should encompass more animals and include other commonly captured small cetaceans, such as the common dolphin and the bottlenose dolphin (Read et al., 1988; Van Waerebeek et al., 1990) and also other localities. Poxvirus infection patterns possibly could serve as a biological tag to help discriminate separate populations, and thus provide useful information for management purposes.

Among cetaceans, poxviruses have been reported only from delphinids and even then documented accounts from free-ranging dolphins are rare (Geraci et al., 1979), perhaps because little attention is paid to such lesions. The present account is the first record of poxvirus infection in a porpoise (family Phocoenidae). It also is the first report for *L. obscurus*, for cetaceans of the southeast Pacific Ocean and for the southern hemisphere.

Poxviruses commonly cause disease in human beings (Hicks and Worthy, 1987; Fenner, 1990). The extensive handling and consumption of thousands of small cetaceans by Peruvians each year thus raises the question of whether dolphinpox may have a public health significance. Indeed, mild manifestations of an infection could easily go unnoticed among those social groups which for economic reasons do not seek medical help for afflictions which are not life-threatening.

We kindly acknowledge Mrs. G. Van Heule for her excellent technical assistance

and Dr. M. Klinowska for critical comments on the manuscript. Field work by KVV and JCR was supported in part by grants from the Whale and Dolphin Conservation Society, Leopold III-Fonds voor Natuuronderzoek en Natuurbehoud, Van Tienhoven Foundation and BBC Wildlife Magazine.

#### LITERATURE CITED

- BRITT, J. O., AND E. B. HOWARD. 1983. Virus diseases. *In* Pathobiology of marine mammal diseases, Vol. 1, E. B. Howard (ed.). CRC Press, Boca Raton, Florida, pp. 47-67.
- DAILEY, M. D. 1985. Diseases of mammalia: Cetacea. *In* Diseases of marine animals, Vol. 4, part 2, O. Kinne (ed.). Biologische Anstalt Helgoland, Hamburg, Federal Republic of Germany, pp. 805-848.
- FENNER, F. 1990. Poxviruses. *In* Virology, 2nd ed., B. N. Fields, D. M. Knippe, R. M. Chanock, M. S. Hirsch, T. P. Monath, and B. Roizman (eds.). Raven Press, New York, New York, pp. 2113-2133.
- , P. A. BACHMANN, E. P. J. GIBBS, F. A. MURPHY, M. J. STUDDERT, AND D. O. WHITE. 1987. Veterinary virology. Academic Press Inc., San Diego, California, pp. 387-405.
- FLOM, J. O., AND E. J. HOUK. 1979. Morphologic evidence of poxvirus in "tattoo" lesions from captive bottlenosed dolphins. *Journal of Wildlife Diseases* 15: 593-596.
- GERACI, J. R., B. D. HICKS, AND D. J. ST. AUBIN. 1979. Dolphin pox: A skin disease of cetaceans. *Canadian Journal of Comparative Medicine* 43: 399-404.
- GLAUERT, A. M. 1975. Embedding. *In* Fixation, dehydration and embedding of biological specimens. Practical methods in electron microscopy, Vol. 3, part 1, A. M. Glauert (ed.). North Holland Publishing Company, Amsterdam, Holland, pp. 123-176.
- HADLOW, W. J., N. F. CHEVILLE, AND W. L. JELLYSON. 1980. Occurrence of pox in a northern fur seal on the Pribilof Islands. *Journal of Wildlife Diseases* 16: 305-312.
- HICKS, B. D., AND G. A. WORTHY. 1987. Sealpox in captive grey seals (*Halichoerus grypus*) and their handlers. *Journal of Wildlife Diseases* 23: 1-6.
- HODGMAN, C. D. 1946. Handbook of chemistry and physics, 30th ed. Chemical Rubber Publishing Company, Cleveland, Ohio, 1,405 pp.
- MILLONIG, G. 1976. Laboratory manual of biological electron microscopy, M. Saviolo (ed.). M. Saviolo (publisher) Vercelli, Italy, 13 pp.
- OSTERHAUS, A. D. M. E., H. W. J. BROEDERS, I. K.

- G. VISSER, J. S. TEPPEMA, AND E. J. VEDDER. 1990. Isolation of an orthopoxvirus from pox-like lesions of a grey seal (*Halichoerus grypus*). *The Veterinary Record* 127: 91-92.
- READ, A. J., K. VAN WAEREBEEK, J. C. REYES, J. S. MCKINNON, AND L. C. LEHMAN. 1988. The exploitation of small cetaceans in coastal Peru. *Biological Conservation* 46: 53-70.
- VAN WAEREBEEK, K., AND J. C. REYES. 1990. Catch of small cetaceans at Pucusana port, central Peru, during 1987. *Biological Conservation* 51: 15-22.
- , ———, A. J. READ, AND J. S. MCKINNON. 1990. Preliminary observations of bottlenose dolphins from the Pacific coast of South America. *In* *The bottlenose dolphin*, S. Leatherwood and R. Reeves (eds.). Academic Press, San Diego, California, pp. 143-154.
- WILSON, T. M., AND I. POGLAYEN-NEUWALL. 1971. Pox in South American sea lions (*Otaria byronia*). *Canadian Journal of Comparative Medicine* 35: 174-177.
- , N. F. CHEVILLE, AND L. KARSTAD. 1969. Sealpox. *Bulletin of the Wildlife Disease Association* 5: 412-418.
- , R. W. DYKES, AND K. S. TSAI. 1972. Pox in young, captive harbor seals. *Journal of the American Veterinary Medical Association* 15: 611-617.
- WONNACOTT, T. H., AND R. J. WONNACOTT. 1990. *Introductory statistics*, 5th ed. John Wiley and Sons, New York, New York, 207 pp.

*Received for publication 13 November 1991.*