

Focal dermal hypoplasia

- a radiographic case report

SADJ May 2020, Vol. 75 No. 4 p208 - p210

Z Yakoob¹, C Nel²

ABSTRACT

Focal dermal hypoplasia (FDH) is an unusual X-linked dominant disorder that affects ectoderm and mesoderm derived tissues with females affected in 90% of cases. A case report of a 12 year old female diagnosed with FDH is presented. The dental significance of these patients are multifactorial and dental management should be focused on prevention and regular monitory visits.

Restoration of functionality should be addressed by a combination of orthodontic, basic restorative and prosthodontic disciplines. Due to the multisystem involvement and the dental complexities of patients suffering from FDH a multidisciplinary approach is required for optimal patient care.

Keywords

Focal dermal hypoplasia, Goltz-Gorlin syndrome, Ectodermal Dysplasia.

INTRODUCTION

Focal dermal hypoplasia (FDH), also known as Goltz-Gorlin syndrome was first reported in 1962 by Goltz, Peterson, Gorlin and Ravitz.¹ FDH is an unusual X-linked dominant disorder that affects ectoderm and mesoderm derived tissues.²

The PORCN (porcupine O-acyltransferase) gene mutation can be inherited or occur sporadically, with females affected in 90% of cases.^{3,4} FDH is characterized by a wide range of multisystem abnormalities and all patients present with dermatological conditions. The eyes, teeth, skeletal, urinary, gastrointestinal, cardiovascular and central nervous systems may all present with manifestations (Figure 1).^{3,5}

Over 280 cases have been reported in the literature, with a small number of these reporting oral and dental features.³ The reported dental abnormalities associated with this condition include; hypodontia, enamel hypoplasia and structural alterations such as taurodontism and abnormal root morphology.

Disturbances in eruption and ectopic teeth are also a common finding.³ One study reports the presence of enamel defects in the form of vertical grooves that run along the Blaschko lines, as a strong indicative factor for FDH.⁶

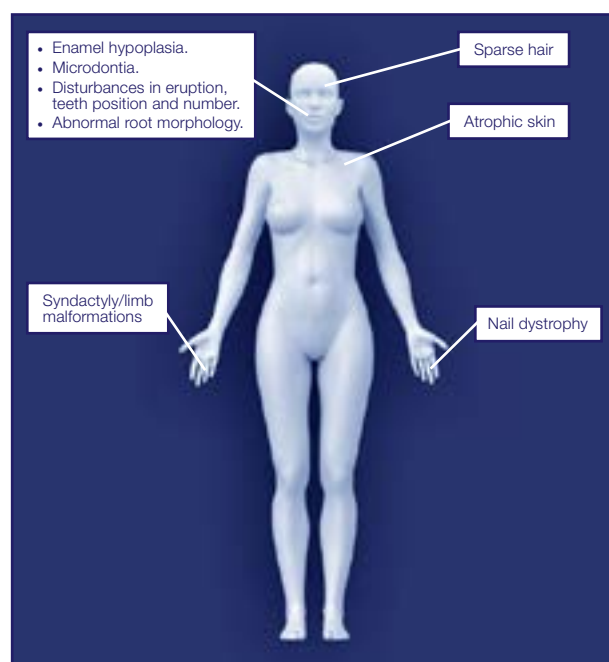


Figure 1. Most common conditions associated with FDH.⁴

CASE DESCRIPTION

A 12 year old female diagnosed with FDH reported to our institution seeking dental care. The diagnosis was made by a geneticist at infancy. She has been managed for numerous multisystem conditions since birth and was referred to our institution for further dental and orthodontic management.

The patient has a history of surgical treatment for the correction of syndactyly of the hands (Figure 2). The patient's toes have not been surgically corrected (Figure 3). The patient has been reportedly struggling with chronic conjunctivitis, middle ear infections and dermatitis.

Author affiliations:

1. Zarah Yakoob: BChD (UWC), PG Dip Dent (Maxillofacial Radiology) (UWC), MSc (Maxillofacial Radiology) (UWC), Faculty of Health Sciences, Department of Oral Pathology and Oral Biology, University of Pretoria.
ORCID Number: 0000-0003-1966-5574
2. Chané Nel: BChD (UP), MSc Maxillofacial Radiology (UP), Faculty of Health Sciences, Department of Oral Pathology and Oral Biology, University of Pretoria.
ORCID Number: 0000-0003-4047-6356

Corresponding author: Zarah Yakoob

Pretoria Oral and Dental Hospital, Corner of Dr Savage and Steve Biko Road, Pretoria, South Africa.
Email: zarah.yakoob@up.ac.za

Author contributions:

1. Zarah Yakoob: First draft, revision, final write-up and final approval - 50%
2. Chané Nel: Conceptualization, first draft, revision, final write-up and approval - 50%

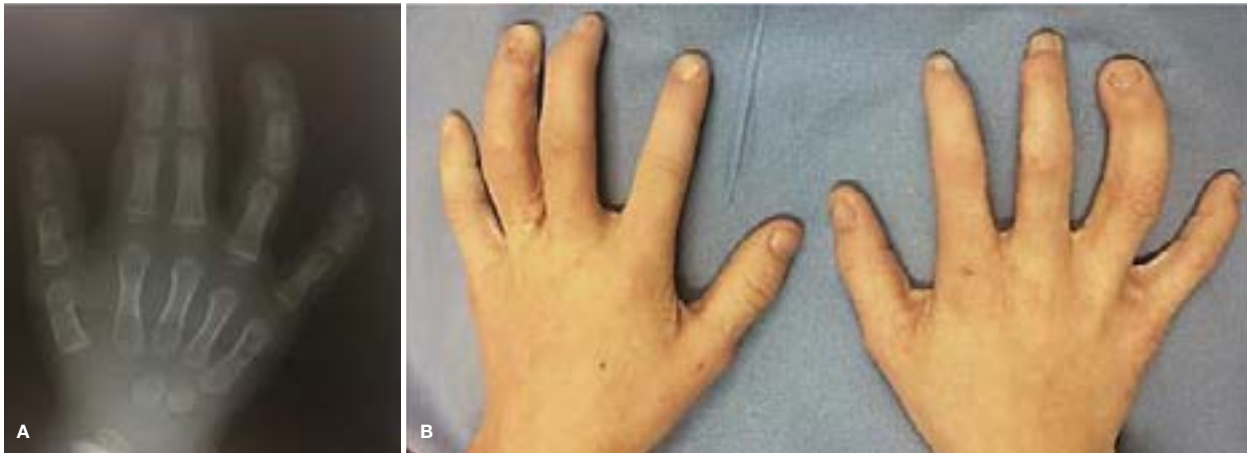


Figure 2. Preoperative radiograph (A) of right hand exhibiting syndactyly. Soft tissue union of the right index and middle finger. Clinical picture (B) of hands after surgical correction.

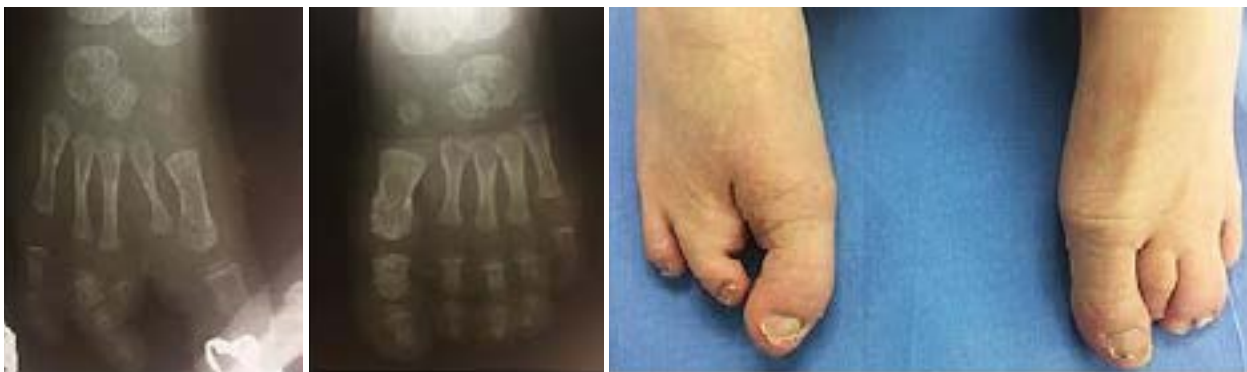

Figure 3. Current clinical presentation and previous radiographs of feet. On the right foot the proximal, middle and distal phalanges of the index toe are missing. The middle and distal phalanges of the middle toe on the right foot is also missing. On the left foot soft tissue union is visualised between the middle and fourth toe.

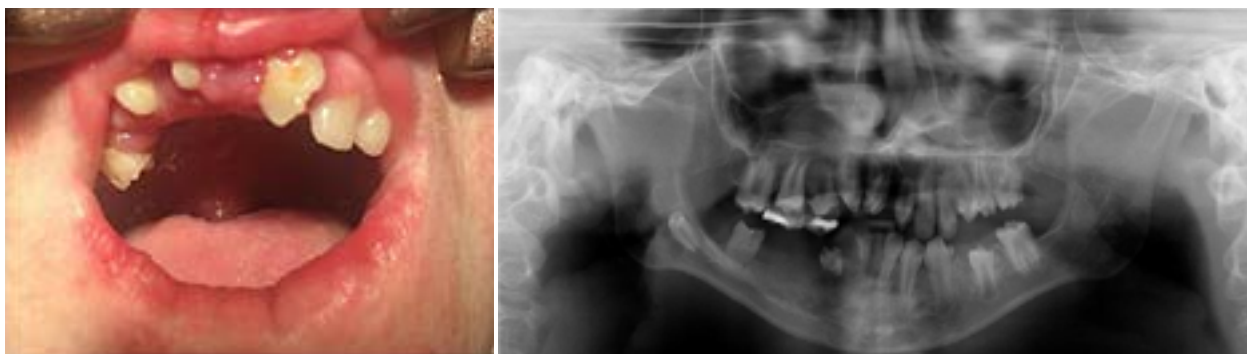

Figure 4. Clinical photograph demonstrating patchy skin, gingival enlargement and enamel hypoplasia.

Figure 5. Panoramic radiograph of the patient exhibiting enamel hypoplasia and hypodontia.

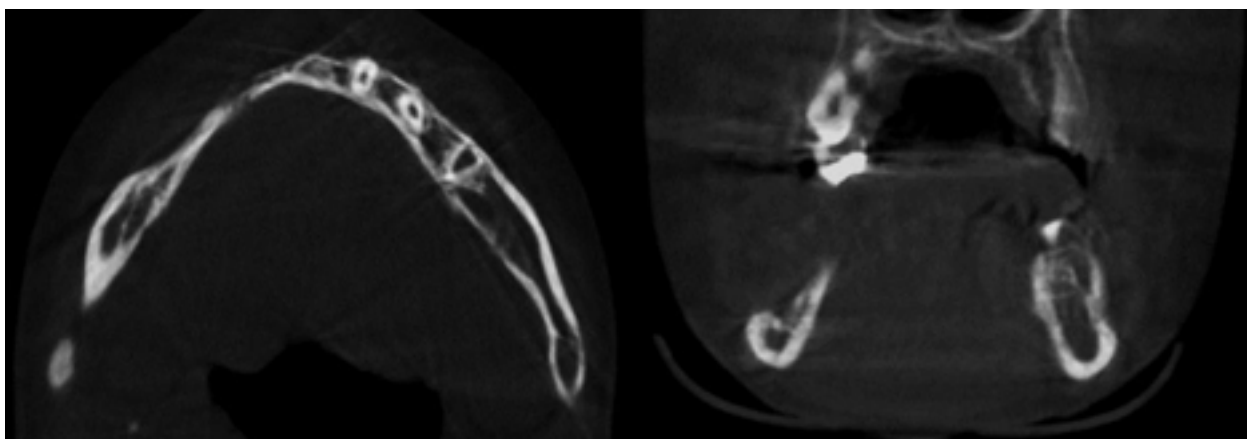


Figure 6. Axial and coronal CBCT slice exhibiting mandibular bone.

The extra-oral examination revealed sparse hair, dystrophic nails and red patchy skin. The intra-oral examination revealed microstomia, generalized inflammatory gingival enlargement and numerous missing and mal-aligned teeth (Figure 4).

The visualization of vertical grooving of the anterior teeth was not feasible due to the altered eruption and alignment. The patient was subsequently referred for radiographic assessment. The panoramic radiograph (Figure 5) revealed an elongated left condylar neck and interrupted calcification of the right stylohyoid ligament. Generalized enamel hypoplasia and hypodontia was the most striking radiographic finding.

Radicular hypoplasia was also visible on 43 and 22. Overlap and crowding of maxillary anterior teeth and a disto-angular impaction in the right mandibular corpus was noted. The bone in the 4th quadrant had an irregular presentation and the decision was then made to take a CBCT scan of the area (Figure 6).

The CBCT scan revealed thin crestal bone in the area of the 4th quadrant with intact cortication. This explains the irregular appearance of the bone seen on the panoramic radiograph as the thin bony crest was outside of the panoramic focal trough. The excess mobile soft tissue in the 4th quadrant was excised under general anaesthesia and submitted for histology.

The histological features were that of inflammatory fibrous hyperplasia. The 55, 54 and 43 were also extracted during this procedure. A carious 46 was also detected on the radiograph and was subsequently restored. The patient was assessed by maxillofacial surgeons, orthodontists and a geneticist during her visit at our institution and was further managed by the pedodontics department for restorative and preventive care. Initial verbal consent and later written informed consent was obtained from the mother of the child to continue with the study. Ethical approval was obtained from the University of Pretoria Ethics committee (Reference number: 143/2019).

DISCUSSION

A three year follow up study found that enamel hypoplasia is a significant risk factor for caries development.⁷ Therefore patients with FDH have increased susceptibility to caries formation due to the hypoplastic enamel. Additionally, hypoplastic enamel is significant as it is associated with altered aesthetics and increased dentinal sensitivity.

Masticatory functionality is impaired due to the hypodontia and ectopic teeth with few teeth in full occlusion. The microstomia influences oral hygiene practices which often leads to gingivitis and a higher prevalence of caries of the susceptible enamel. Dental treatments and interventions should be focused on prevention with regular dental check-ups, fissure sealants and topical fluoride application. Restoration of functionality should be addressed by a combination of orthodontic, basic restorative and prosthodontic disciplines.

Due to the multisystem involvement and the dental complexities of patients suffering from FDH a multidisciplinary approach is required for optimal patient care.

Declaration

The authors declare no conflict of interest.

Ethical considerations

'All procedures followed were in accordance with the ethical standards of the responsible committee on human experimentation (institutional and national) and with the Helsinki Declaration of 1975, as revised in 2008 (5).

Informed consent was obtained from all patients for being included in the study.

This article does not contain any studies with human or animal subjects performed by any of the authors.

References

1. Nathwani S, Martin K, Bunyan R. Focal dermal hypoplasia: A novel finding in disguise. *J Oral Biol Craniofacial Res.* 2018; 8(2): 143-6.
2. Yesodharan D, Buschenfelde UMZ, Kutsche K, Nair KM, Nampoothiri S. Goltz-Gorlin Syndrome: Revisiting the Clinical Spectrum. *Indian J Pediatr.* 2018; 85(12): 1067-72.
3. Wang L, Jin X, Zhao X, Liu D, Hu T, Li W, et al. Focal dermal hypoplasia: Updates. *Oral Dis.* 2014; 20(1): 17-24.
4. Grzeschik KH, Bornholdt D, Oeffner F, König A, del Carmen Boente M, Enders H, et al. Deficiency of PORCN, a regulator of Wnt signaling, is associated with focal dermal hypoplasia. *Nat Genet.* 2007; 39(7): 833-5.
5. Ghosh SK, Dutta A, Sarkar S, Nag SS, Biwas SK, Mandal P. Focal dermal hypoplasia (Goltz Syndrome): A cross-sectional study from Eastern India. *Indian J Dermatol.* 2017; 62(5): 498-504.
6. Gysin S, Itin P. Blaschko Linear Enamel Defects – A Marker for Focal Dermal Hypoplasia: Case Report of Focal Dermal Hypoplasia. *Case Rep Dermatol.* 2015; 7(2): 90-4.
7. Basha S, Noor Mohamed R, Swamy HS. Association between enamel hypoplasia and dental caries in primary second molars and permanent first molars: A 3-year follow-up study. *Ann Trop Med Public Heal.* 2016; 9(1): 4-11.