



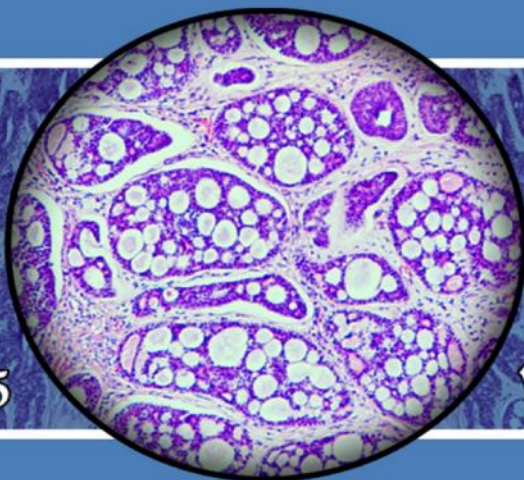
# 1<sup>st</sup> Afzalipour International Medical Congress On Pathology



دانشگاه علوم پزشکی و خدمات  
بهداشتی دامانی کرمان

Kerman

18 to 20 November 2015



کرمان

۲۷ تا ۲۹ آبانماه ۱۳۹۴

مجموعه مقالات ارائه شده در

تختین گنجره بین المللی پزشکی  
افضلی پور  
باجوریت پاتولوژی



دانشگاه علوم پزشکی کرمان  
معاونت تحقیقات و فناوری



مرکز تحقیقات پاتولوژی  
و سلول های بنیادی



من آسیب شناسی ایران



بانک ملت




ظنون آزمایشگاه  
LAB TECH



Roche



شرکت آکبریه



شرکت آکبریه  
Akbarieh Company



الکترونیک پزشکی پیشرفته  
ADVANCE MEDTRONICS

# A Rule Based Classification Model to Predict Colon Cancer Survival

Reza Abbasi<sup>1</sup>, Mitra Montazeri<sup>2,3</sup>, Mohammad Zare<sup>4</sup>, Majid Amiri gharghani<sup>5</sup>

<sup>1</sup>Master of Science in Health Information Technology, Researcher of Medical Informatics Research Center, Department of Health Information Technology, School of Management and Information, Scientific Research Center, Kerman University of Medical Sciences, Kerman, Iran. <sup>2</sup>Medical Informatics Research Center, Institute for Futures Studies in Health, Kerman University of Medical Sciences, Kerman, Iran. <sup>3</sup>Computer Engineering Department, Shahid Bahonar University, Kerman, Iran. <sup>4</sup>Master of Science in Epidemiology, staff of Namazi Hospital, Shiraz, Iran. <sup>5</sup>Master of Science in environmental health, Department of environmental of health, Faculty of Health, Kerman University of Medical Sciences, Kerman, Iran.

**Introduction:** Colon cancer is the second most common cancer in the world and fourth most common cancer in both sexes in Iran, whose % 8.12 of all cancers in the covers. Predict the outcome of cancer and basic clinical data about it is very important. Data mining techniques can be used to predict cancer outcome. In our country, data mining studies on colon cancer, not covered as lung or breast cancers. It seems can be with identify factors influencing on survival and modify them, increased survival of colon cancer patients. Then according to high rates of colon cancer and the benefits of data mining to predict survival, in this study examined factors influencing on the survival of these patients.

**Materials and Methods:** We use a dataset with four attributes that include the records of 570 patients in which 327 Patients (57.4%) and 243 (42.6%) patients were males and females respectively. Trees Random Forest (TRF), AdaBoost (AD), RBF Network (RBFN), and Multilayer Perceptron (MLP) machine learning techniques with 10-cross fold technique were used with the proposed model for the prediction of colon cancer survival. The performance of machine learning techniques were evaluated with accuracy, precision, sensitivity, specificity, and area under ROC curve.

**Results:** Out of 570 patients, 338 patients and 232 patients were alive and dead respectively. In this Study, at first sight it seems that among this techniques, Trees Random Forest (TRF) technique showed better results in comparison to other techniques (AD, RBFN and MLP). The accuracy, sensitivity, specificity and the area under ROC curve of TRF are 0.76, 0.808, 0.70 and 0.83, respectively.

**Conclusions:** In this study seems that Trees Random Forest model (TRF) which is a rule based classification model was the best model with the highest level of accuracy. Therefore, this model is recommended as a useful tool for colon cancer survival prediction as well as medical decision making.

**Keywords:** Colon Cancer, Survival prediction, Data Mining.

# Urinary Tract Infection in Spinal Cord Injuries

Taher Akbari Saeed<sup>1</sup>, Sajad Varmazyar<sup>2</sup>, Alireza Mordadi<sup>3</sup>, Ali Tavakoli<sup>4</sup>

<sup>1</sup>Master of Science in Laboratory Hematology and Blood Banking, Department of Laboratory Hematology and Blood Banking, School of Allied Medical Sciences, Scientific Research Center, Kerman University of Medical Sciences, Kerman, Iran. <sup>2</sup>Master of Science in Virology, Department of Virology, School of Medical Sciences, Scientific Research Center, Tehran University of Medical Sciences, Tehran, Iran. <sup>3</sup>Master of Science in Medical Microbiology, Department of Medical Microbiology, School of Medical Sciences, Scientific Research Center, Hamedan University of Medical Sciences, Hamedan, Iran. <sup>4</sup>Bachelor of Science in Medical Laboratory Sciences, , School of Allied Medical Sciences, Scientific Research Center, Tehran University of Medical Sciences, Tehran, Iran.

Spinal cord injuries have traumatic or non-traumatic in etiology, but are typically associated with major trauma from motor vehicle accidents, falls, sports injuries, and violence. Urinary Tract Infections (UTI) is one of the most frequent conditions seen in spinal cord injuries patients. Diagnosis is not always easy due to lack of symptoms. Present study is survey about urinary tract infection and pyuria in these patients. All of patients with spinal cord injuries, who admitted to “Brain and Spinal Injury Repair Research Centre” in Imam Hospital in duration one year, were included in this study. Clean catch midstream urine samples were collected of patients and were analyzed by biochemical and microscopically surveys. In total 103 patients, 22 patients (25.3%) have cervical spinal cord injury, 52 patients (59.8%) have thoracic spinal cord injury and 13 patients (14.9%) have lumbar spinal cord injury. 83 patients were urine culture positive with urinary tract infection and pyuria were seen in 65 patients. the highest incidence of UTI and pyuria were demonstrated in patients with cervical spinal cord damage. E.coli (%33), Klebsiella pneumoniae (10.7%) and Enterobacter cloacae (7.8%) were isolated in urine samples, respectively. The high incidence of resistancy to Nitrofurantoin and Imipenem in E.coli were seen (51.1% and 43.7%, respectively). Patients with spinal cord injuries have to use catheter for long time and or for all of life, and they are high risk to recurrent urinary tract infections and other infections. These patients need to monitor for urinary tract infection although without any symptoms of infections and sometimes they need to take prophylactic antibiotics.

**Keywords:** Spinal cord injury, Urinary tract infection, Pyuria.

# Comparing of enzyme activity of ACP and ALP in the saliva samples of patients affected with periodontal disease and healthy subjects

Taher Akbari Saeed<sup>1</sup>, Mahsa Sohani<sup>2</sup>

<sup>1</sup>Master of Science in Laboratory Hematology and Blood Banking, Department of Laboratory Hematology and Blood Banking, School of Allied Medical Sciences, Scientific Research Center, Kerman University of Medical Sciences, Kerman, Iran. <sup>2</sup>Master of Science in Laboratory Hematology and Blood Banking, Department of Laboratory Hematology and Blood Banking, School of Allied Medical Sciences, Scientific Research Center, Tehran University of Medical Sciences, Tehran, Iran.

**Introduction:** Lack of hygiene leads to massive accumulation of plaque and gum tissue is an infection that is called gingivitis and if left untreated, the inflammation of periodontal tissues to other published and it is referred to as periodontitis.

Current clinical diagnostic criteria of this disease: Pocket depth, clinical attachment level, bleeding on probing, gingival redness, but none of the above criteria, do not provide information on the context of the active form of the disease occurs or a risk of loss of tissue connections. Biochemical diagnostic tests for the assessment of periodontal disease with clinical examinations provided, is focused mainly on causing by the surface of the host probing liquid (GCF) such as prostaglandins, elastase, collagenase, interleukin and AST. It looks review of salivary enzyme levels such as ACP and ALP are very useful biochemical markers for the evaluation of periodontal tissue damage, disease diagnosis, and monitoring and evaluation of patient response to treatment for dentists.

**Materials and Methods:** This study has measured enzyme activity alkaline phosphatase (ALP) and acid phosphatase (ACP) in Saliva healthy subjects (35 males and females) and simple to advanced periodontal disease patients (72 males and females) and the relationship between salivary tissue enzyme activity of ACP and ALP in health and disease periodontium and also has review of periodontal disease. Periodontal disease and disease levels in subjects participating in clinical research was diagnosed by a dentist by the current diagnostic criteria for the disease, including PD (Probing Depth), CAL (Clinical Attachment Loss), BOP (Bleeding on Probing) and red gums, GI (Gingival Index), based on standards. Activity of enzymes ACP and ALP was measured by using standard laboratory kits. Finally, all the data obtained were analyzed by using SPSS software.

**Results:** The mean of ALP levels in healthy subjects and in patients with moderate to severe periodontitis, are respectively, 8.34, 14.23 and 35.06. The mean of ACP levels in healthy subjects and in patients with moderate to severe periodontitis, are respectively, 20.61, 33.18 and 72.69. Both association was significant ( $P < 0.01$ ).

**Conclusion:** According to the significant relationship that has been observed between levels of salivary enzymes " ACP and ALP " with levels of periodontal disease and periodontal tissues in health and disease, it can be used as a biochemical index for the diagnosis of periodontal disease and monitoring response to treatment in patients, also, gaining detailed information about the extent of tissue damage and tissue regions that disease progression occurs actively or there is a risk of loss of tissue joints.

**Keywords:** Periodontal disease, Salivary enzymes, ACP, ALP.

# Oral Involvement in Mycosis Fungoides: Report of a Case

Sara Amanpour<sup>1</sup>, Mohammad Reza Zarei<sup>2</sup>, Shahriar Dabiri<sup>3</sup>

<sup>1</sup>Assistant Professor, Department of Oral and Maxillofacial Pathology, School of Dentistry, Kerman University of Medical Sciences. <sup>2</sup>Associate Professor, Department of Oral Medicine, School of Dentistry, Kerman University of Medical Sciences. <sup>3</sup>Professor of pathology, School of Medicine, Kerman University of Medical Sciences.

**Introduction:** Mycosis fungoides (MF) is a cutaneous T-cell lymphoma that usually evolves through 3 classical stages: scaly patches, infiltrative plaques, and finally tumours. Oral involvement is uncommon in cutaneous T-cell lymphomas and usually associated with poor prognosis. The oral sites more frequently involved are the tongue, palate, gingiva, buccal mucosa, lips and oropharynx. Clinical presentation varies and includes ulcerated tumors, indurated plaques, papules, leukoplakia-like lesions, nodules, and multiple erosions. In almost all patients cutaneous lesions preceded mucosal ones, ranging from 7 months to 40 years, with an average of 8 years. The differential diagnosis of oral mycosis fungoides includes geographic tongue, benign eosinophilic ulcers of the oral mucosa, trauma, lymphomatoid papulosis, malignancies, and infection.

## Case Report:

A 43-year-old white male, who was diagnosed with mycosis fungoides of the skin a few months ago, presented with the chief complaint of a painful ulcer of the tongue. Clinical examination revealed a deep necrotic ulcer on the left lateral border of the tongue. There were also small, round ulcers on the ventral surface of the tongue at the same side. Some of these small ulcers had coalesced to produce large confluent ulcerations with irregular borders. Histologic examination showed a dense and diffuse infiltrate of large atypical lymphocytes with exocytosis. Numerous mitoses and eosinophils were also present. The phenotype of the tongue lesion was CD3<sup>+</sup>, CD4<sup>+</sup>, and CD8<sup>-</sup>.

Of the reported cases today, more than 50% died within 1 year of the presentation of oral lesions and almost all died within 3 years. This survival rate is worse than that of patients with lymphadenopathy, erythroderma or tumoral lesions, and similar to that of patients with visceral involvement. Therefore, oral involvement in MF must be considered a marker for poor prognosis and a manifestation of advanced disease.

**Keywords:** Mycosis fungoides, Oral involvement, Tongue, Case report.

# A Manual Cost-Effective Method for Obtaining Standard Platelet rich plasma in Health Centers

Farzaneh Armin<sup>1</sup>, Zahra Ameri<sup>1</sup>, Alireza Farsinejad<sup>2</sup>

<sup>1</sup>Department of Hematology and laboratory Sciences, Faculty of allied medicine, Kerman University of Medical Sciences, Kerman, Iran. <sup>2</sup>Pathology and Stem Cell Research Center, Kerman University of Medical Sciences, Kerman, Iran.

**Introduction:** During the past decade, Platelet-rich plasma (PRP) has been used frequently in the cosmetic surgery and regenerative medicine. It is advocated as a safe and efficient way to introduce increased concentrations of growth factors and other bioactive molecules to injured tissues in an attempt to optimize the local healing environment. However, several factors influence the effectiveness of this product. Variations in the volume of whole blood taken, the platelet recovery efficacy, the final volume of plasma in which the platelets are suspended, the presence or absence of red and/or white blood cells, and the addition of pH-altering compounds can all affect the characters and potential efficacy of the PRP product. Therefore, achieve to a simple, practical, cost-effective and repeatable method is very effective.

**Materials and Methods:** 20 blood units were obtained from healthy donors following standard clinical procedures, predonation screening, and written informed consent at the Iranian Blood Transfusion Organization Regional donor center. Each unit contained  $450 \pm 50$  mL of whole blood (WB) and 63 mL of citrate-phosphate-dextrose-adenine (CPDA-1) anticoagulant solution. Each unit was mixed by gently tilting the bag horizontally (2 min) and vertically (2 min) before sampling. Aliquots of 15 mL were placed into 15-mL falcon tubes via a sterile pipette. For Each aliquot, complete blood count (CBC) was determined using a standard cell counter (automatic Sysmex cell counter). In the next step, bloods were processed by different centrifugation speeds and times to obtain platelet-rich plasma, which were then analyzed by cell counter for efficacy evaluation.

**Results:** The results showed that centrifuging with 427.6g for 10 min results in the most platelet enrichment. Platelet concentration was also 1.86 times higher than the baseline value and white blood cell count did not exceed the reference range. Volume of gained PRP was 4 ml.

**Conclusions:** Centrifugation with suggested circumstances is a relatively simple, inexpensive and repeatable method for obtaining platelet-rich plasma, potentially available for therapeutic use to improve the healing process.

**Keywords:** Platelet-rich plasma, Whole Blood, Complete Blood Count, Centrifugation.

# The prevalence of impaired glucose tolerance in patients with thalassemia major in Iran-a systematic review and meta-analysis study

Milad Azami<sup>1</sup>, Kourosh Sayehmiri<sup>2</sup>, Samiramis Qavam<sup>3</sup>, Mohammadreza HafeziAhmadi<sup>4</sup>

<sup>1</sup>Medical Student, Student Research Committee, Ilam University of Medical Sciences, Ilam, Iran. <sup>2</sup>Associate Professor, Department of Biostatistics, Research Center for Prevention of Psychosocial Impairment, Ilam University of Medical Sciences, Ilam, Iran. <sup>3</sup>Department of Cardiology, Faculty of Medicine, Ilam University of Medical Sciences, Ilam, Iran. <sup>4</sup>Department of Pathology, Faculty of Medicine, Ilam University of Medical Sciences, Ilam, Iran.

**Introduction:** Thalassemia major is considered a public health problem So that the most common genetic diseases in the world. Impaired glucose tolerance (IGT) is one of the most common endocrine complications in thalassemic patients. Prevalence of Impaired glucose tolerance in major thalassemia patients is different in our country in different studies and there is no total estimate about it. So this Meta analysis study has been done to investigate IGT prevalence in thalassemia major patients in Iran.

**Materials and Methods:** This study is a systematic review Based on electronic databases including Magiran, Iran medex, IranDoc, SID, Medlib and international databases including Scopus, Pubmed, ScainceDiret, and Google Scholar. Articles search mechanism is mainly using the systematic search for key words in Persian and English With all the possible combinations of key words, original and sensitive by two independent researchers. Then, all articles that had inclusion criteria were examined and for quality the articles evaluated by STROBE Check list and to pooled of results of studies random effects model in meta-analysis was used.

**Results:** 1332 subjects were studied in 10 studies. Prevalence of IGT in patients with thalassemia major in Iran was estimated 5.7% (CI: 95%, 4.7-6.8). The minimum and maximum IGT were Babel (52.7%) and Yasooj (87.2%), respectively.

**Conclusion:** Prevalence of IGT in patients with thalassemia major was high. And annual glucose tolerance test in these patients is necessary.

**Keywords:** Prevalence, Impaired glucose tolerance, Thalassemia major, Systematic review, Meta-analysis, Iran.

# **The Prevalence of Diabetes Mellitus in patients with thalassemia major in Iran: A systematic review and meta-analysis study**

Milad Azami<sup>1</sup>, Kourosh Sayehmiri<sup>2</sup>, Mohammadreza HafeziAhmadi<sup>3</sup>, Ghobad Abangah<sup>4</sup>

<sup>1</sup>Medical Student, Student Research Committee, Ilam University of Medical Sciences, Ilam, Iran. <sup>2</sup>Associate Professor, Department of Biostatistics, Research Center for Prevention of Psychosocial Impairment, Ilam University of Medical Sciences, Ilam, Iran. <sup>3</sup>Department of Pathology, Faculty of Medicine, Ilam University of Medical Sciences, Ilam, Iran. <sup>4</sup>Department of Gastroenterology, Faculty of Medicine, Ilam University of Medical Sciences, Ilam, Iran.

**Introduction:** Mellitus form of Diabetes is one of the most common endocrine complications in thalassemic patients. In different studies, Prevalence of diabetes in patients with thalassemia major of Iran is different and there is no total estimate about it. So this Meta analysis study has been done to investigate diabetes prevalence in thalassemia major patients in Iran.

**Materials and Methods:** This study is based on received information achieved from Magiran, Iran medex, IranDoc, SID, Medlib and international databases including Embase, Scopus, Web of Science, Pubmed, ScainceDiret, and also Google Scholar in chronological order of 1991-2015 with using standard key words. Search and extraction of data were done by two independed reviewers. Then, all articles that had inclusion criteria were examined. To pooled of results of studies random effects model in meta-analysis was used.

**Results:** 4690 subjects were studied in 29 studies. Prevalence of diabetes in patients with thalassemia major in Iran was estimated 10/1% (CI: 95%, 8/1-12/2). The minimum and maximum prevalence of diabetes were South (12/7%) and West of the country (5/3%), respectively. The relationship between prevalence of diabetes with year of study was studied, this relationship is not statistically significant (P= 0.0777).

**Conclusion:** Prevalence of diabetes in thalassemia major in Iran is relatively high and annual Diabetic test in these patients is necessary.

**Keywords:** Diabetes, Endocrine disorders, Thalassemia major meta-analysis, Systematic review.



# Tuberculous Appendicitis: A Rare Clinical Entity

Shahriar Dabiri<sup>1</sup>, Moeinadin Safavi<sup>1,2</sup>, Freidoon Solhjoo<sup>2</sup>

<sup>1</sup>Pathology Department, School of Medicine, Kerman University of Medical Sciences, Kerman, Iran.

<sup>2</sup>Molecular Pathology Department, School of Medicine, Shiraz University of Medical Sciences, Shiraz, Iran.

**Introduction:** Tuberculosis may involve any organ of body. Extra pulmonary tuberculosis, in decreasing order of frequency, includes: skeletal system (30%), urinary system (24%), lymph nodes (13%), genital organs (8%), meningeal membranes (4%), and gastrointestinal system (3%). Although alimentary tuberculosis is rather prevalent in endemic countries, tuberculous appendicitis is astonishingly rare.

**Case presentation:** Here we present a 16 year old girl with complaint of anorexia, weight loss, diarrhea, fever and right iliac fossa pain since 6 months before her admission. Physical examination was normal except tachycardia and tenderness of McBurney's point. The patient underwent diagnostic laparotomy with the impression of chronic appendicitis and an inflamed appendix adjacent to an enlarged lymph node was discovered. Histopathological findings showed focal ulceration of appendix mucosa along with epithelioid granuloma and Langhan's giant cell in its wall. The lymph node exhibited typical confluent caseous necrosis. PCR for Mycobacterium tuberculosis depicted a positive result. Ultimately she was treated with anti-tuberculosis regimen of RIPE (Rifampicine, Isoniazid, Pyrazinamide, Ethambutol).

Incidence of tuberculous appendicitis ranges from 0.1 to 3.0% among all appendectomies. Its incidence is obviously higher in known cases of tuberculosis and reaches 1.5 to 30%. Its exact pathogenesis is not clarified. It is supposed that appendix involvement can be primary or secondary. Primary tuberculous appendicitis is resulted from hematogenous spread from undetectable sources. Secondary involvement is a local process due to direct extension of ileocecal infection, spreading of distant lesions of ileum or ascending colon through retrograde lymphatic current, or periappendicitis originating from peritoneal involvement. In conclusion, tuberculous appendicitis is a rare clinical entity that mandates correct diagnosis through histopathological evaluation and high clinical suspicion especially in endemic areas to prevent treatment failure and subsequent infectious complication.

**Keywords:** Appendicitis, Tuberculosis, Case Report.

# The Association of HLA Class 1 and Class 2 Antigens with Multiple Myeloma in Iranian Patients

Romina Dastmalchi<sup>1</sup>, Arezou Sayad<sup>1</sup>

<sup>1</sup> Shahid Beheshti University of Medical Sciences, Department of Medical Genetics, Tehran, Iran

**Introduction:** Multiple myeloma (MM) is a B-cell malignancy characterized by the clonal proliferation of malignant plasma cells. According to results of some studies, it has been suggested that the HLA class 1 and 2 genes have susceptibility effects on MM. Studies of different populations have reported different HLA class 1 and 2 alleles that affect MM. In this study, we assessed the association of HLA class 1 and class 2 antigens with MM in Iranian patients.

**Materials and Methods:** We performed a case-control genotyping study with 105 Iranian MM patients that were selected from the bone marrow transplantation department of Taleghani Hospital and 150 controls using single specific primer-polymerase chain reaction with the HLA-Ready Gene ABDR Kit.

**Results:** Our results demonstrated that 21% of patients versus 12% of controls and 11% of patients versus 3% of controls carried HLA-A\*03 and HLA-B\*18, respectively. The MM patients had a significant increase in the frequency of HLA-A\*03 and HLA-B\*18 alleles in comparison to control subjects ( $p=0.039$ ,  $OR=2.057$  and  $p=0.013$ ,  $OR=3.567$ , respectively).

**Conclusion:** Our findings suggested that the HLA-A\*03 and HLA-B\*18 alleles have significant susceptibility effects on MM in the Iranian population. However, compared to other populations, the above-mentioned alleles had different statuses. Since there are not many studies evaluating and calculating this association among ethnic groups, further studies among other populations are needed to explain the exact association of the HLA genes with MM.

**Keywords:** Multiple myeloma, HLA genes.

# Intraparotid Facial Nerve Schwannoma

Moeinadin Safavi MD<sup>1,2</sup>

<sup>1</sup>Pathology Department, School of Medicine, Kerman University of Medical Sciences, Kerman, Iran.

<sup>2</sup>Molecular Pathology and cytogenetic Department, School of Medicine, Shiraz University of Medical Sciences, Shiraz, Iran.

**Introduction:** Schwannomas or neurilemmomas are uncommon benign neurogenic neoplasms that can stem from any peripheral, autonomic or cranial nerves except olfactory and optic nerve. Head and neck schwannoma approximately accounts for 25 to 40% of this benign neurogenic tumor. In contrary to well-description of acoustic nerve schwannoma facial nerve schwannomas are very few and rather unknown. Intraparotid facial nerve involvement by schwannoma is even rarer and represents only 10% of facial nerve schwannomas. Hereby, authors present a case of Intraparotid facial nerve schwannoma and discuss its presentation and management briefly.

**Case presentation:** Patient was a 41 year old man with a tiny infra-auricular mass for twenty years. The mass was painless and mobile for many years. Nevertheless, it became larger and reached a 2cm during 6 months. The frozen section revealed a benign neoplastic growth composed of wavy spindle cells with focal palisading in hypercellular areas (Antoni A) which were separated by myxoid hypocellular regions (Antoni B). As diagnosis was schwannoma, the mass was resected without sacrificing facial nerve.

Management of IPFNS is a matter of debate. Most leading factors that determine treatment strategy include preoperative facial nerve function, gross attachment of tumor to facial nerve defined as loosely attached or intertwined and finally location of tumor defined as intratemporal or exclusively intraparotid. Resection of intraparotid tumor is mainstay of treatment for separable and loosely attached tumors. Observation is preferred for inseparable intraparotid tumors whose facial nerve function is grade III/IV or better according to House Brackman classification. Finally, resection of mass and grafting is the method of choice for tumors that extend intratemporal region via stylomastoid foramen. Anyhow, if facial nerve function is desirable, tumor debulking, mastoidectomy and annual imaging can substitute the latter.

**Keywords:** Parotid Gland, Schwannoma.

# Case report of a gravid gigantomastia (gravid macromastia)

Tahereh Eslam-Manesh<sup>1</sup>

<sup>1</sup>Department of pathology, Rafsanjan University of Medical Sciences, Rafsanjan, Iran.

Breast enlargement during pregnancy is a physiological response to hormones to prepare for breast feeding. Rarely, in a limited number of the pregnant woman, the rapid and inappropriate growth result in a giant breast or gigantomastia. A 25-year-old pregnant woman with a lived 3-year boy presented with too big and fast-growing breasts with ulceration and necrosis of the covering skin, restriction of movement and activity, neck pain, fever and anemia. Due to uncontrollable her status, pregnancy was terminated. Also, she went under mastectomy. Again, Two years later she admitted with pregnancy and similar sign and symptoms in breasts, more severe in the left breast. In the third pregnancy despite numerous illnesses she continued the pregnancy and after the birth of her baby by cesarean section, she underwent mastectomy. She was not able to breastfeed. Grossly, huge breast with multiple areas of ulceration and necrosis of the overlying skin was evident. The cutting surface consists of multiple variable-sized cysts, filled with milky fluid and mucoid material. Microscopic examination revealed marked proliferation of the ducts and stroma. The ducts lined by two cell types. The stroma containing foci of acute and chronic inflammation and edema. With regard to the clinical data and macroscopic and microscopic findings the final diagnosis was gestational gigantomastia.

**Keywords:** Gravid gigantomastia , Gravid macromastia, Mastectomy, Breast, Pregnancy.

# The study of the rates of diabetes and hyperlipidemia in patients with lipoma referred to Ali-ebn abitaleb Hospital in Rafsanjan, 2013

Tahereh Eslam-Manesh<sup>1</sup>

<sup>1</sup>Department of pathology, Rafsanjan University of Medical Sciences, Rafsanjan, Iran.

**Introduction:** Lipomas are adipose tumours which are one of the commonest and most benign of all tumors. In some studies, increased rate of metabolic disorders such as diabetes and hyperlipidemia has been reported in patients with lipoma. The aim of this study was to determine the rate of diabetes and hyperlipidemia in people with and without Lipoma.

**Materials and Methods:** This cross-sectional study was performed on 100 people referred to Ali-ebn abitaleb hospital in Rafsanjan in two groups: with lipoma (n=50) and non lipoma (n=50) were matched for age and sex. After fasting and blood sampling of patients fasting blood glucose, total cholesterol, triglycerides, HDL and LDL were measured. The data was analyzed with SPSS software.

**Results:** The mean age of patients was 39 years. 21 cases were male (42 %) and 29 were female (58 %). In lipoma- group fasting blood glucose was normal in 30 cases (60%), 19 cases (38%) showed impaired fasting glucose and 1 case (2%) showed diabetes mellitus. In non-lipoma persons 32 cases (64%) showed normal fasting blood glucose and 18 cases (36%) presented with impaired fasting glucose. In lipoma-group one case (2%) showed normal level of triglycerid (<150), 3 cases (6%) were borderline high (150-199) and 46 cases (92%) were high (200-449). In non-lipoma group 5 cases (10%) showed borderline high triglyceride and 45 cases (90%) had high triglycerides. The total number of lipoma-group presented with high cholesterol level ( > 240). In the control group 1 case (2%) showed desirable (<200) and 49 cases (98%) showed high level of cholesterol. All 50 cases in lipoma-group showed borderline high level of LDL (130-159). In the control group 1 case (2%) showed optimal LDL (<100), 4 people (8%) near optimal (100-129) and 45 (90%) had borderline high. 27 cases (54%) in lipoma-group showed low HDL (<40) and 23 cases (46%) showed high HDL ( > 60). The control group showed low HDL in 35 cases (70%) and high HDL (30%) in 15 cases.

**Conclusion:** This study showed no higher prevalence of diabetes and hyperlipidemia in patients with lipoma compared with non-lipoma persons. Study with a larger sample is recommended for more definitive conclusions.

**Keywords:** Lipoma, Diabetes, Hyperlipidemia.

# Investigation nicotine-induced drug resistance effect using MTT assay in MCF-7 breast cancer cell line

Mojde Esmaeili<sup>1</sup>, Hosein Ali Sasan<sup>1</sup>, Saeed Esmaeili Mahani<sup>1</sup>, Sedighe Gharbi<sup>1</sup>, Fatemeh Jafari<sup>1</sup>, Hamze Pasban<sup>1</sup>

<sup>1</sup>Department of Biology, Faculty of Science Shahid Bahonar University of Kerman, Kerman, Iran

**Introduction:** Cancer is a deadly disease and the second leading cause of death, after cardiovascular diseases in the world. Breast cancer is the most common known cancer in women with its resistance to the current therapeutics, is an important clinical challenge. Nicotine, the major addictive compound in cigarette smoke, is a carcinogen that causes cancer and is known to induce drug resistance in some cancer cells. There are strong epidemiological evidences which smoking as a risk factor of lung cancer and other cancer such as breast cancer. Here, we examined nicotine effect in MCF-7 breast cancer cells and we showed nicotine induced drug resistance using MTT assay. However, the underlying mechanisms are not fully understood.

**Materials and Methods:** To evaluate drug resistance affected nicotine, firstly MCF-7 cells were grown in DMEM high glucose medium supplemented with 10% fetal bovine serum, and 1% antibiotic. Then were treated with 100 $\mu$ L of nicotine. After 72 h these cells were treated with 1-10  $\mu$ g/ml of doxorubicin. Finally Cell viability was determined using MTT assay.

**Results:** Our study showed that according to the doses of doxorubicin, doxorubicin has cytotoxic effects and causes cell death, but the cells that were treated with nicotine, the cell survival increase and significant induction of drug resistance ( $P < 0.05$ ) is seen.

**Conclusion:** Our study suggested that nicotine as a major compound in tobacco through biological different processes, leading to resistance to doxorubicin-induced cell death.

**Keywords:** Breast cancer, Nicotine, Drug resistance, MTT assay.

## Study of sub-acute toxicity of *Rosa damascena* methanolic extract in rats

A. Gholamhosseinian<sup>1</sup>, M. Samareh Salavati<sup>2</sup>, F. Shadkam<sup>2</sup>, H. Fallah<sup>1</sup>, S. Rahemi<sup>1</sup>

<sup>1</sup>Department of Biochemistry, Medical School & Kerman Physiology Research Center, Kerman University of Medical Sciences, Kerman, Iran. <sup>2</sup>Department of Hematology and Laboratory Sciences. Faculty of Allied Medicine, Kerman, Iran.

**Introduction:** *Rosa damascena* has been used with the medical purposes. Biological effects of *Rosa damascena* were studied due to its widespread consumption in Iran. Therefore, this study aimed to investigate the toxicity effects of *Rosa damascena* on various factors such as weight of some organs, hematologic factors, renal and hepatic markers.

**Method:** In this study, 16 male wistar rats were divided randomly into two groups. Control group were received routine care and *Rosa damascene* group were received methanolic extract of *Rosa damascena* flowers (1gr/kg body weight) for 14 days. At the end of this period, after 14 h fasting, animals were anesthetized and blood and organs were collected.

**Results:** Our results showed that *Rosa damascena* has no effect on the weight of organs and hematological factors; however it has a little effect on the number of platelets and decreases them. Results of this study suggest, extracts of *R. damascena* flowers improves the level of serum electrolytes and hematological derangements.

**Conclusion:** Our results suggest that *Rosa damascena* has no sub-acute toxicity and can use for different cases.

**Key Words:** Rosa damascene, Sub-acute toxicity.

# **The agreement between fine needle aspiration cytology results with histopathologic reports in patients with surgically removed thyroid nodules referred to Urmia Imam Khomeini hospital**

Farzaneh Hosseini Gharalari<sup>1</sup>, Samira Mahmoudi<sup>2</sup>

<sup>1</sup>Pathology Department, Urmia University of Medical Sciences, Urmia, Iran. <sup>2</sup>Urmia University of Medical Sciences, Urmia, Iran.

**Introduction:** Thyroid nodules are the most common presentation of thyroid diseases with 4-7% prevalence and their assessment is important, because both benign and malignant lesions are presented as nodules and only few are malignant and need surgical intervention. Fine needle aspiration cytology (FNAC) has been recommended as the gold standard diagnostic procedure before surgery due to its cost-effectiveness.

**Materials and Methods:** Thyroid FNAC and surgical pathology reports from April 2009 until April 2014 in Pathology department of Urmia Imam Khomeini hospital were studied and the cases with both reports were selected. FNAC results were divided into: benign, malignant, indeterminate and inadequate specimen groups. Pathology results were divided into: benign and malignant groups.

**Results:** Seventy patients with both FNAC and surgical pathology reports were included in this study. The age range was between 21 to 77 years old ( $46.1 \pm 13.3$ ). Sixty one cases (87.1%) were female and 9 cases (12.9%) were male. Thirty nine (55.7%) FNAC results were benign, 8 (11.4%) malignant, 16 (22.9%) indeterminate and 7 (10%) cases were inadequate for diagnosis. Forty six (65.7%) surgical pathology reports were benign and 24 (34.3%) were malignant. Concordance coefficient of Kappa was 60%.

**Conclusion:** Since thyroid FNAC samples are sometimes inadequate for diagnosis and some of them are indeterminate and regarding the coordination found in Kappa test, Both FNAC and histopathologic evaluation of thyroid nodules are necessary, especially in these two conditions and these two methods have high diagnostic value when used together.

**Keywords:** Thyroid nodule, Fine needle aspiration, Cytology, Histopathology.



# **The introduction of ellagic acid as the active ingredient in pomegranate juice for the treatment of Aphthous stomatitis**

Atefeh Iranmanesh<sup>1</sup>

<sup>1</sup>BSc of cellular and molecular of biology – Biotechnology, Azad university, Kerman , Iran.

Aphthous stomatitis (Canker sore) is a common oral disease with different causes. This disease is associated with pain and burning in the mouth and tongue and eating and drinking acidic foods, increases the burning. Drug therapy usually involves the use of antibiotics and local anesthetics in the area of canker sore. In traditional therapy, the use of Pomegranate juice has been recommended in the treatment of this disease. Pomegranate juice, despite having vitamins and protein, has a phenol called ellagic acid which is in addition to pomegranate juice, to be found in pomegranate seed oil. Plants hydrolyzed tannins to produce this material. In fact, It is antioxidants that found in fruit and vegetables. The antioxidant mechanism of action of this substance, its role in oxidative stress reactions. It can be used as reducing free radicals and prevents the creation of mutations affecting DNA binding to cells. It also has an impact on the in their tissues, can prevent the spread and its infection. In the treatment of canker sore of the mouth, it is recommended that pomegranate juice can be used as a mouthwash.

**Keywords:** Ellagic acid, Aphthous stomatitis, Oxidative stress reactions.

# Angiogenesis effect of human amniotic membrane graft in an experimental defect of dog esophagus

Fattah Iranmanesh<sup>1</sup>, Alireza Farsinezhad<sup>2</sup>, Sara Rostami<sup>1</sup>, Shahriar Dabiri<sup>2</sup>, Omid Azari<sup>1</sup>, Reza Kheirandish<sup>3</sup>

<sup>1</sup>Department of Clinical Sciences, Faculty of Veterinary Medicine, Shahid Bahonar University of Kerman.

<sup>2</sup>Department of Pathology, School of Medicine, Kerman University of Medical Sciences, Kerman, Iran.

<sup>3</sup>Department of Pathobiology, Faculty of Veterinary Medicine, Shahid Bahonar University of Kerman, Iran.

**Introduction:** Complete regeneration is the major goal of esophageal wound treatment. Desired regenerative outcome have not been achieved by none of the current treatments. Recently, there is a growing tendency toward application of human amniotic membrane (HAM) as a biologic substitute for wound healing. Amniotic membrane, the inner layer of the human placenta, is rich in growth factors, proteins and stem cells. So, it can potentially be useful in tissue regeneration. Reconstruction of the esophagus is difficult due to the segmental blood supply and lack of serosa. So, successful and complete regeneration is continued to be the major goal of esophageal wound repairmen. This study was designed to evaluate angiogenesis effect of xenograft Human amniotic membrane (HAM) in enhancing the healing process of the esophagus wounds.

**Materials and Methods:** Twelve healthy, male, mongrel dogs approximately 1 year old at weight range of 20±5 kg were used in this study. Surgical defects (2 cm-longed) were created in the proximal aspect of cervical esophagus. In the AM group (n=8), amniotic membrane graft were placed on the esophageal defect and sutured with standard patern, a subgroup of 4 dogs (AM 1 group) was sacrificed on day 30 and the other 4 animals (AM 2) kept alive until 45 days. Control groups (control 1 and 2) were considered the same as treatment group of AM 1 and AM 2 with no treatment. Specimens were fixed with 10% buffered formalin (Merck) for 14 days. Histological assessments were performed by a masked pathologist under a light microscope (BX 51, Olympus, Japan).

**Results and discussion:** The significant role of growth factors in wound healing has been well determined. So, it is announced that local administration of growth factors can potentially be useful in tissue regeneration. One of the primary challenges in the repair of esophagus is growth factors supply. The HAM is an abundant birthing tissue that due to its unique structure, composition and neonatal derivation, had promising results when used in a number of tissue repair applications. We aimed to determine whether grafts of AM, a readily disposable and low cost material with previous clinical experience in humans, would be able to heal and remodel esophageal wound. Histological analysis exhibited re-epithelialization, angiogenesis and granulation tissue. We conclude that AM accelerates esophageal wound healing due to angiogenesis effects, but because of the residue of HAM even after 45 days, its benefit become guarded.

**Keywords:** Wound healing, Amniotic membrane, Esophagus, Dog.

# Reevaluation of diagnosed Nodal Lymphoma based on new WHO classification in Kerman/Iran

Maryam Iranpour<sup>1</sup>, Harold Stein<sup>2</sup>, Hamid Tabrizchi<sup>1</sup>, Shahriar Dabiri<sup>1</sup>, Roshanak Boub<sup>2</sup>, Behjat Kalantari-Khandani<sup>3</sup>, Vahid Moazed<sup>3</sup>, Ali Nemati<sup>3</sup>, Bahram PourSeyedi<sup>4</sup>, Hamid Zeinali Nejad<sup>4</sup>, MohammadHasan Larizadeh<sup>5</sup>

<sup>1</sup>Department of Pathology, Afzalipour Medical School, Kerman, Iran. <sup>2</sup>Department of Pathology, Berlin Medical School, Germany. <sup>3</sup>Department of Oncology, Kerman University of Medical Sciences, Kerman, Iran. <sup>4</sup>Department of Surgery, Kerman University of Medical Sciences, Kerman, Iran. <sup>5</sup>Department of Radiotherapy, Kerman University of Medical Sciences, Kerman, Iran.

**Introduction:** Evaluation of the 133 cases of Nodal Lymphoma according to the new WHO classification (IHC, FISH and cytogenetic methods)

**Materials and Methods:** In this study, 133 cases of malignant lymphomas in Kerman, from 1380-1388, were investigated; with supervision and supporting of Berlin Medical School, Germany. They were classified according to WHO classification. The primary diagnosis was based on formalin fixed paraffin sections, stained with H&E. In all cases immunohistochemical study were done. Cases with inconclusive morphological and immunohistochemical findings were additionally analyzed for the presence of clonally rearranged of immunoglobulin heavy chain genes (*IgH*) and T-cell receptor gamma (*TCRG*) chain genes by polymerase chain reaction (PCR). The cases with diagnosis of follicular lymphoma, Burkitt lymphoma and atypical Burkitt lymphoma were subjected to interphase FISH.

**Results:** Hodgkin lymphoma were 37% and non Hodgkin lymphoma 63%. Non Hodgkin lymphoma included B cell lymphoma (74%) and T cell lymphoma (26%). The most frequent form of classic Hodgkin lymphoma was Mixed cellularity (41%) and high correlation with Epstein-Barr-Virus is seen in lymphocytic rich. Non Hodgkin lymphoma classification according to subtype were Diffuse large B-cell lymphoma (24%), Follicular lymphoma (23%), T Lymphoblastic Leukemia/Lymphoma (13%), Burkitt's lymphoma (8%), Anaplastic large cell lymphoma (8%), Chronic Lymphocytic Leukemia/Small Lymphocytic Lymphoma (7.2%), B Lymphoblastic Leukemia/Lymphoma (3.6%), Peripheral T-cell lymphoma (2.4%), Angioimmunoblastic T-cell lymphoma (2.4%), Mantle cell lymphoma (2.4%) and one case (1.2%) from each one of the following subtypes: Multiple Myeloma, Plasmacytoma, Plasmablastic lymphoma, Hairy cell leukemia and Low grade B cell lymphoma, unclassified. In cases of Diffuse Large B-cell Lymphoma; 4 cases were Germinal center B-cell like (GCB) and 7 cases were Non germinal center B-cell like (non-GCB) and 2 cases were Activated B-cell like (ABC). Most of Follicular Lymphoma in Kerman were high grade with CD10-/ BCL6+/ MUM1+ and High MIB1. No translocation (14/18) was seen. Half of Burkitts lymphoma show IGH/MYC fusion.

**Conclusion:** The most interesting findings comparing with previous reports from Kerman found by Berlin group as: Most of Follicular Lymphoma were high grade without translocation (14/18). High correlation with Epstein-Barr-Virus is seen in lymphocytic rich Hodgkin lymphoma. Half of Burkitts lymphoma show IGH/MYC fusion.

**Keywords:** Nodal lymphoma, Kerman, IHC, FISH, PCR.

# **A case report of atypical pityriasis rosea with unilateral presentation**

Iraj esfandiarpour<sup>1</sup>, Hoda Badakhsh<sup>1</sup>, Fahameh Fadaei<sup>1</sup>

<sup>1</sup>Department of dermatology , Afzalipour hospital, Medical University of Kerman, Kerman, Iran.

A case report of atypical pityriasis rosea with unilateral presentation Iraj esfandiarpour, Hoda Badakhsh, Fahameh Fadaei Pityriasis rosea (PR) is an acute, self-limiting disease, probably infective in origin, affecting mainly children and young adults, and characterized by a distinctive skin eruption and minimal constitutional symptom. It is characterized by the initial eruption of a Herald patch, which is followed by generalized scaly oval eruptions typically on the trunk and proximal extremities along the Langer's lines of cleavage, giving the characteristic "christmas tree appearance". PR may be atypical in the lesions or in its course. Atypical case of pityriasis rosea are fairly common and less readily recognized than typical eruptions, and may pose a diagnostic challenge. Here we represent a case of atypical pityriasis rosea with a sudden onset of several asymptomatic, erythematous and scaly plaques on her trunk and unilaterally (right side) distribution biopsy from representative lesions showed focal parakeratosis, mild epidermal hyperplasia and spongiosis, extravasation of RBC around superficial vascular structures and mild perivascular lymphocyte infiltrate. Atypical cases of PR are fairly common and less readily recognized. Careful history, clinical evaluation and follow-up are important to avoid misdiagnosis of PR and physicians should be aware of PR variants so that appropriate management and reassurance can be offered. For atypical eruptions without a definite diagnosis, it is safer to consider lesional skin biopsy.

**Keywords:** Atypical pityriasis rosea.

# Investigation of nicotine-induced drug resistance effect on apoptotic protein p53 expression in MCF-7 breast cancer cell line

Fatemeh Jafari<sup>1</sup>, Hosein Ali Sasan<sup>1</sup>, Saeed Esmaeili Mahani<sup>1</sup>, Sedighe Gharbi<sup>1</sup>, Mojde Esmaeili<sup>1</sup>, Hamze Pasban<sup>1</sup>

<sup>1</sup>Department of Biology, Faculty of Science, Shahid Bahonar University of Kerman, Kerman, Iran

**Introduction:** Nicotine, a main addictive compound in tobacco smoke, has been linked to promotion and progression of lung and breast cancer. According to epidemiological studies, about 30% of cancer deaths every year in the United States are associated with exposure to tobacco smoke or tobacco products, indicating the importance and urgency for cessation of active and passive cigarette smoke. Evidence has been emerging for the increasing breast cancer risk associated with tobacco smoke exposure. Breast cancer is the most common malignancy and the second leading mortality within all kind of cancer in women. Drug resistance is a major obstacle in systemic treatment of advanced or metastasis breast cancer, which leads to incontrollable disease state and mortality. Furthermore, the anti-apoptotic property of nicotine in breast cancer cells has been demonstrated that it may change p53 protein expression. Here, we evaluate that nicotine-induced drug resistance in MCF-7 breast cancer cell line can effected on apoptotic protein p53 expression.

**Materials and Methods:** To evaluate protein expression, the treated MCF-7 cells with nicotine (100  $\mu$ L), were cultured and then total protein was extracted and changes of p53 protein expression was determined by western blot assay.

**Results:** Our results demonstrate that p53 expression evaluated by Western blotting analysis probably is not different between control and treated cells and nicotine affected in drug-resistance with another pathway.

**Conclusion:** However, further studies are necessary to evaluate the changes of p53 expression in nicotine-induced drug resistance.

**Keywords:** Nicotine, Breast cancer, Drug resistance, Anti-apoptotic.

# Primary hydatid cyst of the neck, diagnosed in frozen section

Elham Jafari<sup>1</sup>, Mahdieh shokrizadeh<sup>1</sup>, Mohsen shahba<sup>2</sup>, Shahriar Dabiri<sup>1</sup>

<sup>1</sup>Department of Pathology, Kerman University of Medical Sciences, Kerman, Iran. <sup>2</sup>Department of Neurosurgery, Kerman University of Medical Science, Kerman, Iran.

**Introduction:** Hydatid cyst, the disease develops as a slow growing cyst found in patients that are infected with echinococcosis, also known as hydatidosis. *Echinococcus granulosus* is the most common *Echinococcus* species affecting humans, due to dog tapeworm in larval or cystic stage. Echinococcosis can involve any organ. The liver is the most common organ involved, followed by the lungs. These two organs account for 90% of cases of echinococcosis. Hydatid cyst in the head and neck is rare, only a few cases have been reported in the literature. Our case is an unusual location of hydatidosis even in countries where echinococcal infection is endemic. We report a 15-year-old girl presenting with an asymptomatic cervical cyst. Cervical computed tomography scan findings reveal a benign congenital cyst, but frozen section shows hydatid cyst.

**Keyword:** Hydatid cyst, Echinococcosis, Computed tomography scan, Frozen section.

---

# Comparison and Characterization of mesenchymal stem cells from human dental pulp and human oral epithelial

Saleh Jahanshahi<sup>1</sup>, Mohammad Amin Edalatmanesh<sup>2</sup>, Ali Reza Farsinejad<sup>3</sup>

<sup>1</sup>Department of Physiology, College of Sciences, Fars Science and Research Branch, Islamic Azad University, Fars, Iran. <sup>2</sup>Department of Physiology, College of Sciences, Shiraz Branch, Islamic Azad University, Shiraz, Iran. <sup>3</sup>Pathology and Stem Cell Research Center, Kerman University of Medical Sciences, Kerman, Iran.

**Introduction:** The identification and characterization of stem cells is a major focus of developmental biology and regenerative medicine. Human dental stem cells have high proliferative potential for self-renewal that is important to the repair capacity of the tissue. The aim of this study was to isolate human dental pulp stem cells (DPSCs) and human oral epithelial stem cells (OESCs) regarding to their potential role in tissue regeneration.

**Materials and Methods:** The postnatal stem cells were isolated from dental pulp and oral epithelial seeded in -MEM with 20% fetal bovine serum (FBS). To investigate the mesenchymal nature of cells, differentiation potential along osteoblastic and adipogenic lineages was done. Nanog gene expression profile were analysed with Real time-PCR in mesenchymal stem cells derived from Dental pulp, oral epithelial and bone marrow.

**Results:** The isolated cell populations have similar fibroblastic like morphology. These cells were capable of differentiating into osteocyte and adipocyte. Real-time PCR for NANOG and ACTB genes showed positive expression of this genes in all both isolated cell types. Dental pulp and oral epithelial stem cells have a similar potency as that of bone marrow derived mesenchymal stem cells. Oral epithelial stem cells showed more nanog gene expression than dental pulp stem cells.

**Conclusion:** DPSCs and OESCs exist in various tissues of the oral cavity and can use as a source of mesenchymal stem cells for developing bioengineered organs and also in craniomaxillofacial reconstruction with varying efficiency in differentiation and proliferation.

**Keywords:** Dental pulp, Oral epithelial, Mesenchymal stem cells.

# **A review of molecular diagnostic methods in pathology: Polymerase chain reaction and in situ hybridization**

Mahsa kalantari<sup>1</sup>, Parisa Kalantari<sup>2</sup>

<sup>1</sup>Department of Oral and Maxillofacial Pathology, School of Dentistry, Kerman University of Medical Sciences, Kerman, Iran. <sup>2</sup>Department of Orthodontics, School of Dentistry, Kerman University of Medical Sciences, Kerman, Iran.

The advent of the polymerase chain reaction (PCR) radically transformed biological science from the time it was discovered. For the first time, PCR allowed for specific detection and production of large amounts of DNA. The technique is widely used by clinicians and researchers to diagnose diseases, clone and sequence genes, and carry out sophisticated quantitative and genomic studies in a rapid and very sensitive manner. One of the most important medical applications of the classic PCR method is detection of pathogens. In addition, the PCR assay is used in forensic medicine to identify criminals. Modified versions of PCR have allowed quantitative measurements of gene expression with techniques called real-time PCR.

In situ hybridization (ISH) consists of the detection of specific DNA or RNA sequences in tissue sections or cell preparations using a labeled complementary nucleic acid sequence or probe. Under the appropriate conditions, this probe will hybridize to the target DNA or RNA and be visualized by either radioactive, nonradioactive or fluorochrome labels incorporated into the probe. ISH has mainly been used for the detection of viral infections, gene expression by neoplasms and genetic alterations in tumors. Because of the widespread use of these methods, it is important to understand the basic principles of them and their applications.

**Keywords:** In situ hybridization, Polymerase chain reaction, Molecular methods.



# **Clinicopathologic evaluation of salivary gland neoplasms in Iran: Review of the literature**

Mahsa kalantari<sup>1</sup>, Molouk Torabi<sup>1</sup>, Parisa Kalantari<sup>2</sup>

<sup>1</sup>Department of Oral and Maxillofacial Pathology, School of Dentistry, Kerman University of Medical Sciences, Kerman, Iran. <sup>2</sup>Department of Orthodontics, School of Dentistry, Kerman University of Medical Sciences, Kerman, Iran.

Neoplasms of salivary gland origin are very rare, accounting for less than 1% of all tumors and 3% to 5% of head and neck neoplasms. These tumors occur commonly in the parotid gland, but other major and minor salivary glands also may be affected.

The clinicopathologic features of these tumors including patient age and sex, tumor location, and distribution are imperative for accurate diagnosis and management and vary with race and geographic location. Due to their difficult diagnosis, management and unpredictable clinical course of disease epidemiologic studies of these tumors are an important part of the oral and maxillofacial pathology and their varied occurrences in the population have been the focus of several studies. This paper reviews the published English literatures about the clinicopathologic features of salivary gland neoplasms in Iranian population.

**Keywords:** Salivary gland neoplasms, Benign tumors, Malignant tumors, Incidence, Iran.

# **Carcinosarcoma de novo of the parotid gland; an unusual case report**

Karimi A<sup>1</sup>, Aghai A<sup>1</sup>, Saffar H<sup>2</sup>, Etebarian A<sup>3</sup>

<sup>1</sup>Department of oral and maxillofacial surgery, School of dentistry, Tehran University of Medical Sciences, Tehran, Iran. <sup>2</sup>Department of pathology, Shariati Hospital, Tehran University of Medical Sciences, Tehran, Iran. <sup>3</sup>Department of oral and maxillofacial pathology, School of dentistry, Alborz University of Medical Sciences, Karaj, Iran.

True malignant mixed tumors of the salivary gland (Carcinosarcoma) are extremely rare tumors composed of both carcinomatous and sarcomatous components. This report presents the clinical, histological, surgical and imaging findings of a carcinosarcoma arising in both superficial and deep portions of left parotid in an 18-year old young man. He underwent parotid mass excision and 30 sessions of chemotherapy and developed a local recurrence at the surgical site after 3 months of the original diagnosis. Subsequently, a radical parotidectomy with radical neck dissection was performed and the patient is being followed on regular basis for any recurrences or metastasis. Pathologic evaluation revealed biphasic population of tumor cells including sheets of atypical cells with large vesicular nuclei mixed with spindle cells embedding in a chondromyxoid background. With regard to histopathogenesis, based on the lack of histopathological evidence and antecedent history of pleomorphic adenoma, we consider the present case to be de novo, not an ex-PA.

**Keywords:** Carcinosarcoma, Salivary gland neoplasm, Parotid gland, Total parotidectomy.

# Neuroprotective effects of *Pimpinella anisum* in rat brain

Fariba Karimzadeh<sup>1</sup>, Mahmoud Hosseini<sup>2</sup>

<sup>1</sup>Cellular and Molecular Research Center, Iran University of Medical Sciences, Tehran, Iran. <sup>2</sup>Mashhad University of Medical Sciences, Mashhad, Iran.

**Introduction:** Essential oil of *Pimpinella anisum* L. Apiaceae (anise oil) has been widely used in traditional Persian medicine to treat a variety of diseases, including some neurological disorders. This study was aimed to test the possible anti-seizure and anti-hypoxia effects of anise oil.

**Materials and Methods:** The effects of different concentrations of anise oil were tested on seizure attacks induced by pentylenetetrazol (PTZ) injection and neuronal hypoxia induced by oxygen withdrawal as well as on production of dark neurons and induction of long-term potentiation (LTP) in in vivo and in vitro experimental models of rat brain.

**Results:** Anise oil significantly prolonged the latency of seizure attacks and reduced the amplitude and duration of epileptiform burst discharges induced by injection of intraperitoneal PTZ. In addition, anise oil significantly inhibited production of dark neurons in different regions of the brain in epileptic rats. Anise oil also significantly enhanced the duration of the appearance of anoxic terminal negativity induced by oxygen withdrawal and inhibited induction of LTP in hippocampal slices.

**Conclusions:** Our data indicate the anticonvulsant and neuroprotective effects of anise oil, likely via inhibition of synaptic plasticity. Further evaluation of anise oil to use in the treatment of neurological disorders is suggested.

**Keywords:** Apoptosis, Damage, Neuroprotective.

# Behavioural and histopathological assessment of the effects of periodic fasting on pentylenetetrazol-induced seizures in rats

Fariba Karimzadeh<sup>1</sup>, Marzieh Gharakhani<sup>2</sup>, Soodeh Razeghi Jahromi<sup>2</sup>

<sup>1</sup>Cellular and Molecular Research Center, Iran University of Medical Sciences, Tehran, Iran. <sup>2</sup>Tehran University of Medical Sciences, Tehran, Iran.

**Introduction:** Periodic fasting (PF) was suggested to display antiepileptic and neuroprotective effects, which is in stark contrast to severe fasting or starvation. However, these beneficial effects seem to depend on the type and duration of the used feeding protocol. There are discrepancies concerning both antiepileptic and neuroprotective effects of a PF-diet during repetitive seizures in different epilepsy models. This study was designed to evaluate the effects of different PF protocols on behavioural and histopathological consequences of epilepsy in adult rats.

**Materials and Methods:** Recurrent generalized seizures were caused by repetitive injection of pentylenetetrazol (PTZ) for a period of 4 weeks every other day. While control animals had free access to food and water, animals on a Pf diet were on intermittent fasting for 24 hours every 48 hours for 4 weeks before (T1), after (T2), or both before and after (T3) the injection of PTZ. Behavioural studies were carried out after PTZ injections and histological investigations were performed after the experiments were completed.

**Results:** Seizure assessment showed that the severity of seizures was significantly decreased in groups T1 and T3 when compared with control rats. Dark neuron densities in hippocampal CA1 and CA3 areas were decreased in PF groups, but never in the temporal cortex. The PF-diet also decreased the number of terminal deoxynucleotidyltransferase-mediated dUTP nick end-labelling-positive neurons in the hippocampus in both areas and all PF-diet protocols.

**Conclusion:** These results support the idea that a PF-diet has anticonvulsive and neuroprotective effects on epileptic rats but underlines that different PF-diet protocols can have varying effects. Anticonvulsive effects were strongest when the PF-diet started before the onset of excitotoxic injuries, the number of dark neurons was decreased and apoptosis was prevented by all PF-diet protocols investigated in this work. Further evaluation of PF-diet protocols for possible clinical anticonvulsant and neuroprotective effects is suggested.

**Keywords:** Antiepileptic, Neuroprotective, Apoptosis.

# The Prevalence of Methylenetetrahydrofolate Reductase Polymorphisms in Iranian Patients with Glanzmann's Thrombasthenia

Shima Kazemzadeh<sup>1</sup>, Rezvan Mohammadi<sup>2</sup>, Fatemeh Shadkam Farokhi<sup>2</sup>, Alireza Farsinejad<sup>3</sup>,  
Fereidoon Ala<sup>4</sup>

<sup>1</sup>Cardiovascular Research Center and Department of Pathology, Kerman University of Medical Sciences, Kerman, Iran. <sup>2</sup>Physiology Research Center, Kerman University of Medical Sciences, Kerman, Iran. <sup>3</sup>Pathology and Stem Cell Research Center, Kerman University of Medical Sciences, Kerman, Iran. <sup>4</sup>Iranian Comprehensive Hemophilia Care Centre, Tehran, Iran.

**Introduction:** Methylenetetrahydrofolate reductase (MTHFR) is one of the main enzymes involved in Homocysteine metabolism which plays a significant role in the production of endogenous folic acid. The polymorphisms identified in MTHFR gene reduce the activity of this enzyme and increase the risk of venous and arterial thrombosis. There are limited investigations regarding the effects of thrombogenic polymorphisms on the clinical phenotypes of rare hereditary hemorrhagic disorders like Glanzmann's thrombasthenia (GT). This signifies the necessity of further studies in populations with a larger number of patients.

**Materials and Methods:** In the present case-control study, we evaluated 65 patients with GT and 100 normal volunteer blood donors (as the control group). The detection of MTHFR 677C>T, 1298A>C polymorphisms was conducted using PCR-RFLP method. According to GLanzmann's Thrombasthenia Italian Team (GLATIT) Protocol, the severity of bleeding in the patients was also determined.

**Results:** Based on our results, there was no significant statistical difference in prevalence of MTHFR 677C>T polymorphism (P=0.703) and MTHFR 1298A>C polymorphism (P=0.187) between patients and the control group. In addition, we found no association between severity of bleeding and aforementioned polymorphisms (P=0.385).

**Conclusion:** We concluded that, the thrombogenic mutations of MTHFR could not solely modulate the severity of clinical symptoms in patients with GT.

**Keywords:** Glanzmann's thrombasthenia, Methylenetetrahydrofolate reductase, Polymorphism.

# The study of Opium-induced apoptosis of tumor cell lines under laboratory conditions

Morteza Khaleghimahani<sup>1</sup>, Alireza Farsinejad<sup>1</sup>, Mahsa Ziasistani<sup>1</sup>, Ehsan Salarkia<sup>2</sup>, Gholamreza Asadikaram<sup>3,4</sup>

<sup>1</sup>Pathology and Stem Cell Research Center, Afzalipour Kerman University of Medical Sciences, Kerman, Iran. <sup>2</sup>Department of Biology, Faculty of Science, Karaj Branch, Islamic Azad University, Karaj, Iran. <sup>3</sup>Endocrinology and Metabolism Research Center, Institute of Basic and Clinical Physiology Sciences, Kerman University of Medical Sciences, Kerman, Iran. <sup>4</sup>Department of Biochemistry, Faculty of Medicine, Kerman University of Medical Sciences, Kerman, Iran.

**Introduction:** The programmed cell death or apoptosis can be triggered by a variety of internal and external stimuli. Previous studies have shown that opium and some of its derivatives cause programmed death of certain cells. The current study is aimed at investigation of the opium effects on the apoptosis of different cell lines and compare such effects with one another.

**Materials and Methods:** The study is carried out on 3 cell lines (AA8, N2a, PC12). After preparation of stock solution,  $2.86 \times 10^{-4}$  g/ml of opium was added to culture medium. Cytotoxicity and apoptotic effect of opium on the cell lines, after 48 hours, were evaluated by 3-[4,5-dimethylthiazol-2-yl]-2,5-diphenyltetrazolium bromide (MTT) assay and Annexin-PI method, respectively.

**Results:** The results of this study showed that opium with concentration of  $2.86 \times 10^{-4}$  g/ml after 48 hours significantly induces apoptosis in certain cell lines (i.e. AA8, N2a), apoptosis and necrosis in other cell line (i.e. PC12). Furthermore, apoptotic and/or necrotic effects of opium is cell-type specific and various tissues have different sensitivity to opium.

**Conclusion:** Therefore, one could infer that the usage of opium with different levels in different tissues leads to certain disorders in some tissues and may have therapeutic effects under distinctive conditions (i.e. unchecked growth of cells) as confirmed by the results.

**Keywords:** Opium, Apoptosis, Necrosis, Cell lines.

## Skin Metastasis of breast cancer as a presenting sign: A case report

Maryam khalili<sup>1</sup>, Mahin Aflatoonian<sup>1</sup>, Alireza Zaynaldinimeymand<sup>2</sup>, Rahim Ahmadi<sup>2</sup>, Niloofar Mehrolhasani<sup>2</sup>, Simin ShamsiMeymandi<sup>3</sup>, Shahriar Dabiri<sup>4</sup>

<sup>1</sup>Assistant professor of dermatology, Department of Dermatology, Kerman University of Medical Sciences, Iran. <sup>2</sup>Resident of dermatology, Kerman University of Medical Sciences, Iran. <sup>3</sup>Professor of dermatology, Pathology and Stem Cell Research Center, Kerman University of Medical Sciences, Iran. <sup>4</sup>Professor of Pathology, Pathology and Stem Cell Research Center, Kerman University of Medical Sciences, Iran.

**Introduction:** Breast cancer is the most frequently neoplasm in women and it is also the second cause of death results from cancer in female. It includes nearly three quarter of the skin metastasis in women. Skin metastasis is seen in nearly 6% of the breast cancers and half of this rate has skin involvement as presenting sign. Regions of metastasis of breast cancer are most common in pulmonary, bone, liver, adrenal, brain, skin and kidney. Skin metastasis of breast cancer frequently seen in the site of previous mastectomy, other sites of metastases includes anterior side of the chest, axillary, back, scalp and supraclavicular<sup>4</sup>. Here, we are going to present a woman with metastatic breast cancer as a presenting sign.

**Case report:** A 32 -year -old woman referred to dermatology clinic with a painless firm erythematous nodule in upper right quadrant of right breast. She had a history of the lesion development from a few months ago after pregnancy, during nursing period. Physical examination demonstrated a nodule with size nearly 2 cm<sup>2</sup> with skin retraction and adhering to underlying tissue. Also there were two smaller nodules in adjacent skin with firm consistency. Physical examination of left breast was normal but right breast had firm consistency. There was no lymphadenopathy or other remarkable sign in examination. We biopsied the lesion with suspect to skin metastasis that showed infiltration of different sized glands in the dermis by atypical epithelium and embedded in a desmoplastic stroma with areas of lymphatic evasion diagnosed as metastatic well differentiated breast carcinoma. Patient was referred to gynecologist for more evaluation. Unfortunately, we missed our patient follow up.

**Discussion:** Metastasis is development of a neoplastic lesion from an original neoplasm that is not adjacent to it. Skin metastasis is an indicative of progressive disease and usually has a poor prognosis. Skin metastasis related to breast cancer has various clinical presentations among other causes of skin metastasis. In nearly 80% of the cases presented as single or multiple infiltrated erythematous firm nodule or papule. Other presentations include telangectatic carcinoma (11%), erysipeloid or inflammatory (3%), encuirass carcinoma with peaud'orange appearance (3%), alopecia neoplastica (2%), zosteriform pattern (0.8%) , pigmented type and infermammary crease involvement. Metastasis of breast carcinoma is distributed through lymphatic or blood vessels or by direct extension. Most types of breast cancer occur throughlymphatic dissemination except alopecia neoplastica and eyelid metastasis that caused by hematogenous distribution. Erysipeloid type presented as erythematous inflamed plaque with elevated border and edema that can lead to skin retraction and tenderness or pruritus. Histology demonstrated dilated lymphatic vessels with cords of neoplastic cells within them. Encuriass type is appeared as sclerodermoid plaque as well as infiltrating neoplastic cells array in small groups or rows between fibrotic areas (Indian filing) without any inflammation. Telangectatic types are includes dilated lymphatic vessels and congestion of blood vessels that appeared as purple to red papule and vesicle. Eyelid involvement occurs as painless nodule or induration and swelling. Scalp involvement appeared as an annulare infiltrated plaque with cicatricial alopecia. Immunohistochemical study is positive for CK7 (cytokeratin), ER/PR (estrogen receptor/progesterone receptor), GCDFP-15(gross cystic disease fluid protein-15). Standard treatment for breast cancer and its metastasis is mastectomy and radiation therapy with or without adjuvant chemotherapy or hormonotherapy. Treatment modalities such as photodynamic therapy, interferon, topical miltefosine, ceramides and imiquimod have been used for skin metastasis.

**Keywords:** Skin Metastatic Breast Cancer, Presenting Sign.

# **Relapsing kaposivaricelliform eruption in a patient with darier disease: a case report and review of literature**

Maryam KhaliliMeybodi<sup>1</sup>, Hoda Badakhsh<sup>1</sup>, Mahin Aflatoonian<sup>1</sup>, Fahameh Fadaei<sup>1</sup>, Simin ShamsiMeymandi<sup>1</sup>

<sup>1</sup>Department of dermatology, Afzalipour hospital, Medical University of Kerman, Kerman, Iran.

**Introduction:** Kaposivaricelliform eruption is caused by viral infections such as herpes simplex in inflammatory skin disorders. Cell-mediated immunodeficiency and skin barrier disruption can predispose patients of this eruption. Here, we are going to present a known case of darier disease with relapsing kaposivaricelliform eruption in less than one month.

**Keywords:** Darier disease, Kaposivaricelliform eruption.



# Making up a new cost-effective cellular fibrin membrane

Seyedeh Mehrnaz Kouhbanani Nejad<sup>1</sup>, Farzaneh Armin<sup>1</sup>, Alireza Farsinejad<sup>2</sup>, Ali Derakhshani<sup>2</sup>,  
Saleh Jahanshahi<sup>2</sup>, Zahra Sheikh Shoaie<sup>2</sup>

<sup>1</sup>Department of Hematology and laboratory Sciences, Faculty of allied medicine, Kerman University of Medical Sciences, Kerman, Iran. <sup>2</sup>Pathology and Stem Cell Research Center, Kerman University of Medical Sciences, Kerman, Iran.

**Introduction:** Fibrin is a critical blood component that in physiological conditions plays an important role in tissue injuries since it acts as a support for the hemostatic plug, forming a protein mesh that results from the polymerization of fibrinogen. Because of this characteristic of fibrin, it has been used extensively as a biopolymer membrane in tissue engineering. In our study we composite a fibrin membrane derived from human plasma and made it cellular with rat skin fibroblasts to evaluate a new skin substitute in vitro.

**Materials and Methods:** According to primary cell culture method, a biopsy of rat skin were punched, then fibroblasts were isolated after 10 days by Trypsin enzyme. Harvested fibroblasts were placed on fibrin membrane, to evaluate adhesion and density of this biomaterial in vitro.

**Results:** Cultured fibroblasts were spindle shape morphologically and 2 days after placing them on fibrin membrane, they covered 40% of fibrin membrane surface. This cellular membrane had rational cellular density and viability.

**Discussion:** Various skin substitutes have been used in recent years such as amniotic membrane, synthetic polymer sheet, bovine and human dermal matrix, skin allograft/xenograft and synthetic skin substitutes like Hyalomatrix. One of these skin substitutes is fibrin membrane, that is cost-effective, readily available, resistant to infections and also it has the ability of cells adhesion. Our new cellular fibrin membrane has rational adhesion ability and viability for fibroblasts.

**Conclusion:** Fibrin membrane is a suitable and cost-effective skin substitute for wound healing.

**Keywords:** Fibrin membrane, Fibroblast, Skin substitute, Biomaterial.

**Evaluation of frequency of EBV, MpyV and MMTV infections in breast tissue with lymph nodes in patients with breast cancer after mastectomy, kerman.**  
**1390-91**

Mahdiye Lashkarizadeh<sup>1</sup>

<sup>1</sup>MD of pathology, Kerman University of Medical Science, Department of pathology.

**Introduction:** Breast cancer is the one of important causes of mortality in wemon. It is estimated 3% of mortalities is caused by breast cancer. Enviromental factors are of the most important causes in cancer. These environmental factors drives our attention to carcinogene viruses.

**Materials and Methods:** 100 pateints with breast cancer (Invasive, DCIS, DIN) and 100 intact women were studied and the pathologic samples were examined.

**Results:** 8 patienst (8%) from DNA of EBV in the samples of breast cancer and 10 patient (22%) in the samples of axillary lymph nodes was positive, 18 patient (18%) from EBER RNA in the samples of breast and 25 patient (55%) in axillary lymph nodes was positive.

**Conclusion:** The results show that EBV and MMTV are the most important viruses found in tumoral masses of breast.

**Keywords:** Breast cancer, EBV.

# Can immunohistochemistry markers predict the behavior of laryngeal squamous cell carcinoma

Maryam Maghbul<sup>1</sup>, Mohamad Javad Ashraf<sup>2</sup>, Negar Azarpira<sup>2</sup>

<sup>1</sup>Departments of Pathology, fassa University of Medical Sciences, fassa, Iran. <sup>2</sup>Departments of Pathology, shiraz University of Medical Sciences, shiraz, Iran.

**Introduction:** Ki67 and p53 expression in tumoral and nontumoral tissue of laryngeal squamous cell carcinoma were determined for the possible role of immunohistochemistry as a diagnostic aid in evaluating laryngeal biopsies.

**Materials and Methods:** Samples from 60 patients with primary laryngeal squamous cell carcinoma (SCC) were analyzed retrospectively. The uninvolved vocal cord was evaluated as a non-tumoral sample. Paraffin sections of tumors were immunohistochemically stained for p53 and Ki67 expression.

**Results:** Overall, p53 expression was found in 40 (66%) of the patients. There was a significant correlation among tumoral p53 expression and tumor location, tumor stage and lymph node involvement. Most grade I tumors had a Ki67 labeling index <50% and a labeling index 50 was found mainly in high-grade tumors. Tumoral Ki67 expression correlated significantly with tumor grade and mitotic count. There was no correlation between Ki67 labeling index and tumor region. In non-tumoral tissue, 95% of high-grade pre-neoplastic lesions revealed a high expression of Ki67. Non-tumoral p53 expression did not correlate with histological findings.

**Conclusion:** P53 and Ki67 expression in tumoral tissue may be a prognostic marker in patients with laryngeal SCC. Evaluation of the proliferative index in biopsy samples of dysplastic laryngeal mucosa is potentially useful for predicting the progression toward carcinoma.

**Keywords:** Immunohistochemistry markers, Larynx, Squamous cell carcinoma.

# Evaluation expression of pp65, Large T antigen and p53 genes and related viruses (JC, CMV) in Glioblastoma tissues

Reza Malekpour Afshar<sup>1</sup>, Hamid Reza Mollaei<sup>2</sup>, Bahare Zandi<sup>3</sup>

<sup>1</sup>Associated professor of pathology, Neuroscience Research Center, Kerman university of medical sciences, Kerman, IRAN. <sup>2</sup>Department of medical virology, Kerman University of medical sciences, Kerman, IRAN. <sup>3</sup>Resident of Pathology, Pathology and stem cell cancer research, Kerman University of medical sciences, Kerman, IRAN.

**Introduction:** Glioblastoma multiforme is the most aggressive of the gliomas, a collection of tumors arising from glia in the central nervous system. The association between human cytomegalovirus (HCMV) and JC virus with glioblastoma multiforme (GBM) is becoming a new concept. Our aim was to investigate the prevalence of HCMV and JC viruses in GBM among Iranian patients. Furthermore, in our study the expression rate of pp65, Large T antigen and p53 proteins were detected and their relation with GBM was evaluated.

**Materials and Methods:** We measured the presence of HCMV and JC viral genomes in GBM samples from Iranian patients. For determination expression level of pp65, p53 and large T-antigen mRNA, reverse transcription real time PCR (rReal Time PCR) was done.

**Results:** One hundred ninety-nine patients with GBM cancer were evaluated. Mean±SD of age for male was 50.01±19.5 and female was 50.72±19.63 years old. The P53 rate dramatically drops which suggests that the reduction in amount of p53 may involve in making tumors. Large T antigen expression is shown in JC positive samples. The PP65 antigen in the positive CMV and JC patients were observed.

**Conclusion:** The role of human cytomegalovirus (HCMV) and JC virus in the pathogenicity of glial tumours was reported. HCMV products and JCV with oncogenic potential can induces development of various tumors including medulloblastomas and glioblastomas. The JCV is producing early gene product, T-antigen, which has the ability to associate with and functionally inactivate well-studied tumor suppressor proteins including p53 and pRB.

**Keywords:** Glioblastoma, HCMV, JC Virus, P53, Large T Antigen.

# Ethical standards in human tissue research: Guidelines in Iran

Mobasher Mina<sup>1</sup>, Shakibi Mohammad Reza<sup>2</sup>

<sup>1</sup>Assistant Professor, Medical ethics and History of Medicine group in Traditional Medicine Faculty, and Deputy of Research Affairs in Medicine Faculty, Kerman University of Medical Sciences. <sup>2</sup>Associate Professor, Internal Medicine group, Dean of Medicine Faculty, Kerman University of Medical Sciences.

**Introduction:** In order to have an effective health research, ethical standards, which is an indispensable element should be taken into account; so that ethical standards in research have been developed in Iran. The strategic plan was designed to regulation research ethics in our country 20 years ago. In addition, editing National Ethical Guidelines for Biomedical Research and development of Research Ethics Committees at national level and universities in some common projects in 2005 were the most important of which to gain ethical standards in research.

**Materials and Methodes:** In this study, we aimed to critically review and introduce these guidelines in research into human organs and tissues, stem cells, gamete and embryo, and to clarify challenges in applying ethical standards in these studies. These guidelines which are available at the web site of Medical Ethics and Medical History Research Centre were revised by an expert team in Tehran University of medical sciences in 2013 and some of them translated to English and published in genuine journals.

**Results:** There are two parts in the ethical guidance of human tissues and organs research includes general and special guide. In general part, human dignity, ethical committee approved in these studies and privacy of participants were emphasized. Furthermore, special part administered ethical points of research into aborted fetus, human tissue from cadaver and living donor and bio-banks. Ethical guideline of stem cells research includes 19 items to present certain issues such as authorized resources of stem cells, participants' informed consent and confidentiality in this regard. Also, ethical topics in gamete and embryo research especially human dignity, informed consent and confidentiality were affirmed in it's guidance.

**Conclusion:** A noticeable factor leading to obtain ethical standards in our country is to improve the capacity and performance of researchers and to train scientists for ethical issues in research. In fact, the expert members of research centers should be familiar with ethical issues in human research implicate legal and regulatory concepts governing research. Above all, a systematic approaches and criteria for human tissues research, structure and methods could be perhaps reflective of the developed organization of ethical standards and regulatory suitable capacities in our country in this regard.

**Keywords:** Ethics, Human tissue, Research, Guideline.

# **Ethics, professionalism and patient's rights in the pathology laboratory**

Mina Mobasher<sup>1</sup>, Molouk Torabi Parizi<sup>2</sup>

<sup>1</sup>Assistant professor, Department of Medical Ethics, Medical School, Kerman University of Medical Sciences, Kerman, Iran. <sup>2</sup>Associate professor, Department of Oral Pathology, Dental School, Kerman University of Medical Sciences, Kerman, Iran.

Professionalism is an important part of medicine's contract with society. The concept of the profession of a doctor has changed considerably with the times. Professionalism is a theoretical compound, more easily described in lofty idealistic terms than by observable behaviors. There is also much variation in concept of 'professionalism' in different countries. The societal and cultural value can influence the perception and interpretation of professional behavior of a physician. It is important for each institution to define professionalism in its own background. Pathology laboratory as well as staffs should have a clear understanding of the features, characteristics and qualities that contribute to professionalism. A written content (such as ethics, decision making/moral reasoning, communication, humanism, empathy), and an accurate list of knowledge, skills and attitudes guards against delivering conflicting messages to staffs. In the present study we will describe ethics and professionalism in pathology laboratories and frequently asked questions such as patient's rights concerning human tissue or other specimens, Pathologists' rights regarding the use of human tissue or other specimens.

# Prevalence of Gastric mucosal nodularity in *Helicobacter pylori* infection

Maryam Maghbul<sup>1</sup>

<sup>1</sup>Departments of Pathology, fassa University of Medical Sciences, fassa, Iran. <sup>2</sup>Departments of Pathology, shiraz University of Medical Sciences, shiraz, Iran.

**Introduction:** Gastric mucosal nodularity is an endoscopic finding occasionally seen in general practice. There is no consensus about the definite endoscopic definition of nodular gastritis and its clinical classification as an acute or chronic lesion. Various terms such as antral nodularity, antral nodular hyperplasia, nodular antritis, and micronodular gastritis have been used for endoscopic nodular gastritis. Endoscopic nodular gastritis is more common in areas with high prevalence of *Helicobacter pylori* infection. Many studies have shown that the prevalence of some types of gastritis such as endoscopic nodular gastritis is higher in *H. pylori*-positive cases in comparison with *H. pylori*-negatives. However, some reports did not show any significant correlation between endoscopic nodular gastritis and *H. pylori* positivity. There is also no consensus about the association of endoscopic nodular gastritis with histopathological changes such as histological premalignant lesions. Because there is no general consensus on the association of endoscopic nodular gastritis and histological premalignant lesions (e.g. atrophic gastritis, intestinal metaplasia, and dysplasia), we designed this study to find a possible connection. In this study a range of histological premalignant lesions were comparatively analysed between two groups of Iranian adult dyspeptic patients with and without endoscopic nodular gastritis.

**Materials and Methods:** After obtaining the approval of the university ethical committee (93-01-13-8145) as well as written informed consent from each patient or his or her legal guardian in accordance with the Helsinki Declaration, all the consecutive rural patients with dyspepsia were recruited in this cross-sectional study between November 2011 and January 2014. Diagnosis of dyspepsia was based on clinical findings. Endoscopic nodular gastritis was defined as a miliary nodular appearance on the antrum and/or body of gastric mucosa on endoscopy. The biopsies were taken from all of the included patients with endoscopic nodular gastritis and normal endoscopy. Two biopsies from the antrum and two biopsies from the body were obtained from all patients with endoscopic nodular gastritis and the control group.

**Result:** From 5366 evaluated patients, a total of 273 patients with endoscopic nodular gastritis and 1103 precipitants with normal endoscopic findings as a control group were evaluated. The mean age (SD) of patients with endoscopic nodular gastritis and the control group was 38.19±16.23 and 39.21 ±15.62 years, respectively. Of the patients with endoscopic nodular gastritis, 58.24% were in the age group 20-40 years and the majority of them (69.96) were woman. In the *H. pylori*-positive subgroup the prevalence of premalignant lesions in patients with nodular gastritis was significantly higher than in the normal endoscopy group (16.3% vs. 7.9%,  $p = 0.000$ ).

The prevalence of dysplasia (OR 3.98; 95% CI 2.27-6.66;  $p < 0.001$ ) and incomplete intestinal metaplasia (OR 8.63; 95% CI 1.47-45.00;  $p = 0.004$ ) in patients with endoscopic nodular gastritis were significantly higher than the control group. On the other hand, atrophic gastritis (OR 1.18; 95% CI 0.38-3.60;  $p = 0.799$ ) and complete intestinal metaplasia (OR 1.21; 95% CI 0.51-2.57;  $p = 0.716$ ) were more frequent in patients with endoscopic nodular gastritis than in the control group, but the difference was not significant.

**Keywords:** *Helicobacter pylori*, Gastric mucosal nodularity.

# Histopathological evaluation of the effects of green tea on ischemia–reperfusion injury after experimental testicular torsion in rat

Hasan Moshfegh<sup>1</sup>, Jalil Abshenas<sup>2</sup>, Reza Kheirandish<sup>3</sup>, Homayoun Babaei<sup>2</sup>, Alireza Shafiiian<sup>1</sup>

<sup>1</sup>School of Veterinary Medicine, Shahid Bahonar University of Kerman, Kerman, Iran. <sup>2</sup>Department of Clinical Studies, School of Veterinary Medicine, Shahid Bahonar University of Kerman, Kerman, Iran.

<sup>3</sup>Department of Pathobiology, School of Veterinary Medicine, Shahid Bahonar University of Kerman, Kerman, Iran.

**Introduction:** Testicular torsion (TT) is a surgical emergency which can lead to orchiectomy of the ipsilateral testis and often to infertility of the contralateral testis. The main pathophysiology of TT is ischemia-reperfusion (I-R) injury of the testis caused by the twisted spermatic cord and its release. The aim of the present study is to investigate the effects of green tea as an antioxidant and anti-inflammatory agent on I-R injury following testicular torsion.

**Materials and methods:** Forty adult male rats were selected and divided into 4 groups each containing 10 rats. Group one was kept for determination of the basal values. Rats of group two and three were treated with green tea extract (in a dose of 2% in their drinking water) one week before TT and until two hours after TT. The testes of group 2 were remained intact and testes of group 3 were rotated 720 degree counter clock wise for 2 hours, after being anesthetized. Rats of group four (control of torsion), had TT like group three without green tea treatment.

**Results:** Testicular torsion lead in a significant decrease in the percentage of spermatogenesis, seminiferous tubules diameters, meiotic index and Johnson's score compared to the control and green tea treatment groups. The administration of green tea significantly increased the related parameters (P 0.05).

**Conclusion:** In conclusion, green tea, as a potent anti oxidant is very effective in healing and improving I-R injury following testicular torsion.

**Keywords:** Green tea, Testicular Torsion, Rat, Pathology.



# Mapping the Iranian's Research Literature in the Field of pathology in Scopus Database 2010-2014

Maryam Okhovati<sup>1</sup>, Hossein GhaedAmini<sup>2</sup>, Fathemeh Karami<sup>3</sup>, Reza Malekpour Afshar<sup>4</sup>, Morteza Zare<sup>5</sup>, Azam Bazrafshan<sup>5</sup>, Malihe Sadat Bazrafshan<sup>3</sup>

<sup>1</sup>Physiology Research Center, Neuroscience Research Center, Institute of Neuropharmacology, Kerman, Iran. <sup>2</sup>Medical Student, Neuroscience Research Center, Institute of Neuropharmacology, Kerman University of Medical sciences, Kerman, Iran. <sup>3</sup>Scientometrics and Webometrics Research Committee, Deputy for Research, Kerman University of Medical Sciences, Kerman, Iran. <sup>4</sup>Department of Pathology, Faculty of Medicine, Kerman University of Medical Sciences, Kerman, Iran. <sup>5</sup>Neuroscience Research Center, Institute of Neuropharmacology, Kerman University of Medical sciences, Kerman, Iran.

**Introduction:** To provide research and collaboration overview of Iranian research efforts in the field of pathology during 2010-2014.

**Materials and Methods:** This is a bibliometric study using the Scopus database as data source, searching the affiliation address relevant to pathology and Iran was used as search strategy. Subject and geographical overlay maps were also applied to visualize the network activities of the Iranian authors. Highly cited articles (citations>10) were further explored to highlight the impact of research domains more specifically.

**Results:** About 3683 articles were published by Iranian authors in Scopus database. Compound annual growth rate of Iranian publications was 0.14% during 2010-2014. Tehran University of Medical Sciences (932 articles), Shiraz University of Medical Sciences (404 articles) and Islamic Azad University (391 articles) were the leading institutions in the field of pathology. Medicine (72%), biochemistry, genetics and molecular biology (21%), biological sciences (13%), pharmacology and toxicology (8%) were the major research topics accordingly. United States (7%), Netherlands (3%) and Canada (2.6%) were the most important collaborators of Iranian authors.

**Conclusion:** Iranian's research efforts in the field of pathology have been increased slightly over the last years. Yet joint multi-disciplinary collaborations are needed to cover the inadequately described areas of pathology in the country.

**Keywords:** Pathology, Scientometrics, Iran, Science Policy.

# Histological effect of valerian extract on the fatty liver in hypercholesterolemic rabbits

Arezo pakdaman<sup>1</sup>, Habibloah jowhary<sup>2</sup>

<sup>1</sup>Department of Biology, Islamic Azad University, Jahrom, Iran. <sup>2</sup>Department of Biology, Islamic Azad University, Darab, Iran.

**Introduction:** In today's world of ever increasing progress of science and the discovery of new diseases and the ineffectiveness of many chemical agents in the treatment of diseases and their complications, the attention of the world's growing more and more of medicinal plants. The aim of this study was the effect of valerian extract on histological study on fatty liver in hypercholesterolemic rabbits.

**Materials and Methods:** In this experimental study, 25 New Zealand rabbits were used. Rabbits 5 groups divided. Controls received no drug, sham 1 day, 10 ml of corn oil (vehicle- cholesterol) were controls 2 daily 10 ml cholesterol and experimental groups 1 and 2, respectively, 50 and 200 ml of ethanol extracts of valerian received.

**Results:** The histological results showed that high cholesterol could lead to liver damage and necrosis in a control group that received cholesterol and the liver damage in experimental groups that received valerian extract was improved.

**Conclusion:** The results suggest that valerian extract may cause improved liver damage in rabbits.

**Keywords:** Hypercholesterolemic, Rabbit, Liver, Histology, Valerian extract.

# Histological effect of valerian extract on the kidney in hypercholesterolemic rabbits

Arezo pakdaman<sup>1</sup>, Mahsa kamali<sup>1</sup>, Habibloah jowhary<sup>2</sup>

<sup>1</sup>Department of Biology, Islamic Azad University, Jahrom, Iran. <sup>2</sup>Department of Biology, Islamic Azad University, Darab, Iran.

**Introduction:** In today's world of ever increasing progress of science and the discovery of new diseases and the ineffectiveness of many chemical agents in the treatment of diseases and their complications, the attention of the world's growing more and more of medicinal plants. The aim of this study was the effect of valerian extract on histological study on fatty kidney in hypercholesterolemic rabbits.

**Materials and Methods:** In this experimental study, 25 New Zealand rabbits were used. Rabbits 5 groups divided. Controls received no drug, sham 1 day, 10 ml of corn oil (vehicle- cholesterol) were controls 2 daily 10 ml cholesterol and experimental groups 1 and 2, respectively, 50 and 200 ml of ethanol extracts of valerian received.

**Results:** The histological results showed that high cholesterol could lead to kidney damage and necrosis in a control group that received cholesterol and the kidney damage in experimental groups that received valerian extract was improved.

**Conclusion:** The results suggest that valerian extract may cause improved kidney damage in rabbits.

**Keywords:** Hypercholesterolemic, Rabbit, Kidney, Histology, Valerian extract.

# Histological effect of chicory extract on the fatty liver in hypercholesterolemic female rabbits

Fatemeh pishrozadeh<sup>1</sup>, Habibloah jowhary<sup>2</sup>

<sup>1</sup>Department of Biology, Islamic Azad University, Jahrom, Iran. <sup>2</sup>Department of Biology, Islamic Azad University, Darab, Iran.

**Introduction:** The role of plants in reducing blood lipids and thereby reduce the risk of liver diseases such as fatty liver is known. Accordingly, we examined the effect of chicory extract on changes in histology of fatty liver in hypercholesterolemic rabbits.

**Materials and Methods:** In this experimental study, 25 female New Zealand rabbits were used. Rabbits 5 groups divided. Control group received no drug, sham 1 received 10 ml of corn oil (vehicle- cholesterol), sham 2 received 10 ml cholesterol and experimental group 1 received 500 ml of ethanol extracts of chicory with cholesterol and experimental 2 received only chicory extract.

**Results:** The histological results showed that high cholesterol could lead to liver damage and necrosis in a control group that received cholesterol and the liver damage in experimental groups that received chicory extract was improved.

**Conclusion:** This study shows that high cholesterol has an acute effect on the liver and chicory extract improves tissue damage.

**Keywords:** Chicory extract, Hypercholesterolemic, Rabbit, Liver, Histology.

# Detection of CEBPA mutations in acute myeloid leukemia patients

S.Rostami<sup>1</sup>

1

**Introduction:** While about half of AML patients can be classified by a specific genetic abnormality, around half of cases are placed into the cytogenetically normal AML. Molecular genetics has already provided important insights to the diagnosis, risk stratification and treatment management of acute myeloid leukemia. Mutations affecting CCAAT/enhancer binding protein alpha (CEBPA ) Identify a subset of acute myeloid leukemia (AML) patients with favorable outcome.

**Materials and Methods:** In this study CEBPA mutation status was determined in 80 patients with acute myeloid leukemia at diagnosis. Four overlapping fluorescently labeled primers used to amplify the complete coding sequences of the CEBPA gene and capillary electrophoresis was done on a 3130 Genetic Analyzer.

**Results:** In 73 patients single fragments were amplified from wild-type genomic DNA with each of the primer pairs. Overall, we identified 11 mutations in 7 patients (8.75%). Four patients were double-mut for CEBPA mutation, whereas 3 proved to be single-mut for CEBPA gene mutations. Most of the mutations were located within TAD1 and c-terminal domains of protein.

**Conclusion:** In this study the overall incidence of CEBPA mutations was similar to other large studies. Detection of CEBPA mutation may be important in not only risk stratification but also in monitoring minimal residual disease in AML patients.

**Keywords:** CEBPA mutation, AML.

# Wound healing effect of platelet-rich fibrin flap in an experimental defect of dog esophagus

Sara Rostami<sup>1</sup>, Alireza Farsinezhad<sup>2</sup>, Fattah Iranmanesh<sup>1</sup>, Shahriar Dabiri<sup>2</sup>, Omid Azari<sup>1</sup>, Reza Kheirandish<sup>3</sup>

<sup>1</sup>Department of Clinical Sciences, Faculty of Veterinary Medicine, Shahid Bahonar University of Kerman.

<sup>2</sup>Department of Pathology, School of Medicine, Kerman University of Medical Sciences, Kerman, Iran.

<sup>3</sup>Department of Pathobiology, Faculty of Veterinary Medicine, Shahid Bahonar University of Kerman, Iran.

**Introduction:** Complete and predictable regeneration of the esophagus remains a major challenge due to its segmental blood supply and lack of serosa. For decades, attempts have been done to enhance esophageal wound healing. Development of the bioactive surgical additives is one of the new advances to regulate inflammation and improve regeneration. Platelet-rich fibrin (PRF), a new generation of platelet concentrate, is a natural fibrin-based biomaterial. It is prepared from an anticoagulant-free blood harvest without any artificial biochemical modification that allows obtaining fibrin membranes enriched with platelets and growth factors. Although this preparation is widely used to enhance tissue regeneration, there is little research of its efficacy for esophageal healing. This study was designed to evaluate angiogenesis effect of PRF for the healing process enhancement of the esophageal wounds.

**Materials and Methods:** Twelve healthy, mongrel dogs approximately 1 year old at weight range of 20±5 kg were used in this study. Surgical defects (2 cm-longed) were created in the proximal aspect of cervical esophagus. In the AM group (n=8), PRF graft were placed on the esophageal defect and sutured with standard pattern, a subgroup of 4 dogs (PRF 1 group) was sacrificed on day 30 and the other 4 animals (PRF 2) kept alive until 45 days. Control groups (control 1 and 2) were considered the same as treatment group of PRF 1 and PRF 2 with no treatment. Specimens were fixed with 10% buffered formalin (Merck) for 14 days. Histological assessments were performed by a masked pathologist under a light microscope (BX 51, Olympus, Japan).

**Results and discussion:** The significant role of growth factors in wound healing has been well determined. So, it is announced that local administration of growth factors can potentially be useful in tissue regeneration. PRF as a fibrin matrix is enriched for platelets, growth factors, leukocyte and cytokines. So, it proposes the potential for many new therapeutic alternatives. Healing of esophagus is more complicated than simple soft tissue healing. One of the primary challenges in the repair of esophagus is growth factors supply. We aimed to determine whether grafts of PRF, a readily disposable and low cost material with previous clinical experience in humans, would be able to heal and remodel esophageal wound. Histological analysis exhibited re-epithelialization, angiogenesis and granulation tissue. We conclude that PRF can be used to promote wound healing, bone graft stabilization, wound sealing and homeostasis.

**Keywords:** Wound healing, Platelet rich fibrin, Esophagus, Dog.

# Survey of the healing effect of green tea extract on testicular tissue after scrotal heat stress in mice

Maryam Rouzkhosh<sup>1</sup>, Jalil Abshenas<sup>2</sup>, Homayoun Babaei<sup>2</sup>, Reza Kheirandish<sup>3</sup>, Afshin Aghaabbasi<sup>4</sup>,  
Alireza Shafii<sup>1</sup>

<sup>1</sup>School of Veterinary Medicine, Shahid Bahonar University of Kerman, Kerman, Iran. <sup>2</sup>Department of Clinical Studies, School of Veterinary Medicine, Shahid Bahonar University of Kerman, Kerman, Iran.

<sup>3</sup>Department of Pathobiology, School of Veterinary Medicine, Shahid Bahonar University of Kerman, Kerman, Iran. <sup>4</sup>School of Veterinary Medicine, Islamic Azad University of Kazeroon, Fars, Iran.

**Introduction:** Green tea from young leaves of the plant *Camellia Sinensis* is known to have potent antioxidant, anti-inflammatory and anti-cancer effects. Any agent increasing the testis temperature such as high ambient temperature or local stress on the testis can lead to disorder in spermatogenesis and infertility arisen from azoospermia and oligospermia. The aim of the present study is to investigate therapeutic effects from the prescription of green tea extract on spermatogenesis in the mice in which the testis were placed under heat stress.

**Materials and Methods:** Ninety adult male mice were randomly divided into six groups consisted of two therapeutical groups, two green tea groups, one group of heat-control, and a normal-control group. The testes (scrotal area) of the mice in therapeutic and heat control groups were placed under local heat stress by 42°C for 20 minutes. Then, the therapeutic groups were placed under the daily and oral administration of 500 and 750 mg/kg of green tea. Finally, by sampling from testis and their epididymises, four parameters including percent of spermatogenesis, meiotic index, seminiferous tubules diameter, and Johnson's score were evaluated in day 14, 28, and 42 of experiment.

**Results:** The heat destructive effects on spermatogenesis and fertility are so obvious in the results arisen from heat-control group. Results from therapeutic groups showed that administration of green tea, particularly at a dose of 500 mg/kg, after 28 and 42 days, improved parameters relevant to fertility and the properties of sperms.

**Conclusion:** Results of the present study demonstrated that green tea extract can improve the healing process followed by heat stress to testes, and fasten the normal spermatogenesis.

**Keywords:** Green tea, Scrotal heat stress, Testes, Mouse, Pathology.

# Serum levels of Rheumatoid Factor and anti-phosphatidylethanolamine in patients Ischemic Heart Disease

Amin Safa<sup>1</sup>, Ali Derakhshani<sup>2</sup>, Ali Bazi<sup>1</sup>

<sup>1</sup>Department of Laboratory Sciences, Allied Medical Sciences School, Zabol University of Medical Sciences, Zabol, Iran. <sup>2</sup>Pathology and Stem Cell Research Center, Medical School, Kerman University of Medical Sciences, kerman, Iran.

**Introduction:** Many factors play a role in ischemia heart disease. Hence, this study aimed to evaluate the relationship between serum levels rheumatoid factor (RF) and anti-phosphatidylethanolamine (PEA) in patients with Ischemic Heart Disease (IHD).

**Materials and Methods:** A total of 110 patients with IHD with acute myocardial infarction (AMI; n=55) or unstable angina (UA; n=55) and 60 sex- and age-matched healthy subjects were enrolled in this study. Serum samples of participants were tested for the serum level of RF was measured by latex method and anti-phosphatidylethanolamine by enzyme-linked immunosorbent assay (ELISA).

**Results:** The mean serum levels of RF in AMI group and UA group were significantly higher than those observed in the control group ( $P < 0.0001$ ). The differences of the serum levels of anti-phosphatidylethanolamine were not significant between AMI, UA and the control groups.

**Conclusion:** Higher serum levels of RF in patients with IHD may be considered as independent risk factors for IHD.

**Keywords:** Anti-phosphatidylethanolamine, Myocardial Infarction, Rheumatoid Factor, Unstable Angina.



# Effect of folic acid supplementation on acute effects of co-trimoxazole on quality of sperm and histopathological changes in the testes of adult male rats

Ehsan Salarkia<sup>1</sup>, Morteza Khaleghimahani<sup>2</sup>, Gholamreza Sepehri<sup>3</sup>

<sup>1</sup>Department of Biology, Faculty of Science, Karaj Branch, Islamic Azad University, Karaj, Iran. <sup>2</sup>Pathology and Stem Cell Research Center, Afzalipour Kerman University of Medical Sciences, Kerman, Iran. <sup>3</sup>Kerman Neuroscience Research Center, Kerman University of Medical Science, Kerman, Iran.

**Introduction:** The antibacterial co-trimoxazole is the combination of trimethoprim and sulfamethoxazole with 5:1 ratio. Co-trimoxazole inhibits both the production and activation of folic acid which result in production of DNA synthesis which is necessary for reproductive and sperm quality. Long term administration of co-trimoxazole may interfere with sperm synthesis in the testes, so this study was performed to evaluate the probable protective effect of folic acid on co-trimoxazole induced changes in testes tissue and sperm quality in male rats.

**Materials and Methods:** For this study, 100 male Wistar rats were used. The mice were divided into 15 groups (n=7). Male rats received co-trimoxazole (60 and 120 mg/kg) for 14 and 28 days either alone or in combination with folic acid (1 mg/kg). Control rat received nothing and sham group received saline with same procedure. After the completion of treatment rats were anaesthetized with Xylazine-Ketamine and testes were removed for histological studies (Cell count of spermatogonium, primary and secondary spermatocytes, Leydig, Sertoli, blood vessels and the diameter of the seminiferous tubules). The epididymis and testes' sperm were used for the studying of sperm quality (sperm count, viability and percent of live and motile sperm).

**Result:** The study showed that the Injection of different doses of co-trimoxazole in special doses of 60 and 120 mg/kg reduced sperm count, viability and percent of live and motile sperm, compared with the control group, this decrease is largely improved with injection of 1 mg/kg of folic acid. However, at a dose of 120 mg/kg the effect of the index to the extent that the administration was not normal. The histopathology examination of testicular tissue showed that the Injection of co-trimoxazole with values of 60 and 120 mg/kg reduced the number of spermatogonia, primary and secondary spermatocytes and Sertoli cells, as well as the diameter of the seminiferous tubules, but change the arrangement and number of Leydig cells and blood vessels are not seen. In these case combined of folic acid these changes greatly improved.

**Conclusion:** Based on this study and other studies, co-trimoxazole with impact on spermatogenesis, reduced number and sperm quality in mice, as well as co-trimoxazole a direct effect on testicular tissue destroys Spermatozoon and the Sertoli cells. That administration of folic acid can be largely compensated for the negative effects of it.

**Keywords:** Sperm, Testes, Co-Trimoxazole, Folic Acid.

# Effect of hydroxyethyl starch in the process of dental pulp stem cell cultivation

M. Samareh Salavati<sup>1</sup>, M. Lashkari<sup>1</sup>, A. Derakhshani<sup>2</sup>, A. Farsinejad<sup>2</sup>

<sup>1</sup> Department of Hematology and Laboratory Sciences, Faculty of Allied Medicine, Kerman, Iran.

<sup>2</sup> Pathology and Stem Cell Research Center, Kerman University of Medical Sciences, Kerman, Iran.

**Introduction:** In cell culture process, Fetal Bovine Serum (FBS) is mostly used as medium supplement, but because of its problems, nowadays many alternatives such as umbilical cord blood serum (CBS) are presented. In cord blood bank, Hydroxy Ethyl Starch(HES) is used to separate red blood cells (RBCs) and then the plasma that contains HES is discarded. In this study, the HES plasma is utilized as a FBS replacement for culturing Dental Pulp Stem Cells (DPSCs) to evaluate the effect of HES on DPSCs culture.

**Materials and Methods:** DPSCs were cultured in presence of MEM- containing FBS or HES plasma. Morphology of the cells was checked by Invert microscope and the viability was investigated by MTT assay. Gene expression and the chromosomal changes were measured by real time PCR and Karyotype test, respectively.

**Results:** Human DPSCs cultured in presence of FBS or HES plasma showed typical fibroblast-like morphology, which is characteristic of MSC. Cells cultured in HES plasma had slightly less cell count as compared to cells cultured in FBS. Cytogenetic analysis of cells and gene expression in presence of both of them were similar.

**Conclusion:** HES plasma supports the growth of MSCs, while no differences were observed in the MSC numbers and morphology of them compared with FBS. Therefore, HES plasma can be used as an effective substitute to FBS for developing clinically useful protocols for culturing cells.

**Keywords:** Hydroxy Ethyl Starch, Mesenchymal Stem Cell, Fetal bovine serum.

# Ocular surface sequential tissue-response in Solar-induced conjunctival lesions

Nosaibe Seirfar<sup>1</sup>, Samaneh Koohestani<sup>2</sup>, Roshanak Aliakbar-Navahi<sup>2</sup>, Mohammad Javad Ashraf<sup>1</sup>,  
Shahram bamdad<sup>2</sup>

<sup>1</sup>Department of Pathology, Khalili Hospital, Shiraz University of Medical Sciences, Shiraz, Iran.

<sup>2</sup>Department of Ophthalmology, Khalili Hospital, Shiraz University of Medical Sciences, Shiraz, Iran.

**Introduction:** To evaluate and compare the incidence of histological changes in the spectrum of solar induced conjunctival lesions.

**Materials and Methods:** A retrospective study carried out on histology tissue slides of 464 conjunctival specimens previously diagnosed as pterygia, epithelial dysplasia and squamous cell carcinoma received from April 2009 to July 2013 in Khalili Hospital, Shiraz, Iran. The following coexisting histological variables of epithelial hyperplasia, hyperkeratosis, hypermelanosis, solar elastosis and squamous metaplasia among ocular surface squamous lesions (OSSN) were evaluated.

**Results:** 356 (76.7%) of the specimens were pterygia while conjunctival intraepithelial neoplasia (CIN) cases were 64 (13.8%) and squamous cell carcinoma (SCC) cases were 44 (9.5%). Solar elastosis was the most common finding in pterygia group (97.5%) while squamous hyperplasia was more significant in the CIN (95.3%) and SCC (100%) cases. Solar elastosis in pterygia was significantly higher than CIN and SCC group ( $P < 0.001$ ) but epithelial hyperplasia showed obviously greater amount in CIN and SCC cases than pterygia ( $P < 0.001$ ). Squamous metaplasia and hyperkeratosis were significantly much higher in CIN and SCC lesions than pterygia group ( $P < 0.001$ ) but they did not show a significant difference between CIN and SCC cases. Also, the results did not show any obvious difference between the three solar induced conjunctival lesions with regard to hypermelanosis.

**Conclusion:** OSSN is a spectrum of conjunctival epithelial lesions from mild dysplasia to invasive squamous cell carcinoma that composes a portion of solar induced conjunctival lesions. The first tissue response to the UV- light has the subepithelial component of solar elastosis and then with the continuation and progression of the light damage, the epithelial component reaction (epithelial hyperplasia) occurs. According to the results of this study, one can consider the solar elastosis as only a solar tissue response and not a risk factor for OSSN.

**Keywords:** Conjunctival lesions, Intraepithelial dysplasia, Squamous cell carcinoma, Sequential tissue-response.

# Accelerating effects of cinnamon extract on testicular regeneration following scrotal heat stress in rats

Alireza Shafii<sup>1</sup>, Jalil Abshenas<sup>2</sup>, Reza Kheirandish<sup>3</sup>

<sup>1</sup>School of Veterinary Medicine, Shahid Bahonar University of Kerman, Kerman, Iran. <sup>2</sup>Department of Clinical Studies, School of Veterinary Medicine, Shahid Bahonar University of Kerman, Kerman, Iran.

<sup>3</sup>Department of Pathobiology, School of Veterinary Medicine, Shahid Bahonar University of Kerman, Kerman, Iran.

**Introduction:** Scrotal temperature in mammals is 2–8°C lower than that of the rest of the body and is a requirement for normal spermatogenesis. In man, raised scrotal temperature may occur as a result of occupational exposure, lifestyle or a clinical disorder, such as cryptorchidism. A high testicular temperature impairs spermatogenesis, and could lead to reduced testicular weight and sperm numbers, accompanied by a transient period of partial or complete infertility. Cinnamon is a spice obtained from the inner bark of several trees from the genus *Cinnamomum* that is used in both sweet and savoury foods. Several medicinal properties has been associated with cinnamon. It has also been reported as a potent antioxidant. The present study aimed to evaluate the effects of cinnamon extract on testicular regeneration after scrotal heat stress in rats.

**Materials and Methods:** Fifty six adult male rats were selected and divided into 8 groups consisted of two therapeutic, two heat control, two cinnamon-control and two normal-control groups. The testes of the mices relevant to therapeutic and heat control groups were placed under local heat stress of scrotal area by the 43°C for 15 minutes. Then, the therapeutic groups were placed under the daily and oral prescription with 200 mg/kg cinnamon. Finally, after sampling from testis, the meiotic index (MI) and Johnson's score (JS), as important parameters related to fertility, were evaluated on days 28 and 49 of the experiment.

**Results:** The heat destructive effects were so obvious on spermatogenesis and fertility in the results arising from heat-control groups (day 28: MI=2.02±0.05 and JS=5.47±0.23; day 49: MI=1.88±0.04 and JS=6.50±0.25). The meiotic index (day 28: 2.45±0.06; day 49: 2.39±0.03) and Johnson's score (day 28: 7.42±0.16; day 49: 8.36±0.19) of the therapeutic groups were significantly higher than those of heat-control groups (P<0.05).

**Conclusion:** In conclusion, results of this study showed that oral administration of cinnamon, following scrotal heat stress, accelerated the regeneration of testiular tissue and reduced the destructive effects of heat stress.

**Keywords:** Scrotal Heat Stress, Tetstis, Cinnamon, Rat, Pathology.

# Unusual presentation of cutaneous leishmaniasis in an endemic area of Kerman province, Iran

Simin Shamsi Meymandi<sup>1</sup>, Maryam khalili<sup>2</sup>, Mahin Aflatoonian<sup>2</sup>, Rahim Ahmadi<sup>3</sup>, Alireza ZeynadiniMeymand<sup>3</sup>

<sup>1</sup>Professor of dermatology, Pathology and Stem Cell Research Center, Kerman University of Medical Sciences, Iran. <sup>2</sup>Assistant professor of dermatology, Department of Dermatology, Kerman University of Medical Sciences, Iran. <sup>3</sup>Resident of dermatology, Kerman University of Medical Sciences, Iran.

**Introduction:** Leishmaniasis is a common protozoan infectious disease which transmitted by sand fly belonging to phlebotomous family. Depending on parasite genetic background, number of inoculation, host immune response to parasite, clinical presentation classified to acute and chronic types.

Acute form can be seen with typical morphology as papule, plaque, ulcerative nodule and impetiginous types. Atypical forms are classified based on morphology and location. Atypical morphology can be presented as zosteriform, eczematous, erysipeloid, verrusiform and psoriasiform. Atypical locations include macrocheilia, palmoplantar, paronychial and chancriform.

Chronic form of leishmaniasis can be presented as lupoid form in the site of scar results from previous leishmaniasis or appeared as a lesion with duration more than one year without any improvement.

In this article we described four patients with uncommon presentation of cutaneous leishmaniasis.

## Case reports:

### Case 1:

A 28-year-old man presented with a history of a pruritic lesion near proximal nail fold of right third finger since a few months ago. Previously, He referred to general physician and the lesion was treated with impression of eczema by topical corticosteroid and emollient with no improvement. On physical examination, an indurated shiny purplish-red papule was observed. Since, our patient lived in an endemic area of leishmaniasis with no response to treatment, we decided to biopsy the lesion. Histologically, a granulomatous infiltration with numerous leishman bodies was reported. We referred our patient to leishmaniasis treatment center that weekly Intralesional meglumine antimoniate with cryotherapy every other week was administered and the lesion was cleared after 8 weeks treatment course.

### Case 2:

An 18-year-old woman referred to dermatology center with a severely pruritic lesion on volar of the left forearm, from about 1 year ago. Initially, patient referred to general physician and with the diagnosis of keloid was treated by Intralesional triamcinolone, without any improvement. On examination, a 2 cm<sup>2</sup> indurated yellowish-brown plaque with apple-jelly appearance and some scales on the surface and depigmentation at the margin of it was observed. The lesion was biopsied, because of chronicity and induration, with differential diagnosis of chronic or lupoid leishmaniasis, sarcoidosis and lupus vulgaris. Finally, with diagnosis of chronic leishmaniasis was treated with weekly intralesional meglumine antimoniate and biweekly cryotherapy for 3 months and was completely cured.

**Case 3:**

A 53-year-old woman was complained of the multiple ulcerated lesions in two legs and one forearm that admitted in Afzalipour hospital in Kerman for further evaluation. She had past history of 10 years diabetes mellitus that received insulin to control serum glucose. There was no other medical and drug history. On physical examination, no fever, lymphadenopathy or constitutional symptom were detected. Multiple painless ulcerated reddish-brown nodules and plaques with crust formation on the surface in linear array were observed.

Direct smear for bacterial infection was positive for pseudomonas which was treated by ciprofloxacin. Biopsy was performed from one of the lesions which leishman bodies was detected. The patient responded to intramuscular injection of meglumine antimoniate with dosage 20 mg/kg/day for three weeks.

**Case 4:**

A 47 year old man referred to our clinic with history of painful indurated plaque on dorsum of hand from 1 year ago, which was treated with intralesional glucantime and cryotherapy for 4 weeks, but, the lesion continued to spreading on dorsal of his hand as indurated reddish-brown plaque with yellowish crust on the surface and swelling of his hand resemble to infected contact dermatitis. Bacterial smear and culture from the lesion was positive and patient received with cefazoline 1g, twice a day. After remission of bacterial infection, since, induration of the lesion was persisted, skin biopsy was performed. Diagnosis of leishmaniasis was confirmed. Patient treated with parenteral administration of glucantimefor three weeks. Treatment continued with oral allopurinol until 3 months and the lesion cured.

# Evaluation of clinicopathologic 100 skin biopsies in Afzalipour Hospital, Kerman

Simin Shamsi Meymandi<sup>1</sup>, Siavash M. Shanehsaz<sup>1</sup>, Hoda Badakhsh<sup>1</sup>, Fahameh Fadaei<sup>1</sup>

<sup>1</sup>Dermatology and Leishmaniasis Research Center, Kerman University of Medical Sciences, Kerman, Iran.

**Introduction:** Skin biopsy is an essential investigation for dermatologists. The technique used to obtain a specimen for microscopic evaluation may have a significant impact on the ability of the dermatologist to arrive at the correct diagnosis.

**Materials and Methods:** In Afzalipour hospital, a tertiary center, 100 skin biopsies were prospectively reviewed during a three month period in the autumn of 2013. These biopsies were taken from the dermatology clinic, Afzalipour hospital; all run by different dermatology residents and same paramedical personnel. These biopsies were separately reviewed by different dermatology residents and a dermatopathologist before a final diagnosis was made.

**Results:** The correlation between the pathologist and the dermatologist was high at (90%) agreement. Other study found a clinicopathologic correlation of up to (75%) by the treating dermatologists. The high correlation seen here might be due to the active participation of the dermatology residents in reviewing the dermatohistopathological slides and the open discussion between the dermatology residents and dermatopathologist. Eczematous changes were seen in 38.46% ( $n=5$ ) of drug-related dermatoses. Psoriasiform changes were seen in 23.07% ( $n=3$ ), vasculitic in 15.37% ( $n=2$ ), lichenoid in 7.7% ( $n=1$ ), erythema multiforme in 7.7% ( $n=1$ ) and fixed drug eruption in 7.7% ( $n=1$ ). Other studies found morbilliform rash constituting majority of cases clinicopathologically. This is in marked contrast with the current study where eczematous changes were the commonest drug-related dermatoses. Another interesting finding was the high proportion of cutaneous lymphoma. Cutaneous lymphoma was seen as the second most common malignancy constituting 20% ( $n=2$ ) of the 27 cases of cutaneous malignancies. It ranked behind basal cell carcinoma with 50% ( $n=5$ ) and squamous cell carcinoma with 20% ( $n=2$ ). Malignant melanoma was seen in only 10% ( $n=1$ ) of cases. The malignant melanoma was of acral lentiginous type.

**Conclusion:** High clinicopathologic correlation and the pattern of drug-related dermatoses and cutaneous malignancies was shown in our study differ from other studies. Our study showed that cutaneous lymphoma was more common in Afzalipour hospital compared to malignant melanoma. However, due to the small number of cases, this finding cannot be conclusively confirmed.

**Keywords:** Skin biopsies, Cutaneous lymphoma.

# Oct4 spliced variants are up-regulated in breast cancer and correlated with tumor grade

Saamaaneh Soheili<sup>1</sup>, MalekHossien Asadi<sup>1</sup>, Alireza Farsinejad<sup>2</sup>, Shahriar Dabiri<sup>2</sup>

<sup>1</sup>Department of Biotechnology, Institute of Environmental Science, Graduate University of Advanced Technology, Kerman, Iran. <sup>2</sup>Department of Pathology, Afzalipour Medical School, Kerman University of Medical Science.

**Introduction:** Octamer-binding transcription factor 4 (OCT4), is a key regulator of self-renewal and pluripotency in embryonic stem cells located on chromosome 6p.21.3 and can potentially encode three spliced variants designate Oct4A, Oct4B and Oct4B1. OCT4A is primarily localized within the nucleus of the embryonic stem cells, where it sustains the self renewal and pluripotency properties of the cells. In contrast, OCT4B is mainly located within the cytoplasm of somatic cancer cell lines and apparently lacks any self-renewal regulatory role. In addition to its expression in somatic cells, OCT4B1 is highly expressed in ES/EC cells and is rapidly down-regulated upon induction of differentiation. Based on cancer stem cell concept, the expression of OCT4 is potentially proposed to express in tumor tissues and it has critical role in tumorigenesis. High level OCT4 expression is used as a clinical diagnostic tool in primary and metastatic embryonic carcinomas. Accordingly, we have investigated the potential expression of OCT4 variants in breast cancer tissues compare to marginal ones.

**Materials and Methods:** In this study the expression of Oct4 spliced variants were assessed by quantitative RT-PCR in 34 patients. The expression of OCT4 at protein level was also checked out by immunohistochemical (IHC) analysis.

**Results:** Our results revealed that the Oct4 variants are highly expressed in breast cancer tissue samples in compare to marginal ones. Our data showed that a considerable correlation between the expression level of different Oct4 variants and the tumors' grade and ER and P53 status. All three variants are highly expressed in ER and PR positive, P53 negative and Her2 positive. IHC analysis showed that OCT4A is expressed in high grade tubular breast cancer tissues but Oct4B which localize in cytoplasmic of tumor cells is expressed in low grade tubular and lobular breast cancer tissues.

**Conclusion:** Alltogether, our data demonstrated a distinctive expression pattern of *OCT4* spliced variants in different types and grades of breast cancer and the further evidence which confirmed the role of Oct4, a stem cell factor, involvement in carcinogenesis.

**Keywords:** OCT4, Embryonic stem cells, Breast cancer, OCT4B1.



# Retroperitoneal Granular Cell Tumor: a rare localization of a rare tumor

Shirin Taraz Jamshidi<sup>1</sup>, Masoumeh Gharib<sup>1</sup>, Ghodratollah Maddah<sup>2</sup>

<sup>1</sup>Department of Pathology, Mashhad University of Medical Sciences, Mashhad, Iran. <sup>2</sup>Department of Surgery, Endoscopic Surgery Research Center, Mashhad University of Medical Sciences, Mashhad, Iran.

**Introduction:** Granular cell tumor (GCT) is a rare neoplasm. The cell of origin is unknown but currently, Schwann cells are considered as the origin of the tumor. The most common sites of this neoplasm are skin, subcutaneous region, and tongue. Retroperitoneal GCT is extremely rare and so far only two cases have been reported in the English literature.

**Case report:** A 36-year-old woman was admitted for a hypogastric mass and underwent laparotomy. She had a retroperitoneal mass, measuring 3 centimeters in greatest dimension, with adhesion to adjacent organs. As the mass was suspicious for malignancy, it was removed with wide margins. Histopathologic examination revealed a tumor composed of uniform cells with eosinophilic cytoplasm and small centrally located nuclei. Immunohistochemically, tumor cells were positive for S100 and CD68 and negative for cytokeratin. The patient was discharged with the final diagnosis of retroperitoneal granular cell tumor. No complications during nine months observation were observed.

**Discussion:** Retroperitoneal granular cell tumor is extremely rare and so far only two cases have been reported in the English literatures. The first was a case of multiple GCTs, one presenting in retroperitoneum and the others in the skin. The second was a retroperitoneal GCT with involvement of the pancreas mimicking pancreatic cancer. Most GCTs are benign and malignant behavior is very rare in this tumor. In this case, the clinical and imaging features were in favor of malignancy. However, histopathologic and immunohistochemical studies confirm the diagnosis of retroperitoneal GCT.

**Conclusion:** Retroperitoneum is an extremely rare site for GCT and retroperitoneal GCT can clinically and radiologically mimic malignancy.

**Keywords:** Retroperitoneum, Granular cell tumor.

# Clinical and pathological evaluation of odontogenic cysts in children and adolescents (a 18 years study)

Molouk Torabi<sup>1</sup>, Ali Taheri<sup>2</sup>, Soodabeh Torabi<sup>3</sup>, Mahsa Kalantari<sup>4</sup>

<sup>1, 2, 4</sup>Department of Oral Pathology, Kerman University of Medical Sciences, Kerman, Iran. <sup>3</sup>Dentist.

**Background and aim:** Odontogenic cysts are an important aspect of oral and maxillofacial pathology. Odontogenic cysts lined by epithelium that is derived from odontogenic epithelium and are seen only in jaws. The aim of the present study was to evaluate frequency of odontogenic cysts diagnosed in Kerman dental school pathology laboratory.

**Materials and Methods:** The study sample comprised of all oral biopsies reported by the Dept. of Oral Pathology of Kerman Dental School over a period of 18 years (1996-2014). The clinical case details of patients aged 0-18 years were retrieved from the archives and were reviewed. Details such as age, gender, site of biopsy and diagnosis were noted. All the data analysis and graph formations were performed using Microsoft Excel.

**Results:** 326 specimens were pediatric oral lesions. Among these specimens, 81 (24.84%) odontogenic cysts were diagnosed. The two most common was dentigerous cysts 23 (28.39%), and radicular cysts 19 (23.45%), respectively. No significant differences were found between sexes in the diagnosis of odontogenic cysts. Mandible was the most prevalent site of dentigerous cysts.

**Conclusion:** The results of the present study showed the most prevalent odontogenic cysts were dentigerous cyst and radicular cysts.

**Keywords:** Odontogenic, Cyst, Dentigerous, Radicular, Children, Adolescent.

# Antineoplastic effects of citrate and celecoxib on mammary tumor cells

Reza Vahidi<sup>1</sup>, Alireza Farsinejad<sup>1</sup>, Mahsa Ziasistani<sup>1</sup>, Mohammad Mohsen Taghavi<sup>2</sup>, Rahim Vahidi<sup>1</sup>

<sup>1</sup>Pathology and Stem cell Research Center, School of Medicine, Kerman University of Medical Sciences, Kerman, Iran. <sup>2</sup>Department of Anatomy, Histology and Embryology, school of medicine, Rafsangan University of Medical Sciences, Iran.

**Introduction:** Canine mammary tumors have been proposed as a model to study human breast cancer owing to the great number of resemblances between them, from epidemiological data to the histological patterns of the neoplastic lesions. In addition, the same molecular properties such as overexpression of steroid receptors, proliferation markers, epidermal growth factor, p53 suppressor gene mutations and cyclooxygenases show similarities between the two. Celecoxib and citrate have been shown to possess antitumor activity in a variety of cancer cells. However, the antitumor activities of these agents on Cox<sub>2</sub>-negative mammary tumors have not been well demonstrated. The aim of our study was to investigate the apoptotic and antiproliferative effects of citrate and celecoxib, individually and in combination, on canine mammary tumor cell line CF41-Mg.

**Materials and Methods:** MTT assay was performed to determine cell viability, and Annexin-PI test was performed to evaluate apoptosis induction.

**Results:** MTT assay results revealed that compared with the control groups, treatment groups, as both single and combined treatments, showed significant inhibition of tumor growth in a dose-dependent manner. IC<sub>50</sub> concentrations of citrate and celecoxib were defined 26mM and 22μM, respectively. In another set of experiment, significant increase in cell apoptosis was observed at IC<sub>50</sub> concentrations of citrate and celecoxib after 48h incubation. In spite of that, simultaneous treatment of cells with citrate and celecoxib eventuated with meaningful toxicity augmentation and induction of apoptosis at lower concentrations. Also necrotic cells were decreased by coadministration of the two agents.

**Conclusion:** In conclusion, the present study indicates significant cytotoxic and apoptotic effects of citrate and celecoxib coadministration on CF41-Mg cells, and proposes new strategies for counteracting cancer cells proliferation and overcoming chemo resistance.

**Key words:** Mammary tumors, Citrate, Celecoxib, Apoptosis.

# Effect of chronic consumption of nandrolone decanoate along with high and mild intensity exercise on Bax/Bcl2 ratio in brain

Reza Vahidi<sup>1</sup>, Siyavash Joukar<sup>2,3</sup>, Beydolah Shahouzehi<sup>4</sup>, Alireza Farsinejad<sup>1</sup>

<sup>1</sup>Pathology and Stem cell Research Center, School of Medicine, Kerman University of Medical Sciences, Kerman, Iran. <sup>2</sup>Cardiovascular Research Center, Institute of Basic and Clinical Physiology Sciences, Kerman University of Medical Sciences, Kerman, Iran. <sup>3</sup>Department of Physiology and Pharmacology, Kerman University of Medical Sciences, Kerman, Iran. <sup>4</sup>Department of Biochemistry, School of Medicine, Kerman University of Medical Sciences, Kerman, Iran.

**Introduction:** Anabolic-androgenic steroids (AAS) are used by athletes to increase muscle mass and strength. There is some evidence related to the neurodegenerative and neurotoxicity effects of AAS agents such as nandrolone decanoate (ND). On the other hand, several studies have shown the ability of physical exercise to improve many aspects of brain function. In this study the effect of ND along with mild and severe exercise on some biochemical apoptosis indices of brain was investigated.

**Materials and Methods:** Animals were grouped in: 1. control group (CTL), 2. Vehicle group (Arach): received arachis oil twice/week for 8 weeks, 3. Nan group: received ND 5 mg/kg twice/week for 8 weeks, 4. Intense Exercise (IEx): 8 weeks under severe endurance swimming, 5. Mild Exercise (MEx): 8 weeks under mild endurance swimming. 6-7: Arach + (Intense & mild) Ex groups, and 8-9: Nan + (Intense & mild) Exs. At the end of the study period, animals were anesthetized and decapitated then brain tissues were dissected, frozen in liquid nitrogen, and subjected to western blotting in order to detect Bax and bcl2 proteins by specific antibodies.

**Results:** ND significantly increased bax/bcl-2 ratio compared to CTL group ( $P < 0.001$ ). This ratio was also insignificantly higher in exercise groups than CTL groups. Co-administration of ND and exercise with different severity decreased the bax/bcl-2 ratio in comparison with ND group ( $P < 0.001$ ).

**Conclusion:** ND can increase bax/bcl-2 ratio in brain and is a potential risk factor to degeneration of brain tissue. We showed that mild and intensive exercise can reverse ND deteriorating effects in brain by decreasing bax/bcl-2 ratio.

**Keywords:** Nandrolone decanoate, Brain, Exercise, Bax/bcl2 ratio.

# Adenoid Cystic Carcinoma: Clinical, Molecular and Pathological Features

Maryam Zamanzadeh<sup>1</sup>

<sup>1</sup>Assistant professor, Department of Oral and Maxillofacial Pathology, School of Dentistry, Mazandaran university of medical sciences, Sari, Iran.

Adenoid cystic carcinoma (ACC) is the most frequent malignant tumor of the sub-mandibular gland and the minor salivary glands. It is a malignant neoplasm that, despite its slow growth, shows an unfavorable prognosis. The clinical features and common pathological and molecular alterations of ACC are reviewed in this paper.

## **Clinical features**

The clinical course of conventional ACC is typically a slow but relentlessly progressive one. Although the majority of patients with ACC are alive at 5 years post diagnosis, the majority will go on to die of their disease. Although good local control is usually achieved by resection of the primary tumor, often accompanied by post-operative radiation therapy, late recurrence is common both regionally and at distant sites. Local recurrence is attributed in part due to the proclivity of ACC for perineural invasion. The neurotropism also contributes to the infiltrative nature of this neoplasm, with deep penetration of vital structures of the craniofacial region along major nerve trunks. Because of these clinical features, ACC has been described as “one of the most biologically destructive and unpredictable tumors of the head and neck”. Unlike most carcinomas of the head and neck, ACC seldom metastasizes to regional lymph nodes. Distant metastasis occurs in up to 40 % of cases, with the lungs being the most common site, but liver, kidney, bones and brain are also affected by metastatic disease.

## **Molecular alterations**

Recent studies have identified that the majority of ACC contain alterations of the MYB gene, usually resulting in a fusion gene product with the NFIB gene by a t(6;9) translocation event. The molecular consequences of this alteration are incompletely understood, as are secondary molecular alterations that contribute to the neoplastic phenotype of ACC.

## **Pathological features**

Histologically, ACC are composed of small basaloid epithelial tumor cells, with small to moderate amounts of cytoplasm. The nuclei tend not to be pleomorphic, and have small or inconspicuous nucleoli. The tumor is composed of cells that exhibit either luminal epithelial differentiation or myoepithelial differentiation, with myoepithelial differentiation predominating. Several growth patterns have been described for ACC. The most common and classic pattern is characterized by tumor cells arranged in variably sized nests of cells with distinct, punched-out spaces or pseudocysts, in a so-called cribriform pattern. The cribriform spaces contain hyaline material, variably eosinophilic or basophilic in color. Most carcinomas with such an appearance will secrete mucin; however, in ACC, the secreted substances are basement membrane constituents, including proteoglycans. A second growth pattern, typically mixed with the cribriform pattern, is a tubular pattern where the tumor infiltrates in separate gland-like groups with single central lumens. The third growth pattern is a solid growth pattern, where tumor cells grow in sheets without lumen formation. This third pattern has been recognized as representing a higher grade of tumor.

**Keywords:** Adenoid cystic carcinoma, Salivary gland neoplasms, Salivary glands, MYB, NFIB.

# Histogenesis of salivary gland neoplasms

Maryam Zamanzadeh<sup>1</sup>

<sup>1</sup>Assistant professor, Department of Oral and Maxillofacial Pathology, School of Dentistry, Mazandaran university of medical sciences, Sari, Iran.

Salivary gland tumors are one of the most complex and relatively rare group of lesions encountered in oral pathology practice. Their complexity is attributed to heterogeneity of the cells of origin of these lesions. The problem is compounded by the ability of these cells to differentiate and modify into various morphological subtypes resulting in a myriad of histomorphological patterns. This also leads to a frequent overlap of microscopic features among various neoplasms and sometimes even between benign and malignant lesions causing significant diagnostic dilemma which sometimes may even not be resolved by immunohistochemical studies. Despite this the knowledge of histogenesis and morphogenetic concepts of salivary gland tumorigenesis greatly helps the pathologist in classifying these lesions as well as determining the prognosis. It will also help in development of newer strategies for differentiating these lesions and making an early diagnosis.

The pathologists usually encounter benign neoplasms and very few experience full range of salivary cancers which are best managed in specialist centers. The modern approach is more realistic, in that histological typing is based on cellular differentiation rather than cell of origin. Immunohistochemical staining has only limited role in diagnosis of salivary gland tumors. Its main applications are:

1. To delineate whether there is two cell type differentiations in tumors with complex architecture. Demonstration of EMA or CEA may help to highlight ductal structures (glandular lumina) in the solid variant of AdCC, cellular pleomorphic adenoma, the solid form of epithelial myoepithelial carcinoma, and BCA
2. To confirm the diagnosis of myoepithelioma/ myoepithelial carcinoma by demonstrating markers such as calponin and actin
3. Ki-67 proliferative index may be useful in distinguishing an adenoma from a carcinoma (Ki-67 index usually <5% versus >10%).

Recently, CD117 have been shown to help in highlighting the luminal cell component of various salivary gland tumors, whereas p63 or maspin can aid in highlighting the abluminal cell component. Salivary gland tumors offer a myriad of diversity thus maintaining the ambiguity of these neoplasms. Still the enigma of diagnosing the salivary gland tumors continues challenging Oral Pathologists in routine practice. It is important for the pathologist to assess the cytoarchitectural features and cytoarchitectural profile of these neoplasms and correlate them with histogenetic concepts for better understanding which in turn will help in diagnosis and management of these lesions.

**Keywords:** Histogenesis, Morphogenesis, Salivary gland tumor.

# Survival, Growth and dedifferentiation of human chondrocytes in fibrin scaffolds

Mahsa ziasistani<sup>1</sup>, Ali derakhshani<sup>1</sup>, Alireza Farsinejad<sup>1</sup>

<sup>1</sup>Pathology and Stem cell Research Center, Kerman University of Medical Science, Kerman, Iran.

**Introduction:** In order to generate tissue-engineered autologous cartilage, there is tremendous interest in using human chondrocytes isolated from small biopsies. In this study, we investigated the potential of freshly isolated human chondrocytes cultivated in long-term stable fibrin tissue engineering of cartilage has been the focus of research owing to its superior structural rigidity and ease of harvest. In vitro constructs formed from chondrocytes using fibrin scaffold have been shown to be viable. We evaluated cellular proliferation and production of cartilaginous extracellular matrix (ECM) components in fibrin scaffold.

**Materials and Methods:** Human chondrocytes harvested from adult articular cartilage were expanded in monolayer and re-assembled three-dimensionally fibrin scaffolds. Chondrocytes in fibrin scaffolds was assessed by histological and immuno-histochemical staining. Fibrin scaffolds characteristics cells were then grown in fibrinogen, thrombin. After that A part of the construct as well as cell pellets were prepared as a histochemistry and immuno-histochemistry staining.

**Results:** Histological, immuno-histochemical showed that dedifferentiated chondrocytes fibrin scaffolds and form a cartilaginous matrix. Cellular proliferation per cell were highest in the fibrinogen, thrombin. Although expanded chondrocytes were embedded in fibrin scaffolds that ensure initial mechanical stability.

**Conclusion:** These data suggest that fibrin is suited as a mechanically stable support structure for scaffold-assisted chondrocyte grafts, initiating chondrogenic re-differentiation of expanded chondrocytes.

**Keywords:** Fibrin scaffold, Survival, Dedifferentiation, Proliferation, Chondrocyte.

# Laparoscopic Retroperitoneal Lymph Node Dissection After Chemotherapy: A Review

Seyed Amir Mohsen Ziaee<sup>1</sup>, Akbar Nouralizadeh<sup>1</sup>, Mohammad Ali Fallah<sup>1</sup>, Mohammad Ali Ghaed<sup>1</sup>, Mahboubeh Mirzaei<sup>2</sup>, Mohammad Hadi Radfar<sup>1</sup>

<sup>1</sup>Urology and Nephrology Research Center, Shahid Labbafinejad Hospital, Shahid Beheshti University of Medical Sciences, Tehran, Iran. <sup>2</sup>Department of Urology, Kerman University of Medical Sciences, Kerman, Iran.

**Introduction:** To review and summarize the literature regarding the current status of postchemotherapy laparoscopic retroperitoneal lymph node dissection (PCL-RPLND) in patients with testicular germ cell tumor.

**Evidence Acquisition:** A comprehensive review of the English literature was performed using the PubMed database using the terms “laparoscopy” or “laparoscopic”, retroperitoneal lymph node dissection, and “postchemotherapy” or “chemotherapy”.

**Results:** PC L-RPLND is more challenging than primary L-RPLND. However, morbidity, operative time, and complications have improved as surgical experience has increased.

**Conclusion:** PCL-RPLND is a technically demanding procedure and should be performed in high volume-centers. It has been shown that PCL-RPLND is a feasible and effective procedure in experienced hands. The oncological efficacy of this approach is similar to the results of open series.

**Keywords:** Testicular neoplasms, Laparoscopy, Chemotherapy.



# Laparoscopic nephroureterectomy with concomitant open bladder cuff excision: a single center experience

Ziaee SA<sup>1</sup>, Azizi V<sup>1</sup>, Nouralizadeh A<sup>1</sup>, Gooran S<sup>1</sup>, Radfar MH<sup>1</sup>, Mirzaei M<sup>2</sup>

<sup>1</sup>Urology and Nephrology Research Center, Shahid Labbafinejad Hospital, Shahid Beheshti University of Medical Sciences, Tehran, Iran. <sup>2</sup>Department of Urology, Kerman University of Medical Sciences, Kerman, Iran.

**Purpose:** To evaluate the efficacy of laparoscopic nephroureterectomy and open bladder cuff excision for management of upper urinary tract urothelial carcinoma.

**Materials and Methods:** Twenty-two patients with upper urinary tract urothelial carcinoma, who had undergone laparoscopic nephroureterectomy and open bladder cuff excision between September 2004 and October 2010, were studied retrospectively. Operation time, blood loss, analgesic dose, and complications were recorded. Local and port site recurrence, distant metastasis, and survival rate were also evaluated.

**Results:** Patients consisted of 18 men and 4 women, with the mean age of 64.1 years (range, 52 to 83 years). Right upper urinary tract was the involved site in 12 patients and left in 10 patients. Mean operation time was 216 minutes (range, 145 to 395 minutes) and mean hospital stay was 4.3 days. Mean follow-up period was 36.57 months (range, 6 to 65 months). No trocar site recurrence occurred. Three-year overall survival and metastasis-free survival were 95% and 90%, respectively.

**Conclusion:** Laparoscopic nephroureterectomy along with open bladder cuff excision harbors an advantage of laparoscopy concomitant with simplicity and safety of open excision of distal ureter and bladder cuff through the same inevitable incision that is needed for specimen retrieval, without adding any more morbidity to the patient, a win-win radical surgery.

**Keywords:** Laparoscopic nephroureterectomy, Urothelial carcinoma, Open bladder cuff excision.