



ISSN:
Electronic version: 1984-5685
RSBO. 2020 Jan-Jun;17(1):12-20

Original Research Article

Analysis of the internal anatomy of mandibular molars using different cone-beam computed tomography protocols

Flares Baratto-Filho¹
Nathaly Dias Morais¹
Kauhanna Vianna de Oliveira¹
Flávia Sens Fagundes Tomazinho¹
Carla Castiglia Gonzaga¹
Marilisa Carneiro Leão Gabardo¹
Jardel Francisco Mazzi-Chaves²
Manoel Damiano Sousa-Neto²

Corresponding author:

Flares Baratto-Filho
Rua Prof. Pedro Viriato Parigot de Souza, n. 5.300
CEP 81280-330 – Curitiba – Paraná – Brasil
E-mail: fbaratto1@gmail.com

¹ School of Health Sciences, Universidade Positivo – Curitiba – PR – Brazil.

² Department of Dentistry, Universidade de São Paulo – Ribeirão Preto – SP – Brazil.

Received for publication: February 7, 2020. Accepted for publication: May 24, 2020.

Keywords:

anatomy; Endodontics;
cone-beam computed
tomography.

Abstract

Introduction and Objective: The aim of this study was to analyze the root canal anatomy variations of permanent mandibular molars using three different cone-beam computed tomography (CBCT) protocols. **Material and methods:** Thirty-five freshly extracted first and second mandibular molars were collected and subjected to three CBCT protocols: i-CAT Classic (ICC); i-CAT Next Generation (ICN), and PreXion 3D (PXD). Images were evaluated by two previously calibrated and experienced endodontists. The morphological root canal configurations were classified according to Vertucci. Data were analyzed for frequency, and the binomial and Kappa tests were then performed ($\alpha = 0.05$). **Results:** ICC and ICN were able to diagnose a higher percentage of anatomical variations in the mesial roots. In this same root, Vertucci's type V was the most prevalent, and in distal was the type I. In comparisons of CBCT techniques for agreement, significant differences in the mesial root canals were found in the following: ICC *versus* (vs) ICN; ICC vs PXD; and ICN vs PXD ($p < 0.001$). However, there were no statistical differences in

the distal root canals ($p > 0.05$). The level of agreement in mesial roots was poor or absent, while in distal was moderate. **Conclusion:** Anatomical variations were found in both root canals, with higher variability in the mesial, highlighting ICC and ICN protocols, and the prevalence of Vertucci's type V, while in the distal prevailed the type I.

Introduction

Clinical success in endodontic treatment is considered achieved when the tooth is in totally function, without painful symptomatology, with absence of periapical inflammation and adequate root canal filling confirmed by radiographic images [14]. Therefore, the knowledge of the root canals anatomy and its variations is extremely important for the success of endodontic treatment [3, 8, 12, 42, 43].

Studies investigating the internal anatomy of dental groups have been performed, presenting a variety [1, 2, 4, 6, 27, 37, 39, 41], through different identification techniques, such as radiographic examinations, tooth sectioning, among others [3, 24, 25, 30]. However, most of these methods are destructive and/or may modify the tooth anatomy, which limits the use of these methods [20].

Although periapical radiography is widely used in endodontics, overlapping structures, possible distortions and the ability to compress three-dimensional structures in two-dimensional images can obscure important anatomical details, the knowledge of which would result in a more accurate diagnosis and efficient endodontic treatment [38]. Current techniques enable the identification of root canals without further damage to teeth or the patient [20]. In this regard, cone-beam computed tomography (CBCT) can provide high-contrast three-dimensional volumetric images at low cost and low radiation exposure [17, 26, 28] due to its limited field of view (FOV) in the axial dimension [36].

Different CBCT protocols have been studied to identify the most suitable protocol for each clinical step with lower radiation doses for the patients [5, 23, 34].

The diagnostic capacity of CBCT has motivated several researches [5, 13, 20, 22, 27, 31, 37, 38, 40]. Studies have been performed to classify the internal anatomy in mandibular molars, since this group of teeth presented a high complexity root canal system [6, 9-12, 15, 18, 33], and requires more frequently an endodontic treatment [16, 32]. Thus,

the aim of this study was to analyze the ability of different CBCT images in the root canal morphology classification of mandibular molars using different CBCT protocols: i-CAT Classic (Imaging Sciences International, Hatfield, USA); i-CAT Next Generation (Imaging Sciences International, Hatfield, USA); and PreXion 3D (Prexion, San Mateo, USA).

Material and methods

Sample selection

After approval by the research ethics committee (registration no. 2.077.489) from Universidade Positivo, 35 freshly extracted first and second molars with the following features were analyzed: (a) closed apex, (b) no previous endodontic treatment, resorption, perforation, visible signs of fracture or cracking, and (c) three distinct canals (mesiobuccal, mesiolingual, and distal) identified using periapical radiography.

The sample was then classified according to the classifications proposed by Vertucci [42], and Al-Qudah and Awawdeh [3], and randomly assigned to one of the three protocols. The pulp chambers were then accessed using 1014 and 3081 HL drills (KG Sorensen, São Paulo, Brazil). The canal negotiation was performed using a K#10 file (Dentsply Maillefer, Ballaigues, Switzerland) to confirm the distinction of the canals under clinical conditions.

Cone-beam computed tomographic acquisitions

Digital radiography was performed using the digital Snapshot size 1 sensor (Instrumentarium Imaging, Tuusula, Finland) with an active area of 19.95 mm × 30 mm. The radiation unit used for radiography was the Spectro 70x Seletronic (Dabi Atlante, Ribeirão Preto, Brazil) operating at 7 mA, 70 kV, and exposure time of 0.25 s. The samples were placed in a special device to guarantee parallelism during radiographic imaging (orthoradial, mesioradial, and distoradial).

Tomographic examinations

The roots were previously coated with utility wax to simulate the space occupied by the periodontal ligament [20]. Then, the teeth were placed on an acrylic holder with external dimensions of 9.8 cm × 5.4 cm × 2.4 cm, and a 5 mm of wall thickness, filled with common gypsum and rice flour in equal proportions to mimic the alveolar bone [26].

Three tomography protocols were used as follow:

1. ICC Group (i-CAT Classic): 120 kV; 3-8 mA; 0.25 mm of isotropic voxel; FOV of 6 cm × 13 cm; and acquisition time of 40 s.
2. ICN Group (i-CAT Next Generation): 120 kV; 3-8 mA; 0.125 mm of isotropic voxel; FOV of 8 cm × 8 cm; and acquisition time of 26.9 s.
3. PXD Group (PreXion3D): 90 kV; 4 mA; 0.09 mm of isotropic voxel; FOV of 5.6 cm × 5.6 cm; and acquisition time of 16.8 s.

Images acquired from the ICC and ICN groups were analyzed using iCAT Vision 1.8.1.10 software (Imaging Sciences International, Hatfield, USA), while images from the PXD group were analyzed using the PreXion 3D Viewer (Prexion, San Mateo, USA) The study protocol of the Freitas *et al.* [8] was followed.

All images were evaluated simultaneously by two calibrated and experienced endodontists (kappa = 0.81), whose interpretations were based on the sagittal, axial, and coronal views, changing the

zoom controls, and adjusting brightness, contrast and sharpness to allow better visualization whenever necessary using protocol-independent software. The number and morphology of the canals of the mesial and distal roots were then observed and recorded.

Statistical analysis

Frequency analyses, binomial and Kappa tests were performed using SPSS version 21 (IBM Corp., Armonk, USA). A significance level of 0.05, with corresponding 95% confidence interval (CI), was adopted to compare the results of the applied protocols. The results of the Kappa's test were analyzed according to Landis and Koch [19].

Results

Data regarding the visualization of the number of canals found in both roots of the mandibular molars using the different tomographic protocols are summarized in table I, and the frequencies of the root canal configurations are shown in table II. Vertucci's type V (1-2) was the most prevalent in mesial root canals, and in distal was type I (1-1). It was observed that ICC and ICN diagnosed a higher percentage of anatomical configurations in the mesial roots when compared to PXD (table II).

Table I - Number of canals of mandibular molars from cervical to apical direction (n = 35)

Sample	ICC	ICN	PXD	ICC	ICN	PXD
		M			D	
1	1-2	1-2	1-2	1	1	1
2	1-2	1-2	1-2-1	1	1	1
3	1-2-1	1-2-1	1-2-1	1	1	1
4	2-1	2-1-2-1	2-3-2-1	1	1	1
5	2-1	1-2-3-1	1-2-3-2-1	1	1	1
6	1-2-1	2-1	1-2-1	1	1	1
7	1-2-1	1-2-1	1-2-1	1-2-1	1-2-1	1-2-1
8	1-2-1	1-2-1	1-2-1	1	1-2-1-2-1	1
9	2-1-2	1-2-1	1-2-1	1	1	1
10	1-2	2	1-2-1	1	1-2	1
11	1-2-1	1-2-1	1-2-1	1	1	1-2
12	2	1-2	1-2	1	1	1
13	2	2	1-2	1	1	1
14	1-3-2	1-3-2-1	1-3-2-1	1	1	1
15	1-2	1-2-1	1-2-1	1	1	1
16	2-1	1	1	1	1	1

(Continues on the next page)

Sample	ICC	ICN	PXD	ICC	ICN	PXD
		M			D	
17	2-1	1-2-1-2	2-3-2-1	2-1	1-2-1	1-2-1
18	2	1-2	2-1-2	1	1	1
19	1-2	2	1-2-1-2	1	1	1
20	1-2	1-2	2-3-2	1	1	1
21	1-2	1	1	1	1	1
22	1-2-1	1-2-1	1-2-1	1	1	1
23	1-2	1-2	1-2	1	1	1
24	2	2	2	1	1	1
25	2	1-2	1-2	1	1-2-1	1
26	1-2	1-2-1	1-2-1	1	1	1
27	1-2-1	1-2-1	1-2-1	1	1	1
28	1-2	1-2	1-2-1-2	1	1	1
29	2-1	1-2-1	1-2	1	1	1
30	2	1-2	1-2	1	1	1
31	2	1-2	1-2	1	1	1
32	2	3-2	1-2-1	1	1	1
33	2	2	1-2-1	1	1	1
34	1-2	1-2	1-2	1	1	1
35	2	1-2	1-2	1-2	1-2	1

Note: M (mesial); D (distal); ICC (i-CAT Classic); ICN (i-CAT Next Generation); PXD (PreXion 3D)

In the mesial roots, the frequencies of agreement among the three protocols for configurations 1-2-1 (type III), 1-2 (type V) and 2-2 (type IV) were 17.1%, 8.6% and 2.8%, respectively. For the distal root, configurations 1-1 (type I) and 1-2-1 (type III), prevailed in 80.0% and 2.8% of samples, respectively.

Table II - Frequencies of anatomical variations of different tomographic protocols (n = 35)

Anatomical variation (Type)	ICC	ICN	PXD	ICC	ICN	PXD
	n (%)	n (%)	n (%)	n (%)	n (%)	n (%)
	M			D		
1-1 (I)	-	1 (2.9)	-	32 (91.4)	29 (82.9)	32 (91.4)
2-1 (II)	5 (14.3)	1 (2.9)	-	1 (2.9)	-	-
1-2-1 (III)	7 (20.0)	10 (28.6)	2 (5.7)	1 (2.9)	3 (8.6)	2 (5.7)
2-2 (IV)	10 (28.6)	6 (17.1)	-	-	-	-
1-2 (V)	11 (31.4)	13 (37.1)	33 (94.3)	1 (2.9)	2 (5.7)	1 (2.9)
1-2-1-2 (VII)	-	1 (2.9)	-	-	-	-
1-2-1-2-1	-	-	-	-	1 (2.9)	-
1-2-3-1	-	1 (2.9)	-	-	-	-
1-3-2	1 (2.9)	-	-	-	-	-
2-1-1	1 (2.9)	-	-	-	-	-
2-1-2-1	-	1 (2.9)	-	-	-	-
3-2	-	1 (2.9)	-	-	-	-

Note: M (mesial); D (distal); ICC (i-CAT Classic); ICN (i-CAT Next Generation); PXD (PreXion 3D)

Table III shows the concordant anatomical variations between the groups based on the tomographic protocols.

Table III - Concordant anatomical variations of different tomographic protocols (n = 35)

Anatomical variation	ICCxICN	ICCxPXD	ICNxPXD	ICCxICN	ICCxPXD	ICNxPXD
	M			D		
1				29	31	28
1-2	7	11	13	1	1	
1-2-1	6			1		2
2	3					
Total	16	11	13	31	32	30

Note: M (mesial); D (distal); ICC (i-CAT Classic); ICN (i-CAT Next Generation); PXD (PreXion 3D)

Concordance among the mesial roots varied, with values of 45.7% (n = 16) between the ICC and ICN groups (p < 0.001); 31.4% (n = 11) between ICC and PXD (p < 0.001); and 37.1% (n = 13) between ICN and PXD (p < 0.001); in the distal roots the values were 88.6% (n = 31) between ICC and ICN (p = 0.125), 91.4% (n = 32) between ICC and PXD; and 85.7% (n = 30) between ICN and PXD (p = 0.063) (table IV).

Table IV - Agreement between the groups of the different tomographic protocols (n = 35)

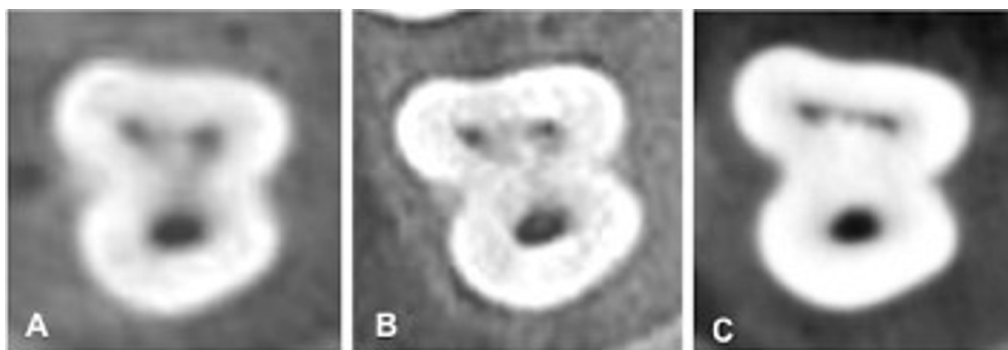
Agreement	ICCxICN		ICCxPXD		ICNxPXD		ICCxICN		ICCxPXD		ICNxPXD													
	M												D											
	n	%	n	%	n	%	n	%	n	%	n	%												
Yes	16	45.7	11	31.4	13	37.1	31	88.6	32	91.4	30	85.7												
No	19	54.3	24	68.6	22	62.9	4	11.4	3	8.6	5	14.3												
Total	35	100.0	35	100.0	35	100.0	35	100.0	35	100.0	35	100.0												
95% CI	LL	UL	LL	UL	LL	UL	LL	UL	LL	UL	LL	UL												
	29.2%	62.2%	16.0%	46.8%	21.1%	53.2%	78.0%	99.1%	82.2%	100.7%	74.1%	97.3%												
p value*	p < 0.001		p < 0.001		p < 0.001		p = 0.125		p = 0.250		p = 0.063													

Note: M (mesial); D (distal); ICC (i-CAT Classic); ICN (i-CAT Next Generation); PXD (PreXion 3D); LL (lower limit) UL (upper limit)

* Binomial test (p < 0.05)

The level of agreement in the paired analyzes revealed the following Kappa values in mesial roots: ICC x ICN = 0.298 (p < 0.001), ICC x PXD = 0.009 (p = 0.814), and ICN x PXD = 0.008 (p = 0.877). In distal roots, the values were, respectively, 0.521 (p < 0.001), 0.470 (p < 0.001), and 0.394 (p = 0.001). These data analyses indicated poor or no agreement between the protocols in the mesial roots, while in the distal the agreement was moderate in all comparisons.

Representative samples of the images acquired using the ICC, ICN, and PXD protocols are presented in figure 1.

**Figure 1** - Images obtained through the protocols (A) ICC, (B) ICN and (C) PXD

Discussion

The present study aimed to analyze the internal anatomy of mandibular molars comparing images acquired using three different tomography protocols. The main results revealed differences among all protocols in the mesial roots.

Knowledge of root canal morphology is a challenge for the dentist, and can directly influence on success of the endodontic treatment [8, 12] if the presence of any additional root canal is not identified and treated [3, 42, 43].

The morphological features of each group of teeth have been researched, which has led to the introduction of a variety of anatomical classifications [1, 2, 4, 8, 24, 25, 27, 30, 37, 39, 41]. For some groups, as in case of maxillary molars, four canals have been found [4, 27, 41] and, in premolars, three canals have been described [1].

The differences among studies can be explained by the methodology design adopted (*in vivo* or *ex vivo*), and by the technique used to classify the root canals, including radiographic examinations, tooth sectioning, among others [3, 30]. However, some techniques used in morphological studies are destructive and/or distort tooth anatomy and, as such, their applicability is limited [20].

In this context, non-destructive and more precise techniques, such as CBCT, have been developed for the study of anatomical variations [17, 34]. A review by Venskutonis *et al.* [38] indicated that this method can be used from diagnosis to post-treatment, but is proposed mainly for evaluation of root canal anatomy. Regarding radiation dose, the authors reported that it is equivalent to the dose in case of panoramic radiography [38].

Findings from the present study revealed statistically significant differences in paired comparisons between groups for the mesial roots. ICC and ICN exams revealed a higher percentage of canal configurations, such as in the results of de Freitas *et al.* [8]. ICC protocol was limited in the identification of additional canals compared with the other groups, evidenced by the lack of concordance in cases with greater anatomical complexity in the mesial roots identified by the ICN and PXD. In the distal roots, anatomical complexities were better identified using the ICN and PXD.

The superior image quality of cone beam tomographs due more to the voxel dimensions, which has more of an effect on results in terms of resolution and details [7, 34] which corroborates other findings [7].

Smaller voxel sizes require longer scanning time and, consequently, greater radiation exposure

[35]. The PXD protocol chosen for this research has been marketed by the manufacturer as high resolution, with 16.8 s being the most appropriate exposure time to reduce exposure of the patient to radiation, despite having the smallest voxel size (0.09 mm).

The choice of FOV sizes in the present study stems from the limited field of analysis. In clinical terms, this limitation leads to a reduction in the patient's exposure to radiation, which is one of the advantages attributed to CBCT [29].

The mesial roots of mandibular molars exhibit greater anatomical diversity, as verified in the current research. In an analysis of 200 teeth of this group using CBCT, Gambarini *et al.* [15] verified the presence of two canals in all cases. These findings differ from those observed here, because the presence of a single canal was found in two samples, with concordance between ICN and PXD, but different from ICC. This difference may have been due to the lower precision of the images acquired using this system, as previously mentioned.

The existence of two canals in the mesial root has been verified in the majority of research using CBCT [6, 10, 15, 18, 33]. In the present study, the types found were, in decreasing order of prevalence: V (1-2), IV (2-2), and III (1-2-1). Torres *et al.* [37] found in Chilean and Belgian populations the most common configurations in the mesial root of mandibular molars was type V. In a systematic review published in 2012, de Pablo *et al.* [11] reported that the most common anatomical configurations in mesial roots are type IV (2-2) and II (2-1). Demirbuga *et al.* [9] found the type IV was the most prevalent configuration in the mesial roots of first mandibular molars, corroborating Kim *et al.* [18], Madani *et al.* [22], and Mohammadzadeh Akhlaghi *et al.* [24].

The common anatomical variation, consisting of only one canal located in the distal root, was found to be concordant among the three systems in 80.0% of the samples. This corroborates the results of other studies [6, 9-11, 18, 33, 37], which indicate a higher frequency of this occurrence in mandibular molars.

Differences found in terms of the frequency of localized canals can be attributed to the method of analysis of anatomical variations, which can be based on the absence or presence of canals [5], or the configuration of canals found in the cervical to apical direction, as adopted in the present research. Additionally, although the Vertucci's classification [42] is the most recognized and used parameter in

this type of study in endodontics, its introduction predates the use of tomographic imaging modalities.

Despite the diagnostic superiority of CBCT, indications for use must be accurate and justified based on inconclusive findings from conventional techniques [34], because it may result in higher doses of absorbed radiation [21]. As with any complementary examination, its use should be considered in clinical diagnosis. The theoretical identification of anatomical variations does not necessarily mean that these canals can be accessed clinically [4].

Conclusion

Anatomical variations were found in both root canals, with higher variability in the mesial, highlighting ICC and ICN protocols, and the prevalence of Vertucci's type V, while in the distal prevailed the type I.

References

- Ahmed HMA, Cheung GSP. Accessory roots and root canals in maxillary premolar teeth: a review of a critical endodontic challenge. *ENDO – Endodontic Practice Today*. 2012;6(1):7-18.
- Ahmed HMA, Versiani MA, De-Deus G, Dummer PMH. A new system for classifying root and root canal morphology. *Int Endod J*. 2017;50(8):761-70.
- Al-Qudah AA, Awawdeh LA. Root and canal morphology of mandibular first and second molar teeth in a Jordanian population. *Int Endod J*. 2009;42(9):775-84.
- Baratto-Filho F, Zaitter S, Haragushiku GA, de Campos EA, Abuabara A, Correr GM. Analysis of the internal anatomy of maxillary first molars by using different methods. *J Endod*. 2009;35(3):337-42.
- Bauman R, Scarfe W, Clark S, Morelli J, Scheetz J, Farman A. Ex vivo detection of mesiobuccal canals in maxillary molars using CBCT at four different isotropic voxel dimensions. *Int Endod J*. 2011;44(8):752-8.
- Choupani Dastgerdi A, Navabi M, Hafezi L, Khalilak Z, Rakhshan V. Anatomy of permanent mandibular first molars in a selected Iranian population using bone-beam computed tomography. *Iran Endod J*. 2018;13(2):251-6.
- da Silveira PF, Fontana MP, Oliveira HW, Vizzotto MB, Montagner F, Silveira HL et al. CBCT-based volume of simulated root resorption – influence of FOV and voxel size. *Int Endod J*. 2015;48(10):959-65.
- de Freitas JV, Baratto-Filho F, Coelho BS, Tomazinho FSF, Crozeta BM, de Sousa Neto MD et al. Efficacy of different cone-beam computed tomographic protocols in the identification of mesiobuccal canals of maxillary first molars: a tomographic and ex vivo study. *J Endod*. 2017;43(5):810-5.
- Demirbuga S, Sekerci AE, Dincer AN, Cayabatmaz M, Zorba YO. Use of cone-beam computed tomography to evaluate root and canal morphology of mandibular first and second molars in Turkish individuals. *Med Oral Patol Oral Cir Bucal*. 2013;18(4):e737-44.
- Deng PU, Halim MS, Masudi SM, Al-Shehadat S, Ahmad B. Cone-beam computed tomography analysis on root and canal morphology of mandibular first permanent molar among multiracial population in East Coast Malaysian population. *Eur J Dent*. 2018;12(3):410-6.
- de Pablo OV, Estevez R, Heilborn C, Cohenca N. Root anatomy and canal configuration of the permanent mandibular first molar: clinical implications and recommendations. *Quintessence Int*. 2012;43(1):15-27.
- de Pablo OV, Estevez R, Peix Sanchez M, Heilborn C, Cohenca N. Root anatomy and canal configuration of the permanent mandibular first molar: a systematic review. *J Endod*. 2010;36(12):1919-31.
- Domark JD, Hatton JF, Benison RP, Hildebolt CF. An ex vivo comparison of digital radiography and cone-beam and micro computed tomography in the detection of the number of canals in the mesiobuccal roots of maxillary molars. *J Endod*. 2013;39(7):901-5.

14. Estrela C, Holland R, Estrela CR, Alencar AH, Sousa-Neto MD, Pécora JD. Characterization of successful root canal treatment. *Braz Dent J.* 2014;25(1):3-11.
15. Gambarini G, Piasecki L, Ropini P, Miccoli G, Di Nardo D, Testarelli L. Cone-beam computed tomographic analysis on root and canal morphology of mandibular first permanent molar among multiracial population in Western European population. *Eur J Dent.* 2018;12(3):434-8.
16. Hollanda AC, de Alencar AH, Estrela CR, Bueno MR, Estrela C. Prevalence of endodontically treated teeth in a Brazilian adult population. *Braz Dent J.* 2008;19(4):313-7.
17. Jeger FB, Lussi A, Bornstein MM, Jacobs R, Janner SF. Cone beam computed tomography in endodontics: a review for daily clinical practice. *Schweiz Monatsschr Zahnmed.* 2013;123(7-8):661-8.
18. Kim SY, Kim BS, Woo J, Kim Y. Morphology of mandibular first molars analyzed by cone-beam computed tomography in a Korean population: variations in the number of roots and canals. *J Endod.* 2013;39(12):1516-21.
19. Landis JR, Koch GG. The measurement of observer agreement for categorical data. *Biometrics.* 1977;33(1):159-74.
20. Lee KW, Kim Y, Perinpanayagam H, Lee JK, Yoo YJ, Lim SM et al. Comparison of alternative image reformatting techniques in micro-computed tomography and tooth clearing for detailed canal morphology. *J Endod.* 2014;40(3):417-22.
21. Ludlow JB, Ivanovic M. Comparative dosimetry of dental CBCT devices and 64-slice CT for oral and maxillofacial radiology. *Oral Surg Oral Med Oral Pathol Oral Radiol Endod.* 2008;106(1):106-14.
22. Madani ZS, Mehraban N, Moudi E, Bijani A. Root and canal morphology of mandibular molars in a selected Iranian population using cone-beam computed tomography. *Iran Endod J.* 2017;12(2):143-8.
23. Melo SL, Bortoluzzi EA, Abreu Jr. M, Correa LR, Correa M. Diagnostic ability of a cone-beam computed tomography scan to assess longitudinal root fractures in prosthetically treated teeth. *J Endod.* 2010;36(11):1879-82.
24. Mohammadzadeh Akhlaghi N, Khalilak Z, Vatanpour M, Mohammadi S, Pirmoradi S, Fazlyab M et al. Root canal anatomy and morphology of mandibular first molars in a selected Iranian population: an in vitro study. *Iran Endod J.* 2017;12(1):87-91.
25. Mokhtari H, Niknami M, Mokhtari Zonouzi HR, Sohrabi A, Ghasemi N, Akbari Golzar A. Accuracy of cone-beam computed tomography in determining the root canal morphology of mandibular first molars. *Iran Endod J.* 2016;11(2):101-5.
26. Neves FS, Vasconcelos TV, Vaz SL, Freitas DQ, Haiter-Neto F. Evaluation of reconstructed images with different voxel sizes of acquisition in the diagnosis of simulated external root resorption using cone beam computed tomography. *Int Endod J.* 2012;45(3):234-9.
27. Nikoloudaki GE, Kontogiannis TG, Kerezoudis NP. Evaluation of the root and canal morphology of maxillary permanent molars and the incidence of the second mesiobuccal root canal in greek population using cone-beam computed tomography. *Open Dent J.* 2015;9:267-72.
28. Patel S. New dimensions in endodontic imaging: Part 2. Cone beam computed tomography. *Int Endod J.* 2009;42(6):463-75.
29. Pauwels R, Zhang G, Theodorakou C, Walker A, Bosmans H, Jacobs R et al. Effective radiation dose and eye lens dose in dental cone beam CT: effect of field of view and angle of rotation. *Br J Radiol.* 2014;87(1042):20130654.
30. Prado MC, Gusman H, Belladonna FG, Prado M, Ormiga F. Effectiveness of three methods for evaluating root canal anatomy of mandibular incisors. *J Oral Sci.* 2016;58(3):347-51.
31. Rahimi S, Mokhtari H, Ranjkesh B, Johari M, Frough Reyhani M, Shahi S et al. Prevalence of extra roots in permanent mandibular first molars in Iranian population: a CBCT analysis. *Iran Endod J.* 2017;12(1):70-3.
32. Scavo R, Martinez Lalis R, Zmener O, Dipietro S, Grana D, Pameijer CH. Frequency and distribution of teeth requiring endodontic therapy in an Argentine population attending a specialty clinic in endodontics. *Int Dent J.* 2011; 61(5): 257-60.

33. Silva EJ, Nejaim Y, Silva AV, Haiter-Neto F, Cohenca N. Evaluation of root canal configuration of mandibular molars in a Brazilian population by using cone-beam computed tomography: an in vivo study. *J Endod.* 2013;39(7):849-52.
34. Special Committee to Revise the Joint AAE/AAOMR Position Statement on use of CBCT in Endodontics. AAE and AAOMR Joint Position Statement: use of cone beam computed tomography in Endodontics 2015 Update. *Oral Surg Oral Med Oral Pathol Oral Radiol.* 2015;120(4):508-12.
35. Stratemann SA, Huang JC, Maki K, Miller AJ, Hatcher DC. Comparison of cone beam computed tomography imaging with physical measures. *Dentomaxillofac Radiol.* 2008;37(2):80-93.
36. Suomalainen A, Vehmas T, Korttesniemi M, Robinson S, Peltola J. Accuracy of linear measurements using dental cone beam and conventional multislice computed tomography. *Dentomaxillofac Radiol.* 2008;37(1):10-7.
37. Torres A, Jacobs R, Lambrechts P, Brizuela C, Cabrera C, Concha G et al. Characterization of mandibular molar root and canal morphology using cone beam computed tomography and its variability in Belgian and Chilean population samples. *Imaging Sci Dent.* 2015;45(2):95-101.
38. Venskutonis T, Plotino G, Juodzbaly G, Mickeviciene L. The importance of cone-beam computed tomography in the management of endodontic problems: a review of the literature. *J Endod.* 2014;40(12):1895-901.
39. Versiani MA, Ordinola-Zapata R, Keles A, Alcin H, Bramante CM, Pécora JD et al. Middle mesial canals in mandibular first molars: a micro-CT study in different populations. *Arch Oral Biol.* 2016;61:130-7.
40. Versiani MA, Pecora JD, Sousa-Neto MD. Microcomputed tomography analysis of the root canal morphology of single-rooted mandibular canines. *Int Endod J.* 2013;46(9):800-7.
41. Versiani MA, Pécora JD, de Sousa-Neto MD. Root and root canal morphology of four-rooted maxillary second molars: a micro-computed tomography study. *J Endod.* 2012;38(7):977-82.
42. Vertucci FJ. Root canal anatomy of the human permanent teeth. *Oral Surg Oral Med Oral Pathol.* 1984;58(5):589-99.
43. Vertucci FJ. Root canal morphology and its relationship to endodontic procedures. *Endod Topics.* 2005;10(1):3-29.