

Artículo de investigación

Investigation of the ectoine gel reparative effect on a thermal burn model

Investigación del efecto reparador del gel ectoine en un modelo de quemadura térmica

Investigação do efeito reparador do gel de ectoína em modelo de queima térmica

Recibido: 20 de septiembre de 2018. Aceptado: 11 de octubre de 2018

Written by:

Alena V. Majorova (Corresponding Author)¹³⁵Boris B. Sysuev¹³⁶Anna V. Sokolova-Merkur'eva¹³⁶Snezhana B. Evseeva¹³⁶Natal'ya I. Nesterova¹³⁶Oksana V. Dudchenko¹³⁶Vladislava A. Veselova¹³⁶Olesya A. Puchenkova¹³⁶Vladislav O. Soldatov¹³⁶

Abstract

Due to the ability to create complexes of water molecules on the surface of the mucous membrane, ectoine is a promising compound for the treatment of burns. In male rats ($n=30$), 2 thermal burns were counteracted under counter-anesthesia, one of which was treated by topical application of the test drugs for 7 days, and the other served as a control. On the 8th day, skin samples in the area of the burn were taken for morphological examination. Histological sections were then scored by independent experts. The best histological picture of thermally damaged tissues was demonstrated by animals receiving ectoine. A less significant, but pronounced reparative effect was observed in histological samples of the actovegin group. The least significant reparative effect was demonstrated by contractubex. Ectoine improved the histological picture, improved repair and reduced the inflammatory response of the tissues and can be recommended for further preclinical studies as a treatment for burns.

Keywords: Ectoine gel, thermal burn model, counter-anesthesia, skin, histology

Resumen

Debido a la capacidad de crear complejos de moléculas de agua en la superficie de la membrana mucosa, la ectoína es un compuesto prometedor para el tratamiento de las quemaduras. En ratas macho ($n = 30$), 2 quemaduras térmicas se contrarrestaron con contraestesia, una de las cuales se trató mediante la aplicación tópica de los fármacos de prueba durante 7 días, y la otra sirvió como control. En el octavo día, se tomaron muestras de piel en el área de la quemadura para un examen morfológico. Las secciones histológicas fueron calificadas por expertos independientes. El mejor cuadro histológico de los tejidos dañados térmicamente fue demostrado por los animales que recibieron ectoína. Se observó un efecto reparador menos significativo, pero pronunciado en muestras histológicas del grupo actovegin. El efecto reparador menos significativo fue demostrado por contractubex. Ectoine mejoró el cuadro histológico, mejoró la reparación y redujo la respuesta inflamatoria de los tejidos y puede recomendarse para estudios preclínicos adicionales como tratamiento para las quemaduras.

¹³⁵ Belgorod State University, 85, Pobedy St., Belgorod, 308015, Russia
e-mail: 1263220@bsu.edu.ru

¹³⁶ Belgorod State University, 85, Pobedy St., Belgorod, 308015, Russia

Palabras claves: Ectoine gel, modelo de quemadura térmica, contraestesia, piel, histología.

Resumo

Devido à capacidade de criar complexos de moléculas de água na superfície da membrana mucosa, a ectoína é um composto promissor para o tratamento de queimaduras. Em ratos machos ($n = 30$), duas queimaduras térmicas foram combatidas sob anestesia, uma das quais foi tratada por aplicação tópica das drogas de teste por 7 dias, e a outra serviu como controle. No oitavo dia, amostras de pele na área da queimadura foram retiradas para exame morfológico. As secções histológicas foram então classificadas por especialistas independentes. O melhor quadro histológico dos tecidos termicamente lesados foi demonstrado pelos animais que receberam ectoína. Um efeito reparador menos significativo, mas pronunciado, foi observado em amostras histológicas do grupo da actovegina. O efeito reparador menos significativo foi demonstrado pelo contratoubex. Ectoine melhorou o quadro histológico, melhorou o reparo e reduziu a resposta inflamatória dos tecidos e pode ser recomendado para estudos pré-clínicos adicionais como tratamento para queimaduras.

Palavras-chave: Ectoine gel, modelo de queimadura térmica, contra-anestesia, pele, histologia

Introduction

Along with the targeted pharmacological preparations of the new generation, for experimental pharmacology, simpler compounds do not lose their relevance (Soldatov et al, 2018; Rajkumar et al, 2016; Voronkov & Pozdnyakov, 2018; Peresytkina et al, 2016; Danilenko, 2018; Shakhno et al, 2016; Galenko-Yaroshevsky et al, 2016; Provotorov et al, 2016). In response to the demands of modern cosmetic and aesthetic medicine, the pharmacological environment forms new approaches to the treatment of morphofunctional skin defects. In case of thermal damage to the skin, one of the most promising strategies is the creation of an artificial barrier between the environment and the damaged area. On this basis, the gel with ectoine is a promising drug for the treatment of burns, since ectoine creates complexes of water molecules on the mucosal surface, forming a "hydration shield" that protects cells of adverse

environmental conditions (Minaeva & Shiryayeva, 2015).

Materials and Methods

In male rats ($n=30$) under anesthesia (chloralhydrate 300 mg/kg) after preliminary depilation of the dorsal surface (70×30 mm) by 15 seconds contact with water in a test tube heated to $99 \pm 1^\circ$ (Mironov, 2012). Since the size and severity of the burn can vary significantly depending on the individual reactivity of the organism, as well as from bioethics considerations, it was decided to ignore the possible resorptive effect of the studied gels and not to add a control group to the design of the experiment, the surface of which will not be treated with drugs. Thus, 2 thermal damages of a round shape and a diameter of about 10 mm were applied counter-laterally on the posterior surface at the level of the ribs (Fig. 1).

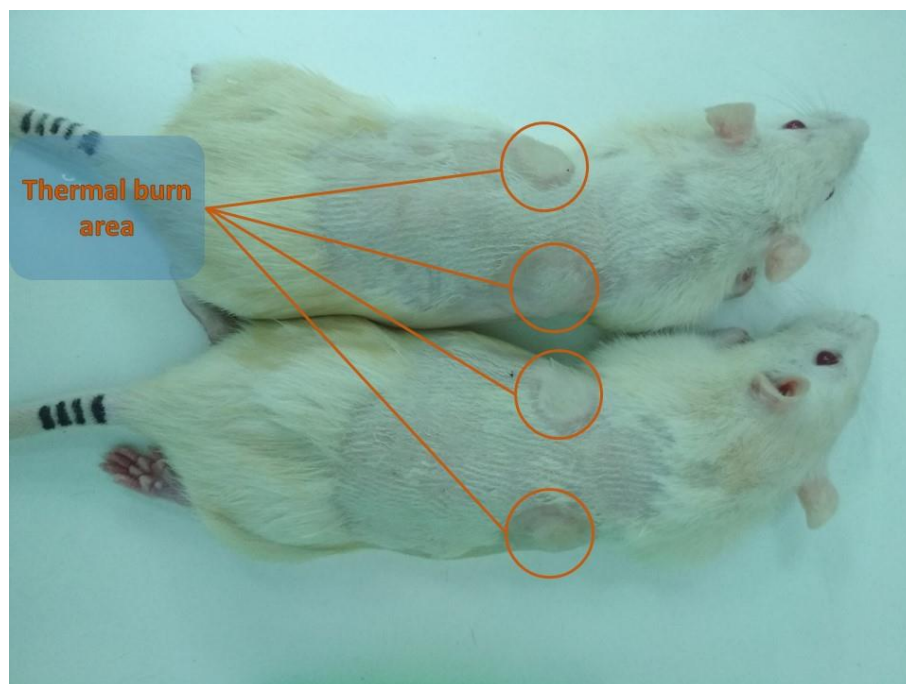


Figure 1. Animals immediately after the application of thermal burns.

Then the animals were divided into 3 equal groups:

I - Ectoine - rubbing 500 mg of ectoine gel onto the burn area located to the right of the spine 10 minutes after the thermal injury was simulated and for the next 6 days (1 time per day)

II - Actovegin - rubbing 500 mg of Actovegin gel onto the burn area to the right of the spine 10 minutes after the thermal injury was simulated and for the next 6 days (1 time per day)

III - Contractubex - rubbing 500 mg of contractubex gel on the burn area to the right of the spine 10 minutes after the thermal injury was simulated and for the next 6 days (1 time per day).

After natural drying of the application area, the animals are placed in individual cages. In the next 6 days, in addition to applying prepartum, photographs of the burn area are made, animals are weighed, as well as an assessment of the clinical condition, physical activity and feed and food consumption. On day 8, animals are

removed from the experiment by the method of cranial dislocation under anesthesia.

Evaluation of the reparative activity of the studied drugs was performed by histological examination of thermally damaged tissues. Cutaneous fragments of the thermal burn areas were cut out and fixed in 10% buffered formalin. The preparation of histological preparations was carried out according to standard methods. Sections were stained using hematoxylin and eosin.

Then, the received preparations were assigned code names for an independent evaluation by an expert commission consisting of 5 doctors from the pathoanatomical bureau of the regional clinical hospital in Belgorod (Russia). The assessment was made on a specially developed scale (Tab. 1):

Table 1. Scale for assessing the reparative activity of the studied drugs with the help of a histological picture of the tissue of thermal damage.

Qualitative attribute	Scores and their characteristics			
Violation of cytoarchitecture	0- None	1 - Weakly expressed	2 - Expressed	3 - Pronounced
Intercellular Matrix Architectonics Disruption	0- None	1 - Weakly expressed	2 - Expressed	3 - Pronounced
Violation of epithelialization	0- None	1 - Weakly expressed	2 - Expressed	3 - Pronounced
Presence of scab	0- None	1 - Weakly expressed	2 - Expressed	3 - Pronounced
Leukocyte infiltration	0- None	1 - Weakly expressed	2 - Expressed	3 - Pronounced

Statistical processing of the obtained results was carried out in R medium using a Tukey post-hoc analysis.

Results

After awakening and on further days of the study, the animals were active, the consumption of feed and food was within the normal range. Signs of infection, excoriation and other adverse events from the skin was not observed. Within 7 days of regular differences in the cumulative clinical evaluation of the studied groups was not observed. The morphological study of the obtained samples in various histological preparations revealed:

- **Ectoine.** A microscopic study of drugs, in the group of observations of ectoine, revealed almost complete recovery of the skin. The fibrous skeleton of the dermis is formed completely. On the surface of the cut of the skin in the area of the burn wound, a scab is visualized, under which is a thin word of the newly formed epidermis (Fig. 2).

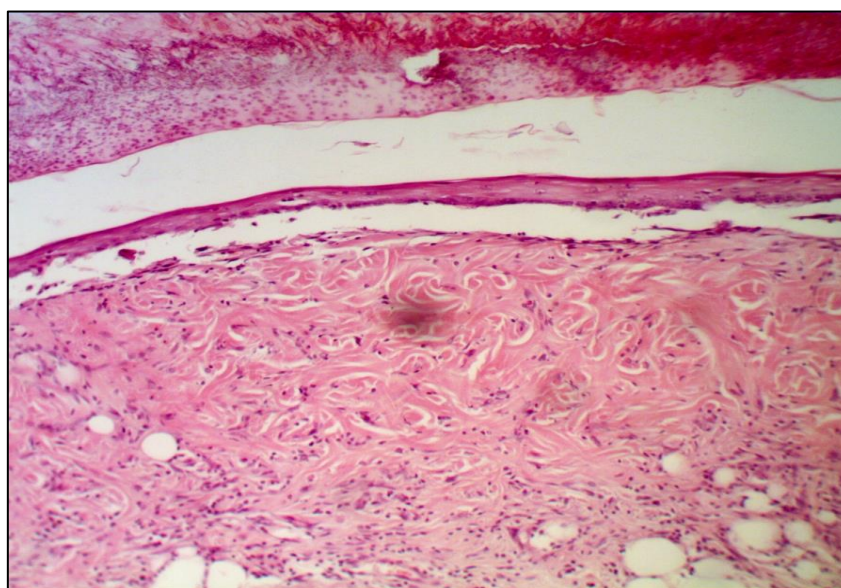


Figure 2. Micrograph of the cut of the skin in the area of the burn in the group of observations with the use of ectoine. Under the scab, the thin newly formed epidermis is well visualized. Stained with hematoxylin/eosin. x200.

The layered structure of the epidermis is preserved (Fig. 3A), three layers are well pronounced. In the basal layer of the cell high prismatic shape. Among the basal epithelial cells, a large number of lymphocytes is detected (Fig. 3B). The stratum corneum is not pronounced, there are no horny scales, which indicates a lack of maturity of the epidermis and full restoration of its functions, including the process of keratinization.

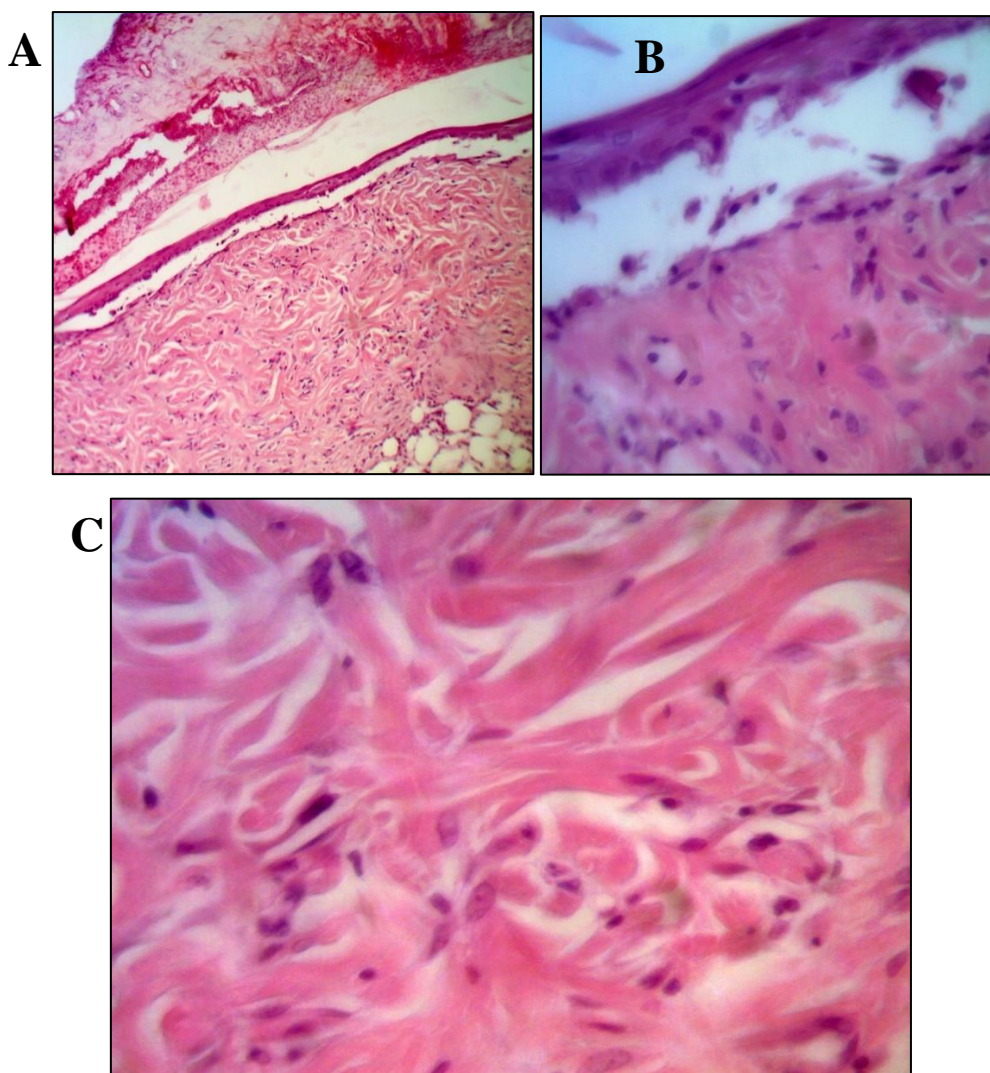


Figure 3. Micrograph of the burn defect zone of the skin in the group using ectoine. The newly formed epidermis is a thin layer located under the scab on the surface of the burn wound. The stratum corneum is not expressed (A, B). x200 (A), x400 (B, C).

In the underlying layers of the dermis in the papillary layer, a fibrous skeleton consists of mature collagen fibers, which have all the morphological and functional criteria necessary for the formation of dense, unformed connective tissue of the dermis.

Regarding the cellular component of the regenerated tissue of the dermis, it should be

noted that in the field of view, cells of the fibroblastic differentiation are predominantly determined, as well as single lymphocytes and mast cells. The fibrous component prevails over the cellular component. Cell density is low (Fig. 3B).

- Ectoine-control. During the histological study of drugs in the group of observations, the ectoine control revealed that there is a scab on the surface of the skin in the area of the burn, which is 3-4 times higher than the experimental group. Epithelization under the scab no. Numerous foci of necrosis are observed over a large area (Fig. 4A, 4B). In the deep dermis, edema, leukocyte infiltration. There are areas of necrosis and soaking with fibrin (Fig. 4B).

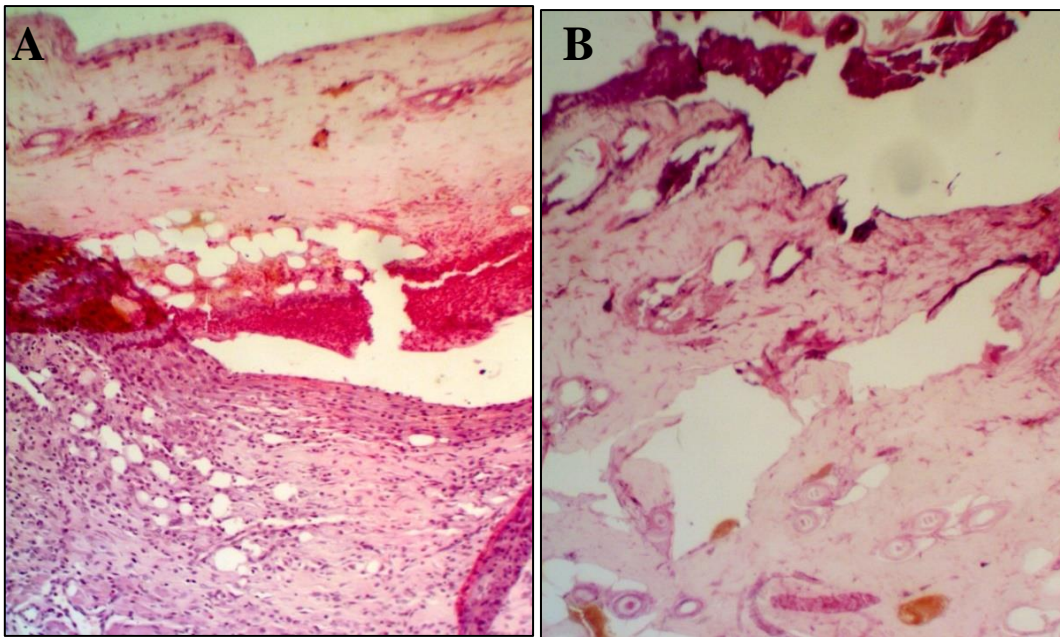
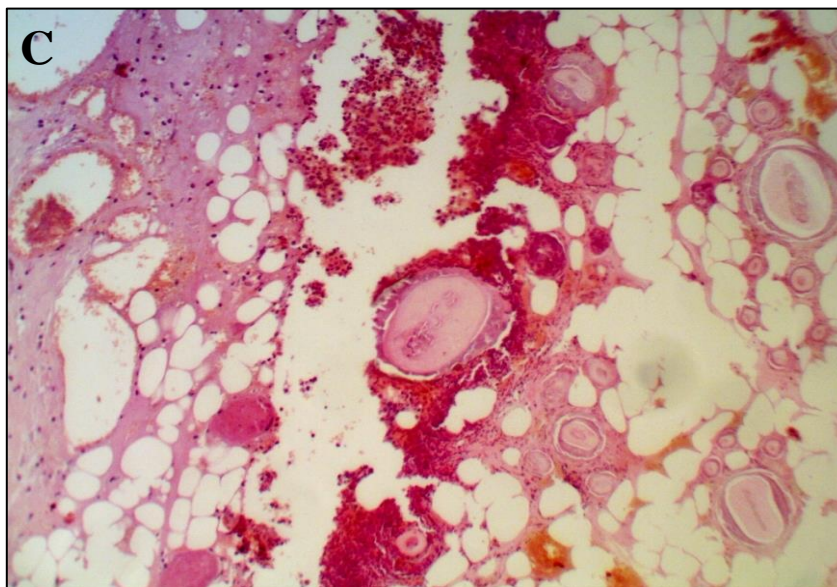


Figure 4. Micrograph of the burn defect zone of the skin in the group using ectoine - control. Epithelization under the scab no. Stained with hematoxylin/eosin. x200.



- **Contractubex.** In preparations in the area of burns on the surface, complete epithelialization of the epidermis is determined (Fig. 5A). The epithelium is thick, layered structure saved. In some epithelial cells in their nuclei, the phenomena of karyopcnosis are expressed. In

the zone of epithelialization or connective tissue scar, the hair follicles are not visualized.

In the underlying dermis there is a large number of newly formed blood vessels, with signs of hemorrhage into the surrounding tissue. Collagen fibers are disintegrated (Fig. 5B).

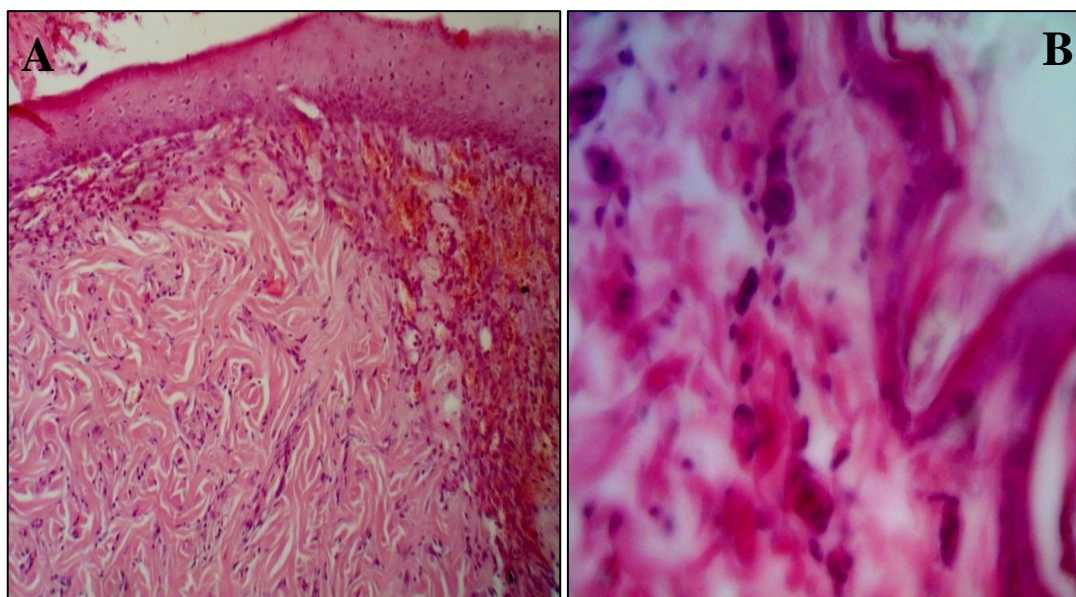


Figure 5. Micrograph of the burn defect area of the skin in the group using contractubex. There is a complete regeneration of the burn defect. In the epidermis, there is a complete restoration of the structural and functional organization. Stained with hematoxylin and eosin. H. x 200 (A), x400 (B).

- **Contractubex-control.** In the areas of the burn defect layer-by-layer structure of the skin is restored. The eschar in the area of damage is not. There is a complete restoration of the epidermis over the area of the burn wound. The stratified squamous non-keratinized epithelium has a layer-by-layer structure, the layers are

clearly differentiated. The newly formed fibers are thin, randomly located. The cellular component is predominant on the fibrous. Lymphocytes and fibroblasts predominate among cells (Fig. 6).

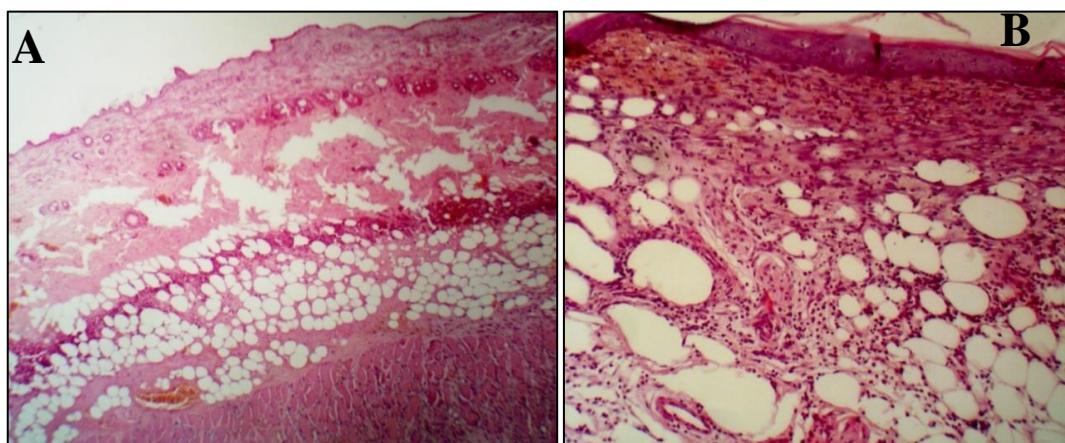


Figure 6. Micrograph of the burn defect area of the skin in the group using contractubex-control. There is a complete restoration of the spatial organization of the skin in the area of the burn defect. Stained with hematoxylin and eosin. x200.

- **Actovegin.** A thin newly formed layer of the epidermis (Fig. 7A) is visualized at the site of the burn, without a clear division into layers (Fig. 7B). Derivatives of the skin are preserved, which may indicate a shallow depth of the burn. In the

underlying dermis, edema is pronounced, the collagen fibers are randomly arranged and in different directions (Fig. 7B).

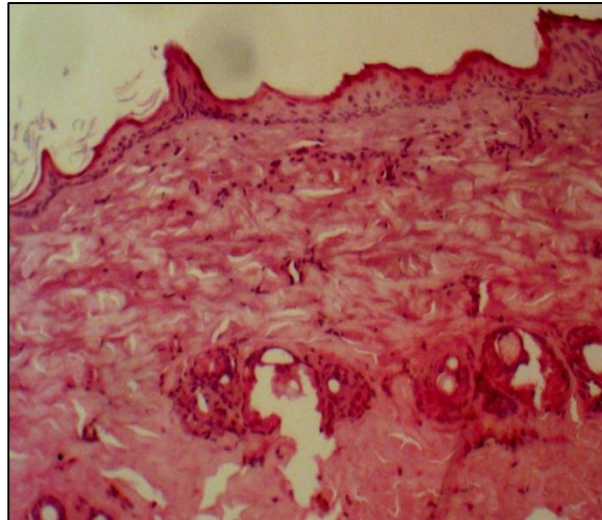


Figure 7. Photomicrograph of the burn defect area of the skin in the actovegin group. Complete regeneration of the burn defect of the wound. Stained with hematoxylin and eosin. x 200.

- **Actovegin-control.** The study of microscopic preparations in the control group revealed the presence of complete regeneration of the skin in the place of the burn wound. The stratified squamous non-keratinized epithelium has a well-

pronounced layer-by-layer structure. The stratum corneum is quite well expressed and formed by horny scales (Fig. 8).

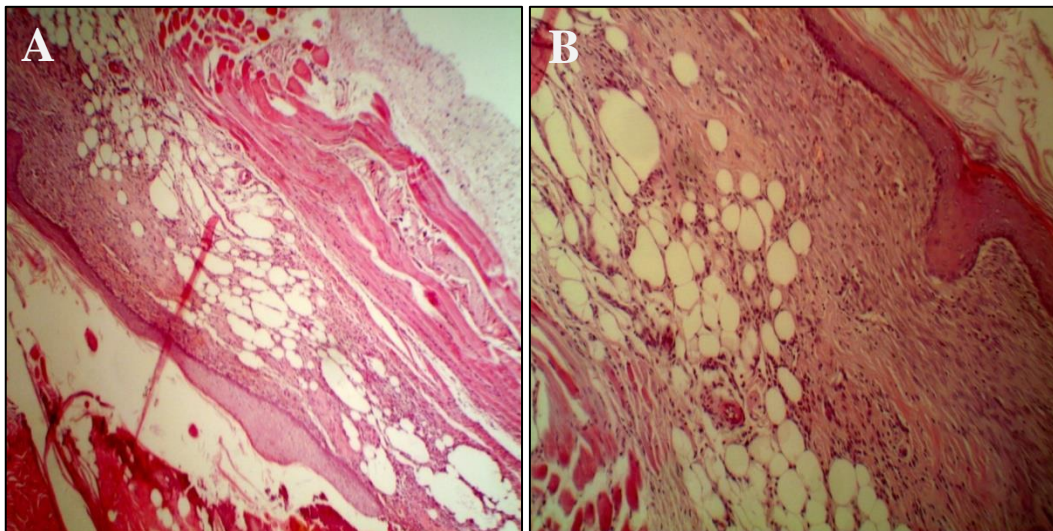


Figure 8. Photomicrograph of the burn defect area of the skin in the actovegin-control group. x200

- **Comparative quantitative assessment.** When questioning the expert commission in each group, the average score was determined (Tab. 2). It was found that the best histological picture of thermally damaged tissues was demonstrated by animals receiving ectoine. A less significant,

but pronounced reparative effect was observed in histological samples of the actovegin group. The least significant reparative effect was demonstrated by contractubex (Tab. 2, Fig. 9).

Table 2. The results of the microscopic specimens of the skin scoring by an expert commission (M±m).

Qualitative attribute	Score					
	Ectoine	E-C	Actovegin	A-C	Contractubex	C-C
Violation of cytoarchitecture	0.91±0.11	1.72±0.19	1.16±0.15	1.64±0.16	1.45±0.19	1.82±0.12
Intercellular Matrix Architectonics Disruption	1.19±0,08	2.11±0.09	1.51±0.11	2.05±0.09	1.62±0.12	2.21±0.10
Violation of epithelialization	1.41±0.10	2.92±0.12	2.29±0.12	2.95±0.14	2.38±0.14	2.87±0.13
Presence of scab	1.77±0.11	2.31±0.11	1.65±0.14	2.26±0.17	2.01±0.15	2.39±0.16
Leukocyte infiltration	1.75±0.09	2.15±0.17	1.78±0.10	2.21±0.10	1.87±0.14	2.0±0.12
Average score	1.41±0.10* ^	2.24±0.14	1.68±0.12* #	2.22±0.14	1.87±0.16*# ^	2.26±0.13

Note: a lower score indicates a more consistent histological pattern; E-C, A-C, C-C - control for ectoine, actovegin and contractubex, respectively; * - $p < 0.05$ when compared with the control; # - $p < 0.05$ when compared with the group receiving ectoine; ^ - $p < 0.05$ when compared with the actovegin group.

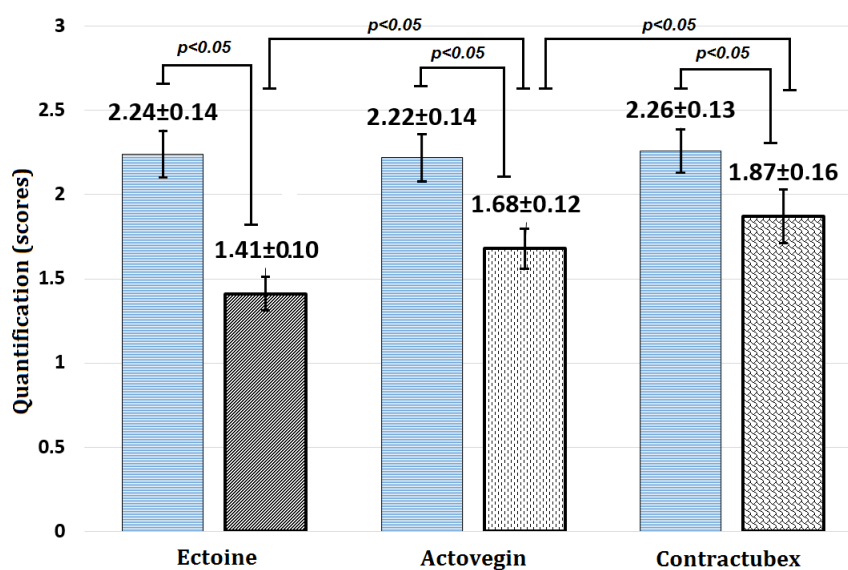


Figure 9. The results of the scoring of skin microscopic preparations by the expert committee.

Note: blue bars (left) - control; gray bars (right) - the studied gel.

Conclusion

The study showed that the best results were obtained with the external use of ectoine gel. According to the results of histological examination, thermal damage in this group was less pronounced than in the control group. A smaller, but significant reparative effect showed actovegin gel. Finally, contractubex gel showed the lowest efficacy.

Thus, ectoine gel shows positive reparative properties and can be recommended for further study, both on models of other burns, and in modeling skin defects of a different etiology.

Reference

Danilenko, L. M. (2018). Doxorubicin-associated Cardiomyopathy: New Approaches to Pharmacological Correction Using 3-(2, 2, 2-trimethylhydrazinium) Propionate Derivatives. *Research Results in Pharmacology*, 4(1), 81-86.

Galenko-Yaroshevsky, P. A., Kulikov, A. L., Vinakov, D. V., Avtina, T. V., Suzdalev, K. F., & Pokrovskii, M. V. (2016). Pharmacokinetic studies derived indole SS-68 with antiarrhythmic and antianginal properties. *Research result: pharmacology and clinical pharmacology*, 2(2), 20-24.

Minaeva, N. V., & Shiryayeva, D. M. (2015). Comparative Evaluation of the Efficacy in Treating Children with Seasonal Allergic Rhinitis Using Antihistamine Combined with Ectoine Nasal Spray and Antihistamine Monotherapy; Results of an Open Randomized Study. *Voprosy Sovremennoj Peditrii*, 14(4), 483-488.

Mironov, A. N., & Bunatyan, N. D. (2012). Guidelines for conducting pre-clinical trials of medicinal products. Part one. Moscow: Grif and K, 237-238. ISBN 978-5-9901447-1-2.

Peresyapkina, A. A., Gubareva, V. O., Levkova, E. A., & Shabelnikova, A. S. (2016). Correction of retinal angiopathy of hypertensive type by minoxidil, sildenafil in experiment. *Research result: pharmacology and clinical pharmacology*, 2(4).

Provotorov, V. Y., Korokin, M. V., Pokrovskii, M. V., Povetkin, S. V., Lazareva, G. A., Stepchenko, A. A., & Bystrova, N. A. (2016). Endothelio- and cardioprotective effects of vitamin B6 and folic acid in modelling methionine-induced hyperhomocysteinemia. *Research result: pharmacology and clinical pharmacology*, 2(1), 16-19.

Rajkumar, D. S. R., Gudyrev, O. S., Faitelson, A. V., Stepchenko, A. A., Dolzhikov, A. A., & Povetkin, S. V. (2016). Study of the influence of L-norvaline, rosuvastatin and their combination on the level of microcirculation in bone tissue in experimental osteoporosis and fractures on its background. *Research result: pharmacology and clinical pharmacology*, 2(1).

Shakhno, E. A., Savitskaya, T. A., Pokrovskaya, T. G., Yakushev, V. I., Pokrovskii, M. V., & Grinshpan, D. D. (2016). Use of L-arginine immobilised on activated carbon for pharmacological correction of endothelial dysfunction. *Research Results in Pharmacology*, 2(1), 30-35.

Soldatov, V. O., Shmykova, E. A., Pershina, M. A., Ksenofontov, A. O., & Zamitsky, Y. M. (2018). Imidazoline receptors agonists: possible mechanisms of endothelioprotection.

Voronkov, A. V., & Pozdnyakov, D. I. (2018). Endothelotropic activity of 4-hydroxy-3, 5-di-tret-butylcinnamic acid in the conditions of experimental cerebral ischemia. *Research Result: Pharmacology and Clinical Pharmacology* 4 (2): 1-10. RESEARCH RESULT, 1.