

Case Report

DOI: 10.22114/ajem.v0i0.254

A 21-year-old Pregnant Trauma Patient with Asymptomatic Fat Embolism; a Case Report

Niloofar Ayoobi-Yazdi, Faeze Salahshour*, Mehran Arab-Ahmadi, Samira Hemati, Mohammad Amiri

Advanced Diagnostic and Interventional Radiology Research Center, Tehran University of Medical Science, Tehran, Iran.

*Corresponding author: Faeze Salahshour; Email: F-salahshour@sina.tums.ac.ir

Published online: 2019-09-18

Abstract

Introduction: Fat embolism syndrome (FES) is most often associated with orthopedic trauma that typically presents 24–72 hours after the trauma with a classic triad. Only few cases of fat embolism due to lower extremity venous system had been reported.

Case presentation: The current case report presents a pregnant woman who was referred to our emergency department with bilateral femoral open fracture. After detecting fetal demise by abdominopelvic ultrasound, an area of fat density in right external iliac vein was detected in abdominopelvic contrast enhanced computed tomography (CT) scan which was considered as the probable diagnosis of fat embolism. While the patient did not show signs and symptoms of FES, the fat embolism was confirmed in further evaluations.

Conclusion: In summary, although detection of fat embolus in CT scan in the emergency department is very rare, evaluation of lower extremity venous system in a posttraumatic patient seems to be crucial because early diagnosis of fat embolism can help the clinicians to prevent FES.

Key words: Case Reports; Embolism, Fat; Multiple Trauma; Pregnant Women

Cite this article as: Ayoobi-Yazdi N, Salahshour F, Arab-Ahmadi M, Hemati S, Amiri M. A 21-year-old Pregnant Trauma Patient with Asymptomatic Fat Embolism; a Case Report. *Adv J Emerg Med.* 2020;4(2):e32.

INTRODUCTION

Fat embolization occurs frequently following orthopedic trauma (1). Fat embolism syndrome (FES) typically presents 24–72 hours after the trauma with a classic triad of (i) respiratory changes (often the first clinical feature), (ii) neurological symptoms and (iii) petechial rash (2). The treatment of FES is primarily supportive; hence, our focus must be on prevention. Although early fracture stabilization decreases the rate of FES, questions about management of patients with bilateral femoral fractures have remained (3). The current case report presents a pregnant

woman with bilateral femoral fracture in whom the fat embolism was primarily diagnosed with a contrast enhanced CT in emergency department (ED).

CASE PRESENTATION

A 21-year-old 31-week pregnant woman presented to our ED following motor vehicle collision. She didn't have any previous medical or surgical history. On arrival her vital signs were stable except for mild tachycardia and severe pain. She had developed bilateral femoral open fracture

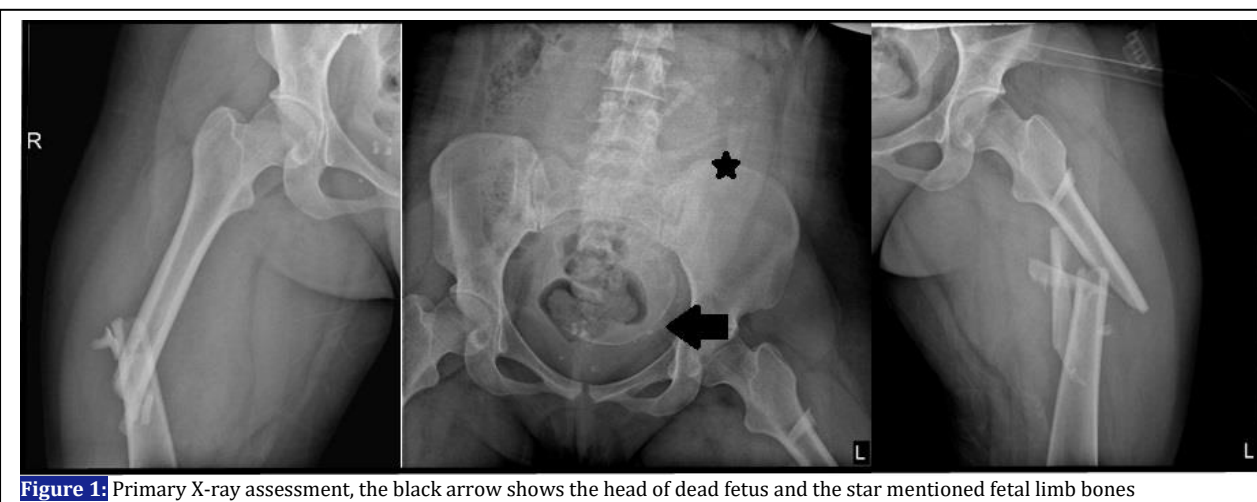


Figure 1: Primary X-ray assessment, the black arrow shows the head of dead fetus and the star mentioned fetal limb bones

(Figure 1). In initial ultrasound abdominopelvic investigation, we detected fetal demise despite normal abdominal survey. Therefore, trauma team was allowed to have further assessments with X-ray and computed tomography (CT) scan. Caesarian delivery and intramedullary nailing were conducted on 2nd day of admission. Thereafter, Thoracoabdominopelvic contrast enhanced CT scan was performed that revealed an area of fat density in right external iliac vein. (Figure 2).

In her spiral chest CT scan in the same survey, we detected some ground glass opacities in the apex of right lung adjacent to first and second ribs' fracture. It was considered as either contusion or fat emboli (Figure 3).

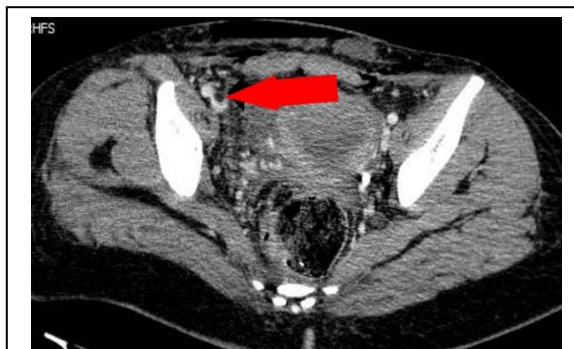

Figure 2: Fat emboli in right iliac vein (red arrow)

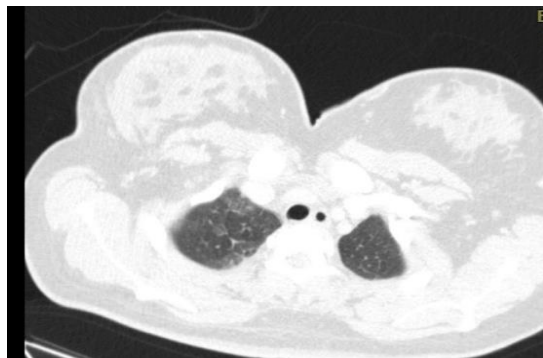


Figure 3: Ground glass opacities in the apex of right lung

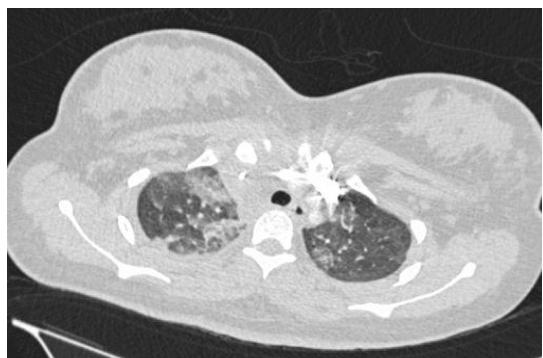


Figure 4: Patchy air space opacities and atelectatic areas in right upper lobe of lung in favor of fat emboli

She underwent spiral chest CT angiography due to her dyspnea and low O₂ saturations to rule out pulmonary thromboemboli. We found the mentioned areas have been progressed to patchy air space opacities and atelectatic areas in right upper lobe of lung in favor of fat emboli, which was an imaging diagnostic clue for fat emboli rather than lung contusions (Figure 4).

Our patient did not develop either neurological nor dermatological sign or symptoms. She was administered daily prophylaxis heparin dosage therefore; she did not have any sign or symptom of deep vein thrombosis during her complete bed rest with bilateral traction. Her remaining hospital course was uneventful without evidence of development of FES.

DISCUSSION

Fat embolism is the presence of fat particles within the microcirculation, which can produce embolic phenomena followed or not by clinical sequel. FES is the systemic manifestation of fat emboli within the microcirculation. Fat embolism occurs in over 90% of cases of trauma (1). In retrospective review, incidence of FES was less than 1% (4). The dramatic increase in morbidity and mortality of patients with FES underscores the importance of careful clinical examination with a high index of suspicion for diagnosis of FES in patients with long bone fractures especially in multiple bone fractures or movement of fracture segments (5).

The exact mechanism producing fat emboli is not well understood. Fat emboli may occur either by direct entry of disrupted bone marrow into the bloodstream (the mechanical theory) or via interaction of cytokines and free fatty acids in the plasma (the biochemical theory) (6). If the fat embolus is early diagnosed in the emergency department, the patient may be observed carefully for the presentations of FES. However, the fat embolism usually does not appear as a large fat complex within vessels at the CT scan. Hence, early diagnosis of fat embolism in ED is very difficult.

There are cases of fat embolism in lower extremity venous system had been reported (7, 8). Similar to our case, none of the two reported cases had any event of FES. While we detected fat embolism in right external iliac vein, previous cases had fat embolism in distal superficial femoral vein (8) and right common iliac vein (7). In most cases of FES, it resolves spontaneously. Hence, the need for placing an inferior vena cava (IVC) filter in the traumatic patient with a fat embolism in lower

extremity venous system is controversial. While Lee et.al placed an IVC filter (7), we and Chowdhary et.al (8) did not.

CONCLUSIONS

In summary, although detection of fat embolus in CT scan in the emergency department is very rare, evaluation of lower extremity venous system in a posttraumatic patient seems to be crucial because early diagnosis of fat embolism can help the clinicians to prevent FES.

ACKNOWLEDGEMENTS

None.

REFERENCES

1. Eriksson EA, Pellegrini DC, Vanderkolk WE, Minshall CT, Fakhry SM, Cohle SD. Incidence of pulmonary fat embolism at autopsy: an undiagnosed epidemic. *J Trauma*. 2011;71(2):312-5.
2. Taviloglu K, Yanar H. Fat embolism syndrome. *Surg Today*. 2007;37(1):5-8.
3. Rothberg DL, Makarewich CA. Fat Embolism and Fat Embolism Syndrome. *J Am Acad Orthop Surg*. 2019;27(8):e346-55.
4. Bulger EM, Smith DG, Maier RV, Jurkovich GJ. Fat embolism syndrome: a 10-year review. *Arch Surg*. 1997;132(4):435-9.
5. Georgopoulos D, Bouros D. Fat embolism syndrome: clinical examination is still the preferable diagnostic method. *Chest*. 2003;123(4):982-3.
6. Gupta A, Reilly CS. Fat embolism. *BJA Educ*. 2007;7(5):148-51.
7. Lee H, Moon J, Kwon J, Lee JC-J. Rare Imaging of Fat Embolism Seen on Computed Tomography in the Common Iliac Vein after Polytrauma. *J Trauma Inj*. 2018;31(2):103-6.
8. Chowdhary V, Mehta V, Bajaj T, Scheiner J. Rare imaging of a known entity: fat embolism seen on CT in lower extremity vein after trauma. *Radiol Case Rep*. 2017;12(3):488-90.

AUTHORS' CONTRIBUTION

All the authors fulfil the criteria of authorship based on the recommendations of the International Committee of Medical Journal Editors (ICMJE).

CONFLICT OF INTEREST

None declared

FUNDING

None declared