

Case Report

DOI: 10.22114/ajem.v0i0.195

Distal Catheter Migration into Scrotum as a Rare Complication of Ventriculoperitoneal Shunt in Pediatrics; A Case Series

Ali Abdoli¹, Manouchehr Ghorbanpour², Afshin Fayyazi³, Mohammad Reza Saatian^{1*}

1. Department of Neurosurgery, School of Medicine, Hamadan University of Medical Sciences, Hamadan, Iran.

2. Department of Pediatric Surgery, School of Medicine, Hamadan University of Medical Sciences, Hamadan, Iran.

3. Department of Pediatric Neurology, Hamadan University of Medical Sciences, Hamadan, Iran.

*Corresponding author: Mohammad Reza Saatian; Email: mrsaatian@yahoo.com

Published online: 2019-12-08

Abstract

Introduction: Ventriculoperitoneal (VP) shunt placement is the common treatment approach in children with hydrocephalus. Complications of VP shunt are not uncommon but some are unusual and rare. Except infection and obstruction, other complications of VP shunts are uncommon and distal catheter migration into scrotum is one of the rarest ones.

Case presentation: Here we present a rare complication of VP shunt, distal catheter migration into scrotum, in 4 patients that presented with scrotal swelling or bulging in the inguinal region, who underwent surgery for replacment of the distal cathether in peritoneum and processus vaginalis repair.

Conclusion: In patients with a history of VP shunt placement who candidate for surgery due to inguinal hernia or hydrocele, possible migration of distal catheter should keep in mind by the surgeon. This complication can occur as early as at the time of shunt placement or delayed.

Key words: Children; Hydrocephalus; Surgical Procedures, Operative; Scrotum; Ventriculoperitoneal Shunt

Cite this article as: Abdoli A, Ghorbanpour M, Fayyazi A, Saatian MR. Distal Catheter Migration into Scrotum as a Rare Complication of Ventriculoperitoneal Shunt in Pediatrics; A Case Series. Adv J Emerg Med. 2020;*(*)e*.

INTRODUCTION

Ventriculoperitoneal (VP) shunt is still the most widely conducted managment for hydrocephalus in pediatrics. This surgical procedure has become the most common surgery in pediatric Neurosurgery (1-3). Complications of VP shunt are not uncommon but some are unusual and rare. Here we describe a rare complication of VP shunt, distal catheter migration into the scrotum, in 4 patients presented during the period between 2012 and 2019 to the Besat Hospital, Hamadan, Iran.

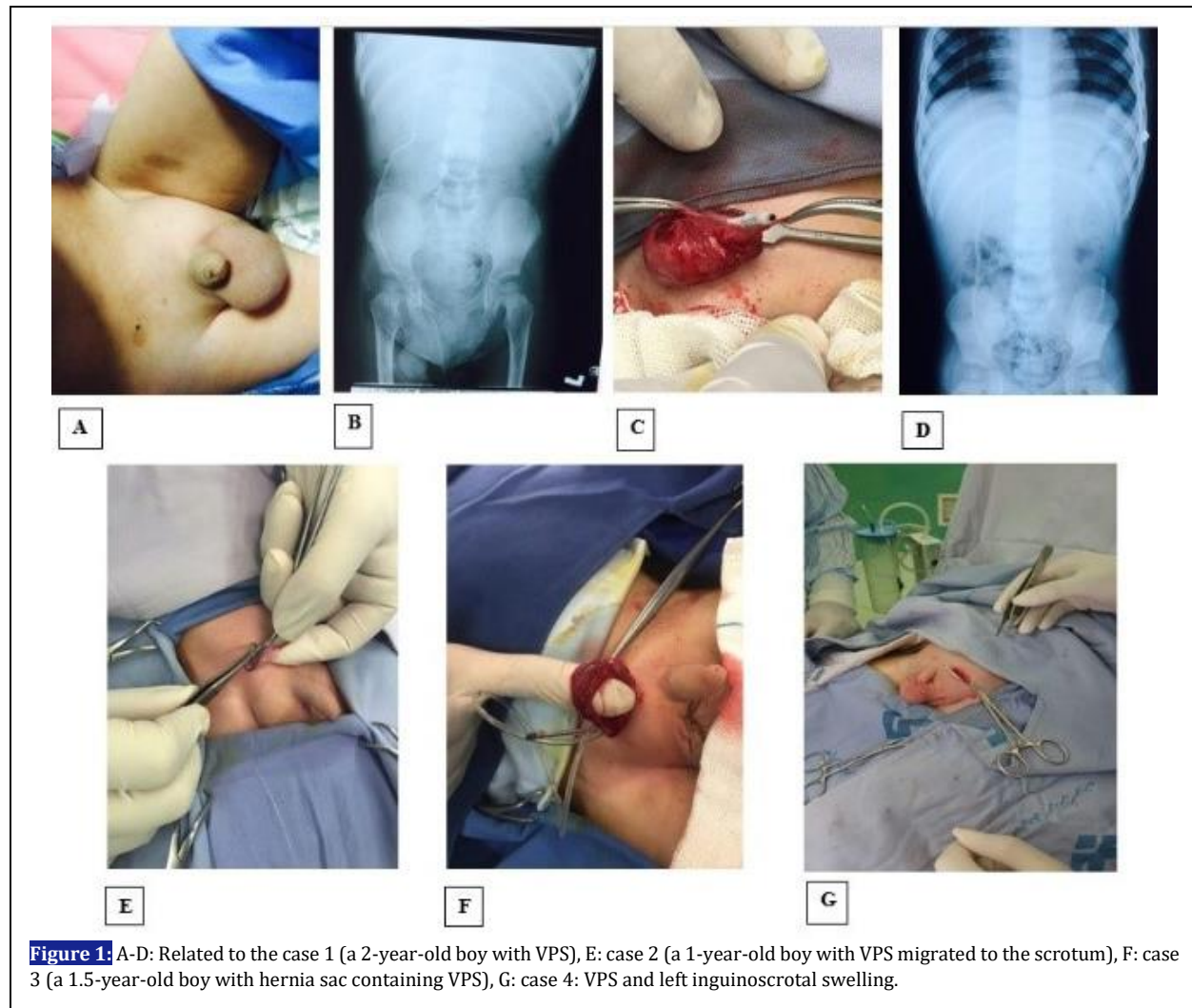
CASE PRESENTATION

Case 1: A 2-year-old boy with hydrocephalus who recently underwent VP shunt, presented with a history of right scrotal swelling since ten days after operation. Ultrasonography was performed that revealed hydrocele along with the presence of distal catheter in the scrotum. An abdominopelvic X-ray was aslo done which confirmed the migration of the distal catheter of VP shunt into the right scrotum. The patient was operated for replacement of catheter into peritoneum and processus vaginalis closure was done. Post-operative abdominal X-ray has showed the distal catheter in peritoneum. The patient discharged without any problems two days after surgery (Figure 1A-D).

Case 2: A 1-year-old boy went to operating room due to inguinal herniation. He had a history of VP shunt due to hydrocephaly 10 months before but without any problem. During operation the surgeon palpated an unusual thing in processus vaginalis and finally saw distal catheter of shunt and replaced it into peritoneum. The patient was discharged with good condition two days after surgery (Figure 1E).

Case 3: A 1.5-year-old boy presented with swelling in the right inguinal region. He was No fever, pain and features of intestinal obstruction were existed. He had undergone VP shunt procedure for congenital hydrocephalus at the age of 5 months. He underwent elective herniorrhaphy and the hernia sac containing distal catheter repaired. The baby discharged three days later in good condition (Figure 1F).

Case 4: A 1-year-old male child who underwent VP shunt placement at the age of 8 months presented with left inguinoscrotal swelling. The Surgical exploration conducted with the first diagnosis of inguinal hernia and hydrocele that revealed a patent processus vaginalis through which the VP shunt had migrated into the left scrotum. Due to the proper function of shunt, it was sent back to the



abdominal space and repositioned and the hernia sac was repaired (Figure 1G).

DISCUSSION

Despite significant improvements, complications of VP shunts remain common (4, 5). These complications include infection, blockage, malfunction or rarely migration of the shunt. Migration may occur into the lateral ventricle, mediastinum, chest, gastrointestinal tract, abdominal wall, bladder, vagina and a rare place happened for our patients was scrotum (6-10). The processus vaginalis is an embryonic developmental outpouching of the peritoneum. It is present from almost 12th week of gestational age. Closure of processus vaginalis may occurs at any point from a few weeks before birth, to a few weeks thereafter. Failure of neonatal closure of the processus vaginalis is a mechanism for inguinal hernia and hydrocele development and may allow the distal

catheter migrate from the abdominal cavity into the scrotum in patients with VP shunt (1, 9, 11). Migration of the distal catheter into the scrotum is a rare complication and has been reported in some cases in the literature. The most patients were younger than three years and right side was predominant. The most common treatment of this complication was repositioning of catheter and processus vaginalis closure that we believe is the best option. Other treatment included laparoscopic distal catheter trimming and shortening of distal catheter via open abdominal incision (1, 2, 12).

CONCLUSIONS

In patients with a history of VP shunt placement who candidate for surgery due to inguinal hernia or hydrocele, possible migration of distal catheter should keep in mind by the surgeon. This complication can occur as early as at the time of shunt placement or delayed.

ACKNOWLEDGEMENTS

None.

CONFLICT OF INTEREST

None declared

AUTHORS' CONTRIBUTION

All the authors fulfil the criteria of authorship based on the recommendations of the International Committee of Medical Journal Editors (ICMJE).

FUNDING

None declared

REFERENCES

1. Lee BS, Vadera S, Gonzalez-Martinez JA. Rare complication of ventriculoperitoneal shunt. Early onset of distal catheter migration into scrotum in an adult male: Case report and literature review. *Int J Surg Case Rep.* 2014;6C:198-202.
2. Shahizon AMM, Hanafiah M, Hing EY, Julian MR. Migration of a fractured ventriculoperitoneal shunt into the scrotum: a rare complication. *BMJ Case Rep.* 2013;2013:bcr2013200609.
3. Walsh AR, Kombogiorgas D. Coiled ventricular-peritoneal shunt within the scrotum. *Pediatr Neurosurg.* 2004;40(5):257-8.
4. Rahman N, Lakhoo K. Patent processus vaginalis: a window to the abdomen. *Afr J Paediatr Surg.* 2009;6(2):116-7.
5. Silver RI, Docimo SG. A ventriculoperitoneal shunt masquerading as a paratesticular tumor. *J Pediatr Surg.* 2000;35(9):1407-8.
6. Agarwal T, Pandey S, Niranjana A, Jain V, Mishra S, Agarwal V. Unusual complication of ventriculoperitoneal shunt surgery. *J Pediatr Neurosci.* 2009;4(2):122-3.
7. Karaosmanoglu D, Metin Y, Akata D, Haliloglu M. An unusual cause of hydrocele: malpositioned ventriculoperitoneal shunt in the scrotum. *J Ultrasound Med.* 2008;27(1):159-60.
8. Kita D, Hayashi Y, Kinoshita M, Ohama K, Hamada J. Scrotal migration of the peritoneal catheter of a ventriculoperitoneal shunt in a 5-year-old male. *Neurol Med Chir (Tokyo).* 2010;50(12):1122-5.
9. Mohammadi A, Hedayatiasl A, Ghasemi-Rad M. Scrotal migration of a ventriculoperitoneal shunt: a case report and review of literature. *Med Ultrason.* 2012;14(2):158-60.
10. Rivero-Garvia M, Barbeito Gaido JL, Morcillo J, Marquez Rivas J. Shunt dysfunction secondary to peritoneal catheter migration to the scrotum. *Arch Argent Pediatr.* 2013;111(1):e14-6.
11. Ho CC, Jamaludin WJ, Goh EH, Singam P, Zainuddin ZM. Scrotal mass: a rare complication of ventriculoperitoneal shunt. *Acta medica (Hradec Kralove).* 2011;54(2):81-2.
12. Ward JF, Moquin RR, Maurer ST. Expanding the differential diagnosis of the acute scrotum: ventriculoperitoneal shunt herniation. *Urology.* 2001;58(2):281.