

Original Article

DOI: 10.22114/ajem.v0i0.154

A New Formula for Confirmation of Proper Endotracheal Tube Placement with Ultrasonography

Atousa Akhgar^{1,2}, Shamim Bahrami², Payam Mohammadinejad², Zahra Khazaeipour³, Hooman Hossein-Nejad^{2*}

1. Prehospital and Hospital Emergency Research Center, Tehran University of Medical Sciences, Tehran, Iran.

2. Department of Emergency Medicine, Imam Khomeini Hospital Complex, Tehran University of Medical Sciences, Tehran, Iran.

2. Brain and Spinal Cord Injury Research Center, Tehran University of Medical Sciences, Tehran, Iran.

*Corresponding author: Hooman Hossein-Nejad; Email: hoseinnejad@tums.ac.ir

Published online: 2019-05-16

Abstract

Background: Endotracheal intubation is an important procedure in critical care and emergency medicine settings. Optimal depth of the tube placement has been a serious concern because of several complications associated with its malposition.

Objective: The aim of the current study was to find a new formula to estimate the proper endotracheal tube depth when using ultrasonography or lighted stylet device in order to increase the accuracy of determining Endotracheal tube (ETT) depth and decrease the side effects of ETT misplacement.

Method: Patients older than 18 years of age admitted to Imam emergency department who needed tracheal intubation were included. Tube's length at the angle of the mouth while the tube passed the suprasternal notch, ETT depth after insertion and the distance from ETT's tip to carina were recorded. Ultrasonography and portable chest x-ray were used as tools for measuring these lengths.

Results: A total number of 91 patients including 55 men and 36 women were eligible for inclusion in the study. Not placing the tube at proper depth was considered as the failure of intubation. This failure rate was 9.9% in the standard method which would have been 1.1% if our proposed formula was used.

Conclusion: The findings of this study suggest that the use of this new formula may help in predicting the proper intubation tube placement. Further studies are warranted to confirm these findings.

Key words: Critical Care; Emergency Medicine; Intubation, Intratracheal; Ultrasonography

Cite this article as: Akhgar A, Bahrami S, Mohammadinejad P, Khazaeipour Z, Hossein-Nejad H. A New Formula for Confirmation of Proper Endotracheal Tube Placement with Ultrasonography. *Adv J Emerg Med.* 2019;3(3):e25.

INTRODUCTION

Airway management is one of the most important skills for a physician in the emergency department (ED) and critical care settings. One of the most important and routinely used approaches to establish a secure and safe airway is intratracheal intubation. Displacement and misplacement of the endotracheal tube (ETT) could result in serious complications including left lung atelectasis and right lung pneumonia in patients who are one lung intubated; On the other hand, esophageal intubation can be life threatening and lead to death. Extubation and vocal cord injury are also the side effects of misplacement of ETT (1, 2). Hence, American Heart Association commented on performing a complete assessment with ultrasonography if the provider has expertise to ascertain the correct placement of the endotracheal tube after the intubation procedure (3). Direct visualization of the endotracheal tube (ETT) insertion through the vocal cords and into the trachea is the first method to confirm proper

tube placement. Several methods have been suggested to confirm the proper tube placement in trachea like lungs auscultation, visualization of bilateral chest rising and End-tidal carbon dioxide detection with capnography but there are few methods to confirm the proper depth of the placement of the tube. The fiberoptic intubation laryngoscope allows definitive positioning of the tube but it is not always available and also needs some expert provider (4). Another method is using control chest x-ray which should be assessed after initial placement of the tube but this exposes the patient to radiation and usually needs a portable X-ray device which is a costly and time-consuming method. In recent years, the use of ultrasound for confirmation of endotracheal tube placement has gained increasing popularity (5). The aim of the current study was to find a new formula to estimate the proper endotracheal tube depth when using ultrasonography or lighted stylet device in order to increase the accuracy of determining ETT depth

and decrease the side effects of ETT misplacement.

METHODS

Study design and setting

The current observational study was performed on patients who were admitted to ED and required intubation as decided by their treating physicians. The study was performed at the emergency departments of Imam Khomeini Hospital Complex and Sina Hospital both affiliated with Tehran University of Medical Sciences in Tehran, Iran, between March 2015 and March 2016. The ethics committee of TUMS approved the process of the study.

Participants

A convenient sample of patients was enrolled when an emergency medicine resident as a research assistant was present in the ED in day and night shift work. Participants were all patients older than 18 years old who were admitted to Sina and Imam emergency departments and needed tracheal intubation due to clinical assessment.

Ultrasonography modality and intubation

SonoScape S6 Portable Ultrasound Machine (SonoScape, China) was used in all assessments. We used sonography to identify when the tracheal tube passes the suprasternal notch. Hence, we used a high-frequency probe (5-10 Mhz) and put it perpendicular to the suprasternal notch during intubation by the assistant researcher. When the tube passed the notch the reverberation disappeared on the monitor's screen and at this time the tube depth at the angle of the mouth has been recorded. Intubation was performed by the treating physician independent of the

ultrasonography which was performed by another emergency medicine physician. As a standard of care, to confirm the tube's position, supine anterior-posterior (AP) chest X-ray was performed using a portable chest x-ray device.

Measurement

After taking chest x-ray of the intubated patient, the length from the tip of the tube to carina was recorded, we also calculate the proper number of the tube at the angle of the mouth if the tube's end would be in at least 2 cm far from carina in accordance with the desired position which mentioned in previous study (6, 7). In all cases, the following data were recorded: patient's gender, height, tube's length at the angle of the mouth while the tube passed the suprasternal notch, tube depth after ETT insertion, the distance from ETT's tip to the carina and our desired length if we correct them in the proper position. Adequate tube position was defined by a distance of 2 cm or more between ETT's tip and the carina. This definition is consistent with general clinical practice and previous studies of orotracheal intubation (6, 7). The following indexes were used to find a formula for proper depth of intubation (Figure 1):

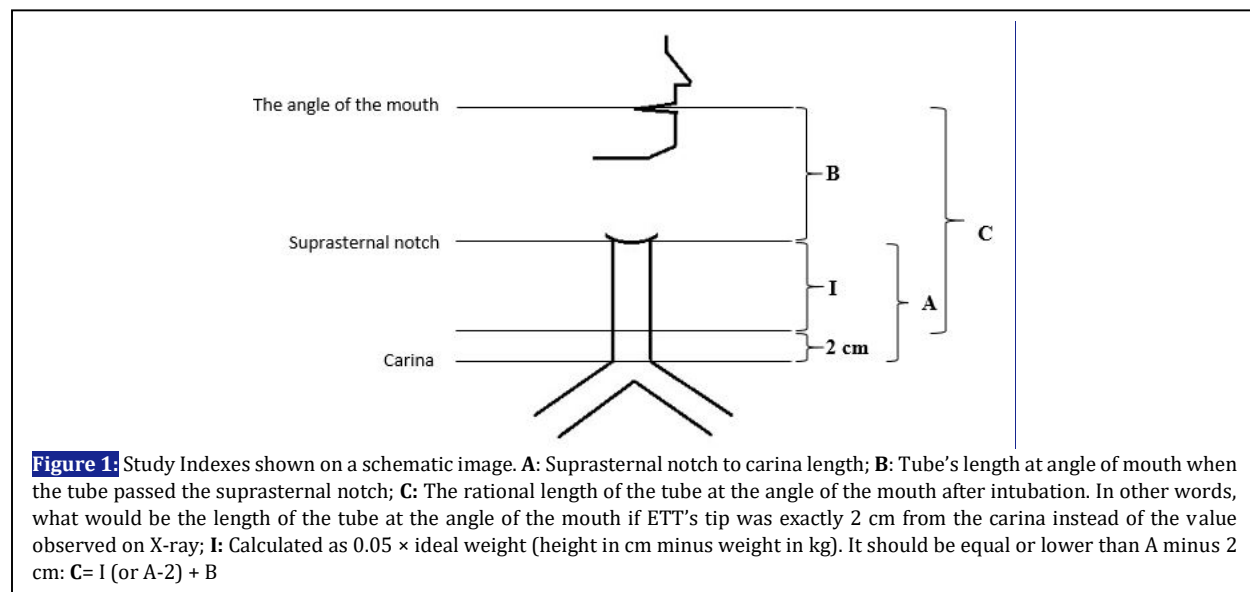
A: Suprasternal notch to carina length

B: Tube's length at the angle of the mouth when the tube passed the suprasternal notch

C: The estimated ideal length of the tube at the angle of the mouth after intubation. It is equal to the estimated ideal length of the tube at the angle of the mouth when ETT's tip is located at exactly 2 cm from the carina.

Statistical analysis

Data were analyzed and charts were designed



using GraphPad Prism version 6.07 software for Windows (GraphPad Software, Inc., California, USA). Continuous data are presented as mean \pm standard deviation. Categorical data are presented as frequency (percentage). Independent t-test was used for evaluating the significance of the difference between normally distributed variables. Pearson's Correlation Coefficient was used to assess the relationship between two continuous variables. P- Values of $\leq 0/05$ were considered as indicators of statistically significant differences.

RESULTS

A total number of 91 patients including 55 (60.44%) males and 36 (39.56%) females were included. The mean height was 167.9 ± 8.8 cm (161.0 ± 6.38 cm in females vs. 172.4 ± 7.37 cm in males, $p < 0.001$).

Since ultrasonography is unable to follow the tube beyond the suprasternal notch, a formula was designed to calculate the distance between suprasternal notch and ETT's tip (called I), assuming that ETT's tip distance from the carina would be a minimum of 2 cm.

I: Calculated as $0.05 \times$ ideal weight according to Broca Index (height in cm minus 100). It should be equal or lower than A minus 2 cm.

$$C = I \text{ (or } A - 2) + B$$

The rate of failure as detected by X-ray and considered as a distance of less than 2 cm between the tube's tip and the carina was observed in 9 out of 91 patients (9.9%) who underwent intubation. Using I index in order to estimate the distance between suprasternal notch and an acceptable place for the tube's tip which was considered as being at least 2 cm far from the cardia, only 1 intubation (1.1%) would fail. In other words, if intubations were performed guided by ultrasonography to measure the distance from the angle of the mouth to the suprasternal notch (B index), and adding this value to I index, could have resulted in a success rate of 98.9% instead of 90.1% and a reduction of 88.9% in the failure rate (1.1% vs. 9.9%).

The mean length of the tube at the angle of the mouth after intubation (\hat{C}) was 21.64 ± 0.98 cm in all patients (20.67 ± 0.89 cm in females vs. 21.64 ± 0.85 cm in males, $p < 0.001$). The mean length of tubes' tip to carina on chest X-ray after intubation was 3.4 ± 1.12 cm, (3.05 ± 0.95 cm in females and 3.63 ± 1.56 cm in males, $p = 0.048$).

As we mentioned before we use some indexes for estimation of the proper depth of the tube during intubation, one of them was index A. The mean value for A index was 16.67 ± 0.93 cm (16.82 ± 0.84

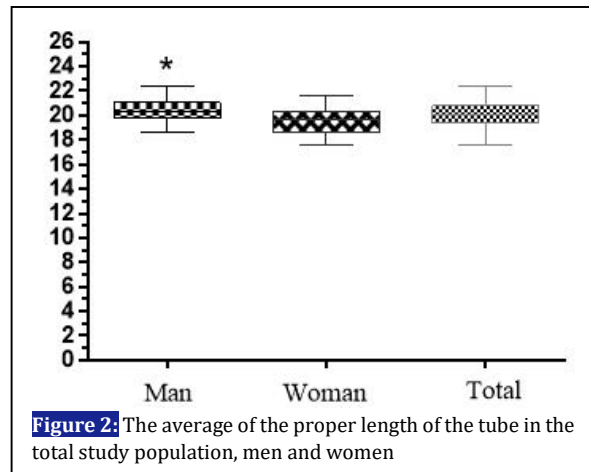


Figure 2: The average of the proper length of the tube in the total study population, men and women

cm in females vs. 16.44 ± 1.02 cm in males, $p > 0.05$). By using this formula, we calculate the proper length for all 91 patients, the total average of this length was 20.07 ± 1.08 cm (19.5 ± 1.12 cm in females vs. 20.44 ± 0.89 cm in males, $p > 0.05$). (Figure 2) So by using this formula we can estimate the proper depth of the tube after measuring the length of the tube from angle of the mouth to suprasternal notch by ultrasonography method.

DISCUSSION

Although intubation is an important and lifesaving procedure, patients may experience serious complications during and after intubation as well as after the extubation. Physicians' skills, speed and accuracy are some of the most important factors which can influence the incidence of these complications (8). Inappropriate depth of the ET tube is one of the main causes of ETT complications. Too deep insertion of the tube can cause pneumothorax in the right lung and atelectasis in the left lung (3, 8). Moreover, inserting the tube with a less than proper length can cause accidental extubation, vocal cords injury and even laryngeal paralysis (9). In order to confirm ETT proper placement, we can use a physical examination, such as lung auscultation, which is not ideal due to the high probability of errors.⁷ Another method is the use of chest X-ray after the intubation. The desired position of ETT is at 5 ± 2 cm distance from the carina (5, 8).

In this study we tried to find a formula for estimation of the depth of the ETT lower than suprasternal notch where we cannot be informed by ultrasound because of the bony sternum by using ultrasonography to find a proper ETT depth. The mean height in our study was 167.9 ± 8.89 . Hence, it can be concluded that our patients had similar demographic and anatomical features as in

the previous studies (10-12). Several studies have been done on marking ETT placement by ultrasonography, some with the aim of proper placement of ETT and some for finding new methods for indirect predicting of the proper depth of the tube (13-15).

Some researchers used topographic measurement to determine the ETT depth like Oron et al. that measured the distance between the right side of the mouth to the right mandible angle and the distance from the right mandible angle to the mid part of the manubrium. With this measurement, the mean ETT depth was 23.21 cm and about 58.5% of ETTs' tips were placed in a distance range of less than 3 cm from the carina (14). In this study, the mean length of ETT tip to carina was 3.40 ± 1.12 cm with an average of 3.05 ± 0.95 cm in female patients and 3.63 ± 1.67 cm in male patients which was compatible with other studies (15).

In one study, Hosseini et al tried to assess the diaphragm movement by using ultrasonography on 57 patients and came to this conclusion that movement of diaphragm can be helpful in diagnosing proper ETT placement with an accuracy of 96% (11). Another study by Ahmadi *et al.* revealed that the proper EET placement can be determined by placing ultrasonography probe on the lower part of the chest on the sagittal axis between anterior and the mid-axillary line (10).

In the current study, we used ultrasonography probe for assessing part of our measurement by putting the probe on the suprasternal notch and recording the ETT length while the tube passed and reverberation disappeared on our monitor and adding $0.05 \times$ ideal weight to it to find the proper depth. We decided to use ultrasonography and topographic measurements at the same time to find some indexes and formula in order to place ETT in proper depth much easier. We simply can insert the tube roughly 0.05 % of ideal body weight deep after the tube is arrived at the suprasternal notch, so by using this formula we could significantly reduce our failure rate to 1.1%. It should be mentioned here that one case did not fulfill the confirmation

criteria in our study just because the distance from ETT's tip to the carina was less than 2cm.

Limitations

In some cases, it was difficult to have bedside ultrasonography during intubation in critical situations. To address this issue, we used a relatively larger sample size in order to get a better result. Also, it should be kept in mind that recognizing the tip of ETT in the suprasternal notch by ultrasonography needs enough expertise but one can simply find this point by other devices like lighted styled. Moreover, it may be difficult to accurately measure patients' height for estimating the proper depth of the tube. Finally, since one case of intubation would fail even by using our formula, further studies are warranted to determine how much this study could be considered as a representative of the efficacy of this new modality.

CONCLUSIONS

Based on the findings of current study, the proper depth of the tube from supra sternal notch equals to $(\text{length} - 100)/20$. Regarding the importance of endotracheal intubation in the emergency room and preventing adverse effects of the intubation, using our formula may be helpful in estimating the proper depth of the tube. More studies need to be done to confirm these findings.

ACKNOWLEDGEMENTS

None.

AUTHORS' CONTRIBUTION

All the authors met the standards of authorship based on the recommendations of the International Committee of Medical Journal Editors.

CONFLICT OF INTEREST

None declared.

FUNDING

None declared.

REFERENCES

1. Jaber S, Jung B, Corne P, Sebbane M, Muller L, Chanques G, et al. An intervention to decrease complications related to endotracheal intubation in the intensive care unit: a prospective, multiple-center study. *Intensive Care Med.* 2010;36(2):248-55.
2. Bahar İ, Elay G, Coşkun R, Gündoğan K, Güven M, Sungur M. Complications of Endotracheal Intubation in the Intensive Care Unit: A Single-center Experience after Training. *Erciyes Med J.* 2015;37(4):133-7.
3. Link M, Berkow L, Kudenchuk P, Halperin H, Hess E, Moitra V, et al. Part 7: Adult Advanced Cardiovascular Life Support: 2015 American Heart Association Guidelines Update for Cardiopulmonary Resuscitation and Emergency Cardiovascular Care. *Circulation.* 2015;132(18 Suppl 2):S444.

4. Collins S, Blank R. Fiberoptic intubation: an overview and update. *Respir Care*. 2014;59(6):865-78.
5. Chou H-C, Tseng W-P, Wang C-H, Ma MH-M, Wang H-P, Huang P-C, et al. Tracheal rapid ultrasound exam (TRUE) for confirming endotracheal tube placement during emergency intubation. *Resuscitation*. 2011;82(10):1279-84.
6. Visser R, Danzl D. Intubation and Mechanical Ventilation. *Tintinallis Emergency Medicine: A Comprehensive study Guide*. 8 ed2016.
7. Robert J. Tracheal Intubation. *Robert and Hedges' Clinical procedures in Emergency Medicine*. 6 ed2014.
8. Nasim F, Chae J, Goel S. Endotracheal intubation in critically ill patients: Direct laryngoscopy, complications, and cardiac arrest. *Am J Respir Crit Care Med*. 2018;197(12):1625-7.
9. Hossein-Nejad H, Payandemehr P, Bashiri S, Nedai H. Chest radiography after endotracheal tube placement: is it necessary or not? *Am J Emerg Med*. 2013;31(8):1181-2.
10. Ahmadi K, Ramezani M, Ebrahimi M. Ultrasound as a Secondary Confirmation Method after Endotracheal Intubation. *Med J Mashhad Uni Med Sci*. 2013;56(4):236-42.
11. Hosseini JS, Talebian MT, Ghafari MH, Eslami V. Secondary confirmation of endotracheal tube position by diaphragm motion in right subcostal ultrasound view. *Int J Crit Illn Inj Sci*. 2013;3(2):113-7.
12. Werner SL, Smith CE, Goldstein JR, Jones RA, Cydulka RK. Pilot study to evaluate the accuracy of ultrasonography in confirming endotracheal tube placement. *Ann Emerg Med*. 2007;49(1):75-80.
13. Weaver B, Lyon M, Blaivas M. Confirmation of endotracheal tube placement after intubation using the ultrasound sliding lung sign. *Acad Emerg Med*. 2006;13(3):239-44.
14. Evron S, Weisenberg M, Harow E, Khazin V, Szmuk P, Gavish D, et al. Proper insertion depth of endotracheal tubes in adults by topographic landmarks measurements. *J Clin Anesth*. 2007;19(1):15-9.
15. Varshney M, Sharma K, Kumar R, Varshney PG. Appropriate depth of placement of oral endotracheal tube and its possible determinants in Indian adult patients. *Indian J Anaesth*. 2011;55(5):488-93.